

THE SURGERY OF THE ALIMENTARY TRACT

BY

SIR HUGH DEVINE

M.S., F.R.A.C.S., F.A.C.S., HON. F.R.C.S (ENG.)

*Formerly Senior Surgeon, St. Vincent's Hospital Clinical School, Melbourne, and other Stewart
Lecturer in Surgery, Melbourne University; President, Royal Australasian College of
Surgeons; Hon. Fellow of the Association of Surgeons of Great Britain and
Ireland; Chairman, Editorial Committee of the Australasian and
New Zealand Journal of Surgery*

WITH 690 ILLUSTRATIONS, SOME IN COLOUR

BRISTOL: JOHN WRIGHT & SONS LTD.
LONDON: SIMPKIN MARSHALL LTD.

1940

PRINTED IN GREAT BRITAIN BY
JOHN WRIGHT AND SONS LTD.
STONEBRIDGE HOUSE, BRISTOL, 1

PREFACE

'THIS book deals with important aspects of the surgery of the alimentary canal and its adnexal organs. It is the fruit of many years' experience of clinical teaching and surgical practice. No attempt has been made to make it a complete and comprehensive treatise on the surgery of the abdomen; such an attempt would destroy its individuality and defeat the author's purpose.

In the first place the work represents a clinical research into the pathology of living tissue as seen at the operation table, with a view to adding to the standard diagnosis of text-books those refinements in clinical, radiological, and other forms of surgical diagnosis which help early and accurate recognition of disease and therefore successful surgical treatment.

In the second place it represents the distillate of surgical experience in regard to selection of operative methods, improvements in the operative technique of the commoner operations, and advantageous pre-operative and post-operative treatment—all with the object of trying to lessen the morbidity of surgical treatment and make it as safe as possible for the patient.

Assuming as it does a certain amount of text-book knowledge, this work is intended mainly for the post-graduate. It will, I feel, be of use to the student as a reference work. But I hope it will be of special value to those who intend to practise, or who are practising, abdominal surgery.

Part I is devoted to the diagnosis of dyspepsia. The reason for this is that the weakness in my own abdominal surgery has been incompetence in clinical diagnosis in contrast to increasing competence in radiological diagnosis and surgical treatment: cases did not reach the radiologist, and therefore the surgeon, as early as they might have done; the organic significance of non-text-book-like syndromes of dyspepsia was not recognized.

With this knowledge in mind, I have tried to add on to the clear-cut text-book pictures of dyspeptic syndromes (usually based on well-established disease) those dyspeptic 'patterns' which are the manifestations of early disease, and which can only be learnt from observation on the pathology of living tissue at the operation

table and the post-operative review of the case-history in the light of the operation findings.

With a view of helping in the early recognition of these early dyspeptic 'patterns', I have attempted to show the mechanism of causation of dyspepsia: how it is that certain diseases produce certain 'patterns' of dyspepsia; how the same disease—for example, gastric carcinoma—may produce many varieties of dyspeptic 'patterns'; and how disease in one case may produce a dyspepsia and in another may be 'silent'. Further, with the object of encouraging early discrimination between the forms of onset of diseases, and therefore early X-ray examination, I have tried to show that in many obscure dyspeptic manifestations a significance attaches to whether the incidence of a dyspepsia is on the filling or emptying of the stomach. I am quite conscious that some of the conceptions I have put forward will not afford a complete explanation in all circumstances, but they will serve, I hope, as directional thought in the search for clinical 'clues' to use in the solution of dyspeptic problems.

With the idea, too, of further improving diagnosis and helping the surgeon to say 'no' when an operation of doubtful value is recommended, I have added chapters on consultative radio-surgical diagnosis. In these I have attempted to overcome the tendency to divorce clinical from radiological diagnosis, and to correlate these by dealing with them as a hypothetical consultation into which I have also woven those equivocal radiological observations which I have been able to check at the operation table.

In this part, Dr. John Horan had very kindly contributed a chapter on Gastroscopy.

Part II deals with the surgical treatment of the diseases which give rise to dyspeptic syndromes. It also has to do with the treatment of diseases of those organs in the upper part of the abdomen other than the stomach—liver, gall-bladder, pancreas, and spleen—which may cause some dyspeptic manifestations. Here, by describing methods of technique in detail and introducing refinements and improvements in everyday operation procedures, I hope to achieve two objects: to lessen the unnecessary morbidity which I find often follows routine abdominal procedures; and to minimize the dangers of operations in the upper part of the abdomen.

The chapter on Hydatid of the Liver—incorporating mostly my own experiences—is concerned with pitfalls in diagnosis as well as operative difficulties.

In Part III will be found chapters on the strategy of surgical approach to a case of intestinal obstruction or of a perforated hollow

organ—affections which may involve the upper or the lower part of the abdomen. In these I have attempted to reproduce the actual circumstances that are found in practice, and to provide the surgeon with a preconceived plan of attack.

Part IV is mostly concerned with the surgery of the appendix, the large bowel, and the rectum.

In the management of appendicitis I have kept in mind the facts that deaths in acute appendicitis generally result from a failure to recognize unusual and non-text-book-like syndromes and from an inability to deal with the unorthodox pathological conditions so frequently and so unexpectedly found in this disease. Accordingly, I have tried to present this subject in a way which will throw into perspective aspects of the disease which are of practical importance, and aspects the study of which will arm the surgeon so that he may detect early, and deal with successfully, the abnormal in acute appendicitis.

In the chapters on the colon and rectum, I have attempted to indicate the way to improved results in the surgery of this region. Since the diagnosis and treatment of diverticulitis have led me along thorny paths, I present my experiences—successful and unsuccessful—for the value they may have to my readers. Because it is a fact that colon carcinoma—a relatively 'benign' malignancy—comes to operation mostly in its middle or late stages, I have made the diagnosis of malignant colon the central point of colonic diagnosis. And for the reason that operations on the distal colon and rectum have a high mortality-rate owing to the surgical disabilities attendant on the peculiar function of these organs, I have described methods designed to ensure that operation and reparative processes in these regions shall take place in an organ temporarily deprived of its function—methods which experience has shown give a lower mortality-rate.

In this work the pathogenesis of disease is not systemically considered, but only so far as it will explain the 'patterns' of disease and the basis of surgical treatment. Many standard methods of technique are not dealt with as these can be found in other works.

My thanks are due to the publishers, Messrs. John Wright & Sons Ltd., for the help I have received from them, and for the manner in which they have produced this work; to Miss Elizabeth Sellenger for the illustrations; and to Professor W. A. Osborne for his help in the correction of proofs.

HUGH DEVINE.

MELBOURNE,

March, 1940.

THE SURGERY OF THE ALIMENTARY TRACT

Section I

THE CLINICAL DIAGNOSIS OF SURGICAL DYSPEPSIA

CHAPTER I

DYSPHAGIA IN THE UPPER PART OF THE ŒSOPHAGUS

THE Œsophagus is fairly well supplied with sensory nerves—better, at any rate, than the stomach—and for this reason a patient can localize an œsophageal lesion. The upper part of the œsophagus is sensitive, the lower part insensitive, to touch; the œsophagus throughout its whole length is sensitive to pressure and to temperature. A patient with obstruction in the œsophagus can therefore generally point to the spot where swallowing is obstructed (*Fig. 1*).

In 85 per cent of cases, carcinoma of the œsophagus is the cause of the obstruction. For this reason dysphagia, to the medical mind, generally means a malignant œsophagus.

Sites of Obstruction in the Œsophagus: the Narrow Places.—Congenitally there are three 'narrow places' in the œsophagus: (1) The level of the larynx, 7 in. from the incisor teeth; (2) The bifurcation of the trachea, 11 in. from the incisor teeth; (3) The lower end of the œsophagus, 17 in. from the incisor teeth, about 2 cm. above its opening into the stomach (*Fig. 2*).

As swallowed fluid will impinge on these narrowings, organic strictures, which result from swallowing corrosive fluids, will naturally occur in these three situations. Spasm of the circular muscle of the œsophagus is also liable to occur in these positions. Furthermore,

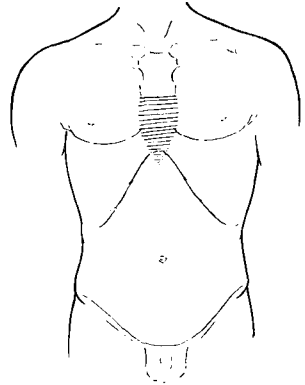


Fig. 1.—Shading indicates the area to which pain is likely to be referred from the lower end of the œsophagus.

they are the favourite sites for malignant growths. Thus it will be seen that the site of an obstruction is a very poor guide to its nature.

In the upper part of the œsophagus the diagnosis of a dysphagia as a rule presents little difficulty, for a dysphagia in this situation

is nearly always caused by a malignant growth.

In this respect it differs from the lower part of the œsophagus, because in that region a diagnosis of a dysphagia presents considerable difficulties; for the innocent condition cardio-

spasm so frequently and unexpectedly occurs in that situation. Clinically, therefore, it is of advantage to discuss the question of dysphagia in relation to site, namely, the three 'narrow places' of the œsophagus, the upper part, the middle part, and the lower part.

In this discussion unusual conditions, such as aneurysm of the aorta, mediastinal tumour, enlarged mediastinal glands, and mediastinal abscess, will not be considered.

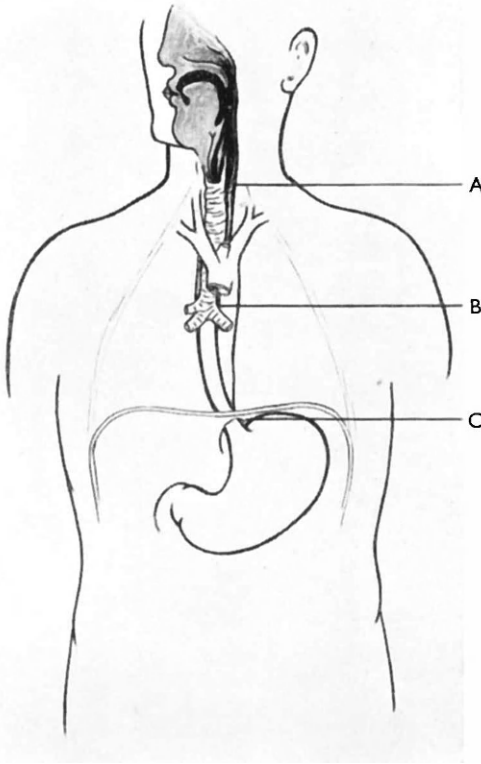


Fig. 2.—The three narrow places in the œsophagus.

DYSPHAGIA IN THE UPPER END OF THE ŒSOPHAGUS

Before discussing dysphagia in the upper end of the œsophagus, it must be pointed out that there are certain malignant conditions which occur in the lower part of the pharynx adjoining the œsophagus and in the pyriform fossa, which lie close to the beginning of the œsophagus, and which give rise to discomfort on swallowing, and these should be considered in relation to this problem of dysphagia.

Hidden Hypopharyngeal Malignancy.—A hypopharyngeal growth may abut on the upper end of the œsophagus and give rise

to symptoms of dysphagia. Most malignant tumours of the pharynx, however, give some symptomatic evidence of their presence and are then easily detected when an examination is made. But there are in the pharynx or its vicinity some forms of malignant growth which are difficult to detect. The cases that follow will serve as examples to illustrate this point.

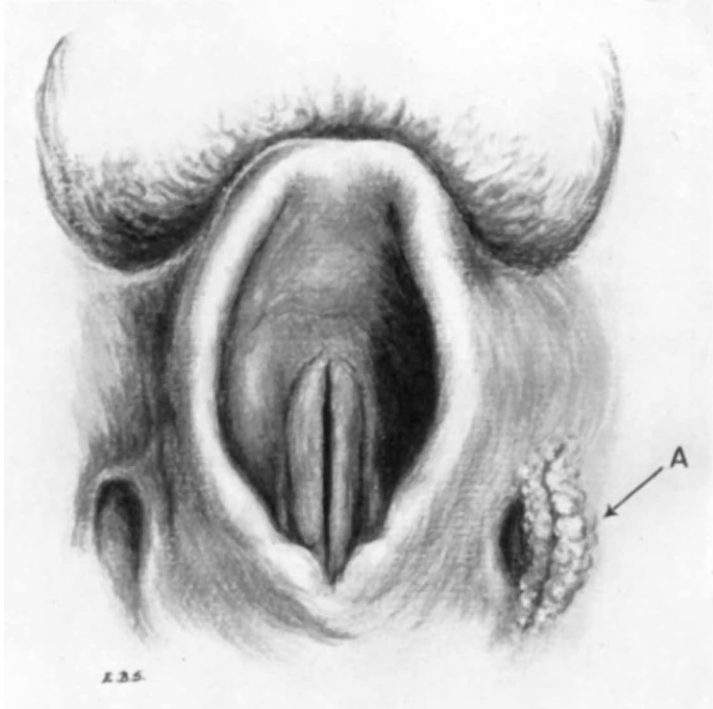

Fig. 3.—A malignant fissure (A) with thickened edges, situated in the pyriform fossa.

Epithelioma of the Pyriform Fossa.—A woman, aged 45, complained that she had a sensation as if something was stuck in the right side of her throat opposite the hyoid bone. She said she was continually 'getting up' mucus, which seemed to come from this spot. A careful examination with the laryngeal mirror revealed nothing. As the symptoms continued, a further examination was made with a direct laryngoscope. A fissure with infiltrated edges was found in the pyriform fossa (Fig. 3).

Epithelioma of the Vallecula.—A man, aged 57, sought advice because he could feel a firm, hard lump in the upper part of his neck. On examination, this lump was found to have all the characteristics of a malignant gland. The pharynx was carefully examined for a primary growth, but nothing abnormal could be found. The gland was removed and a section

showed that it had an epithelial structure and cell-nests. Repeated pharyngeal examinations were now made, but no primary growth could be discovered. Some eighteen months later an epithelioma was discovered growing from the area where the base of the tongue joins the pharynx, that is, from the vallecula.

The reason why this epithelioma could not be seen at first was probably owing to the fact that in its early stages it was a malignant fissure like one of those found in leucoplakia of the tongue (the patient had a leucoplakia of the tongue), and that in the position in which it was situated it would be very difficult to distinguish it from the normal crease in this region.

The history of this patient also exemplifies another important fact: it shows that a malignant gland in the upper part of the neck, even though no primary malignant condition is obvious, is nearly always secondary to a hidden malignancy either in the pharynx, the pyriform fossa, the vallecula, or in some part of the larynx or the upper part of the œsophagus.

The causes of dysphagia in the upper part of the œsophagus are:

(1) Carcinoma of the upper part of the œsophagus; (2) Diverticula.

Carcinoma of the Upper Part of the Œsophagus.—Carcinoma of the upper part of the œsophagus usually occurs in women. The patient complains that the food seems to stop in the region of the larynx; she can point to the actual spot. She may be aphonic from the direct extension of the growth to the vocal cords. Usually she has salivary troubles and dribbles constantly because she cannot swallow her saliva. Examination generally reveals a hard, painless gland in the neck; indeed, this may be the first sign, and may be present for many months before the patient complains of any symptoms. A laryngeal examination easily reveals the growth.

A woman, aged 45, complained that she could not swallow and that the food seemed to cling to a spot opposite her larynx. Two months after the onset of the dysphagia she noticed that her voice became hoarse. She constantly dribbled saliva, which she could not swallow. On examination of the neck, an enlarged, hard, painless gland was discovered.

Diverticulum of the Upper Part of the Œsophagus.—Diverticula occur commonly at the junction of the œsophagus and the pharynx. However, they rarely cause a dysphagia in the upper part of the œsophagus. They are caused by pressure from the inside of the œsophagus and are called 'pressure diverticula', and are congenital. Patients generally give a history of: (a) Long-standing dysphagia; (b) Regurgitations of portions of food after eating; (c) Discomfort and pressure in the neck; (d) A complaint that if

pressure be made on the pouch, some of its contents can be made to empty into the mouth. X rays will show the diverticulum.

Treatment.—The treatment of the so-called pulsion diverticulum of the œsophagus, which actually arises in the pharynx, is removal of the sac and closure of the opening in the pharynx thus made. This may be carried out in a one- or two-stage operation. In the two-stage (Moersch and Judd¹) the sac is first freed and sutured to the neck muscles. Eight days later it is exposed and removed and the neck sutured over. Shallow² employs a one-stage operation. He recommends that after the usual exposure the œsophagoscope should be passed into the sac, which should be emptied by aspiration and pushed into the wound. The sac should then be grasped and the œsophagoscope passed into the œsophagus and kept there while the sac is dissected free, excised, the defect closed, and the wound in the neck closed.

Dysphagia due to traction diverticula is not common, and, furthermore, traction diverticula occur less frequently than pressure diverticula; they also occur farther down in the œsophagus. They are, as a rule, small, and do not give rise to trouble.

DYSPHAGIA IN THE MIDDLE PART OF THE ŒSOPHAGUS

This is generally caused by—

Carcinoma of the Œsophagus at the Level of the Bifurcation of the Trachea.—In this condition the manifestations are as follows: (a) Symptoms of œsophageal obstruction referred to the level of the bifurcation of the trachea; (b) Aphonia caused by paralysis of the recurrent laryngeal nerve; (c) Symptoms of mediastinitis and of pleuritic effusion; (d) Indications of pressure on either bronchus, such as evidence of deficient entry of air into either lung; and (e) It is not uncommon for a carcinoma in this situation to perforate into the bronchus. The following is an example:—

A man, aged 60, complained of a sensation under the upper part of the sternum, as if the food lodged there. He could not, he said, swallow solids, but could get down liquids. His voice had become husky. He regurgitated a small quantity of food after each meal. This had a nasty smell and taste, and was often mixed with blood. He had lost a lot of weight, and looked very pale and ill.

REFERENCES

- ¹ MOERSCH and JUDD, *Surg. Gynecol. and Obst.*, 1934, **58**, April, 781.
² SHALLOW, *Ibid.*, 1936, **62**, March, 624.

CHAPTER II

**DYSPHAGIA IN THE LOWER PART OF THE ŒSOPHAGUS :
DYSPHAGIC DYSPEPSIA**

THE meaning of the term 'dyspepsia'—"the remorse of a guilty stomach"—should, perhaps, be stretched generically to include all those somewhat similar syndromes which arise as the result of disease of almost any part of the alimentary canal or its adnexal organs. The term 'surgical dyspepsia' may then very well be used to indicate all those dyspepsias which are of surgical interest.

In considering the surgical dyspepsias it is necessary to take into account diseases of the lower end of the œsophagus, for manifestations of disease of the stomach, especially of its proximal part, are frequently confused with those of the lower end of the œsophagus.

Obstruction of the lower end of the œsophagus may be due to either innocent or malignant disease, and the early symptoms of these conditions may take the form of a mild dyspepsia with dysphagic symptoms.

The symptoms alone may not give any indication of the nature or the position of the obstruction. A scirrhus obstructing type of carcinoma may grow so slowly that little ill-health is produced, the patient looks well, and a diagnosis of innocent obstruction is made. A fungating carcinoma may ulcerate, break down, and produce only intermittent obstruction and thus give the impression of a dysphagia of innocent cause. This latter type of carcinoma, too, may give rise to a form of dyspepsia similar to that of carcinoma of the body of the stomach.

Cardiospasm, an innocent condition, may occur in old people as well as in young people, and when it does, its symptoms may be confused either with those of a malignant œsophageal obstruction or with some gastric condition.

Generally, however, the clinical problem in an obstruction at the lower end of the œsophagus centres round the practical question of whether it is possible to be able to say, from the symptoms and signs, that the obstruction is non-malignant, that is, innocent cardiospasm; in order words, whether it is possible to relieve the patient from the overhanging shadow of malignancy.

The symptoms and signs of dysphagia in the lower part of the œsophagus should therefore be studied mainly from the above point of view.

CARCINOMA OF THE LOWER END OF THE ŒSOPHAGUS

Carcinoma of the lower end of the œsophagus is usually of the epidermoid type, without cell-nests or cornification. Occasionally, however, the adenocarcinomatous type is seen, and probably this arises from anomalous glands in the wall of the œsophagus, similar to those in the stomach.

It has the following pathological tendencies, each of which gives rise to a characteristic clinical syndrome :—

1. It usually takes the form of an infiltration spreading round the œsophagus as an annular scirrhus type of growth producing a narrowing and an obstruction.

2. It may fungate and ulcerate, when it is very likely to invade the mediastinum.

3. It may form a deep circumscribed ulcer.

4. It may arise as a result of the spread into the œsophagus of a carcinoma of the cardiac end of the stomach.

A growth of the first type, early in its course, gives rise to symptoms of obstruction rather than to those which arise from the constitutional effects of the growth itself, and consequently it is a type of growth where a gastrostomy may prolong life.

In growths of the second, third, and fourth types, symptoms arising from the general constitutional effects which are caused by bleeding and sepsis are more prominent than those from obstruction, and in these kinds of carcinoma a gastrostomy will not prolong life.

As a rule, however, carcinoma of the œsophagus grows rapidly and involves very vital structures and its course rarely exceeds a year.

The Syndrome of Fungating Carcinoma of the Œsophagus Confused with that of Carcinoma of the Fundus of the Stomach.

—While scirrhus carcinoma of the œsophagus always causes dysphagia early in its course, fungating carcinoma, in which ulceration usually predominates, may give rise to dysphagia late in its course, or to such a slight dysphagia in a mild dyspeptic syndrome that the œsophageal origin of the symptoms passes unnoticed. Thus it is not uncommon for patients suffering from this fungating ulcerating type of carcinoma of the œsophagus to be regarded as suffering from carcinoma of the body of the stomach.

An instance of this is the following :—

A man, aged 45, complained of anorexia, loss of energy, and great loss of weight, all of which extended over a period of two months. He had become very anæmic and ill. He had no difficulty whatever in swallowing. A diagnosis of either carcinoma of the body of the stomach or of the body of the pancreas was made. Operation showed that the stomach and pancreas were normal. Two months later symptoms of dysphagia developed, and an œsophagoscopic examination disclosed a fungating carcinoma.

A second instance :—

A man, middle-aged, very pale, anæmic and sick-looking, had lost a great deal of weight. He had no difficulty in swallowing. His condition was thought to be due to carcinoma of the stomach. A radiograph showed a small stomach with no apparent evidence of malignancy, and the routine X-ray examination of the œsophagus did not give rise to a suspicion of carcinomatous involvement. Notwithstanding these negative findings, the patient's symptoms were so like those of carcinoma of the body of the stomach that an exploratory operation was performed. The stomach was found to be normal. The patient died without a diagnosis having been made. Post-mortem examination revealed a deep malignant ulcer of the œsophagus which had caused no obstruction.

The Syndrome of Dysphagic Dyspepsia Caused by Carcinoma of the Lower Part of the Œsophagus.—Unlike carcinoma of the upper part of the œsophagus, which is commoner in women, carcinoma of the lower part is more frequent in men. In carcinoma of this region an obstruction to solid food develops gradually, generally in a man over forty, and gets steadily worse. As distinguished from an obstruction of an innocent nature like cardiospasm, the symptoms have been present over a period of months rather than years, and show no intermissions.

The patient notices that he eructates food, that he does not actually vomit it, and that the food eructated has not the usual sour taste of vomited material ; but that, owing to the ulceration of the growth, it has a bad taste and a bad smell.

In the early stages of the disease, while the growth is small, the patient may be hungry and may have a healthy appearance. In the later stages, however, he becomes anorexic, loses energy and weight, and looks very ill. Sometimes an improvement in his dysphagia, owing to the ulceration and breaking down of an obstructing fungation, may lead to the belief that it is of innocent origin.

As a rule the patient can point to the site, usually over the 7th costal cartilage, where he thinks the food is held up.

CARDIOSPASM

The Syndrome of Dysphagic Dyspepsia caused by Innocent Obstruction of the Lower End of the Œsophagus.—‘Cardiospasm’ and ‘achalasia’ are names given to a curious but fairly

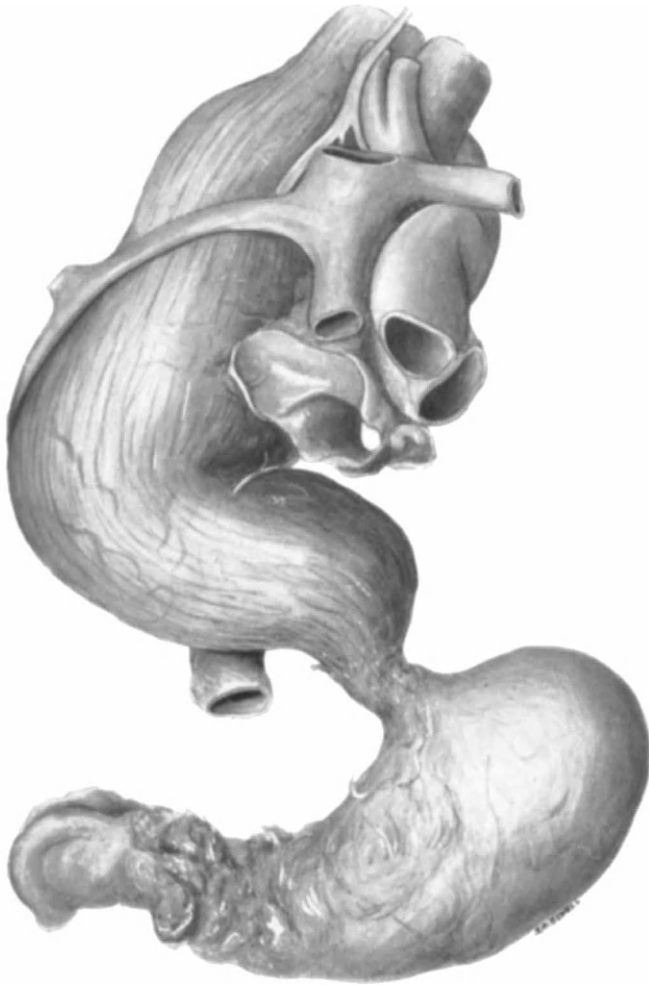

Fig. 4.—Post-mortem specimen of cardiospasm. (From Rutherford Morison's 'Introduction to Surgery'.)

common disorder of the neuromuscular mechanism of the lower end of the œsophagus. In this condition the œsophagus is, as a rule, greatly dilated as far as the hiatus of the diaphragm (*Fig 4*). So far

as my observations have shown, the sphincter permits an œsophago-scope to pass without offering any obstruction.

There are various views as to the aetiology of cardiospasm. Some pathologists think that it is caused by a degeneration of the vagus nerve-endings which disturbs the balance of the autonomic system and allows overaction of the sympathetic. A gunshot, wounding the vagus, has caused a dilatation of the œsophagus similar to a cardiospasm. I have seen a case of cardiospasm in which an œsophageal ulcer—apparently a primary one following typhoid—was present. In this case it is conceivable that the ulcer may have caused an irritative spasm of the circular muscle of the lower end of the œsophagus and thus produced the cardiospasm. Hurst asserts that cardiospasm is due to the fact that the cardia has lost the power to relax, and he therefore coined the name ‘achalasia’ for the condition. It has been thought that it may be the result of overaction of the sympathetic, causing contraction of the cardia and relaxation of the œsophageal wall—a condition akin to gastric and duodenal ileus. It is a clinical fact that it is often associated with ulcers in the œsophagus, but as a rule these ulcers are secondary and the result of infection arising from stasis of food following the great dilatation.

The lower end of the œsophagus probably possesses a nerve-supply on parallel lines to that of every other segment of the alimentary canal. We know it has a vagal supply. According to recent work (Mitchell¹) the lower part of the œsophagus receives filaments from both sympathetic ganglionated trunks. These fibres arise from the 6th to the 9th or 10th ganglia, and unite with the vagal plexus or penetrate the œsophageal wall directly.

Thus, regarded from a clinical point of view, it is most likely that the causation of cardiospasm is similar to that of the various gross pathological dilatations—“idiopathic dilatations”—which sporadically occur in the other sections of the alimentary canal (*see* p. 52). It is also likely that it is only amenable to the principles of treatment which govern these dilatations.

The following history is typical of a case of cardiospasm:—

In a woman, aged 45, illness came on *suddenly* four and a half months previous to being seen, with a *severe pain* situated over the middle of the sternum. This pain lasted for ten minutes, and then gradually disappeared. Subsequently she had two similar attacks. Then she began to get *hiccups* as soon as she took any food, and while food was proceeding down the œsophagus she had a sensation as if it was passing over a raw surface. The food, she thought, did not get right down into the stomach. A month later she said she began to vomit after taking solid food. The vomitus did not taste sour, and had no bad taste or smell. She had a good

appetite. She could not, she said, swallow solids ; but if she drank a large glass of water quickly, it would wash solid food through into the stomach. She looked healthy. In three months she had lost 7 lb. in weight. An œsophagoscope could be passed through the cardiac orifice without any sense of obstruction. Although this patient was treated by hydrostatic dilatation and by gastrostomy she never got completely well, and she died, about five years after the onset of her trouble, of some intercurrent disease caused by asthenia.

The following history illustrates a case of cardiospasm with a somewhat different clinical pattern :—

The patient thinks that all her food seems to stop just above her epigastric notch. She has pain, which is situated over the 7th costal cartilage, which radiates round the lower part of the thorax, and which strikes through to the back. She can swallow fluids fairly easily if they are hot, but she cannot swallow meat or bread. She has had only a little loss of weight. She says that the difficulty in swallowing came on rather suddenly nine years ago. At that time she had a lot of frothing from the mouth ; then, on taking food, it seemed to stop in the upper part of the œsophagus and choke her ; and finally she had to go to a doctor to have a tube passed. After that, swallowing was better for a while, but the trouble soon came back. She has had the cardiospasm treated for nine years with various methods of dilatation, including a mercury tube, but she has not improved.

(This case was relieved by manual dilatation of the lower end of the œsophagus, and the patient has been well for some years.)

These two case-histories are typical of usual types of cardiospasm. In many instances, however, this condition comes on without pain and very insidiously. The patient may complain only of substernal fullness and discomfort after meals, followed by regurgitation of food.

The Dysphagic Dyspeptic Symptoms of Cardiospasm Confused with those of Gastric Affections.—As cardiospasm may arise on the one hand with a dyspeptic pattern in which pain may be a predominant feature, and on the other hand with a dyspeptic syndrome in which pain is absent, it is not surprising that it should be confused with gastric affections, and it is not uncommon for it to remain unrecognized.

The following case-history may be regarded as an illustrative example :—

A female patient, who complained of “ indigestion ”, of “ vomiting ” immediately after meals, and of a slight menorrhagia, consulted a gynæcologist. Assuming that her ‘ dyspepsia ’ was caused by a uterine condition, the gynæcologist removed a diseased uterus. She continued to “ vomit ” in an alarming way after her operation. Investigation showed that this was not true vomiting, but that the food was just regurgitated and did not taste sour. A radiograph showed that she was suffering from very gross cardiospasm.

Diagnosis from Carcinoma.—The following table shows the difference between cardiospasm and malignant œsophagus.

CARDIOSPASM	MALIGNANT ŒSOPHAGUS
Situated at the hiatus of diaphragm or at the cardia.	If the radiograph shows the obstruction to be other than this, it is likely to be carcinoma.
More frequent in females and in young people (neurotic).	More frequent in males and in persons over 40 years.
Onset is sudden, and symptoms do not progress. Intermissions occasionally.	Onset is gradual; symptoms get steadily worse. Rarely any intermission.
Pain substernal, sharp and lancinating, and often symptoms of vagus nerve stimulation.	More discomfort than pain.
Regurgitated material tastes sweet and smells sweet, and is copious as the dilatation is big. Patients are comparatively well notwithstanding great dilatation of the œsophagus.	Regurgitated material smells bad and tastes nasty (from ulceration), and is scanty because dilatation is moderate. Patients die before the dilatation gets very big.
Patients look fairly healthy, even after twelve or eighteen months.	Patients look very sick, and are often cachectic even after an illness of a few months.
Wasting not so marked.	Wasting very marked.
A glass of water, drunk quickly, may enable patient to swallow solid food.	A glass of water will make no difference to the swallowing of solid food.
Bougie may be passed, after which the symptoms may improve.	Bougie cannot, as a rule, be passed.
Radiograph shows the œsophagus in the proximity of the obstruction free from any infiltration, and therefore of the shape of the lower end of a turnip; and the dilatation of the œsophagus is sometimes enormous.	Radiograph has a characteristic appearance; the œsophagus in the proximity of the obstruction is, as a result of infiltration of its walls, the shape of the lower end of a carrot; and the dilatation of the œsophagus is not very great; the patient dies before the dilatation can become as big as that resulting from cardiospasm.
No enlarged lymph-gland can be found in the neck.	Occasionally an enlarged lymph-gland may be found in the neck.
Œsophagoscope discloses no obstruction, but a greatly dilated œsophagus.	Œsophagoscope encounters obstruction, and a small piece may be removed and examined with the microscope.

Cardiospasm Mistaken for Malignant Œsophagus.—It is worth remembering that cardiospasm is much more frequently present than is generally supposed, and may so mimic the symptoms of carcinoma of the œsophagus that it is mistaken for this condition. I should like to quote an instructive mistake to illustrate this point.

A man, aged 59 years, cachectic, very emaciated, who appeared to be in the last stages of malignancy, was found, on X-ray examination, to have an enormously dilated stomach. His clinical manifestations and the X-ray appearance of his stomach suggested that he was suffering from carcinoma of the pylorus which was the cause of his pyloric obstruction. At operation I was surprised to find that his pyloric obstruction was caused by a healed ulcer-scar—an innocent condition. I performed a gastro-enterostomy. Five months after the operation he returned, complaining of great difficulty in swallowing. I now felt that I had made a mistake, and that the malignant appearance of the patient and his very bad ill-health before the operation must have been the result of early carcinoma of the œsophagus, a condition which I felt sure was now the cause of his dysphagia. I felt that the innocent ulcer-scar pyloric stenosis must have been a coexisting condition.

Although in the radiograph (Fig. 5) the lower end of the œsophagus was rather rounded, and therefore did not appear to be infiltrated by a carcinoma, I felt that the slightly irregular isthmus (Fig. 5, A) and the moderate dilatation of the œsophagus indicated a malignant obstruction. In the belief, therefore, that he was suffering from carcinoma of the œsophagus, I did a gastrostomy. Two years later the patient was so well that the family doctor came to the conclusion that the obstruction must have been the result of a cardiospasm, and allowed the gastrostomy opening to close. The patient again became very ill and cachectic, developed mediastinal symptoms and opacities (as seen by X rays) through the lung, and appeared to be in a dying condition. His serious condition, I now thought, proved that his œsophageal obstruction was certainly malignant, and that the assumption of the family doctor was wrong. As a forlorn hope I again performed gastrostomy. The patient rapidly recovered, and was alive and well many years later. The man's condition was always so bad at the time of treatment that it was never possible to make an œsophagoscopic examination. Eventually an œsophagoscopic examination was made, enabling a definite diagnosis of cardiospasm to be made.

This case is a good example of the great difficulty of distinguishing between a cardiospasm and a malignant obstruction.

Comparison of X-ray Appearance of Cardiospasm and Carcinoma of the Lower End of the Œsophagus.—The X-ray diagnosis centres

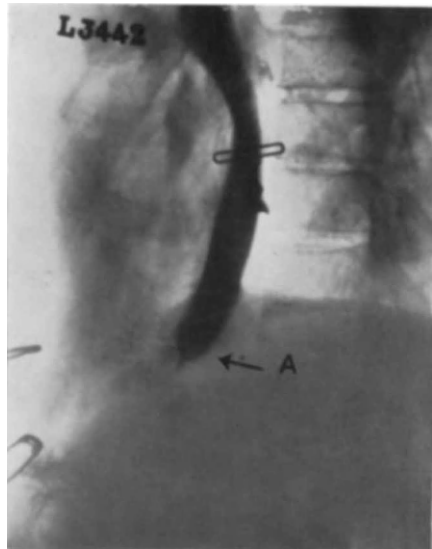


Fig. 5.—Radiograph of cardiospasm. (By courtesy of Dr. H. M. Hewlett.)

round the extent of the œsophageal dilatation; upon the exact observation of the shape and contours of the lower end of the œsophagus, just above the obstruction; and upon the position, contours, and density of the shadow of the isthmus at the point of obstruction.

In cardiospasm, the lower end of the œsophagus is smoothly round with sharp edges, and with a little projection coming from it; in other words, there is no infiltration around the part of the

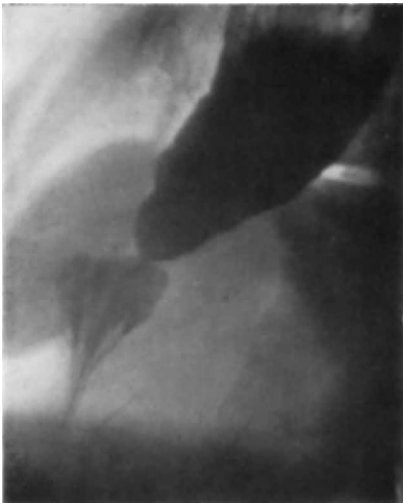

Fig. 6.—Radiograph of cardiospasm.

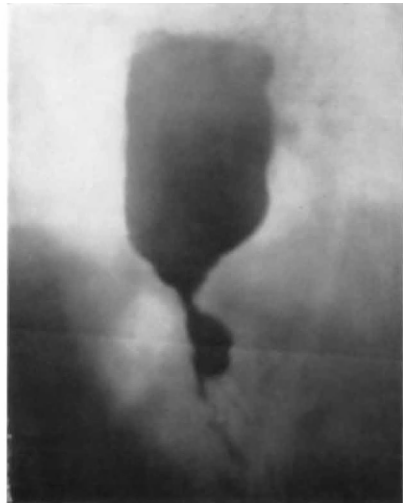

Fig. 7.—Radiograph of cardiospasm. (By courtesy of Dr. H. M. Hewlett.)

Figs. 6 and 7 show the great dilatation which occurs in cardiospasm, and also the characteristic shape of the lower end, which is not tapering, but bluntly rounded or bellying with a small point.

œsophagus which approximates the spasm; the X-ray shadow resembles the lower end of a turnip. Further, the shadow of the barium-filled œsophagus shows great dilatation, much greater than that seen in carcinoma. (*Figs. 6, 7.*)

In carcinomatous obstruction the lower end of the œsophagus tapers like a carrot, and its edges are ill-defined and wavy, because they are infiltrated and do not expand evenly or show sharp outlines. The barium-filled œsophagus does not show as great a dilatation as in the case of cardiospasm, and its barium shadow will be seen to terminate in a cone pointing downwards, from the apex of which a fine twisted stream of barium emulsion will be observed making its way through the tortuous irregularities of the growth.

Fig. 8 is a radiograph of a carcinoma of the œsophagus showing these characteristics.

Transient Cardiospasm.—Mild dysphagic disturbances of a transient character are occasionally found in association with inflammatory disease of the gall-bladder or of the stomach and duodenum. These disturbances are probably caused by a mild degree of cardiospasm, probably reflexly caused by the disease in the stomach, duodenum, or gall-bladder. The higher the ulcer is on the lesser curvature, the more likely it is to cause these dysphagic disturbances. In such cases X rays show a slowing-up of the barium meal in the œsophagus, but never any dilatation of the œsophagus.

Occasionally ulcer of the stomach or duodenum may be found associated with a typical cardiospasm.

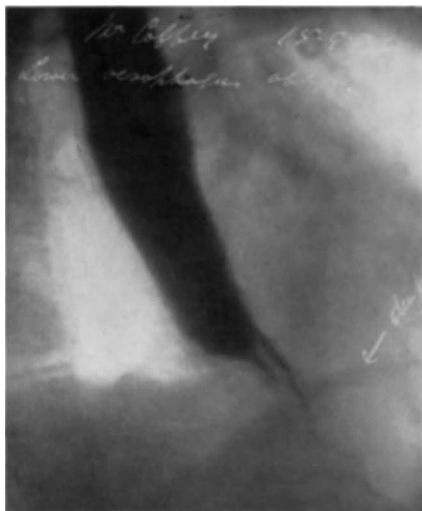

Fig. 8.—This radiograph shows the characteristic tapering lower end in carcinoma of the œsophagus. (By courtesy of Dr. H. M. Hewlett.)

CHRONIC PEPTIC ULCER OF THE ŒSOPHAGUS

Chronic peptic ulcer of the œsophagus occurs more frequently than is generally thought. It is seen in association with chronic ulcer of the stomach or duodenum, when the symptoms are often obscured by those of the gastric or duodenal lesions. Alexander Lyall² has reported eight cases of chronic peptic ulcer of the œsophagus which he found at post-mortem. In half of these cases a coexistent gastric or duodenal ulcer was present.

The symptoms of a chronic ulcer of the œsophagus are as a rule pain on the taking of food; the pain is substernal, and sometimes spreads into the epigastrium; it is often mistaken for the pain of gastric or duodenal ulcer. Dysphagia, more or less severe, is also a prominent symptom. The X-ray manifestations may show a delay in the œsophagus of a barium meal, and it may be possible to demonstrate an ulcer niche. Such a case is described by Sauerbruch³:—

An emaciated woman of 37 was admitted to the clinic with the following history. Her illness had begun seven years previously with

pain in the epigastrium and vomiting. Swallowing became progressively more difficult, and treatment by œsophageal dilatation had given only temporary relief. Radiological examination clearly demonstrated a small ulcer about 2 cm. above the diaphragm, and there was marked spasm of the cardia.

Operation (Sauerbruch).—Jejunostomy was carried out, and during the operation a small ulcer could be felt on the posterior wall of the œsophagus, immediately above the hiatus. The stomach and duodenum were normal. After nineteen days the symptoms were so far relieved that food could be swallowed without distress, and when the patient was examined three years later swallowing was normal and all trace of the ulcer had disappeared.

ŒSOPHAGITIS AS A CAUSE OF DYSPHAGIC DYSPEPSIA

Not infrequently an œsophagitis is found associated with high gastric acidity. I have seen it follow the undoing of a gastro-enterostomy where there was a sudden rise in gastric acidity. Œsophagitis gives rise to sternal pain following the intake of food, and a slight dysphagia. It, too, must be distinguished from gastric and duodenal dyspeptic syndromes.

DYSPHAGIC DYSPEPSIA REFLEXLY CAUSED

It is not uncommon to find a dysphagic dyspepsia reflexly caused in the same way as a disturbance of the filling and the emptying of the stomach is caused by inflammatory lesions in the alimentary canal, or in its adnexal organs such as the gall-bladder. In the case described on p. 15, where cardiospasm was found to be associated with ulcer stenosis of the pylorus, it is possible that the œsophageal condition was reflexly caused by neuromuscular disturbance originating from the inflammatory disease in the pylorus. Spasm of the cardia with mild pain beneath the xiphisternum is sometimes seen in cases of inflammatory disease of the gall-bladder, and more frequently in inflammatory disease of the stomach or duodenum. When the disease of the stomach is high up towards the cardia, œsophageal disturbances are frequent, and there may be considerable delay in the œsophagus of a swallowed barium meal. Moersch and Walters⁴ have demonstrated that "under certain conditions, stimulation of the peripheral ends of the splanchnic nerve, the gall-bladder, the urinary bladder, and the intestines, produces spasm of the cardia", and they express the belief that "the splanchnic nerves are the main afferent paths and, in part, the efferent paths for the reflex". An œsophageal cardiospasm produced in this way, if well established, is not always relieved when the primary gastric or cholecystic lesion is cured.

Carrington has pointed out that diaphragmatic hernia is frequently found associated with some cardiospasm.

THE PLUMMER-VINSON SYNDROME

A syndrome of dysphagia associated with a hypochromic anæmia, a well-marked atrophic glossitis, and an achlorhydria, is described by Plummer and Vinson. It is seen in thin and edentulous females. At first sight the condition appears to be caused by carcinoma of the œsophagus. A blood examination, however, clears up the diagnosis.

THE TREATMENT OF DYSPHAGIA

Where the Obstruction is Caused by Carcinoma.—In the treatment of dysphagia caused by carcinoma, the only hope of helping the patient depends upon the type of carcinoma; if it is of the scirrhous type it grows slowly, produces obstruction early, and a gastrostomy will prolong the patient's life; if, however, the growth is of the fungating type, obstruction is not such a factor as a toxæmia from a rapidly growing cancer, and gastrostomy will not help. In this latter type of growth, implantation of radon seeds may keep the growth in check and prolong the life of the patient. The radon seeds are implanted by a specially made introducer which is used under direct vision through an œsophagoscope. The use of radium is not without danger to the œsophageal wall, and recurrence is the rule.

Where the Obstruction is Caused by Cardiospasm.—The treatment of cardiospasm will depend a good deal on its degree. Dilatation of the cardiospasm brings about an improvement in most cases. It may be produced either by hydrostatic pressure or by manual dilatation.

Dilatation by Hydrostatic Pressure.—Plummer of the Mayo Clinic devised a method of dilating the œsophagus by hydrostatic pressure. The dilator is depicted in *Fig. 9*. In using this method it is necessary, as a preliminary, to make the patient swallow snarls of fine silk, which are washed through the cardiospasm by a draught of water into the intestinal coils, where they become fixed. On this thread, which is held taut, the end of the hydrostatic dilator is threaded and it is then passed through the cardiospasm, the thread guiding the dilator through the eccentric opening of the cardiospasm.

It is necessary to use the greatest gentleness, because the œsophageal wall is very thin, and may be easily perforated. The position of the dilator should be adjusted in front of the X-ray screen. A water pressure of 10 lb. is used to dilate the bag. If the bag is in the proper position, the patient should experience pain when the bag is distended with the water pressure. If no pain is experienced, the bag should be adjusted till, when the pressure is applied, a pain is produced. This dilatation may have to be repeated several times

at intervals. Frequently the results of this treatment are dramatic, and the patient is often able to swallow food at once.

Dilatation by the Use of a Mercury Tube.—Hurst advocates the use of a mercury tube and for it claims many cures.

Manual Dilatation.—It often happens that the treatment of cardiospasm by hydrostatic pressure or a mercury tube fails to cure a cardiospasm. In such a case, it is the experience of many surgeons (Walton, Wakeley, and others) and my own that manual dilatation of the cardiospasm will, in practically all cases, relieve the condition.

Manual dilatation of the cardiospasm requires an abdominal operation. The two precautions that experience has taught me are essential for the safety of manual dilatations are: (a) To regard the œsophageal contents as septic, and take special precautions to prevent their infecting not only the peritoneal cavity but also the abdominal

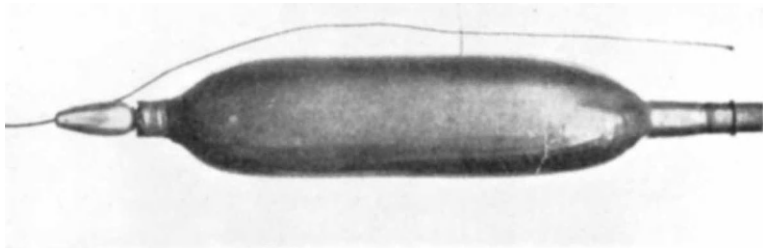


Fig. 9.—The Plummer hydrostatic dilator. (From the 'Collected Papers of the Mayo Clinic'.)

wall wound; and (b) To take a long while to dilate the cardiospasm, so that the muscle fibres are stretched so slowly that they will not rupture and predispose to the formation of a mediastinitis, the great danger in manual dilatation.

The steps of the operation are as follows:—

1. As a preliminary to the operation the œsophagus must be faithfully washed out for three or four days before the operation. The reason for this is that stasis of food in the œsophagus causes considerable infection, and this is liable to cause infection of the abdominal wound or peritoneum, for, unlike the contents of the stomach, the sterility of which is ensured by the presence of hydrochloric acid, those of the œsophagus in a case of cardiospasm are not sterile.

2. A left upper paramedian incision is made, extending to the lower edge of the thorax.

3. The abdomen is opened, and the author's operating frame (see Chapter XXXIV) inserted in the wound (Fig. 10), and used to clamp impermeable protective towels over the edges of the wound.

4. A trocar is now inserted into the stomach, and its contents are aspirated.

5. The stomach is opened as near as possible to the œsophagus by an incision in its long axis. It is then 'vacuum-cleaned' with a sucker. Very gently and very slowly two and then three and finally four fingers are inserted into the cardia, and the 'cardiospasm' is dilated ever so gently. It is necessary to emphasize this, for unless the dilatation is carried out very slowly it is extremely easy to cause a tear, or to bruise the thin œsophageal wall, with the result that the mediastinum may become infected and a fatal result ensue.

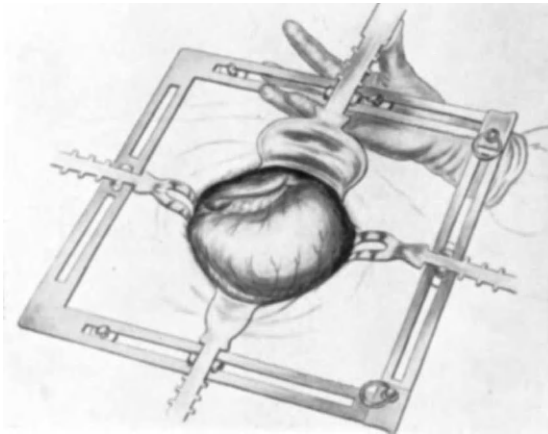


Fig. 10.—Operating frame set in position, exposing the fundus of the stomach.

As an example of the efficacy of manual dilatation, the following case, one of several, is quoted :—

A patient suffered from a cardiospasm which was so bad that he could scarcely swallow any food at all. Over a period of three years he had lost four stone in weight, and had become so ill that he was quite unable to work. The cardiospasm had been dilated repeatedly with Plummer's hydrostatic dilator, without any improvement in swallowing. Finally it was decided to dilate the cardiospasm manually. The result was dramatic. He was able to swallow very soon after the operation, and his spasm was completely cured. Twelve months after the operation he had gained three stone in weight, and now, eight years after the operation, is still quite well. *Fig. 11* is a radiograph of this patient's œsophagus taken before the dilatation. When he was examined eight years later, he said he had no difficulty in swallowing any kind of food, unless he swallowed it too quickly. Then he would experience some difficulty, but a glass of water would relieve this at once. A radiograph showed that the food did not go straight through the œsophagus into the stomach, but there was a

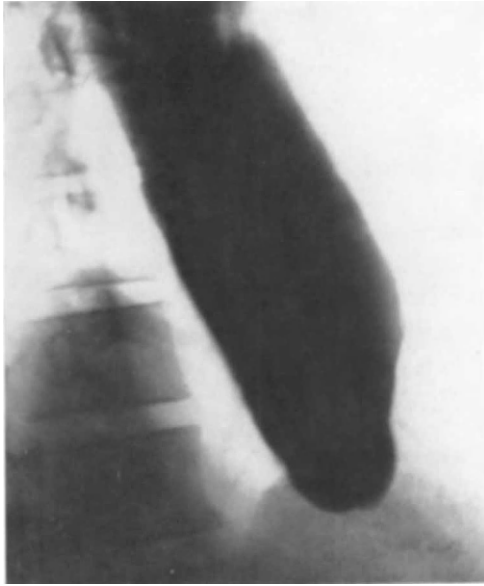

Fig. 11.—Radiograph of œsophagus taken before the manual dilatation.

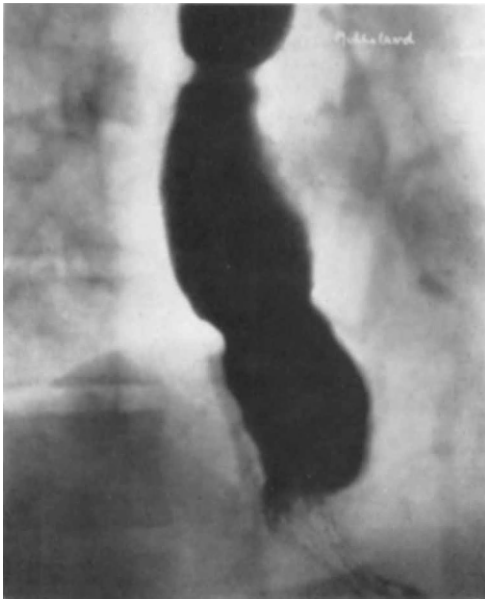

Fig. 12.—Radiograph taken eight years after manual dilatation.
(Ten minutes after a meal.)

delay of about ten or fifteen minutes. *Fig. 12* is a radiograph of the œsophagus taken eight years after the manual dilatation. It shows that ten minutes after a meal there is still a certain amount of food in the œsophagus. The patient, however, is not conscious of any delay. In this radiograph it will be noticed that the œsophagus has not contracted, and that as a matter of fact there is not a great deal of difference in its appearance from that shown in *Fig. 12*, which was taken before the manual dilatation. Other cases of cardiospasm treated by manual dilatation showed little diminution in the barium shadow, although the symptoms were relieved.

As an example of the dangers of manually dilating a cardiospasm the history of the following case is instructive :

A man had for years complained of difficulty in swallowing. A radiograph revealed that he had a cardiospasm with an enormous dilatation of the œsophagus. Over a period of twelve months the cardiospasm was repeatedly dilated with Plummer's hydrostatic dilator, without obtaining any improvement in his swallowing. It was then decided to dilate the cardiospasm manually, and the patient was operated on for that purpose. The dilatation was carried out very gently; notwithstanding this, three days after the operation the patient became very ill and died from mediastinal infection.

Division of the Sympathetic Supply of the Lower End of the Œsophagus.—The sympathetic fibres running on the left of the left gastric artery, fibres which supply the lower end of the œsophagus, have been divided, by Knight⁵ and others, with a view to relieving the cardiospasm. The principle on which this operation is based is that the cause of the cardiospasm is an imbalance between the sympathetic fibres which are supposed to supply the cardiac sphincter, and the vagus fibres which innervate the wall of the œsophagus. So far, no very definite permanent satisfactory results have followed the use of this operation, and the results seem to be on a level with those of division of the sympathetic in the treatment of other pathological dilatations in other sections of the alimentary canal.

REFERENCES

- ¹ MITCHELL, G. A. G., "The Nerve-supply of the Gastro-œsophageal Junction", *Brit. Jour. Surg.*, 1938, **26**, 333.
- ² LYALL, A., *Brit. Jour. Surg.*, 1937, **24**, 534.
- ³ SAUERBRUCH, F., and O'SHAUGHNESSY, L., *Thoracic Surgery*, 315.
- ⁴ BALFOUR and EUSTERMAN, *The Stomach and Duodenum*, 716.
- ⁵ KNIGHT, G. C., "Sympathectomy in the Treatment of Achalasia of the Cardia", *Brit. Jour. Surg.*, 1935, **22**, 864.

CHAPTER III

THE SYMPTOMS OF DYSPEPSIA

IN healthy persons the ingestion of food is a pleasant function, and the subsequent digestion and absorption quite an unconscious process. Any discomfort or unpleasant manifestations following the intake of food may be classed under the name of 'dyspepsia'.

Dyspepsia, then, is an awareness of the process of digestion. It is caused by a great variety of diseases. Its main cause, of course, is disease of the stomach; but it may arise from disease anywhere in the alimentary canal, or as a reflexion of disease in any part of the body.

General Symptoms of Dyspepsia.—General manifestations of dyspepsia may consist of any, or all, of the following symptoms or signs:—

1. Fullness, discomfort, pain.
2. Nausea, vomiting with or without definite relation to food, and with or without relief of the dyspeptic symptoms.
3. Flatulence, heartburn, and acid eructations.
4. Epigastric reflex rigidity and tenderness.
5. Epigastric cutaneous hyperæsthesia.
6. 'Deep tender spot' (visceral tenderness).

The preponderance of one or more of these manifestations, or a particular combination of some of them, may form types or patterns of dyspepsia which are characteristic of the disease causing them.

Thus, careful study of the various forms of dyspepsia and how they are caused is of value in the early recognition of disease.

Of the dyspeptic manifestations above enumerated, the most important from a diagnostic point of view are: fullness, discomfort, and pain; vomiting, if it occurs in definite relation to the taking of food; and 'deep tender spot' (visceral tenderness).

1. *Fullness, Discomfort, Pain.*—Fullness and discomfort may be regarded as minor degrees of pain. Pain, when it is present, is one of the most informative symptoms in a dyspepsia complex.

2. *Nausea and Vomiting.*—Nausea is present to a greater or lesser extent in the majority of dyspeptic syndromes. It varies, however, in its incidence in relation to the taking of food. Its variation may have a significance of diagnostic value in distinguishing a dyspepsia of innocent origin from one of malignant origin.

Vomiting is more often caused by a derangement of function than by organic disease. It presents various types, the difference between which can be recognized. Thus the symptom of vomiting, keenly scrutinized, becomes of diagnostic value.

3. *Flatulence, Heartburn, and Acid Eructations*.—In every dyspeptic picture there are general symptoms such as flatulence, heartburn, etc.; symptoms which are of little value in making a diagnosis.

4. *Epigastric Reflex Rigidity and Tenderness*.—With any of the manifestations of a dyspepsia there may be an epigastric rigidity and tenderness. These sensory signs correspond to the supply of the 7th, 8th, and 9th nerve-roots to the abdominal wall. Painful afferent impulses from the stomach pass by the sympathetic rami through these nerve-roots to the corresponding segments of the spinal cord. These impulses cause an increased excitability of these segments, and this is reflected in the corresponding sensory innervation of the abdominal wall.

This reflex rigidity and tenderness is always situated in the epigastrium, and therefore does not correspond to the anatomical position of the stomach, for the reason that this organ has dropped owing to man's upright position (*Fig. 13*).

5. *Epigastric Cutaneous Hyperæsthesia*.—An epigastric hyper-sensitivity is not constant in its appearance, even in the case of an organic gastric lesion. It is not uncommon to find at operation a gastric or duodenal ulcer where no cutaneous hyperæsthesia has been present before the operation. It is therefore not a consistent sign in a dyspepsia, nor one on which reliance can be placed. It is probably like the pain of ulcer, which depends largely on the degree of inflammatory infiltration of the ulcer.

6. *'Deep Tender Spot'* (Visceral Tenderness).—In contradistinction to diffuse epigastric tenderness, a local 'deep tender spot' is found over an area of localized inflammation in the stomach such as that caused by a chronic gastric or duodenal ulcer.

If a chronic ulcer be visualized on the X-ray screen and pressed upon, it will be found to be exquisitely tender. It will also be noticed that the tenderness is very local, and corresponds accurately to the situation of the ulcer (*Fig. 13, A*). Such a 'deep tender spot' definitely indicates organic disease.

This 'deep tender spot' may not, in the case of chronic ulcer, be always present. As a matter of experience, it has been found that the greater the inflammatory reaction in the ulcer the greater the tenderness of the 'deep tender spot'. Thus, in some chronic ulcers in which the inflammatory infiltration is inadequate to cause pain (*see p. 34*), the 'deep tender spot' may be absent.

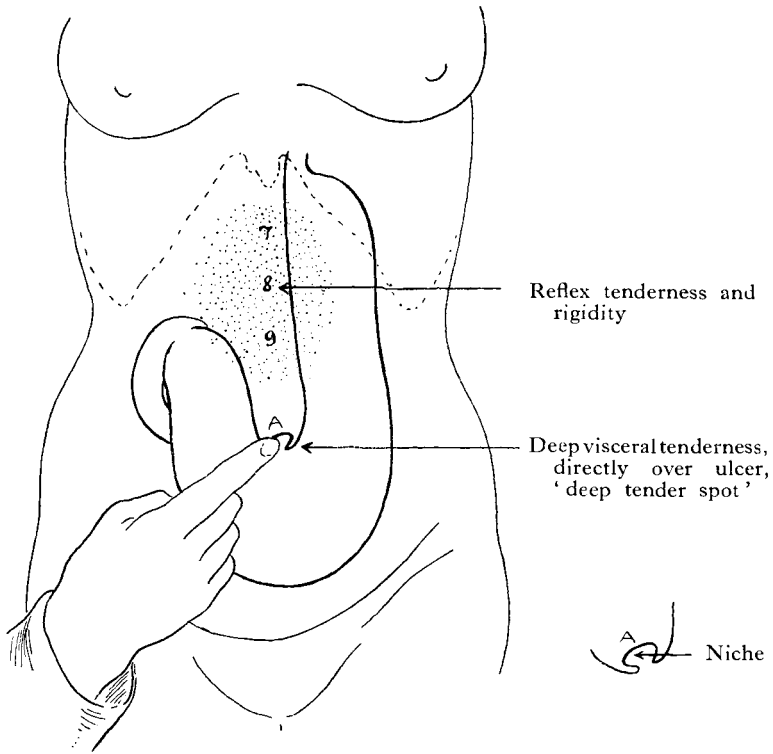


Fig. 13.—Diagram showing the position of the reflex rigidity and tenderness, corresponding to the 7th, 8th, and 9th segments. A indicates the 'deep tender spot'.

The Great Variety of Dyspeptic Syndromes.—Dyspeptic symptoms and signs may so combine that they can form an almost infinite number of patterns, each of which may indicate either a particular phase of functional disturbance of the stomach, or a type or a degree of organic disease of the stomach.

For example, functional disease of the stomach may cause a dyspeptic syndrome almost indistinguishable from that of an early carcinoma. It may, on the other hand, produce a clinical picture of dyspepsia which is easily confused with that caused by a type of gastric ulcer. Again, a certain type of carcinoma of the stomach may give rise to a dyspepsia similar to that of gastric ulcer, and another type may cause a dyspeptic picture similar to that found in duodenal ulcer. Also, an extragastric alimentary lesion may cause a dyspepsia like that of gastric ulcer or carcinoma, and systemic disease may give a picture of organic disease of the stomach.

Thus disease, either systemic or local, may produce an almost infinite variety of dyspeptic patterns, at first glance one much like another, but all more or less capable of recognition by taking advantage of the refinements of modern diagnostic methods.

So numerous, then, are these various patterns that it is impossible to think of cataloguing each one as a distinct entity—that is, as a distinct type of dyspepsia ; to interpret their significance they must be analysed into their components.

The Surgeon's Approach to a Case of Dyspepsia.—There are two ways in which the surgeon may approach the problem of a diagnosis in a case of dyspepsia which may have a surgical cause.

He may approach it from the standpoint of a knowledge of how the physiological conditions of the stomach are disturbed, and try to analyse the dyspeptic picture ; that is, try to recognize the manifestations of disturbance of function caused by a disease. In other words, he may attack the problem from the standpoint of the mechanism of its causation.

He may also approach it from the point of view of his knowledge of the various causes of dyspepsia, and of the phases of disease which he knows produce dyspeptic syndromes ; that is, he may approach the problem from an aetiological point of view.

CHAPTER IV

THE MECHANISM OF THE CAUSATION OF DYSPEPSIA

DYSPEPSIA may be regarded as a disturbance of the normal functions of the stomach caused by a vital, functional, or organic disturbance of the gastric wall. Dyspeptic symptoms and signs are only the indications of disorder of function ; they are evidence that the natural, painless activities of the stomach or the duodenum have become disturbed by disease.

THE NORMAL FUNCTIONS OF THE STOMACH

The Motor Function of the Stomach.—The stomach is a receptacle into which food is intermittently taken in quantities, stored for a time, and doled out continuously in small amounts to the intestine, the main organ concerned with digestion and absorption. In point of fact, the main function of the stomach is its motor activity, that is, its filling and its emptying. The dominance of this motor function of the stomach is more evident in the stomach of the dog, in which the motor power of the stomach is more highly developed. The dog does not chew, but ‘ bolts ’ his food, and his stomach is called on for great motor action ; consequently the stomach is small, thick-walled, and powerfully muscled.

Other Functions of the Stomach.—Of the other functions of the stomach the most important are : (a) Partial digestion of protein—a preparation of the protein for intestinal digestion ; (b) Secretion—in a day, the stomach produces about two pints of secretion, the main digestive constituents of which are pepsin and hydrochloric acid ; (c) Preparation of intrinsic factors for osmotic equilibrium. The digestive functions of the stomach may be taken over by the intestine, and consequently partial removal of the stomach causes little disturbance to the organism.

Of the gastric functions, the secretory seems to be affected more by toxic, circulatory, and nervous disturbances, that is, by medical diseases ; its disorder, therefore, appears to be more a concern of the physician. The manifestations of this disorder are generally of the nauseous type of dyspepsia—a *painless dyspepsia*.

On the other hand, the important motor gastric function

seems to be affected more by organic disease—that is, by surgical diseases; and its disorder, therefore, is more a concern of the surgeon.

A derangement of this function gives rise to distinctive symptoms, to fullness, discomfort, or pain—to a *painful dyspepsia*. Further, as the motor function consists of two main activities, namely, the filling of the stomach, which is an active relaxation, and the emptying, which is an active contraction, it follows that a disorder of motor function must be one not only of the emptying function, but also of the filling function.

THE MECHANISM OF THE CAUSATION OF GASTRIC PAIN

In order to understand how derangement of the gastric motor functions in some cases produces fullness, in other cases discomfort and pain, and in order to appreciate the incidence of these symptoms in relation to the intake of food, it is necessary to have a knowledge of the physiological mechanism whereby gastric pain can be produced.

This involves a consideration of the following:—

1. The sensory innervation of the stomach.
2. The nature of the postural gastric tone underlying gastric retention; that is, the mechanism concerned with the filling of the stomach.
3. The nature of the gastric postural tone underlying the expulsive action of the stomach; that is, the mechanism concerned with the emptying of the stomach.
4. The mechanical effects of the various degrees and stages of organic—inflammatory and malignant—diseases.

I. THE SENSORY INNERVATION OF THE STOMACH

The Tension Receptors of the Gastric Wall.—The stomach has not the same sensory receptors as the skin. When operating on the stomach under local anæsthesia, it can be handled and cut without pain. If, however, it is dragged or pulled on, nausea and vomiting occur. The ordinary skin sensory receptors which serve the sensations of touch, heat and cold, and pain, are not required in the stomach; it is not necessary for the stomach, like a limb, to remove itself from injury. Therefore no pain receptors are required; it is only necessary for the stomach to have sensation which will indicate when it is full. Thus receptors sensitive to tension are the main ones provided in

the stomach. Stimulation of these tension receptors may cause a sensation of fullness, discomfort, or pain.

The Path of the Tension Impulses from the Stomach.—With a view to affording physiological and anatomical explanations of epigastric tenderness and rigidity and of the ‘deep tender spot’—manifestations which are found in most dyspeptic syndromes—it is of value to discuss the path of the tension impulses: that is, the path of the afferent sensory fibres from the stomach (*Fig. 14*).

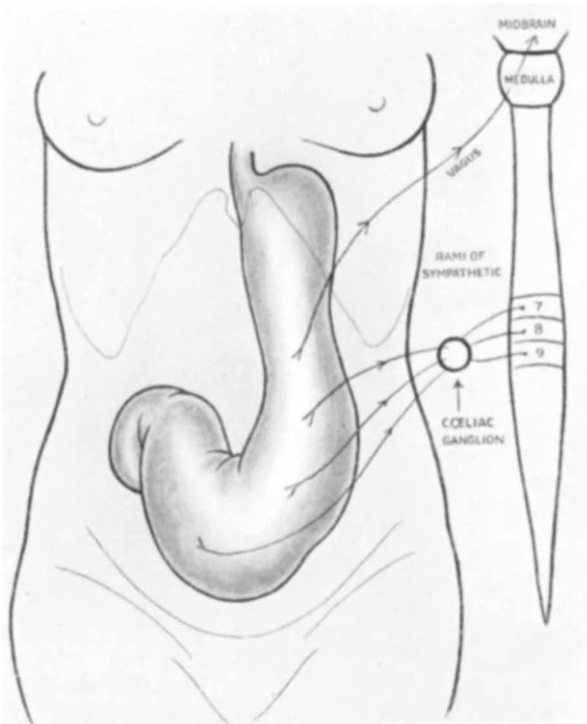


Fig. 14.—The afferent nerve-fibres of the stomach to the 7th, 8th, and 9th spinal segments.

Afferent impulses travel through both sympathetic and vagus nerves. They travel by the afferent fibres of the sympathetic supply of the stomach to the cœliac plexus, and from there, by the rami, to the spinal cord in the 7th, 8th, and 9th segments. These afferent impulses may then either pass by the cord to the midbrain sympathetic centre, which, as it is not in the sensorium, does not interpret the impulse as pain. A segmental excitation arising from afferent impulses from

the sympathetic may give rise to a reflex protective action of the muscular abdominal wall—that is, to epigastric rigidity—to *défense musculaire*. It may also cause a cutaneous hyperæsthesia. As a clinical fact it is found that this hyperæsthesia and reflex contraction are always higher than the lesion in the stomach (*see Fig. 13*). The reason for this probably is that, as a result of a man's upright position, his stomach has dropped (Kinsella). If it were not for this, the somatic segment and the visceral segment would correspond. Hence the epigastric *défense musculaire* and epigastric cutaneous hyperæsthesia resulting from gastric disease is constant in its localization, and corresponds to the 7th, 8th, and 9th spinal segments.

Afferent impulses from the stomach may also travel by the fibres of the vagus to the medulla, and from there, probably, to higher centres in the brain. Thus it is not unlikely that, through these vagal fibres, an injury to the stomach can to some extent be localized by the sensorium. It is probable that through these afferent vagus fibres stimuli pass from a chronic gastric ulcer to the sensorium; and that it is by way of these fibres that the patient obtains the sensation of 'deep tender spot' (*see Fig. 13*) which is usually found over a chronic ulcer, and which corresponds accurately to its situation. It may, however, be the involvement of the visceral peritoneum over the chronic ulcer which gives the 'deep tender spot'.

Stimulation of the Tension Receptors.—Stimulation of these tension receptors (causing fullness, discomfort, or pain) may be produced in the following ways: (a) By the effect of increased tension in the gastric wall, caused by *muscle spasm, inflammatory infiltration, or malignant infiltration*; and (b) By the effect of increased tension in the lumen of the stomach.

a. INCREASED TENSION IN THE GASTRIC WALL.—

Muscle Spasm.—A simple example of the role of spasm of muscle in producing pain was seen when Beaumont introduced his thermometer into the pyloric muscle of Alexis St. Martin. In this instance, pain was at once caused by the spasm of the pyloric muscle contracting upon the thermometer.

Where obstruction in a hollow organ develops, painful muscular spasms may occur in the hypertrophied muscle walls. An example of this was seen in a case of chronic ulcer of the pyloric muscle (*Fig. 15*) which produced almost complete obstruction of the pylorus in four months. In this case, severe cramp-like pains were present four hours after every meal, and they coincided with the development of deep, powerful, visible peristaltic waves which set in about this time.

Where obstruction in a hollow organ develops slowly, the same degree of spasm and therefore pain does not occur. For example, in the case of slowly growing pyloric carcinoma, tetanic-like spasm of the gastric muscle, which has hypertrophied slowly, does not occur; and in this case no definite pain results.

Inflammatory Infiltration.—The role of inflammatory infiltration in producing pain is seen in the case of chronic gastric ulcer, in

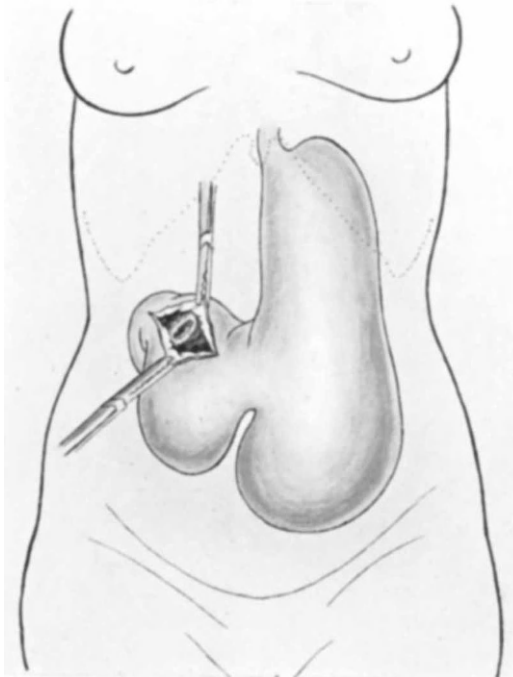


Fig. 15.—Operation sketch of a chronic ulcer of the pylorus of four months' duration causing dilatation and hypertrophy of the stomach, with cramp-like colicky pains four hours after food.

which gastric pain is the predominant feature. In this type of ulcer the edges and the base are intensely infiltrated, being densely packed with inflammatory cells. This infiltration, if it is sufficiently extensive, is an adequate stimulus to the tension fibres for the production of pain (*Fig. 16*).

On the other hand, in an acute ulcer, very little if any inflammatory infiltration is present. As a consequence this type of ulcer is not associated with pain, and it does not cause a *painful dyspepsia* (*Fig. 17*).

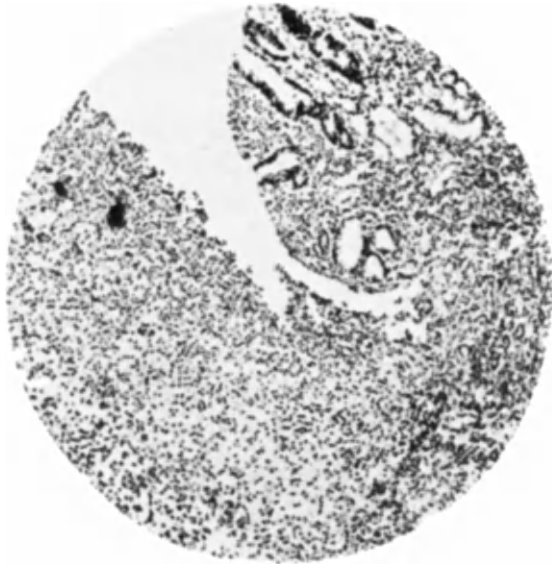


Fig. 16.—Section of chronic ulcer with its edges and base packed with inflammatory cells. This ulcer gave the typical pain of gastric ulcer. (Microphotograph by courtesy of Dr. Wright-Smith.)




Fig. 17.—Section of acute ulcer in which practically no inflammatory infiltration can be seen and which did not give rise to pain. (Microphotograph by courtesy of Dr. Wright-Smith.)

Depending on its degree of inflammatory infiltration, subacute ulcer may or may not be associated with a minor degree of painful dyspepsia.

The hypothesis that stimulation of the tension receptors in the stomach causes the pain of chronic ulcer does not, at first sight, appear to afford an adequate explanation of this pain and that of other organic diseases of the stomach.

Why does the pain of most cases of chronic ulcer come on only from one to two hours after meals? The inflammatory reaction in the ulcer could not alter in such short painless intervals.

Why does the pain of chronic ulcer disappear? I have often seen cases of chronic ulcer come into my wards with acute pain after meals; and after appropriate treatment, the pain has disappeared. Nevertheless, at operation I have found a firm hard chronic ulcer.

Why are some chronic ulcers painful and others not? A chronic ulcer having all the appearances of the type of chronic ulcer which usually gives rise to pain may be seen with the gastroscope, and yet the patient may not have complained of pain after meals (J. Horan, personal communications). Many chronic ulcers are present during life without causing painful symptoms. In an analysis of 218 cases studied at autopsies Wright-Smith reports that, in an autopsy series of 97 cases of chronic gastric ulcer, no symptoms had been reported during life in 22 of them.¹

Why does the pain of chronic ulcer almost always disappear immediately after a gastro-enterostomy before any immediate change could take place in the inflammatory infiltration of the ulcer?

I have no doubt that in all these cases of chronic ulcer which do not cause painful symptoms, the inflammatory infiltration is inadequate to cause tension stimulus sufficient to cause pain, even with the addition of the extra tension stimulus caused by muscle movement.

Is there, then, another factor in the causation of ulcer pain?

Many authors have suggested that increased or prolonged acidity is the other factor, mainly because the pain of ulcer is relieved by alkaline drinks. Without going into reasons, it is obvious that the effect of a greater or lesser degree of acidity does not afford an explanation of the variation of the incidence of pain in any of the circumstances above mentioned.

The explanation of the pain of chronic ulcer is, I believe, that the stimulation of the tension receptors must be adequate before actual pain is produced. The gastric ulcer which loses its pain when treated in hospital has lost some of its inflammatory infiltration as the

result of rest and treatment, and the stimulation to the tension fibres is then inadequate to produce pain. An analogous condition is seen in the case of chronic ulcer of the leg. While the patient is attending the out-patient department, where it is not possible to treat the ulcer properly, it will be so painful that the patient cannot sleep. After a week's treatment in hospital, although the ulcer looks much the same, it no longer gives rise to constant pain—the inflammatory infiltration and therefore the pressure on the nerve-endings in the ulcer have been lessened by treatment. It is, however, still tender to touch or to movement—that is, when extra pressure on the inflammatory infiltration offers an adequate stimulus to the sensory fibres.

Such a hypothesis, in regard to the typical pain of chronic ulcer, is supported by the fact that in very old chronic penetrating ulcers where the inflammatory infiltration is intense, in contrast to the ordinary type of chronic gastric ulcer in which the inflammatory infiltration is not so marked, pain is continuously present, but becomes worse one or two hours after meals—about the time when the stomach is emptying.

In the ordinary type of chronic gastric ulcer, I believe that a tension stimulus adequate to produce pain is brought about by the vigorous peristaltic movements and muscular contraction (increased tension stimulus) as the stomach empties itself and becomes small. I believe this pain is produced in the same way as intense pain is caused *only* during the emptying of the bladder in a case of a deep chronic ulcer of the trigone. In such an ulcer I have watched (with a cystoscope) the patient experiencing the most intense pain during the emptying stage of the bladder; that is, as the bladder contracted and the trigone became puckered. The moment the bladder was filled, the pain disappeared. The same kind of pain on emptying will be seen in cases of trigonitis of the bladder. I feel that the pain of the chronic gastric ulcer, like that of the ulcer of the trigone, and the partially cured ulcer of the leg previously referred to, is only produced when the tension is increased and is accompanied by muscular movement.

It is the active processes of gastric emptying which give rise to the pain in chronic gastric ulcer. It can be shown by X-ray investigation that it is only when the stomach is emptying—not when it is empty—that the pain begins to come on. Further, if chronic ulcer develops in a stomach which cannot empty—that is, in a stomach which has become dilated from a duodenal or pyloric stenosis, the ulcer, no matter how chronic it is, does not give rise to any pain (a case is quoted on p. 123 to exemplify this fact). I feel sure that

the relief of the chronic gastric ulcer which follows the taking of food or of alkaline drinks is due to the distending of the stomach or duodenum, which relieves the pain just as the filling of the bladder obliterates the pain in ulcer of the trigone. It is not the alkali which relieves the pain, but the fluid distending the stomach. And as bicarbonate of soda at once gives rise to gas which distends the stomach, it relieves the pain much more quickly than alkaline drinks containing magnesium oxide.

Malignant Infiltration.—The action of malignant infiltration of the gastric wall in producing stimulation of the tension receptors is uncertain, probably because of its slow development. It does not *always* give rise to pain in relation to food, and when it does, the pain is *not severe* like that caused by infiltration of a chronic gastric ulcer.

If the growth is in the area in which there is deep peristalsis, that is, in the pyloric part of the stomach, it usually produces discomfort or pain *both during the filling and the emptying of the stomach*. The discomfort or pain during filling is probably the result of the extra tension stimulus caused by the muscular action of distending the empty and rigid-walled stomach. The discomfort or pain on emptying is most likely caused by the disordered peristaltic contractions and by the puckering contraction in the almost empty stomach, both acting on the infiltrated and rigid wall of the pyloric part of the stomach. Thus, in both the filling and the emptying of the carcinomatous stomach, it is the muscle movement causing extra tension stimulus in the infiltrated gastric wall which provides a stimulus adequate to produce pain.

If the lesion is in the cardiac part of the stomach, it may not cause pain, for in this part of the stomach there is no peristaltic movement. However, carcinomatous infiltration of any part of the gastric wall may give rise to a continuous low-grade pain—to an ‘ache’.

A malignancy can give rise to a tension stimulus and pain in another way. A carcinomatous lump in the pyloric part of the stomach can cause pain just like that of gastric or duodenal ulcer: that is, pain two to three hours after food, and pain relieved by further food or alkaline drink. This pain is probably produced by a painful tetanic spasm of the emptying stomach around the lump—an effort to expel it from the stomach as if it were a foreign body. It is not unlikely that it is analogous to that pain which occurs in the case of an intense spasm of the lower part of the sigmoid, which gives rise to the sensation of intense tenesmus—a spasm so intense that it can produce a hard malignant-like tumour (*see p. 65*).

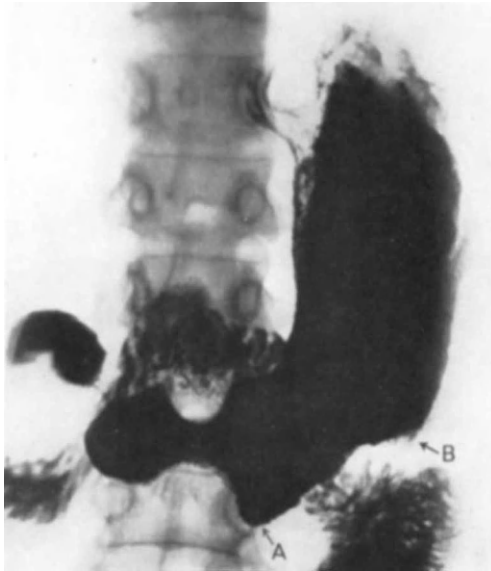This type of gastric pain is exemplified in the following history:—

A patient complained that “as soon as she stood up from the table” she suffered from epigastric pain, which gradually died away; and that about an hour later, a severe crampy pain began to come on. When

Fig. 18.—Sketch showing the situation of a carcinomatous tumour, which could be felt only when crampy pain came on as the stomach emptied.

this crampy pain was most severe, a definite tumour could be felt to develop under the palpating hand (*Fig. 18*).

At times the tumour became less obvious, coming and going, after the manner of the tumour which one sometimes sees in an obstruction of the small intestine. *Fig. 19* shows a radiograph of this tumour, which was situated on the posterior wall of the stomach.



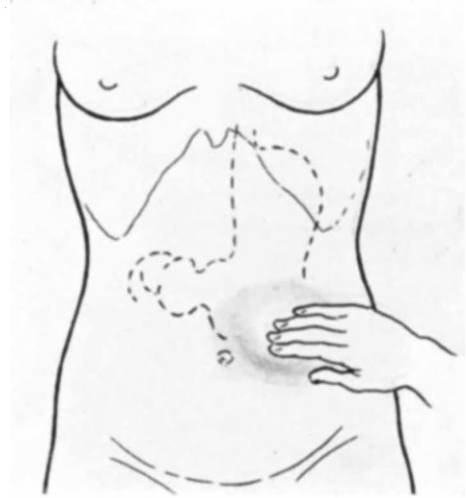The deformity on the greater curve caused by the tumour can be seen extending from A to B. This radiograph was taken fifteen months after the onset of the malignancy.

In this case the tumour was probably a painful spastic

Fig. 19. — Radiograph showing tumour of the stomach. The situation of the tumour is marked A to B. (By courtesy of Dr. John O'Sullivan.)

contraction of the gastric wall, in the emptying stomach, around a carcinomatous tumour—an effort, as it were, to expel the lump. This crampy pain disappeared when food was taken—a clinical feature

which led to the belief that the patient was suffering from a gastric or duodenal ulcer



b. INCREASED TENSION IN THE LUMEN OF THE STOMACH.—The effect of tension in the lumen of a hollow organ, such as the stomach, is seen in the following experiment by Burge, Martzloff, Suckow, and Thornton². A segment of small intestine with its blood-supply was isolated and closed at each end. The continuity of the intestine was established in the usual way. The isolated segment was so fixed on to the abdominal wall that its contents could be aspirated

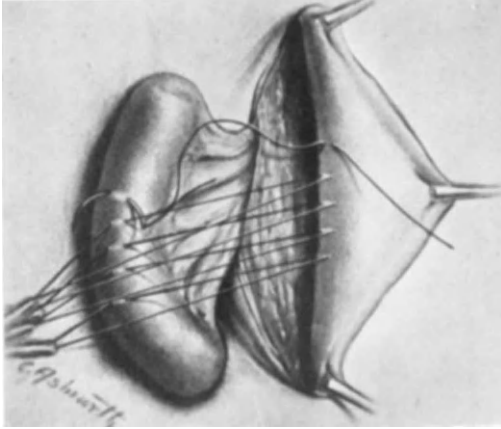


Fig. 20.—Closed experimental loop, sutured under the abdominal wall.

(*Re-drawn by kind permission from the 'Archives of Surgery'.*)

at will by a hypodermic syringe (*Fig. 20*). Secretion occurred, and as a result of this distension in the closed loop, as the tension increased in the lumen, the animal invariably began to vomit. When the contents of the loop were aspirated and the tension thus reduced, the animal was immediately relieved and at once began to eat. This would seem to prove that symptoms of nausea, discomfort, and probably pain were caused by the tension in the loop, or the muscular effort to which the distension gave rise.

2. POSTURAL TONE UNDERLYING GASTRIC RETENTION

The postural tone of gastric muscle is that property of involuntary muscle generally to which the term 'plasticity' has been applied. It permits of the muscle comfortably taking up any new position; that is, it allows various degrees of distension of the stomach without the muscle becoming fatigued or the tension in the lumen of the stomach becoming increased. The muscle can, as it were, lock itself into each new position by a sort of 'ratchet action'.

This postural tone is probably mainly of myogenic origin, but it is controlled or varied by the action of the involuntary nervous system—the parasympathetic and the sympathetic.

The postural tone is concerned with the mechanism of the painless or comfortable filling of the stomach. Thus, if the musculature of the stomach—and therefore the postural tone—is normal, and if its autonomic innervation is healthy, the stomach is capable of relaxing in an orderly fashion to accommodate food which is being taken into it in increasing amounts. By this orderly relaxation the stomach takes up, as it were, a new ‘retention posture’ with each addition of food.

An increase in the quantity of intake of food does not, therefore, cause an increase in the intragastric tension, as it would if the stomach were an elastic bag; consequently the stomach accommodates the food *without discomfort*.

As has been pointed out, this capability of taking up a new ‘retention posture’ as the stomach fills is a quality inherent in the muscle itself. It may, however, be modified or considerably disturbed by impulses which it receives from the autonomic system—that is, from the vagus or from the sympathetic. This orderly, comfortable filling or unfolding of the stomach, which depends upon the normality of the gastric muscle and also on that of its nervous supply, can therefore be deranged by functional disturbance of its nervous mechanism, by organic disease of the gastric wall, or by a congenital myogenic abnormality. Under such circumstances the gastric wall cannot relax in the normal orderly fashion as it receives food. The consequence of this is that intragastric tension rises and the filling of the stomach is attended with *fullness, discomfort, or even with pain*.

In cases of dyspepsia of this type, caused by a derangement of retention postural tone, the stomach when seen at operation is small and healthy-looking. The patient, however, may have felt full and uncomfortable after meals, and may even have experienced pain.

This form of dyspepsia may come under the notice of the surgeon because the pain that occurs after food is thought to be due to organic disease of the stomach, such as gastric ulcer or carcinoma.

The normality of the postural tone of the gastric muscle and therefore the comfortable filling of the stomach can also be interfered with by organic diseases, such as by *a more or less general infiltration* of the gastric wall by carcinoma. In this case the wall cannot relax for each new retention posture, and the tension in the lumen of the stomach increases. The taking of food is accordingly attended with fullness and discomfort and occasionally with pain.

In contrast to the effect of malignant infiltration on postural tone, *local* inflammatory organic disease of the stomach, such as gastric

ulcer, does not produce a general infiltration of the gastric wall, and for this reason does not cause a derangement of the retention postural tone and disturb the normal comfortable filling of the stomach.

A general inflammatory condition of the gastric wall, however, such as gastritis, does interfere with this postural tone, and in this case the filling of the stomach is attended with some discomfort.

It is interesting and also important from the point of view of the early diagnosis of gastric cancer to appreciate these distinctions in regard to the disturbance of gastric wall retention postural tone by organic disease. For instance, in some cases of early carcinoma, where the infiltration of the gastric wall is not very extensive, a disturbance of the postural tone—of the gastric filling—is only seen in the final stages of the filling of the stomach; that is, only when a full meal is taken. A clinical example to illustrate this fact is given on p. 47.

3. POSTURAL TONE UNDERLYING GASTRIC EXPULSION

The stomach empties itself by a series of movements of its muscular wall. These are: a sustained tonic contraction in the cardiac part of the stomach; a series of rhythmic peristaltic contractions in the pyloric part, increasing in power as they approach the terminal part of the stomach; and a relaxation of the pyloric muscle together with a prepyloric fan of sympathetically innervated muscle-fibres. This property of the gastric muscle of an orderly emptying, or of doling out its stored nutriment (mechanically and biochemically prepared) to the intestine, is inherent in the gastric muscle. It is also to a certain extent under the control of the autonomic nervous system.

The efficiency and the painlessness of the emptying processes depend on a normal postural tone and nervous mechanism. Disturbance of one or the other or both can make the emptying uncomfortable or cause painful spasm.

Individual Capability of Retention or of Emptying.—A property of inherent postural tone of gastric muscle is that it influences the individual capability of retention or of emptying of a particular stomach. Some stomachs can hold a lot with comfort and others can only hold a comparatively small quantity; some stomachs empty quickly and others empty slowly.

This individual capability, too, is, to a large extent influenced by the more or less inherent development of either the sympathetic or the parasympathetic system. Some persons are sympatheticotonic and others are vagotonic.

But the most profound alterations in individual gastric retention or individual gastric emptying are caused more from congenital myogenic faults than from any under- or over-activity of a part of the autonomic system. These alterations are seen in those gross pathological retentions and dilatations of the alimentary canal such as cardiospasm, gastric and duodenal ileus, ileus of the small intestine, megalocolon, megacystis, etc., while the most profound alterations in gastric emptying are seen in those intense spasms which sometimes occur in the stomach, the duodenum, the colon, and the bladder, some of which appear to have a congenital—perhaps myogenic—basis. (See Chapter VI.)

The normal retention postural tone or the stomach's capability of retention, therefore, varies according to an inherent tendency in the muscle of the individual and to the development of the involuntary nervous system.

In a healthy strong man, who is usually vagotonic, the empty stomach is small, horn-shaped, muscular, highly situated, and with a small air-content. Its capacity for retention is small; it empties quickly. *Fig. 21* shows the usual type of stomach in the sthenic male. This type of stomach may be the result of an inherent postural tone which is dependent on sex, or it may be due to dominance of vagal influences.

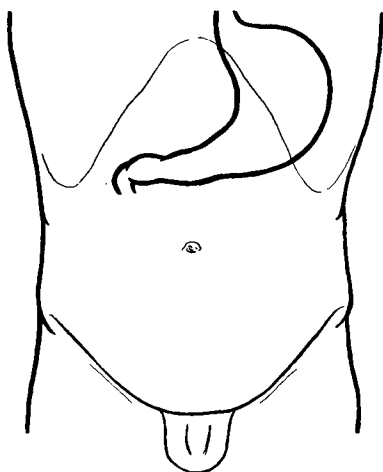


Fig. 21.—Usual type of stomach in sthenic males.

On the other hand, in a woman, who is usually sympathetico-tonic, the resting stomach presents rather a contrast to that of the healthy male. It is usually large, thin-walled, low-situated—sometimes almost in the pelvis—with a large air-content. Its capacity for retention is great; it empties slowly. It has an exaggerated retention postural tone. This may be an inherent postural tone which goes with the sex; or it may be due to an overacting sympathetic, evidences of which are so frequently found in the woman who has borne children. *Fig. 22* is a diagram of this type of stomach.

The pathological dilatations and spasms of the alimentary canal, which are described in Chapter VI, are, reasoning on clinical grounds, probably just gross pathological faults in the postural tone which

underlie the filling and the emptying functions of the stomach; that is, pathological disturbances of the functions of filling and emptying.

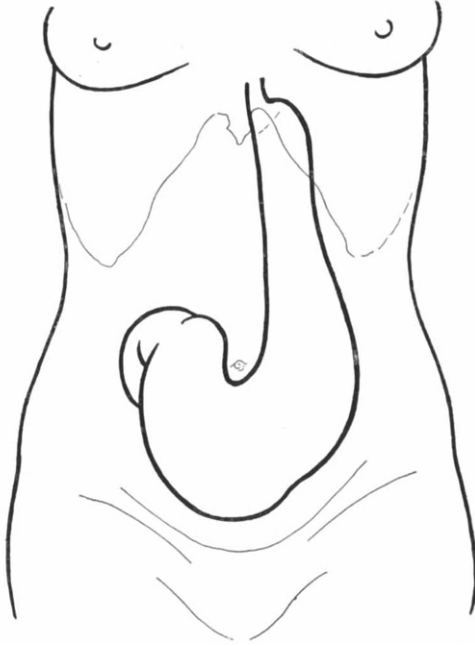


Fig. 22.—Exaggerated retention posture in woman's stomach.

4. MECHANICAL EFFECTS OF INFLAMMATORY OR MALIGNANT DISEASE

The actual tissue mechanism which causes the adequate stimulation of gastric tension receptors, and therefore pain, is the degree of alteration of normal gastric wall tissue caused by organic disease; that is, the degree of inflammatory or malignant infiltration.

The various stages of inflammation and of malignancy have been discussed in relation to the sensory innervation of the stomach and postural tone, and do not need to be described again.

EFFECTS OF IMPAIRMENT OF THE VITALITY OF THE GASTRIC WALL BY SYSTEMIC DISEASE

It must be mentioned in any discussion on the mechanism of the causation of dyspepsia that impairment of the vitality of the gastric wall, that is, of its circulation and of the vitality of its tissues, is a most important factor in the causation of dyspepsia.

Diseases with a general effect such as chronic nephritis, disease of the liver such as cirrhosis, arteriosclerosis, the anæmias, local

infections like tuberculous disease of the lung, general infections—all these interfere with the vitality of the gastric wall, or partially destroy its vitality by excretion of toxins.

The circulation of the gastric wall and therefore its vitality can also be affected by the congestion caused by heart failure; and sometimes a dyspepsia may become obvious before signs of heart failure appear.

Thus systemic diseases, or local disease in other parts of the body, can cause a gross dysfunction of the stomach by interfering with the vitality of its gastric wall, and thus give rise to dyspeptic syndromes which are often indistinguishable from those due to organic disease of the stomach.

CLINICAL DEDUCTIONS

Having now, with a view to being able to analyse and recognize a dyspeptic pattern, discussed the derangement of normal gastric motor function, and the mechanism of the causation of gastric pain, we are in a position to make some clinical deductions.

Basis of Dyspepsia.—Organic disease of the gastric wall of itself or with the additional effect of muscular movement can produce definite painful or uncomfortable dyspeptic symptoms, and can cause motor functions of the stomach (the filling and emptying) to become more or less uncomfortable or painful. Indefinite dyspeptic symptoms, due to secretory disturbance, follow as a result of the derangement of the motor functions.

Painless and Painful Dyspepsia.—It will be found that in practice it is possible to make a very broad generalization and divide dyspepsia into two great groups: the dyspepsia which is associated with more or less pain—a '*painful dyspepsia*'; and the dyspepsia which is free from pain—that is, one in which discomfort, nausea, and other symptoms are the main features—a '*painless dyspepsia*'.

'Surgical Dyspepsia' and 'Medical Dyspepsia'.—It will also be found that, as a broad general rule, a painful dyspepsia indicates surgical disease, either in the stomach or the duodenum or in some other abdominal organ, and it may therefore be termed *surgical dyspepsia*.

In general, too, it may be taken that a painless dyspepsia is mainly of medical significance, and it may therefore be called *medical dyspepsia*.

To both these broad generalizations there are, however, exceptions which will be dealt with later.

Recognition of the 'Pattern' of a Dyspepsia.—As a dyspeptic condition is a reflection of disordered gastric function, the surgeon should approach the diagnosis of cases of dyspepsia from the point of view of cultivating the art of recognizing the *pattern* of a dyspepsia by a knowledge of its mechanism of causation. He should try to recognize the particular pattern which is of surgical significance; and in the interests of successful surgical treatment he should try to recognize it in its early stages—a task of some difficulty.

SUMMARY OF GENERAL CAUSATIVE FACTORS

The general factors which may bring about dyspepsia can be summarized as follows :—

1. Disturbances Arising in the Stomach Itself.—(a) Disturbances due to impairment of the vitality of the gastric wall—*dyspepsia caused by systemic disease*; (b) Disturbance in the function of filling or of emptying of the stomach, caused neuromuscularly—*functional dyspepsia*; (c) Disturbance of the function of filling or emptying of the stomach caused by *organic disease*, such as gastric carcinoma, gastric or duodenal ulcer, or chronic gastritis—*organic dyspepsia*.

2. Disturbances Arising outside the Stomach.—Disturbances of the filling or of the emptying of the stomach neurogenically caused by a disease of an abdominal organ other than the stomach, such as the gall-bladder, appendix, pancreas, colon, or kidneys—*reflex dyspepsia*.

REFERENCES

- ¹ WRIGHT-SMITH, R. J., Walter and Eliza Hall Institute of Research, Melbourne "Peptic Ulcer", *Med. Jour. of Australia*, 1937, Dec. 11.
- ² BRUGET, MARTZLOFF, SUCKOW, and THORNTON, "The Closed Intestinal Loop", *Arch. of Surg.*, 1930, **21**, No. 5, Nov.

CHAPTER V

THE INCIDENCE OF DYSPEPSIA ON THE FILLING OR EMPTYING OF THE STOMACH

IF the various syndromes of dyspepsia are minutely examined, it will be found that in some cases the incidence of the dyspeptic symptoms is on the emptying phase of the stomach ; in others it will be seen that the phase of dyspeptic symptoms is more during the filling of the stomach, that is, just after food ; and in still others symptoms will be noticed on the filling as well as on the emptying of the stomach.

Further, if in these syndromes the incidence of a dyspepsia on the filling or on the emptying of the stomach is studied, the knowledge will help the surgeon to recognize early a particular pattern of dyspepsia, and therefore a cause which may require surgical treatment.

DYSPEPSIA DURING THE FILLING PHASE OF THE STOMACH

The following conditions give rise to dyspepsia following the intake of food :—

1. *Functional disturbances of the neuromuscular mechanism of the gastric wall.*
2. *Organic disease of the gastric wall, caused by: (a) Diffuse chronic inflammation—chronic gastritis; (b) Diffuse malignant infiltration.*

1. Functional Disturbances.—If, during the filling of the stomach, it fails to relax in an orderly fashion as the food is taken into it (probably owing to a disturbance of the inherent postural tone of the organ or its neuromuscular mechanism), the tension in the lumen of the stomach rises, and a feeling of fullness, even with a small quantity of food, is felt. Further intake of food will cause a feeling of discomfort or even pain—epigastric pain.

The dyspeptic symptoms may continue for an hour or more after the taking of food, but the important thing is that they follow on the taking of food—there is no symptom-free time interval.

This type of functionally caused epigastric pain is liable to occur in young people, in whom the nervous system is unstable. It may also be caused reflexly (through the autonomic nervous system) by

disease of the gall-bladder or of the appendix. Its surgical interest lies in the fact that it is often confused with the epigastric pain caused by organic disease of the gastric wall.

In these cases of painful functional disturbance, the stomach, when seen at operation, is small, and appears to be healthy.

2. Organic Disease.—A dyspepsia following the filling of the stomach may be caused by organic disease of the gastric wall, such as : (a) Diffuse chronic gastritis ; (b) More or less diffuse malignant infiltration of the gastric wall.

a. Diffuse Chronic Gastritis.—Where the gastric wall is more or less uniformly affected by a chronic gastritis, the filling function of the stomach is disturbed, and the expanding of the stomach is usually associated with fullness, discomfort, or even with mild pain ; that is, a dyspeptic phase, more or less painful, follows almost immediately after food.

These disturbances of the filling function of the stomach occur fairly consistently in that type of secondary chronic gastritis which is nearly always associated with old penetrating ulcer of the stomach. And it is for the reason that symptoms follow immediately on the intake of food—symptoms of fullness, discomfort, or pain—that these old penetrating ulcers of the stomach are often clinically diagnosed as carcinoma, or at any rate excite the suspicion of the presence of a carcinoma.

b. Diffuse Malignant Infiltration of the Gastric Wall.—Even a slight malignant infiltration of the gastric wall may disturb the painless or comfortable filling, or, what is more important, the painless or comfortable *complete* filling, of the stomach. Such an infiltration prevents the orderly normal painless relaxation of the gastric wall which provides for the intake of increasing quantities of food or the taking of a *full* meal without discomfort. In other words, such an infiltration disturbs the normal retention postural tone of the gastric muscle.

Recognition of this fact is diagnostically important, because it is one of the early signs of gastric carcinoma, as will be seen in the following clinical example :—

A surgeon, accustomed to attend a yearly medical dinner, found that he felt full when he had taken only about three-quarters as much as he had the previous year : that is, he felt for the first time that he had discomfort when he took a full meal. During the year which followed he found that he had to reduce the quantity of his meals gradually in order to avoid a sensation of fullness and discomfort ; in other words, he had a progressive disturbance of the *complete* filling of his stomach. Nine months after the yearly dinner it was discovered that he had carcinoma of the stomach.

If in this case a radiograph had been taken nine months previously, that is, when his filling dyspepsia from a full meal started, it would probably have shown (deduced from his radiograph nine months later) a small flat infiltrating carcinoma—a small lesion which made the complete filling of the stomach uncomfortable.

Another instructive mistake, and an example of the importance of the early recognition of the significance of pain or discomfort on the filling of the stomach, is shown in the following case-history:—

A woman, aged 37, had been ill for two years. She said that *as she took food and stood up from the table after a full meal, a pain which lasted for a quarter of an hour came on*. She was then free from pain till the advent of the pain one and a half to two hours after meals. This patient had been X-rayed, but no sign of carcinoma of the stomach or ulcer had been found. Two years later it was found that the patient was suffering from a slowly growing carcinoma of the posterior wall of the stomach. Because the carcinomatous condition was situated on the posterior wall of the stomach, therefore causing little *en face* X-ray deformity of the gastric wall, it was not recognized. And yet all the time she was complaining that as she took food and stood up from the table she had pain. This pain on taking a full meal—that is, on the filling of the stomach—should have at once suggested to her medical attendant the possibility of a carcinomatous infiltration of the gastric wall.

Thus a dyspeptic syndrome in which discomfort, nausea, or pain occurs immediately after the intake of food—that is, when the stomach is unfolding to receive the food (a filling disorder)—is frequently the result of a diffuse or local carcinomatous infiltration of the gastric wall, and only occasionally caused by a diffuse inflammatory infiltration.

DYSPEPSIA DURING THE EMPTYING PHASE OF THE STOMACH

In the following conditions, the incidence of the dyspeptic symptoms may occur during the emptying phase of the stomach: (1) *Functional disturbance of the gastric musculature*; (2) *Organic disease of the gastric wall*; (3) *Emptying disorders due to pyloric stenosis*.

I. Functional Disturbances.—A functional disturbance of the emptying of the stomach may be the result of a too rapid emptying—‘irritable stomach’—due to an exaggerated emptying posture.

Rapid Emptying (‘*Irritable Stomach*’).—This generally occurs in a person who has an inherent exaggerated postural emptying tone, or who is vagotonic. It is often part of a diathesis which predisposes to duodenal ulcer. It may, however, be caused reflexly by some inflammatory irritation in the vagal nerve field.

Its dyspeptic manifestations occur when the stomach is empty; that is, before meals. They may take the form of discomfort or pain similar to that of gastric or duodenal ulcer, which is probably caused by a painful spasm of the empty stomach or duodenum. For example:—

A patient had for years, off and on, attacks of pain two or three hours after his meals. All he had to do in order to get relief was to take a drink of water. It had never been possible to demonstrate an organic lesion in his stomach or duodenum.

2. Organic Disease.—Dyspepsia occurring mostly during the emptying of the stomach may be due to (a) inflammation or (b) malignant infiltration of the gastric wall.

a. Inflammation of the Gastric Wall.—There are two forms: (i) a diffuse inflammation; (ii) a localized inflammation.

i. *Diffuse chronic inflammation:* In the case of a chronic gastritis which is present mainly in the pyloric part of the stomach, discomfort and pain are caused when its walls are contracting and puckering the pyloric part during the emptying phase of the stomach. This pain during the emptying phase is similar to that of gastric ulcer.

ii. *Local chronic inflammation:* In an uncomplicated chronic gastric ulcer, when the stomach is emptying and contracting, when it begins to pucker up the rigid and sensitive ulcer, and when the peristaltic waves in this small stomach begin to exert their pressure effects on the ulcer, then pain occurs—the pain, so characteristic of uncomplicated gastric ulcer, which occurs one to two hours after meals while the stomach is emptying.

b. Malignant Infiltration of the Gastric Wall.—In some cases of malignant infiltration of the gastric wall and particularly of the pyloric part of the stomach, as the stomach empties and the peristaltic waves and contracted stomach pucker the infiltrated muscle, pain occurs—the pain an hour or two after a meal which is a frequent symptom in gastric carcinoma, and which is often confused with that arising from gastric ulcer.

In other cases where the malignancy is more of a tumefaction than an infiltration, an unusual type of pain may occur as the stomach empties. The emptying stomach contracts on the carcinomatous lump (only if it is in the prepyloric portion of the stomach), and appears to go into a state of painful spasm round it. It seeks, as it were, to expel this lump in its wall as if it were a lump of food. This painful spasm occurs in other hollow organs and is analogous to that which sometimes occurs in carcinoma of the lower end of the sigmoid (*see pp. 64, 65*), and which gives rise to a continuous tenesmus—a sustained effort by the bowel to discharge the lump in its wall as if it were a lump of fæces. This pain of a spastic stomach round

a carcinomatous lump, which occurs from two to three hours after food, and which is relieved by filling the stomach with food—a hunger pain—is of practical importance, for it may lead to an erroneous diagnosis of prepyloric or duodenal ulcer. It is in such circumstances that cases of gastric carcinoma have been erroneously treated as prepyloric or duodenal ulcer, and valuable time has been lost.

The following case is a good illustration :—

A man, aged 40, gave the history that he had been for the past nine months suffering from pain three hours after meals—a hunger pain. The pain occurred after every meal, was relieved by taking food or baking-soda, and was a pain typical of duodenal ulcer. Over a period of nine months the patient had got steadily worse ; he had had *no intermission* whatever of his symptoms. No tender spot could be found on the abdominal wall. At the onset of his symptoms he had seen a medical man, who had made a diagnosis of duodenal ulcer, for which disease he had been under treatment. Operation disclosed that he had a carcinomatous lump in the prepyloric portion of the stomach.

3. Pyloric Stenosis.—In *incomplete* organic pyloric obstruction, painful dyspeptic symptoms may arise when the stomach is emptying.

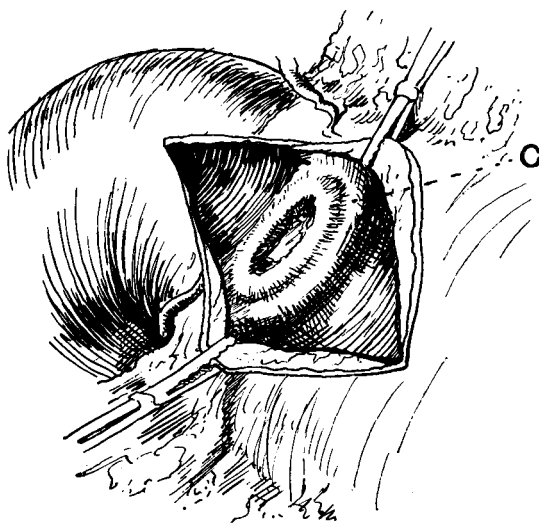


Fig. 23.—Linear pyloric ulcer which caused a rather rapidly occurring pyloric stenosis with a painful emptying dyspepsia. C, Ulcer.

These symptoms take the form of cramping colicky pain many hours after meals, when, in the attempt to empty its contents, powerful

peristaltic movements can be seen over the hypertrophied stomach. But all cases of organic pyloric obstruction do not produce colicky pain during the emptying phase; in one case an organic pyloric obstruction will produce a *painful dyspepsia*, and in another a *painless dyspepsia*. Such a difference in the dyspeptic syndromes associated with pyloric obstruction will be seen if the two case-histories which follow are compared.

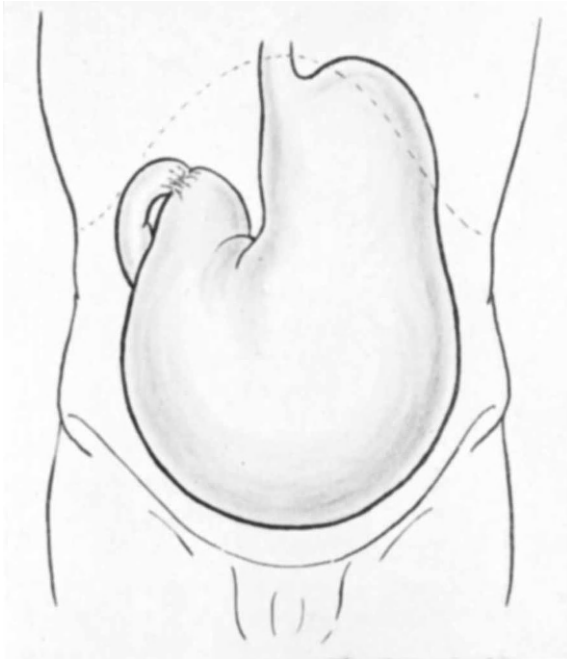


Fig. 24. — Operation sketch of huge stomach, the result of a slow-growing scirrhus carcinoma of the pylorus. The patient had no painful dyspepsia.

A woman, aged approximately 55, developed cramping pain about four hours after meals. She was a very thin woman, and on examination the shape of a dilated stomach was visible on the thin abdominal wall, and the peristaltic contractions, which could be seen, corresponded to the occurrence of the crampy pains. The history extended only over about three or four months. At operation, a small, narrow, deep chronic ulcer, about 7 or 8 cm. wide and 2 cm. long, encircled about a third of the pyloric orifice (Fig. 23). This ulcer had produced rather an acute pyloric obstruction, and the crampy pains were apparently caused by the deep peristaltic waves in a hypertrophied gastric muscle.

In the second case a man, aged 50, complained that for the last three years he had been gradually losing weight; that he suffered from vomiting

attacks, in which he vomited large quantities ; and that he had gradually become very constipated. On examination, through his thin abdominal wall, the shape of an enormous dilated stomach could be seen, over which coursed deep peristaltic waves. He had no painful dyspepsia whatever.

At operation a very slow-growing scirrhus carcinoma of the pylorus, which had caused enormous dilatation of the stomach, was found (*Fig. 24*).

The same discrepancy in regard to an obstructed outlet can occur in other hollow organs. For instance, a sudden obstruction in the cystic duct due to a gall-stone may cause intense colicky pain ; while on the other hand a quiet impaction can cause a huge mucocele of the gall-bladder which may develop quite painlessly because it develops slowly.

CHAPTER VI
**GROSS DILATATIONS AND SPASMS OF THE
ALIMENTARY CANAL**

IN the case of functions so important as those which have to do with the filling and the emptying of the various sections of the alimentary canal, it might be expected, judging from the analogy of the other bodily functions, that in some individuals these gastric functions would be the subject of profound derangements. This is the case, for in the alimentary canal there are found, in all its sections, gross pathological dilatations somewhat similar to the condition called cardiospasm—profound disturbances of the mechanism of retention. There are also seen, in the different parts of the alimentary canal, marked pathological spasms—gross disturbances of the mechanism of emptying.

The study of the incidence and the causes of these profound dilatations and spasms is not only of value from the point of view of knowledge in regard to their occurrence, recognition, and treatment, but also from that of the better understanding it gives us of the origin of various dyspeptic syndromes which may arise as a result of different degrees of these conditions in the stomach and duodenum, or following their occurrence in sections of the alimentary canal other than the stomach.

The alimentary canal of the primitive animal is a simple tube. Very early in the animal scale a series of sections, guarded by sphincters, develops for the retention and digestion of food products.

Thus, as the animal scale ascends, the food begins to be retained in the different sections of the alimentary canal by the formation in it of a number of dilatations laid down as a series of 'retention postures'. These are possibly mostly myogenic in origin. They are, however, governed to some extent by the action of the primitive nervous system—the sympathetic nervous system; for we know that stimulation of the sympathetic supply to these sacculations causes relaxation of their walls and contraction of muscle-fibres in the vicinity of their exits—a synergic movement that must give rise to retention of their contents.

These various sections are probably emptied in the reverse way to the reception of food—that is, by a series of what we might call

'emptying postures': the muscle wall contracts, and the muscle-fibres in the vicinity of their exits relax—a movement which is mainly of myogenic origin, but is to some extent brought about by stimulation of the fibres of the parasympathetic, a system made up of the vagus nerves and the pelvic nerve.

Thus there is developed in the alimentary canal a system of neuromuscular sections, each section being cut off from its neighbour by a sphincter, and each provided with a mechanism for holding nutritive material for a time for digestive or absorptive purposes, or

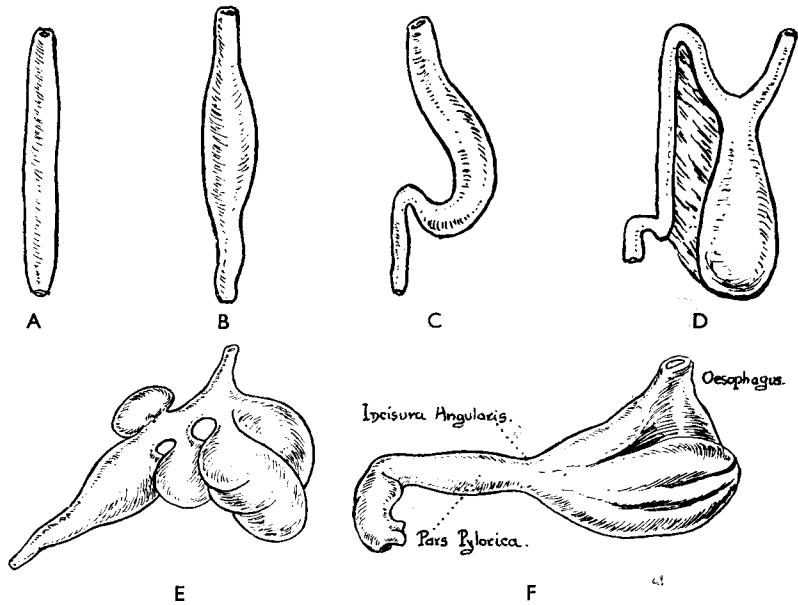


Fig. 25.—Evolution of the animal stomach. A, Stomach of the pickarel (Nuhn); B, Stomach of *Proleus anguineus* (Nuhn); C, Stomach of *Scincus ocellatus* (Nuhn); D, Stomach of the eel (Huntington); E, Scheme of the ruminant compound stomach (Nuhn); F, Stomach of a 10-mm. human embryo (Lewis). (After Alvarez.)

for retaining excretory matter till it can be discharged, and each provided with a neuromuscular mechanism of its own, which is part of a general neuromuscular arrangement governing the whole alimentary canal.

The stomach, one of these neuromuscular sections, is evolved from this primitive straight tube (Fig. 25, A). In Fig. 25, D, the stomach of the eel, a diverticulum from this tube—the primitive stomach—is seen. In Fig. 25, F, is seen the stomach of the 10-mm. human embryo, in which the fundus has expanded from the gastric canal.

While in man most of these sections are guarded by definite sphincters, others have only rudimentary sphincters which are not macroscopically obvious.

The bladder, a hollow organ for the retention and discharge of urine, and in primitive animals a part of the alimentary canal, has its

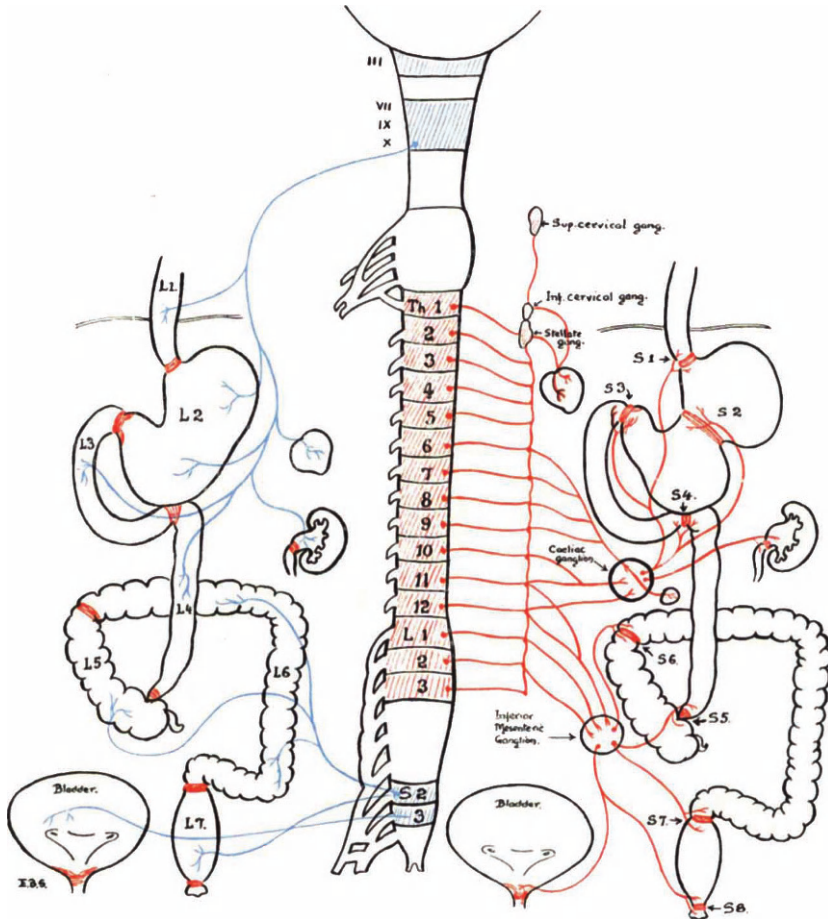


Fig. 26.—Schema of the involuntary nervous supply of the various abdominal viscera. It is made up of the sympathetic (red) and the parasympathetic — the vagus and pelvic nerves—(blue).

emptying and its filling controlled in a somewhat analogous way to that of the various sacculations of the alimentary canal.

Fig. 26 shows a schema of these various neuromuscular sections of the alimentary canal and their nerve-supply (in the case of the œsophagus not quite substantiated). It also shows the rudimentary

as well as the ordinary well-known sphincters. And it shows, for purposes of comparison, the nerve-supply for retention and emptying in the case of the bladder, which developmentally arises from the primitive alimentary canal, and also that for the retention and emptying of urine in the pelvis of the kidney, in which is found the same kind of supposed balanced innervation.

If now we examine the functions of retention and emptying in the various segments of the alimentary canal, bladder, and pelvis of the kidney, we find that, as a matter of clinical observation, in any of these organs there can be gross derangements of these functions.

Judging from experimental evidence, and from clinical observations, we know that these disturbances of retaining and emptying can be brought about in more than one way.

In regard to the function of retention, as pointed out in Chapter IV, we know that an increase can be caused either by an exaggeration of the retention function brought about by an overaction of the sympathetic system, or by a weakening of the emptying function caused by a feeble action of the parasympathetic system. In this regard, too, we know that it may be entirely a pathological fault—a pathological retention mainly of myogenic origin. The same principle applies to the function of emptying.

Thus, throughout the whole length of the alimentary canal there may be sporadically found gross disturbances of the neuromuscular mechanism of any of the various neuromuscular sections, giving rise to exaggerations of the retentive function, and therefore to *gross pathological dilatations*—the so-called atonic dilatations; and conversely to an exactly opposite type causing great exaggerations of the emptying function—which become evident as *gross pathological spasms*.

GROSS PATHOLOGICAL DILATATIONS

Idiopathic Ileus.—Some of these derangements of the retention mechanism of the various parts of the alimentary canal are described below.

Ileus of the Œsophagus (Cardiospasm or Achalasia).—One of the most typical examples of these gross pathological dilatations is the so-called cardiospasm of the œsophagus, a condition which has been described in detail in Chapter II, where an example of this gross dilatation of the œsophagus is to be seen in *Fig. 4*.

Although the word 'ileus', from the Greek *ἰλεός* = colic, is a term perhaps misapplied to most of these so-called paralytic pathological dilatations—it is applied, for example, to gastric ileus, duodenal ileus, and small-intestine ileus—it may for the purposes of comparison be

also temporarily misapplied to the gross pathological dilatation of the œsophagus called cardiospasm, which we might call œsophageal ileus.

Ileus of the Gastric Fundus.—An ileus of the cardiac portion of the stomach is occasionally seen. In X-ray observations I have seen forms of this paralytic dilatation, and in some instances it has attained an enormous size. The dilatation was limited to the fundal part of the stomach, and was bounded by the cardiac sphincter and a sharply marked-off complete hour-glass contraction about the position of the rudimentary mid-gastric sphincter.

Ileus of the Stomach.—High grades of paralytic dilatation of the whole stomach—gastric ileus—are frequently seen in neurotic types of female patients, and a minor grade of it is often the cause of a dyspepsia.

Gastric ileus is also seen after some gastric operations, when the stomach is found to be paralytically dilated and unable to empty its contents.

Ileus of the Stomach and Duodenum.—An enormous acute dilatation of the stomach and the duodenum—acute gastroduodenal ileus—sometimes follows operations. The distal limit of the ileus is always found in the region of the rudimentary sphincter near the terminal part of the duodenum. The condition is not caused, as was previously thought, by an obstruction of the duodenum due to the dragging on the superior mesenteric artery.

The following case record is an example of a chronic ileus of the duodenum. It also shows how these cases come within the purview of the surgeon. Incidentally, too, it is an instance of the futility of surgical treatment, such as duodeno-jejunostomy.

A thin nervous type of female patient, aged 28, complained of a vague dyspepsia without any pain, coming on between two and three hours after meals. She had lost weight and complained of constipation. She was thin and emaciated, and had diffuse tenderness over the duodenum. She had been ill for years. The radiograph showed that the duodenum was enormously dilated.

At the operation, an extreme dilatation of the duodenum, which extended from the pyloric orifice to the terminal part of the duodenum, was found. The stomach was not dilated. A duodeno-jejunostomy was performed. The patient's symptoms were only slightly improved by the operation.

Some years later, at a second operation, it could be demonstrated that although the duodeno-jejunostomy opening functioned, the actual dilatation of the duodenum had not decreased. (*Fig. 27.*)

This case is a good example of a pronounced ileus of the duodenum. The result of the operation on this patient shows also that it is not

caused by an obstruction, but by some form of paralysis or active dilatation of the duodenal wall ; for even when an anastomotic opening was made in the dilated duodenum, it did not contract to its normal size, as it would do if the dilatation were due to obstruction.

Fig. 28 is an operation sketch of a large duodenal ileus for which gastro-enterostomy had been performed. Reoperation, many years later, showed the duodenum still very large, notwithstanding the fact

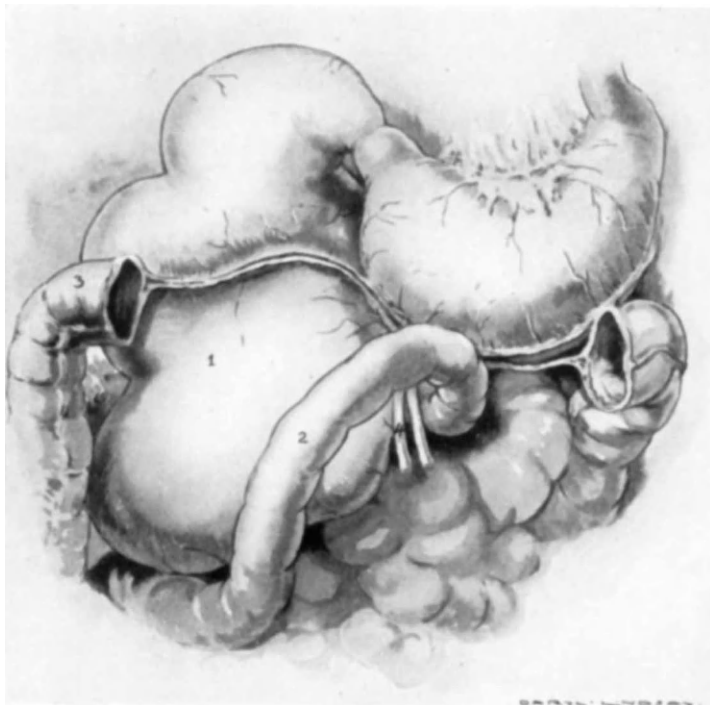

Fig. 27.—Sketch of a case of duodenal ileus, in which duodeno-jejunostomy was carried out. 1, Dilated duodenum; 2, Anastomosis between jejunum and dilated duodenum; 3, Colon; 4, Superior mesenteric artery.

that scarcely any gastric contents had passed through it, shown by the small atrophic afferent loop (smallness exaggerated in the sketch) to the stoma. The patient's symptoms were worse after the gastro-enterostomy, and the gastro-anastomosis had to be undone.

Ileus of the Small Intestine.—Paralytic ileus is the term given to the so-called idiopathic dilatation of the small intestine, which occasionally occurs after an abdominal operation, and the cause of which is not obvious. An example of this, taken from my own practice, is as follows.

I operated on a female patient who had a very poor type of nervous system. The operation was an exploratory one for an obscure abdominal condition.

At the operation, a very gentle exploration revealed no sign of organic disease. I was most careful to disturb intestines as little as possible, and was able to do this by holding up the abdominal wall with my abdominal operating frame.

Notwithstanding this care, the patient developed a paralytic ileus, which was so intractable that in desperation I reoperated, feeling that there must be some organic obstruction. I found the whole of the ileum dilated as far as the ileocæcal valve—a clear case of an idiopathic paralytic dilatation of the small intestine. The patient died—probably as the result of the second operation.

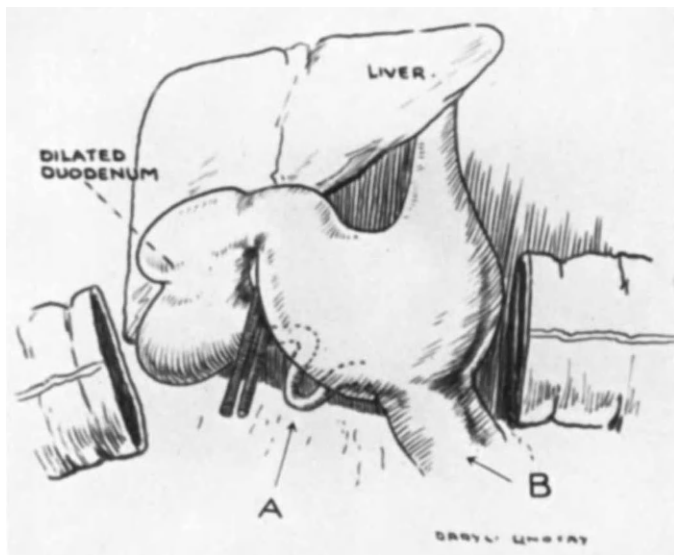


Fig. 28.—Operation sketch of a case of duodenal ileus many years after a gastro-enterostomy had been performed. The duodenum still remains dilated. A, Small atrophic afferent loop; B, Very enlarged efferent loop.

It has been my experience that paralytic ileus of the small intestine occurs in two sets of circumstances.

It is found in patients with a very debilitated nervous system, in whom there is a general overdevelopment of sympathetic action; that is, in those who are suffering from enteroptosis, and who have an exaggeration of all retention postures.

It is also seen in patients in association with infection or disturbance of the retroperitoneal tissue: such as, for instance, in operations of the kidney where there may be infection of the retroperitoneal

apparently similar in their origin to those occurring in the various sections of the alimentary canal. In these cases the walls are thin and passively dilated. Many cases of this nature have also been reported in the literature—the hydronephroses caused by a neuromuscular disturbance.

Idiopathic Dilatation of the Ureters.—Enormous distension of both ureters is sometimes found in children. In such cases, at the time of the post-mortem, no satisfactory mechanical explanation has ever been found. A condition somewhat similar to this, but to a lesser degree, is sometimes found in adults.

In a case reported personally by the late Dr. Lazarus the patient complained of a dragging pain in the right side, and the radiograph showed a dilated ureter on both sides—a double hydro-ureter. Stretching the orifice of the ureter on the right side relieved the patient's pain, but did not cause any diminution of the dilatation of the ureter (*Fig. 30*).

Pathological Dilatation Caused by Hypertrophy of the Sphincter and the Presphincteric Muscle-fibres.—In all the various gross pathological dilatations already described, the walls of the visceral section are thin and lack muscle power, and the sphincter appears normal. This may be taken as evidence that these conditions are gross exaggerations of the retention mechanism.

But there are also pathological dilatations in which the muscle-layers of the organ are greatly hypertrophied and where apparently there is an overdevelopment of the sphincter and presphincter muscle-fibres—sympathetically supplied muscle.

An example of this type of dilatation is seen in the dilated and hypertrophied stomach of congenital pyloric stenosis. In this condition the wall of the stomach is muscular and empties the stomach as soon as the greatly increased sphincteric muscle-fibres are divided. It is obvious in this case that the dilatation is a secondary condition to sphincteric muscle obstruction, and a condition diametrically opposite to the so-called idiopathic or paralytic dilatation or ileus described earlier in this chapter.

Aschoff describes a condition of dilatation (with hypertrophy) of the gall-bladder which is obstructive, and in which spasm or hypertrophy of the sphincter is the cause.

Of much the same character as the above, probably, is a dilatation which I accurately observed in the pelvis of the kidney in the following interesting case—an observation which should throw some light on almost similar conditions which have been seen in the adult stomach.

At an operation for an enlarged kidney, I found (as had been diagnosed by a previous X-ray examination) a large hydronephrosis of the organ. Irritation of the pelvis caused powerful peristaltic waves to travel down the pelvis until they reached a spot about $\frac{3}{4}$ in. from the pelvo-ureteral junction, where the waves immediately returned as antiperistaltic waves. The walls of the pelvis were hypertrophied and thick. As the kidney had to be removed, I divided the ureter. No urine issued from the ureter as the result of the peristaltic waves. I then inserted a cannula into the cut ureter, whereupon the peristaltic waves at once caused the urine to flow. When the kidney was removed and held up, that is, when its tissues were devitalized, the urine flowed out of the dilated pelvis through the cut ureter by the force of gravity.

This type of pathological dilatation is entirely different from the usual hydronephrosis caused by neuromuscular dilatation. The deep peristaltic and antiperistaltic waves indicated obstruction. The obstruction in this case was probably some type of presphincteric or sphincteric muscular obstruction or block—a freakish overdevelopment of sympathetically innervated fibres.

It is now interesting to consider that the stomach and the duodenum may be pathologically dilated together or separately; that the colon and the rectum may be dilated together or separately; that the colon, the rectum, and the bladder may be dilated together or separately.

Thus it is obvious that the coexistence of pathological dilatation of segments of the alimentary canal suggests at once that the lesion is in the sympathetic ganglionic plexus; that is, in the retroperitoneal tissue of the posterior abdominal wall, a plane in which is situated a great deal of lymph-gland tissue, very vulnerable to infection, and a plane which is very much exposed to the effect of operation, trauma, mild infection after operation, and infection from almost any abdominal infective process.

In order to appreciate the nature of these pathological dilatations of the œsophagus, stomach, and duodenum, it has been necessary to discuss the gross functional disturbances in regard to retention of all sections of the alimentary canal, and all hollow organs; for, judging from clinical observations, these extreme disturbances of the function of retention seem to have—indeed, must have—a similar neuromuscular or neuromuscular and myogenic basis.

What is Learnt from the Treatment of these Pathological Dilatations.—A further interesting light is thrown on these pathological dilatations when the result of their treatment is considered. I have been able to relieve permanently several cases of cardiospasm by manually stretching the lower end of the œsophagus and its sphincter.

Yet although the patient is completely relieved, has gained many stone in weight, has been well for years—in one case as long as eight years—nevertheless the dilatation of the œsophagus has remained much the same; that is, the anatomy of its wall has not changed—the wall has not contracted to normal. In Chapter II is the radiograph of a cardiospasm taken eight years after the lower end of the œsophagus had been stretched, when it still showed almost the same dilatation as it did before the operation (*Fig. 12*). Although the patient had gained four stone in weight and exhibited practically no symptoms, it is difficult to see much difference between this radiograph of his œsophagus and that taken before the treatment (*Fig. 11*).

In cases where pathological colonic dilatation has been treated by section of the sympathetic, there is clinical evidence to show that the dilated colonic wall has contracted somewhat, but never to its normal condition.

Since it has become possible by the zonal method of spinal anæsthesia of Kirschner to anæsthetize the sympathetic fibres innervating the colon without anæsthetizing the pelvic nerve, it has been found by X-ray observations that the enlarged dilated colon contracts considerably, and empties itself more effectually, as a result of the paralysis of its sympathetic supply.

In the cases of duodenal ileus which I quoted earlier, and in which I performed duodeno-jejunostomies, my observations over a period of many years showed that, although the duodeno-jejunostomy stoma functioned and the duodenum emptied better, the duodenal wall had never contracted.

In cases of hydronephrosis of neuromuscular origin, in which the ureter has been anastomosed to the dilated pelvis, it has been found that, although the dilated pelvis emptied more rapidly and the patient was relieved, injections of radio-opaque substances showed that the dilated pelvis of the kidney had not contracted.

Thus it would seem from clinical observations of the effect of their successful treatment that these inorganic pathological disturbances of the emptying of the sections of the alimentary canal and of hollow organs consist of a relaxation of the wall, active or passive, probably due to functional lesions of the sympathetic plexus, or to injury of the ganglion cells in the retroperitoneal tissues of the posterior abdominal wall. They may, of course, be pathological retention postures of myogenic origin.

It is important to study the gross pathological dilatations which in isolated instances are found in the various sections of the alimentary canal, because they come before the surgeon for surgical treatment,

and are on unsound principles subjected to useless operations. It is also wise to consider them because they serve as an introduction to the study of surgical dyspepsia; for they show the extreme disorders of the function of retention which can occur in the various sections of the alimentary canal without any obvious signs of organic disease. Their ubiquitous occurrence in all hollow organs and in all sections of the alimentary canal gives some support to my belief, based on my own clinical observations, that, particularly in the fore and hind gut, lesser grades of this type of retention disorder occur frequently; and that degrees of the disorder become in many cases the basis of a dyspepsia and the forerunner of organic gastric disease.⁴

GROSS PATHOLOGICAL SPASMS

Just as there are extreme dilatations of the various sections of the alimentary canal of doubtful origin—pathological dilatations—so there are in these sections isolated cases of extreme spasms, extreme exaggerations of the function of the mechanism of emptying—pathological spasms.

The most pronounced pathological spasms which I have ever seen in hollow organs have been in the sigmoid and in the bladder—organs in which the function of emptying must necessarily be most pronounced, for they are mainly concerned with the ejection of excreta, in contrast to organs like the stomach, which are mainly concerned with the reception of food—with the function of filling of the stomach.

Pronounced Painful Spasm in the Sigmoid.—The following case is an example of gross pathological spasm:—

A soldier who had been bayoneted several times in the abdomen, recovered after months of great suffering and after many operations undertaken to close fæcal fistulæ and to relieve chronic obstructions. His nervous system was completely shattered. He began to suffer from spasms of intense pain in the left iliac fossa. These attacks of pain, which would last for three or four days, were associated with a continuous tenesmus: he would sit on the lavatory for hours, passing only a little mucus.

Sigmoidoscopic examination revealed nothing abnormal in the rectum or in that part of the sigmoid which could be visualized with the sigmoidoscope.

During the attacks a hard, firm, globular tumour could be felt in the left iliac fossa, in the region of the sigmoid (*Fig. 31*). The patient found that he could lessen the intensity of these attacks by getting drunk.

At an exploratory operation a firm, hard tumour about as big as a small orange was found occupying the lower portion of the sigmoid. It had all the appearances of a carcinoma, and felt so hard that for a while it was

very great, it was possible to cure the condition by overstretching the bladder by internal pressure, on the same principle as the lower end of the œsophagus is overstretching for the cure of cardiospasm.

This observation, of course, is only of interest in the present discussion inasmuch as it suggests that these pathological spasms may be the result of a disturbance in an inherent postural tone of the muscle of a particular segment rather than a disturbance of the nervous control of the muscle of the segment.

If, then, the various grades of pathological dilations and pathological spasms which can take place in the different segments of the alimentary canal occur as the result of either disturbances of the inherent properties of muscle or minor disharmonies in the autonomic nervous system, it will be obvious that in disordered states of the general nervous system, which must affect the autonomic nervous system, the foundations of disease in the stomach can be laid. These may arise either from the delay caused by the dilatation, exposing its mucous membrane to the prolonged action of a weak acid gastric juice, or from the spasm concentrating the intensive action of a strong gastric juice on a particular part of the gastric or duodenal wall, as happens, for example, in duodenal ulcer.

Furthermore, it will be obvious that, in the disturbed state of the general nervous system which can occur after repeated operations, when the threshold of sensation to normal impulses is lowered, minor degrees of abnormal spasm of the alimentary canal can give rise to pain. It is this type of painful syndrome which may be erroneously interpreted as being due to organic disease, or to adhesions from previous operations, and which often leads to a useless operation on the mistaken diagnosis of peritoneal adhesions.

REFERENCES

- ¹ *Der Chirurg*, 1936, Jan. 15.
- ² ASCHOFF, LUDWIG, *Pathologische Anatomie*, 1928. Jena: Gustav Fischer.
- ³ MORISON, RUTHERFORD, *Introduction to Surgery*, 3rd ed., 1935, 250. Bristol: John Wright & Sons Ltd.
- ⁴ BROWN, A. E., "Cardiospasm, Megacolon, and Megacystis", *Austral. and N.Z. Jour. Surg.*, 1936, July, 88 (abstr. from *Der Chirurg*, 1936, Jan. 15).

CHAPTER VII

THE SIGNIFICANCE OF NAUSEA AND VOMITING

IN the chapter on the mechanism of causation of dyspepsia, the symptoms of fullness, discomfort, pain, were given full consideration. In many dyspeptic pictures, however, nausea and vomiting rather than these symptoms are the main features.

A predominance of nausea and vomiting in a dyspeptic picture is suggestive of a malignant cause. If these symptoms come on *immediately after the intake of food*, this is more indicative of carcinoma. If they occur after an interval of time following the taking of food, and if the vomited material is scanty—that is, the vomiting is not for the purpose of relieving the stomach of the intake of food—and if the vomiting does not give relief, then such a type of nausea and vomiting is also suggestive of malignancy, even if the dyspepsia is painful like that of gastric ulcer. Broadly speaking, a great deal of nausea and vomiting distributed through a painful dyspeptic syndrome suggests malignancy.

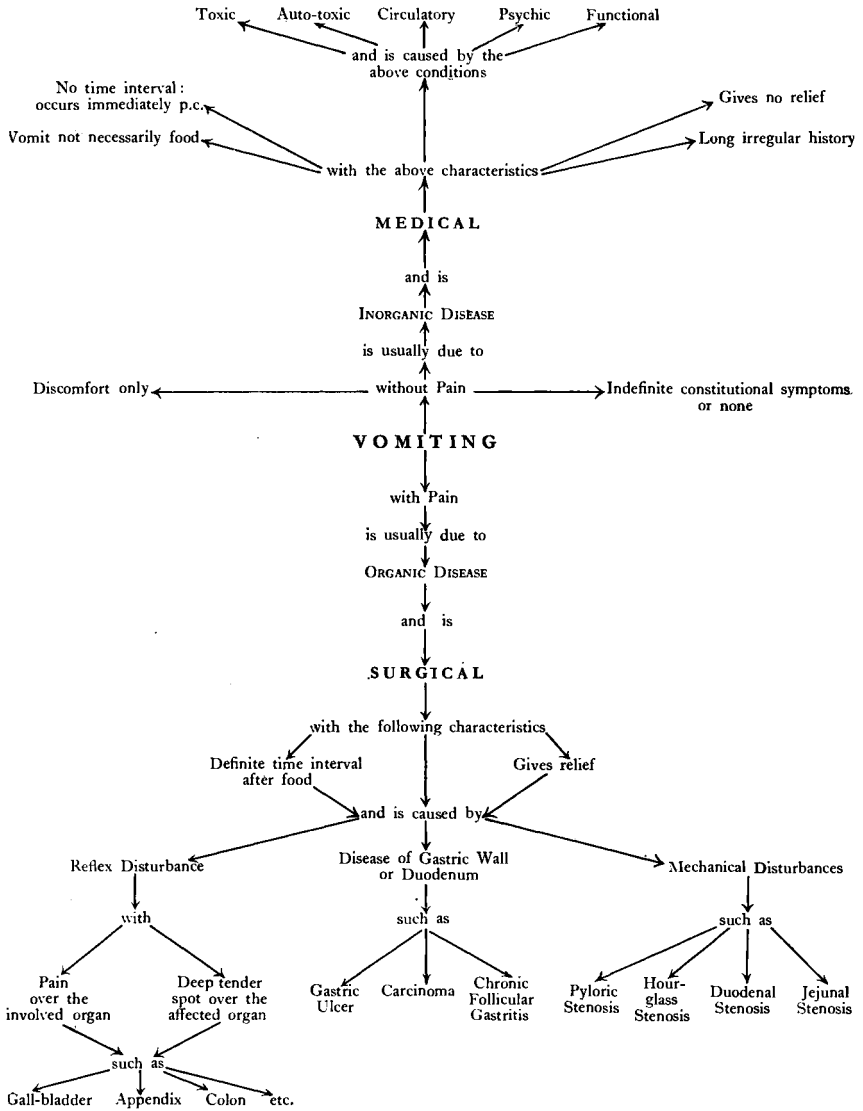
Nausea and vomiting which come on immediately after meals may also be manifestations of functional disease of the stomach.

A dyspeptic picture in which nausea and vomiting are dominant features is, too, characteristic of that form of dyspepsia which is seen sometimes in the early stages, and always in the late stages of renal or hepatic disease, or disease in the other systems of the body such as pulmonary tuberculosis.

Where nausea and vomiting are features of a dyspeptic syndrome which has originated from a gastric malignancy, they are usually associated with a more or less painful dyspepsia, with a progressive constipation, and with an increasing constitutional disturbance.

A nausea-and-vomiting type of dyspepsia is not characteristic of uncomplicated gastric or duodenal ulcer. In these conditions, as practically the whole of the gastric and duodenal wall is quite healthy, spontaneous nausea and vomiting do not usually occur. The patient who suffers from an uncomplicated gastric or duodenal ulcer generally induces vomiting to get relief from his pain. When nausea and vomiting do occur in uncomplicated chronic peptic ulcer, these symptoms never come on immediately after the intake of food ; but only

Schema of the Significance of Vomiting as a Symptom



when some time has elapsed, the interval being completely free from any symptoms.

If, however, chronic gastric or duodenal ulcer becomes complicated, as, for instance, if it becomes a penetrating ulcer, then there is often found spreading from the ulcer into the surrounding gastric or duodenal wall a diffuse secondary gastritis; and in such cases, as the main part of the gastric wall is not healthy, the intake of food is generally followed immediately by a certain amount of nausea and perhaps of vomiting (sometimes associated with fullness and discomfort).

Thus the inclusion of a nauseous and vomiting complex in a painful dyspeptic syndrome, that is, a syndrome indicative of *uncomplicated* peptic ulcer, is suggestive of one of two things. It may indicate that a secondary diffuse gastritis has developed as the result of chronic infection extending from an old and penetrating ulcer; or, on the other hand, it may suggest that an innocent chronic peptic ulcer has become malignant.

All the types of nausea and vomiting already mentioned must be distinguished from that form of nausea and vomiting which occurs as the result of mechanical interference; that is, as the result of a pyloric or a duodenal obstruction. In these cases a continuous nauseous feeling is not a feature; nausea immediately precedes the vomiting. Vomiting which occurs three, four, or five hours after a meal, or at the end of each day perhaps, at about nine or ten o'clock at night, has a mechanical origin. Such vomiting is caused by a pyloric or duodenal stenosis. It nearly always occurs at the same time each day; severe nausea comes on just before the vomiting is about to take place; and relief of fullness, discomfort, or pain, following the vomiting, is very distinct. In these cases of mechanical obstruction the quantity of the vomited material is, of course, copious. Sometimes this type of vomiting is associated with cramp-like colicky pains, which disappear when the vomiting takes place.

GENERAL DISTINCTIONS BETWEEN MEDICAL AND SURGICAL DYSPEPSIA

It may be wise at this stage in the discussion of surgical dyspepsia to make some generalizations in regard to the distinction between the dyspepsia caused by inorganic disease (medical dyspepsia) and that caused by organic disease (surgical dyspepsia). The table on p. 71 has been drawn up to show the broad distinctions between the two.

DIFFERENCES BETWEEN THE DYSPEPSIA OF INORGANIC
AND OF ORGANIC DISEASE

INORGANIC DISEASE	ORGANIC DISEASE
No definite onset.	A very definite onset.
A background of nervous debility.	A background of good nervous health.
Symptoms (usually nausea and vomiting) immediately the stomach begins to fill.	Symptom-free interval of time after food. Absence of symptoms during filling of the stomach, as in case of chronic ulcer. Symptoms of discomfort and pain only on emptying the stomach.
Comparative good health.	Definite onset of ill-health, getting progressively worse (as in case of carcinoma).
No definite cause ascertainable.	Possible cause usually obvious.
Symptoms are irregularly intermittent.	No intermissions: as in carcinoma. Periodicity: as in chronic ulcer.
May be general epigastric hyperæsthesia: never a 'deep tender spot'.	'Deep tender spot.'
No sign of organic disease such as hæmorrhage.	Signs of organic disease as shown by hæmorrhage or occult blood.
Bears no direct relation to errors in diet except in dyspepsia of allergic origin. Origin traceable to nervous or emotional causes.	Has a definite relation to dietetic errors, or to particular articles of food.

CHAPTER VIII

**AETIOLOGICAL CLASSIFICATION OF SURGICAL
DYSPEPSIA**

DYSPEPSIA may now be discussed from an aetiological point of view, and for this purpose may be broadly classified into four great groups as follows :—

1. Dyspepsia caused by disturbance of the vitality of the gastric or duodenal wall, the result of local or systemic disease—*vitality dyspepsia*.
2. Dyspepsia which arises as the result of a disturbance of the neuromuscular function of the stomach—*functional dyspepsia*.
3. Dyspepsia which occurs as the result of neuromuscular reflex disturbances either in other parts of the alimentary canal or in its adnexal organs, such as the appendix, gall-bladder, or pancreas—*reflex dyspepsia*.
4. Dyspepsia caused by organic disease of the œsophagus, stomach, or duodenum—*organic dyspepsia*.

The first two types, which are of slight surgical importance, are dealt with below. They require but brief discussion.

Vitality Dyspepsia.—In order that the gastric wall should function, it must have a normal circulation and cells of normal vitality. Dyspeptic syndromes can thus arise as a result of local or systemic disease, which may disturb the vitality of the gastric wall by the excretion of toxic products or by causing circulatory deficiencies. This disturbance of its vitality interferes with the normal motor and secretory functions of the stomach, and a dyspeptic syndrome, generally of the painless type, occurs. Nausea and vomiting are features of this form of dyspepsia. The symptoms of fullness and discomfort may also be present.

This type of dyspepsia may be one of the earliest manifestations of disease with a systemic effect, and may come on before there is any suspicion of the condition. Since it may be associated with constitutional disturbances, the surgeon is sometimes confronted, in consultation, with a patient complaining of this kind of dyspepsia, because it is thought that he may be suffering from an early carcinoma of the stomach. It is not uncommon to see cases of this

painless, nauseous type of dyspepsia associated with anorexia, in which an early carcinoma is regarded as the cause of the dyspepsia, but in which early tuberculous disease of the lung is the true cause.

A congestion of the stomach arising from an early and perhaps unrecognized heart failure may give rise to a dyspeptic syndrome of nausea and vomiting associated with perhaps hæmatemesis and melæna. This kind of painless dyspeptic syndrome is frequently seen in the early stages of a slowly developing heart failure which occurs in renal degenerative disease. The painless type of dyspepsia, the cachexia of the renal disease, the hæmatemesis, and the nutritional changes in this dyspeptic pattern, give a clinical picture very like that of gastric carcinoma.

A painless dyspeptic syndrome is often seen as an early manifestation of hepatic cirrhosis, or in the early changes of pernicious anæmia.

Addison's disease may give a dyspeptic syndrome very like that of gastric carcinoma.

Severe painful dyspepsias are frequently seen in degenerative conditions of the nervous system, such as locomotor ataxia.

Functional Dyspepsia.—The various phases of functional dyspepsia have already been discussed in a general way, not only in regard to their causation, but also to the way in which they may simulate dyspepsia of organic origin and therefore be confused with dyspepsia of surgical import. As this type of dyspepsia is not of much importance from a surgical point of view, it is not necessary to discuss it separately.

CHAPTER IX
REFLEX DYSPEPSIA

THE symptoms of a reflex dyspepsia are, in most cases, manifestations of disturbance of the motor functions of the stomach. These functions of filling and emptying of the stomach in their relation to those of the other sections of the alimentary canal are controlled and co-ordinated by the autonomic nervous system, the parasympathetic and sympathetic (*see Fig. 26, p. 54*).

The parasympathetic supply to the alimentary canal comes by way of the vagus and the sacral outflow. The vagal nerve supply to the stomach is thus only a small part of a much larger vagal field which innervates the greater part of the alimentary canal. A disturbance, therefore, in any part of this larger vagal nerve field may affect the smaller vagal nerve-supply of the stomach, and consequently may disturb its expulsive function (its emptying mechanism).

Similarly, a pathological condition in any part of the alimentary canal must necessarily involve the whole sympathetic field, and through this it can disturb the smaller sympathetic supply of the stomach, and therefore its retention function (its filling mechanism).

Thus it will be obvious how disease in any part of the alimentary canal can interfere with either the filling or the emptying of the stomach, or with both of these functions; and how disease of the appendix or of the gall-bladder, or indeed of any other part of the alimentary canal, can cause dyspepsia—a *reflex dyspepsia*.

This basis of reflex dyspepsia is experimentally shown when the small intestine is divided at its lower end. The emptying function of the stomach is at once interfered with, probably through neuromuscular channels, and ceases for perhaps seven or eight hours. It would appear as if this reaction to an injury to the alimentary canal was a conservative provision of nature temporarily to relieve an injured intestine of its function, in order to give it rest, and thus a chance for its injury to be repaired. Thus it is not improbable that a subacute or chronic appendicitis causes a neuromuscular reflex comparable with that of the injured intestine, and that it causes a reflex dyspepsia probably due to a disturbance of the motor functions of the stomach.

Delay in emptying in one alimentary segment will also reflexly cause delay in the emptying of other segments. An instance of the

effect of delay in one segment is seen in the dyspepsia which may usher in an early carcinoma of the sigmoid. This dyspepsia is no doubt caused by a reflex disturbance of gastric emptying due to the delay in emptying of the sigmoid neuromuscular section.

Quick emptying in one alimentary segment will cause a quick emptying of the section above it. For instance, an enema in an empty and isolated recto-sigmoid segment will often make a transverse colostomy or an enterostomy act at once—act so quickly that it must be due rather to a reflex than a mechanical cause.

Thus we see another basis for a reflex dyspepsia; that is, a delayed or a quick emptying of one or more segments of the alimentary canal. We see how the normality of motor function in the stomach—the reception and transport of food material—is dependent on that of the other segments of the alimentary canal. We see, too, how necessary this is for the welfare of the individual, and appreciate the conservative foundation on which a reflex dyspepsia is based.

Recognition of Reflex Dyspepsia.—The surgeon will suspect that a dyspepsia is of reflex origin because it has the clinical characteristics of a surgical, painful dyspepsia, and because, by clinical and X-ray examination, he can find no causative organic disease of the stomach. Naturally he will then clinically investigate the possibility of a reflex dyspepsia (usually painful), and search for the presence of organic disease in other parts of the alimentary canal or its adnexa which could reflexly cause such a painful dyspepsia.

Pathological Causes.—From what has just been pointed out it is obvious that *inflammatory disease of the appendix, colon, small bowel, gall-bladder, and pancreas*, all of which organs are in the same sympathetic or parasympathetic field as that of the stomach, may easily cause a disorder of its filling or emptying and, therefore, a reflex dyspepsia.

Further, since *chronic duodenal, intestinal, and colonic obstruction* can interfere with the emptying of segments of the alimentary canal, these conditions can also give rise to a reflex dyspepsia.

There are also two other conditions which cause what appears to be a reflex dyspepsia. These are a partial calculous obstruction at the renal pelvi-ureteral junction, and a gross tuberculous affection of the abdominal glands. Both of these conditions give rise to a dyspepsia, but cause it mechanically, not reflexly. The first causes it by partially obstructing the pelvi-ureteral junction; and the second by obstructing the lymph-vessel absorption of food products.

Characteristics.—A reflex dyspepsia is curiously irregular in its incidence. For example, the 'attacks' of reflex dyspepsia caused by gall-bladder disease may last for a few weeks or a few days. The

intervals between the attacks are therefore characteristically irregular in their duration. The type of symptom and its severity are also curiously irregular—one symptom may appear at one time, and a different one at another time. The reflex dyspepsia due to chronic appendicitis comes on distinctively in 'attacks', the onset of which bears no relation to dietetic errors, and the intervals between which are peculiarly irregular. Moreover, unlike the painful dyspepsia of gastric ulcer, the attacks are non-periodic and non-seasonal.

REFLEX DYSPEPSIAS

Dyspepsias from gall-bladder disease: Nauseous; Flatulent; Gastric-ulcer-like; Duodenal-ulcer-like; Post-cholecystectomy.

Dyspepsia from pancreatic carcinoma.

Dyspepsias from appendiceal lesions.

Dyspepsia from renal calculous disease.

Dyspepsia due to tuberculous lymphadenitis of the mesentery.

Dyspepsia due to colonic affections.

Reflex Gall-bladder Dyspepsia.—

Nauseous Type.—In one type of dyspeptic syndrome brought about by gall-bladder disease there may be a nausea shortly after

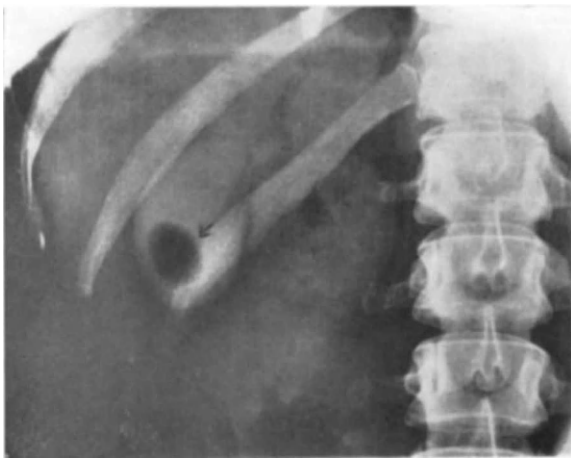


Fig. 32.—Radiograph of cholesterol stone in gall-bladder, which caused nauseous dyspepsia.

taking food; there may be no feeling of fullness and little flatulence. For example:—

At a pelvic operation, exploration revealed a stone in the gall-bladder. The stone was not removed. For twelve months the patient's dyspeptic picture was studied, and it was found that, at irregular intervals, she

suffered from severe nausea and some flatulence after meals. At a subsequent operation a small cholesterol stone was removed, and from that time onwards the nauseous dyspepsia disappeared. Apparently this small stone frequently became jammed after meals, in the S-shaped part of the gall-bladder or in the cystic duct, and caused the nausea. *Fig. 32* shows an X-ray picture of the gall-stone.

Flatulent Painless Type.—Flatulent painless dyspepsia is not infrequently the only manifestation of a cholelithiasis. It is probably due to a reflex disturbance of the motility of the stomach: that is, to a disturbance of its filling, giving rise to a sensation of fullness. The patient (usually a woman) feels that her stomach is full and

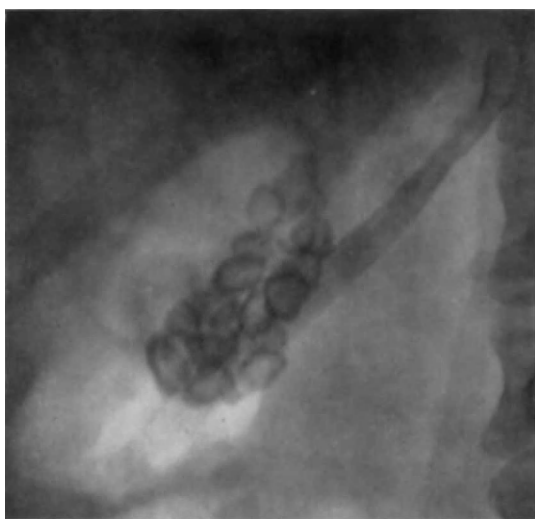


Fig. 33.—Radiograph of 'packed gall-bladder' which gave rise to symptoms similar to those of duodenal ulcer.

tries to get relief by belching. Actually her stomach is not distended, but she has a disturbance of the postural tone of the gastric wall with perhaps increase of the tension in the lumen of the stomach, and she feels that it is full. In these cases there may or may not be an associated disturbance of the gastric secretory function. This flatulent dyspepsia is peculiar in that it may come in 'attacks'.

Gastric-ulcer-like Type.—In some cases of gall-bladder disease, reflex painful dyspeptic symptoms coincide with the emptying phase of the stomach. In such cases there is then a variable interval of freedom from symptoms after the intake of food, followed by discomfort and other dyspeptic symptoms, and by a gastric-ulcer-like pain. These symptoms may be attributable to the painful

emptying phase of an inflamed gall-bladder or of a gall-bladder full of gall-stones.

Such a dyspeptic picture is very like that caused by gastric ulcer ; but as has been pointed out, these attacks of painful dyspepsia, unlike the painful dyspepsia of gastric ulcer, are characteristically irregular in their occurrence and duration.

Severe Duodenal-ulcer-like Type.—Sometimes a very diseased gall-bladder gives rise to such severe pain, coming on so long after meals and so dependent on the intake of food, that it is almost indistinguishable from that caused by duodenal ulcer.

A man complained that he suffered from severe pain about three hours after each meal. This pain was worse when he took certain articles of diet. Now and again he would get periods of relief from this pain, but they were very irregular. The pain after meals came in attacks, sometimes lasting a month. At times he developed an attack of epigastric pain, which was so bad that it would be necessary for him to have injections of morphia. This case had been diagnosed and treated as duodenal ulcer. Operation revealed that he had a gall-bladder packed very tightly with stones ('packed gall-bladder') (*Fig. 33*).

The following history is another example of this type of duodenal-ulcer-like gall-bladder dyspepsia in a case of duodenal ileus :—

A man, aged 43, had been ill for eighteen months, complaining of acid eructations and discomfort from two to three hours after meals. During the last month of his illness he had, three hours after food, suffered from a severe epigastric pain, which was relieved by food or by a warm drink. His general condition was good. It was thought that he had a duodenal ulcer. The radiologist's report was: "There is evidence of the presence of duodenal ulcer, with an associated dilatation of the second and third parts of the duodenum" (*Fig. 34*). Operation disclosed a duodenal ileus, the dilatation of which extended to the superior mesenteric artery, and a gall-bladder which was packed with gall-stones (*Fig. 35*).

Post-cholecystectomy Type.—It is not uncommon for a dyspepsia to follow a cholecystectomy—especially a cholecystectomy unskillfully performed. This dyspepsia may be of either (*a*) the painless or (*b*) the painful type, according to its causation, and in some cases it may have a reflex origin.

a. A painless type of dyspepsia which sometimes comes on after a cholecystectomy may be caused by adhesions of the duodenum and the prepyloric part of the stomach to the sutured peritoneum over the area from which the gall-bladder was removed. In such cases the adhesions are usually not firm and cartilaginous, and are therefore of the mild type, so that the dyspepsia is usually of the painless type. It may, however, be very intractable and not amenable to treatment.

b. A *painful dyspepsia* following a cholecystectomy can be caused by firm cartilaginous adhesions of the first and second parts of the duodenum to the bare surface of the liver which is left when the gall-bladder has been removed, and over which the peritoneum has not been properly sutured. In such circumstances a partial mechanical duodenal obstruction may be caused by the kinking of the duodenum

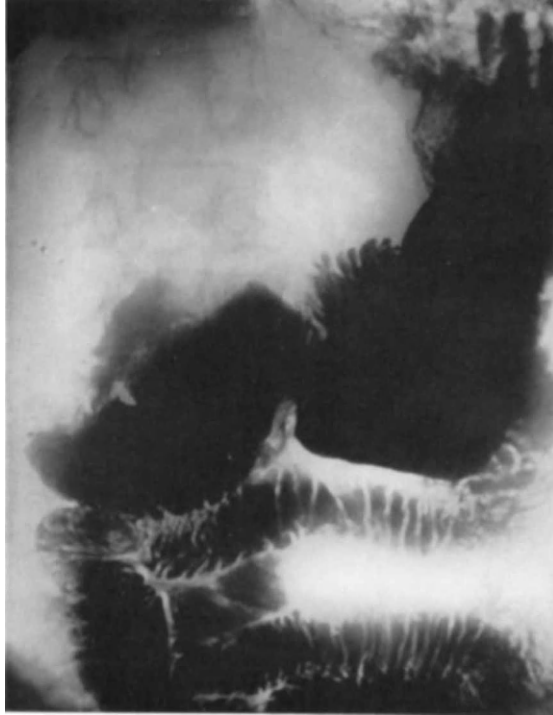


Fig. 34.—Radiograph showing a case of duodenal ileus with duodenal-ulcer-like symptoms due to gall-stones. Operation showed that the symptoms were caused by the gall-stones, and not by the duodenal ileus. (*By courtesy of Drs. Stephens and Crisp.*)

due to the *firm* adhesion to the liver. In this case the patient may vomit large quantities of gastric contents.

In less severe adhesions of this type, nausea, caused by the continual pull on the duodenum by the heavy liver, and pain an hour or two after meals probably caused by hampered duodenal peristaltic efforts, may be features of a dyspepsia following cholecystectomy.

Fortunately, dyspepsia following cholecystectomy is nowadays of less frequent occurrence than hitherto, because, in the modern

technique of removal of the gall-bladder, so much stress is laid on the great necessity of carefully peritonealizing the gall-bladder bed.

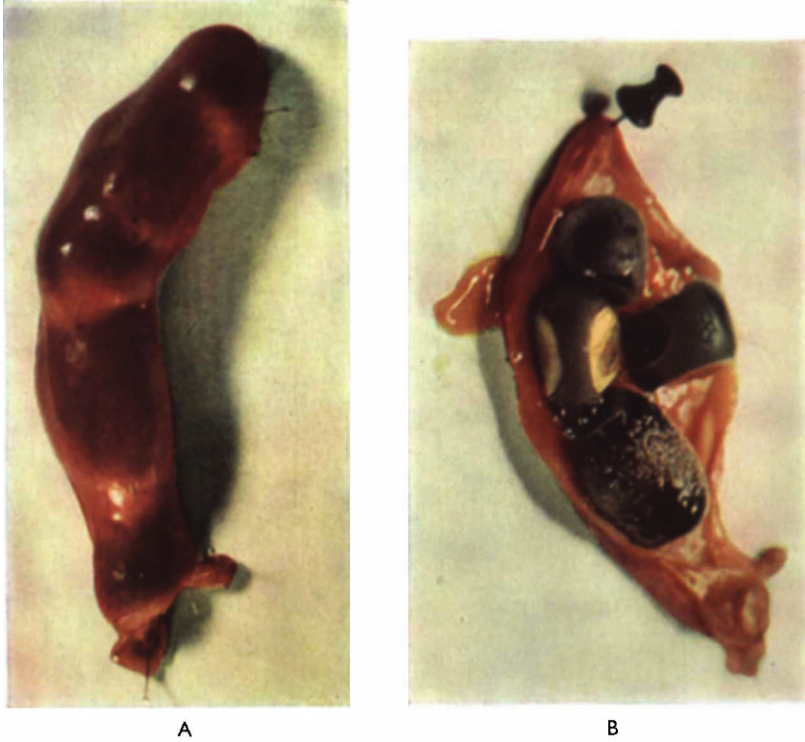


Fig. 35.—Gall-bladder packed with stones. A. Before opening; B. Opened to show stones.

A painful dyspepsia after cholecystectomy may also be caused by an incomplete cholecystectomy, when, for instance, a small stone is left in Hartmann's pouch, as in the following case:—

A patient complained that for twenty years he had attacks of nausea, vomiting, and epigastric pain. An operation was performed on him, gall-stones were found, and his gall-bladder was removed. Three weeks after the operation he again began to suffer from the same sort of epigastric pain, which kept on recurring in attacks over a period of many years. The pain bore a definite relation to the taking of food, and was like that of gastric ulcer. This was shown by the fact that for years he had been frequently sent in to hospital for dietetic and medicinal treatment for gastric ulcer. Fig. 36 is a radiograph of his stomach, which shows a good deal of deformation of the whole of the prepyloric part. The deformation was thought to be caused by a gastric ulcer.

Operation disclosed that a pouch of Hartmann, which had been wrapped in the peritoneum round the common duct, had been overlooked and not removed. In this was found a small stone, shown in Fig. 37.

Very occasionally a painful dyspepsia follows cholecystectomy probably as the result of a spasm of the sphincter of Oddi. After meals the patient may experience colicky pain. In these cases I have found that the common duct was dilated, but even after careful

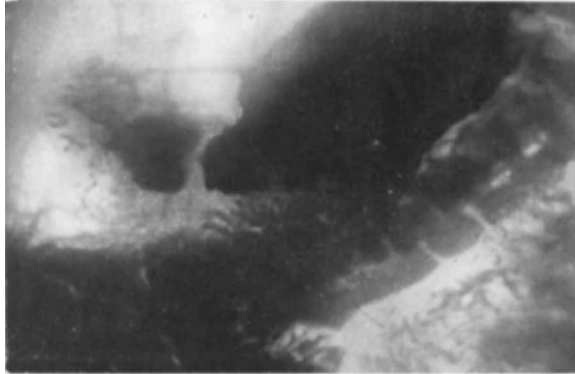


Fig. 36.—Radiograph of stomach in a case of stone in the pouch of Hartmann. The stomach shows a good deal of deformation.

examination I have not been able to detect the presence of any small stone which might have been overlooked. I have therefore always assumed that this condition was due to some spastic condition of the sphincter of Oddi caused by an imbalance of the sphincteric apparatus following removal of the gall-bladder.

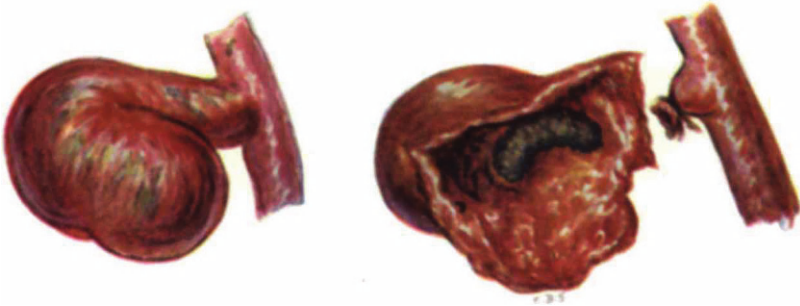

Fig. 37.—Showing a pouch of Hartmann containing a stone left behind after a cholecystectomy.

As the gall-bladder and the stomach are innervated from the same spinal segments—the 7th, 8th, and 9th—it follows that in reflex painful dyspepsia arising from gall-bladder disease, epigastric pain—the pain of the inflamed gall-bladder itself—will have the same distribution as that arising from disease of the stomach. As this epigastric

pain also may vary with the intake of food, the similarity of painful dyspepsia due to gall-bladder disease to that caused by chronic gastric or duodenal ulcer is sometimes very great.

Significance of the 'Deep Tender Spot' in Reflex Gall-bladder Dyspepsia.—As a rule, in a case of reflex gall-bladder dyspepsia a 'deep tender spot' is found over the gall-bladder. If a 'deep tender spot' is absent, there is usually a history that at a previous

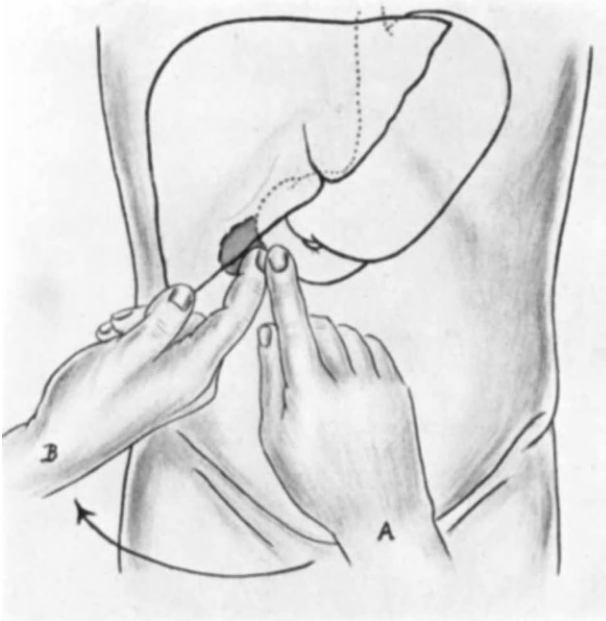

Fig. 38.—Axis pressure. A, Tenderness at the end of a deep breath with the pulp of the finger pointing to the under surface of the liver indicates disease of the gall-bladder; B, Tenderness with the pulp of the finger pointing in this direction indicates duodenal ulcer.

examination it may have been present. Occasionally, however, there is no 'deep tender spot' nor even a history of one, and even a cholecystogram may show no evidence of cholecystitis or of gall-stones. Yet despite this negative evidence, the dyspepsia may still be caused by gall-stones. Under such circumstances, then, the diagnosis of a gall-bladder dyspepsia from that of a functional dyspepsia can only be made by a shrewd analysis of the clinical dyspeptic picture.

Diagnosis of an Equivocal 'Deep Tender Spot'.—Sometimes, in a case of supposed gall-bladder dyspepsia, there may be a 'deep tender

spot' which appears to be situated over the gall-bladder. It may, however, be the 'deep tender spot' of a chronic duodenal ulcer, the symptoms of which, as we have seen, may be similar to those of gall-bladder disease. In order to discriminate between the 'deep tender spot' of duodenal ulcer and that of gall-bladder disease, the finger should be placed on the spot, and the pulp of the finger should be directed towards the lower surface of the patient's liver. If the patient takes a deep breath, as the descending liver touches the palpating finger, tenderness should be felt if it is due to gall-bladder disease. If there is no tenderness, then, without changing the position of the finger, its pulp is directed backwards towards the spine, thus altering the axis of the pressure. Tenderness felt in this axis indicates duodenal ulcer (*Fig. 38*).

Dyspepsia Caused by Scirrhus Carcinoma of the Body of the Pancreas.—A dyspepsia very similar to that caused by gall-stones may be caused by scirrhus carcinoma of the body of the pancreas in its early stages.

As a rule, the ordinary adenocarcinoma of the body of the pancreas does not give rise to pain. But the very chronic scirrhus carcinoma in this situation may cause considerable pain; and when this pain is indefinitely related to the intake of food, and situated in the lower part of the epigastrium, the dyspeptic syndrome is not unlike that of gall-bladder disease or that of duodenal ulcer.

The following case-history is an example :—

A patient began to complain of pain occurring fairly regularly in his epigastrium and radiating through to the back, more on the left side than on the right side. His pain came on about two o'clock in the morning, and because of this time-incidence and his indefinite dyspepsia it was thought that he was suffering from a duodenal ulcer. He was then radiographed and considerable deformity of the duodenum was seen. His epigastrium was rigid but he had no tender spot. A definite diagnosis of duodenal ulcer was then made. While under treatment for this condition he began

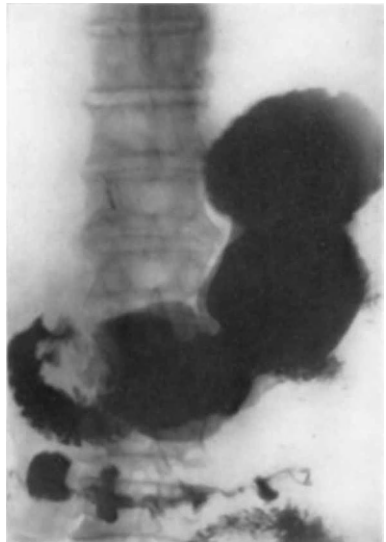


Fig. 39.—Radiograph of chronic scirrhus carcinoma of the body of the pancreas with great contraction, which caused distortion of the duodenum.

to lose his appetite, to lose weight, and to be unable to work. It was decided to operate on him, but while waiting for his operation, he suddenly developed jaundice with *great pain*. It was then thought that he undoubtedly had gall-stones, and that the duodenal ulcer diagnosis was an error. Operation disclosed that he had a very chronic scirrhus carcinoma of the pancreas with great contraction. Evidently this had caused the distortion of the duodenum seen in the radiograph (*Fig. 39*), the epigastric pain radiating through to the back on the left side, and the jaundice (from a rapidly occurring obstruction of the common duct) which came on with a great deal of pain.

Appendiceal Dyspepsia.—Reflex appendiceal dyspepsia occurs, characteristically, in ‘attacks’ of fairly short duration. It may occur as a painless dyspepsia. It may also come on as a painful dyspepsia

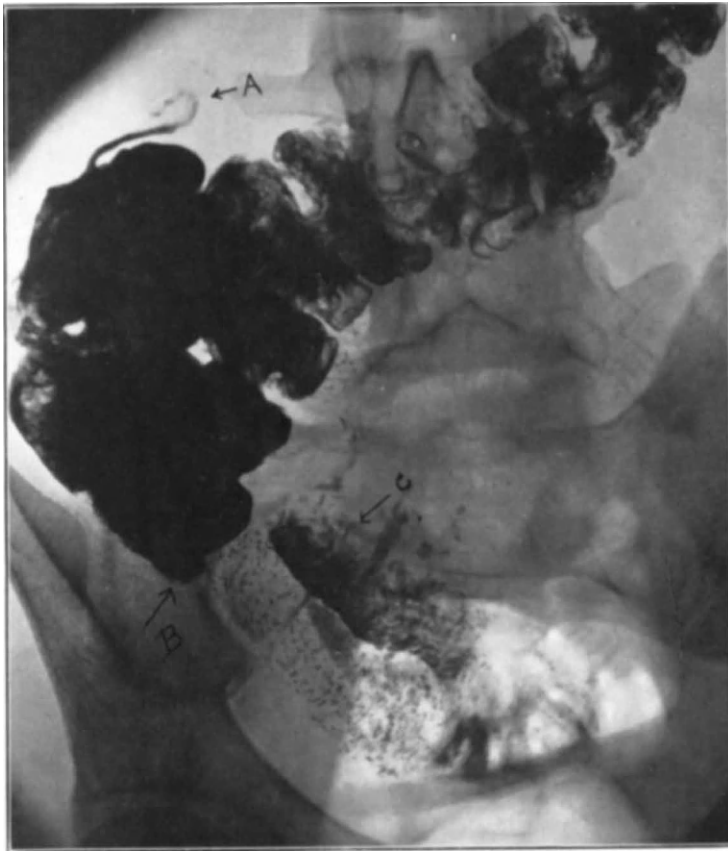


Fig. 40.—Radiograph of an undescended appendix (A); in this case the tender spot was over the right kidney. (*Figs. 40 and 41* by courtesy of the ‘*Journal of the College of Surgeons in Australasia*’.)

with an epigastric pain, which bears a very indefinite relation to the intake of food. The epigastric pain is the visceral pain of the diseased appendix which is referred to the 9th and 10th segments of the spinal cord—the epigastric pain which is often seen as the first symptom of an inflamed appendix.

The intervals between appendiceal dyspeptic attacks are as a rule irregular, and the attacks are neither periodic nor seasonal. Generally in an attack there is a 'deep tender spot' over the appendix.

If in the case of a dyspepsia suspected of being appendiceal there is no characteristically 'deep tender appendiceal spot', the appendix

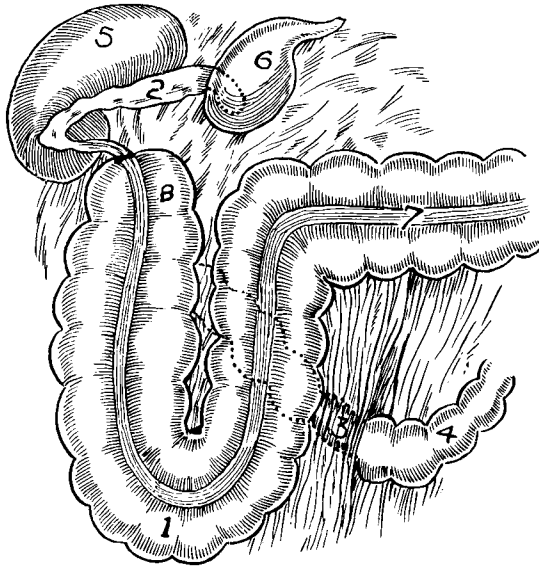


Fig. 41.—Drawing of the actual condition found at operation in the same case as *Fig. 40.* (1) Junction of ascending and transverse colon; (2) Appendix; (3) Terminal ileum retroperitoneally situated; (4) Ileum; (5) Kidney; (6) Gall-bladder; (7) Transverse colon; (8) Cæcum.

should be localized by X rays. Then, perhaps, it will be found that the appendix is not in the usual situation. It may have failed to descend, and be still in the subhepatic region; it may have descended too far and be in the pelvis; or it may be behind the colon. A 'deep tender spot' will then be sought over the abnormal position of the appendix: if it is a pelvic appendix, by making a rectal examination; if it is a subhepatic appendix, by making an examination over the gall-bladder or the kidney region.

Fig. 40 shows the radiograph of an appendix situated under the liver. This appendix when inflamed gave rise to renal symptoms.

In between acute attacks the patient had an appendiceal dyspepsia. *Fig. 41* is an operation sketch of the situation of the appendix.

The patient was tender over the renal region and not over McBurney's point.

In this case the appendiceal dyspepsia may have been caused as much by a chronic obstruction of the ileum, due to an associated developmental defect in its lower end, as by a neuromuscular disturbance due to the inflamed appendix.

In some cases of appendiceal dyspepsia there is no 'deep tender spot', owing to the fact that the inflamed appendix may be retro-cæcal, as, for instance, in the following case:—

A man complained that for years he had suffered from "attacks of indigestion". He said that these attacks would come on suddenly, that he would suffer a certain amount of epigastric discomfort, even pain, which would be indefinitely related to meals. During these attacks he would become constipated. He had no 'deep tender spot'. In between attacks he felt well. What he particularly noticed was that as soon as the attack came on *his tongue became very coated*, and remained so until the attack cleared up. Here was a hard-working man of 40, who suffered from irregular attacks of "acute indigestion", with a background of stable nervous health. Operation disclosed that he had a very long retrocolic appendix, with a bulbous end, which was subacutely inflamed. The patient's dyspeptic attacks completely disappeared after the operation. This patient, therefore, had a typical appendiceal dyspepsia.

To-day the diagnosis of appendiceal dyspepsia is too frequently made. It is made when functional disease of the stomach is the real cause of the dyspepsia. It is not recognized that appendiceal dyspepsia is not very common, and that dyspepsia from functional disorders of the stomach is by far the most frequently occurring dyspepsia. Care is not taken to distinguish the two; therefore many unnecessary appendicectomies for supposed appendiceal dyspepsia are carried out. For this there is no excuse, since appendiceal dyspepsia is clinically a distinctive type which can be recognized, and, furthermore, there is nearly always definite evidence of inflammation, that is, of organic disease.

So-called Renal Dyspepsia.—Where there is a partial obstruction at the renal pelvi-ureteral junction, such, for instance, as that caused by an irregularly shaped stone, painful dyspepsia-like symptoms may coincide with the emptying phase of the stomach. This dyspepsia is probably the result of an increased pressure in the renal pelvis arising from an increased urinary excretion, which occurs after a meal in which there is a copious intake of fluid. The pain is not in the epigastrium, but more in the right hypochondrium. It only

A mild painless dyspepsia is often the first sign of a colonic carcinoma. It is a form of dyspepsia which is often regarded as being caused by early carcinoma of the stomach; and when an X-ray examination of the stomach shows no evidence of gastric carcinoma, no colonic radiograph is made, and a chance of finding an early carcinoma of the colon is lost. It is only when the patient returns with late malignant disease of the colon that the mistake is recognized. Usually in this type of dyspepsia, signs of disease of the colon are present if looked for; occult blood may be found, or, on X-ray examination, a colonic filling defect or evidence of diverticulitis.

CHAPTER X

GASTRITIS AND DUODENITIS

CHRONIC GASTRITIS AS A CAUSE OF SURGICAL DYSPEPSIA

DURING the last few years, the studies of Konjetzny, Nicolaysen, and others have directed attention to a particular form of chronic inflammation of the gastric wall to which they have given the name of chronic follicular gastritis or chronic irritation gastritis. Comparatively little, however, of this type of gastritis seems to have been described in English-speaking countries.

This form of chronic gastritis is a chronic, simple, non-specific inflammatory disease, generally limited to the antrum of the stomach and to the first part of the duodenum. It may be responsible for a painful dyspeptic syndrome, accompanied by hæmorrhages of periodic incidence, which is indistinguishable from that of gastric or duodenal ulcer.

Dyspeptic symptoms arise both on the filling and the emptying of the stomach. As it fills, and the infiltrated antral wall unfolds, only mild dyspeptic symptoms—nausea or discomfort—are felt. As it empties and the infiltrated antral wall is puckered and contracted, very definite symptoms—discomfort and pain—are experienced. Pain coming on two or three hours after food, sometimes relieved by food or by vomiting, is an outstanding feature.

This peculiar form of gastritis is nearly always confined to the pyloric part of the stomach, or to the first and second parts of the duodenum, or to the jejunum in the vicinity of a gastro-enterostomy stoma. Rarely does it involve the whole stomach.

The observations in relation to this type of gastritis have all been made on fresh operation resection preparations, fixed at once in formalin. Changes in the tissues of the gastric wall take place so quickly after death that preparations taken from the stomach at autopsies are of no value.

It is instructive to consider in detail the macroscopic characteristics of this form of gastritis. In the same stomach fresh and older processes of the inflammation are found lying side by side: a fresh infiltrative exudative process, and close by it a chronic reparative and regenerative condition. The mucous membrane may be reddened

and swollen, its folds being broader and deeper than normal. A layer of mucus which cannot be washed off with water may overlie the mucous membrane. In the region of the reddened and swollen mucous membrane small mucous membrane bleedings may be seen. Multiple superficial erosions, covered with fibrinous plaques, are also found. The mucous membrane is thickened and is usually the part of the wall most affected; the muscle and serous layers are only involved in the late stages of the disease. The condition is irregularly distributed in those parts of the stomach which it affects. Irregular wartlike processes are sometimes found. The lymph-glands in the region of the pyloric antrum are usually red and swollen.

The histological picture presents very definite characteristics. The mucous membrane is found packed with large lymph-follicles having germinal centres. The gastric glands are separated from each other by round cells, plasma cells, and eosinophils. The muscularis mucosæ is irregularly fixed and fibrosed. The submucous layer is diffusely scarred, and has dilated blood-vessels.

Types of Gastritis.—Two types of gastritis are usually described: a hypertrophic form and an atrophic form, the latter being a later stage of the disease than the former.

In the hypertrophic form the folds are enlarged. In the atrophic form the furrows between the folds in the stomach may entirely disappear, and the gastric folds become much smaller than the normal. In this stage there may be anacidity. Frequently, however, patches of hypertrophic and atrophic forms of the gastritis are found lying side by side in the same stomach. In the late stages of the hypertrophic type, the gastric wall in the pyloric part of the stomach may be rigid and much thickened. Such a condition sometimes causes a pyloric stenosis. It may also give rise to a rigidity of the prepyloric part of the stomach simulating a carcinoma of the stomach.

Orator and Paschkin go so far as to say that a normal gastric mucous membrane is only rarely met with. Probably the reason for this opinion is that modern pathological material, especially on the Continent, is composed mostly of resection preparations taken from operations; that is, these specimens come from patients who undergo operation always under the suspicion of having some surgical gastric lesion.

As observed by X rays, two stages of this form of chronic gastritis are always described: a first stage, when there is a hypertrophy of the mucous membrane, the rugæ of the stomach being distinctly enlarged and distorted, and the clefts between deepened, with sometimes star-like cavities which, when filled with barium, look like the niche of an

ulcer ; and a second stage, when the rugæ are atrophied, and there are atrophic changes in the mucous membrane.

Schindler, basing his observations on gastroscopic examination, maintains that the alterations in the folds which are taken as evidence of hypertrophic gastritis may be caused by greater muscular contraction of the gastric wall, which would throw the mucous membrane into broader folds.

The Cause of Gastritis.—Konjetzny thinks that the cause of gastritis is some exogenous factor. He does not think it is caused by any form of bacteria.

Aschoff, on the other hand, thinks that it has a biochemical endogenous origin, namely, that it is caused by the action of hydrochloric acid.

Endogenous factors arising from infection, and from the action of toxic and allergic conditions, according to Kauffmann's investigations in hæmatogenous gastritis, may play a part in causing chronic gastritis. He finds that in infective conditions the products of albuminous degeneration can exert a toxic irritative action on gastric mucous membrane. According to his investigations, it may be taken as a fact that, without the accompanying action of bacteria, but through the patient's own body-juices and especially through the degeneration of the body's own tissue, a tissue inflammation can be caused in other parts of the body, and perhaps in the gastric wall.

Gutzeit has drawn attention to the fact that chronic gastritis is frequently found in infections of the gall-bladder.

Öhnell and other Continental authors have regarded some form of vitamin deficiency as a cause ; and there is not wanting evidence that a vitamin deficiency is the cause of inflammation in the mucous membranes of other hollow organs, as, for instance, in the bladder in vitamin-deficiency disease (in China).

Berg is of opinion that the problem of gastritis is wrapped up in some way with the pathology of the whole alimentary tract (gastro-enteritis, etc.) and of the liver and the pancreatic system, probably involving in some way an allergic question.

However, no matter what the cause may be, the various observers—surgeons, endoscopists, pathologists, radiographers—seem to agree on the pathological histological character.

Two instructive cases, which illustrate the late stages of this form of chronic gastritis, are reported by Dr. R. Wanke.¹ They are of especial surgical interest because they show that in these late stages of gastritis an organic pyloric stenosis can develop, or the prepyloric region may become so thickened and enlarged that it forms a tumour

which may be mistaken for a malignant growth. These case reports also show how difficult it is, in a radiological diagnosis, to distinguish this late result of chronic gastritis from a malignant condition.

The first case was a man, aged 40, who had suffered for fifteen years with gastric troubles, which had come on almost every year in the autumn, and which lasted for about four weeks. He complained of crampy pains and heartburn which came on before meals. These sufferings disappeared after taking food. His appetite was good. He had no loss of weight; occasionally he vomited. Between the umbilicus and the right anterior superior spine he had a slight tenderness. Test-meal showed almost an anacidity.

X rays showed a stiff antrum which did not unfold in the normal way; it remained in a permanently contracted condition. (*Figs. 43, 44.*)

At operation there was found in the prepyloric region, more towards the lesser than towards the greater curve and about the size of a half-crown, a firm, not sharply limited,

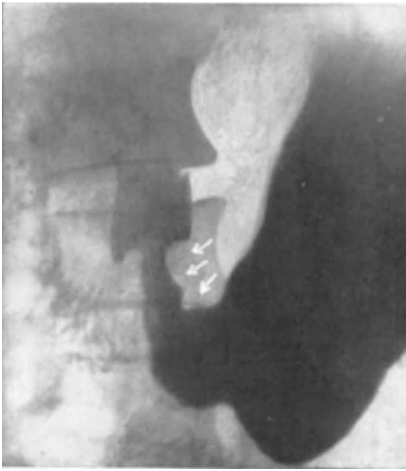

Fig. 43.—Radiograph in chronic gastritis. The arrows point to the hypertrophic pyloric stenosis. (*Figs. 43-47 from the 'Zentralblatt für Chirurgie'.*)

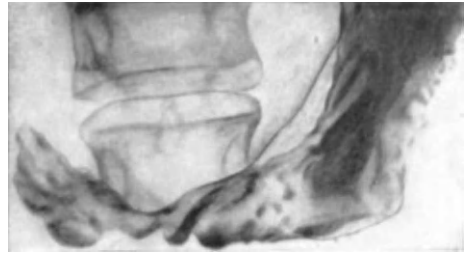


Fig. 44.—Radiograph in same case as *Fig. 43*, showing mucous membrane relief, and the thickening of the mucosal folds in the prepyloric region.

swelling which was at first regarded as a malignant tumour. *Fig. 45* shows the specimen (opened out) which was removed at operation. It comprises the antral and pyloric parts of the stomach. In this preparation there is a contraction of the antral region, which increases towards the pylorus, and the part immediately proximal to the pylorus is organically stenosed. In the mucous membrane of the antrum there are regions of atrophic mucous membrane, and of warty uneven elevations. On the lesser curve, about the height of the isthmus, lies an irregular deepened region about the size of a half-crown, which is partly a superficial swelling and partly a scarred isthmus. The mucous membrane of the fundus is normal.

The histological examination showed a chronic ulcerous antral gastritis with extensive loss of tissue and much disappearance of glandular formation; a submucosa slightly œdematous in the regions of the erosions and ulcerations; much scar formation; and towards the pylorus an increasing hypertrophy and thickening of the muscularis.

The second case was a man, aged 37, who eight years previously had had an operation for appendicitis. Since four years previously he had

suffered from a periodical repetition of stomach troubles. He had a feeling of pressure in the epigastrium one or two hours after meals. His appetite was good. Light food was well borne. He had much eructation, and, during the latter months of his history, almost daily vomiting. In recent months he lost 18 lb. in weight.

On examination, he had tenderness in the epigastrium. Occult blood was found in the stool. Test breakfast showed anacidity. A radiograph (*Fig. 46*) revealed striking deformity of the antrum and some dilatation of the stomach. It showed also on the side of the greater curvature a




Fig. 45.—Specimen removed at operation in the same case as *Figs. 43, 44.*

marked, peculiar, smoothly limited filling defect, and a shortening of the lesser curvature of the antrum.

The operation revealed a peculiar plastic thickening of the stomach wall in the pyloric region and injection of the vessels and swelling of the glands on the greater curvature. The pyloric part of the stomach was removed.

The operation specimen showed a flask-like narrowing of the antral part of the stomach, especially the pyloric part, which appeared contracted and shortened. The stomach wall in this neighbourhood was thickened. The mucous membrane in the antrum and also that of the fundus, so far as this was included in the specimen, was pathologically altered. In the region of the isthmus there was an area about the size of a two-shilling piece which was altered, being partly ulcerated and partly scarred. The mucous membrane of the rest of the specimen had folds which were irregularly swollen, while in the antrum and nearer the pylorus the folds were flatter and thinner (*Fig. 47*).

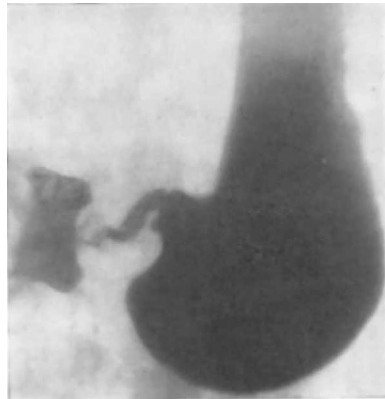


Fig. 46.—Radiograph showing hypertrophic pyloric stenosis on the basis of a chronic gastritis.

The histological examination showed extensive atrophy of the antral mucous membrane. In only a few parts were there remnants of glandular elements. There was a rich round-celled infiltration in the gland follicles, especially in the fundus region. The submucosa was altered in the region of the scar formation. The muscularis became gradually thicker as it approached the pylorus.

A type of chronic gastritis is not infrequently seen as a precedent condition in the formation of chronic gastric or duodenal ulcer. Konjetzny goes so far as to suggest that the chronic gastritis described by him is the basis of chronic gastric, duodenal, or jejunal ulcer.

In my own surgical practice I have frequently operated on patients who had the characteristic symptoms of a chronic peptic ulcer, but in whom, although I always examined carefully the inside of the stomach or duodenum, I could find no trace of ulcer. In most of the cases, however, I observed evidence of gastritis, namely, redness and swelling of the mucous membrane, etc. Many of



Fig. 47.—Resection preparation in same case as Fig. 46.

these patients in the course of time developed a definite chronic ulcer and required a gastric resection or other operation. I feel sure that the chronic gastritis or duodenitis which I found at the previous operation was the basis on which the chronic ulcer developed, but I think that this gastritis or duodenitis was brought about by the action of excessive acidity—the same factor which I believe is the main cause of peptic ulcer.

X-ray Recognition of Chronic Gastritis.—The hypertrophied or atrophied rugæ can be recognized by X rays. A ‘mucous membrane relief’, after the method of Berg, can be obtained by ‘white-washing’ the mucous membrane with a small quantity of colloidal watery solution of barium sulphate, and a study of this relief will show whether the mucous membrane is the subject of chronic gastritis.

The following illustrations, taken from Berg's book,² show the application of this method. *Figs. 48 and 49* show an 'aimed' X-ray

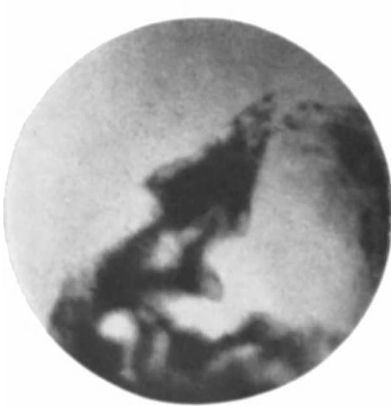

Fig. 48.—Chronic gastritis. (*Figs. 48-50 and 52-55 from Berg's 'Röntgenuntersuchungen am Innenrelief des Verdauungskanals': G. Thieme.*)

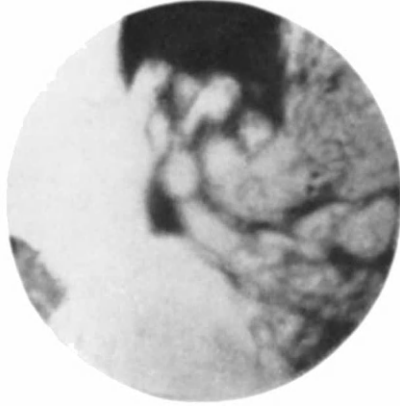


Fig. 49.—Chronic gastritis.

picture taken of the prepyloric region which is affected by chronic gastritis. The preparation of the resected prepyloric region of the stomach is shown in *Fig. 50c*.

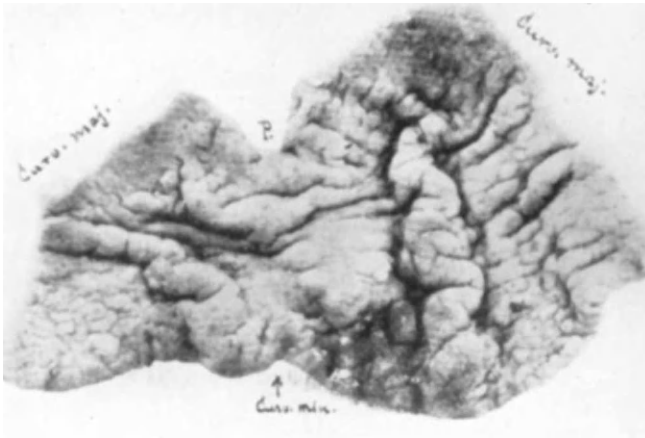


Fig. 50.—Resection preparation of same case as that seen in *Figs. 48 and 49*.

The first two show broad, irregular, swollen mucous membrane folds, with starlike deepening to the right in the field of the picture. They suggest also shimmering of the contrast material. The third

(*Fig. 50*) is the preparation of the antrum and the first part of the duodenum, obtained at operation, which shows the grossly swollen, hypertrophic condition of the mucous membrane. This condition had given rise to symptoms similar to those of gastric ulcer; in fact, the condition was operated upon on the supposition that the patient suffered from a gastric ulcer because the radiograph showed a starlike deepening of the prepyloric region which appeared radiographically to support the clinical diagnosis.

Atrophic Gastritis in Pernicious Anæmia.—From a surgical point of view, it is necessary to appreciate the fact that a severe atrophic gastritis is found in patients suffering from pernicious anæmia; for

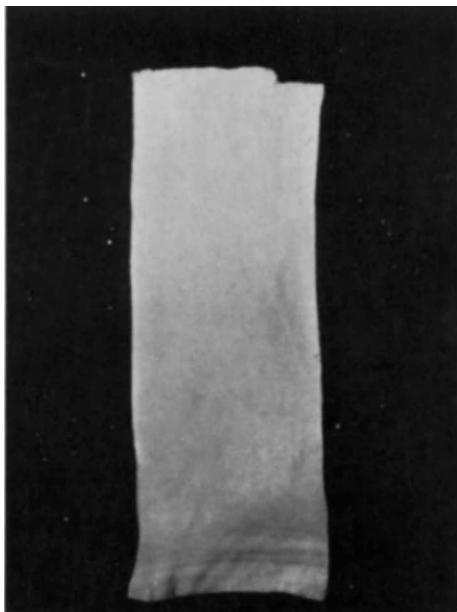


Fig. 51.—Mucous membrane of the stomach in pernicious anæmia, showing atrophic gastritis. (By courtesy of Dr. Wright-Smith, Walter and Eliza Hall Institute, Melbourne Hospital.)

this gastritis is sometimes associated with a form of painless dyspepsia, a constitutional disturbance, and an achlorhydria—a syndrome which is confused with carcinoma of the body of the stomach or carcinoma of the body of the pancreas.

The following case-history (Dr. Wright-Smith) is an example:—

A woman, aged 45, for three years had suffered from weakness, loss of weight, and numbness of hands and legs. She had suffered from much shortness of breath, had fainted several times, and had occasional epistaxis and attacks of vomiting.

The red blood-cells numbered only 1,000,000 per c.mm., and a film showed marked anisocytosis with numerous megalocytes and some megaloblasts. A few small hæmorrhages were found on the optic fundi.

The patient died.

The specimen, *Fig. 51*, shows the condition of the stomach in pernicious anæmia. The gastric wall was thin and the mucosa was quite flat, showing no rugæ. Microscopic examination revealed a considerable degree of atrophy and spoiling of the mucosa.

Thus it will be seen that primary chronic gastritis is an important factor in the diagnosis of a painful surgical dyspepsia.

It is also an important aetiological consideration in the surgical treatment of chronic ulcer.

It is doubtful if it is as common in Australia as it is in Europe.

Gastritis Associated with Gastric Stasis.—Chronic gastritis of secondary origin is sometimes found in stomachs in which there has been a prolonged stasis; as, for example, in the following case:—

A very thin, delicate man of 38 had suffered almost all his life with gastric trouble. He complained of vague epigastric pain about four hours after meals, and now and again of a fainting and weakness followed by pallor. Eventually he vomited a large quantity of blood. No ulcer could be found radiographically. He went through the usual gamut of operations, at one time having his appendix removed, at another his stomach explored. No evidence of ulcer could be found. Sometimes the pain would wake him up at one o'clock in the morning. His free acid was between 15 and 20.

At operation it was found that he had a duodenal ileus. A small piece of gastric mucous membrane was removed, and subsequent microscopic examination showed the presence of extensive chronic gastritis, the mucous membrane being infiltrated with round cells (lymphocytes and plasma cells).

It is in this type of case, with a certain amount of gastric and duodenal stasis caused by congenital disturbance of the autonomic nervous system, that gastritis may be the cause of symptoms, and the explanation of a lifelong dyspeptic syndrome.

Gastritis and Duodenitis Secondary to Chronic Penetrating Ulcer.—In his studies of the mucosal relief pattern in the case of penetrating gastric ulcer, Berg has been able to show that there are extensive alterations of the mucosal pattern in the case of demonstrable penetrating gastric ulcer. These mucosal relief changes become radiographically evident by a broadening of the mucosal folds, a deepening of the furrows between them, and an alteration of their normal direction. The changes are caused by a diffuse gastritis of the hypertrophic type, similar in its radiographic manifestations to

the chronic gastritis of Konjetzny. It is most marked in the region of the penetrating ulcer, but is often found extending over almost the whole of the stomach. It is the result of a secondary infection spreading from the penetrating ulcer.

Berg has also found similar mucosal changes, indicating a duodenitis, associated with penetrating duodenal ulcer.

Fig. 52 is a 'mucous relief' pattern of a stomach in which was present a penetrating ulcer situated about the angulus. It cannot be seen in the picture, but it became obvious when pressure was made on the stomach and an 'aimed' X-ray picture was taken. In this picture it will be noticed

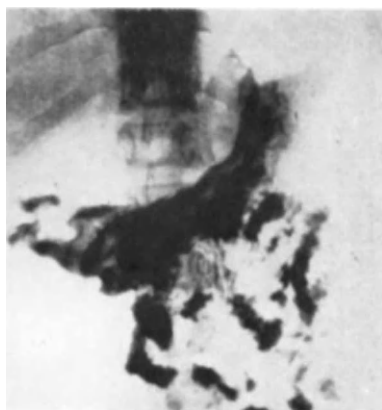

Fig. 52.—Mucous relief pattern of stomach showing gastritis secondary to a penetrating ulcer. (*Figs. 52-56 from Berg.*²)

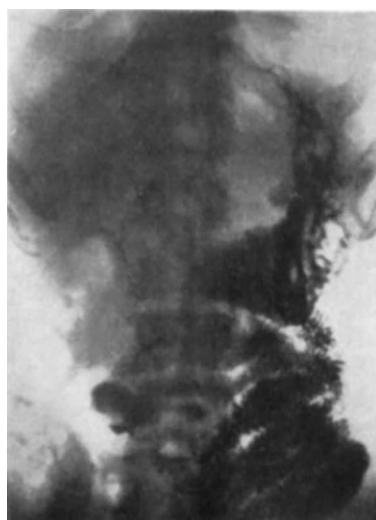

Fig. 53.—Large ulcer niche on the lesser curvature.

that over the whole stomach there is a broadening of the calibre of the folds.

Berg writes that, as these ulcers are medically treated and get better, the mucous folds become smaller; that is, as the ulcer heals, the accompanying gastritis improves. Finally, he observes that the folds return to normal when the ulcer is cured.

In *Fig. 53* (the same case as *Fig. 52*), which was taken before the penetrating ulcer began to heal, a large ulcer niche can be seen on the lesser curvature. Considerable swelling of the folds of the mucous membrane, not only in the region of the ulcer, but throughout the whole stomach as well, is also seen—a definite ulcer gastritis.

The patient was a man, aged 33, who for three months had suffered from strong epigastric pains characteristic of ulcer of the lesser curvature, and who had had no treatment.

Gastritis and Jejunitis following Operations on the Stomach.

—In stomachs in which a gastro-enterostomy has been carried out, it is not uncommon to find in X-ray examination that there is a hypertrophic condition of the membrane—an expression of chronic gastritis—extending over nearly the whole of the stomach. Sometimes this

condition is confined to the gastric and jejunal regions in the vicinity of the stoma, and in these areas it gradually dies

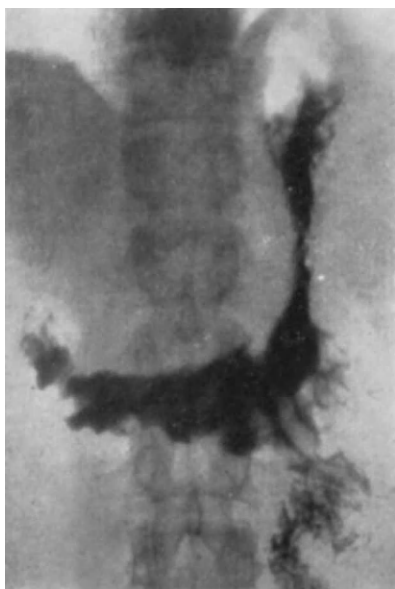

Fig. 54.—Mucosal relief, in a case of gastro-enterostomy, showing great swelling of the mucosal folds, and evidence of chronic gastritis and jejunitis.

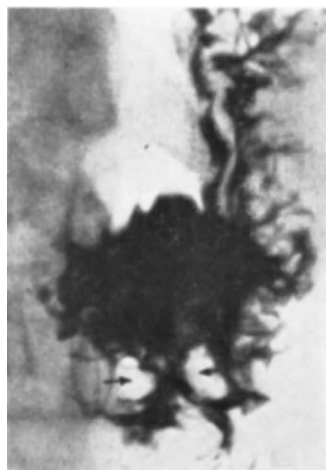

Fig. 55.—Swelling of a gastro-enterostomy ring (indicated by the arrows), showing jejunitis but no fresh jejunal ulcer formation. At operation no jejunal ulcer was found.

away into normal mucous membrane. Much evidence of chronic gastritis and jejunitis has also been found by gastroscopic examination.

These mucous membrane changes are as a rule only found in those gastro-enterostomies where there is a disturbance of emptying. The chronic gastritis and jejunitis which they represent is now regarded by Berg and other observers as the cause of many of the unpleasant symptoms, such as nausea and other symptoms of dyspepsia, which sometimes follow gastro-enterostomy. Some observers of the Konjetzny school regard the condition as a gastritis on which arose the ulcer on account of which the

gastro-enterostomy was performed. They think that the gastritis existed before the gastro-enterostomy.

Others, again, think that it is the result of the gastro-enterostomy ; that it may be due to the action of the regurgitated duodenal contents ; or to the effect of a disturbance of the emptying of the stomach, the result of technical errors in the performance of gastro-enterostomy. I have myself frequently seen this condition in cases of gastro-enterostomy in which the symptoms of jejunal ulcer have been present, but in which no ulcer could be found at operation.

Berg cites an example to show this type of jejunitis. A man, aged 40, was operated upon, two years previously, on account of a duodenal ulcer. A radical resection could not be done because the ulcer involved the common duct, and a gastro-enterostomy was performed. Somewhat similar symptoms to the original pain came on some time after the gastro-enterostomy. The patient was again operated upon, when no jejunal ulcer but an extensive and high-grade chronic gastritis and jejunitis was found. *Figs. 54 and 55* show radiographs in which jejunitis is seen in the neighbourhood of the anastomosis, the anastomotic region and the efferent loop being particularly affected ; and in which are evident broad swollen mucosal folds on both sides of the gastro-enterostomy opening.

DUODENITIS

Aschoff, Büchner, and Knotzke write of an acute peptic duodenitis. Judd, Starr, and Nagel report also observations of duodenitis made at operations. Duodenitis is as a rule limited to the regions in which ulcer usually occurs ; that is, to the first part of the duodenum. Occasionally, however, as Berg points out, it is found extending as far as the papilla of Vater.

X-ray Appearance of Duodenitis.—The macroscopical and pathological histological changes are analogous with those found in cases of chronic gastritis, with which, as has been previously pointed out, it is frequently found in association.

Berg, Cordiner, Calthrop, and others have pointed out the X-ray characteristics of chronic gastritis. There is a veiling of the mucous membrane relief cap by an inflammatory exudate. A broadening and a stiffening of the mucosal folds is also obvious. The hollows intervening between the folds are deepened and show a starlike pattern. The folds are stiffer, and, when they are examined under the screen, it requires more pressure to obliterate them. The folds may show an abnormal direction. Frequently deposits of barium are obtained in the starlike depression

between the folds, and these deposits may simulate a true niche. *Fig. 56*, taken from a paper by G. R. Mather Cordiner and G. T. Calthrop,³ shows a radiograph which is a good example of a case of duodenitis.

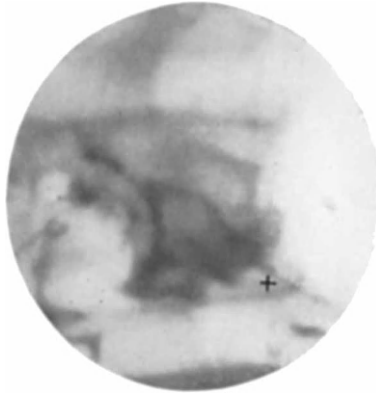

Fig. 56.—Duodenitis. 'Aimed' exposure with 'dosed compression' showing stiffened and broadened mucosal folds. X, Pylorus.
(From the 'British Journal of Surgery'.)

REFERENCES

- ¹ WANKE, R., "Zur Röntgendiagnostik und Therapie der hypertrophischen Pylorusstenose auf dem Boden der chronischen Gastritis", *Zentralb. f. Chir.* 1932, No. 14.
- ² BERG, HANS HEINRICH, *Röntgenuntersuchungen am Innenrelief des Verdauungskanal.* Leipzig: G. Thieme.
- ³ CORDINER, G. R. MATHER, and CALTHROP, G. T., "The Radiography of the Duodenal Cap," *Brit. Jour. Surg.*, 1936, April, 700.

CHAPTER XI
THE AETIOLOGY OF PEPTIC ULCER

It will now be necessary to consider the causation and types of peptic ulcer in order that it may be possible to discuss more intelligently the many dyspeptic patterns which it can originate.

Regarded from a physiological point of view, the first part of the duodenum, where duodenal ulcer occurs, may be considered as a part of the stomach; for it is subjected to the same physiological and pathological conditions as the stomach, and the causation of duodenal ulcer will therefore have the same underlying basis as that of gastric ulcer. The aetiology of gastric, duodenal, and jejunal ulcer may thus be discussed under the one head of peptic ulcer.

The Incidence of Peptic Ulcer.—In a series of 4085 consecutive autopsies performed at the Melbourne Hospital, during the years 1927 to 1936, Wright-Smith¹ found peptic ulceration in 218 cases.

Types.—The types of gastric and duodenal ulcer which Wright-Smith found are set out in *Table I.*

Table I.—TYPE INCIDENCE OF PEPTIC ULCER

TYPE OF ULCER	NUMBER
Acute gastric	10
Subacute gastric	5
Chronic gastric	97
Acute duodenal	3
Chronic duodenal	95
Chronic gastric and duodenal combined ..	8
Total	218

Sex Incidence.—The ratio of males to females was 3.95 to 1.0, as may be seen from *Table II.* The proportion of males to females in the whole series of autopsies was 1.84 to 1.0.

Causes of Death in Peptic Ulcer.—Of the series of 218 cases of peptic ulcer, 85 gastric ulcers were directly responsible for death. Of these, perforation was the cause of death in 33: that is, 30 cases out of 112 cases of gastric ulcer, 10 of which were acute, 5 subacute, and 97 chronic. Hæmorrhage without perforation occurred in 35

Table II.—SEX INCIDENCE OF PEPTIC ULCER

TYPE OF ULCER	MALES	FEMALES
Acute gastric	6	4
Subacute gastric	3	2
Chronic gastric	81	16
Acute duodenal	3	0
Chronic duodenal	75	20
Chronic gastric and duodenal combined	6	2
Total	174	44

cases, 5 of which were acute ulcers. Hæmorrhage severe enough to be the main factor in causing death occurred in 42 cases of gastric ulcer. Duodenal ulcers were responsible for death in 70 of the 218 cases. Hæmorrhage severe enough to be the cause occurred in 20 cases, including 3 with perforation. All the duodenal ulcers were of the chronic variety.

The Distribution of Peptic Ulcer.—Peptic ulcer is found along the lesser curvature, that is, along the gastric canal (*Magenstrasse*); in the pyloric part of the stomach; in the first part of the duodenum; and, in the case of a gastro-enterostomy, in the jejunum at the beginning of the efferent loop, and sometimes, perhaps, on the margin of the stoma. It is also found in the vicinity of the neck of a Meckel's diverticulum, in which there is dystopic gastric mucous membrane, and therefore secretion of acid.

Thus peptic ulcer is found wherever the influence of acid is exerted on a mucous membrane which does not itself produce acid. It is rarely found in the fundal part of the stomach where the acid is produced. (Büchner).

THEORIES OF CAUSATION

The aetiology of gastric and duodenal ulcer cannot yet be said to be clearly established, although recent clinical research has added much to our knowledge in this respect.

There are three theories in regard to the causation of peptic ulcer.

The first, which may be called 'Virchow's theory' (1853) or the 'infarction theory', postulates a primary local or general lowering of the vitality of the gastric wall. It is thought that the local devitalization, which may take place through circulatory or infective disturbances in the blood-vessels of the stomach, allows autodigestion of the devitalized tissue to take place, with a consequent loss of substance which constitutes an *acute peptic ulcer*. It is thought that out of this

acute ulcer, as a result of various forms of irritation and secondary infection, a chronic ulcer may develop.

The second theory, which may be termed the 'chronic gastritis theory', was advanced by Konjetzny, Kalima, and Puhl, from the surgical clinic in Kiel. These observers believe that a subacute or chronic gastroduodenitis, exogenously caused, is the basis on which peptic ulcer develops. They think that chronic ulcer is merely an extension of this condition, a complication of a gastritis which should really be called 'ulcerative gastritis'.

The third theory, which may be termed the 'acidic theory,' or the theory of the peptic genesis of ulcer, has in recent years been prominently brought forward by Continental and American observers. These workers do not believe that gastric mucous membrane possesses a protection against the digestive capacity of gastric juice, and that the development of an ulcer requires a lowering of vitality in areas of the gastric wall. They believe that an ulcer can develop in the stomach or duodenum from the effects of the gastric juice alone. They think that ulcer is caused by a disturbance of the gastric secretory conditions. According to this acidic theory, peptic ulcer is primarily due to biochemical conditions, to the excessive action of acid gastric juice; and chronic peptic ulcer, in its very beginning, arises from continued and excessive corrosive and irritating action of the acid gastric juice.

These three theories involve widely different conceptions of the surgical treatment of peptic ulcer, and for that reason must be carefully considered.

Infarction Theory.—The infarction theory was advanced by Virchow, and in 1926 elaborated by Hauser.² According to this view, chronic peptic ulcer occurs in the following way. An acute ulcer, which is a loss of substance of the gastric mucous membrane, is first formed. A small area of the gastric wall becomes partially devitalized by local infection or vascular metastatic infection; or it becomes devascularized by some arterial deficiency. Such an area thus loses its normal circulation—its vitality—and therefore some of whatever property gives the gastric wall immunity from the digestive juice. It is then capable of being digested by the gastric juice; and the clean-cut, thin-edged, funnel-shaped ulcer which we know as acute peptic ulcer is the result of this local digestive action. From this acute ulcer, by the irritative action of food, of peristalsis, of gastric stasis, or the result of the advent of secondary infection, chronic ulcer forms.

It is thought, on good clinical grounds, that in a majority of cases these acute ulcers are complications of a general or focal sepsis. It

is supposed that the organisms gain access to the systemic circulation from infected teeth, infected nasal sinuses, or infected tonsils; and to the portal circulation from chronic appendicitis, chronic cholecystitis, or other infections of the portal system. These organisms lodge in a gastric arteriole, and infect and partially devitalize an area of tissue in the gastric wall corresponding to the arteriole. Auto-digestion of this area then naturally follows, and an *acute ulcer*, sometimes called an infective ulcer, results. And in support of this we know that the macroscopic appearance of an acute ulcer differs from that of a chronic ulcer in that it shows no evidence of inflammation, having no thickened inflammatory edges.

Instead of a local devitalization of the gastric wall general devitalization may occur as part of the general disease. Under such circumstances a patchy autodigestion, which begets multiple acute ulcers, may take place. Multiple acute gastric or duodenal ulcers of this nature are often seen in autopsies on patients who have died as a result of diseases with a general effect such as nephritis, portal cirrhosis, acute infectious conditions, and the various forms of anæmia (*Fig. 57*).

Although nowadays much doubt attaches to the soundness of this infarction theory, we must, as surgeons endeavouring to cure patients of peptic ulcer, give it consideration; for the two main factors in the causation of acute ulcer that it postulates are a sensible and practical basis for the medical as well as the surgical treatment of acute and, to a lesser extent, of chronic ulcer. For example, in treating peptic ulcer, we must look not only for infective and devitalizing conditions as a cause, but also for excessive digestive action of the gastric juice—that is, for a hyperacidity.

Objections to the infarction theory of the formation of peptic ulcer, however, have been advanced by many workers, and principally by Aschoff, Büchner, and Lindau. These observers point out that:—

1. It is almost impossible to produce a chronic ulcer experimentally from an acute ulcer.

2. If infection were the primary cause, then all the coats of the gastric wall should be involved at the same time; but, as a rule, only the mucous coat is found to be affected.

3. It has never been possible histologically to demonstrate any actual infection.

4. It has never been possible to establish any definite relation between the vascular distribution and the ulcer area.

If, however, a deficient resistance in the gastric wall does not play a part in the formation of peptic ulcer, it is difficult to explain the

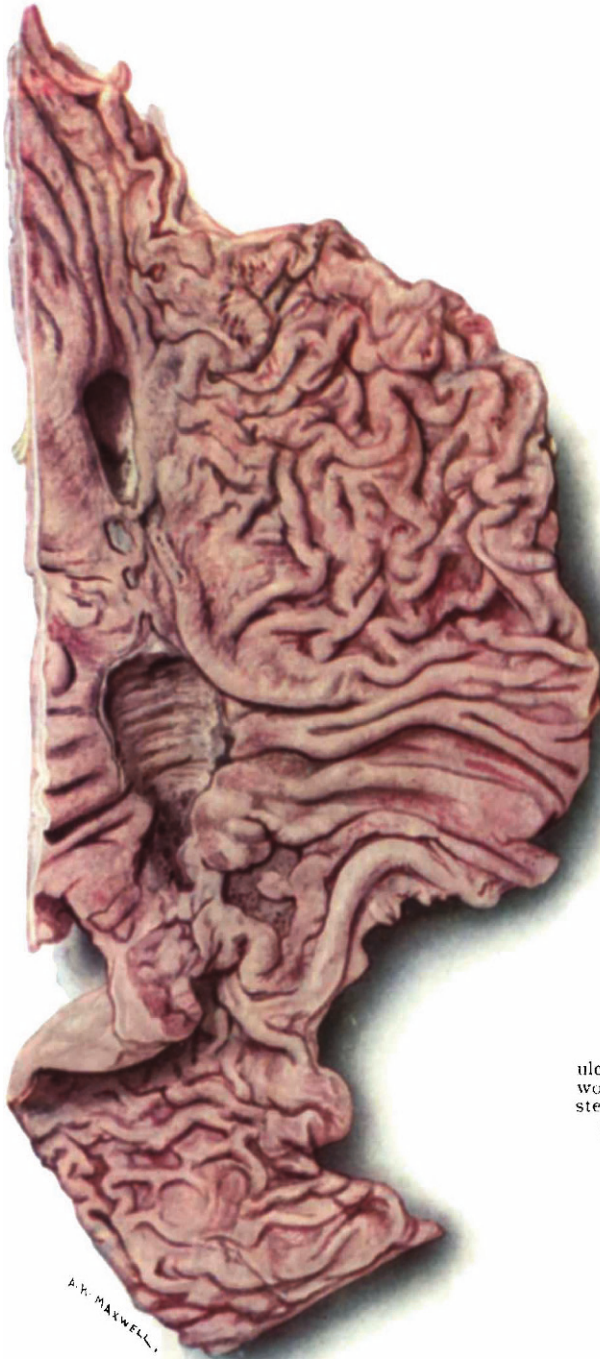

Fig. 57.—Multiple gastric ulcers found post mortem in a woman who died from mitral stenosis and granular kidneys.
(From the
'British Journal of Surgery'.)

A. H. MAXWELL.

formation of the peptic ulcer which occurs in such tumours of the stomach as lipoma, sarcoma, or myoma. In these tumours I have invariably found an ulcer on that part of the surface which projects most into the lumen of the stomach, and which therefore is most exposed to the action of acid. The tissue of these tumours is undoubtedly deficient in blood-supply and therefore in vitality, and I feel sure that this deficiency is the primary cause of the ulcer. I have always regarded this observation as evidence that a deficient resistance in the gastric wall tissue must be an important factor in the formation of peptic ulcer.

The Chronic Gastritis Theory.—The theory that a gastritis is the primary cause of peptic ulcer was advanced by Konjetzny, Kalima, and Puhl.³ These authors carried out examinations of the gastric mucous membrane in cases of ulcer, and made microscopic studies of the resected specimens. In these they found inflammatory changes in the mucous membrane which began as an acute or subacute gastro-duodenitis with disturbances to the surface epithelium. They found various grades of inflammation lying side by side, and superficial erosions which eventually formed small ulcerations. These erosions were inflammatory and did not depend on the effects of the gastric juice or upon any primary circulatory disturbance. They showed a marked tendency to heal, and when they did so, they left behind them an atrophic scar in the mucous membrane. Sometimes an erosion broke through into the submucosa, and thus gave rise to a typical peptic ulcer.

These authors were able to show illustrative specimens of the various stages of development of an erosion into a chronic peptic ulcer. They regard peptic ulcer as merely a complication of chronic gastritis, and the gastritis on which it forms as an *ulcerative gastritis*.

The Acidic Theory.—Büchner has shown that a peptic ulcer can develop in the stomach or duodenum from the effect of gastric juice alone. According to him, the gastric mucous membrane possesses no protection against the digestive action of gastric juice. He does not think that the development of an ulcer requires a lowering of the vitality of a certain area of the stomach.

Büchner and his co-workers base their assertion that peptic ulcer is due solely to an acidic condition on the following observations:—

1. By pouring 1·5 per cent hydrochloric acid into the stomach of cats, they could produce an erosive gastritis and defects of substance in the gastric mucous membrane.

2. By using hypodermic injections of histamine, which stimulate the production of gastric juice, they caused ulcers to develop in the

pyloric part of the empty stomach of fasting animals. In all these experiments ulcers developed in the pyloric part of the stomach, never in the region of the acid-producing glands. Büchner therefore regarded this fundal area which produced the acid as peculiarly immune to its irritative action.

3. They demonstrated peptic ulcer in cases of Meckel's diverticulum in which there was dystopic gastric mucosa histologically analogous with the fundal mucosa of the stomach, and in which there was therefore secretion of acid.

In these cases the peptic ulcer was found only at the neck of the diverticulum, never in the dystopic gastric mucous membrane. It was also of the typical chronic round type (*Fig. 58*).

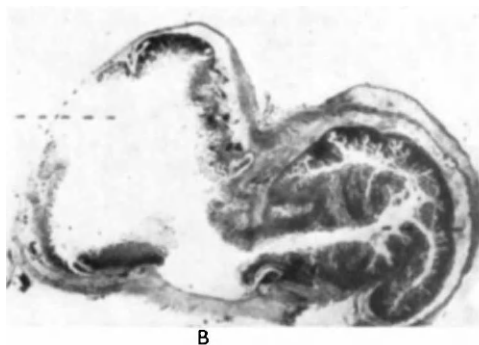

Fig. 58.—Section through a Meckel's diverticulum which contained dystopic gastric mucous membrane. A peptic ulcer (E) was found at the neck of the diverticulum. A, Ileum; B, Callous ulcer situated in ordinary intestinal mucosa at the neck of the pouch; C, Meckel's diverticulum lined by hyperplastic mucosa of fundic type. (*From 'Surgery, Gynecology and Obstetrics'.*)

Büchner's observations have been recently confirmed by Lindau.⁴

Mann experimentally confirmed the peptic genesis of ulcer. In dogs, he isolated the papilla of Vater and transplanted it into the lower part of the ileum. Thus he prevented the alkaline duodenal contents, which have not only a neutralizing effect on the gastric contents but also a diluting action, from reaching the stomach and upper part of the duodenum. He found that typical chronic ulcers similar to those occurring in man developed in the stomach and upper part of the duodenum. When the papilla of Vater was sutured back into its original situation in the duodenum, the ulcers healed at once.

Dragstedt⁵ carried out experiments which are also illuminating as evidence in favour of the peptic genesis of ulcer. He found that if living tissues are exposed to the pure effect of undiluted gastric secretion, they will succumb to its digestive action. He found that organs

such as the spleen and the kidneys, when implanted into the wall of the normal stomach of an animal and thus exposed to the usual action of gastric contents, remain little affected. If, however, they are implanted into the wall of an isolated gastric pouch and thus exposed to the action of undiluted gastric contents, they are promptly digested. He found that this undiluted secretion from the fundus of the stomach could digest the normal mucosa of the stomach itself, and that the resultant defect displayed all the features of a chronic ulcer in man. Thus, according to this observer, the reason why the stomach does not digest itself under normal conditions is owing to the fact that it is



Fig. 59.—Fibrinoid necrosis, the basis of a beginning ulcer.
(*Figs. 59, 60 from Aschoff's 'Pathologische Anatomie'.*)

protected from the digestive action of the gastric juice by a process of dilution and neutralization. Gastric juice is diluted by swallowed food and fluid and by saliva, by the secretion of mucus from the pyloric antrum. It is neutralized—buffered—by the protein of food, and by regurgitations of alkaline duodenal contents. A failure in dilution or in neutralization exposes the stomach to the action of undiluted gastric juice, and therefore to the formation of a peptic ulcer.

Dragstedt also showed by experiments on a frog's legs that the digestive activity of gastric juice depended upon the percentage of hydrochloric acid. Below 0.15 per cent of free hydrochloric acid, gastric juice did not affect living tissue. When, however, the acidity of the juice exceeded 0.15 per cent, living tissue was digested. In this respect it is significant, Dragstedt points out, that the free acidity

of the normal gastric contents of man rarely exceeds 0·15 per cent (42 clinical units), except in those patients who suffer from peptic ulcer.

Aschoff also believes that peptic ulcer is formed solely on an acidic basis. He thinks that the corrosive effect of acid juice is concentrated by peristaltic action on certain susceptible regions of the stomach. He is firmly convinced that no primary damage to the gastric wall is a necessary prelude to the formation of peptic ulcer.

According to this author, a peptic ulcer begins as small hæmorrhagic erosions limited to the pyloric part of the stomach, or to the duodenum—they never occur in the fundal part. In association with

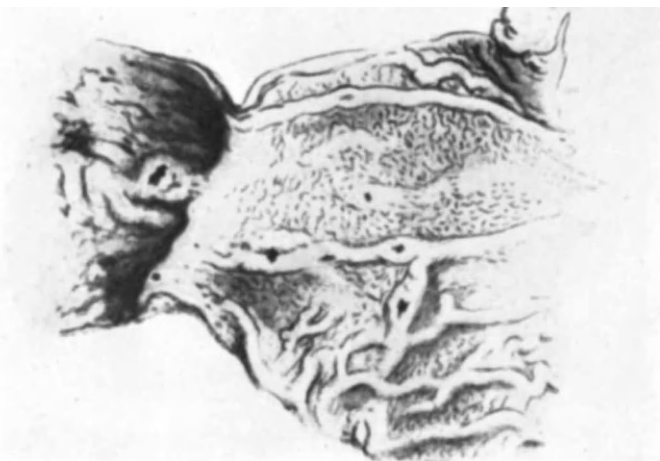

Fig. 60.—The distribution of erosions on the folds of the stomach.

these erosions are often seen large mucous membrane erosions which are situated either on the *Magenstrasse* or on the pyloric canal. A low-power section of one of these hæmorrhagic erosions (*Fig. 59*) shows that in its early stages it is a patch of fibrinoid necrosis, probably caused by the erosive action of acid. Aschoff finds that these minute erosions are situated on the folds of the stomach, where the effect of the acid gastric juice would be greatest (*Fig. 60*).

To understand Aschoff's and Büchner's point of view in relation to the origin of gastric and duodenal ulcer, it is necessary to follow their conceptions of the anatomy and physiology of the stomach.

The stomach is divided into a number of gland zones, which are histologically and biologically heterogeneous. From the view-point of anatomy and physiology, the upper part of the duodenum belongs to these and is in series with them. Aschoff has coined the term 'gastral systems' for these parts of the digestive canal. *Fig. 61*

shows the stomach slit along the greater curvature and opened out so as to show these regions, while *Fig. 62* shows a sagittal section

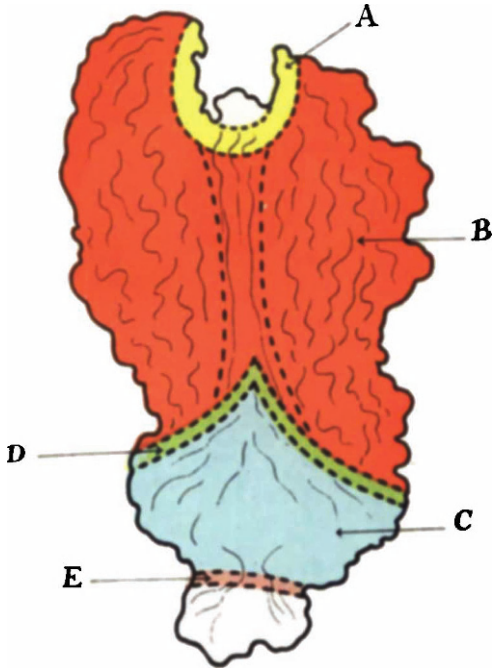


Fig. 61.—Gland fields in the human stomach.

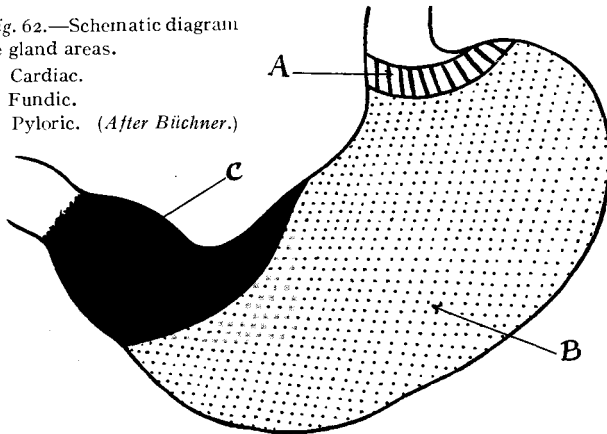
- A, Cardiac.
- B, Fundic.
- C, Pyloric.
- D, Intermediate.
- E, Pylorus.

(After Aschoff.)

of the stomach with the regions indicated. Beginning from the œsophagus, the following zones come in turn: (1) the narrow zone

Fig. 62.—Schematic diagram of the gland areas.

- A, Cardiac.
- B, Fundic.
- C, Pyloric. (After Büchner.)



of the cardiac glands; (2) the zone of the fundal glands; (3) the zone of the pyloric glands; (4) the duodenal mucous membrane.

The zone of the pyloric glands reaches much higher up on the lesser curve than on the greater curve (*Figs. 61, 62*).

In the fundal zones are situated the cells which produce hydrochloric acid and pepsin. In the pyloric zone is secreted an alkaline or neutral mucus. In the narrow intermediate zone are found glands of both fundal and pyloric types.

Büchner and Aschoff believe that the mucous membrane in the fundal zone, where the acid is produced, is more resistant to its erosive action than the mucous membrane in the pyloric part or in the duodenum. They believe that the farther away the mucous membrane

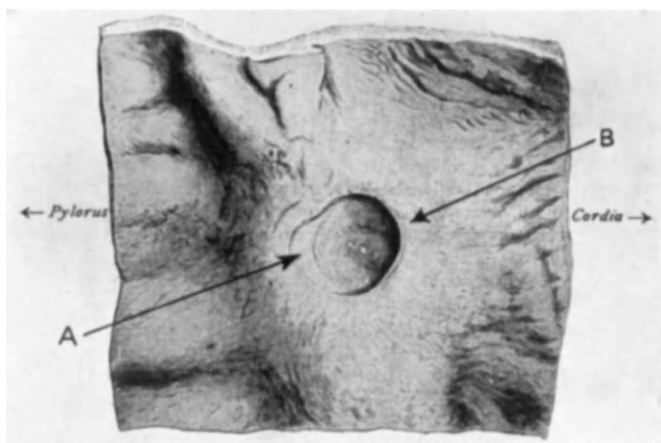


Fig. 63.—A. The shelving edge of the ulcer; B, The overhanging edge, which does not receive the force of the peristaltic wave of acid gastric juice. (*Figs. 63, 64 from Aschoff's 'Pathologische Anatomie'*.)

is situated from the fundal mucous membrane, the less natural resistance it has to the erosive action of acid.

Aschoff's observations show how these erosions in the pyloric and duodenal zones, which are less resistant to acid, gradually develop into ulcers. The erosions, even those which have become small ulcers, situated on the mucous membrane of the body of the stomach heal; but the erosions in the pyloric canal or along the *Magenstrasse*—regions in which the effect of the acid is concentrated by peristaltic action—develop into small ulcers. These ulcers continue to increase in size from the continued action of the acid. The distal part of the ulcer, where from peristaltic action the wave of acid gastric juice impinges, becomes shelving; and the proximal edge of the ulcer, where it is protected to a certain extent from the action of the acid, becomes overhanging (*Fig. 63*).

Orator has shown that peptic ulcer is invariably found in the gastric canal or in the first part of the duodenum, and Aschoff explains this clinical observation in the following way. In the gastric canal the mucous membrane is firmly fixed to the gastric wall. A consequence of this is that an erosive wound in this situation gapes, and therefore exposes its base, unprotected by mucous membrane, to the continued erosive action of the acid gastric juice. In the case of

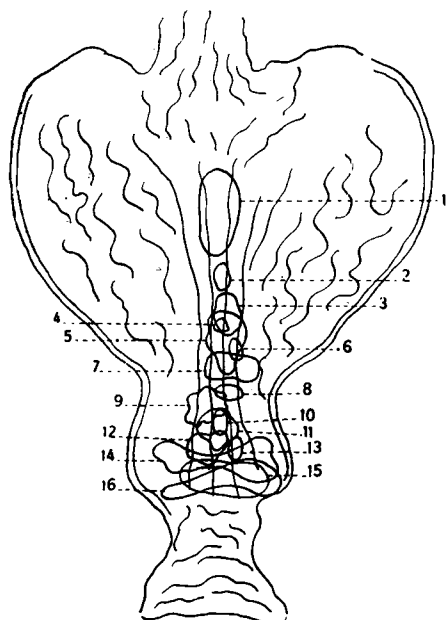


Fig. 64.—Showing the situation of gastric ulcers on the *Magenstrasse* (gastric canal). The numbers indicate the incidence of ulcer in this area.

the erosion on the body of the stomach, the mucous membrane of which slides easily on the muscular gastric wall, the mucous membrane does not gape, but closes over the erosion, and protects it from the further action of the acid gastric juice. Thus the ulcers on the *Magenstrasse* remain as chronic ulcers, while those on the pyloric part—the body of the stomach—heal. (Fig. 64.)

Hence it is seen that, according to the theory of Büchner and Aschoff, in contrast to the infarction theory, peptic ulcer is chronic practically from its commencement.

Aschoff's hypothesis also affords an explanation of the reason why peptic ulcers are

usually found on the gastric canal. I have only seen one case of chronic peptic ulcer of the fundus of the stomach.

Clinical Evidence.—There are many clinical observations which confirm the acidic genesis of ulcer.

The very chronic form of duodenal ulcer is always associated with a high acidity.

Jejunal ulcer nearly always follows a gastro-enterostomy performed for the chronic type of duodenal ulcer, which is usually accompanied by a high acidity, and in which this acidity still remains high after the gastro-enterostomy.

Jejunal ulcer (not marginal ulcer) formed in a few of my cases for the first time after a lapse of fifteen to twenty years after a

gastro-enterostomy, and these ulcers could only have been brought about by the erosive action of gastric acidity.

I have observed that a gastric acidity can produce a jejunal ulcer in circumstances where previously there had been neither a gastric nor a duodenal ulcer; that is, in physiological conditions which could not cause the formation of the ordinary type of peptic ulcer. Two patients, who had no evidence of duodenal or gastric ulcer, had gastro-enterostomies performed on them. With the gastro-enterostomy in each case was combined a pyloric occlusion made by tying the pylorus with silkworm-gut. Thus the whole of the acid gastric contents were thrown upon the jejunum. In each case a chronic jejunal (not marginal) ulcer formed. Obviously there was no predisposing condition of the jejunal mucous membrane, and jejunal ulcer must have been caused by peptic action. Incidentally this observation also showed that the mucous membrane of the jejunum was not as resistant to the action of acid as that of the stomach or duodenum.

That there may be low values of acidity associated with the formation of gastric ulcer is explained by the fact that there are other important factors which contribute to the acidic causation of gastric ulcer. One of these is that prolongation of the action of low acidity on tissues has the same effect as a short exposure to high acidity. Thus pyloric spasm or stenosis can prolong acidic action on the gastric mucous membrane, not only by the stimulation of the retained food causing continuous secretion of gastric juice, but also by permitting a long-continued action of this acid juice on the gastric wall.

There is another clinical factor which may have a bearing on the acidic genesis of ulcer—the action of a pathological disturbance of secretion on the empty stomach. In some individuals a continued secretion occurs pathologically during the resting phase of the stomach. When this happens, pure undiluted juice, not necessarily of a concentration higher than normal, may act on the gastric wall in the empty stomach, and we know that pure undiluted and therefore unbuffered normal gastric juice can produce erosion of the gastric mucous membrane (Dragstedt).

THE PRACTISING SURGEON AND THESE HYPOTHESES

It will be seen that in relation to the causation of peptic ulcer there are three well recognized theories: (1) That some lowering of the vitality of the gastric wall is a necessary preliminary to the formation of ulcer; (2) That ulcer arises on the base of a chronic gastritis; (3) That acid is the primary and sole cause of ulcer.

It has been necessary to discuss the cause of peptic ulcer in detail, because the experimental evidence and clinical observations from which deductions as to the cause of ulcer have been made can be valuable guides in its treatment. Although these causation theories seem so different, it is, however, not impossible to reconcile them. Regarding chronic gastritis as of acidic origin (Aschoff's view), we may consider that gastric or duodenal ulceration can be brought about by variation of the two great factors which must be concerned in the formation of ulcer, namely, the vitality of the gastro-duodenal wall, and the concentration of the gastric acidity. A high acidity and a normal vitality of the gastro-duodenal wall can cause an ulcer that might be termed an *acidic ulcer*. A normal acidity and a defective vitality of the gastro-duodenal wall can originate an ulcer that might be called an *infective ulcer*. Both ulcers may have the same macroscopic appearance, but the factors in their causation are different. For practical purposes, we might regard the problem of the formation of peptic ulcer in much the same way as the occurrence of an infective condition: that either a virile germ combined with normal resistance, or an unvirile germ combined with a weak resistance, may give rise to an infective condition; in each case the infective state is much the same, but the main causative factor is different.

The following important practical points therefore emerge from the above discussion on the aetiology of peptic ulcer:—

1. Treatment.—For the purposes of surgical treatment of peptic ulcer, and notwithstanding the arguments advanced by Continental observers against an infective cause, the surgeon must assume the possibility that an infective vascular or a metabolic local devitalization of the gastric wall may have been an original cause of the formation of chronic ulcer. The practising surgeon has had ample evidence of the infective basis of ulcer; he has, for example, seen acute ulcer and its bleeding as a complication of acute appendicitis. The acute ulcer, too, that he finds in this condition is, as a rule, a loss of substance only; it shows no evidence of chronic inflammation. It never looks as if caused by the chronic irritation of acid.

Thus, when operating for chronic gastric ulcer, the surgeon should, on the basis of this theory, search for and remove any infective focus; and should deal with coincident disease which may have contributed to a lowering of the vitality of the gastric wall.

2. The Type of Operation to be Employed.—In designing the nature of his operative interference, the surgeon will accept the consensus of modern opinion that ulcer is due to peptic influence, that is, to the abnormal action of acidity. Therefore, if the acidity is high,

the surgeon must employ operations such as partial gastrectomy, partial gastrectomy with exclusion, or extensive partial exclusion—operations which can be depended upon to reduce the percentage of acidity adequately.

Furthermore, the surgeon must accept the acidic theory to the extent that, in cases of duodenal ulcer associated with high acidity, he will not employ an operation such as gastro-enterostomy, which cannot adequately reduce the acidity, and which therefore not only cannot cure a duodenal ulcer, but may actually beget a new one—a jejunal ulcer—much more dangerous than the original duodenal ulcer.

3. The Ulcer may be only a Local Sign of General Gastric Disease.—Accepting provisionally the theory of ulcer gastritis the surgeon will keep in mind that the chronic gastric ulcer on which he may be going to operate may be only a manifestation of chronic gastritis. He will therefore never perform a gastro-enterostomy in cases where he suspects, from the history and the appearance of the mucous membrane, that an ulcer has arisen on the basis of a chronic gastritis. He will in such cases be more inclined to perform partial gastrectomy so as to remove the gastritic area.

4. Diagnosis.—Recognizing that a chronic gastritis, whether of acidic or of other origin, may precede the formation of peptic ulcer, the surgeon will know that a certain pattern of surgical dyspepsia, which would be indicative of chronic gastric ulcer, may possibly be due to a chronic gastritis.

Thus, he will be able to understand the absence of the signs of peptic ulcer in the presence of symptoms indicative of ulcer.

Having discussed the causation of gastric ulcer, and its relation to ulcer gastritis, and having seen the difference between acute ulcer and chronic ulcer, we are now in a position to resume our discussion of surgical dyspepsia.

REFERENCES

- ¹ WRIGHT-SMITH, R. J., Peptic Ulcer: An Analysis of 218 Cases Studied at Autopsies," *Med. Jour. of Australia*, 1937, Dec. 11.
- ² HAUSER, *Handb. d. spez. path. Anat. u. Histol.* (Henke-Lubarsch), 1926, 4.
- ³ KONJETZNY, *Ergebn. d. inn. Med. u. Kinderh.*, 1930, 37.
- ⁴ LINDAU, ARVID, and WULFF, HELGE, "Peptic Genesis of Gastric and Duodenal Ulcer, etc.," *Surg. Gynecol. and Obst.*, 1931, Nov.
- ⁵ DRAGSTEDT, L. R., *Ibid.*, 1932, Sept.
- ⁶ ASCHOFF, LUDWIG, *Pathologische Anatomie.*

CHAPTER XII

THE DYSPEPSIA OF ACUTE GASTRIC ULCER

As a matter of practical experience, acute ulcer is usually found in patients in whom there is a lowering of the vitality of the gastric or the duodenal wall.

Acute Ulcer arising from a General Cause.—Acute ulcer is seen in general infective states ; in circulatory deficiencies, as in patients with congestive failure, and in the late stages of arteriosclerosis ; in leukæmias and anæmias ; in renal and hepatic insufficiency, where the excretion of autogenously produced toxins spoils the tissue of the gastro-duodenal wall ; and in many other general devitalizing conditions. Acute ulcers found in such conditions are usually multiple.

Acute Ulcer arising from a Local Cause.—Where an acute ulcer is attributable to some local infection, such as acute or chronic appendicitis or cholecystitis, it is often single, but may be multiple.

Thus, a patient with such an acute ulcer may require surgical treatment for a local infection, such as a chronic appendicitis or cholecystitis which has caused the ulcer or ulcers ; but a patient with acute ulcers from a general cause will require management for his general condition—that is, he will need medical attention.

Furthermore, an acute ulcer arising from a local cause may demand surgical treatment where it gives rise to a profound and incessant hæmatemesis ; and if in such an emergency a partial gastrectomy was considered as a therapeutic measure, it would not be based on unsound principles. The rationale of this is that the gastric wall, except in the vicinity of the ulcer, would be healthy ; but in the case of multiple acute ulcers from general disease, the whole gastric wall would be unhealthy—the patient would not be suffering from a local disease.

Acute Ulcer on the Scar of a Healed Chronic Ulcer.—From the surgical point of view there is also another aspect to the single acute ulcer—the question of the surgical treatment of bleeding from an acute ulcer forming on the scar of a healed ulcer. It not infrequently happens that acute ulcer arises painlessly in the lowly vitalized scar of a healed chronic ulcer large enough to be unprotected by

prolapsing mucous membrane (*see* p. 114). Bleeding from such an acute ulcer must be treated on the same lines as bleeding from a chronic ulcer, for acute ulcer arising in this way may keep on recurring and bleeding until the devitalized spot is resected. Thus the principles underlying the treatment of such an acute ulcer should be the same as in chronic ulcer.

Operative Appearance of Acute Ulcer.—Macroscopically, an acute ulcer appears to be merely a localized loss of substance; neither its edges nor its base are infiltrated with inflammatory cells as in chronic ulcer. Therefore at operation it cannot be felt by external palpation of the stomach, and it does not indicate its presence by injection of vessels, redness, or other signs of inflammation. The only way the surgeon can demonstrate the presence of an acute ulcer is to open the stomach and examine the mucous membrane.

The Dyspepsia of Acute Ulcer.—As in acute ulcer there is very little inflammatory infiltration and therefore practically no stimulus to the tension receptors of the wall of the stomach, it does not give rise to pain. Thus its syndrome does not come into the category of the painful or surgical dyspepsias, although, strictly speaking, some aspects of acute ulcer are of surgical importance.

Sometimes acute ulcer gives rise to a mild painless dyspepsia, but often a profound bleeding or a perforation is the first sign of its presence.

A dyspepsia caused by a chronic appendicitis or cholecystitis may be an accompaniment of acute ulcer.

The investigation from a surgical point of view of an acute ulcer, usually a concern of the physician, involves the following: a discrimination in regard to its causation; the elimination of general disease as a cause; the search for the symptoms and signs of an infective focus; the question of the symptoms of a surgical chronic ulcer in the previous history—that is, whether or not the acute ulcer has formed on an old scar. However, in the majority of cases of acute ulcer there is no history of a removable infective focus or of the presence of a previous chronic ulcer, and thus the treatment is usually medical rather than surgical.

The following are examples of cases of acute ulcer:—

The first case is that of a man, aged 38, a very hard worker, and unmarried, who was *perfectly well* until he contracted influenza. One week later he developed a slight indigestion; his appetite became capricious, and he was too sick to work. A few days later he got a profound, alarming hæmatemesis, which was succeeded by three other severe attacks, until finally he became very ill and in danger of death. He had no 'deep tender spot'.

In this case, the attack of influenza—an infective origin—the complete absence of any previous dyspepsia, the painless character of the dyspepsia, and the profound hæmatemesis, are the features to be noted.

Ten years later this man was well and had had no recurrence of bleeding.

The second case is that of a man, aged 45, who had a gastric ulcer resected but had not had a gastro-enterostomy combined with the resection. This man developed an attack of acute gangrenous appendicitis. Nine days after this attack he had a profound hæmatemesis. Presumably the bleeding was a complication of an acute ulcer arising probably on the scar of the resection, and as the result of infection—an 'infective acute ulcer on a scar basis'.

Perforation in Acute Ulcer.—In practically all the cases upon which I have operated for a perforated gastric ulcer, I have found that the patient has had no previous painful dyspepsia; that is, he has had no clinical indication of a chronic ulcer prior to the perforation. And I have regarded this as evidence that the majority of gastric perforations have occurred in acute or subacute ulcers.

At operation, however, I found in most of these cases what appeared to be a chronic ulcer. There was a fair amount of inflammatory thickening around the edge of the perforation, but it was that degree of infiltration of subacute or mild chronic ulcer the stimulation of which was not adequate to produce pain. Thus I felt that this reasoning explained why the symptoms were those of acute ulcer, while the operation findings were those of chronic ulcer.

In other cases I thought that this type of infiltration might be the result of a secondary infection arising in an acute ulcer, and that probably the perforation coincided with the advent of this secondary infection. Of special interest in this regard—that is, to the actual determining cause of a perforation—is a recent account of a series of histological examinations made by Puhl and Schmidt¹ in resection specimens of perforated ulcers which were immediately fixed in formalin. As changes in gastric tissue take place very quickly after death, observations made from post-mortem specimens are not reliable, and few pathological examinations have been made on fresh operation specimens of perforated gastric and duodenal ulcers. The main findings of these authors were that at the edge of the perforation and in its vicinity there was a zone of dying tissue, which did not take the stain very well, in which the nuclei were undergoing disintegration, and in which all the connective tissue was swollen. This zone was succeeded by one of leucocytic infiltration, obviously a zone of tissue with reactionary changes brought about by the effect of the zone of dying tissue, which could only be caused by the

erosive action of the gastric juice (*Fig. 65*). The importance of these investigations is that they show that a secondary inflammatory process is not the cause of a perforation, but that this is due to the action of the erosive gastric juice.

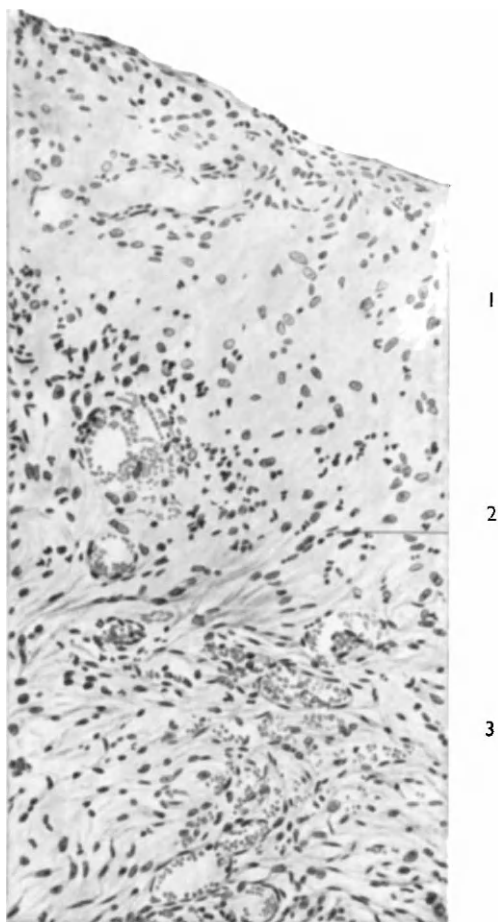


Fig. 65.—High-power drawing of section taken through edge of perforated acute ulcer. 1, Zone of swollen cells in the tissue which does not take the stain well—the zone of dying tissue; 2, Leucocytic reaction; 3, Inflammatory infiltration of subserosa tissues. (*From the 'Zentralblatt für Chirurgie'.*)

Perforation of an ulcer not infrequently occurs from two to three hours after a meal; and therefore it is not improbable that most perforations are due to the action of unbuffered gastric juice on the wall of an empty stomach or duodenum which may or may not

be the subject of some degree of temporary devitalization. It is also not unlikely that hæmatemesis from an acute ulcer is caused in a similar way.

It is, too, of special interest in regard to the question of whether perforation occurs more frequently in acute or in chronic ulcer, that Wright-Smith, in a series of 97 chronic ulcers found post mortem, ascertained the fact that in 22 the patients during life had complained of no symptoms suggestive of chronic ulcer; that is, absence of symptoms before a perforation does not mean that it has occurred in an acute ulcer.

Acute ulcer is occasionally found in association with chronic ulcer.

Occult blood is found in the early stages of acute ulcer, so that this test should always be made in suspected cases.

X-ray Diagnosis.—Radiography does not reveal any evidence of acute ulcer, for the ulceration is too insignificant to show a niche. X rays therefore do not help in the diagnosis.

REFERENCE

- ¹ PUHL, H., and SCHMIDT, RUDOLF, *Zentralb. f. Chir.*, 1936, No. 17.

CHAPTER XIII

THE DYSPEPSIA OF UNCOMPLICATED CHRONIC GASTRIC ULCER

Clinical Features.—The main features of the dyspepsia of *uncomplicated* ulcer are: (1) Painful dyspepsia during the emptying phase of the stomach; (2) Absence of dyspeptic symptoms and of pain during the filling phase of the stomach; (3) Absence of nausea and spontaneous vomiting; (4) Normal appetite; (5) Absence of nutritional disturbances; (6) Absence of disturbance of bowel function; (7) Presence of a 'deep tender spot' and probably an X-ray niche which corresponds to this spot.

1. *Painful Dyspepsia during the Emptying Phase.*—The typical dyspeptic 'pattern' of uncomplicated chronic gastric ulcer of the lesser curvature is a *painful dyspepsia*, in which the pain is severe and of a burning, gnawing, boring character.

The most striking characteristic of this painful gastric-ulcer dyspepsia is that it *coincides with the emptying phase of the stomach*. Its time incidence after a meal depends therefore on the particular rate of emptying of the individual stomach, and on the distance of the ulcer from the cardia. The more rapidly the stomach empties and the nearer the ulcer is to the cardia, the sooner the onset of painful dyspepsia after the intake of food.

This pain so characteristic of ulcer, coming on during the emptying phase of a stomach in which the main part of the gastric wall is healthy, is probably caused by the contraction of the partially emptied stomach on the inflammatorily infiltrated and rigid ulcer, and by the action of the vigorous peristaltic movement on the sensitive ulcer in the contracted stomach.

The pain in these cases is probably produced in the same way as it is caused in almost similar circumstances by an ulcer in the region of the exit—the trigone—of a hollow organ like the bladder (*see p. 35*).

If the stomach cannot empty and contract on a chronic ulcer, this ulcer may not give rise to pain. This fact is shown in the following interesting case-history:—

A man, aged 40, suffered for four years from fullness after meals, belching of wind, and other dyspeptic symptoms. *He had never at any*

time had any pain. He vomited large quantities of gastric contents. A radiograph showed a deep penetrating ulcer of the lesser curvature, and great dilatation of the stomach (*Fig. 66*).

It was difficult to understand why such a deep penetrating ulcer did not give rise to pain, but the operation disclosed the reason. An old posterior duodenal wall ulcer (which usually forms painlessly) had caused almost complete stenosis of the duodenum and great dilatation of the stomach. A gastric ulcer had formed in this dilated stomach, for there

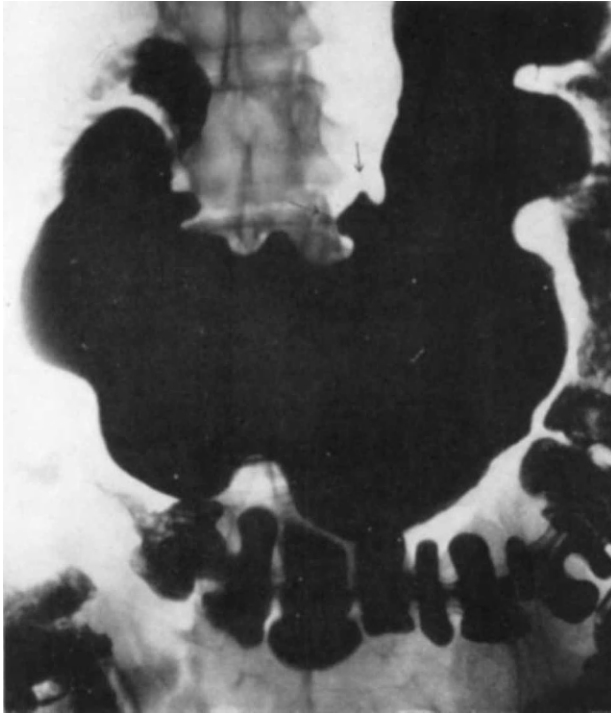

Fig. 66.—Radiograph showing ulcer of the lesser curvature and dilated stomach. Arrows point to ulcer.

could be no doubt that the duodenal ulcer long predated the gastric ulcer. Thus the stomach could never contract, always remaining dilated, and for this reason even a deeply penetrating ulcer of the lesser curve could never cause the characteristic pain of an ulcer in that situation.

The diagnostic importance of recognizing this fact is also shown in this case. On account of the painless history, the patient was thought to be suffering from malignant disease, no suspicion arising that he was suffering from an innocent ulcer. Indeed, because of his very bad general condition he had been regarded as inoperable.

At operation, two-thirds of the stomach and part of the duodenum to below the stenosis were removed.

A peculiarity of the painful dyspepsia of uncomplicated chronic ulcer is that, in the same patient, the pain recurs each day at the same time after the intake of food.

A still further peculiarity, and one that distinguishes the painful dyspepsia of gastric ulcer from the almost similar type occurring in certain phases of gall-bladder disease, is that it is periodic in its occurrence; whereas the painful gastric-ulcer-like dyspepsia caused by gall-bladder disease is irregular in its incidence, that is, it is aperiodic.

Since the presence of food in the stomach is the reason for its emptying, it follows that, when vomiting takes place and the food is removed, the patient gets relief from pain.

If the dyspeptic pain of ulcer is due to the emptying of the stomach, it follows that the patient should be able to relieve his ulcer dyspepsia by filling his stomach; or by abolishing the emptying phase through vomiting. Both these he is able to do, for it is well known that many patients suffering from ulcer often get relief on taking more food, or a bland fluid, and if they vomit they get relief from the pain. It is, of course, characteristic of the pain of gastric ulcer that alkaline drinks relieve the pain. I am inclined to think that this relief is due more to the filling of the stomach than to the action of the alkali; for experimentally the application of dilute hydrochloric acid to a chronic ulcer does not produce pain.

2. *Absence of Dyspeptic Symptoms and Pain during the Filling Phase.*—It should be specially noted that, in uncomplicated gastric ulcer, there is no painful or other form of dyspepsia during the filling of the stomach. Any painful manifestations, or even any *discomfort* on the *filling of the stomach*, should at once invite a *suspicion of the presence of carcinoma of the stomach*, or of some complication of chronic ulcer, such as an accompanying secondary chronic gastritis or the beginning of organic pyloric stenosis.

3. *Absence of Nausea and Spontaneous Vomiting.*—In contrast to the dyspepsia of carcinoma of the stomach, there is little spontaneous feeling of nausea and little spontaneous vomiting. It is in order to get relief from pain and not as a result of nausea, that the patient with the chronic gastric ulcer vomits. He must induce it himself; *spontaneous nausea or vomiting, especially during the filling phase of the stomach*, should at once excite a suspicion of carcinoma of the stomach; it is unusual in an uncomplicated gastric ulcer syndrome.

4. *Normal Appetite.*—As in uncomplicated chronic ulcer the gastric wall is healthy except in the region of the ulcer and its immediate neighbourhood, this painful gastric-ulcer dyspepsia is associated with a *normal appetite*.

5. *Absence of Nutritional Disturbance.*—Nutritional disturbances are not, as a rule, a feature of uncomplicated gastric ulcer. As the patient can relieve the pain by taking food, and as his appetite is good, he takes more food than under normal circumstances, and his nutrition often improves. It is only when complications in the ulcer ensue that nutritional disturbances develop.

6. *Absence of Disturbance of Bowel Function.*—It is an important diagnostic point in distinguishing gastric ulcer from gastric carcinoma

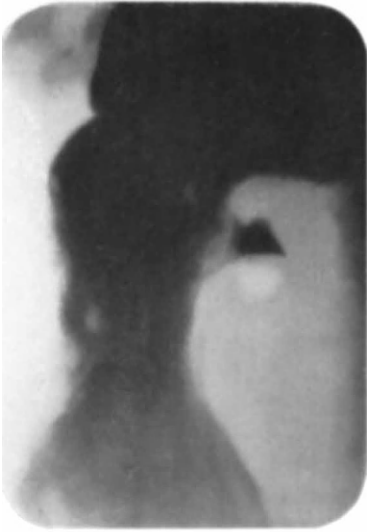

Fig. 67.—Ulcer of lesser curve, showing niche with air-bubble. Pressure over the niche elicited an exquisite local tenderness.

(Figs. 67, 68 by courtesy of Dr. H. M. Hewlett.)

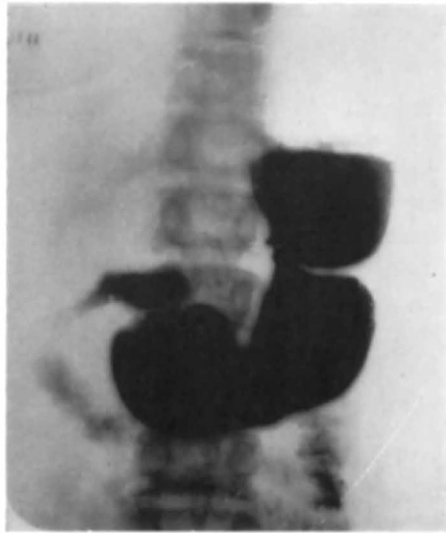


Fig. 68.—Small ulcer of lesser curve showing the muscular hour-glass spasm which is usually seen opposite the ulcer. Note that the isthmus is regular and lies on the lesser curvature—the isthmus of a carcinomatous growth is usually central.

that uncomplicated gastric or duodenal ulcer does not as a rule seem to disturb much the normal bowel function of the patient. On the other hand, constipation is an early, a persistent, and a progressive symptom in gastric carcinoma, even though there may be no pyloric obstruction.

7. *Presence of a 'Deep Tender Spot'.*—The most important diagnostic feature in a gastric-ulcer dyspepsia is the very localized 'deep tender spot', which corresponds to some part of the lesser curve of the stomach—the ulcer-bearing area—and probably also to an X-ray niche which can be seen on the X-ray screen (Figs. 67-69).

Characteristics of Chronic Ulcer in the Various Parts of the Stomach.—

Ulcer of the Lesser Curvature.—The following is an illustrative, typical history of uncomplicated ulcer of the lesser curvature :—

A male patient, aged 43, had been ill for seventeen months. At first he suffered from fullness, discomfort, and pain after meals. He was free from symptoms for four months. He then developed very bad burning pain from one and a half to two hours after food. This was relieved by food or alkaline drinks. He was accustomed to induce vomiting in order to ease the pain. He had two mild attacks of hæmatemesis. He had lost

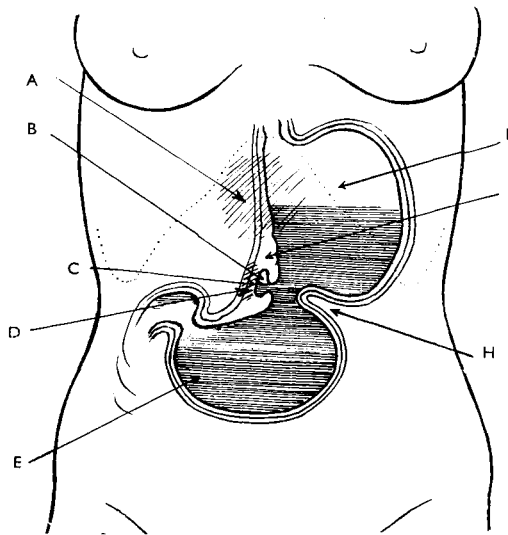


Fig. 69.—Diagram of ulcer of lesser curve, to show the characteristic X-ray appearances. A, Area of hyperæsthesia; B, Air-bubble in niche; C, Deep tender spot; D, Area of infiltration; E, Some dilatation of stomach due to pyloric spasm; F, Air; G, Adniculum; H, Hour-glass directly opposite ulcer, which may be partly muscle spasm, partly organic contraction. (After Forssell.)

a little weight but this was due to lighter diet. His bowels were regular. On examination, there was general epigastric tenderness and a local point of tenderness—a 'deep tender spot'—over the lesser curvature. This spot corresponded to a niche which could be seen by X rays on the lesser curvature. At operation, an ulcer of the lesser curvature, about 2 in. from the pylorus, was found.

High-situated ('Hochsitzung') Ulcer of the Lesser Curvature.—If the ulcer is situated high on the lesser curvature, as in Fig. 70 (Philippides¹), the pain comes on from half an hour to one hour after meals. An ulcer in this situation may also give rise to dysphagic disturbances due to transient cardiospasm.

Pyloric and Prepyloric Ulcer.—If the ulcer is situated close to the pylorus the pain may occur from two to three hours after meals. Moreover, in this situation it is usually associated with a good deal of pyloric spasm, in which case there may be some degree of gastric stasis and therefore some mild nutritional disturbance.

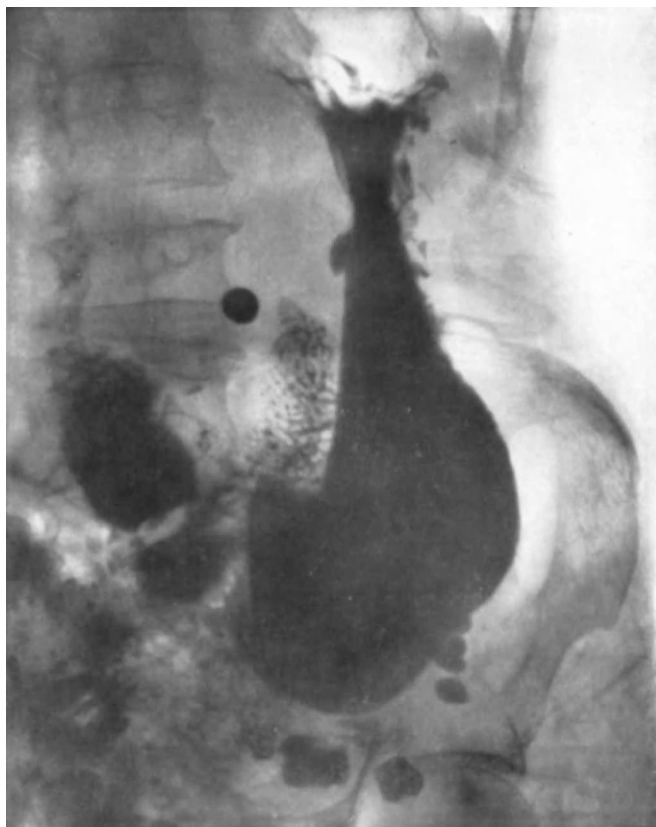


Fig. 70.—Radiograph of ulcer high up on the lesser curvature.
(From 'Der Chirurg'.)

Ulcer on the pylorus, or close to it, may cause anomalous symptoms. In one case, a patient with a long linear ulcer on the pyloric muscle complained of a transient pain coming on almost immediately after meals, and also pain coming on again four hours after meals. In another case, a patient who had an ulcer of the posterior lip of the pyloric orifice (Figs. 71, 72) suffered from severe epigastric pain which came on rather suddenly. Food would ease the pain, which would return in a little while, and would then

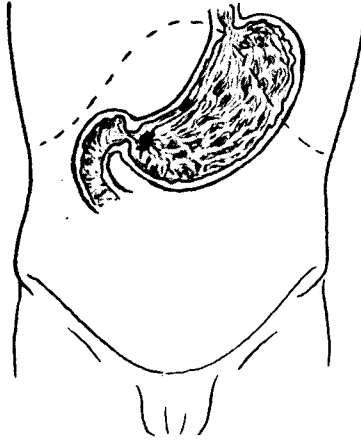


Fig. 71.—Operation sketch of ulcer of the prepylorus on its posterior wall about half an inch from the pyloric muscle.

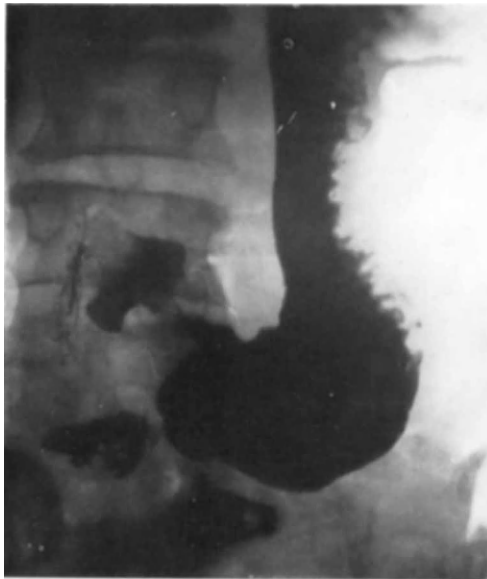


Fig. 72.—Radiograph in same case as *Fig. 71*. This ulcer caused the filling defect indicated, which was at first regarded as the filling defect of carcinoma. Closer examination, however, showed that it was not quite constant in its shape and extent, and also that its edges were rather too sharply defined for the filling defect of carcinoma.

persist throughout a whole night. His epigastrium was diffusely tender and very rigid.

In both these cases of an ulcer unusually situated, the pain setting in so soon after food was no doubt due to the fact that there was in each case an inflammatory and therefore painful *organic pyloric obstruction*, and pain came on the moment the stomach began to empty and the pylorus started to move. It is, however, rare for a pyloric obstruction to be caused by a florid ulcer forming on the pyloric muscle itself.

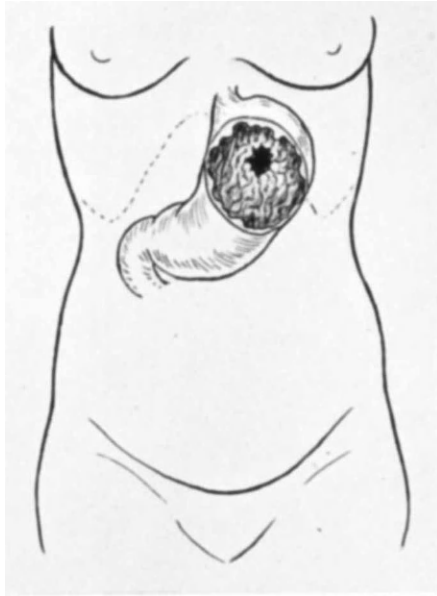


Fig. 73.—Operation sketch of chronic ulcer of the posterior wall of the fundus.

Ulcer of the Fundus of the Stomach.—To the painful dyspepsia of uncomplicated gastric ulcer there is an exception. Very occasionally a chronic ulcer is found in the fundus of the stomach, and in this case pain is almost absent. Probably the absence of pain is due to the fact that the ulcer is situated in that part of the stomach where there are no peristaltic waves, and where the stomach cannot contract to a small compass.

In such an ulcer the patient may suffer from only a mild painless dyspepsia. Fig. 73 (an operation sketch) shows an ulcer in this position—a case where the patient complained of a slight painless dyspepsia.

Ulcer of the fundus, however, is rare, and I have only seen one case. It is so rare that its presence should excite the suspicion of malignancy; for there is a type of malignant fundal ulcer which is very local, only mildly infiltrated, and very like an innocent gastric ulcer. Such malignant ulcers, however, are very large.

In my opinion, these chronic ulcers of the fundus originate in a different way to those which are found on the gastric canal. I think that they owe their origin more to an infective condition, and are caused in much the same way as ulcers in other parts of the body; the action of acidity, I believe, is only a contributing factor.

REFERENCE

- ¹ PHILIPPIDES, D., "Die schlauchformige Resektion der Behandlung des kardianahen Geschwürs", *Der Chirurg*, 1936, Sept., 688.

CHAPTER XIV

THE DYSPEPSIA OF COMPLICATED GASTRIC ULCER

Complications of Gastric Ulcer.—The complications of gastric ulcer which alter the ulcer syndrome are as follows: (1) Penetration of the ulcer and secondary gastritis; (2) Ulcer-tumour; (3) Pyloric stenosis; (4) Hour-glass contraction; (5) Carcinomatous degeneration.

The Effect of the Advent of a Complication on the Dyspeptic Syndrome of Uncomplicated Ulcer.—The advent of a complication in a case of chronic ulcer alters the character of the clinical picture. Once an ulcer becomes complicated, the clear-cut painful 'emptying dyspepsia', so characteristic of uncomplicated ulcer, changes.

When, for instance, a chronic ulcer penetrates and becomes associated with a chronic gastritis, the *filling of the stomach* is not symptomless as it is in uncomplicated ulcer. It now gives rise to more or less discomfort—sometimes to slight transient pain. There are therefore symptoms during the *filling*—in this case probably very slight—as well as during the *emptying* of the stomach; that is, there is not an interval after food which is completely free from symptoms.

Again, when a chronic ulcer becomes complicated by pyloric stenosis, the patient begins to lose the good appetite which previously he had, to lose weight, to become constipated, and to look ill and emaciated. The severe pain and the 'deep tender spot' so characteristic of the uncomplicated chronic ulcer disappear.

Thus, when ulcer becomes complicated, a new dyspeptic pattern unlike that of uncomplicated gastric ulcer is created—a dyspeptic pattern which is very similar to that of carcinoma of the stomach. The advantage of recognizing this transition is important, because it helps when making a diagnosis between gastric ulcer and gastric carcinoma, often a difficult problem.

I. PENETRATION OF THE ULCER AND SECONDARY GASTRITIS

An ulcer is said to be penetrating when it has ulcerated through all the coats of the stomach; or when this has occurred and its base is formed by one of the neighbouring organs such as the liver or the pancreas.

As the result of this penetration and the infection with which it is associated, there is generally found at X-ray examination an area of low-grade secondary gastritis spreading from the ulcer throughout most of the gastric wall. In addition there is also a certain amount of inflammation in the organ which has been penetrated—the pancreas or the liver—and which forms the base of the ulcer.

Penetrating ulcers therefore give a different dyspeptic syndrome from that of an uncomplicated ulcer; and the clinical picture is

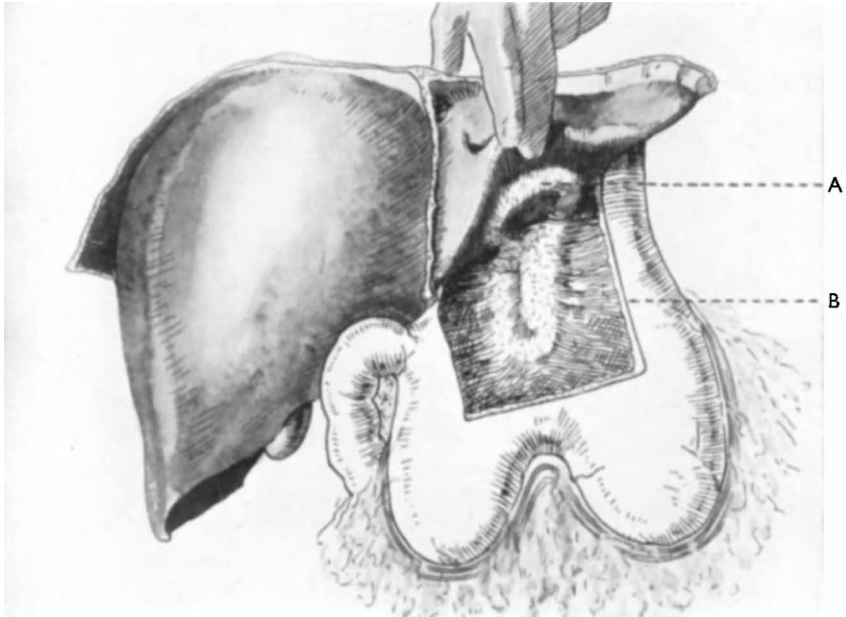


Fig. 74.—Operation sketch of penetrating ulcer of the upper part of the lesser curve (A), which has ulcerated into the left lobe of the liver, the base of the ulcer being formed by liver substance. B, Window cut to show ulcer.

sometimes very like that of gastric carcinoma. This, however, depends on the situation of the ulcer.

Penetrating ulcers are usually found in association with the liver or pancreas.

Ulcer Penetrating the Liver.—Penetrating ulcer high up on the lesser curvature—*hochsitzung Ulcus*—may ulcerate into the left lobe of the liver (Fig. 74). Such an ulcer gives rise to a characteristic clinical picture, first because of the high situation of the ulcer, and secondly because of its penetration. Severe ulcer pain may come on about half an hour after meals. A more or less *constant pain* may be

present and may radiate through to the back and the left side. There may be considerable loss of appetite and ill-health.

Chronic Ulcer of the Posterior Wall of the Stomach penetrating the Pancreas.—An ulcer penetrating into the pancreas gives rise to a characteristic dyspeptic syndrome.

Where an ulcer which has extended on to the posterior wall of the stomach penetrates, its base is formed by the body of the pancreas, and in such an ulcer there are several elements which go to make up its dyspeptic pattern. These are: (*a*) a pain an hour or two after meals, caused by the action of the emptying stomach on the chronic ulcer; (*b*) mild dyspeptic symptoms coming on immediately after meals (during the filling of the stomach), probably originating from the diffuse chronic gastritis associated with the old and very infected penetrating ulcer; (*c*) a constant dull pain, often striking through into the back, probably due to the effect of an inflammatory disturbance of the pancreas, the tissue of which forms the base of the ulcer; (*d*) ill-health, the result of constitutional and nutritional changes originating from disturbance of the pancreatic function and from the effect of a diffuse gastritis on gastric function.

In addition to all the above, the syndrome of chronic penetrating ulcer of the pancreas may be complicated by the fact that an old penetrating ulcer may be associated with a hypochlorhydria or an achlorhydria—a feature very suggestive of gastric carcinoma. The syndrome may be still further confused by another happening: an ulcer of the posterior gastric wall may involve the transverse mesocolon by direct extension, and by irritating its nerve plexus may cause *referred pain* over the sigmoid. This pain may suggest a diagnosis of a sigmoid lesion (*see pp. 139, 140*).

Thus it will be seen that in long-standing and badly infected chronic penetrating peptic ulcers there is often a composite dyspeptic pattern, the dissection of which is necessary in order that a refinement in clinical diagnosis may be able to distinguish it from that of gastric carcinoma, with which it is frequently confused.

ILLUSTRATIVE EXAMPLES OF PENETRATING ULCERS : DIAGNOSIS FROM CARCINOMA

Fig. 75 is a radiograph of an ulcer of the posterior wall of the stomach which deeply penetrated the pancreas.

The patient had an eight months' history of a mildly painful dyspepsia after meals, with loss of appetite, weight, and energy. He had become cachectic and emaciated, and clinically he was

regarded as suffering from gastric carcinoma. Radiographically, too, a diagnosis of malignant ulcer of the pyloric part of the stomach was made.

Operation disclosed a very deep perforating ulcer on the posterior wall of the stomach, penetrating into the pancreas.

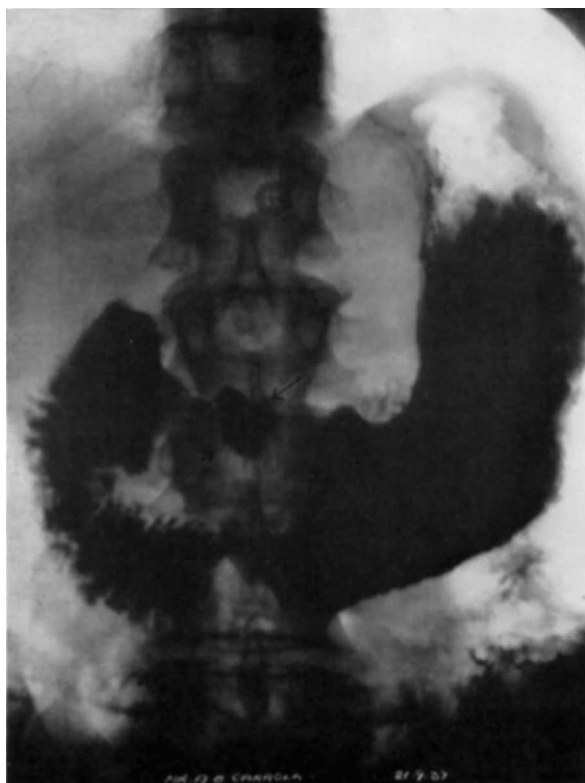


Fig. 75.—Radiograph of perforating ulcer on the posterior wall of the stomach penetrating the pancreas.

Penetrating Ulcer the Cause of Napoleon's Death.—In relation to this subject of penetrating ulcer, it is interesting to review, in the light of modern knowledge, the clinical history of Napoleon's illness and the post-mortem findings. This account is taken from a paper by Professor Tauno Kalima, Helsingfors, Finland.¹

According to Kalima, it was probably from a penetrating prepyloric gastric ulcer, from which spread a secondary diffuse gastritis, that Napoleon died, and not from cancer of the stomach as was recorded by Andromarchi, who made the post-mortem.

On the last day of September, 1817, Napoleon developed a severe pain in the right part of the epigastrium over the lower margin of the ribs. This pain did not last long. O'Meara, his surgeon, thought that he felt a swelling on the right side, and that Napoleon was suffering from an affection of the liver. From the end of July, 1818, to January, 1819, Napoleon's health was fairly good. On Jan. 17, 1819, he again became sick. He complained of bad right-sided pain, which radiated to the shoulder, somewhat similar to the pain which he had had sixteen months previously. His general health at this time was very bad. In the autumn of 1820 he was not well enough to take riding exercise, and his health began to get gradually worse. He complained of pain over the region of the stomach and over the lower part of the chest. The pain radiated to the shoulders. He began to vomit frequently, he became anæmic, and easily fatigued. About this time—January, 1821—he had some short remissions of his illness. He ate very little and became very constipated. The last phase of Napoleon's sickness commenced in the middle of March, 1821. He vomited each day during April, at the same time every day (evidently owing to a pyloric stenosis). In the intervals he suffered almost constantly with severe nausea. Two weeks before he died, he vomited many times daily. The vomitus usually contained blood. He died in May, 1821.

The general view held among historical writers and medical men of the past as well as of to-day is that Napoleon I died of cancer of the stomach. This view is based upon the post-mortem examination, which showed that the Emperor's stomach was the seat of a very widespread conglomeration of scirrhus ulcerations. A critical examination of the clinical course of the illness, however, suggests the picture of gastric ulcer with periodical dyspeptic symptoms, interrupted by prolonged remissions, increasing anæmia (probably as a result of occult bleeding), marked irritability of the stomach with daily frequent vomiting, severe attacks of pain, and persistent ache in the epigastrium, etc. The immediate cause of death was profuse hæmorrhage from the stomach.

Close examination of the post-mortem report shows beyond doubt that the antral part of the Emperor's stomach was the seat of a characteristic, funnel-shaped penetrating callous ulcer, the floor of which was formed by the lower surface of the liver. This finding is mentioned in the post-mortem report more in passing and as a by-finding, while chief attention is directed to the numerous ulcerations spread over almost the whole of the mucous membrane of the stomach. These ulcerations were regarded as cancerous, or

as ulcerations in the stage of cancerous degeneration. The clinical picture, especially taking into account the pronounced irritability of the stomach during the final period of the illness, is definitely against the view that the ulcerations in question were of cancerous nature : in that case the stomach would have formed into a stiff tube without any contractile power whatsoever. Moreover, no metastases were found at the autopsy.

On the other hand, by assuming that Napoleon's stomach was the seat of a simple widespread ulcerous gastritis secondary to an infected penetrating ulcer, the anatomical findings can be brought into complete harmony with the clinical picture. This hypothesis finds support in the anatomical investigations of recent years concerning the relation of chronic gastritis to the pathogenesis of gastric ulcer. Further, we now know that cancer rarely arises in an old chronic ulcer, but that characteristically it comes on *de novo* in a healthy stomach. It is unlikely, therefore, that a condition which the post-mortem findings show was penetrating ulcer should, in the short period of three and a half years, have suffered malignant degeneration. It should also be particularly pointed out that ulcer disease was unknown in practical medicine during the time of Napoleon. It was through Cruveilhier's investigations (1829), unanimously accepted by medical research of more recent times, that gastric ulcer first became separated as an independent clinical entity from other affections of the stomach, and especially from cancer of the stomach.

Thus the difficulty of diagnosing the dyspepsia of penetrating ulcer from that of a gastric malignancy is age-old and is still a recurring problem in practice.

Case-histories.—The following case-histories again illustrate this difficulty :—

A man, aged 48, had been ill for years, the acute periods of his illness ranging from two to four months. During these periods he complained of epigastric pain, which came on some time after meals. During the two years which followed the first phase of his illness, the pain gradually lessened in its severity, lost its periodic character, and became constant, being present the whole day but aggravated after meals. The pain then began to extend posteriorly and to the left side. Finally the patient began to vomit quantities of blood. He had not lost much weight but he looked ill and anæmic, and appeared to be the subject of a malignant growth. He had been diagnosed by a consulting physician as suffering from a gastric carcinoma.

At operation a large innocent chronic ulcer penetrating the body of the pancreas was found.

The important diagnostic points of this history are : (a) the mildly painful dyspepsia (like the mildly painful dyspepsia of gastric

carcinoma) associated with the emptying of the stomach (*see* p. 225); (b) the continuous pain made worse by the taking of food during the later part of the history—a pain like that of gastric carcinoma; (c) the cachectic appearance of the patient; (d) the continual attacks of hæmatemesis.

Another good example of the confusion which often arises in a diagnosis between a penetrating ulcer (in this case associated with hour-glass contraction) and an inoperable gastric malignancy is the following:—

The patient was an emaciated, thin, cadaverous, cachectic-looking woman of 66, so ill that she could hardly walk. Because of her profound ill-health, her clinical syndrome, and the absence of any radiographical sign of innocent ulcer, her condition had been regarded by an experienced surgeon as malignant disease of the stomach.

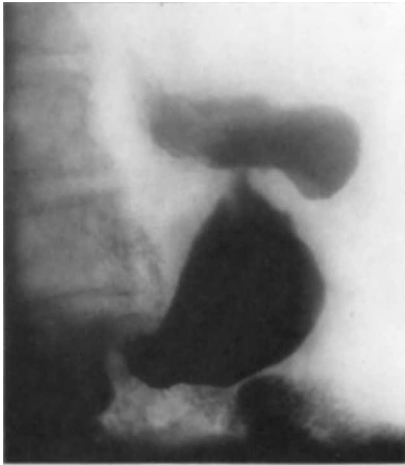

Fig. 76.—Radiograph of hour-glass retraction of the stomach.

She gave a history that, two years previously, she had suffered from indigestion with some *very decided discomfort after food*. After some treatment her condition improved. Months later she began to suffer from discomfort and slight pain, half an hour to two hours after food. As the months went by the pain came to be *continuous over the whole day*, but was somewhat aggravated by taking food, and relieved by vomiting. She vomited half an hour after every meal, even if she took only light food. During the

last two months she had become very constipated; she had noticed that her motions were often black; she had lost 12·6 kg. (two stone) weight; and she had become cachectic, haggard, and weak. She had a tender spot above and to the left of the umbilicus.

The presence of the mildly painful filling dyspepsia, the marked loss of weight in a short time, the cachectic appearance of the patient, the fact that a radiograph showed an hour-glass contraction (*Fig. 76*) with a centrally situated isthmus and slightly indented edges, were all criteria in favour of a gastric carcinoma.

The patient was so ill that I thought she could not stand any surgical interference. However, the presence of a definite 'deep tender spot', together with the fact that during the course of her illness symptoms had disappeared with treatment, encouraged me to make an exploratory operation with the hope that the centrally situated malignant-like isthmus might possibly be caused by an old ulcer of the posterior wall. To my surprise I found, embedded deeply in the pancreas, a very large penetrating ulcer

of the posterior gastric wall which I was able to remove (*Fig. 77*). The patient recovered.

This case, only one instance out of many, shows the confusion that frequently occurs between penetrating ulcer and gastric malignancy, and the need for a painstaking dissection of all dyspeptic patterns.

Penetrating Ulcer of Posterior Wall diagnosed as Sigmoid Malignancy.—Penetrating ulcer of the posterior wall is not always

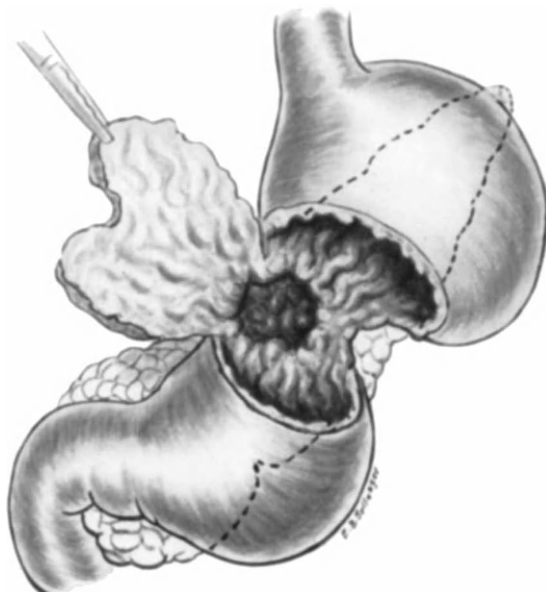


Fig. 77.—Operation sketch of stomach, showing ulcer of posterior wall penetrating pancreas (pancreas dotted in).

demonstrated by an X-ray examination. Where in some instances it is associated with profound ill-health, achlorhydria, and a radiating pain down the left side, the suspicion of innocent chronic ulcer may never arise, and the patient may be regarded as suffering from either a gastric or a sigmoid carcinoma. An example of such confusion is seen in the following case:—

A thin, cachectic, anæmic man of 36 years was rapidly losing health and presented no clear diagnosis. He had been ill for some time, suffering with epigastric pain from half an hour to one hour after food. This pain was relieved by food and magnesia. He never vomited. During a year he had had two or three bouts of this pain of one month's duration. In the intervals he would have a good deal of flatulence. Six years previously he had a hæmatemesis.

Two months prior to being seen, the character of his illness had completely changed. He began to vomit immediately after meals; the pain now came on about an hour and a half after meals, and instead of being epigastric it was situated below and to the left of the umbilicus—over the sigmoid region. He became very sick, and began to look cachectic, to lose weight, and to show the usual appearance of a person suffering from malignant disease.

A fractional test-meal revealed practically no free acid (*Fig. 78*).

X-ray examination showed a hypotonic stomach with two-thirds residue in six hours. The radiographer did not report any sign of a chronic ulcer.

This history appeared very suggestive of gastric or perhaps sigmoid carcinoma.

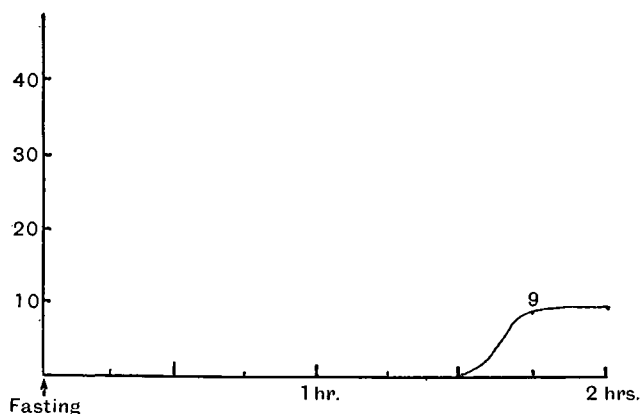


Fig. 78.—Graph of free acid revealed in case of penetrating ulcer of the posterior gastric wall.

Operation disclosed a large innocent chronic ulcer of the posterior gastric wall, situated more towards the cardia than towards the pylorus, deeply penetrating the pancreas, and with an inflammatory area extending from the ulcer into the transverse mesocolon.

Apparently it was only during the last few months that this inflammatory infiltration had extended from the ulcer on to the transverse mesocolon; and probably a relation of the nerve-field of this region to that of the sigmoid colon was the explanation of the extension of his pain downwards towards the sigmoid region. It was this pain, which was out of keeping with the other symptoms, that erroneously turned attention away from the stomach and towards the sigmoid.

These cases of chronic gastric ulcer of the posterior wall, as the above case exemplifies, are nearly always associated with a considerable disability in gastric emptying. This disability may be

due either to crippling of the muscular gastric wall caused by its fixation to the pancreas, or to a hypertonic condition of the pyloric sphincter.

I have dealt at some length with the diagnostic problem involving the distinction between penetrating gastric ulcer and gastric carcinoma, for the clinical history of these patients frequently simulates so closely malignant disease of the stomach that, judging from my own experience at least, many of them are erroneously regarded as suffering from this condition.

REFERENCE

- ¹ KALIMA, TAUNO, "De quelle Maladie est mort Napoleon I?", *Acta chir. Scand.*, 1932, **77**.

CHAPTER XV

THE DYSPEPSIA OF COMPLICATED GASTRIC ULCER

(continued)

It has been pointed out that the complications of gastric ulcer are: (1) Penetration of the ulcer, and secondary gastritis; (2) Ulcer-tumour; (3) Pyloric stenosis; (4) Hour-glass contraction; and (5) Carcinomatous degeneration. Of these, (1) has been dealt with in Chapter XIV.

2. ULCER-TUMOUR

Not infrequently a large firm tumour may form around a penetrating ulcer. This tumour may infiltrate the adjoining organs and even the abdominal wall. It may be indistinguishable in appearance, even when seen at operation, from a gastric carcinoma. As a rule it is irremovable. This inflammatory 'ulcer-tumour' is often confused with gastric carcinoma in the same way that inflammatory diverticular tumour is confused with carcinoma of the sigmoid; and it is the basis of those cases of supposed inoperable cancer of the stomach which have been cured by the faith-healers.

This type of ulcer-tumour is exemplified in the following case record:—

A patient, who had a large firm epigastric tumour which was thought to be malignant, was referred for an operation in the belief that he had a gastric carcinoma.

He had severe pain occurring one hour after food—a painful emptying dyspepsia. He had also loss of weight and attacks of hæmatemesis.

When the abdomen was opened, the surgeon found a large firm tumour of the prepyloric part of the stomach. The tumour was so large, so hard, so infiltrating, and so adherent to the surrounding structures, that he regarded it as undoubtedly an inoperable carcinoma, and performed a palliative gastro-enterostomy.

A few months after the operation the patient sought further surgical advice, in the hope that it would be possible to have the carcinoma removed.

His case was then carefully reviewed. It was noticed that he had a considerable time interval after food without any symptoms whatever; that is, that he had no incidence of dyspeptic symptoms as the stomach filled—no filling dyspepsia. It was also noticed that the tumour was tender. Further, it could be demonstrated in a radiograph that the crater of an ulcer, which could be seen, lay outside the line of the stomach wall.

If this ulcer were of a carcinomatous nature, the patient should first have suffered from a filling dyspepsia; and secondly the crater should have shown inside the normal contour of the gastric wall—a negative gastric filling rather than the positive one which is found in the case of the true ulcer niche. In the light of this reasoning the patient was advised to submit himself to a further operation.

At the second operation a large firm tumour of the prepyloric part of the stomach was found. This tumour infiltrated the surrounding structures—the pancreas, the left lobe of the liver, and the gastro-hepatic omentum—and appeared at first sight to be an inoperable carcinoma. However, careful investigation of the spreading edges of the tumour showed that there was some œdema; that there were no permeating nodules suggestive of carcinoma; and that the glands, though enlarged, were not sufficiently hard to indicate a carcinomatous metastasis. These observations, taken in conjunction with the patient's comparatively good health notwithstanding the great size of this tumour, and with the X-ray findings, were regarded as being in favour of an ulcer-tumour rather than carcinoma.

Accordingly, with great difficulty, the tumour was removed and an extensive partial gastrectomy was performed.

On microscopic examination the tumour proved to be innocent.

Fifteen years later the patient was alive.

These ulcer-tumours are not uncommon. I have seen them in the prepyloric part of the stomach, on the lesser curvature, and associated with some penetrating ulcers of the posterior wall.

Even with the knowledge and experience that I have obtained as a result of taking a special interest in these ulcer-tumours, I can still fail to recognize them. In one case where I had exposed such a tumour at operation, I was not able to say whether it was carcinoma or an ulcer-tumour. Time, however, showed that the tumour was inflammatory and not malignant. It is particularly difficult to distinguish these tumours from carcinomatous tumours complicated by a surrounding inflammation or by abscess formation.

3. PYLORIC STENOSIS

Pyloric obstruction occurs when an ulcer on the pylorus or in the vicinity of the pylorus heals. As the scar of the healed ulcer contracts, organic pyloric obstruction is produced.

In an innocent pyloric stenosis caused by the scar of a healed chronic ulcer, the patient exhibits symptoms of a painless or mildly painful dyspepsia; the severe pain after meals and the 'deep tender spot' which characterized the florid chronic ulcer have disappeared. The patient will, however, in his previous history have shown symptoms of the *severe painful dyspepsia* characteristic of the florid chronic ulcer, which must have been the forerunner of the ulcer-scar

and the organic obstruction. He will also exhibit symptoms arising as a result of the mechanical obstruction of the pylorus, namely, constipation, vomiting, and nutritional loss: symptoms, it must be remembered, which are very like those of carcinoma of the stomach.

Thus, pyloric obstruction preceded by a severely painful dyspepsia and associated with a mildly painful dyspepsia, speaking broadly, may be taken as innocent.

Pyloric Obstruction with a Quick Onset.—If pyloric obstruction is brought about fairly quickly, as, for example, where chronic ulcer develops on the pyloric muscle or in its vicinity, a painful dyspepsia will result. This painful emptying dyspepsia comes on about four hours after meals, and is caused by the powerful contractions of a hypertrophied muscle trying to empty the stomach through a very small opening.

Pyloric Obstruction with a Slow Onset.—Where a pyloric obstruction comes on very slowly, it does not as a rule give rise to a painful emptying dyspepsia, even though powerful peristaltic contractions can be seen on the abdominal wall.

Thus a high-grade pyloric obstruction accompanied by a painless dyspepsia generally means that the obstruction has been produced slowly; and, as the growth of a scirrhous of the pylorus is characteristically slow, such a type of pyloric obstruction is usually of a malignant nature.

However, the pyloric obstruction caused by an ulcer-scar may also come on slowly and give rise to a painless dyspepsia like that of a malignant pylorus. But the difference between the two conditions is that in the case of the ulcer-scar obstruction there will be a very definite previous history of painful peptic-ulcer dyspepsia, even though the actual onset of obstruction may be preceded by months or even years of freedom from painful dyspepsia. This point is brought out well in the following case-history:—

A woman, aged 58, had a seven years' history of periodically recurring attacks of *painful peptic-ulcer dyspepsia*. In these attacks of about three or four months' duration she suffered from a bad burning epigastric pain, one to two hours after food. She had a good appetite, was in good health except for her pain after food, was never constipated, and had not lost weight.

Nine months previous to being seen her pain after meals ceased, she began to lose her appetite, and to become constipated. Gradually she became very ill, and soon had lost 2 stone in weight. She began to vomit a very large quantity—generally at nine o'clock every night. Her appearance completely changed, and she now looked cachectic and ill, and presented the appearance of a person suffering from a gastric malignancy

X rays showed a very dilated and hypertrophied stomach. On examination, she had no 'deep tender spot'. A clinical diagnosis of carcinoma of the pylorus had been made.

At operation a healed prepyloric ulcer was found. In healing, the scar had caused marked pyloric stenosis, and the symptoms from this simulated those of a pyloric carcinoma.

In this history the phase of the florid prepyloric peptic ulcer is evident, and also the phase of healing of the ulcer and scar contraction—mechanical obstruction—when the pain and tenderness disappeared.

4. HOUR-GLASS CONTRACTION

Stenosis of the lumen of the stomach (hour-glass contraction), like that of the pylorus or of the duodenum, may occur when a chronic peptic ulcer on the lesser curve heals and the ulcer-scar contracts.

The stomach is so wide that, as a rule, it is uncommon for an hour-glass contraction to produce obstruction. But obstructions of the pylorus, or of the prepylorus, or of the duodenum, because of the narrow lumen in these parts, is a fairly common accompaniment of chronic peptic ulcer.

An organic hour-glass contraction is usually caused by the complete healing, but it may be caused by the partial healing, of a chronic ulcer. A painful dyspepsia is only associated with an organic hour-glass contraction when the ulcer is not quite healed.

Hour-glass contraction may be wholly due to fibrosis; but sometimes it is caused partly by fibrosis and partly by muscular contraction.

The formation of an hour-glass contraction is associated with almost the same change in the syndrome of chronic ulcer as occurs in the development of pyloric stenosis; the ulcer loses its pain and tenderness, and nutritional disturbances develop. In hour-glass contraction, however, because the lumen of the stomach is so much bigger than that of the pylorus, the onset of nutritional disturbances is very much slower and more gradual.

5. CARCINOMATOUS DEGENERATION

Carcinoma supervening on a chronic ulcer might very well be called 'ulcer-carcinoma'. It is the cause of a variation in the dyspeptic pattern of chronic ulcer which can be recognized. As far as my clinical observations go, in only about 5 to 6 per cent of cases does cancer of the stomach develop in the site of an old ulcer.

When malignant degeneration occurs in the ulcer there is not only an alteration in the dyspeptic pattern, but also a development

of new symptoms which are indicative of the advent of carcinoma. Malignant degeneration in a chronic ulcer must be suspected if a patient who has been suffering for years from the severe painful dyspepsia typical of gastric ulcer loses the acute painfulness of the dyspepsia and the marked tenderness of the 'deep tender spot'; begins to lack the good health and good appetite usually found in a case of chronic ulcer; begins to lose weight and energy, to vomit, to look anæmic and ill, and to become constipated.

In addition to this variation of the dyspeptic pattern and development of new symptoms, radiographic changes in the ulcer can be detected. The ulcer niche ceases to lie outside and comes to lie inside the normal contour of the stomach; it ceases to have the clear-cut definiteness of a niche; and the ulcer area enlarges—that is, evidence of infiltration in the neighbourhood of the ulcer becomes obvious.

In the following case record, the transition of an innocent ulcer into a malignant one is clinically evident:—

A man, aged 46, had "stomach trouble" periodically for twenty years. He had attacks of severe pain two hours after food, followed occasionally by vomiting with relief.

Two years previous to being seen the nature of his illness began to change, and in the last six months it changed completely. At first the pain after food began to diminish, and finally it disappeared. He then began to lose weight, and latterly to lose it very rapidly. A dull pain, quite unlike the original pain, came on some hours after food, and he *felt nauseated immediately after taking food*, that is, he began to suffer from a filling dyspepsia. He also began to vomit regularly a large quantity at the end of each day. He became cachectic and ill-looking.

At operation I found what looked like a very infiltrated chronic ulcer, and I performed a partial gastrectomy. In the specimen the pathologist found a large ulcer which was found to be infiltrated with carcinomatous cells.

It is clear that in this patient a malignant change of a chronic nature began in the ulcer two years before he was seen—that is, when the ulcer pain began to diminish, and when he began to lose weight and energy, to vomit, and to have a filling dyspepsia.

The great practical importance of recognizing early this type of malignant stomach in its incipient stages is that this 'ulcer-carcinoma' grows slowly, does not metastasize early, and if it is removed reasonably promptly the patients are often completely cured.

This practical point is exemplified in the case just cited, for I recognized the malignant change and performed a partial gastrectomy. The resected segment of stomach did not show glandular metastasis, and fifteen years later the patient was alive.

A second instance of this type of carcinoma follows:—

A man, aged 52, complained that for years he had had dyspepsia, with pain in the epigastrium one hour after meals, relieved by hot water. Six months previous to his being seen the epigastric pain had altered in its character and incidence, and he had begun to lose weight rapidly.

Operation showed a carcinomatous ulcer with heaped-up edges, and a metastasis, about the size of a walnut, in a lymph-gland. Section of the ulcer and the gland showed carcinoma.

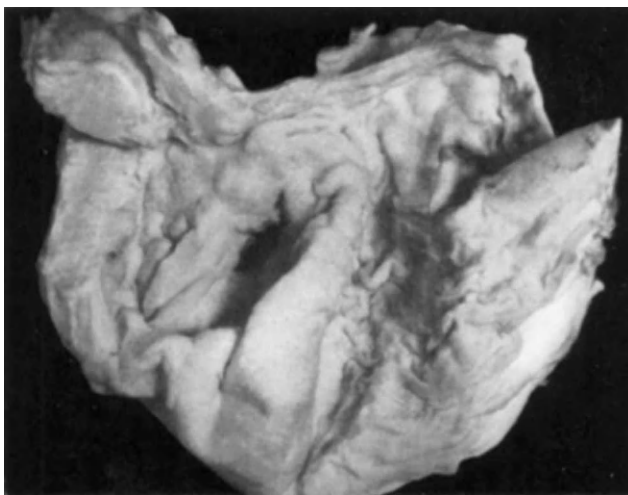

Fig. 79.—Stomach showing an innocent chronic ulcer that has become malignant. (By courtesy of Dr. Wright-Smith, Walter and Eliza Hall Institute Melbourne Hospital—Specimen 6.9224B.)

That was eighteen years ago, and the patient is still alive and well.

These two cases, and I could quote others, are examples of the operability of this type of 'ulcer-carcinoma'.

The following is a very definite case of 'ulcer-carcinoma', reported by courtesy of Dr. Wright-Smith:—

The patient had suffered from symptoms which indicated that he had a gastric ulcer. He was operated on in January, 1928, and a chronic perforating gastric ulcer was found adherent to the liver. A microscopical examination was made of a section removed from the ulcer at the time of the operation. This showed only a chronic inflammatory change.

In 1932 the patient died, and the post-mortem showed that his old chronic ulcer had become the subject of malignant degeneration. *Fig. 79* is a specimen of the stomach showing the condition. At the pylorus is seen a large white mass which was adherent to the pancreas and posterior abdominal wall.

Microscopical examination showed an intense fibrosis of the muscle coats of the stomach; a deep infiltration by masses of spheroidal carcinoma cells; early colloid change; and secondary carcinoma of the colloid type in the lymph-glands.

Difficulty of Recognizing at Operation whether a Chronic Ulcer has become the Subject of Carcinomatous Degeneration.—

At operation it is sometimes difficult to decide whether a chronic ulcer has become malignant. The difficulty cannot always be evaded by removing the doubtfully malignant ulcer, for it not infrequently

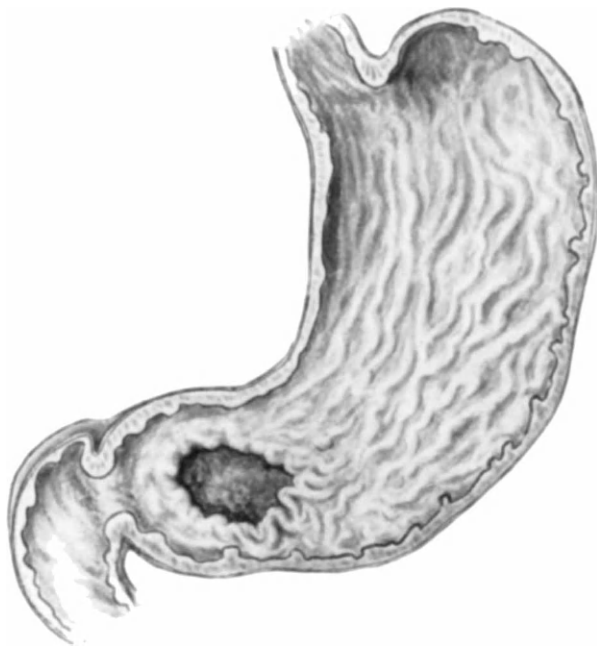

Fig. 80.—Operation sketch of malignant ulcer of prepyloric part of posterior wall.

happens that the partial gastrectomy which the removal of the ulcer would involve would be too big an operation for the patient to stand, whereas a gastro-enterostomy could be performed with safety.

This problem, and the failure to solve it, is illustrated in the following case record:—

A man, aged 60, had had for nearly twenty years the typical painful emptying dyspepsia of a chronic gastric ulcer.

During the three years previous to being seen, the nature of the symptoms had been gradually changing: he had been having less pain, his relief when he induced vomiting was less, his appetite was failing, he was gradually losing weight, and becoming more and more constipated.

I thought that this change in his 'painful dyspepsia' was due to the healing of a prepyloric ulcer, and to the gradual onset of pyloric stenosis. This clinical view was supported by the X-ray observations.

At the operation which I undertook for the relief of the pyloric stenosis I found that his pylorus was stenosed by a fairly firm cicatrix, perhaps a little bulky for the scar of a healed chronic ulcer. After careful scrutiny of the condition I decided that it was innocent, but not without some doubt, and I performed a gastro-enterostomy.

Had the patient not been so terribly emaciated, I would have carried out a partial gastrectomy, in order to be on the safe side. Three years later the patient died, with all the symptoms of a malignant stomach.

It was obvious that I had failed, both clinically and operatively, to recognize malignant degeneration in the ulcer scar.

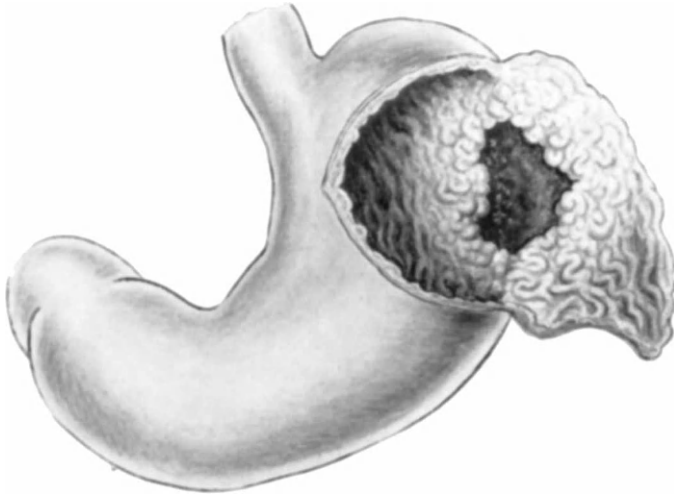


Fig. 81.—Operation sketch of malignant ulcer of the cardia.

Difficulty of Distinguishing at Operation between a Malignant Ulcer and a very Chronic Innocent Ulcer.—There are certain types of malignant ulcers which arise *de novo*, and which are so like a very old innocent gastric ulcer that at operation it is almost impossible to distinguish between them.

These malignant ulcers are about the size of a two-shilling piece. They are deeply excavated, have no surrounding cancerous dissemination at their edges which would help to identify them, and no metastasis in glands. *Figs. 80 and 81* are examples.

In this type of very localized chronic malignant ulcer, in contrast to innocent ulcer, the edges are shelving, not undermined; the base, when examined with the fingers in the same way as an epithelioma

of the lip, feels cartilaginous. Sometimes there will be a pucker on the peritoneal surface of the base. Occasionally this surface will

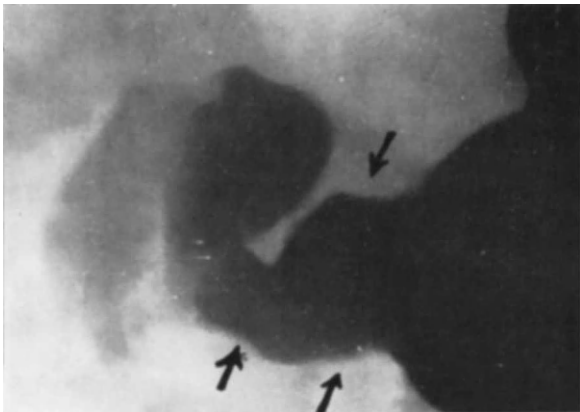


Fig. 82.—Radiograph of prepyloric malignant ulcer, the operation sketch of which is shown in *Fig. 80.*

be infiltrated, forming a cartilaginous plaque. Generally speaking, if the ulcer is big—more than the size of a two-shilling piece—it is very liable to be malignant.

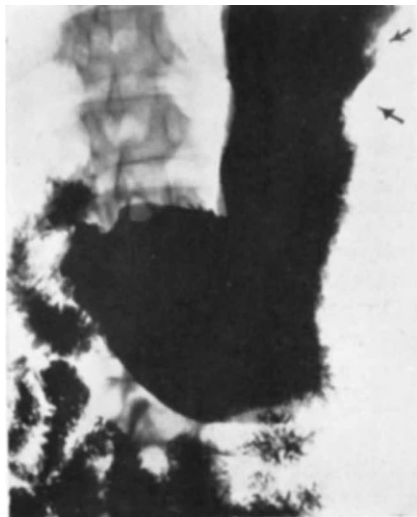

Fig. 83.—Radiograph of malignant ulcer of cardia, the operation sketch of which is shown in *Fig. 81.*

Radiographically, when these large ulcers are malignant they do not show a definite crater, as can be seen, for example, in *Fig. 82*, the prepyloric part of which merely shows a rather sharp-edged deformation of contour; and the very definite ulcer pictured in *Fig. 80* is practically not visible in this radiograph, and only indicated by the contraction which it has produced in the walls of the stomach.

The same difficulty of radiographically detecting the very definite crater of these malignant ulcers is seen in the case illustrated in *Fig. 81*. In

the radiograph (*Fig. 83*) the position of the ulcer is indicated by arrows, but very little evidence of the ulcer can be seen, its

presence being indicated only by a slight deformity, which is produced probably by the fibrocarcinomatous contraction.

Notwithstanding the fact that I have exercised great care in discriminating between this malignant type of ulcer and the very chronic innocent ulcer, I have mistaken a chronic ulcer for a malignant one, as, for example, in the following case:—

A woman, aged 58, complained that for many years she had discomfort in the epigastrium with flatulence and vomiting. X-ray examination revealed a suspicious projection on the lesser curvature.

At the operation, high up on the anterior wall of the stomach, near the upper part of the lesser curvature, a huge ulcer was found. The base of it was cartilaginous, and showed some hard irregularities on its peritoneal surface. It was similar to the malignant ulcers that I have already described, and I felt certain that this ulcer was malignant. I could not take the risk of removing it, because of its high situation, and the very low state of the patient's health. Many years later she was still alive and well.

I have no doubt that this ulcer was of syphilitic or partly syphilitic origin.

Syphilitic Complications in Chronic Ulcer.—Occasionally these very chronic, apparently malignant, ulcers are the result of

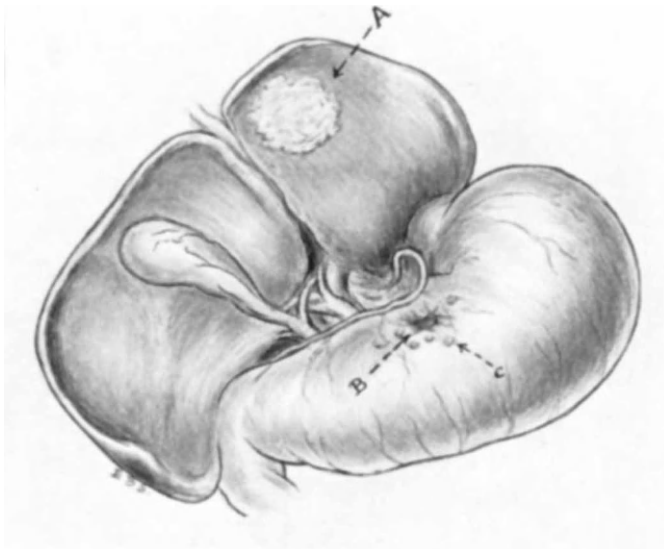


Fig. 84.—Operation sketch of syphilitic condition. A, Malignant-like plaque on liver; B, Ulcer of stomach; C, Nodules.

a syphilitic infection combined with the ordinary causes of chronic peptic ulcer. In one particular case, operation disclosed a large

penetrating ulcer of the lesser curvature, with nodules on the peritoneal surface of the base of the ulcer (*Fig. 84*). In the liver tissue that overlay the base was what appeared to be a malignant infiltration, which apparently had been caused by direct contact. Feeling that the ulcer had become malignant and had involved the liver I did not attempt to remove it, but as there was some gastric stasis I performed a gastro-enterostomy.

A post-operative examination of the patient's blood showed that she had a Wassermann + + +, and she was put on syphilitic treatment. Six years later she was quite well and had no dyspepsia of any kind.

CHAPTER XVI
DUODENITIS

DUODENITIS is a chronic inflammation of the duodenal mucous membrane, which is similar in origin and histological structure to the chronic 'ulcer gastritis' of Aschoff, and probably to the chronic gastritis described by Konjetzny. It runs a chronic course, is periodic in its incidence, and may recur only over long intervals. As in 'ulcer gastritis', Aschoff attributes this condition to the action

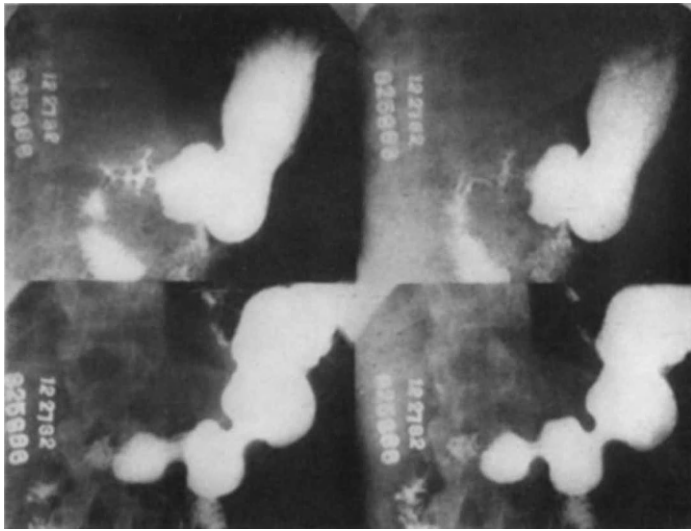


Fig. 85.—Diffuse duodenitis with typical X-ray pattern.
(From Eustermann and Balfour's 'The Stomach and Duodenum'.)

of an excess of hydrochloric acid on the mucous membrane. But Konjetzny and his Kiel school of observers regard it as arising from some exogenous irritating cause. The macroscopical appearances are much the same as those in 'ulcer gastritis'. Erosions ultimately form, and from these chronic duodenal ulcer not infrequently arises.

Symptoms.—The symptoms of duodenitis (or 'ulcer duodenitis') are very similar to those of duodenal ulcer; and many patients suffering from it are operated on in the belief that they are

suffering from duodenal ulcer. However, on the basis of this 'ulcer duodenitis' a definite duodenal ulcer may subsequently develop.

Duodenitis may give rise to a periodic painful dyspepsia, coming on from two and a half to three hours after food, which is almost indistinguishable from the painful dyspepsia of duodenal ulcer. But there are really two distinguishing points: the tenderness is diffuse rather than localized to a 'deep tender point'; and, although there may be deformity of the duodenal cap, there is no niche to be seen. *Fig. 85*, taken from Eustermann and Balfour's¹ book on the stomach and duodenum, shows the X-ray appearance of diffuse duodenitis.

Kirklin points out that the X-ray signs of duodenitis are those of irregular contraction of the duodenal bulb; and that the duodenal cap shows an irregular deformity, the contraction being partly attributable to the spasm caused by the inflammation, and partly due to fibrosis.

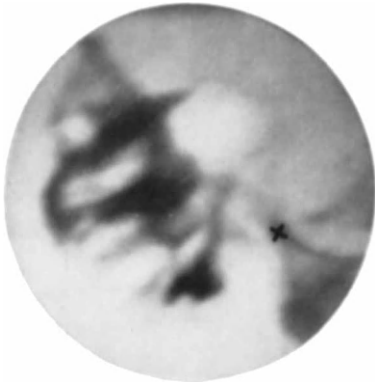

Fig. 86.—Duodenitis, showing swollen mucosal folds with irregular pattern. X, Pylorus. (*From the 'British Journal of Surgery'.*)

Cordiner and Calthrop² describe the X-ray characteristics of duodenitis as follows: "The most common feature of a duodenitis is a veiling of the mucosal pattern by inflammatory exudate, and a broadening and stiffening of the mucosal folds. As the folds are examined under the X-ray screen they appear to have lost their elasticity, and give the impression

that they have been starched. They can no longer be obliterated by stretching the duodenum and they are less easily deformed by pressure. Frequently deposits of the opaque medium may be retained between the swollen and abnormally directed folds, and such deposits may simulate and be difficult to differentiate from a true niche." (*Fig. 86.*)

Acute Duodenitis.—The following case record exemplifies a case of acute duodenitis, recorded by Dr. C. H. Mollison:—

The patient, a woman, aged 59, following a fall was admitted with a fractured pelvis. With splinting she was quite comfortable for a fortnight, when she commenced to vomit. The vomiting gradually became quite intractable and she developed tenderness but no rigidity in the epigastrium. The temperature, which had been normal, rose to 103° F., and death occurred.

MORBID ANATOMY.—The specimen (*Fig. 87*) shows the duodenum, which has been opened from behind. The mucosa is swollen, and in the third part there is a considerable amount of submucosal hæmorrhage. In

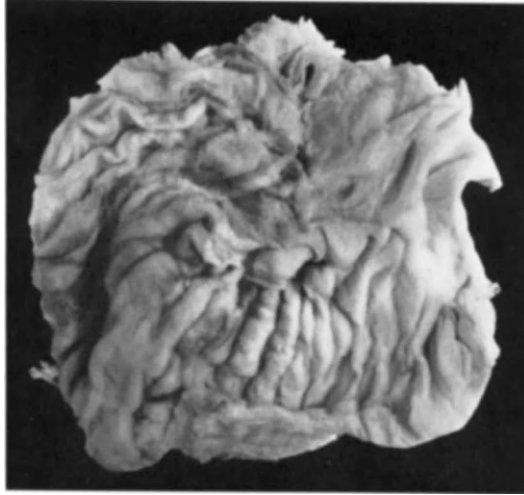

Fig. 87.—Acute duodenitis. (Specimen 7.33, presented to Walter and Eliza Hall Institute, Melbourne Hospital, by Dr. C. H. Mollison. Photograph by courtesy of Dr. Wright-Smith.)

the recent state there was a little purulent exudate between the pancreas and duodenum, but no further abnormality could be detected.

Microscopical examination of the duodenum revealed an acute inflammatory process involving all coats.

REFERENCES

- ¹ EUSTERMANN, G. B., and BALFOUR, D. C., *The Stomach and Duodenum*.
- ² CORDINER, G. R. MATHER, and CALTHROP, G. T., "The Radiography of the Duodenal Cap", *Brit. Jour. Surg.*, 1936, **23**, 700.

CHAPTER XVII

THE DYSPEPSIA OF ACUTE DUODENAL ULCER

ACUTE duodenal ulcer may be, like acute gastric ulcer, a possible complication of some general or focal sepsis. It occurs also in patients in whom there is some general loss of vitality. When it results from focal sepsis it may be single or multiple, but when arising from loss of vitality it is usually multiple. In either case it may be found associated with acute gastric ulcers. It is occasionally found with chronic ulcer.

As in the case of acute gastric ulcer, the causation of acute duodenal ulcer is open to doubt. Both a duodenitis (Konjetzny) and peptic influences (Büchner and Aschoff) have been advanced as the main factor in its aetiology.

Also like acute gastric ulcer, acute duodenal ulcer may not give rise to any dyspepsia, but if it does it is of a mild painless character.

Sometimes the first indication of the presence of acute duodenal ulcer is a profound melæna, or an acute abdominal crisis caused by a perforation.

Fig. 88 is a photograph of the stomach and duodenum of a patient, aged 50 years, who suffered from a diverticulitis of the colon, and who died from a mediastinal lymphosarcoma. In the specimen, and to some extent in the photograph, can be seen a generalized acute gastritis and duodenitis, and in the midst of the duodenitis one large acute duodenal ulcer and several small ones.

Seen at autopsy the stomach was large and distended, its mucous membrane congested, the folds being red and strongly marked. The duodenal mucosa was congested and showed many small hæmorrhages. Just beyond the pylorus a large acute ulcer with a black slough in its base was seen. Several tiny acute ulcers were also present in the first part of the duodenum. The mucosa was swollen and showed a coating of mucus.

Fig. 89 is a colour photograph of a specimen showing two ulcers of the duodenum, one on the posterior wall, and one on the anterior wall, the latter being a 'kissing' ulcer of the perforating type. It has penetrated to the peritoneal coat, is funnel-shaped, and its base is thin. The patient had suffered from indigestion for

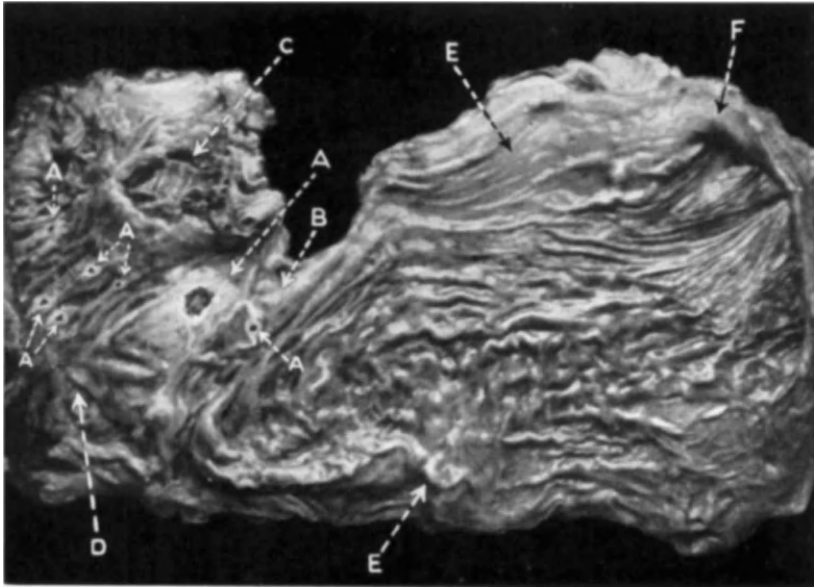


Fig. 88.—Acute duodenal ulcers (one large and several very small ones). A, Ulcer; B, Pylorus; C, Bile-duct (opened); D, Duodenum; E, Stomach; F, Esophagus. (Specimen by courtesy of Dr. Wright-Smith, Walter and Eliza Hall Institute, Melbourne Hospital.)

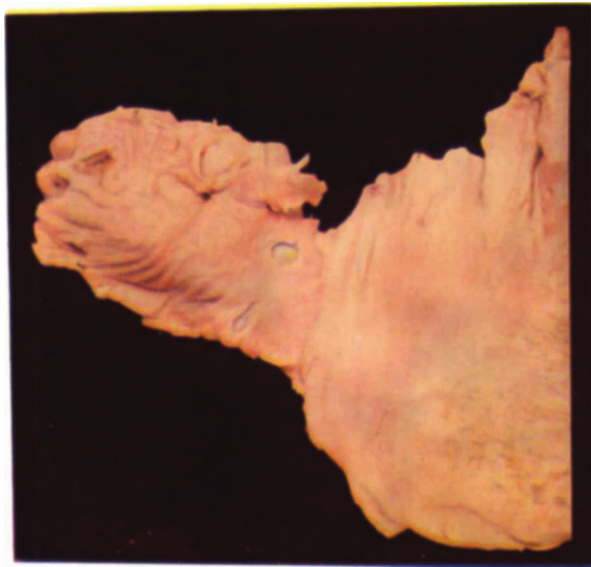

Fig. 89.—Multiple duodenal ulcers. (Specimen by courtesy of Dr. Wright-Smith, Walter and Eliza Hall Institute, Melbourne Hospital.)

five years, and at times had a dull pain in the mid-epigastrium, coming on one hour after meals. This pain was relieved by food, and came on periodically, lasting perhaps for five or six weeks at a time. The patient eventually developed attacks of profound hæmatemesis and melæna, and died as a result of the bleeding.

The following history is typical of an acute duodenal ulcer :—

A patient, who had always appeared to be healthy, suddenly fainted, became pale, and developed all the signs of an internal hæmorrhage. His bowels then acted several times, and he passed large tarry stools. He had had an influenzal infection about two weeks prior to this attack, but had never had any indigestion.

Note the infective element—the influenzal attack—the absence of any previous dyspepsia, and the profound bleeding.

CHAPTER XVIII
THE DYSPEPSIA OF CHRONIC DUODENAL
ULCER

UNCOMPLICATED ULCER

CHRONIC duodenal ulcer may be single or multiple. It occurs usually in the first part of the duodenum, rarely in any other part, and is found characteristically in two situations: on the anterolateral wall, and on the posterior wall. The manifestations in these two positions are very different.

Varieties of Uncomplicated Ulcer.—Wright-Smith¹ found, in 4085 consecutive autopsies, 218 cases of peptic ulcer; of these 3 were acute duodenal, 95 were chronic duodenal, and 8 were chronic gastric and duodenal combined. He found that the duodenal ulcers, as stated above, favoured two sites: one the anterior wall near the anterosuperior border (an ulcer which perforates); the other the posterior wall, often adherent to the pancreas (an ulcer which gives rise to hæmorrhage). In his series of 98 duodenal ulcers found at autopsy, Wright-Smith found that perforation had occurred in 40 cases. Hæmorrhage without perforation occurred in 18 cases. In two cases both hæmorrhage and perforation had occurred. In one of these, two ulcers were present, the anterior one perforating and the posterior one bleeding.

Of the series of 218 cases of peptic ulcer, 70 duodenal ulcers were directly responsible for death. Hæmorrhage severe enough to be the main factor in causing death occurred in 20 cases of duodenal ulcer, including 3 with perforation. All the duodenal ulcers were of the chronic variety. Eighteen of them were situated on the posterior wall, one on the anterosuperior surface, and one on the antero-inferior surface. In 6 cases two ulcers were present. In one case a chronic gastric ulcer was present as well.

Ulcer on the Anterolateral Wall.—The anterolateral wall is the favourite situation for duodenal ulcer. A painful dyspepsia which comes on about 2½ to 3 hours after a meal, that is, at about *the time the duodenum is emptying*—a ‘hunger dyspepsia’—is characteristic of chronic duodenal ulcer in this position. *Fig. 90* is a sketch which shows the usual appearance of such an ulcer when seen at operation.

This painful dyspepsia is relieved by taking a meal, an alkaline drink, or even a drink of water.

The dyspepsia, besides being painful, is sometimes associated with great acidity—acid eructations—and with vomiting; the latter, by causing relaxation of the pylorus, permits a regurgitation of the duodenal contents and therefore a lessening of the acidic concentration.

A 'deep tender spot' over the region of the duodenum is the most important diagnostic manifestation of duodenal ulcer. As has already been pointed out (*see* p. 82) this spot is sometimes difficult

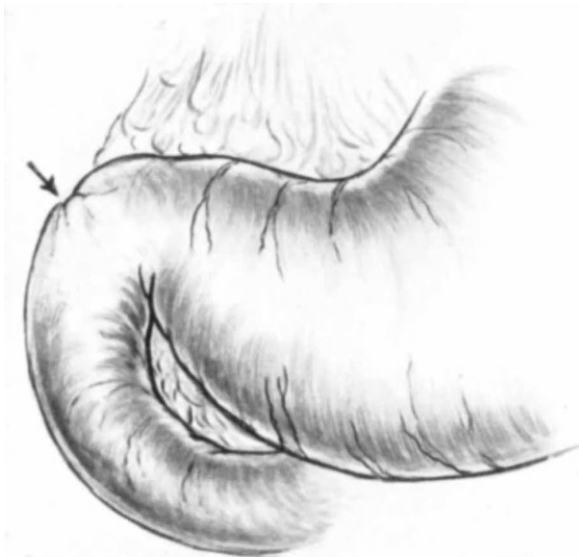


Fig. 90.—Sketch of ulcer of anterolateral wall of the duodenum, showing its appearance when seen at operation.

to distinguish from the 'deep tender spot' of a diseased gall-bladder. *Fig. 38* is a diagram which shows how to distinguish the 'deep tender spot' of duodenal ulcer. The finger-point is pressed towards the posterior abdominal wall, then without changing its position its axis is directed towards the lower surface of the liver. If the axis of tenderness is more towards the posterior wall of the abdomen than upwards towards the base of the liver, especially if in this direction there is no tenderness at the end of a deep inspiration, then the 'deep tender spot' is caused by duodenal ulcer.

The painful dyspepsia of an ulcer on the anterolateral wall may be accompanied by profound attacks of melæna; or by small and continuous bleedings which are only detected when the fæces are

tested for occult blood. Serious bleedings, however, usually come from an ulcer of the posterior duodenal wall.

A striking fact about this duodenal-ulcer dyspepsia is its marked periodicity; indeed, unless the dyspepsia is periodic in character, it is unwise to regard it as being caused by duodenal ulcer.

Ulcer on the Posterior Wall.—A chronic duodenal ulcer of the posterior wall may exhibit the typical painful dyspepsia of a duodenal ulcer on the anterolateral wall. But frequently its main characteristics are a *painless dyspepsia* associated with manifestations of a high acidity, and also in most cases profound attacks of melæna. This type of ulcer does not as a rule give rise to pain doubtless for the reason that it lies on a fixed portion of the duodenal wall which cannot be puckered during the emptying process. It is important to remember, too, that it does not always give rise to a 'deep tender spot'; probably because the peritoneum does not become involved.

Thus the symptoms and signs given by ulcer of the posterior duodenal wall are not generally regarded as those typical of duodenal ulcer; and it is for this reason that the ulcer often remains unrecognized.

Ulcers on the posterior duodenal wall, being as a rule associated with very high acidity, are very chronic and generally penetrate into the pancreas. They are most intractable to medical treatment, and they also present difficulties in surgical treatment. Usually they cannot be cured by gastro-enterostomy, but require an adequate partial gastrectomy or partial gastric exclusion.

As chronic ulcer of the posterior duodenal wall may not cause symptoms, or give any recognizable clinical signs, it is not uncommon for its presence to remain unsuspected by the surgeon when making an exploration of the abdomen. Even when its presence is clinically suspected and it is looked for during an exploration, it may be missed by the surgeon, because it may be quite impalpable on external examination of the duodenum. Thus it is not unusual to see in the autopsy room an ulcer of the posterior wall of the duodenum which had not been diagnosed during life.

COMPLICATED ULCER

The complications of duodenal ulcer (apart from hæmorrhage and perforation) are: (1) Penetration of the pancreas; and (2) Duodenal stenosis.

1. Penetration of the Pancreas.—An ulcer of the posterior wall of the duodenum may ulcerate through all the coats of the duodenal wall and penetrate the pancreas, that is, it may become a penetrating

ulcer. In these circumstances it may give rise to a painful dyspepsia very similar to that of gastric ulcer. The pain may come on from one and a half to two hours after food, and it may be felt on the left side of the epigastrium more than on the right.

An illustration of this type of duodenal dyspepsia is seen in the following case-history :—

A man, aged 37, complained of pain above and a little to the left of the umbilicus. The pain came on about two hours after food and was relieved by vomiting, or by taking food or a bismuth mixture. These attacks of painful dyspepsia occurred during periods of from three to six months. He

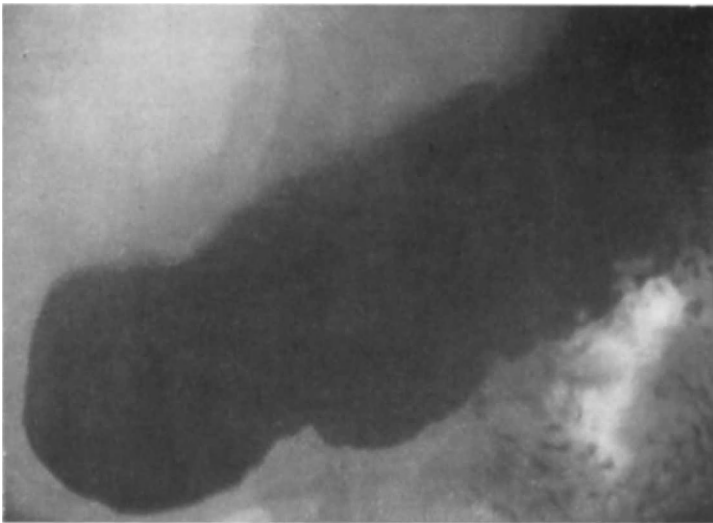


Fig. 91.—Radiograph of ulcer of posterior wall of duodenum penetrating the pancreas. The duodenal bulb has been almost obliterated.

had had several hæmatemeses and attacks of melæna. A clinical diagnosis of gastric ulcer was made.

At operation an ulcer was found on the posterior wall of the duodenum, penetrating the pancreas.

Penetrating ulcers of the posterior duodenal wall, because of the more or less painless character of the dyspepsia caused by them, are tolerated by patients for a great number of years. Furthermore, as they are intractable to medical treatment, they rarely heal. For these reasons, such ulcers are generally associated with a good deal of fibrosis and contraction of the duodenal wall. Hence a radiograph may show no sign at all of a duodenal bulb, as in the case illustrated (*Fig. 91*), where the X-ray examination showed that the duodenal bulb had been almost obliterated. The patient was found

at operation to have an ulcer of the posterior wall of the duodenum penetrating the pancreas. He complained of pain on the left side of the epigastrium, rather diffusely distributed, and very severe. The pain was not relieved by food as it usually is in the ordinary pain of duodenal ulcer. No 'deep tender spot' could be elicited, and the patient volunteered the statement that he had never been tender in this region.

The tendency of a posterior duodenal ulcer to penetrate the pancreas and to cause a *dangerous melæna* is seen in the following case-history (Dr. Wright-Smith):—

A patient was operated on for cholelithiasis nine years previous to being seen, but no calculi were found (probably at that time he was suffering from the effects of the ulcer).

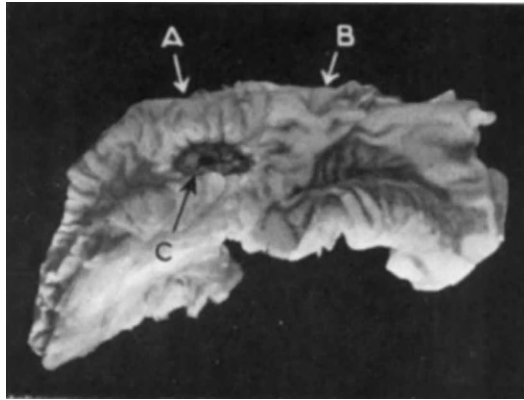


Fig. 92.—Chronic duodenal ulcer (posterior wall) involving pancreas. A, Ulcer; B, Pylorus; C, Open mouth of bleeding vessel. (Specimen 7,35 B, *Walter and Eliza Hall Institute, Melbourne Hospital.* By courtesy of Dr. Wright-Smith.)

He had suffered ever since from attacks of epigastric pain with no definite time relation to food, and with long remissions. He had noticed dark blood in his fæces five months previous to his admission. In the last two years he had lost about three stone in weight. His appetite had always been good. Examination of his abdomen elicited a 'deep tender spot' over the region of the gall-bladder. He had vomited nearly two pints of dark fluid blood. He was explored, and a large chronic ulcer was found on the posterior surface of the duodenum. The patient died after a posterior no-loop gastro-enterostomy operation.

The photograph of the specimen, *Fig. 92*, shows a portion of the stomach and duodenum. One inch from the pylorus, on the posterior surface of the duodenum, is a large oval chronic ulcer. Its walls are raised, thickened, and undermined, and its base is firm and adherent to the pancreas. In the centre of the ulcer is a large open-mouthed vessel, the gastro-duodenal artery.

The following case-history is another example of *penetrating duodenal ulcer of the posterior wall* with special features :—

A patient had severe epigastric pain, which was continuous, and which was very little modified by the taking of food. The pain was somewhat relieved by taking alkaline drinks. He vomited five or six times a day. In four months he had lost three stone in weight. *Fig. 93* is a radiograph of his stomach and duodenum, in which the niche of the ulcer of the posterior wall is clearly visible at *A*. The prepyloric part of the stomach, *B*, shows a

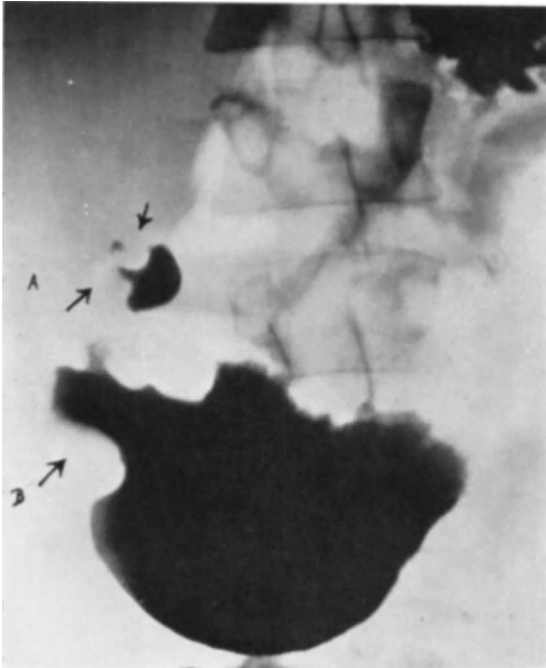

Fig. 93.—Radiograph of ulcer of posterior wall of duodenum. *A*, Niche ; *B*, Fixed prepyloric deformation, probably the result of spasm. (By courtesy of *Dr. John O'Sullivan.*)

persistent sharp deformation, which appears to be a filling defect. Operation showed a large ulcer of the posterior wall of the duodenum deeply penetrating the pancreas, which is depicted in *Fig. 94*.

The patient died. At autopsy it was seen that the prepyloric deformation must undoubtedly have been caused by a spasm, for this part of the stomach was found to be free from organic disease. It is of interest to note from this one case that it would appear possible for a duodenal ulcer to cause a persistent prepyloric spasm.

2. Duodenal Stenosis.—When a duodenal obstruction occurs in an ulcer of the anterolateral wall of the duodenum, it is preceded by the typical painful dyspepsia characteristic of duodenal ulcer.

Not infrequently, however, an almost complete stenosis of the duodenum, causing dilatation of the stomach, may be found, and yet no history of a previous painful dyspepsia be elicited. Such a stenosis can be caused by the healing and contraction of an ulcer of the posterior wall of the duodenum, which may exist, as we have seen, without giving rise to painful symptoms. In a stenosis of this type, because of the absence of previous painful ulcer symptoms, a diagnosis of a malignant pyloric obstruction is usually made. Such

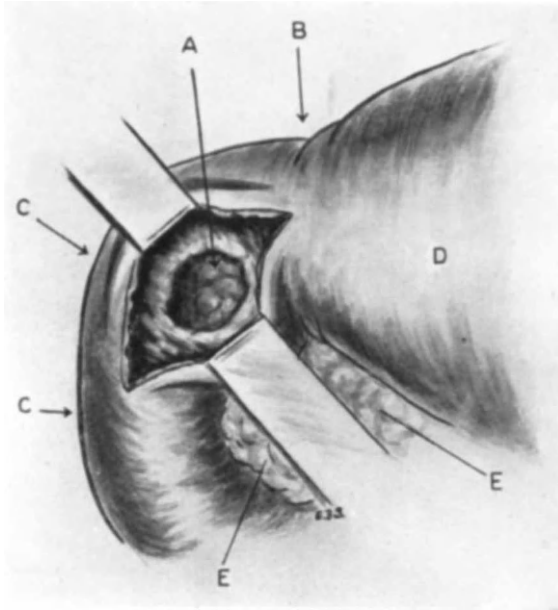


Fig. 94.—Ulcer of the posterior wall of the duodenum, penetrating the pancreas.
A, Ulcer ; B, Pylorus ; C, Duodenum ; D, Stomach ; E, Pancreas.

a form of duodenal obstruction is exemplified in the following case-record :—

A man, aged 50, complained that for nine months previous to being seen he had been vomiting large quantities at the end of each day, that he had lost a considerable amount of weight, and that he had also become very constipated. The most careful cross-questioning could not elicit any history of a painful dyspepsia at any time in his life.

Clinical and X-ray examinations (*Fig. 95*) revealed an enormously dilated stomach, the greater curvature being on a level with the os pubis. At first it was thought that the patient was suffering from a pyloric carcinoma ; but it was felt that the dilatation of the stomach was so enormous that if the obstruction had been caused by carcinoma he could not have lived long enough to produce such distension. Operation showed that the extreme

gastric dilatation was due to a stenosis of the duodenum, resulting from the scar of a healed ulcer of the posterior duodenal wall (*Fig. 96*).

In some cases it is almost impossible to distinguish clinically between innocent duodenal or pyloric obstruction and malignant pyloric obstruction. When such circumstances arise, some help may be obtained from a fractional test-meal. In innocent obstruction a slight trace of hydrochloric acid may be present, though as a rule it is absent; but no lactic acid as a rule is present. In malignant obstruction, hydrochloric acid is always absent and lactic acid is usually present.

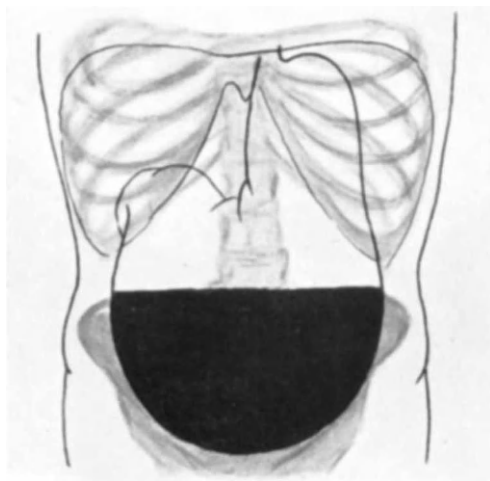


Fig. 95.—Sketch from radiograph of a case of duodenal stenosis, showing the enormous size of the dilated stomach.

Generally, however, a differential diagnosis between innocent and malignant pyloric obstruction is made by means of radiographic examination, which, in the case of carcinoma, may show a prepyloric filling defect.

COEXISTENCE OF CHRONIC PENETRATING DUODENAL AND GASTRIC ULCER

The following case-history illustrates the coexistence of chronic penetrating posterior duodenal wall ulcer, which eventually became stenosed, and penetrating ulcer of the lesser curvature. In this history it will be noticed that the patient suffered only from a painless dyspepsia, and that neither the typical painful dyspepsia of chronic gastric ulcer nor that of chronic duodenal ulcer was present.

A man, aged 40, suffered for four years from fullness after meals, belching of wind, and other dyspeptic symptoms. *He had never at any time had any pain.* At times he vomited large quantities of gastric contents.

A radiograph disclosed a deep penetrating ulcer of the lesser curvature, stenosis of the duodenum, and great dilatation of the stomach (*see Fig. 66, p. 124*).

It was difficult to understand why such a deeply penetrating gastric ulcer did not give rise to pain. The reason for this, however, was obvious at the operation. An old ulcer of the posterior duodenal wall, without giving rise to painful symptoms, had caused almost

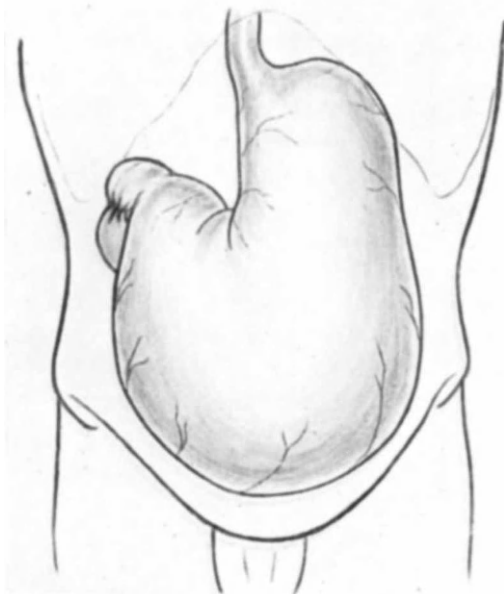


Fig. 96.—Operation sketch of duodenal stenosis caused by scar of healed ulcer of posterior duodenal wall, showing enormous extent of the dilatation.

complete stenosis of the duodenum and great dilatation of the stomach; and in this dilated stomach a deeply penetrating ulcer had formed on the lesser curvature. From an examination of the two lesions there could be no doubt that the duodenal ulcer long antedated the gastric lesion, and that the gastric ulcer had formed in the dilated stomach. Thus, according to my conception of the causation of the pain of uncomplicated ulcer (*see p. 35*), the stomach could never contract sufficiently for the muscular action of the stomach to exert its pressure on the ulcer and thus cause pain.

It is important to recognize that the dilatation from a duodenal (or pyloric) stenosis can render a gastric penetrating ulcer painless;

for such clinical knowledge is valuable in making a diagnosis. For example, in this case, on account of the painless history, the patient had been thought—and on recognized clinical grounds not unjustifiably—to be suffering from malignant disease; on which basis and because of his bad general condition it was regarded as not a suitable case for operation; no suspicion arose that he was suffering from an innocent chronic gastric ulcer.

X-RAY SIGNS OF DUODENAL ULCER

The surgeon, when considering the question of operative interference in a patient with a clinical syndrome indicative of duodenal ulcer, must know what X-ray signs are reliable indications of the condition. They are: (1) A niche—the barium-filled crater of the ulcer; (2) A ‘deep tender spot’ corresponding to the niche; (3) Deformity of the duodenal bulb; (4) Hypertrophy of the mucous folds in the vicinity of a niche or suspected niche; (5) Duodenal stenosis.

The Niche.—In these days of the ‘occasional’ radiographer, the surgeon should know that an expert radiographer can demonstrate an ulcer niche in 90 per cent of cases of duodenal ulcer. It is therefore unwise to accept duodenal deformity as evidence of the presence of duodenal ulcer in the absence of the demonstration of an ulcer niche.

The radiographer may not be able to demonstrate the ulcer as a niche for the following reasons:—

1. The ulcer is not so situated that its barium-filled crater will throw a profile view in an X-ray examination made in the usual way.
2. The ulcer is in such a position that it throws on the screen an *en face* view which is not recognized by the radiographer.
3. The ulcer is situated on the posterior wall, in which position it is difficult to demonstrate the barium-filled crater.
4. The ulcer is so situated that only graduated pressure of the bulb will show the ulcer, and this method has not been employed by the radiographer.

Berg,² of Hamburg, has evolved a technique of “aimed exposure with dosed compression”, by which a radiological diagnosis can be made with great accuracy. The duodenal bulb is first screened from various angles and under various pressures. Where there is any suspicion of an abnormality, by a special arrangement an “aimed exposure with compression” is made from any angle or in any position. The compression enables not only the niche to be radiographed, but also the ‘mucous relief’ of a duodenitis or the pathological changes in the mucous membrane surrounding the ulcer to

be visualized and photographed. The compression cannot obliterate the inflamed and therefore rigid mucous membrane, but it easily causes the 'mucous relief' of the soft normal mucous membrane to disappear, and thus it exposes the diseased area. With this technique it should be possible to demonstrate the niche of a duodenal ulcer in 90 per cent of cases.

The niche is the only definite evidence of a loss of substance from ulceration, and its presence should be demonstrated in two planes. It comprises the barium-filled crater, and the inflammatory reactive tissue changes in the neighbourhood of the ulcer, evidenced

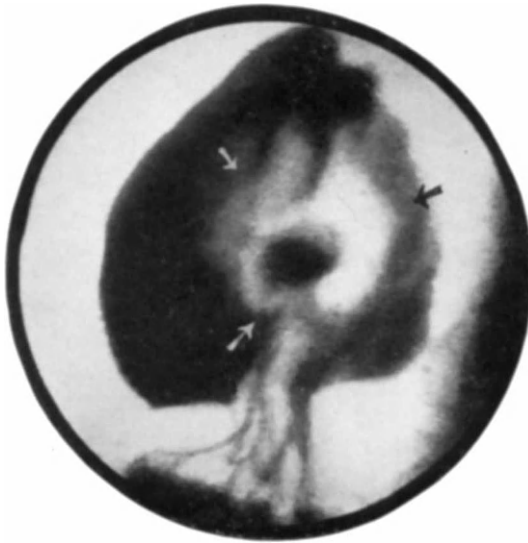

Fig. 97.—Radiograph showing the 'ringwall'.

(*Figs. 97-99 from Berg's 'Röntgenuntersuchungen am Innenrelief des Verdauungskanal'.*)

by deformity of the duodenal bulb and rigidity and hypertrophy of the mucosal folds.

The niche as seen on the X-ray screen should correspond to a 'deep tender spot' on the abdominal wall. But if the niche is the crater of an ulcer on the posterior wall of the duodenum, then there may be no corresponding 'deep tender spot'.

The niche *en face* will show as a circular or oval, well defined opaque deposit surrounded by a transparent ring, called by Berg the 'ringwall'. *Fig. 97* shows this transparent halo round the barium-filled crater. The picture was an aimed diaphragm picture with dosed compression, taken with the patient standing. When the

bulb was distended, this *en face* niche was hidden and could only be demonstrated by the application of a suitable degree of pressure.

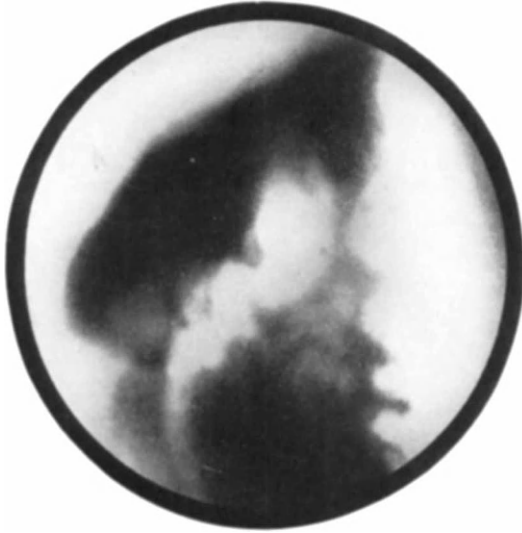

Fig. 98.—Duodenal ulcer with a niche on the posterior wall.

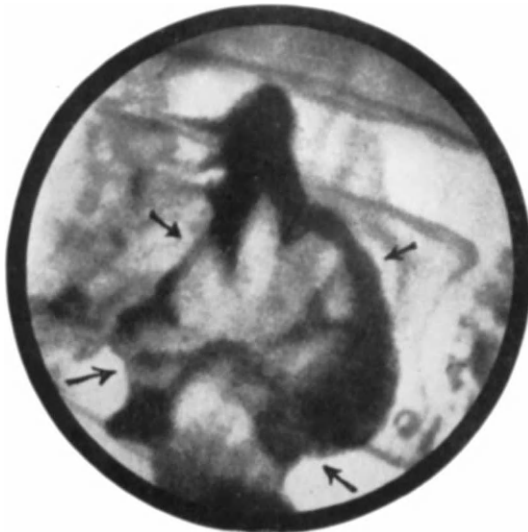


Fig. 99.—Radial convergence of the mucosal folds.

Fig. 98 shows a duodenal ulcer with a niche on the posterior wall. The axis of the bulb is so erected by compression that

the anterior and posterior walls are tangentially radiated. On the posterior wall is seen a funnel-like projection—the *niche seen in profile*—surrounded by a cushion-like concavity; this is the ‘ringwall’ seen in profile. The anterior wall is normal.

The ‘ringwall’ is found in ulcers which are not very old, and which are therefore surrounded by a smooth surface. In the later stages of ulcer, when reactive contractions and scarring take place, a radial convergence of the mucosal folds occurs as shown in *Fig. 99*.

Cordiner and Calthrop,³ who also give radiographs of the ‘ringwall’ (*Figs. 100, 101*), say that when an ulcer of the posterior duodenal wall penetrates the pancreas the bulb becomes fixed, a fact

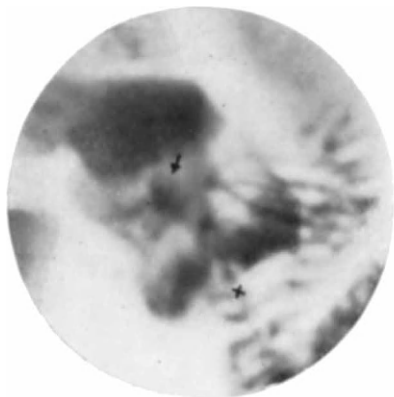


Fig. 100.—*En face* niche with ‘ring-wall’. X, Pylorus. (*Figs. 100, 101* from the ‘*British Journal of Surgery*’.)

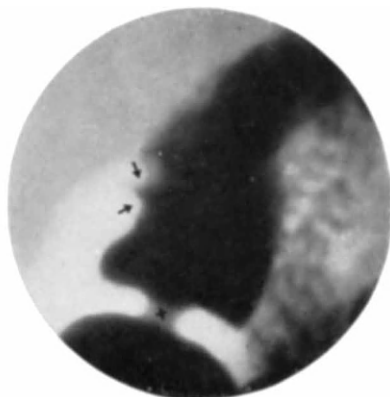

Fig. 101.—The same ulcer as shown in *Fig. 100*, profile view. Niche on anterior wall. ‘Ringwall’ of *en face* niche shows as a concave indentation of profile on either side of ulcer. X, Pylorus.

which can be determined by palpation during a screen examination, when the duodenal wall is put ‘on the stretch’.

‘Deep Tender Spot’ Corresponding to Niche.—If a ‘deep tender spot’ corresponds to a niche, such correspondence may be taken as pathognomonic of the presence of a duodenal ulcer.

Deformities of the Duodenal Cap.—Deformity of the duodenal cap in the case of a chronic ulcer is produced partly by the swollen mucous membrane, partly by the infiltrative thickening of the wall surrounding the ulcer, and partly as the result of scar-tissue contraction in the walls. But deformity of the cap without the demonstration of a niche is not evidence of the presence of duodenal ulcer. A constant deformity of the cap may and frequently does signify the presence of an ulcer, but this is not necessarily the case. Deformities can be caused by an ulcer involving the deeper layers of the

duodenum, and by the fibrotic scarring that results therefrom. They can thus be shown in patients whose ulcers have healed and who are free from symptoms. A deformity of the bulb is also caused by a duodenitis, and it can even be caused by a neuromuscular disorder of the duodenal wall—an irritable duodenum. Therefore deformity of the bulb alone is not for the surgeon a reliable indication of the presence of a duodenal ulcer, even though the duodenal bulb is tender.

REFERENCES

- ¹ WRIGHT-SMITH, R. J., "Peptic Ulcer: Analysis of 218 Cases studied at Autopsy", *Med. Jour. of Australia*, 1937, Dec. 11, 1027.
- ² BERG, HANS HEINRICH, *Röntgenuntersuchungen am Innenrelief des Verdauungskanals*.
- ³ CORDINER, G. R. MATHER, and CALTHROP, G. T., "The Radiography of the Duodenal Cap", *Brit. Jour. Surg.*, 1936, **23**, 700.

CHAPTER XIX

THE DYSPEPSIA OF DUODENAL DIVERTICULUM

DUODENAL diverticula can be divided into three groups: (1) The congenital diverticulum; (2) The acquired diverticulum; and (3) The pseudo-diverticulum.

1. Congenital Diverticulum.—In a congenital diverticulum all three layers of the duodenal wall take part. It corresponds to Meckel's diverticulum. It occurs rarely.

2. Acquired Diverticulum.—An acquired diverticulum is made up of the muscularis mucosæ, the mucosa, and the peritoneum, and is comparable to the diverticulum found in the distal colon.

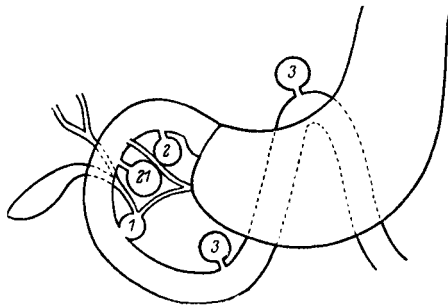


Fig. 102.—Positions in which duodenal diverticula are usually found.
(Figs. 102-105 from 'Der Chirurg'.)

It is of relatively frequent occurrence, and is often found in association with sigmoid diverticula.

3. Pseudo-diverticulum.—A pseudo-diverticulum arises as a result of a pocket caused by the pull of adhesions which have formed on the external wall of the duodenum. It is also called *pulsion diverticulum*. Such a diverticulum may disappear if the adhesions are divided.

Duodenal diverticula are rare before 40 years of age. If they are found before this age, they are congenital. The fact that they are found in older people, in whom the connective tissue apparatus is weakening, suggests that the condition of the connective tissue is probably answerable for their formation. In Fig. 102 are

shown the positions in which they are usually found, according to Abel¹, who, in the clinic of Professor H. Holthusen, found 30 cases in one year.

The diagnosis of duodenal diverticulum is usually only made by X-ray examination, for its clinical picture is not significant. It is often associated with symptoms that are confused with those of carcinoma or duodenal ulcer. These symptoms may, however, have arisen as the result of functional gastric disturbances; and these

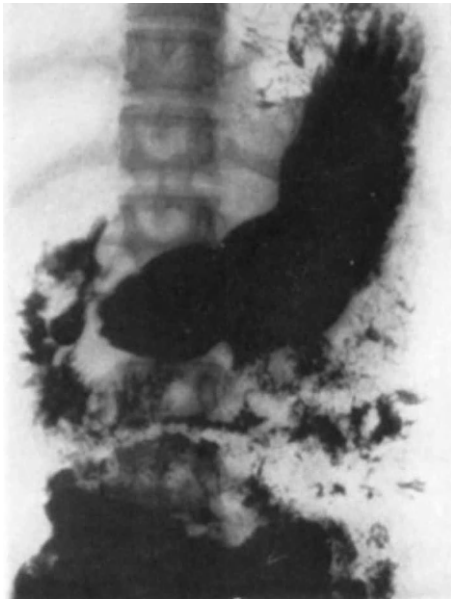


Fig. 103.—A pocket or pseudo-diverticulum in the duodenal bulb caused by the scar of an ulcer.

may have led to the X-ray examination which discovered the diverticulum. Duodenal diverticulum of itself is not a factor in causing symptoms.

The X-ray demonstration of duodenal diverticulum is not difficult, but it must be distinguished from the pocket or pseudo-diverticulum caused by ulcer, as shown in *Fig. 103*, which is the radiograph of such a pocket caused by the gatherings or tuckings originating from the scar of an ulcer of the first part of the duodenum.

Fig. 104 shows a radiograph typical of a diverticulum situated in the duodenal bulb. In this diverticulum the three-layer

picture—barium, secretion, and air-bubble—is seen. In its neck are radiate folds of mucous membrane extending into the diverticulum

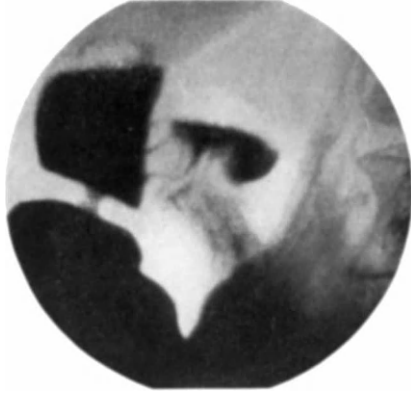


Fig. 104.—A diverticulum in the duodenal bulb. This picture shows also the radiating mucosal folds in the region of the pedicle of the diverticulum

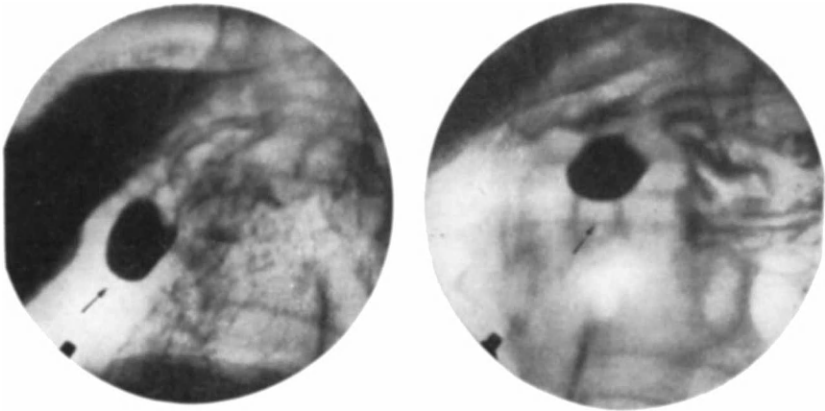


Fig. 105.—Another example of a diverticulum with mucous membrane folds radiating into it.

(Albrecht); these can also be seen in *Fig. 105*, another radiograph of a duodenal diverticulum. The contents of the diverticulum illustrated could be displaced, and its surface was locally tender.

REFERENCE

- ¹ ABEL, W., "Pathologie und Therapie der Duodenaldivertikel", *Der Chirurg*, 1938, March, No. 10, 149.

CHAPTER XX

THE DYSPEPSIA OF JEJUNAL ULCER

GENERAL CONSIDERATIONS IN REGARD TO JEJUNAL ULCER

PRIMARY jejunal ulcer is a very rare disease ; even in 1924 Patterson Brown was able to collect only 35 cases of ulcer of both the jejunum and the ileum ; but jejunal ulcer secondary to gastro-enterostomy is comparatively common. It has been suggested by Walton that

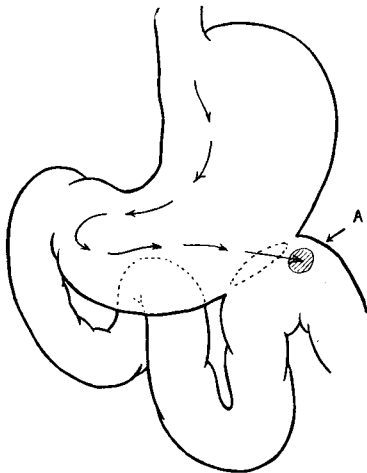


Fig. 106.—Diagrammatic representation of the direction of the current of acid gastric contents in a stomach with a gastro-enterostomy (antiperistaltic). A, Usual site of jejunal ulcer. Arrows show the direction in which the gastric contents travel.

the jejunal ulcer which occurs after a gastro-enterostomy has extended down from a gastro-jejunal ulceration, or in other words, from a marginal ulcer. In my experience, after antiperistaltic gastro-enterostomy the ulcer is nearly always primarily jejunal, and occurs in that situation on the efferent loop where the stream of acid gastric contents is projected by the muscular action of the emptying stomach, as illustrated in *Figs. 106, 107*. This spot is situated on the beginning of the efferent loop, on its lateral wall, about half an inch from the stoma. The situation of the ulcer corresponds to that area in the anterolateral wall of the duodenum on which the stream of gastric contents projected through the pylorus impinges, and where duodenal ulcer commonly develops.

As in the last two decades a very great number of gastro-enterostomies have been performed, many without proper indications and many in unsuitable circumstances, the occurrence of jejunal ulcer has been a feature of modern gastric surgery.

Not only does jejunal ulcer occur after gastro-enterostomy, but it also occurs after partial gastrectomies which have been performed for the cure of duodenal ulcer, especially where the amount of resected

stomach is insufficient. When jejunal ulcer occurs under these circumstances, it forms in the efferent loop—rarely on the margin of the stoma—just where the stream of acid gastric contents impinges on the jejunal wall, and in a position which corresponds to that of jejunal ulcer following gastro-enterostomy. Such a case is shown in *Fig. 108*, in which is also seen a small gastric ulcer.

Jejunal ulcer is rarely found where these operations are performed for gastric ulcer, probably because the gastric acidity associated with this ulcer is lower than with duodenal ulcer. And it is never found where they are done for gastric carcinoma, in which, of course, the acidity is always low.

The formation of jejunal ulcer is sometimes preceded by a jejunitis, the macroscopic characters of which are identical with the 'ulcer gastritis' described by Aschoff, its cause being undoubtedly the erosive action of acid. This jejunitis gives rise to symptoms similar to those of jejunal ulcer.

The following case is an example :—

A patient who had a gastro-enterostomy, and who complained of all the symptoms and exhibited all the signs of a jejunal ulcer, was operated upon with a view to undoing the anastomosis. At the operation no jejunal ulcer could be found, but on the left wall of the jejunum near the stoma was seen an area of jejunitis about the size of a half-crown. In this region the folds of the mucous membrane were very much hypertrophied and the vessels were injected. This area of jejunitis faded away gradually into the surrounding normal jejunum. It corresponded to the usual situation of jejunal ulcer, and without doubt was caused by the impingement of the gastric contents on this part of the opposing jejunal wall.

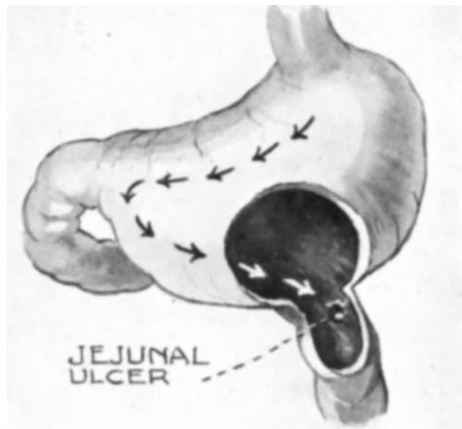


Fig. 107.—Operation sketch showing a jejunal ulcer in the usual position at the beginning of the efferent loop.

CAUSATION OF JEJUNAL ULCER

Judged from a clinical standpoint, the main and perhaps the sole cause of jejunal ulcer is acidic action. For all practical purposes, the other factors usually advanced as causes for jejunal ulcer—suture material, hæmatoma, inaccurate coaptation of the mucous membrane—may be regarded as only contributory. Jejunal ulcer probably arises

under much the same conditions as does duodenal ulcer (*see* p. 103). Moreover, since high acidity is probably the cause of, and therefore usually present with, duodenal ulcer, and since a gastro-enterostomy does not always reduce this high acidity, it follows that jejunal ulcer is frequently found in the wake of a gastro-enterostomy which

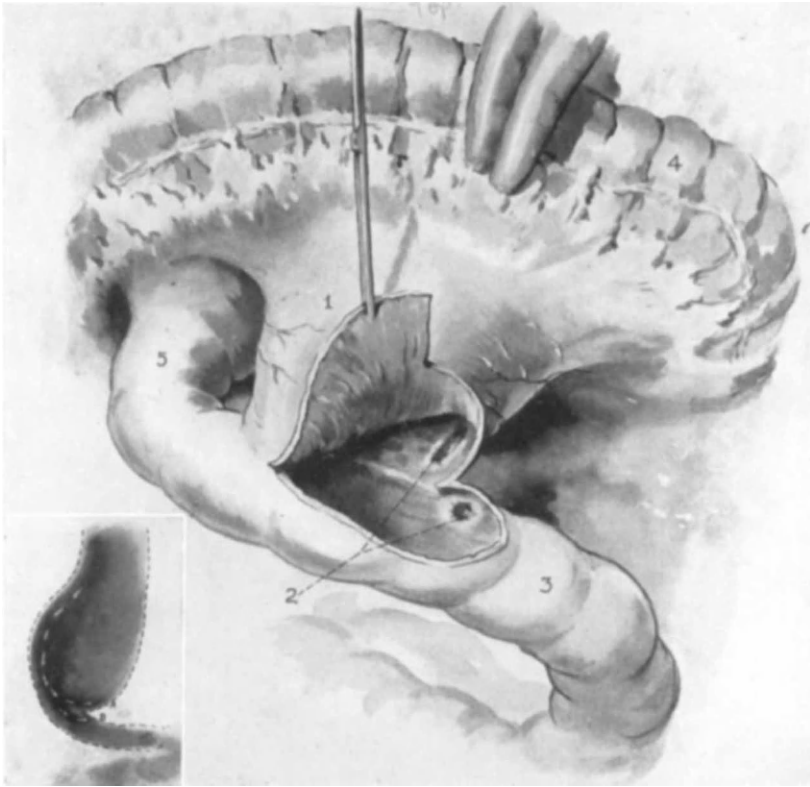


Fig. 108.—Situation of jejunal ulcers after a limited partial gastrectomy—Polya operation. 1, Stomach; 2, Gastrojejunal ulceration; 3, Efferent loop; 4, Transverse colon; 5, Afferent loop.

Inset.—Drawing from the radiograph of this case, which shows what I believe to be the direction of the flow of the gastric contents in the partial gastrectomy here pictured. It explains the formation of the ulcers at A and B.

was performed for a duodenal ulcer associated with a high acidity. Further, if the gastro-enterostomy under such conditions is combined with pyloric occlusion and the whole action of the acid gastric contents is thus made to impinge on the jejunal efferent loop, then the occurrence of jejunal ulcer is very high—as high as 40 per cent.

The occurrence of a peptic ulcer in the jejunum after gastro-enterostomy is explicable on the same basis as that of peptic ulcer of the stomach or the duodenum. Peptic ulcers of the stomach do not form in the fundal zone where the acid is secreted, where, according to Büchner, the mucous membrane seems to have acquired a certain amount of immunity to the action of acid; they form in mucous membrane areas remote from the fundal area; and the more remote the mucous membrane from that which produces the acid, the less is

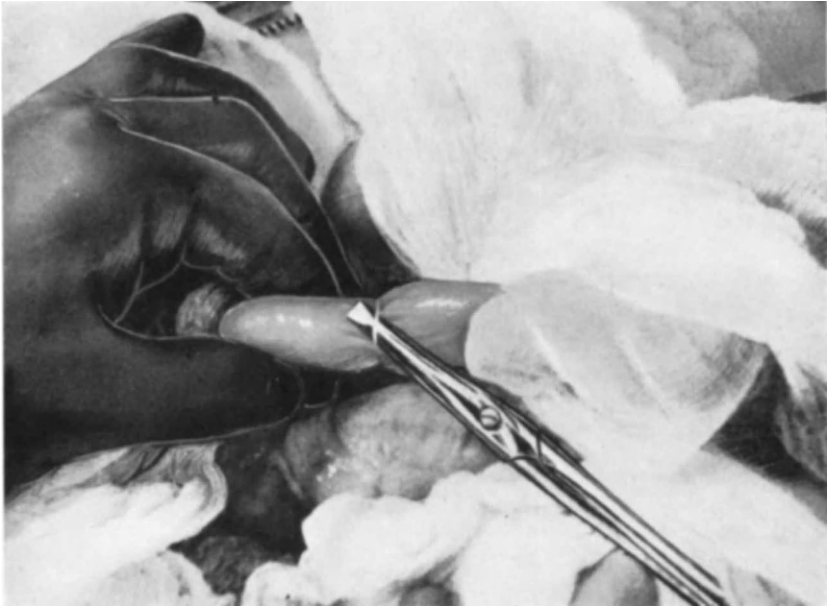

Fig. 109.—Photograph of a silkworm-gut ligature which had been used to occlude the pylorus five years previously. There were practically no adhesions round the silkworm-gut; it had not cut through the tissues, and it had completely occluded the pylorus for that period.

its resistance to the erosive action of the acid. On this account peptic ulcer forms most readily on the jejunal mucous membrane,

Judged from my own clinical experience, this hypothesis would appear to be true. In three patients in whom no duodenal or gastric ulcer existed, gastro-enterostomies had been done under peculiar circumstances of ignorance of surgical pathology. In each case, in addition to a gastro-enterostomy, the pylorus had been completely closed by a silkworm-gut ligature (*Fig. 109*). Such a form of pyloric occlusion, according to my observations in many cases, is permanent, because for some unknown reason the silkworm-gut never cuts out,

and even after a period of five years the pylorus remains completely closed. Thus, in these cases one could be certain that the whole of the acid gastric contents was thrown on the jejunal mucous membrane. In all three patients jejunal ulcer occurred; that is, it formed in patients where previously there had not been a duodenal ulcer, in a jejunum that must have been previously healthy, and as a result of the action of acid gastric contents which had not produced duodenal ulcer.

That the formation of jejunal ulcer which is so often found in association with pyloric occlusion is not caused by the increased formation of acid resulting from the occlusion is suggested by the following observation:—

A patient in whom a gastro-enterostomy had been performed and a pyloric occlusion had been produced by silkworm-gut ligature, developed symptoms which necessitated the undoing of the gastro-enterostomy. As he had been operated on for his gastric trouble six times, the gastric adhesions were intense, and therefore the operation was carried out in two stages. In the first stage the adhesions were removed, the silkworm gut was dissected out, and the pylorus was dilated; in the second the anastomosis was undone, and the openings in the stomach and intestine repaired. Thus it was possible to make observations of the concentration of the gastric acidity before and after each operation. Before the first operation the patient's acidity was 15, 20, 25, with the test-meal. After the first operation, when the ligature had been removed but the stoma had not been touched in any way, the figures were much the same. Evidently the removal of the pyloric obstruction made very little difference to the degree of acidity.

If this observation is correct, then why in the case of duodenal ulcer should not gastro-enterostomy without occlusion be followed by a jejunal ulcer just as frequently as it is in gastro-enterostomy with occlusion? Probably the reason is that the concentrated action of the acid on the jejunal mucous membrane is greatly mitigated by the fact that it has two pathways—through both the stoma and the pylorus; for often the gastric contents go as much by way of the duodenum as by way of the stoma. In my early days of gastric surgery I had proof of this hypothesis. In a few cases where a gastro-enterostomy for a duodenal ulcer had apparently not cured the ulcer I added pyloric exclusion, feeling that I would entirely remove the effects of gastric acidity from the duodenal ulcer. In these cases jejunal ulcer always developed; that is, it occurred in physiological and pathological circumstances which did not beget it in the case of a simple gastro-enterostomy. I feel sure that the pyloric occlusion brought about the jejunal ulcer by causing the whole acid gastric stream to be projected on to the jejunal mucous membrane.

Jejunal ulcers form either years or a few months after a gastric operation. The first patient on whom I did a gastro-enterostomy twenty-three years ago has just returned, suffering for the first time from a jejunal ulcer. Apparently as he got old, and his jejunal mucous membrane lost some of its vitality, it finally succumbed to the continuous erosive action of acid.

When a jejunal ulcer forms a considerable time after the gastro-enterostomy, it is obvious that it cannot be the result of errors in technique, but must be caused by high gastric acidity on a mucous membrane not very resistant to the action of acid—a high acidity which the gastro-enterostomy has failed to reduce adequately.

When a jejunal ulcer forms *soon* after a gastro-enterostomy, it is generally the outcome of some error in technique. A fertile contributing cause of the early occurrence of jejunal ulcer is an inaccurate coaptation of the mucous membrane when making the anastomosis. The mucous membrane is naturally endowed with protection against the action of acidity, but where a wound of the mucous membrane gapes, the acid can act on the deeper layers which are less immune to the action of acid, and thus cause the formation of a peptic ulcer. This inaccurate suturing frequently occurs when the mucous membrane is not sutured as a separate layer.

Another cause which contributes to the early formation of jejunal ulcer is the occurrence of hæmatoma in the line of the anastomosis. Thus the use of clamps predisposes to the occurrence of jejunal ulcer, for when the clamps are removed the sutures cannot always control bleeding and small hæmatomas may form.

The use of unabsorbable sutures is advanced as one of the main sources of jejunal ulcer. As a matter of fact it can only be a very minor factor, as evidenced by the fact that jejunal ulcer is just as common as after gastro-enterostomy performed in the last decade,

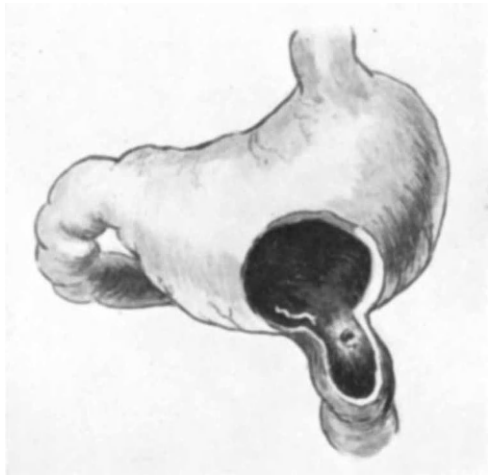

Fig. 110.—Operation sketch showing silk thread without an ulcer in the line of the anastomosis, and a jejunal ulcer in the usual situation.

although silk has been almost abandoned as a suture material for gastro-enterostomy. Furthermore, the following clinical observation seems to prove its unimportance as a factor in the formation of jejunal ulcer. In one case, illustrated in *Fig. 110*, when operating on a patient with jejunal ulcer years after a gastro-enterostomy had been done, I found a silk thread hanging loose in the right edge of the stoma without the slightest sign of any ulceration around it, while a jejunal ulcer was present on the left and posterior portion of the beginning of the efferent loop—the usual position; that is, on that portion of the jejunum where the muscular action of the stomach caused a stream of acid gastric juice to impinge.

CAN THE OCCURRENCE OF JEJUNAL ULCER AFTER GASTRO-ENTEROSTOMY BE MINIMIZED?

The incidence of jejunal ulcer after gastro-enterostomy can be lessened if this operation is so designed that it materially reduces the action of gastric acidity: not only the concentration of the acid, but also the length of time during which it acts on the mucous membrane.

The Cause of High Acidity persisting after Gastro-enterostomy.

—In some cases where the action of gastric acidity has not been reduced after a gastro-enterostomy, the operation has been badly constructed. In others, the gastric acidity to start with has been so high that the most perfectly constructed gastro-enterostomy could not reduce the acidity sufficiently to obviate the formation of jejunal ulcer. In any case, it is probably true that even the most perfectly constructed gastro-enterostomy does not greatly reduce gastric acidity.

Unreduced Acidic Action owing to Bad Construction of the Gastro-enterostomy.—A well constructed gastro-enterostomy will not only reduce the acidity to a certain extent, but also reduce the duration of its action on a mucous membrane—a not unimportant point. A badly constructed gastro-enterostomy will not only fail to reduce gastric acidity, but also, because it has mechanical defects, it will prolong the action of this unreduced acidity on the mucous membrane. Thus a badly constructed gastro-enterostomy is a fruitful source of jejunal ulcer and increases the pathological conditions which beget it.

Where a stoma is made too small, it does not reduce the acidity because it does not permit adequate drainage of food contents or allow alkaline regurgitation.

Where a stoma is placed too far towards the fundus of the stomach, it permits a small 'food rest' to remain for hours in the pyloric part in a sort of backwater, and this 'food rest', by its stimulative action, causes a continuous secretion of acid which, being unbuffered by an

adequate amount of protein food or fluid, erodes the mucous membrane of the empty jejunum and gives rise to jejunal ulcer (*Fig. 111*).

Where the stoma is placed too near the pylorus, it does not lead to quick emptying of the stomach, for the nearer the stoma to the pylorus, the slower the emptying time. Thus the emptying time is not sufficiently hastened, and the reduction of acidic action brought about by good drainage is lost.

Where the stoma is combined with enterostomy, the short-circuiting of the alkaline duodenal contents into the intestine prevents their regurgitation into the stomach and therefore the lowering of the gastric acidity which would otherwise be brought about. An enterostomy is thus a fruitful cause of jejunal ulcer.

Where the stoma is made in a long intestinal loop, the mucous membrane farther down in the jejunum is less resistant to acid, so that a long jejunal loop predisposes to the formation of jejunal ulcer.

Very High Gastric Acidity.—Where the gastric acidity is very high to start with, the most perfectly constructed gastro-enterostomy may not suffice to reduce it adequately, and jejunal ulcer is most likely to occur. Here the fault does not lie with any defect in the gastro-enterostomy, but with the surgeon's bad judgement in doing a gastro-enterostomy in a set of conditions to which it is not applicable. In cases of duodenal ulcer associated with high acidity, some operation other than gastro-enterostomy, such as partial gastrectomy or partial gastric exclusion, should be performed.

Thus it will be seen that the occurrence of jejunal ulcer after gastro-enterostomy can be minimized (not prevented) if errors in technique which reduce the therapeutic effect of a gastro-enterostomy are avoided, and if discrimination in regard to the age of the patient, the percentage of acidity, and the type of lesion is employed.

INCIDENCE OF JEJUNAL ULCER

It is obvious that it is impossible to give reliable statistics as to the frequency of jejunal ulcer in gastro-enterostomy, in partial gastrectomy, or in partial gastric occlusion, for duodenal ulcer. The incidence of

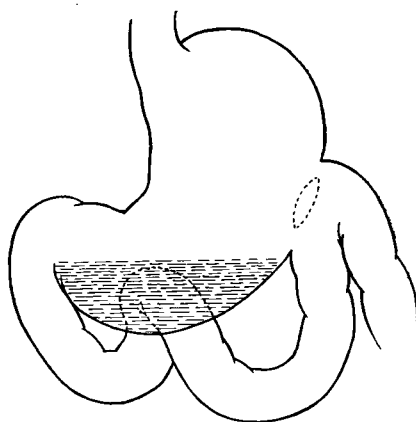


Fig. 111.—Stoma placed too high so that a 'food rest' occurs.

jejunal ulcer is in inverse ratio to the skill and knowledge displayed by the surgeon in performing a gastro-enterostomy based on proper indications and sound physiological and mechanical principles.

In my opinion, jejunal ulcer occurs probably in 20 to 30 per cent of what I might call unsoundly constructed gastro-enterostomies; in from 7 to 12 per cent of soundly constructed gastro-enterostomies and of the limited type of partial gastrectomy which is carried out for duodenal ulcer; and in about 3 to 6 per cent of cases in the radical operation for duodenal ulcer—that is, the operation where two-thirds of the stomach is removed.

The following statistics taken from Kirschner¹ give some idea of the occurrence of jejunal ulcer on the Continent in gastro-enterostomy, partial gastrectomy, and resection with exclusion—all operations employed in Continental clinics for the cure of duodenal ulcer, perhaps of a more serious type than occurs in England or Australia.

RESULTS OF RESECTION AND EXCLUSION (*Finsterer*)

OPERATION	NO. OF CASES	JEJUNAL ULCER
Resection and exclusion without removal of pylorus	81	6.1 per cent (3 cases were in 1919 when inadequate amount of stomach was removed; 3 per cent of jejunal ulcer in operation as now performed)
Modern resection with exclusion operation in which an adequate amount of stomach is removed (last 10 years)	33	3 per cent (1 case)

RESULTS OF GASTRO-ENTEROSTOMY (*Finsterer*)

OPERATION	REPORTER	NO. OF CASES	JEJUNAL ULCER
Gastro-enterostomy	Haberer	365	2 per cent
Gastro-enterostomy	Zukschwerdt und Eck (Enderlen's material)	52 (unresectable duodenal ulcer)	17.3 per cent
Gastro-enterostomy for non-resectable duodenal ulcer	—	—	50 per cent uncured; either the old ulcer unhealed or jejunal ulcer found

In the moderate number of *extensive* gastric exclusions which I have done, no jejunal ulcer has occurred, although some of them have been done for many years. In the earlier and more limited

gastric exclusions, however, jejunal ulcer has occurred, but less often than it does after gastro-enterostomy, and not more frequently than in the similarly limited partial gastrectomy done for duodenal ulcer.

DIAGNOSIS OF JEJUNAL ULCER

Clinical Diagnosis.—Where the immediate convalescence of the patient after gastro-enterostomy has not been satisfactory, the occurrence of jejunal ulcer can be suspected. In other words, it can be expected where there has not been that dramatic relief which usually occurs after a gastro-enterostomy performed for duodenal ulcer, the absence of which generally indicates that there is some mechanical defect in the construction of the gastro-enterostomy.

The syndrome of jejunal ulcer is a painful dyspepsia somewhat like that of duodenal ulcer. The painful dyspepsia, however, occurs sooner after meals—from one-half to one hour after; it is more indefinite in its time relation to the taking of food; it is not relieved so much by alkali; and the 'deep tender spot' with which it is associated is situated to the left and below, rather than to the right and above, the umbilicus. A test-meal usually reveals a high acidity.

In the early stages of jejunal ulcer it is difficult to be sure that an actual ulcer and not a jejunitis is present. A jejunitis, which usually precedes the formation of the ulcer, gives almost the same clinical symptoms. Furthermore, a radiograph does not help, for it is difficult to demonstrate the niche of jejunal ulcer in its early stages.

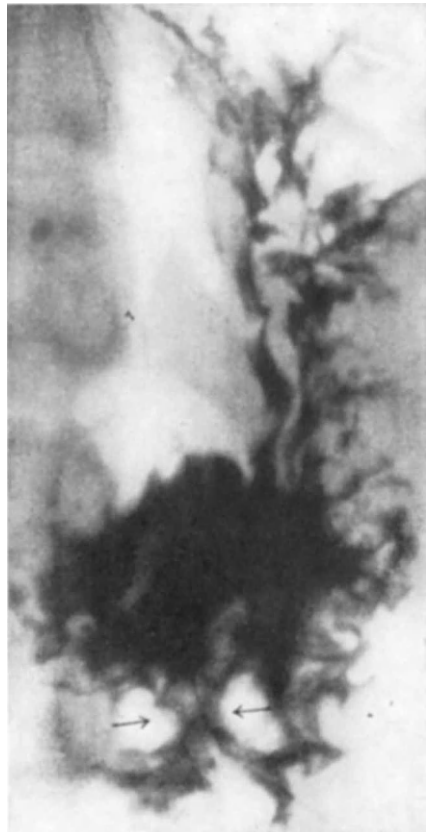


Fig. 112.—Shows swelling of the gastro-enterostomy ring (indicated by arrows) due to gastritis and jejunitis. The patient had vomited blood. No jejunal ulcer could be found at operation. The patient complained of considerable loss of weight.

(Figs. 112-115 from 'Der Chirurg'.)

In some cases this precedent jejunitis may give scarcely any symptoms ; a profuse bleeding may be the only manifestation, and there may be very little if any pain in relation to food. For example :—

A patient who had had a gastro-enterostomy done for duodenal ulcer was well for four years. He then began to suffer from attacks of profound hæmatemesis and melæna, during which his life was in danger. He had no painful dyspepsia. At operation no definite jejunal ulcer could be demonstrated. The bleeding came from a jejunitis.

Another patient had a gastro-enterostomy combined with a pyloric occlusion done for a duodenal ulcer. This patient was bleached white from repeated bleedings, which occurred over a period of two years. He had some dyspepsia but very little pain. At operation no jejunal ulcer was found—only gastritis and jejunitis.

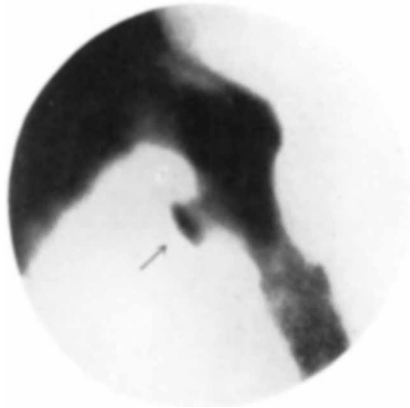


Fig. 113.—Shows jejunal ulcer niche in the beginning of the jejunum.

Sometimes, however, if the jejunal ulcer is very chronic and infiltrates the posterior wall of the abdomen, there will be pain corresponding to that of a penetrating gastric ulcer on the posterior abdominal wall ; that is, pain situated in the left lumbar region, radiating into the back.

X-ray Diagnosis.—A definite diagnosis of jejunal ulcer can be made only by an X-ray examination. It may be possible to demonstrate a niche corresponding to the position of a ‘deep tender spot’. But if the niche of the ulcer is not seen, Berg’s method, in which a relief pattern of the mucous membrane folds of the stomach and jejunum is obtained, may show hypertrophied rigid jejunal folds, indicating the presence of jejunitis, from which a jejunal ulcer as a rule arises, or with which it is usually associated.

Figs. 112–115 (from Berg³) show the various radiographic signs which are found in cases of jejunal ulcer. They serve to demonstrate

the great potentiality of the modern X-ray method in detecting the presence of this form of peptic ulcer. These illustrations also clearly

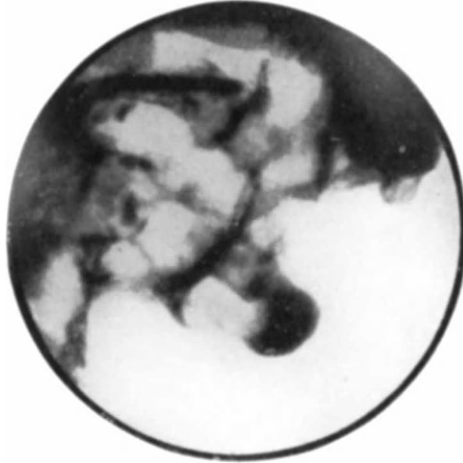


Fig. 114.—Shows jejunal ulcer and a very severe jejunitis. The case was that of a man, aged 32, with two years' gastric trouble following a Billroth II operation (retrocolic anastomosis). Two crater-forming ulcers were found in association with severe antrum gastritis. Note the presence of severe jejunitis in the vicinity of the jejunal ulcer.

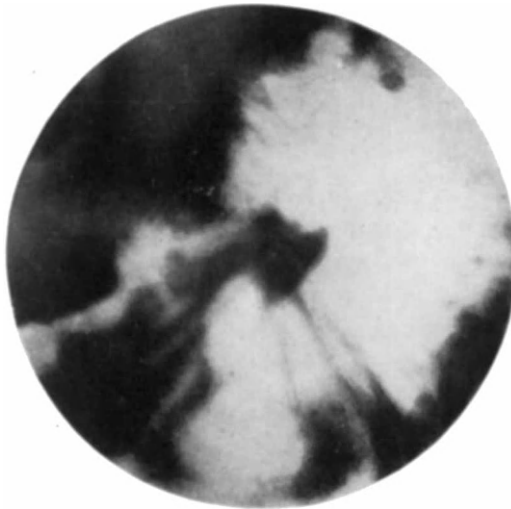

Fig. 115.—Large niche of a jejunal ulcer with an inclination to perforate which followed a gastro-enterostomy. Note the convergence of the mucous membrane folds.

demonstrate the not infrequent association of jejunitis with gastro-enterostomy or partial gastrectomy.

THE DYSPEPSIA OF GASTRO-COLIC FISTULA

A jejunal ulcer which forms where a gastro-jejunal anastomosis has been fixed into the transverse mesocolon too close to the transverse colon may ulcerate into the transverse colon and thus form a gastro-colic fistula.

As a rule, gastro-colic fistula forms during the course of a jejunal ulcer the presence of which, because it gives rise to painful symptoms, is obvious. Furthermore, the transition of this jejunal ulcer into a gastro-colic fistula is usually evident, because the pain and tenderness of the jejunal ulcer disappear, and ill-health, diarrhœa, and constitutional and nutritional disturbances set in.

A gastro-colic fistula may, however, form painlessly; for, as in the case of acute duodenal or gastric ulcer, or a chronic ulcer of the fundus of the stomach, the jejunal ulcer from which the fistula arises may not give any indication of its presence—the patient complains of neither a mild nor painful dyspepsia.

Gastro-colic fistula following a typical history of painful dyspepsia of jejunal ulcer is seen in the following case:—

A man, aged 44, complained of epigastric pain occurring two or three hours after meals. He had a 'deep tender spot' over his duodenum.

At operation a small hypertonic stomach and a duodenal ulcer situated on the anterior wall were found. The duodenal ulcer was excised, and a gastro-enterostomy was done.

Four years after this operation he complained of pain situated on a level with and to the left of the umbilicus. This pain was relieved by food, and accompanied by other symptoms of jejunal ulcer. A year later the pain to the left of the umbilicus disappeared (the jejunal ulcer had perforated into the colon), and he began to complain only of fullness in the epigastrium and on the left side of the abdomen. This fullness disappeared in from half an hour to an hour after meals, and to him it seemed that intestinal movements and diarrhœa followed its disappearance. He passed from six to seven motions a day, but with these he had no tenesmus. His motions showed a great deal of what he called "fermentation". He also complained of a lot of wind and rumbling in the left iliac region. His breath, he said, had become very offensive. He had now no pain after meals. During the last three or four months he had lost energy and become cachectic and had lost 12 lb. in weight. On examination, his abdomen was found to be somewhat distended, and no 'deep tender spot' could be demonstrated.

Radiograph.—The barium meal passed through the stoma but none left the stomach by the pylorus. On giving a clysm a good part of it passed from the transverse colon directly into the stomach.

At a second operation a gastro-colic fistula was found.

The formation of gastro-colic fistula with no indication of the presence of a previous jejunal ulcer is seen in the following rather

THE MEDICAL TREATMENT OF JEJUNAL ULCER

Jejunal ulcer is much more amenable to medical treatment than is generally supposed, and many jejunal ulcers which are operated on could be cured by the physician. Intensive alkaline treatment combined with a proper diet, the application of heat, the administration of large quantities of oil, and rest in bed are recognized medical measures—the same medical treatment which is used for the bad forms of duodenal ulcer. With such medical treatment, especially if it is faithful and prolonged, a jejunal ulcer—even a very bad one—may get better for years. In the event of failure to obtain a cure by this treatment, an Einhorn tube should be allowed to pass through the stoma, left in situ in the jejunum, and the patient fed through the tube. The tube should be passed through the nose. The method, though unpleasant for the patient, has given some very satisfactory results.

The Water Cure.—I have found what I call the water cure to be effective in the treatment of jejunal ulcer. The exact emptying time of the patient's stomach is ascertained by X-ray examination. He is given this information, and instructed to drink a glass of water every ten minutes, while his stomach is empty, until his next meal-time. The water dilutes the undiluted, unbuffered-by-food, resting gastric juice, which otherwise would accumulate in the empty stomach and erode the jejunal mucous membrane.

THE OPERATIVE TREATMENT OF JEJUNAL ULCER

Operative treatment may be as follows:—

1. Resection of the jejunal ulcer with widening of the gastro-enterostomy stoma.
2. Resection of the jejunal ulcer, disconnexion of the gastro-jejunal anastomosis, and suture of the wound in the stomach and the intestine.
3. Partial gastrectomy and enterectomy—the resected intestinal segment including the jejunal ulcer—and the formation of a new gastro-intestinal anastomosis made after the method of Billroth II or of Polya.
4. Extensive partial exclusion.

Resection of the Ulcer ; Widening of the Gastro-enterostomy Stoma.—Jejunal ulcer may be resected ; but if a resection is done, the gastro-enterostomy stoma must at the same time be enlarged. This method of treatment is, however, not very successful, because the pathological and physiological conditions pertaining to the particular gastro-enterostomy, and to the particular stomach in question

—conditions which caused the jejunal ulcer—have not been altered by the resection of the jejunal ulcer. A new jejunal ulcer is therefore almost certain to occur.

Undoing Anastomosis and Resection of Ulcer.—The jejunal ulcer may be resected, the gastro-jejunal union severed, and the wounds thus made in the stomach and the jejunum closed. The continuity of the stomach is thereby restored, and the food passes in the usual way through the pylorus. This procedure is the one to adopt where a patient has had a gastro-enterostomy performed for a duodenal ulcer which was not very chronic, or for perhaps a doubtful duodenal lesion—that is, for a lesion which might have been amenable to medical treatment.

In these circumstances, then, any recurrence of the original duodenal lesion can be prevented by appropriate modern medical treatment; and the patient is spared the danger of a partial gastrectomy for jejunal ulcer—a very serious risk.

Enterectomy and Partial Gastrectomy.—Undoubtedly the most satisfactory treatment for a serious jejunal ulcer is partial enterectomy and gastrectomy. This is, of course, a very difficult operation; and sometimes, where the patient is very debilitated from continual bleedings, it cannot be safely carried out. Under circumstances such as these it may be better to perform an operation less severe but involving the same principles of treatment—namely, a partial gastric exclusion (Devine), in which the jejunal ulcer with the gastro-jejunal anastomosis and two-thirds of the distal part of the stomach are excluded, and the proximal third anastomosed to the jejunum below the original anastomosis.

REFERENCES

- ¹ KIRSCHNER, M., "Die Bewertung der Resektion zur Ausschaltung beim Ulcus Ventriculi et Duodeni", *Der Chirurg*, 1934, March 15.
- ² FINSTERER, H., "Resektion zur Ausschaltung oder Gastro-Enterostomie beim nicht resezierbaren Ulcus Duodeni?", *Zentralb. f. Chir.*, 1934, No. 28, 1634.
- ³ BERG, H. H., "Misserfolge nach Magenoperationen", *Der Chirurg*, 1932, April 15.

CHAPTER XXI

THE DYSPEPSIA OF JEJUNAL DIVERTICULUM
AND OF HIGH JEJUNAL OBSTRUCTIONDIVERTICULUM OF THE UPPER PART
OF THE JEJUNUM

VERY occasionally a large inflamed diverticulum of the upper part of the jejunum will cause a painful dyspepsia coming on about one hour after food, when the gastric contents begin to cause a peristalsis in the region of the inflamed diverticulum. This painful dyspepsia differs from that of gastric ulcer in that it is not relieved by alkaline drinks, food, or the usual remedies for gastric ulcer. An

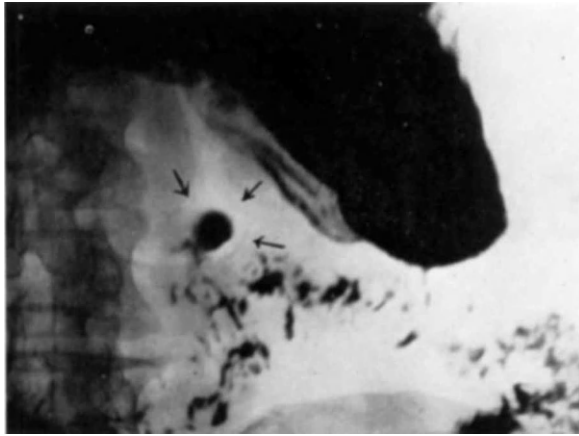


Fig. 117.—Radiograph showing diverticulum of upper part of jejunum. Arrows point to the diverticulum.

exquisitely tender spot is found directly over the diverticulum (as seen under the X-ray screen). The following is an example :—

A woman, aged 65, complained that for twelve months she had had a severe pain coming on about one hour after meals. Alkaline drinks did not relieve the pain. She was exquisitely tender over a small spot which, on X-ray examination, coincided with a diverticulum of the jejunum about as big as the terminal joint of the first finger. This patient also had many diverticula in her colon. The radiograph (*Fig. 117*) shows the diverticulum, the position of which is indicated by arrows. Around it can be seen a white halo, which is probably the inflamed wall of the diverticulum.

HIGH JEJUNAL OBSTRUCTION

In its early stages, the obstruction of the upper part of the jejunum caused by a carcinoma often gives rise to a syndrome of painful dyspepsia which is confused with that of the initial stages of pyloric stenosis. The patient experiences epigastric discomfort—or even pain—after meals, vomits large quantities of bile-stained gastric contents, shows a hypochlorhydria (from dilution of gastric contents), and, when X-rayed, a somewhat dilated stomach. Except for the bile-stained contents, this is a clinical picture of a pyloric stenosis. In the X-ray picture, however, it will be seen that although the stomach may appear dilated, and at first sight as if the dilatation

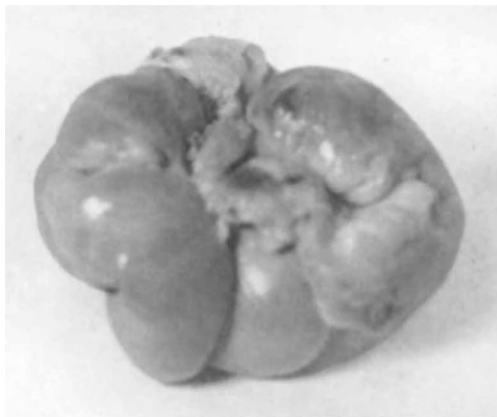

Fig. 118.—Bunch of intestines in the immediate neighbourhood of a carcinoma of the intestine which formed a soft tumour that appeared and disappeared.

has been caused by pyloric stenosis, nevertheless the static barium contents can be 'hand-pushed' through the pylorus.

This form of painful dyspepsia may also come under notice in a patient suspected of having duodenal ulcer, because it is sometimes of the painful duodenal-ulcer type of dyspepsia, the pain occurring two or three hours after a meal. It may also at first confront the clinician as a dyspepsia supposed to be due to duodenal ileus, because a radiograph after a barium meal shows a persistent filling of the second and third parts of the duodenum; that is, shows a dilated duodenum.

It is a clinical fact that it is not diagnosed in its early stages.

Occasionally in cases of jejunal obstruction, especially in their later stages, there may be in the epigastrium or in the neighbourhood of the umbilicus a soft tumour which appears and disappears—

a tumour formed by a bunch of hypertrophied intestinal loops in the vicinity of the carcinomatous obstruction.

Fig. 118 shows a bunch of hypertrophied intestines (removed at operation) which formed in the vicinity of a carcinoma of the intestine, and which became manifest on the abdominal wall as a rather softish uniform tumour, more obvious at one time than another—especially noticeable when the patient was in pain due to spastic contraction of the hypertrophied intestine.

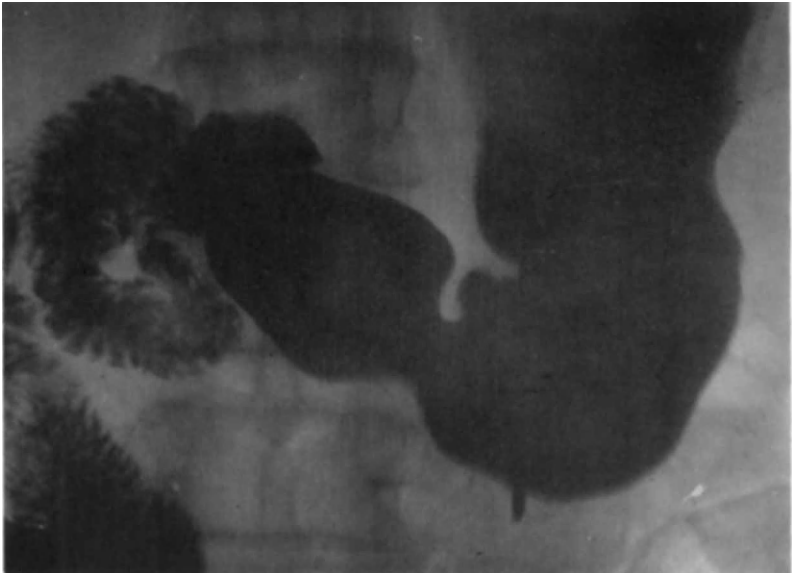

Fig. 119.—Radiograph showing persistent filling of the second and third parts of the duodenum and a dilated loop of jejunum arising to the right of the duodenum.

The following two case-histories illustrate the dyspepsia of high jejunal obstruction :—

The first case was that of a man, aged 61, who consulted a physician because he had become ill with a dyspepsia of a painless type. A test-meal showed an achlorhydria. He was treated with acid mixtures for months, but his dyspepsia gradually became worse.

Two years after the beginning of his illness he began to complain of pain, which came on half an hour after meals, and lasted usually from two to three hours, but frequently for the whole day. This pain was of an aching character and was situated in the epigastrium. It would continue until he vomited a chamberful of bile-stained fluid, in which he could recognize food that he had taken twelve hours previously. Sometimes the odour of the vomitus was distinctly fæcal. He also complained of a pain

over the front of the left kidney, a pain which would come and go. During the last two years he had lost two stone in weight. His bowels were regular and his appetite was fair. The upper part of his abdomen was full and rather tympanitic on percussion. When his stomach was X-rayed, the meal passed down to the duodenum and persistently filled its second and third parts, and then appeared above the duodenal cap and to the right side of the abdomen instead of the left—that is, in dilated jejunal loops situated to the right of the duodenum. *Fig. 119* is a radiograph of this case.

Even at this late stage of this patient's illness a correct diagnosis was not made; for, although clinically he presented most of the symptoms

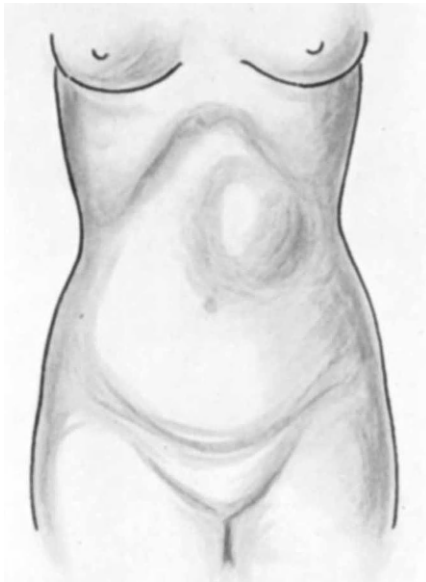


Fig. 120.—Showing situation of soft disappearing tumour.

of pyloric obstruction, radiographically his intestinal condition was not recognized. Operation revealed a carcinoma in the jejunum situated about 18 in. from the duodenum.

The second case was that of a middle-aged woman who became ill with dyspepsia, began to vomit after meals, and to suffer from a progressively increasing constipation. A few months later she began to vomit large quantities of bile-stained vomitus. Examination now showed that she had a tumour on the left side of the upper part of the abdomen (*Fig. 120*). The tumour would disappear from this situation and be found later, perhaps, in the right side of the abdomen about the level of the umbilicus. She had a certain amount of distension in the upper part of the abdomen. When she vomited, this distension would disappear and the tumour could not be felt.

JEJUNAL DIVERTICULUM AND OBSTRUCTION 197

A radiograph showed an enormously distended duodenum and small intestine, the distension of the latter extending to a point about 24 in. from the duodenojejunal flexure (*Fig. 121*).

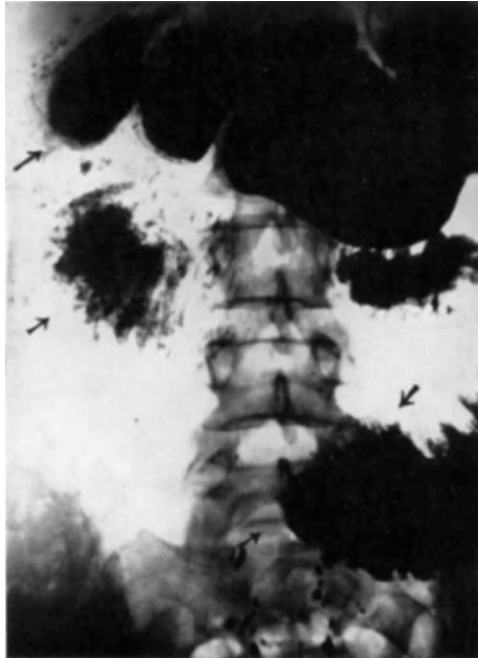

Fig. 121.—Radiograph of the case shown in *Fig. 120*. Arrows indicate the dilated duodenum and the dilated coils of jejunum. (*By courtesy of Dr. J. O'Sullivan.*)

At operation an invasive carcinoma of the scirrhus type without any tumour formation was found. Hard glands filled with secondary deposits were found in the mesentery, and a very large secondary tumour was seen in the liver.

CHAPTER XXII

DYSPEPSIA CAUSED BY ADHESIONS IN THE ABDOMINAL CAVITY

DYSPEPSIA caused by adhesions in the abdominal cavity may arise from adhesions in the following regions: (1) In the vicinity of the stomach caused by inflammatory disease of this organ; (2) In the vicinity of the gall-bladder caused by disease of the gall-bladder or its ducts; (3) In the region of the appendix arising from an inflammation of this viscus; and (4) As the result of operations and the adhesions thereby caused between any of the organs in the abdominal cavity, or between any of these organs and the peritoneum of the anterior abdominal wall—a condition discussed in Chapter XL.

Dyspepsia caused by Adhesions in the Vicinity of the Stomach.

—Adhesions in this region, *perigastric adhesions*, do not as a rule give rise to very definite symptoms of dyspepsia. If the adhesion is a firm one, and connects the anterior wall of the stomach to the abdominal wall, the patient may experience a sensation of fullness on taking a full meal—a filling dyspepsia. He may also experience some discomfort during the emptying stage of the stomach, especially if these firm adhesions connect the pyloric part of the stomach to the liver or to the anterior abdominal wall.

As a rule, the adhesions found after perforations of the stomach do not cause the symptoms usually imputed to them. In the majority of cases these symptoms are due to disease of the stomach itself which has not been cured by the operation, or to a new condition which, like jejunal ulcer, has occurred as a result of the operation.

Dyspepsia caused by Adhesions in the Vicinity of the Gall-bladder.

—Dyspepsia caused by such adhesions is of an indefinite type and not severe, though occasionally the symptoms of extensive disease of the gall-bladder are as much due to firm adhesions to the stomach and duodenum as to the disease of the gall-bladder itself. But in most cases a dyspepsia supposed to be caused by gall-bladder adhesions is due to disease of the gall-bladder and not to the adhesions; and this is true even when there is no very obvious disease of the gall-bladder seen on a superficial examination.

Dyspepsia caused by Adhesions in the Neighbourhood of the Appendix.—Adhesions resulting from a moderate attack of appendicitis do not as a rule cause symptoms. They may, however, be associated with a very mild painless form of dyspepsia, perhaps due to the adhesions, but much more often to the reflex disturbance of the emptying of the stomach from irritation of the sympathetic or vagus fields by a low-grade appendiceal inflammation.

But there is a type of adhesion that sometimes results from a severe inflammation of the appendix and causes a definite dyspeptic syndrome. This adhesion arises in those cases of acute appendicitis, with or without an abscess, in which the appendix is situated under the terminal part of the ileum. The ileum may, in the case of acute appendicitis, become acutely inflamed, or, in the case of abscess, be part of its wall. In either condition, when natural cure takes place, a firm adhesion to the ileum results. This adhesion may cause a kink and a mild obstruction of the terminal part of the ileum, which in turn may cause a dyspeptic picture consisting of more or less discomfort, or even pain, three or four hours after meals—a dyspepsia the basis of which is a chronic obstruction of the ileum.

Dyspepsia arising as the Result of Adhesions caused by Operation.—Following operations, dyspepsia may be caused by adhesions of the small intestine. Where adhesions of the small intestine, especially of the firm ‘pernicious’ type (*see* p. 390), occur between the loops of small intestine, or between these and the scar of the wound in the abdominal wall, they very often give rise to a dyspeptic syndrome, the characteristic feature of which is a mild painful dyspepsia coming on three or four hours after meals. These dyspeptic symptoms are caused by the arrival of food contents in a segment of the small intestine which is mildly or chronically obstructed. The pains are of an intermittent type, and are often associated with a sense of distension in the abdomen. Because of the fairly long interval after a meal, this painful dyspeptic syndrome is not unlike that of a duodenal ulcer. In some of these cases of strong adhesions between the loops of intestine, or between these and the abdominal scar, there is also an epigastric fullness *immediately* after meals, probably caused by the fact that the emptying of the small intestinal segment reflexly interferes with the emptying of the gastric segment.

Dyspepsia and Pain erroneously attributed to Adhesions.—Too often vague post-operative dyspepsia with discomfort or even with pain is erroneously attributed to adhesions. A close investigation may show that in some cases the pains present before the

operation have not disappeared. In certain of these the operation has not cured the original pain. In others it will be found that they are actual organic sequelæ of the illness caused by a pathological condition arising as a result of the operation. And an instance of this latter is seen in the fresh peptic ulcer or in the nausea and vomiting following gastro-enterostomy—symptoms which are the result of a badly performed operation. Further, post-operative dyspepsia may be due to an entirely new pathological condition, which may occur quite independently of the successful treatment of the original disease. Again, it may be a result of unrecognized disease. The original operation may have been performed on an erroneous diagnosis, and the pain may persist after the removal of what was thought to be a chronically inflamed appendix, when it was in reality due to a renal colic or to gall-bladder disease.

It is, however, a fact that functional disturbance is the pathological basis in quite a number of the cases in which dyspepsia, discomfort, and pain follow operations. In these cases, painful contractions of the smooth musculature of hollow organs, contractions which in a normal nervous system would be painless, may be responsible for so-called 'adhesion pains'. In such cases, sometimes seen in women after oophorectomy, the threshold of consciousness for muscular contraction is unduly low; and muscular movements which should be entirely unconscious are felt as pain, and are interpreted as an indication for operation. Operation is, of course, useless and pains persist.

It will thus be seen that the value of an operation for the cure of dyspepsia, discomfort, or pain in patients who have had many operations should be viewed with grave suspicion.

Where adhesions of the small intestine to the abdominal wall, to the omentum, or between loops of the intestine itself, are of the thin, filmy, beneficent type, they do not as a rule cause any dyspeptic symptoms. At operations I have seen adhesions between all the loops of small intestine and from these to the abdominal wall, and yet the patient had no symptoms whatever. Nevertheless some patients whose nervous systems have become debilitated following many operations, and whose threshold of normal physiological stimuli is very much lowered, develop a queer form of dyspepsia as a result of even mild adhesions.

A characteristic of all symptoms caused by adhesions is that they often vary with posture and movement.

CHAPTER XXIII

THE DYSPEPSIA OF BENIGN AND OTHER
TUMOURS OF THE STOMACH

SARCOMA OF THE STOMACH

SARCOMA of the stomach may come under notice with a mild slightly painful indigestion, a hæmatemesis, and on examination an X-ray filling defect—the syndrome being regarded as being caused by carcinoma of the stomach.

It may also attract attention as a case of hæmatemesis without any dyspepsia or constitutional signs. As the hæmatemesis generally arises from an ulcer on the surface of the sarcoma where it bulges into the stomach—an ulcer which will show distinctly in the X-ray examination—the syndrome may be regarded as being caused by gastric ulcer.

Or again, attention may be drawn to it by profound hæmatemeses over a period of years, and when the patient is examined between these attacks, a large deep excavating ulcer may be seen—a chronic ulcer which has its origin on the surface of a chronic fibrosarcoma protruding into the stomach. In a case of this nature the manifestations will be regarded as those of an old chronic ulcer.

In most cases, however, sarcoma is found as a filling defect when the stomach is being radiographically examined in an obscure case of dyspepsia.

My experience comprises three types: (1) Fibrosarcoma projecting into the stomach; (2) Spindle-celled sarcoma with a shallow bleeding ulcer on the most prominent part of its surface, which

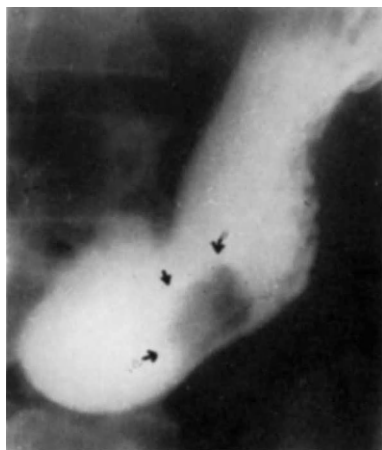

Fig. 122.—Radiograph of fibrosarcoma of the stomach (indicated by arrows).
(By courtesy of Dr. K. S. Cross.)

projects into the lumen of the stomach; and (3) Very chronic fibrosarcoma with deeply excavating chronic ulcer.

1. Fibrosarcoma Projecting into the Stomach.—

In this case a mild, persistent epigastric pain was present after the taking of a full meal. This pain did not occur after small meals. The patient suffered from hæmatemeses. His general health was fairly good. He had some tenderness and rigidity in the epigastrium. *Fig. 122* shows a radiograph of the stomach, in which arrows point to a very definite filling defect, which was erroneously diagnosed by the radiologist as that of

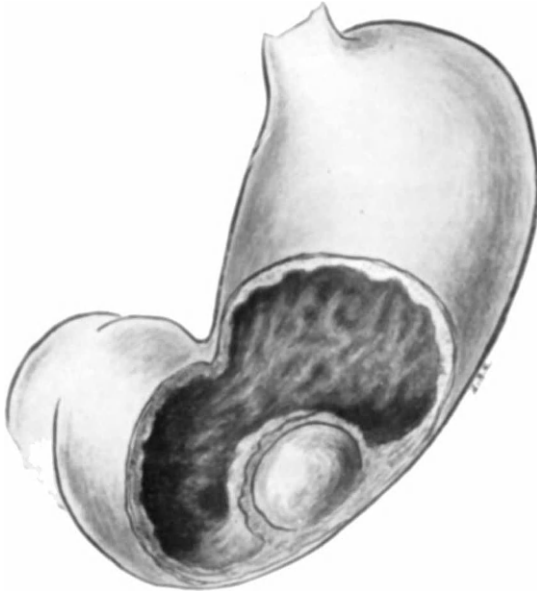


Fig. 123.—Operation sketch of fibrosarcoma of stomach.

a carcinoma of the stomach. The tumour was removed by a limited partial gastrectomy, and proved to be a fibrosarcoma (*Fig. 123*). Six years have elapsed without any recurrence having taken place.

Report on microscopical examination: "An encapsulated tumour consisting of cellular fibrous tissue, the cells being mostly spindle-shaped. Some areas of the tumour are much more highly cellular than others. Diagnosis: fibrosarcoma." (Dr. A. Brenan.)

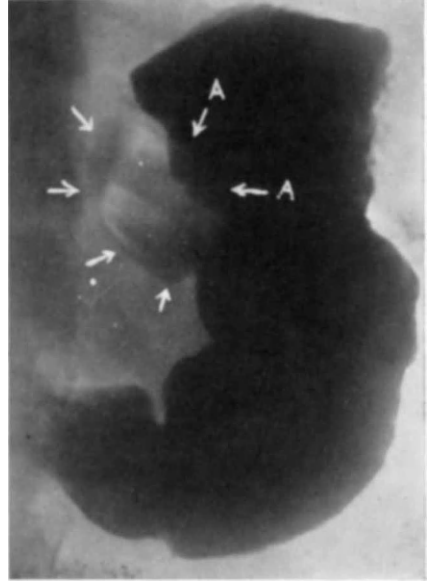
2. Spindle-celled Sarcoma with a Shallow Bleeding Ulcer on its Surface.—

The patient was a woman, aged 38. She complained that she had indigestion, flatulence, and belching after food; that she had had a hæmatemesis four years and another six months previously; and that she had lost about 7 lb. in the last six months. She was very anæmic, and had no epigastric 'deep tender spots'.

A radiograph (*Fig. 124*) showed a shallow niche in the upper part of the lesser curvature, and in connexion with this a round light-coloured shadow as big as an orange, the cause of which, at the time of the radiological examination, was not obvious.

Operation revealed a round mandarin-sized pear-shaped tumour projecting from the lesser curvature near the cardiac orifice.

Fig. 124.—Radiograph of sarcoma of the stomach. Arrows indicate the position of the sarcoma. Arrows marked **A** indicate position of the ulcer on that part of the sarcoma which projected into the lumen of the stomach.



The tumour was dark-coloured and soft, and on the most prominent part of the surface which projected into the stomach a round ulcer about the size of a shilling, with an inactive base and raised edges, was situated.

Fig. 125 is a sketch made at operation, showing the position of the tumour as it bulged into the stomach, and a shallow ulcer on the most prominent part of the projecting surface.

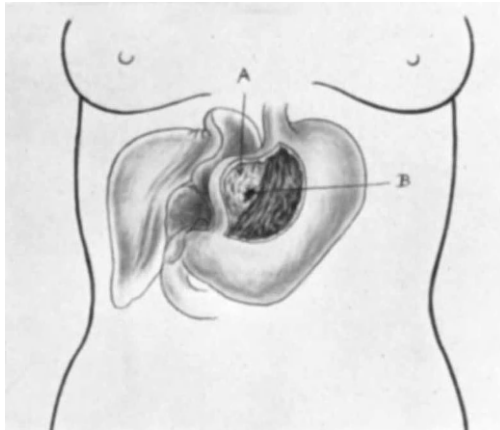


Fig. 125.—Sketch showing position of tumour and shallow ulcer on its projecting surface. **A**, Tumour; **B**, Ulcer.

In the light of the operation finding it is evident that the light-coloured shadow in the vicinity of this ulcer (marked by arrows in *Fig. 124*) is the sarcomatous swelling.

The sarcoma with a considerable part of the lesser curvature on each side of it was removed, and the large gap thus made in the stomach sutured. Seven years have now elapsed and no recurrence of the sarcoma has taken place.

A microscopical examination of the tumour showed a spindle-celled sarcoma.

3. Chronic Fibrosarcoma.—

A patient, a woman aged about 48, came into hospital suffering from a profound hæmatemesis. She complained of slight dyspepsia, but she had no pain after meals. Her general health had been fairly good. Test-meal showed free acid from 20 to 50. The radiograph disclosed on the proximal part of the lesser curvature a large ulcer about the size of a half-crown with overhanging edges and about a quarter of an inch deep.

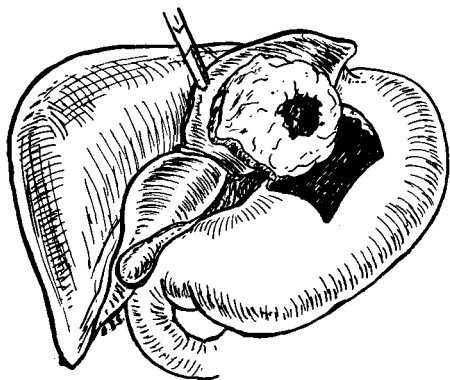


Fig. 126.—Operation sketch of fibrosarcoma of lesser curvature with a large deeply excavated chronic ulcer on its surface.

On account of the fact that this ulcer was obviously of a chronic nature and yet the patient had very little pain after meals, and because it was such a big ulcer, it was at first thought to be malignant. But as a malignant ulcer would not have such overhanging edges, and would not be so obviously seen as a large niche, on second thoughts a diagnosis of large innocent chronic ulcer was made.

At the operation a large deep ulcer of the same size as seen on the radiograph was found. This ulcer, however, was situated on the surface of a large fibrosarcoma which projected into the lumen of the stomach. The fibrosarcoma was adherent to the left lobe of the liver and to other surrounding structures and was irremovable. (*Fig. 126.*)

A microscopical section of the tumour made from an area remote from the ulcer showed a very chronic fibrosarcoma. The patient continued to suffer from two or three profound hæmatemeses each year. Three years later another attempt was made to remove the tumour, and again the operation was unsuccessful.

Eight years after her first hæmatemesis the patient was still alive and comparatively well.

The history of this case will serve to show how very chronic a fibrosarcoma of the stomach can be; how it can give rise to a very large, deeply excavated ulcer with overhanging edges—an ulcer which can be mistaken for a chronic gastric ulcer; and how a fibrosarcomatous ulcer of this nature may be the basis of a recurring hæmatemesis.

MYOMA OF THE STOMACH

A myoma of the stomach may not give rise to symptoms. It may, however, show clinical features exactly similar to those of gastric ulcer. The reason for this is that an actual ulcer often forms on the most prominent part of the myoma where it projects into the stomach where it projects into the stomach.

The X-ray appearances do not differ from those of gastric ulcer. But the presence of a combination of filling defect with ulcer niche will call attention to the fact that an ulcer has formed on a tumour. And as an ulcer niche is not seen in an ulcer of a carcinomatous tumour, this combination of niche and filling defect should suggest innocent tumour.

As a rule, too, the patient does not show signs of the ill-health which would be consistent with the filling defect being carcinoma.

Furthermore, despite the fact that radiological examination demonstrates a deep chronic ulcer which should give a markedly painful dyspeptic syndrome, the patient exhibits clinically only mild manifestations of painful dyspepsia.

The following is a case-history of a myoma of the stomach:—

A woman, aged 65, presented herself for examination because she had passed by the rectum a large quantity of black blood, and subsequently had felt giddy and faint. For many years she had suffered from a burning epigastric pain,

which was aggravated immediately after the taking of food, and was relieved by taking an alkaline powder. Thirteen years previous to admission she

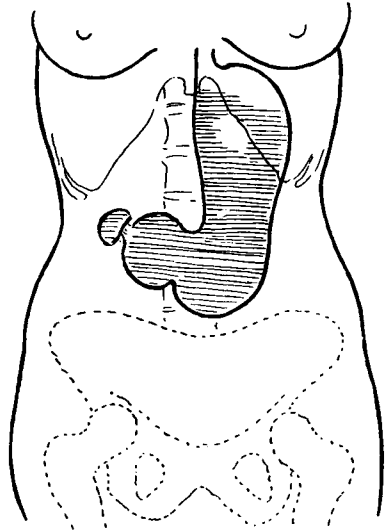


Fig. 127.—Sketch from radiograph of myoma of the stomach.

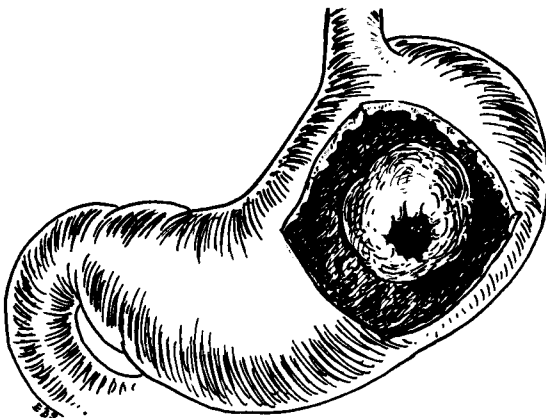


Fig. 128.—Operation sketch to show the position and size of, and the superficial ulcer on, a myoma of the stomach.

had had a bad hæmatemesis and melæna. On examination it was found that she had an indefinite epigastric tenderness, but no tumour could be palpated. X-ray examination disclosed a large ulcer of the posterior wall of the stomach, which was associated with what appeared to be an hour-glass contraction and with a gastric filling defect (*Fig. 127*).

At the operation a tumour of the size of a large orange was found growing from the posterior wall of the stomach, high up in the cardiac end, and projecting upon the peritoneal aspect. When the tumour was removed, an ulcer, 1 in. in diameter and $\frac{1}{3}$ in. deep, was found on the most prominent part of the myoma, projecting into the stomach. The tumour was situated well under the costal margin, and lay in the vicinity of the spleen. Thus it was obvious why the myoma could not be palpated. (*Fig. 128*.)

Microscopically the tumour exhibited interlacing bands of fibrous and muscular tissue.

LIPOMA OF THE STOMACH

A lipoma is rarely found in the stomach, but when it does occur a chronic ulcer may form on that part of its surface which projects into the lumen of the stomach. Confusion then arises in connexion with its diagnosis, for its symptoms and signs are those of gastric

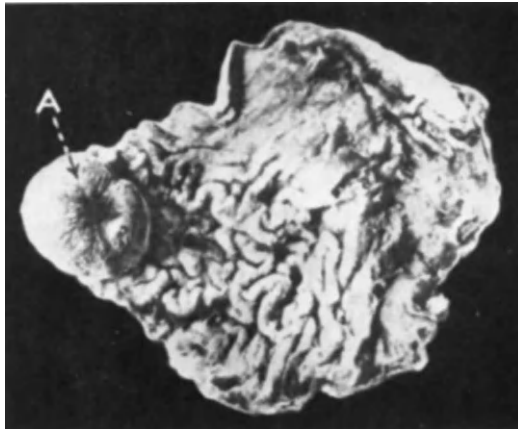


Fig. 129.—Lipoma with an ulcer on its surface. A, Ulcer.
(From the 'Zentralblatt für Chirurgie'.)

ulcer, while its X-ray appearances, showing a filling defect, are those of a gastric carcinoma.

Mandl¹ quotes a case :—

A man, aged 43, complained of symptoms similar to those of a gastric ulcer. His free gastric acidity was 84, total 128. The radiograph showed a sharply defined filling defect about the size of a walnut, close to the pylorus on the small curvature, over which the peristaltic waves passed

without interruption. The region of this filling defect was very sensitive to touch. At operation a lipoma was found situated on the lesser curvature. On the surface of the lipoma was found a sharply defined ulcer (*Fig. 129*).

DIVERTICULUM OF THE STOMACH—GIVING RISE TO ABDOMINAL TUMOUR

Diverticulum of the stomach is a rare condition, and when it does occur it presents a puzzling diagnostic problem. The following is an illustrative case-report of a patient who had a gastric

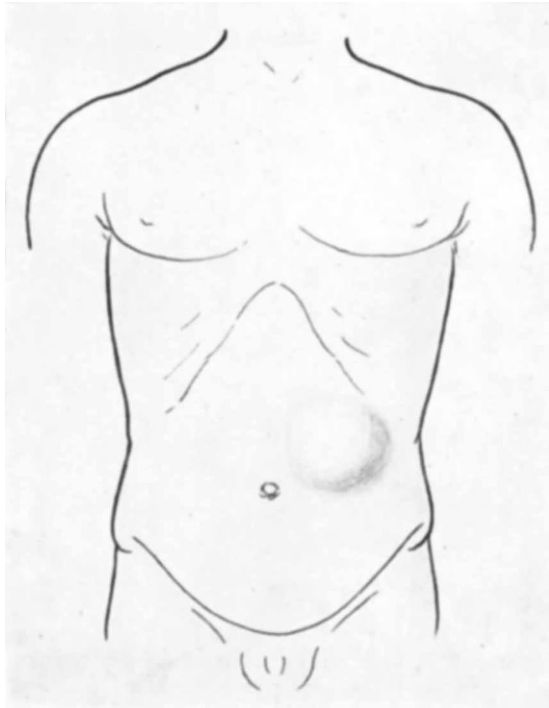


Fig. 130.—Situation of a tumour caused by a diverticulum of the stomach.

diverticulum which gave rise to a tumour in the upper left part of the abdomen :—

The patient, a man aged 36, had been ill for three years. He suffered from attacks of umbilical pain, which lasted from a few hours to a few days. His bowels were more constipated during these attacks, and the pains were worse after food. Lately the attacks had been increasing in severity. On making an abdominal examination a hard round tender swelling, about as big as a large orange, could be felt lateral to and slightly above the level of the umbilicus (*Fig. 130*). X-ray examination showed

that the tumour was situated outside the stomach and lying posterior to it, and that no definite connexion existed between the lumen of the stomach and the tumour.

At operation a large cavity, filled with old-looking pus and detritus and situated between the fundus of the stomach and the pancreas, was found.

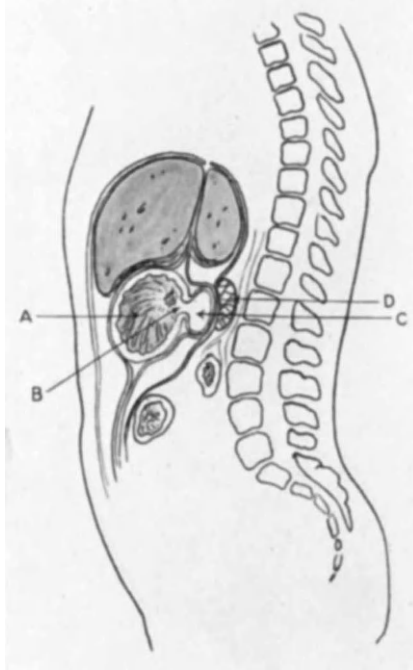


Fig. 131.—Showing the position of the diverticulum of the stomach in the case described. **A**, Cross-section of the stomach; **B**, Opening between the stomach and the cavity; **C**, Cavity covered with serous membrane; **D**, Pancreas.

The wall of the cavity was formed by serous and mucous membrane, and the cavity communicated with the stomach by an opening about 2 or 3 mm. in diameter. The edge of this opening presented no signs of inflammation. The serous and mucous membrane wall of the sac was dissected away, the opening in the stomach closed, and the cavity disinfected and drained. *Fig. 131* is a diagrammatic representation of the position of the cavity.

REFERENCES

- ¹ MANDL, F., and VOGL, A., "Magenlipom und Ulcus pepticum", *Zentralb. f. Chir.*, 1933, Nov. 4, **60**, 2600.

CHAPTER XXIV

THE DYSPEPSIA OF CARCINOMA OF THE
DUODENUM AND STOMACH

THE stomach, the uterus, and the breast are the three organs of the body in which carcinoma is most common. Carcinoma in the stomach has attained notoriety for two reasons: (1) It disseminates early and for this reason is a very fatal form of carcinoma; (2) An early diagnosis is not often made, on account of the fact that its onset is not infrequently 'silent', when its early dyspeptic manifestations are either absent or so slight that they are not appreciated by the patient.

Age Incidence of Gastric Carcinoma.—In the majority of cases, carcinoma of the stomach appears between the ages of forty and sixty. It affects males more often than females, and in the proportion of about three to one.

Site of Carcinoma of the Stomach.—The common site is on the lesser curvature—the gastric canal—or in the vicinity of the pylorus. The reasons for this may be that the gastric canal is the main highway for irritating or hot fluids, that it is subject to small injuries which heal unkindly in this situation, and that it is the favourite site of chronic gastric ulcer.

THE DYSPEPSIA OF CARCINOMA OF THE DUODENUM

It is curious that the incidence of cancer should stop at the duodenum, and that this viscus, perhaps because it is sheltered by the pylorus, remains almost immune from cancer. Cancer of the duodenum does however occur, and it is convenient to consider it briefly here in order that the dyspepsia to which it gives rise may be compared with that of carcinoma of the stomach.

Fig. 132 is an illustration of carcinoma of the duodenum, and the following is the case-history of the patient from whom the specimen was taken:—

The patient was aged 27. She complained that nine months previous to admission she had begun to suffer from pain in the epigastrium. At first the pain was intermittent, but gradually it became constant, occurring immediately after every meal and lasting half an hour, then diminishing

but not disappearing between meals. She had noticed that for some months she had been passing tarry motions. She also said that four years previously she had had what she had been told was an attack of gall-stone colic, and that at that time she was jaundiced and was tender over her gall-bladder.

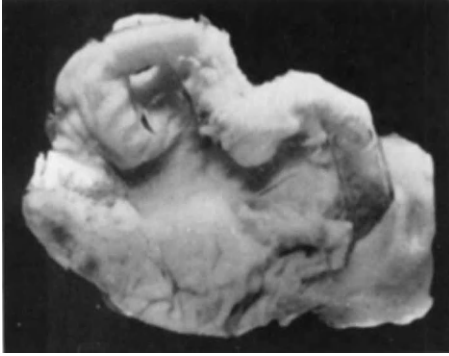

Fig. 132.—Specimen showing carcinoma of the first and second parts of the duodenum. (Specimen No. 7.9223A, Walter and Eliza Hall Institute, Melbourne Hospital. By courtesy of Dr. Wright-Smith.)

On examination, below and to the left of the usual gall-bladder area, a slightly tender, freely movable, and irregular mass could be felt. Radiological examination revealed calculi in the gall-bladder, and an irregular filling defect in the first and second parts of the duodenum.

At operation the calculi were found in the gall-bladder, while a malignant growth was present in the first and second parts of the duodenum. The specimen illustrated in Fig. 132 is the pylorus and the duodenum to near the termination of its second part. The intermediate portion is completely encircled by a firm growth which is commencing to ulcerate. A glass rod has been placed in the common bile-duct, which opened into the middle of the carcinomatous area, and was compressed by the growth. Microscopic examination revealed an adenocarcinoma.

THE DYSPEPSIA OF CARCINOMA OF THE STOMACH

The Mode of Onset of Gastric Carcinoma.—It is highly characteristic of the dyspepsia of carcinoma of the stomach that it occurs in a previously healthy person; a vague type of dyspepsia arising in an adult patient who has had a background of good health and freedom from any gastric symptoms is very likely to be due to gastric carcinoma.

In practice, a broad generalization in regard to the onset of carcinoma of the stomach may be made.

The Onset on a Background of Previous Good Health.—In about 80 per cent of cases, carcinoma of the stomach occurs in a patient who has never been previously sick. Not infrequently he volunteers the information that it is the first time in his life that he has consulted a doctor.

The Onset on a Background of Dyspepsia.—In about 5 or 6 per cent of cases the patient will have suffered from a severe painful dyspepsia typical of chronic gastric ulcer. He will, perhaps, have consulted a doctor because his dyspepsia has altered in character,

become associated with ill-health, loss of weight, and constipation. In such circumstances a carcinoma has developed on an old chronic ulcer—an 'ulcer carcinoma' has formed.

And in about 10 to 15 per cent of cases, carcinoma may develop in patients who are the subjects of a functional or reflex dyspepsia.

How Carcinoma of the Stomach causes Symptoms.—To be able to make an early diagnosis of carcinoma of the stomach—the only kind of diagnosis that is of any avail—it is necessary to understand how carcinoma of the stomach causes symptoms. This it does in the following ways :—

1. By mechanically obstructing the lumen of the stomach, or one or other of its orifices.
2. By infiltrating the gastric wall and disturbing the gastric motor function, and thus causing a dyspepsia which is associated with more or less pain and nausea (a painful dyspepsia).
3. By producing toxic cancer metabolites, which cause hæmolytic and anæmia, loss of energy, wasting, and profound constitutional disturbances.
4. By the effect on the body generally of the ulceration of the lowly vitalized and therefore easily infected cancer tissue.

The predominance of one or another of these factors, or a combination of them, may determine the pattern of the clinical picture of a gastric malignancy—that is, the type of its dyspeptic syndrome.

The Importance of Early Recognition of Carcinomatous Dyspepsia.—Of all the dyspepsias, that of carcinoma of the stomach is the most important clinically, and for this reason it is considered that the subject forms a fitting conclusion to this section of the present volume.

The detailed study of carcinomatous dyspepsia is important because in the majority of cases some form of dyspepsia—sometimes very mild—is usually the first manifestation of carcinoma of the stomach; and if this is promptly recognized and confirmed by X-ray diagnosis, then carcinoma of the stomach can be operated upon in its early stage.

A close examination of carcinomatous dyspepsia is also necessary because its forms are so protean that they can simulate almost any of the dyspeptic patterns which are characteristic of innocent gastric disease. A surgeon must therefore be able to distinguish an early carcinomatous dyspepsia not only by the aid of his knowledge of its vagaries but also by an acquaintance with those forms of dyspepsia of innocent origin in the guise of which it may appear.

Thus an early suspicion that a dyspepsia in its initial stages is of carcinomatous origin means an early X-ray examination, and this means early operation—the most important desideratum in the treatment of gastric carcinoma.

In this account of the dyspepsias of gastric carcinoma I have kept in view one point; that is, to improve our knowledge of the early clinical manifestations of this disease, and thus our early clinical diagnosis. Accordingly, as a result of my experience of cases of carcinoma of the stomach at the operation table, and of reinvestigation of these in the light of the operation findings, I have classified—with a view to assisting their early recognition—various types of carcinomatous dyspepsias, and have set out and considered in detail these types in the remainder of the chapter.

CLINICAL TYPES OF CARCINOMATOUS DYSPEPSIA

1. *A severe painful dyspepsia like that of gastric ulcer* (a type of dyspepsia often confused with that of gastric ulcer).

2. *A mildly painful dyspepsia with obvious ill-health* (a rather common form of carcinomatous dyspepsia).

3. *A severe painful dyspepsia like that that of duodenal ulcer* (an unusual type).

4. *A mild dyspepsia arising only on taking a full meal.* (Important as early indication of presence of carcinoma.)

5. *A very mildly painful (sometimes painless) dyspepsia with good health and normal gastric acidity.* (Important because it is often not recognized.)

6. *Carcinomatous dyspepsia arising on a basis of functional dyspepsia.* (The onset of carcinomatous dyspepsia is obscured by the innocent dyspepsia.)

7. *The dyspepsia (mildly painful) of chronic carcinomatous ulcer.* (Recognition at operation difficult.)

8. *A carcinomatous dyspepsia supervening upon that of old chronic ulcer.* (Changes in the gastric ulcer dyspepsia not recognized.)

9. *The dyspepsia of carcinomatous pyloric obstruction.*

10. *Dysphagic carcinomatous dyspepsia.*

11. *'Silent' carcinoma* (pernicious anæmia type of clinical picture).

12. *Carcinoma in which tumour is the main manifestation.*

1. Severe Painful Dyspepsia like that of Gastric Ulcer.—

In some cases of carcinoma of the stomach, severe pain about one-and-a-half to two hours after meals—a severe painful emptying dyspepsia—so dominates the history that even by experienced practitioners a clinical diagnosis of gastric ulcer has been made.

Usually, but not always, the pathological basis in these cases is a carcinoma involving the lesser curvature, in which tumefaction and invasion of the gastric wall are prominent features. It is the extensive infiltration of the gastric canal (the peristaltic highway) by this type of growth which is probably responsible for the unusual pain as the stomach is emptying.

It is of practical importance to classify and thus draw attention to this carcinomatous dyspeptic pattern, for in these days, when gastric ulcer is so frequently treated medically, this type of carcinoma is not uncommonly treated as gastric ulcer for prolonged periods. The following case-record illustrates this diagnostic error. In this instance the patient was for twelve months medically treated for gastric ulcer, yet even after the lapse of that period of time a partial gastrectomy could be performed successfully :—

The patient, a man aged 50, gave a history of having been ill for eighteen months. His illness had commenced with pain and much fullness in the epigastrium from two to three hours after meals—a painful emptying dyspepsia. This was relieved by alkalis and by belching. Six months after the onset of the illness he began to vomit. The vomiting also relieved the pain. The frequency of the vomiting increased, and during the next three months he vomited every day, four to six hours after meals. (Note the progressive character of the vomiting.) Over a period of twelve months he had been too sick to work, and had lost 12.6 kg. (2 stone) in weight. He had always been constipated, but latterly had to take a great deal more medicine than usual.

On examination, a general epigastric rigidity was found, but no 'deep tender spot'. No tumour could be felt. His blood-pressure (systolic) was 100 mm. Hg.

The operative finding was carcinoma of the lesser curve, involving the prepyloric part of the stomach.

As I have mentioned, this patient's dyspepsia was mistaken for that of uncomplicated gastric ulcer. However, in this case the association of the following features with the painful dyspepsia should have given rise to the suspicion that it was caused by carcinoma of the stomach: (a) The absence of periodicity over a period of twelve months; (b) The progressive character of all the symptoms; (c) The onset of the constipation, which got progressively worse; (d) The progressive loss of weight (nutritional disturbance); (e) Epigastric rigidity in the absence of a 'deep tender spot'; (f) The low blood-pressure (rather common in malignant cases); (g) The spontaneous vomiting. All these are important points in distinguishing between carcinoma of the stomach and gastric ulcer. A careful X-ray examination would, of course, have revealed the carcinoma, but on account of the definite clinical diagnosis, this was not carried out.

Distinction between the Painful Dyspepsia of Gastric Carcinoma and that of Gastric Ulcer.—On broad general grounds, a clinical distinction between the painful dyspepsia of *uncomplicated gastric ulcer* and that of the type of *gastric carcinoma* described above can generally be made. The *painfulness* of a dyspepsia arising from gastric carcinoma is not nearly so severe as that of uncomplicated gastric ulcer. Moreover, a striking feature of the carcinomatous dyspepsia is the presence of nausea and of spontaneous vomiting—not always of food. Further, while in uncomplicated ulcer the stomach unfolds and *fills without the slightest dyspeptic sign*, in carcinoma the unfolding and filling of the stomach nearly always causes dyspeptic manifestations—a feeling of fullness, discomfort, nausea, and sometimes of pain and vomiting. This phase of the dyspepsia—the filling dyspeptic symptoms—is usually mild, and sometimes passes unnoticed, being overshadowed by the painful emptying dyspeptic symptoms. But, though mild, it is of practical importance, because in a case of painful dyspepsia any symptoms or signs which follow quickly on the intake of food, that is, when the stomach is unfolding to receive food, suggest that the dyspepsia may be due to carcinoma rather than to uncomplicated gastric ulcer.

An instance of the significance of this phase is seen in the following case-history of a *young* patient. In this case a gastric-ulcer-like dyspepsia, taken in conjunction with the youth of the patient, very naturally led to an unquestioned diagnosis of gastric ulcer.

A young man, aged 27, complained that he had been ill for nine months. Since the onset of his illness he had got steadily worse; and he had had no remission whatever from his symptoms. He stated that *immediately after taking food* he suffered from dyspeptic symptoms and a severe nagging epigastric pain; that is, *he suffered from a painful filling dyspepsia*. This painful phase then got better, but never quite disappeared, while an hour and a half or two hours after food it became very much worse; that is, a second phase of severe painful dyspepsia developed during the emptying phase of the stomach—a *painful emptying dyspepsia*. A feature of his dyspepsia, too, was that it was associated with quite a *lot of nausea and vomiting*. On examination a small, slightly tender tumour could be felt in the midline between the epigastric notch and the umbilicus.

When this patient was operated on, a uniform infiltrating carcinoma resembling a napkin-ring was found in the prepyloric part of the stomach (*Fig. 133*).

In this case, the *painful dyspepsia* which occurred on the filling of the stomach, the fact that there had been no remission of symptoms over a period of nine months, the spontaneous nausea and vomiting, should have given rise to a suspicion of carcinoma, even in such a

youthful patient. The fact that there was a tumour in the epigastrium was not taken as any evidence of carcinoma, for it was thought that this tumour could well be an 'ulcer tumour'.

This case, then, is a good example illustrating the diagnostic problem of clinically distinguishing the carcinoma of the stomach which gives rise to gastric-ulcer symptoms. An expert X-ray examination would have shown that the condition was carcinoma; but there are types of carcinoma which give rise to a gastric-ulcer-

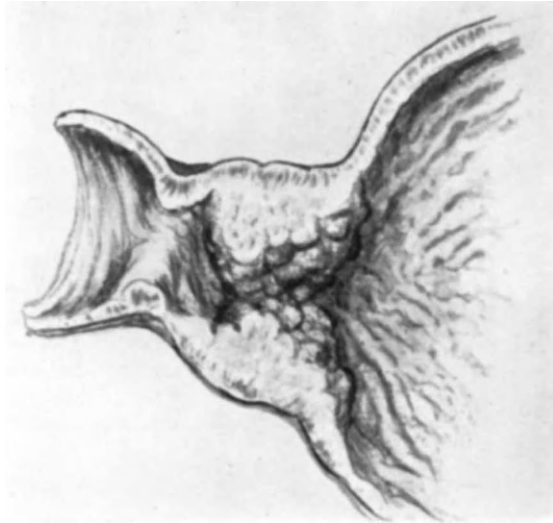

Fig. 133.—Operation sketch of a prepyloric carcinoma giving rise to painful dyspepsia.

like painful dyspepsia, and in which the X-ray signs are equivocal and do not help.

Gastric-ulcer-like Painful Dyspepsia with Equivocal X-ray Signs.—

A painful dyspepsia may arise from a local carcinomatous prepyloric plaque-like infiltration. This is a fibrocarcinomatous type, which infiltrates the gastric canal and the walls of the stomach, and which does not proliferate. It is really the beginning in the prepyloric part of the stomach of a 'leather-bottle' carcinoma.

In such a type of carcinoma the confusion with gastric ulcer is very great. Not alone is this confusion due to the fact that it produces a painful emptying dyspepsia like that of gastric ulcer, but also to the fact that the curious plaque-like spread of this invasive type of carcinoma produces a limited, sharp-edged deformity of contour which is sometimes radiographically indistinguishable from

spasm of the circular muscle of the stomach, often found as an accompaniment of gastric ulcer. The following case is an example of this problem in diagnosis:—

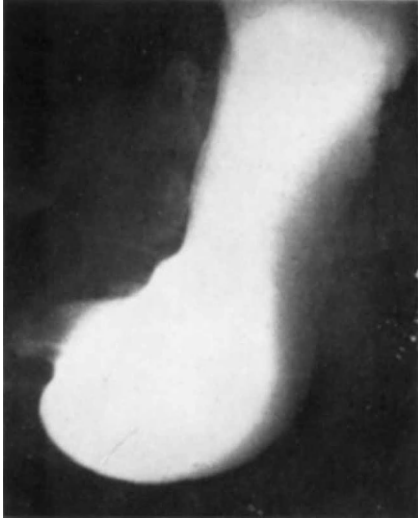

Fig. 134.—Invasive prepyloric carcinoma.

A man, aged 43, complained of what he called a “cold in his stomach”. He could not eat ordinary food, for it gave him pain as soon as he had eaten it; that is, he had a ‘filling dyspepsia’. He also had pain—fairly severe—two or three hours after a meal. He had bad-tasting eructations, and he vomited occasionally in relation to meals. A test-meal yielded the following information: at one hour—free acid 21, total acid 54; at two hours—free acid 40, total acid 58.

X-ray observations showed peristaltic waves passing to the pylorus, but they were slightly interfered with by a persistent prepyloric ‘spasm’—a rather wide incisura. The radiologist’s

diagnosis was prepyloric ulcer. *Fig. 134* is a radiograph showing the prepyloric deformation (taken later in the course of the disease).

The consulting physician’s diagnosis was gastric ulcer.

The patient was medically treated.

After six months’ medical treatment it was noticed that the upper part of the patient’s abdomen had become somewhat rigid; and that notwithstanding this he had no tender spot. Consequently, the rigidity in absence of a tender spot suggested carcinoma rather than ulcer.

At operation, a prepyloric plaque-like carcinoma was demonstrated. *Fig. 135* is an operation sketch showing the type of prepyloric infiltration.

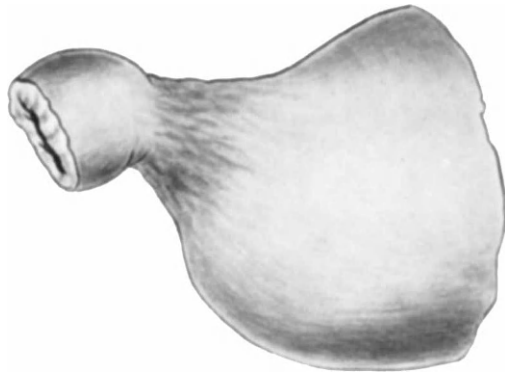


Fig. 135.—Rough sketch at operation, showing the appearance of a plaque-like infiltration of the prepyloric part of the stomach which in its early stages was diagnosed as prepyloric ulcer.

A shrewd analysis of this dyspeptic picture at its onset would have shown that there were symptoms coming on immediately after

the intake of food—a *filling* dyspepsia—and this fact should have excited the suspicion that the dyspepsia was not due to an uncomplicated gastric ulcer. In this case, however, not only was the dyspepsia difficult to distinguish from that of gastric ulcer, but also the gastric analysis showed almost a normal percentage of hydrochloric acid, thus providing additional evidence in favour of gastric ulcer. And again, the spasm-like filling defect seen by X rays lent further credence to the diagnosis of ulcer. Thus the whole clinical picture is a good example of the diagnostic problem in distinguishing between gastric carcinoma and gastric ulcer.

2. Mildly Painful Dyspepsia with Obvious Ill-health.—

Perhaps the common form of a carcinomatous manifestation is a mildly painful dyspepsia, in which the emptying of the stomach is associated with mild pain, and the filling of the stomach is also accompanied by mild pain or discomfort. It is a type of dyspepsia which, because it is mild and indefinite, does not often attract attention early in the course of the disease. The rather indefinite dyspeptic symptoms are usually associated with much sickness and vomiting, with a progressive constipation, and with constitutional symptoms.

Here is a very instructive mistake to show how easily, in these cases of mildly painful dyspepsia, especially in young people, a diagnosis of innocent ulcer may be made:—

A young man of 32, quite healthy-looking, had a hæmatemesis in April, 1936. After he recovered from his bleeding he was X-rayed (*Fig. 136*.) No sign of ulcer or carcinoma was reported. The patient was sent back to work. In October, 1936, he began to get pains in the epigastrium, which would come on during dinner and keep on for about an hour. These pains lasted till December, 1936, when he had another severe hæmatemesis. He was again X-rayed and nothing was reported. Under medical treatment his pains entirely disappeared. This was taken as confirmation that he was suffering from a small ulcer which could not be radiographically demonstrated. He continued to suffer from a mildly painful dyspepsia and progressive ill health until his admission in October, 1937, when he was operated on. Since his first bleeding he had been under the treatment of an experienced consulting physician.

If now the series of radiographs is examined: *Fig. 136*, the first to be taken, shows a peristaltic-like movement at A; but at the apex of this supposed peristaltic curve is a reverse curve, which could not, I think, be present if the deformation were due to a true peristaltic movement; and in the light of after-events it is obviously an indication of a beginning local carcinomatosis. *Fig. 137* shows a radiograph taken in March, 1937, and here can be definitely seen a sharp-edged deformation—an extension of the deformation in *Fig. 136*. *Fig. 138* is a radiograph taken in September, 1937, and portrays the fully developed sharp-edged deformation obviously due to carcinoma.

Fig. 139 is a drawing made at the operation. It shows an infiltrating carcinoma, which started at **A**, where the hour-glass in the radiograph shows, and which spread through the walls of the stomach, especially along the lesser and the greater curvatures, until finally it reached almost to the œsophagus. In this case glandular affection was slight, and even the glands

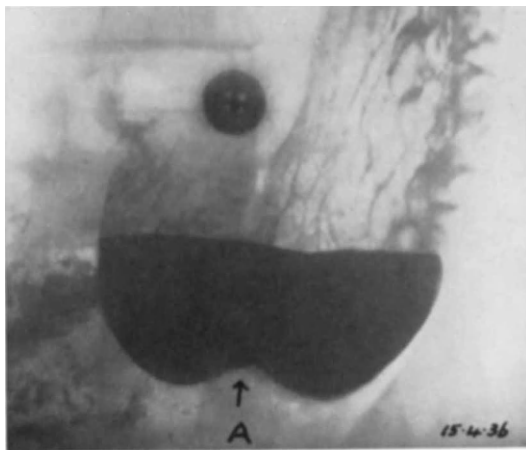


Fig. 136.—Radiograph taken after attack of hæmatemesis.
A, Peristaltic-like curve.

(*Fig. 139, B*) which lay in the midst of the plaque-like infiltration were only mildly involved. There was no tumour formation in the wall of the stomach—only a spreading infiltration. Obviously the growth started at **A**—the hour-glass—and the early clue to it was the slight hour-glass in the first radiograph (*Fig. 136*).

In this case, apart from X-ray manifestations, the pain coming on immediately after the patient took food and lasting for an hour—a painful filling dyspepsia—was definite clinical evidence that the case was gastric carcinoma and not gastric ulcer.

I quote this case at length to show the diagnostic importance of recognizing unusual onsets in carcinoma of the stomach. This patient was handled under the best radiological and diagnostic conditions. What can be expected in average circumstances?

3. Severe Painful Dyspepsia like that of Duodenal Ulcer (an unusual type).—Very occasionally there is found, in a type of carcinoma of the stomach associated with a certain combination of circumstances, a painful emptying dyspepsia coming on about three hours after meals. This dyspepsia is at first sight almost indistinguishable from that caused by duodenal ulcer. It is probably brought about by the painful spastic contraction of the emptying stomach on a prepyloric carcinomatous tumour.

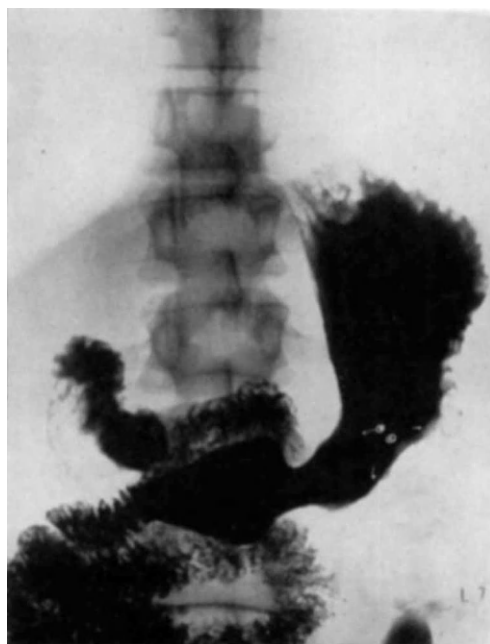


Fig. 137.—Radiograph taken eleven months later.

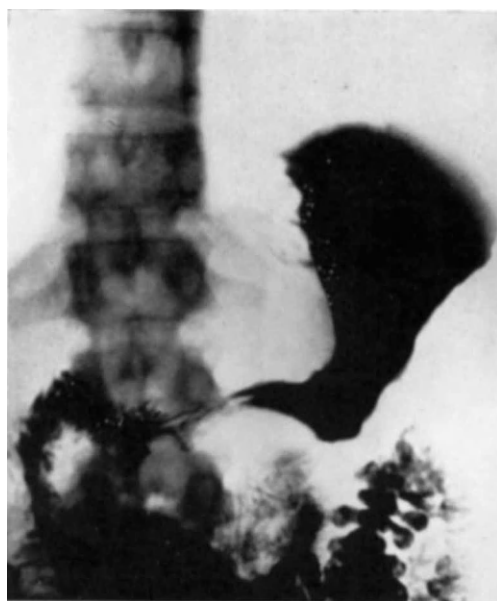

Fig. 138.—Radiograph taken seventeen months later.

The following case-history is an example :—

The patient, a man aged 37, had been ill for nine months. He complained of pain three hours after food : at twelve, at five, and at ten o'clock at night. He obtained great relief on taking food, and some relief on taking alkaline drinks. He had lost 6.3 kg. (one stone) in weight. All

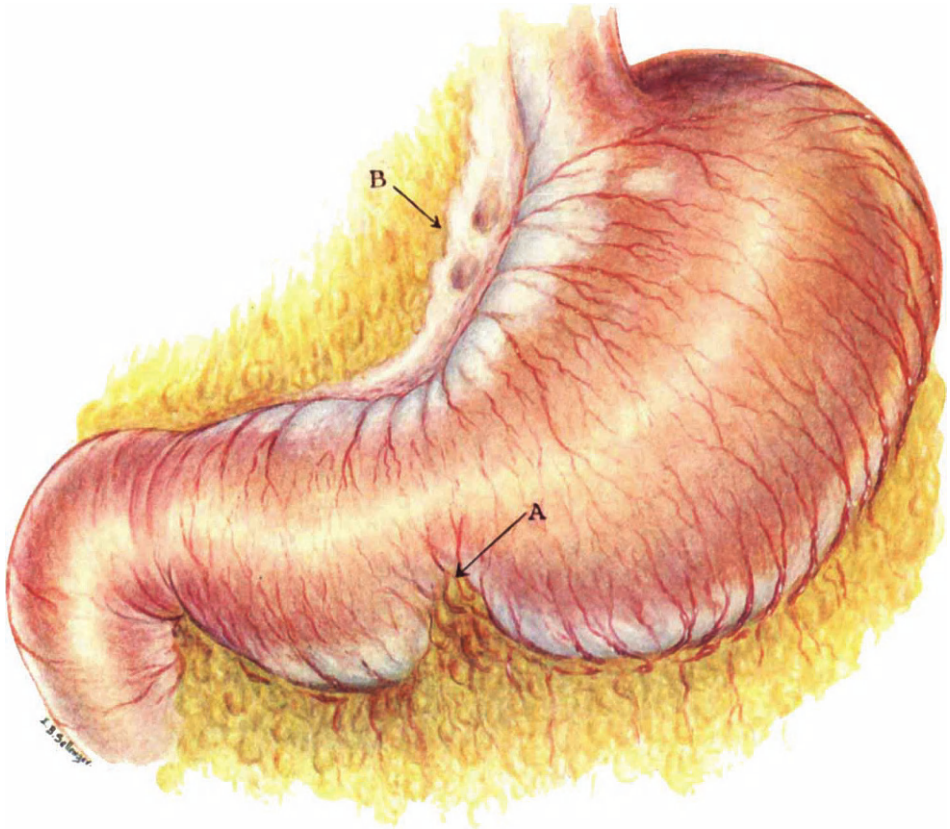


Fig. 139.—Drawing made at operation. It shows an infiltrating carcinoma, which started at A, where the hour-glass deformity shows, and which spread through the walls of the stomach, especially along the lesser and greater curvatures, until it finally reached almost to the œsophagus. B, Plaque-like infiltration, with mildly infected glands. No tumour formation.

the symptoms had steadily progressed without any respite. Examination disclosed that general epigastric rigidity was present, but no tender spot could be found. No tumour could be felt. The patient had been for months under treatment for duodenal ulcer, and not the slightest suspicion of the presence of carcinoma had been entertained. An operation disclosed a carcinomatous lump, extending round and extensively infiltrating the prepyloric region.

Here there were three clinical 'clues' suggesting carcinoma rather than duodenal ulcer: the absence of a 'deep tender spot'; the progressive and non-periodic history; and the distinct loss of weight.

Although this type of carcinomatous dyspepsia is rare, it is important as a clinical observation because it throws some light on how symptoms may be produced in a carcinomatous stomach.

4. Mild Dyspepsia arising only on taking a Full Meal.—

A mild dyspepsia—fullness and discomfort—which comes on only when the patient takes a large meal, is diagnostically important because it is often the earliest symptom of a carcinoma of the stomach; and if particular attention is paid to this form of carcinomatous onset, an early diagnosis of gastric carcinoma may sometimes be made.

The following case-record is an example of this type:—

A surgeon, accustomed to attend an annual medical dinner, found that less food than he had taken at previous annual dinners caused him to feel full and uncomfortable. From that time onwards he noticed that month by month he had to take less and less food in order to avoid a feeling of discomfort. Finally, when I saw him in consultation, nine months after his medical dinner, I found that he had a carcinoma of the stomach, the first symptoms of which had been a mild type of filling dyspepsia, progressive in character, which came on only when he took a large meal.

Apparently the malignant infiltration of the coats of the stomach did not, in its early stages, permit a comfortable *complete* filling of the stomach.

5. A Very Mildly Painful (sometimes Painless) Dyspepsia with Good Health and Normal Gastric Acidity.—Such a dyspepsia is occasionally seen in the early stages of a type of *very slow-growing* carcinoma of the stomach.

Its classification is important because its cause is rarely recognized early. This type of carcinoma begins as a small plaque, is entirely invasive, spreads in the coats of the gastric wall, and scarcely proliferates at all. It causes ill-health that is unnoticeable, at any rate for a considerable time, and it gives rise to a dyspepsia only mildly painful—sometimes painless. Its invasive character produces a sharp-edged deformation of the stomach which is quite unlike the filling defect of a cancer, but very like that of the muscle spasm which accompanies a florid gastric ulcer. If this form of carcinoma begins in the pyloric part of the stomach—the deep peristaltic part—it gives rise to a moderately painful dyspepsia as the stomach empties. If it begins in the fundus, and therefore remote from the deep peristaltic area, it causes only a mildly painless dyspepsia—perhaps only on complete filling of the stomach.

Thus it is a form of gastric carcinoma in which the early diagnosis presents great difficulty. Furthermore, as in its early and middle stages it is not infrequently associated with a normal hydrochloric curve, another misleading sign is provided.

An example of this type is seen in the following very instructive case-history, the subject of which was under expert medical and surgical observation for nearly twelve months before the nature of his disease was definitely diagnosed:—

A man, aged 45, dated the onset of his illness from two years previous to being seen, when he noticed that he began to have discomfort after his evening meal—the biggest meal of the day. This would disappear if he could regurgitate wind. If he was “careful with his food”, i.e., did not take too much, he would not get this discomfort.

For a time he began to lose weight, but later he gained weight. At intervals occult blood was found in his stools. At this time a radiograph showed a *mild* but rather extensive sharp-edged deformation on the greater curvature and to a certain extent on the lesser curvature, the upper end starting about 2 in. from the œsophagus. In view of his good health and healthy appearance this defect was not regarded as being caused by an organic lesion, for it was thought that if the deformation were due to malignancy a tumour of the size indicated by the deformation must certainly cause gross ill-health or be palpable, and on abdominal examination nothing could be felt. He was able to play golf well. His appetite was good; but, because his stomach felt full, he had to stop eating before he wished to do so. A further reason for not regarding his condition as malignant was that his free hydrochloric acid was 40. On medical treatment he had gained quite a lot of weight. He was florid-faced and healthy-looking.

Fig. 140 is a radiograph taken fifteen months after the beginning of his illness, which shows the extensive deformation of the upper part of the lesser curvature and greater curvature.

On the assumption that his case was not carcinoma he went on fairly comfortably, playing golf and carrying out his daily work. Then one day he presented himself complaining of a tender feeling in the navel. When this was examined there was found a definite, hard infiltration of the umbilicus, which was not tender. He eventually died with a carcinomatous ascites.

In this case-history the features which deserve attention are:—

1. The rather long history.
2. The fact that, if the stomach were completely filled, he had a mild filling dyspepsia.
3. A normal hydrochloric acid curve, which was present even eighteen months after the onset of his illness.
4. The patient's comparatively good health, good appetite, good energy—evidenced by his florid healthy appearance, and the fact that he could play golf well eighteen months after his illness commenced.

The Late Stages of this Invasive Type of Carcinoma are generally known as 'Linitis Plastica'.—In a small proportion of cases, the type of growth just described is so very chronic and so mildly toxic that the patient lives long enough for it to spread through the coats of the whole stomach. Thus not infrequently the course of the growth may extend over four years. The tendency of this type is to spread in the peritoneum by permeation to the adjacent organs ; it does not

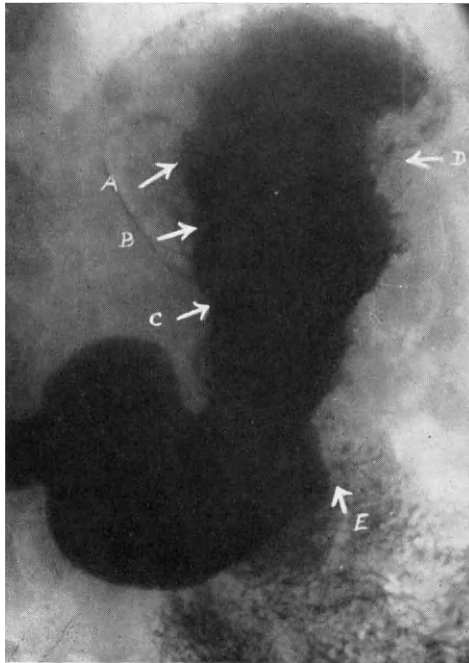

Fig. 140.—Radiograph of carcinoma of the stomach. Arrows A, B, C, D, E show an extensive irregular indentation.

form distant metastases. As its permeating strands of cells spread into the circular lymphatics of the bowel and cause a contraction like a 'ring' carcinoma they may bring about obstruction of either the small or the large intestine, or of both.

The following case-history is a typical example of this type of carcinomatous dyspepsia :—

The patient was a woman, aged 37. Her illness began with nausea, mild pain *immediately after meals* (a filling dyspepsia), and loss of weight. Examination (many months after the onset of her trouble) revealed a tumour in the epigastrium. X rays showed that the stomach was deformed—like a champagne glass with sharp-edged contours—and that it emptied quickly.

At operation it was seen that the tumour which had been palpated was really the whole stomach, the walls of which were uniformly infiltrated, hard, and half an inch thick : it was a 'gizzard' carcinoma of the stomach.

The subject of this history lived nearly four years after this operation, and the last eighteen months of her life were spent in great misery. The growth spread from the stomach to the neighbouring viscera. It first spread round the lymphatics of the transverse colon, and produced a ring-like carcinomatous obstruction, for which a colostomy was done. Several

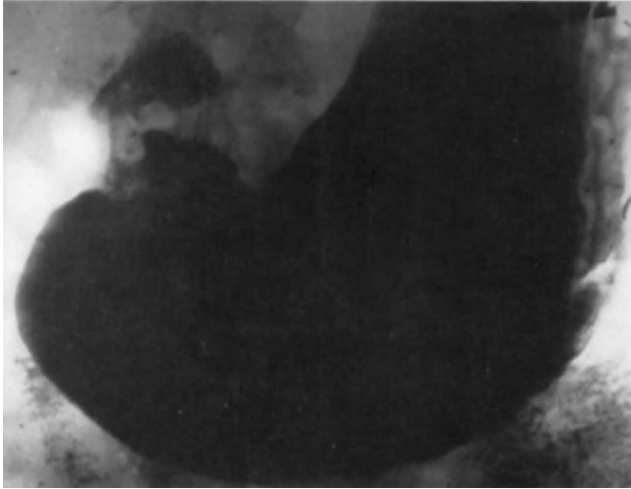

Fig. 141.—Radiograph of a prepyloric carcinoma which occurred in a patient suffering from a dyspepsia of innocent origin.

months later it produced a ring-like obstruction of the small intestine by permeating into its lymphatics. To remedy this obstruction an enterostomy had to be done. Never were there any metastases in the liver or in the glands.

A lymphatic peritoneal widepread dissemination is the striking feature of this kind of carcinoma.

6. Carcinomatous Dyspepsia arising on a Basis of Functional Dyspepsia.—The onset of a carcinomatous dyspepsia may be obscured when gastric carcinoma occurs in a patient who has been suffering from a functional dyspepsia. As a rule, it is unusual for carcinoma to occur in a chronic dyspepsia ; therefore when it does occur the alteration in the dyspeptic pattern may pass unnoticed because its advent is unexpected.

The following is a case-report of a patient who had suffered for years from a 'functional dyspepsia' and who developed a prepyloric carcinoma.

A man, aged 50, complained that for twenty years he had had "stomach trouble"—discomfort, flatulence, and fullness after meals. X rays, six

years previous to being seen, showed that there was a certain amount of spasm in the prepyloric part of the stomach; that it was never possible to visualize the duodenal cap; that the peristaltic waves were poor; and that the stomach was dilated, but emptied in three hours.

The patient consulted his doctor because his dyspepsia, he said, had changed in character and become much worse. He had begun to suffer from more flatulence, much sickness and nausea after meals, pains under his shoulder-blades, and general ill-health. He had now to induce vomiting in order to get relief from his continual nausea, and he could not sleep on account of a constant pain in the right side of the epigastrium.

A radiograph of his stomach (*Fig. 141*), when compared with one taken six years earlier, showed that although the stomach was more dilated it still emptied in the same time. But now it revealed a filling defect in the prepyloric area, that is, in a region which in the previous radiograph could be seen to be normal.

In this dyspeptic picture the changes which indicated the development of carcinoma were: (1) the advent of nausea, sickness, and vomiting after meals; (2) the introduction into the dyspeptic picture of more or less constant pain; (3) that there had recently been a definite onset of a period of *bad health*; and (4) that it was possible, in this case, to compare the present radiograph of the stomach with that taken six years previously, when the alteration of the prepyloric contour was at once obvious.

Operation revealed that this man had a prepyloric carcinoma, and secondaries in his liver.

7. The Dyspepsia (mildly Painful) of Chronic Carcinomatous Ulcer.—Occasionally carcinoma of the stomach takes the form of a very chronic localized ulcer with no peritoneal dissemination or metastasis to glands. In the pyloric region it gives rise to more or less severe painful dyspepsia, but in the fundus it may cause only a painless or mildly painful dyspepsia. When seen at operation, this malignant ulcer is difficult to distinguish from innocent chronic ulcer. Radiographically, it does not show a definite niche, because the crater of the ulcer lies inside the contour of the stomach, and therefore does not show in profile.

The following case-history exemplifies the manifestations of this type of carcinoma:—

A male patient complained of "stomach trouble" on and off for years. For the past twelve months he had had a dull, aching epigastric pain about three hours after meals, which was relieved to a certain extent by taking food. During the past six months the pain became more or less constant, and was not affected by food or alkali, but it got better if he starved himself. During the past three months he had had attacks of sharp cutting pain under the left costal margin, accentuated by expiration, and eased by lying down. He had lost one stone in weight in six months.

Apart from a slight tenderness above and to the left of the umbilicus, physical examination was negative. Fractional test-meal showed a low normal acid curve. X-ray examination revealed an indefinite irregularity

in the mucosal passage at the pyloric end of the stomach, but no ulcer or carcinoma.

At operation an ulcer as large as a half-crown, with thick edges and firm base, was found in the fundus in the situation shown in the operation sketch (see *Fig. 81*, p. 149). No definite contracting infiltration or permeating nodules were seen in the vicinity of the ulcer. It was very difficult to decide whether it was innocent or malignant. It was resected, and a microscopical examination showed that it was malignant.

This localized malignant ulcer was not detected by X-ray examination. But in the light of operation findings the ulcer can be mapped out in the mucous-membrane-relief radiograph (*Fig. 142*).

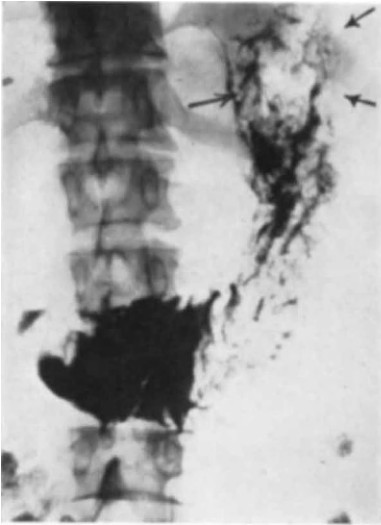

Fig. 142.—Radiograph showing mucous-membrane relief. Arrows mark position of the ulcer. (Cf. *Fig. 83*, p. 150.)

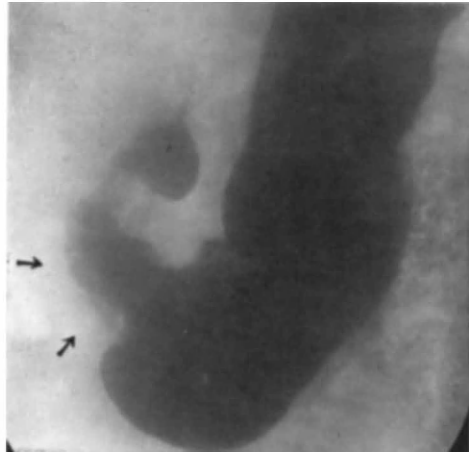


Fig. 143.—Radiograph of malignant ulcer in prepyloric region. Arrows point to the position of the ulcer.

In *Fig. 83* (p. 150) is shown a radiograph of the barium-filled stomach in this case, in which the position of the ulcer is indicated. No niche shows, only a localized deformation of the greater curve. The reason why this ulcer does not show as a niche is that, because of malignant infiltration and therefore contraction, the base of the ulcer lies inside the contour of the gastric wall, not outside it, as in the niche of a penetrating ulcer.

When these localized malignant ulcers occur in the prepyloric region, they are much more easily recognized in the radiograph, though they still present recognitional difficulties at operation. The following case-record exemplifies this type of chronic prepyloric malignant ulcer:—

A man, aged 50, developed moderately severe epigastric pain, began to vomit in relation to food, and to become constipated. In a fortnight he had lost about 10 lb. in weight. He gave a history that he had had, for

three or four years, what he called "an indigestion pain". Examination revealed a slight tenderness above and to the left of the umbilicus. No mass could be felt.

X rays showed that the prepyloric part of the stomach did not distend normally and that no peristaltic waves passed through this area. *No definite ulcer crater could be demonstrated.* Fig. 143 is a radiograph of the case.

At operation a large ulcer, which at first sight appeared to be innocent, was found in the prepyloric part of the stomach (*see Fig. 80, p. 148*). But the hard base of the ulcer was undoubtedly malignant. A partial gastrectomy was performed; and a microscopical examination of the ulcer showed small strands of tumour cells extending irregularly through the ulcer.

8. Carcinomatous Dyspepsia supervening upon that of Old Chronic Ulcer: The Onset of 'Ulcer Carcinoma'.—A small percentage of cases of carcinoma of the stomach arise on the basis of a chronic gastric ulcer. In these cases the change in the type of the dyspepsia, caused by the advent of the carcinoma, can be recognized. The early recognition of this change is of practical importance, because the results of operative treatment in these cases are, in my experience, better than those of any other type of carcinoma.

Distinct changes in the dyspeptic picture of gastric ulcer take place when carcinoma supervenes. As the carcinoma develops in the chronic ulcer, the severe painful dyspepsia which has been such a feature of the illness disappears. As the pain disappears, or at any rate becomes less severe, the 'deep tender spot' also disappears. Sickness and nausea, which were previously absent, now become continually obvious. The appetite begins to lessen. Nutritional disturbances begin to appear. Constipation becomes a feature.

Definite and characteristic changes, recognizable radiologically, also take place in an innocent ulcer when it becomes malignant. The crater of the ulcer is not so well seen by X rays as previously. This is due to the fact that the crater fills up, and also to the fact that the fibrocancerous contractions round the ulcer draw the crater more towards the lumen of the stomach, where it is not seen so well in profile.

The following case-report is a good example of the changes which occur in the dyspepsia of chronic gastric ulcer when carcinoma supervenes:—

A man, aged 46, stated that for twenty years he had been suffering from "stomach trouble": from bad pain and vomiting after food.

Two years ago the features of his illness began to change, and during the last six months they had completely altered. He began to lose weight,

and in the last two months had lost one stone. His pain after meals became much less, and came on much later after a meal. He started to vomit many hours after food, obtaining great relief after doing so. He became ill-looking and of cachectic appearance. On examination no tumour could be felt.

At operation, carcinoma of the pyloric part of the stomach, which had developed in a chronic ulcer, was found. A partial gastrectomy was performed. Thirteen years later this man was still alive—an example of the operability of this type of carcinoma. *Fig. 144* is an operation sketch of the stomach in this case.

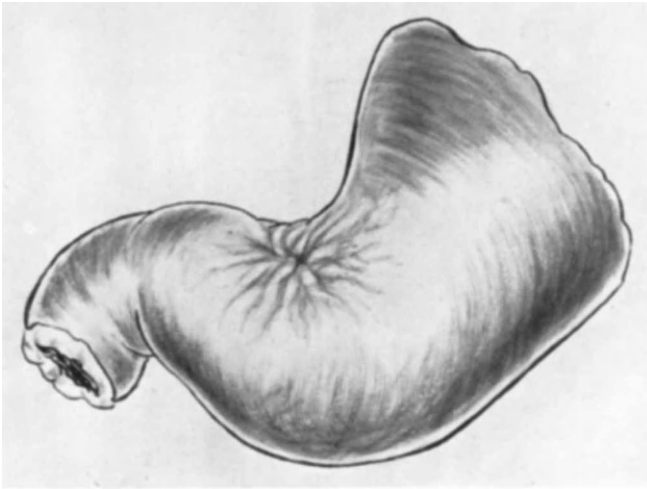


Fig. 144.—Operation sketch showing the contraction and dimpling of the base, a few wavy fine wrinkles, and a peritoneal plaque of infiltration. The tissue near the edge appeared quite healthy, and there was no œdema.

9. The Dyspepsia of Carcinomatous Pyloric Obstruction.—

Carcinoma involving the pylorus is generally of a scirrhus nature. The cancer cell grows slowly, or perhaps the tissue resistance of the body is high, with the result that there is much fibrous tissue reaction. The cancer therefore develops slowly, and hence does not fungate or ulcerate. Thus its course usually extends over two to three years, and its symptoms are due more to a mechanical obstruction of the pylorus than to any toxic effects of the growth itself.

The obstruction which it causes comes on *slowly*, and therefore gives rise to a painless dyspepsia, in which nausea and vomiting are distinctive features. The nausea comes on characteristically immediately after meals, and is probably due to a gastritis resulting from the mechanical obstruction. The stomach becomes hypertrophied and greatly dilated, and ‘obstructive vomiting’, associated with

exacerbations of nausea, occurs at a considerable interval after meals and gives great relief. In these cases of gross dilatation of the stomach there is never any free hydrochloric acid.

In the following case-record of a male patient who had suffered from scirrhus cancer of the pylorus for four years, notice the absence of pain in an almost complete pyloric obstruction, with an enormously hypertrophied and dilated stomach, in which deep peristaltic waves were visible on the abdominal wall.

A man, aged 50, complained of flatulence, wind, heartburn, and bilious attacks beginning very definitely four years previously, and since then becoming progressively worse. He had had a poor appetite for the

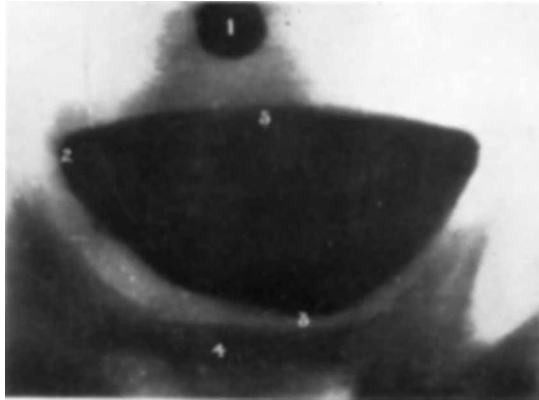


Fig. 145.—Radiograph of scirrhus cancer of the pylorus. 1, Umbilicus; 2, Pyloric end of stomach; 3, Greater curvature; 4, Pubic bone; 5, Middle point of stomach.

last three years. During the last two years he began to vomit occasionally and to lose weight rapidly. He vomited a very large quantity at the end of each day. Never at any time had he had any pain after food. When seen he had lost 25.2 kg. (4 stone) in weight, and visible gastric peristalsis could be seen on his abdominal wall. *Fig. 145* is a radiograph which gives some idea of the great dilatation of his stomach.

Operation revealed almost complete pyloric obstruction caused by a scirrhus carcinoma, and a stomach which was enormously dilated and hypertrophied.

As I have pointed out earlier (p. 165), the quiet and insidious onset of pyloric scirrhus may be mimicked by a cicatrizing ulcer of the posterior duodenal wall, in which situation an ulcer may not give rise to the typical painful dyspepsia characteristic of a florid duodenal ulcer. However, a prepyloric filling defect seen by X rays will distinguish the pyloric carcinoma from the duodenal-ulcer or pyloric-ulcer scar.

The Dyspepsia of Prepyloric Carcinomatous Obstruction.—Where the carcinoma is situated in the prepyloric region, the obstructive symptoms are associated with a more painful dyspepsia than where the growth is actually situated in the pyloric ring. Probably this is due to the fact that the growth is more proliferative, and therefore more of a tumour and less of a scirrhous growth, so that the obstruction develops more rapidly and the tumour causes painful peristalsis.

The following case-history exemplifies these facts :—

A man, aged 30 years (*Fig. 146*), complained of indigestion, fullness, belching, and discomfort followed by epigastric pain from five to



Fig. 146.—The patient here referred to, showing his youthfulness.

thirty minutes after food—a moderately painful filling dyspepsia. He suffered, too, from severe nausea and vomiting, which occurred some hours after food and at night, and which gave great relief. His bowels had become very constipated. His case had been diagnosed and treated for a considerable time as gastric ulcer.

Operation disclosed a carcinoma in the prepyloric region, causing gross pyloric obstruction (*Fig. 147*).

Sometimes a prepyloric obstruction is caused by a papillomatous type of carcinoma, as shown in the following case-record (Dr. Wright-Smith):—

A patient complained that twelve months previously he had suffered from an attack of “gastritis”. He said he was well, however, until six weeks previous to admittance to hospital, when he had a second attack of vomiting. He then began to vomit at intervals of three or four days. The vomit, he said, was very foul, and contained food which he had eaten two to three days previously.

At operation a tumour obstructing the pylorus was found.

The specimen (*Fig. 148*) shows a pedunculated papillomatous tumour, causing pyloric obstruction. Microscopical examination showed that the growth was a papillary adenocarcinoma.

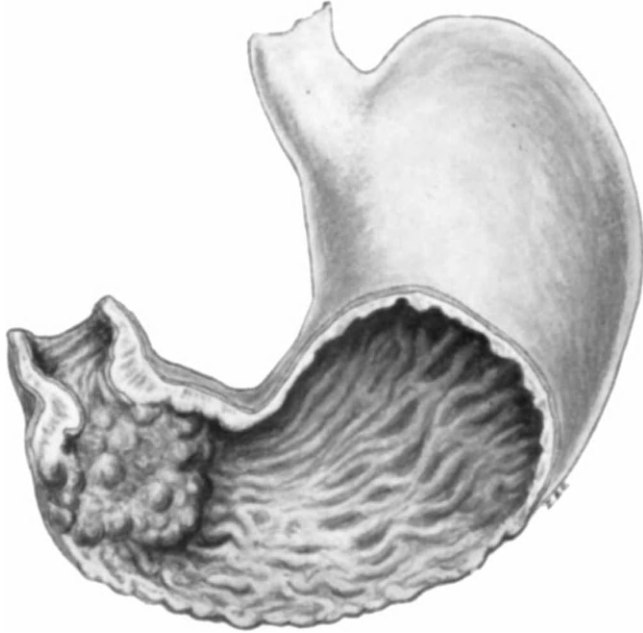


Fig. 147. --Operation sketch of stomach of patient seen in *Fig. 146*, showing prepyloric carcinomatous obstruction.

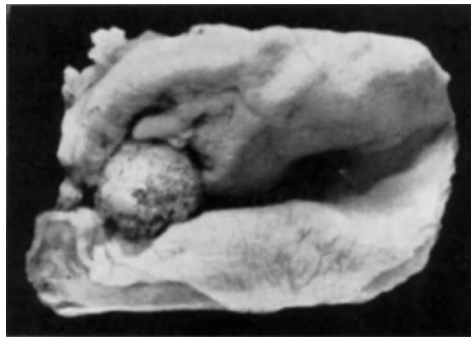

Fig. 148.—Papillary adenocarcinoma obstructing the pylorus. (Specimen 6.9223E, *Walter and Eliza Hall Institute, Melbourne Hospital.* By courtesy of *Dr. Wright-Smith.*)

10. Dysphagic Carcinomatous Dyspepsia.—The first symptom of carcinoma of the stomach may be dysphagia. This will, of course, suggest that the patient has a carcinoma of the œsophagus, when as a matter of fact the dysphagia is a late symptom, being due to

involvement of the œsophagus by a carcinoma which originated in the upper part of the lesser curvature. The symptom of dysphagia may lead to a diagnosis of cardiospasm.

Such an onset is exemplified by the following history:—

A man complained of slight dysphagia and ill-health. A carcinoma of the œsophagus was suspected. An œsophagoscopic examination disclosed no obstruction. A diagnosis of cardiospasm was made. Some months later an exploratory operation revealed a carcinoma of the fundus which had spread to the cardiac orifice, and which had therefore produced, in the early stages, a subjective sensation of dysphagia, without any actual obstruction being visible through the œsophagoscope.

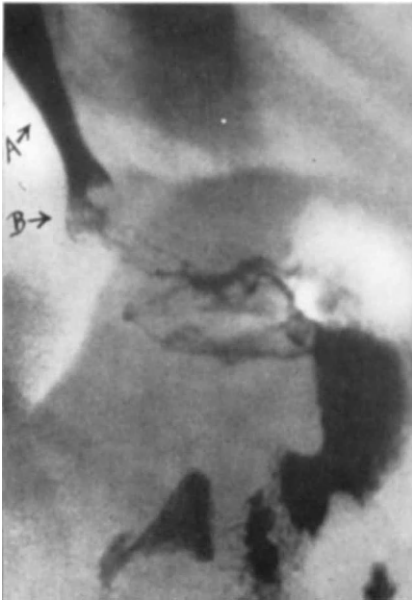


Fig. 149.—Radiograph of filling defect produced by carcinoma of the lesser curvature which has extended up to the cardia. **A** points to the dilated œsophagus; **B** to its lower end to which the growth has extended from the stomach. (*Berg.*)

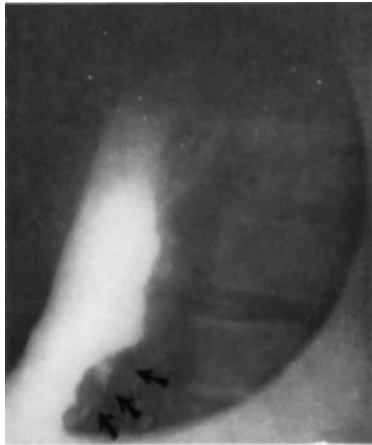

Fig. 150.—Lateral radiograph of 'silent' carcinoma of the posterior wall of the stomach. Arrows show the defect. (*By courtesy of Dr. K. S. Cross.*)

Fig. 149, taken from *Berg*,¹ illustrates this type of gastric carcinoma. In this will be seen the filling defect of the upper part of the lesser curvature caused by a carcinoma which has gradually extended up to the cardia and produced difficulty in swallowing.

II. 'Silent' Carcinoma: a Pernicious Anæmia Type of Clinical Picture.—While on the one hand a dyspepsia more or less painful may usher in one type of carcinoma of the stomach, on the other hand a progressive anæmia with profound constitutional disturbance, with no dyspepsia or a dyspepsia so mild as to be

unremarked by the patient, may be the manifestation of another form of carcinoma—the fungating papillomatous type. In the absence of a palpable tumour, this syndrome of what we might call ‘silent’ carcinoma is very liable to be confused with that of pernicious anæmia. Actually I have seen many cases of so-called pernicious anæmia in which autopsy revealed carcinoma of the body of the stomach.

In ‘silent’ carcinoma free acid is almost always absent, but the achlorhydria does not help to distinguish it from a pernicious anæmia, because in this disease also free acid is usually absent.

The following history is that of a patient who suffered for twelve months from progressive anæmia and profound ill-health. Even after many medical examinations, the cause of his condition had not been ascertained.

A man, aged 53, had been ill for twelve months. He complained that he was unable to work and was not feeling well. He had lost 12·6 kg. (2 stone) in weight in twelve months. He had a fair appetite and some fullness after meals, but no pain. He had gradually become more constipated. He was very anæmic. No tumour could be felt. A front-view radiograph showed no filling defect, but a lateral X-ray photograph (*Fig. 150*) revealed a constant filling defect in the body of the stomach on the posterior wall.

The carcinoma could not be palpated, because it was situated high, and on the posterior gastric wall.

This patient, because of his anæmia, the absence of any palpable tumour, and the absence of a filling defect on routine X-ray examination, was erroneously regarded as suffering from pernicious anæmia. In most cases of ‘silent’ carcinoma, however, a tumour can be palpated, or a filling defect seen, when of course the diagnosis is easy.

For some unknown reason, carcinoma anywhere in the stomach may be ‘silent’ for the greater part of its course. Most cases of carcinoma of the stomach in the vicinity of the gastric canal cause a more or less painful dyspepsia. Yet carcinoma in this position, which may appear to be similar in type to one which causes a painful dyspepsia, may not give rise to any symptoms until quite late.

Fig. 151 is a radiograph showing a carcinoma at just about the junction of the cardiac and pyloric parts of the stomach. The carcinoma, which was of the invasive type, completely encircled the stomach, and produced a fair-sized tumour. Yet this patient did not complain of any discomfort, any filling dyspepsia, until about twelve months (I should estimate) from the onset of the growth.

Operation showed that he had a large tumour at the junction of the cardiac and pyloric parts of the stomach.

Such a case as this shows how difficult it is to dogmatize in regard to the type of dyspepsia carcinoma of a certain form and in

certain positions may produce. This patient had no symptoms whatever until a month before he came into hospital. Only since then had he complained of a fullness and discomfort immediately after meals—of a filling dyspepsia.

As a rule, a 'silent' carcinoma is easily recognizable if the patient consults a medical man. The reason for this is that it is of the tumour rather than the invasive type, and this means that

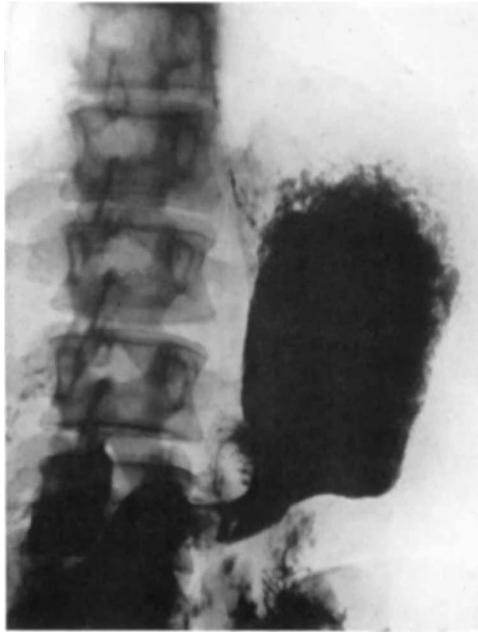

Fig. 151.—Radiograph of 'silent' carcinoma of the stomach in the prepyloric region.

the patient has either a palpable tumour or a definite X-ray filling defect.

The following is a case-record which shows how definite the signs of a 'silent' carcinoma can be :—

A woman, aged 61, complained that for the last six months she had suffered from a mild form of dyspepsia : discomfort after meals, but no pain. She had, she said, attacks of hæmatemesis. She gradually lost weight and strength and appetite. She became very constipated. On examination she was seen to have a very severe grade of anæmia. A large mobile tumour was palpable in the left hypochondrium. The radiograph (*Fig. 152*) shows a very definite filling defect.

At operation a large mobile tumour with a fairly well developed pedicle was found (*Fig. 153*).

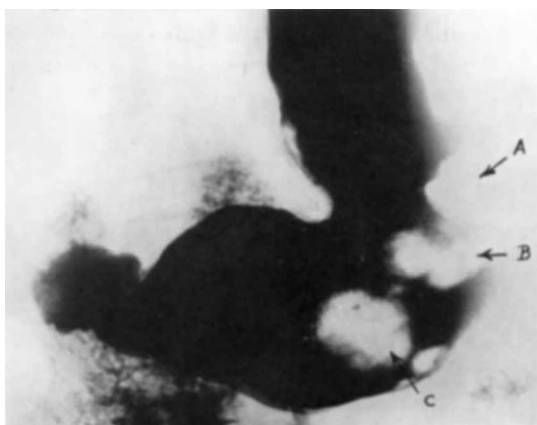

Fig. 152.—Radiograph showing a papillomatous type of 'silent' carcinoma.
A, B, and C indicate the filling defect.
(By courtesy of Drs. D'Arcy and J. O'Sullivan.)

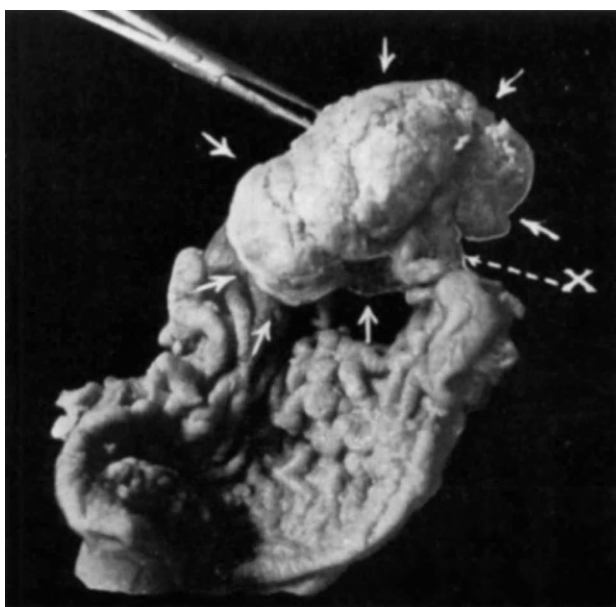


Fig. 153.—The papillomatous tumour seen in *Fig. 152.* X, Pedicle.
(By courtesy of Mr. F. D'Arcy.)

12. Carcinoma in which Tumour is the Main Manifestation.—Here is the history of a patient who consulted me because he could feel a big tumour in the upper part of his abdomen :—

A man, aged 56, had been ill for two months. He complained of a very slight discomfort in the epigastrium three or four hours after food. He had come to the doctor, he said, because he could feel a big lump in the upper part of his abdomen. He had no nausea, vomiting, or constipation, but he had lost a little weight. *Fig. 154*

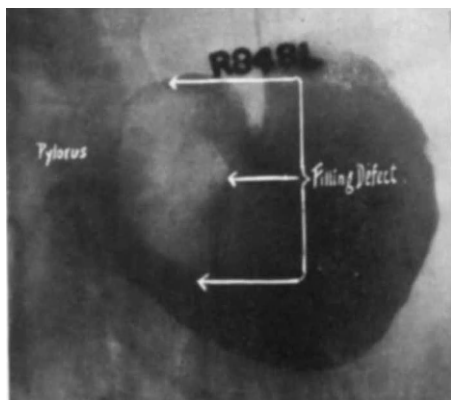


Fig. 154.—Radiograph showing very large filling defect in the stomach.

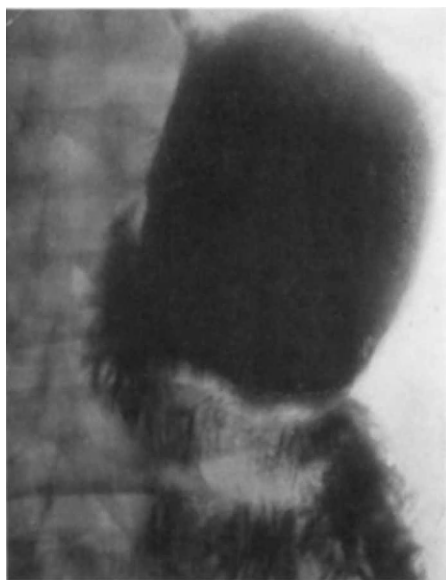

Fig. 155.—Radiograph of the same case as *Fig. 154*, taken fifteen years later. (After a partial gastrectomy.)

is a radiograph of the case, from which it is obvious what a large distinct filling defect this patient had.

A partial gastrectomy was performed, and the man was alive fifteen years after his operation. (*Fig. 155.*)

These large papillomatous carcinomas are much less malignant than the flat invasive type.

REFERENCE

- ¹ BERG, HANS HEINRICH, *Röntgenuntersuchungen am Innenrelief des Verdauungskanals*. Leipzig: G. Thieme.

CHAPTER XXV

THE DYSPEPSIA OF CARCINOMA OF THE
DUODENUM AND STOMACH*(continued)*

PERICARCINOMATOUS INFLAMMATION OR ABSCESS

AN inflammation or an abscess may occur in relation to a carcinoma of the stomach. The tenderness which such a tumour exhibits may create the impression that it is an inflammatory tumour arising around an old chronic ulcer, that is, an 'ulcer tumour'. Any constriction and irregularity in the contour of the stomach, as seen by X rays, which would suggest malignancy, may be taken as the result of reactive changes to the widespread inflammatory condition.

Such a problem is seen in the following history :—

A man aged 56. Four days previous to being seen he took to bed following a severe attack of epigastric pain, which occurred at 3 a.m. The previous day he had had a vomiting attack, but this passed off completely. Three days later he felt some more epigastric pain, but it was of a dull nature and did not seriously inconvenience him. He had had no loss of weight, and his appetite had been only moderately good.

Examination disclosed a large, movable, hard tumour in the mid-epigastrium involving the abdominal wall. The tumour was very tender. Although the radiograph showed a filling defect, the tenderness of the tumour and the fact that it involved the abdominal wall suggested that it was an 'ulcer tumour'.

At operation a hard mass, the size of a very large orange, was found, which was firmly adherent to the overlying peritoneum. The mass was in the lesser curvature of the stomach, and was adherent to the anterior abdominal wall, the liver, and the gall-bladder. After some dissection a small pocket of pus was found. The extensive adhesions, the pus, and the inflammatory appearance of the tumour gave the impression that it was an 'ulcer tumour'. However, the lymphatic glands in the region of the stomach were very large and firm, and on section showed metastatic deposit of carcinoma.

The condition was a carcinomatous tumour in which a perforation had occurred; and around this perforation a pericarcinomatous abscess, surrounded by great inflammatory reaction, had developed.

SIGNIFICANCE OF CERTAIN SYMPTOMS AND SIGNS

Constipation.—Constipation occurs in most cases of carcinoma of the stomach; but in some more than others, and particularly in carcinoma of the pylorus, in which it has a sudden onset and gets progressively worse. The constipation is probably due to a lesser

intake of fluid as a result of the nausea and vomiting. When it occurs in a previously unconstipated patient, and is progressive in spite of treatment, it is a most significant sign of carcinoma of the stomach.

Hæmatemesis.—Hæmatemesis is generally a late sign of malignant disease of the stomach, and if it is due to this disease some other tangible evidence will be present, such as a characteristic dyspepsia or a tumour. It has been my experience that a sudden and profuse symptomless hæmatemesis in an old man is usually due to a non-malignant rather than a malignant cause. Hæmatemesis resulting from malignant stomach is generally small and frequent.

Epigastric Rigidity.—Epigastric rigidity may be the only local sign, and it may be present before a tumour is manifest. This rigidity, however, may denote an involvement of the parietal peritoneum and inoperability. A general epigastric rigidity may be the only sign of carcinoma of the stomach. A patient came to see me because he was losing weight and not able to work. On examination it was found that he had a marked generalized rigidity in the upper part of his abdomen. Operation revealed a carcinoma of the stomach with a general peritoneal spread.

Tumour.—The absence of tumour does not exclude a diagnosis of carcinoma. Tumour may be absent: (*a*) in early scirrhous of the pylorus; (*b*) in those cases of invasive carcinoma where no tumour forms; (*c*) when the growth is impalpable on account of being situated high in the stomach, and therefore under the ribs; or (*d*) when it is situated in the posterior gastric wall—I have seen a tumour on the posterior wall which was only palpable when the stomach was empty.

On the other hand, the presence of an apparently malignant tumour in the region of the stomach must not always be accepted as certain evidence of carcinoma of the stomach. The tumour may not be malignant—it may be an old retrogressed hydatid; or it may be of an inflammatory nature—an ‘ulcer tumour’; and it may be indistinguishable from a malignant tumour both at clinical examination and at operation.

The following case-histories record two instructive mistakes which show the fallacy of regarding an epigastric tumour as an infallible sign of a malignant stomach:—

The first was a case of ‘ulcer tumour’. A man, aged 56, had a palpable tumour in the region of the stomach, and was operated on in the belief that he had a gastric carcinoma. At operation the tumour was still regarded as undoubtedly malignant, and a palliative gastro-enterostomy was done. The patient was told that he would die. With incredible optimism he battled for a favourable opinion. Surgeons and expert X-ray specialists

pronounced against him, and maintained the diagnosis of malignant disease. Finally he came under a leading physician, who reviewed the whole history and X-ray findings, questioned the diagnosis of malignancy, and asked me to reoperate on him. I found that a proliferating chronic inflammation around a large penetrating ulcer of the pancreas had produced a tumour almost macroscopically indistinguishable from a malignant tumour. The supposed malignancy was an 'ulcer tumour'.

The second was a case of a retrogressed hydatid. It shows that a tumour, apparently malignant, situated in the region of the stomach, in a very emaciated and wasted patient, is not necessarily malignant.

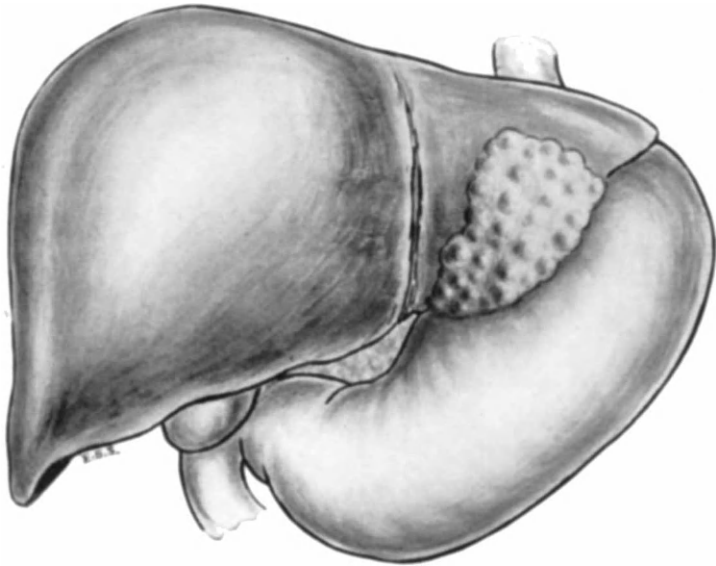


Fig. 156.—Old contracted hydatid of left lobe of liver, mistaken for carcinoma.

The patient had an epigastric tumour, large and irregular, and with the hard, nodular feel characteristic of a malignant tumour. She was cachectic and wasted, and appeared to be suffering from malignant disease of the stomach. X rays showed a filling defect.

At operation the tumour was found in the left lobe of the liver and was lying over the stomach. It was even then regarded as malignant, until an incision disclosed an old degenerated hydatid with a cartilaginous wall half an inch thick (*Fig. 156*).

VALUE OF THE TEST-MEAL IN THE DIAGNOSIS OF CARCINOMA

The value of the test-meal in making a diagnosis of carcinoma of the stomach is in my opinion exaggerated. In giving an opinion on a case of suspected carcinoma of the stomach the results of a test-meal have so often misled me that I no longer take it into serious consideration when making a diagnosis. I have earlier shown that

frequently in cases of chronic gastric ulcer complicated by secondary chronic gastritis or by pyloric obstruction there is no free acid in the stomach. I have also pointed out that normal acid is occasionally found in gastric carcinoma. Furthermore, free acid is absent in many diseases such as pernicious anæmia. I feel, therefore, that it is unwise to place much reliance in making a diagnosis on either its presence or its absence. The test-meal is however of value in making a diagnosis of malignancy when it shows pathological constituents, such as blood, lactic acid, or shreds of tumours.

ERRORS OF DIAGNOSIS IN 'SILENT' CARCINOMA

A diagnosis of 'silent' carcinoma may be erroneously made in the following conditions: (1) Carcinoma of the body of the pancreas; (2) A congestive condition of the stomach arising from incipient heart failure; (3) Addison's disease; (4) Fungating carcinoma of the œsophagus without obstruction; (5) Cirrhosis of the liver; (6) The ill-health which is found in incipient diabetes.

THE EARLY DIAGNOSIS OF CARCINOMA

Of all the problems associated with this disease the one concerning its early diagnosis is the most important, for operation in early stages may cure, but in later stages probably only disseminates, the disease.

An early diagnosis is not usually made, because on the one hand patients do not often seek relief in the early stages of the disease, for, as previously pointed out, the onset of cancer of the stomach may be 'silent'; and because on the other hand, when they do come early, the surgeon or physician often fails to diagnose the disease through failure to recognize a dyspeptic pattern of early carcinoma which does not conform to the text-book types.

The Early Symptoms of Carcinoma of the Stomach.—

1. The onset and progression of an unexplainable loss of mental or physical energy.
2. The onset and steady progression of a secondary anæmia.
3. The onset of constipation, getting steadily worse, and combined with dyspepsia especially coming on immediately after meals—a filling dyspepsia.
4. Unexplainable and progressive loss of weight, occurring over a short period of time, especially associated with the onset of constipation.
5. Dyspepsia of a perhaps moderate grade of painfulness—the pain only slightly modified by the taking of food into the stomach; a dyspepsia getting progressively worse and unamenable to the ordinary remedies; and a dyspepsia associated with much

nausea and perhaps some *vomiting*, with no mechanical cause (as shown by X rays) to account for it.

6. A painful emptying dyspepsia which is unassociated with a 'deep tender spot'; that is, pain after food without indications of the inflammation which a gastric ulcer should show.

7. Epigastric rigidity without any epigastric tenderness.

8. Vomiting of 'coffee grounds' (small quantities).

9. Infiltrated umbilicus. This may be the first noticeable sign, but of course it is not an early one.

An important help towards early clinical diagnosis in gastric carcinoma is parallel progress of symptoms and signs—an observation that two or more symptoms or signs which could be caused by a gastric growth are getting progressively worse at about the same rate.

GENERAL DISTINCTION BETWEEN THE DYSPEPSIA OF INORGANIC AND THAT OF ORGANIC DISEASE

The following table has been drawn up to show the broad distinctions between the dyspepsia of inorganic disease (medical dyspepsia) and that of organic disease (surgical dyspepsia).

INORGANIC DISEASE	ORGANIC DISEASE
No definite onset.	A very definite onset.
A background of nervous debility.	A background of good nervous health.
Symptoms (usually nausea and vomiting) immediately the stomach begins to fill.	Interval of time after food free from symptoms. (No pain or dyspepsia during filling of the stomach, as in chronic ulcer.) Symptoms of discomfort and pain only on emptying the stomach (from half an hour to three hours after taking food).
Comparative good health.	Definite onset of ill-health, getting progressively worse (as in the case of carcinoma).
No definite cause obvious.	Usually some suggestion of a cause.
Symptoms are irregularly intermittent.	No intermissions: as in carcinoma of stomach. Periodicity: as in chronic ulcer.
May be general epigastric hyperæsthesia: never a 'deep tender spot'.	'Deep tender spot'.
No sign of organic disease such as hæmorrhage.	Signs of organic disease as shown by hæmorrhage or occult blood.
No direct relation to errors in diet. Origin traceable to nervous or emotional causes.	A definite relation to dietetic errors or to particular articles of food.

*Section II*THE CONSULTATIVE, RADIOGRAPHIC, AND
GASTROSCOPIC DIAGNOSIS OF SURGICAL DYSPEPSIA

*CHAPTER XXVI***RADIO-SURGICAL DIAGNOSIS****INTERPRETATION OF X-RAY FILMS IN DISEASE
OF SURGICAL NATURE**

THE culminating point in the diagnosis of a case of surgical dyspepsia is the X-ray examination.

In most cases, where such examination is carried out by an expert radiologist, definite and reliable information is obtained. Occasionally, however, this form of examination loses some of its diagnostic value and its usefulness because the clinical diagnosis is not used to focus the radiologist's examination, because clinical symptoms and signs are not balanced against radiographic signs, and because frequently the whole responsibility for a diagnosis is placed on the radiologist. The X-ray examination, too, may not attain its full value because it may concern an equivocal type of gastric lesion—for instance, an obscure case of gastric carcinoma—and when such a lesion is considered without the aid of the physician and the surgeon it may elude the diagnostic skill of the best of radiologists.

There is also, as far as the surgeon is concerned, another problem in connexion with X-ray examination, and therefore a reason why the surgeon should have a knowledge of X-ray criteria. It is that nowadays there are many medical men who, without proper training, "do their own X-ray work". These X-ray workers make very definite but frequently very erroneous diagnoses; consequently the surgeon must be in a position to check their accuracy.

The actual taking of X-ray photographs of diseased tissue has now become, not so much the province of the medical man, as that of the trained technician, who, thanks to X-ray designers, is able to make apparent the greatest detail, not only of the hard bony structures of the body, but also of the soft tissues.

To help in this respect, not only has the designer perfected apparatus for the exact reproduction of pathological conditions of the stomach, but also he has perfected a technique (tomography) whereby photographs can be made of the various planes of the body with the greatest sharpness, so that the exact structure of the solid body can be worked out by taking a series of these plane-pictures at various depths (*Schicht-aufnahmen* or layer-photographs) and superimposing the radiographs thus obtained. In this way cavities hidden in the middle of soft tissues, filling defects in the middle of the stomach, cavities in the lung, and alterations in the density of tissues in the middle of the body can be accurately worked out.

The interpretation of the X-ray plate, however, requires the whole concentration of the radiologist; and in the diagnosis of surgical disease it should be made by a surgeon with a clinical knowledge of the case under discussion.

Exact and painstaking interpretation of the X-ray plate has become one of the most important investigations in regard to surgical disease and its early recognition; and in big surgical clinics, one member may be allotted this special duty.

The interpretation of the radiographic observations of surgical disease requires the following: (1) an interpreter who is surgically trained and who is a member of the surgical clinic; (2) a projection apparatus, which throws on to a screen a picture of lantern-slide size, capable of being examined in consultation between radiologist, surgeon, physician, and others; (3) a viewing-box apparatus provided



Fig. 157.—X-ray projection apparatus.

with specially designed lights to show up the details in X-ray pictures, and with a flexible arm carrying a large microscopic adjustment for the examination of fine detail; and (4) a simple device which can be continually used by the surgeon himself for viewing pictures plastically, i.e., stereoscopically.

The X-ray Projection Apparatus.—An X-ray projection apparatus is especially useful in hospital work, where radiographs should be simultaneously viewed not only by the specialists concerned in making the diagnosis, but also by the students whom they are teaching. The use of such an apparatus constitutes an advance in 'team' X-ray diagnosis of alimentary lesions. It is illustrated in *Fig. 157*.

The Stereoscopic 'Binokel'.—A simple device, enabling X-ray pictures taken with the correct displacement of the X-ray tube to




Fig. 158.—The Stereo-Binokel.

be viewed stereoscopically on the ordinary X-ray viewing-box, is the Stereo-Binokel, illustrated in *Fig. 158*. Not only does this handy instrument—it is similar in use to a field-glass—enable the surgeon to view most of his radiographs stereoscopically without the use of complicated and space-taking apparatus, but it also enables several

consultants to view X-ray pictures stereoscopically at the same time, thus permitting a stereoscopic consultation.

Consultative Diagnosis.—In order to get the full value of the X-ray examination of surgical dyspepsia, and to help the radiologist in his own X-ray difficulties, the X-ray diagnosis is discussed in the following chapters as a hypothetical consultation in front of the X-ray screen between the surgeon, the physician, and the radiologist; and discussed more from the point of view of the surgeon than that of either the physician or the radiologist.

The Surgeon's Point of View.—In the X-ray examination of the stomach, the surgeon will have two objectives in his mind:—

His first objective will be to help the radiologist to discover any surgical lesion. He will use knowledge which he has obtained in his clinical examination: (a) to focus the radiologist's attention on particular regions where he thinks disease may be present; (b) to remind the radiologist that there are certain lesions which are likely

to be present ; (c) to discuss with the radiologist the question of the compatibility of the X-ray signs with the clinical findings.

His second objective will be to apply his surgically trained mind to study on the X-ray screen any surgical lesion which has been discovered, with a view (a) to seeing whether it is amenable to surgical treatment ; (b) to planning what surgery it may require.

Preliminary Œsophageal Investigation.—Before any X-ray examination of the stomach is made, it is wise to be sure that the

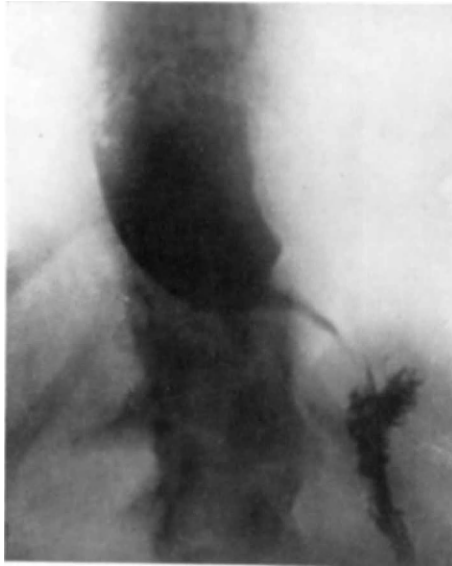

Fig. 159.—Radiograph of an œsophagus in which a very definite cardiospasm is seen. The patient had been clinically diagnosed as suffering from a dyspepsia of gastric origin.

barium-filled œsophagus is carefully viewed. It is not sufficient that no obstruction is obvious—it is necessary to see if there is any alteration in the contour of the œsophagus. The reason for this is that cases of painless dyspepsia, clinically significant of ‘silent’ carcinoma of the stomach, are sometimes caused by a fungating ulcerating carcinoma or sarcoma of the œsophagus. This type of carcinoma does not produce obstruction, but can be detected if the contour of the filled œsophagus is carefully observed.

The following case-record gives an example of such a case :—

A patient had all the symptoms of malignant stomach. The report of the X-ray examination of œsophagus and stomach was negative. Exploratory operation revealed a normal stomach, but a fine cirrhosis of the liver

was present, which was thought to be the cause of his trouble. Some months later he complained of difficulty in swallowing. Œsophagoscopy was carried out, and an ulcerating sarcoma of the œsophagus was found.

Mild degrees of cardiospasm give rise to a painless dyspepsia, and are occasionally missed by the radiologist. Sometimes, however, he may be misled by the clinician, who may misdiagnose a dyspepsia caused by a cardiospasm. The following is an example :—

Fig. 159 is a radiograph of a cardiospasm in a patient who complained of a mild dyspepsia, and who was ultimately sent for a gastric X-ray examination in the belief that her dyspepsia was of gastric origin. This patient said that when she started to take food she “vomited” at once. She had not lost weight. When a meal was finished she had no more sickness.

In this case an œsophageal trouble was not clinically suspected, but the radiographer in the routine examination discovered a cardiospasm.

The Radio-clinical Classification of ‘Surgical’ Dyspepsia.—

Generally speaking, dyspepsias which are of interest to the surgeon will fall into one of the following groups :—

GROUP 1.—*Painless dyspepsia without a ‘deep tender spot’ and without constitutional disturbance.* Clinical diagnosis: Functional dyspepsia.

GROUP 2.—*Painless dyspepsia without a ‘deep tender spot’ but with constitutional disturbance.* Clinical diagnosis: Carcinoma of the stomach.

GROUP 3.—*Painless dyspepsia with a history of recurring hæmatemesis.* Clinical diagnosis: (a) ‘Silent’ carcinoma; (b) Acute ulcer or (c) Acute ulcer on the scar of a healed ulcer; and (d) Enlarged spleen—first stage of splenic anæmia.

GROUP 4.—*Painful dyspepsia with a ‘deep tender spot’.* Clinical diagnosis: (a) Chronic gastric ulcer; (b) Chronic duodenal ulcer; (c) Reflex dyspepsia (appendix, gall-bladder, etc.); (d) Gastritis.

GROUP 5.—*Painful dyspepsia without a ‘deep tender spot’.* Clinical diagnosis: (a) Atypical chronic peptic ulcer (ulcer of the posterior wall of the stomach or duodenum); (b) Gastric malignancy.

Scheme of the Discussion.—These various dyspeptic groups will be discussed in the chapters which follow. Thus the next chapter in this section (Chapter XXVII) will be concerned with the radio-surgical problems of the diagnosis of dyspepsia in early obscure forms of malignancy which may be confused with functional dyspepsia, or with the dyspepsia of the less-known forms of gastric inflammatory disease; Chapter XXVIII will deal with radio-surgical diagnostic problems in definitely established inflammatory disease;

Chapter XXIX will discuss difficulties in diagnosis of dyspepsias which are of malignant or supposedly malignant origin, and which are best clarified by consultation; Chapter XXX discusses the attitude of the surgeon towards the radiological evidence in its bearing on the problem of operation; while Chapter XXXI will deal with a consultation in the case of a hæmatemesis. The final chapter in this section, Chapter XXXII, is devoted to the subject of gastroscopy.

CHAPTER XXVII

RADIO-SURGICAL PROBLEMS IN THE DIAGNOSIS OF
OBSCURE TYPES OF PAINLESS DYSPESIAGroup 1.—PAINLESS DYSPESIA WITHOUT A 'DEEP TENDER
SPOT' AND WITHOUT CONSTITUTIONAL DISTURBANCE

IN the case of painless dyspepsia without constitutional disturbance and without a 'deep tender spot' the clinical diagnosis will as a rule be functional dyspepsia. If in such a case the usual routine X-ray examination reveals no sign of gastric disease, in the ordinary course of events a diagnosis of functional dyspepsia would be made. Such a diagnosis, however, may not be correct, for sometimes early stages of carcinoma of an obscure type may be present, and without special attention being paid to them may be missed.

The surgeon should therefore put three questions to the radiologist in regard to three phases of malignant disease which in their early stages may not at first sight be radiographically obvious, and which in this stage may not give rise to any constitutional disturbance. The three questions are :—

1. Are the symptoms caused by an early '*silent*' carcinoma of the stomach, giving no evidence of constitutional disturbance because it is too early, and giving no very obvious radiological sign because it is situated on the posterior gastric wall, or high in the fundus of the stomach ?

2. Are the symptoms an indication of the presence of an early stage of a localized invasive carcinoma—*linitis plastica*—a condition which gives mildly painless dyspeptic symptoms, affects the general health but slightly, and affords very little X-ray evidence of its presence.

3. Are the symptoms those of a very *chronic carcinomatous ulcer* of the fundus of the stomach—an ulcer which may give rise to an almost painless dyspeptic pattern, and which may be most difficult to detect radiographically ?

The discussion in regard to these phases of gastric carcinoma will be as follows :—

1. 'Silent' Carcinoma of the Stomach.—A papillomatous tumour of the posterior gastric wall is usually 'silent'. Such a tumour may also be impalpable, especially when the stomach is full ;

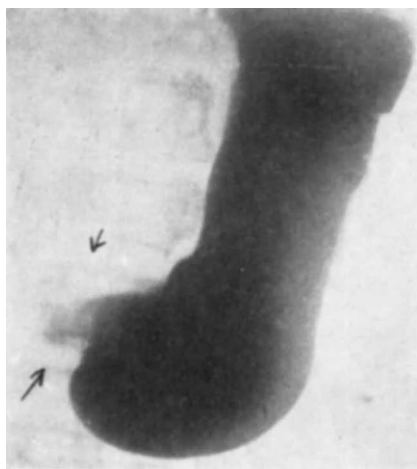

Fig. 160.—Sharp prepyloric deformity caused by an invasive carcinoma in the prepyloric region.

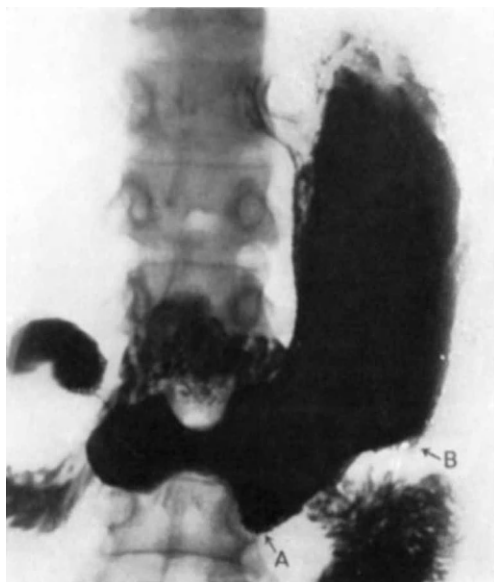

Fig. 161.—Plaque of invasive carcinoma of the posterior wall of the stomach eighteen months after its onset. The arrows A and B point to the position of the deformity. In its early stages this growth did not give rise to a deformation of contour which could be radiographically recognized. (By courtesy of Dr. John O'Sullivan.)

and because it is on the posterior wall it is liable to be overlooked by the radiologist.

These carcinomatous tumours of the posterior wall of the stomach can best be demonstrated by a lateral radiograph. *Fig. 150* (p. 232) shows a lateral radiograph of a patient's stomach in which is seen the filling defect of a carcinomatous tumour of the posterior wall. This tumour gave very little evidence of its presence in an antero-posterior radiograph.

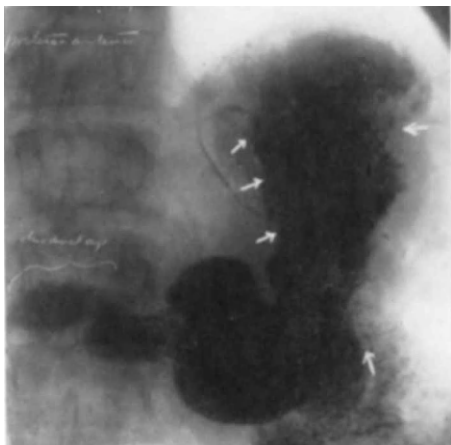


Fig. 162.—Gross deformity on the greater curvature in a patient who appeared quite healthy. This deformity was caused by an extensive local linitis plastica beginning in the fundus of the stomach. Arrows point to the extent of the deformity. In its early stages, eighteen months previous to this radiograph being taken, it was difficult to recognize any deformity.

Carcinomatous tumours in the fundus, in the vicinity of the air bubble, are usually 'silent', and are difficult to detect radiographically; but a painstaking examination in the reverse Trendelenburg position will usually demonstrate a carcinoma in this situation.

However, no difficulty as a rule arises in the radiological diagnosis of a carcinoma of the 'silent' type, for it is usually of the papillomatous rather than the invasive type, and therefore gives a filling defect which is easily demonstrable.

2. Localized Invasive Carcinoma (Linitis Plastica).

—Highly invasive carcinoma in its early stages causes only a mildly painful or a painless dyspepsia. It is also a local plaque-like gastric malignancy—an entirely invasive malignancy—which, for many reasons, may easily be missed by the radiologist. For one reason, the deformity which it causes is not great; for another, he may not be on the look-out for this type of malignancy; and for a third, if it is on the posterior wall, the slight sharp-edged deformity of the stomach which it may cause can be easily overlooked.

Figs. 160–163 are four radiographs of the stomach showing various grades of local sharp-edged deformations indicative of local invasive carcinoma (linitis plastica). The early stage of this condition is difficult to detect, not alone radiographically, but also clinically; for it causes very little if any dyspepsia.




Fig. 163.—Extensive sharp-edged deformity due to late invasive carcinoma.

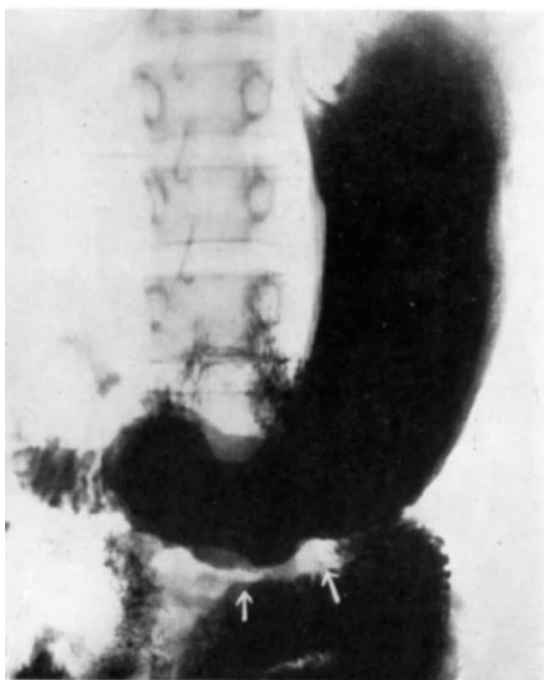


Fig. 164.—Radiograph of plaque-like malignant condition of the posterior wall—a localized linitis plastica.

Fig. 164 shows a radiograph of a stomach in which a localized linitis plastica of the posterior wall developed. The X-ray picture shows only a slight and easily overlooked deformation (indicated by arrows) caused by the plaque-like invasion of the posterior wall. The patient was aged 39, and suffered from a painless dyspepsia that was mild, but clinically recognizable as due to a malignancy. She had practically no constitutional disturbance. Her condition went unrecognized (radiographically) for fifteen months.

3. Chronic Carcinomatous Ulcer of the Fundus.—Another rare form of malignancy which causes an almost painless dyspepsia is a somewhat unusual type of chronic carcinomatous ulcer of the fundus of the stomach. Macroscopically the contour and excavation of this carcinomatous ulcer are so like those of innocent chronic ulcer that it is difficult to distinguish between the two conditions. The carcinomatous ulcer, however, does not show a true ulcer X-ray niche; and thus it is radiographically difficult to detect by X-ray examination. A radiograph of the barium-filled stomach in which such an ulcer was present is shown in *Fig. 83* (p. 150). Very little evidence of the ulcer is seen. *Fig. 142* (p. 226) is the mucous-membrane relief of the same stomach, and even in this the carcinomatous ulcer is not very obvious. However, after the ulcer had been seen at operation, its position on the radiograph could be picked out. *Fig. 81* (p. 149) is a sketch of the growth made at the operation.

Having excluded the three surgical conditions mentioned above—‘*silent carcinoma, local invasive carcinoma, and carcinomatous ulcer of the fundus*’—any further questions with regard to the X-ray diagnosis in this form of painless or mildly painful dyspepsia will not concern the surgeon but the physician. The condition will probably be *some form of functional dyspepsia*.

Group 2.—PAINLESS DYSPEPSIA WITHOUT A ‘DEEP TENDER SPOT’ BUT WITH CONSTITUTIONAL DISTURBANCE

In this group, in which a painless dyspepsia is associated with a distinctly obvious constitutional disturbance, the radiographer will as a rule discover the usual type of carcinoma of the stomach.

If, however, his routine examination is negative, then a further search must be made for obscure forms of malignant disease. The types of carcinoma mentioned under *Group 1* must be put forward by the surgeon to stimulate further investigation.

If there is nothing to be found in the stomach, the physician’s help should be enlisted with a view to finding a cause for the constitutional disturbance. With his clinical help in regard to the symptoms,

early tuberculosis of the lung, renal or cardio-renal disease, or some other condition may be found to be the cause of the dyspepsia and the constitutional disturbance.

Group 3.—**PAINLESS DYSPEPSIA WITH RECURRING HÆMATEMESIS**

In the case of painless dyspepsia with recurring hæmatemesis where the routine X-ray examination may reveal no pathological condition, the surgeon must ask the radiographer to make a special examination to exclude these diseased states: (1) '*Silent*' carcinoma; (2) *Acute ulcer*—although this may be invisible; (3) *Acute ulcer on the scar of a healed ulcer*; and (4) *Enlarged spleen*, which can be radiographically recognized.

1. 'Silent' Carcinoma.—This has already been discussed above (*Group I*).

2. Acute Ulcer.—It may not be possible to demonstrate a niche in the case of an acute ulcer. If it is suspected, the possibility of its arising from a focal infection, such as from a chronic appendicitis or a cholecystitis, must not be forgotten. These conditions, which are radiographically detectable and which require surgical treatment, should be sought for by subsequent X-ray examination.

3. Acute Ulcer Arising on the Scar of a Healed Ulcer.—In such a case some evidence of the old ulcer may be visible on the X-ray screen. The surgeon may be able to volunteer the information that the patient has a history of a painful chronic ulcer in the past.

4. Enlarged Spleen.—An enlarged spleen, very often the cause of a hæmatemesis with a mild dyspeptic complex, is often missed at X-ray examination, for the simple reason that it is not thought of and not looked for. If found it would indicate the possibility of a splenic anæmia, which may cause a hæmatemesis associated with painless dyspepsia.

CHAPTER XXVIII

RADIO-SURGICAL PROBLEMS IN THE DIAGNOSIS OF
DEFINITE INFLAMMATORY DISEASEGroup 4.—PAINFUL DYSPEPSIA WITH A 'DEEP
TENDER SPOT'

IN a painful dyspepsia of this type, the surgeon will direct the radiographer's attention to the condition which, judging from his clinical observations, he thinks may be the cause of the patient's suffering. His opinion will be that the differential diagnosis lies between the following conditions: (1) *Chronic gastric ulcer* (gastric 'deep tender spot'); (2) *Chronic duodenal ulcer* (duodenal 'deep tender spot'); (3) *Reflex dyspepsia* (extragastric 'deep tender spot'), such as is caused by disease of the gall-bladder, appendix, colon, or chronic intestinal obstruction; and (4) *Gastritis* or *intrinsic neuromuscular disorder* (diffuse gastric 'deep tender spot').

The surgeon should accurately localize any 'deep tender spot', and even mark its situation on the abdominal wall. The radiologist then usually proceeds to make a mucous-membrane relief by using a barium wash, and he follows this up with an ordinary barium filling.

The radio-surgical problems may then be considered in the following order:

1. Chronic Gastric Ulcer.—Chronic gastric ulcer with a definite tender point usually shows plainly on the screen as a niche. The tender point is nearly always situated over the *Magenstrasse*.

From the surgeon's point of view, an ulcer chronic enough to require surgical treatment should always be plainly visible, for the effects of its chronic fibrotic contraction and the niche of its crater will be obvious.

There are, however, two types of chronic ulcer which do not show on the X-ray screen, though they require surgical treatment. They are chronic ulcer of the posterior gastric wall, and chronic ulcer of the posterior duodenal wall. These ulcers are not always radiographically obvious, and must be searched for; otherwise they occasionally escape observation. Moreover, they do not as a rule show a 'deep tender spot'. They can best be demonstrated by lateral examination and special X-ray methods.

The Pathology of the Chronic Ulcer.—If a chronic ulcer is found the surgeon must take advantage of the X-ray screen to study the living pathology of such an ulcer. He must study its situation, its degree of penetration, its chronicity, the extent of any complications found associated with it such as pyloric stenosis. As a result of this study, he must assess its amenability to medical treatment, or visualize any surgical treatment that he may think necessary.

The surgeon must also seek for any evidence of a causal focal infection. Such evidence may have to be elicited at a later X-ray

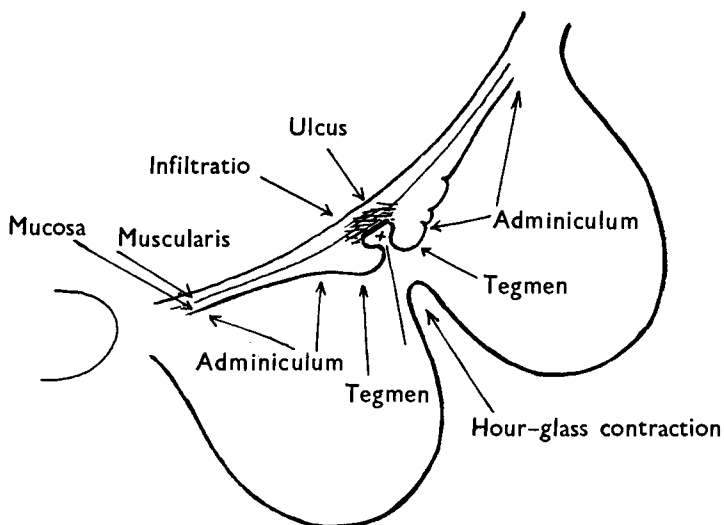


Fig. 165.—Diagram showing chronic penetrating ulcer of the lesser curvature. (After Forssell.)

examination; for the appendix or the gall-bladder may have to be visualized by special X-ray methods in order to determine the significance of the location of a 'deep tender spot'.

Where the ulcer is very chronic, where it has penetrated the gastric or duodenal wall, where organic complications are associated with it, and where there has been a contributory cause such as chronic appendicitis or chronic cholecystitis—a cause which is still present—the surgeon's advice will be that the patient should be treated surgically.

Thus, in regard to the relative merits of surgical or medical treatment of the chronic ulcer viewed on the screen, a discussion will take place between the surgeon and the physician, with the living pathology represented by its X-ray shadows in front of them. And thus it not uncommonly happens that the surgeon will be able to

find out more about the patient's condition from a study of the X-ray appearance than he will at the actual operation.

The Characteristic X-ray Appearance of Chronic Ulcer of the Lesser Curve.—The characteristic features in a radiograph of a chronic ulcer are shown in *Fig. 165*, a diagram adapted from Forssell, which shows the morphological changes to be expected in a chronic penetrating ulcer of the lesser curvature when it is viewed on the X-ray

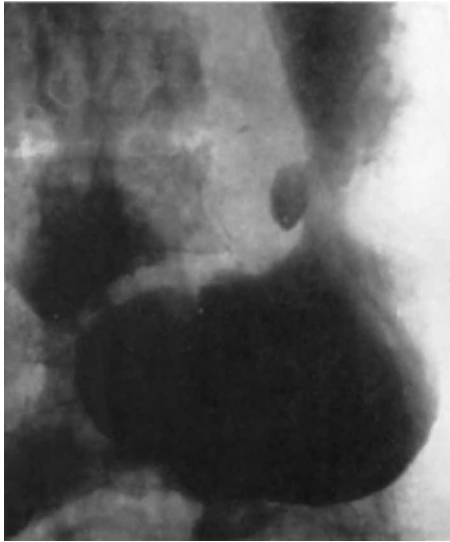


Fig. 166.—Chronic penetrating ulcer of the lesser curvature with hour-glass spasm.
(By courtesy of Dr. H. M. Hewlett.)

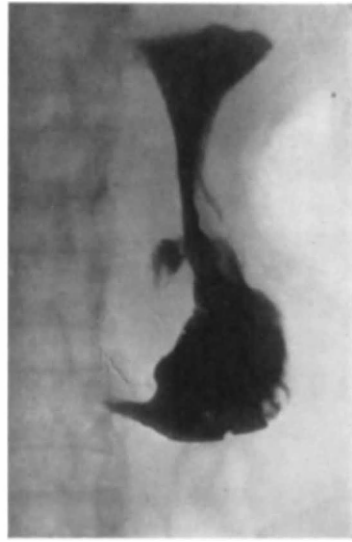


Fig. 167.—Chronic penetrating ulcer of the lesser curvature—an ulcer which requires surgical treatment.
(By courtesy of Dr. H. M. Hewlett.)

screen. *Figs. 166 and 167* are radiographs which show deep penetrating ulcers of the lesser curvature associated with considerable hour-glass contraction, and ulcers which are so chronic that surgical interference is indicated.

Superficial Gastric Ulcer.—In cases where the ulcer is definitely to be seen as a niche, no doubt will arise in regard to the diagnosis, and the 'deep tender spot' of course will be a secondary consideration. Where, however, no definite niche, or only a doubtful one, is to be seen, but where a 'deep tender spot' is found, and the patient has the typical symptoms of chronic peptic ulcer, then a good deal of reliance may have to be placed on the exact situation of the 'deep tender spot'. Here the surgeon can help. If he can actually assign this 'deep tender spot' to the *Magenstrasse*, the area in which we

know gastric ulcers occur, then this observation is strong presumptive evidence that a gastric ulcer is present but that it has not penetrated deeply enough to show a definite niche.

This type of superficial ulcer, however, would not require surgical treatment, and the surgeon would naturally suggest that its treatment should be handed over to the physician.

Florid Ulcer on the Scar of a Healed Ulcer.—As a rule, an ulcer which has not penetrated the gastric wall—that is, an ulcer which is only superficial—is better treated medically. But a subacute or chronic ulcer which has formed on the scar of a healed ulcer, although it does not penetrate, may require surgical treatment, for this type of ulcer is likely to produce not only serious but also constantly recurring hæmatemeses.

In these circumstances the surgeon may be able to help in the recognition of such an ulcer, for the clinical history which he can bring forward may assist in its detection. He may be able to adduce evidence that although at the time of the examination the patient complained of only a *painless* dyspepsia, he or she had a previous history of a *painful* dyspepsia. Such history would be evidence of the previous existence of a chronic ulcer. In the case of such a suspicion, the radiologist may find some X-ray evidence of a previous chronic ulcer, such as distortion of the gastric wall as a result of scar formation, hour-glass contraction, or deformity of the duodenal wall.

Ulcer as a Cause of Hæmatemesis or Melæna.—After a patient has recovered from a hæmatemesis, an X-ray examination is usually made in order to find out if the bleeding has been caused by an ulcer which can be surgically remedied.

A chronic ulcer will of course be obvious; whereas an acute ulcer will leave no X-ray evidence of its presence.

An acute ulcer which forms on a chronic ulcer scar will give some X-ray indication of the presence of the scar which followed the healing of the ulcer—indications such as have just been described. The importance of recognizing the formation of subacute or chronic ulcer on the scar of a healed ulcer is important, for this type of bleeding ulcer often requires surgical treatment. Bleeding from such an ulcer is usually classified under the *painless* hæmatemeses, and therefore among those hæmatemeses which are treated medically; but the question of treating such bleeding in its early stage by partial gastrectomy should always be considered.

The Nature of an Hour-glass Contraction.—In connexion with the diagnosis of chronic peptic ulcer, the question of the nature of an hour-glass contraction will frequently come up for discussion. Is

an hour-glass contraction the result of the fibrosis and the muscular spasm which usually accompany innocent gastric ulcer? Or is it due to a malignant infiltration of the circularly running lymphatic vessels, and the consequent contraction?

The isthmus of an innocent hour-glass contraction found associated with chronic ulcer is always eccentric, that is, it is situated on the lesser curve. Further, unlike hour-glass contraction which is

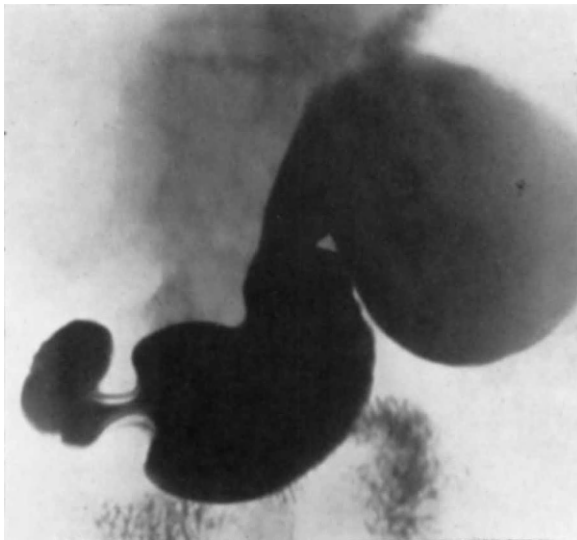


Fig. 168.—Hour-glass spasm in a stomach without an ulcer. Note position of isthmus close to the lesser curvature, and the sharp outline of the hour-glass.

caused by carcinoma, the edges of its barium shadow are sharp and homogeneous in their denseness (as in *Fig. 168*).

The isthmus of an hour-glass contraction caused by carcinoma is nearly always central. Its edges are not sharp, and the barium shadow in the vicinity of the isthmus is not homogeneous in its denseness. Further, any indentation of the lesser curve side of the isthmus towards the lumen and away from the normal line of the lesser curve of the stomach, as shown in *Fig. 169*, is always suggestive of malignancy.

However, a chronic innocent ulcer of the posterior gastric wall may also give rise to an hour-glass with a central isthmus. Such an ulcer is seen in *Fig. 76* (p. 138), a radiograph showing an hour-glass which resulted from an ulcer of the posterior wall. But in this case the isthmus has sharp edges and a uniformly dense barium shadow to the actual edges of the isthmus.

The absence of a 'deep tender spot' is also indicative of an hour-glass of malignant origin. The presence of a 'deep tender spot' in an hour-glass contraction suggests ulcer as its cause, for such an hour-glass generally retains some inflammatory characteristics because the ulcer which has caused it is usually not completely healed. It should be remembered, however, that an hour-glass contraction

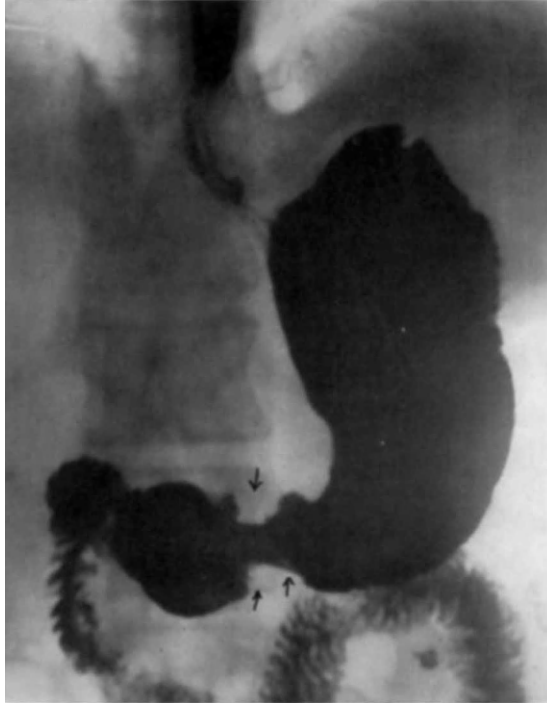

Fig. 169.—Radiograph showing an hour-glass contraction caused by carcinoma. The central situation of the isthmus is seen, and the arrows point to the slight irregularities in density of its edges.

resulting from an ulcer of the posterior wall may have no 'deep tender spot'.

Association of Pyloric Stenosis with Chronic Gastric Ulcer.—Another radio-surgical problem in relation to the pathology of chronic gastric ulcer is whether there is evidence of an associated mechanical pyloric obstruction. Any high-grade organic pyloric stenosis is always obvious, but minor grades may be missed, and it is these grades which, when found in association with a chronic gastric ulcer, turn the scale in favour of its surgical treatment. They are often missed, because some radiologists rely on a six-hour observation of the

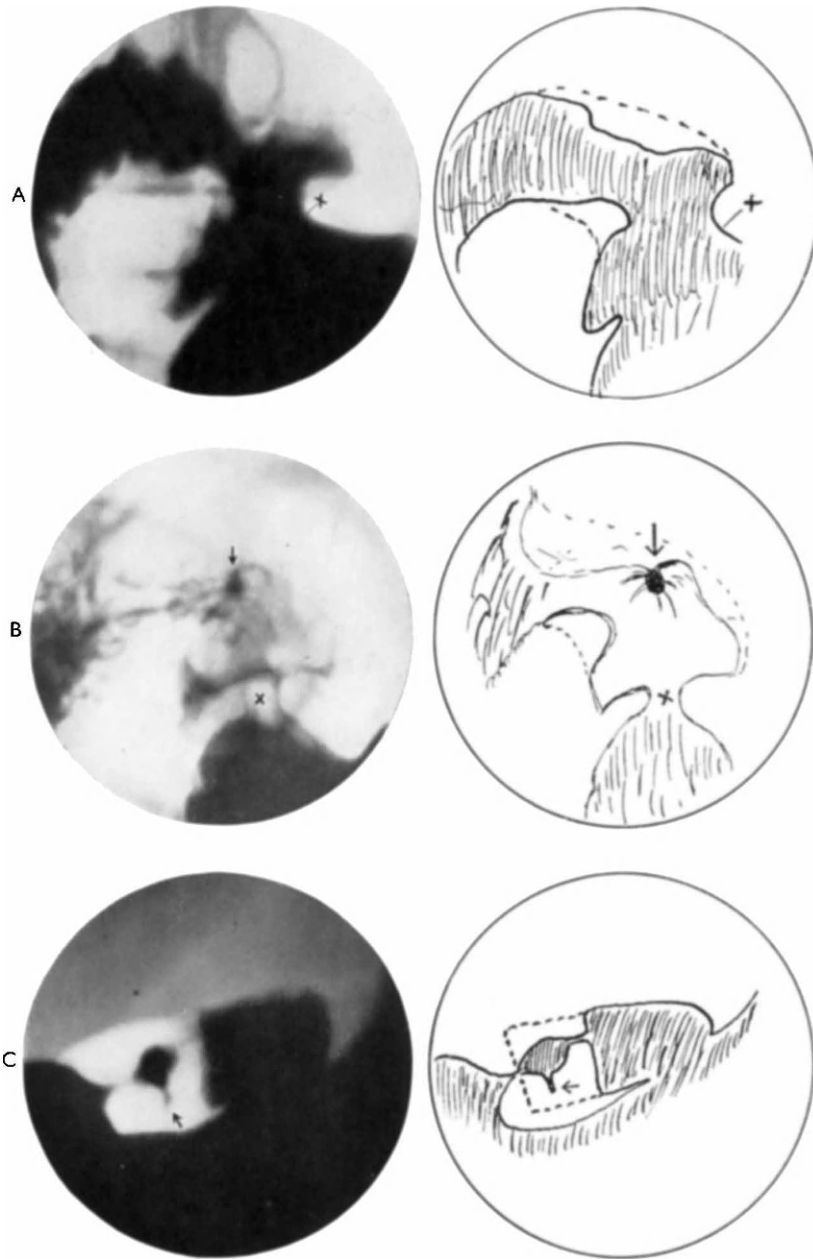

Fig. 170.—A, Typical deformed duodenal cap; B, *En face* niche; C, Profile view—niche on posterior wall. Arrows point to niche. X, Pylorus.
(Cordiner and Calthrop. From the 'British Journal of Surgery'.)

emptying time, and are satisfied, if the stomach empties in six hours, that there is no pyloric stenosis. A six-hour emptying time in the presence of a strongly hypertrophied gastric muscle and powerful peristaltic waves is indicative of a moderate grade of organic pyloric obstruction and invites surgical attention. On the other hand a six-hour emptying time in association with a hypotonic gastric muscle would not be significant of any obstruction, and would not be of any surgical import. Therefore in assessing the permeability of the pylorus, the *emptying power* of the gastric muscle should be balanced against the *emptying time* of the stomach.

2. Chronic Duodenal Ulcer.—As a rule, in well-established duodenal ulcers in the usual position on the antero-lateral wall the 'deep tender spot' is very definitely over the duodenum. Furthermore it corresponds with a niche which can be demonstrated. Such an ulcer presents no radio-surgical problem; the surgeon can study its pathology in regard to chronicity and to the presence of complications, and can then decide whether it should be treated medically or surgically.

A well established definite ulcer of the antero-lateral duodenal wall gives rise either to a niche, or to deformity of the duodenal bulb, or to both. *Fig. 170* (Cordiner and Calthrop¹) shows a series of radiographs with illustrative diagrams of duodenal deformity with niche seen *en face* and in profile. The niche is seen as a marginal fleck or as a dense spot within the barium shadow, which must be demonstrated as a rule by graduated pressure over the bulb ('dosed compression').

Radiographs made in the usual way may show a normal bulb which conceals a duodenal ulcer niche.

In *Fig. 171* is seen a radiograph made in the ordinary way (without compression) of the duodenum of a patient who had the clinical symptoms of duodenal ulcer, but no X-ray sign of the condition. Operation revealed a duodenal ulcer.

In the great majority of cases of duodenal ulcer it is possible to demonstrate a niche in association with deformity of the duodenal bulb. Deformity of the duodenal bulb is due to scar contraction, to spasm of the muscularis mucosæ, or to both. To be diagnostic of duodenal ulcer it must be persistent in position and contour. Deformity of the duodenal bulb, however, is not pathognomonic of ulcer. The demonstration of a niche is the only reliable evidence of the presence of duodenal ulcer.

There are, however, in connexion with dyspepsia accompanied by a duodenal 'deep tender spot', two radio-surgical problems:

the problem of the *ulcer of the posterior duodenal wall*, and that of the *indefinitely demonstrable duodenal ulcer*.

Ulcer of the Posterior Duodenal Wall.—Ulcer of the posterior duodenal wall is very often not seen during an X-ray examination, or only indefinitely seen. As a rule, too, it does not give rise to a definite 'deep tender spot'. It may therefore be missed.

Thus in a clinical complex suggesting a duodenal lesion—perhaps a painless acid type of dyspepsia with profound attacks of melæna—the posterior duodenal wall requires to be radiographed in lateral positions, with 'dosed compression', and with the advantage

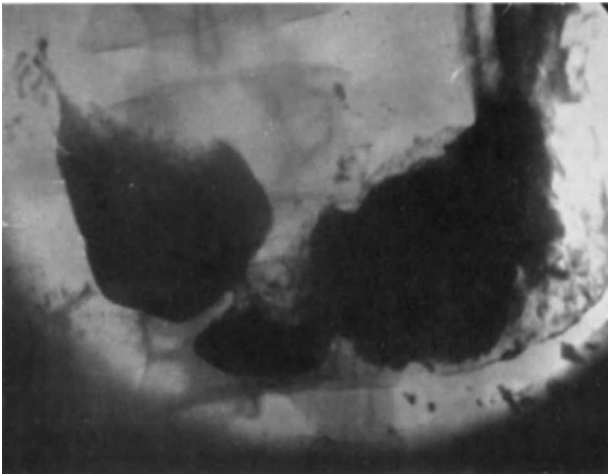


Fig. 171.—Radiograph of an apparently normal duodenal cap in which an ulcer was found at operation.

of every radiographic artifice, in order to exclude the possibility of ulcer in this position. Ulcer in this situation is, however, dealt with in the next chapter under *Group 5*, where it is discussed in regard to the differential diagnosis of gastric carcinoma.

Indefinitely Demonstrable Duodenal Ulcer.—In the case of the indefinitely demonstrable ulcer of the duodenum, the problem which confronts the consultants is that the patient has a painful dyspepsia of the duodenal ulcer type, a 'deep tender spot' over his duodenum, radiologically a deformity of his duodenal bulb, and yet he has no definite ulcer niche which can be demonstrated.

Although these duodenal-ulcer-like manifestations may be due to a small undemonstrable duodenal ulcer, they can be caused by duodenitis, which we know can mimic the symptoms of duodenal ulcer and cause a duodenal deformity as a result of a muscular spasm.

Consequently the clinical and X-ray distinction between duodenal ulcer and duodenitis comes up for discussion.

Duodenitis has the same cause as duodenal ulcer, that is, high acidity; and it usually gives rise to the same clinical symptoms. A localized 'deep tender spot' may be present as a result of a duodenal erosion which has formed on the basis of the duodenitis. Usually, however, a general duodenal tenderness is found. A duodenitis may show a pseudo-niche (*Fig. 172*, from Cordiner and Calthrop¹), and even, too, a small duodenal ulcer. However, as far as the surgeon is concerned, a duodenal ulcer which demands surgical treatment should be clearly demonstrable by X rays. If therefore the radiological diagnosis is only 'suspected' duodenal ulcer, it is better surgical judgement to agree that the physician should take over the treatment of such cases, except perhaps where the patient is suffering from alarming attacks of *melæna*.

Thus the problem of the indefinite ulcer of the duodenum and the question of the presence of duodenitis is not a very real one for the surgeon.

3. Reflex Dyspepsia.—In a case of painful dyspepsia in which the 'deep tender point' corresponds neither to the stomach nor to the duodenum, the question of the presence of a reflex dyspepsia arises. The clinical question must then be discussed to ascertain if there are manifestations of gall-bladder, appendiceal, pancreatic, intestinal, colonic, or renal disease.

Here again the correlation of essential points in the history with essential points in the radiological findings will probably establish the diagnosis. By utilizing the various X-ray methods, an attempt must be made to localize the gall-bladder and the appendix. The situation of the 'deep tender spot' must then be compared with the position of these organs. Their exact radiographic localization is always important, for the following reasons: The gall-bladder may be abnormally situated, and be as low as the usual level of the appendix, and what is regarded as an appendicitic may really be a

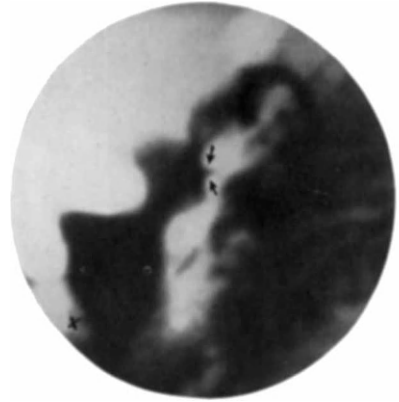

Fig. 172.—Radiograph showing the deformity of the duodenal cap due to duodenitis. A pseudo-niche (shown by arrows) is seen in profile on the posterior wall. X, Pylorus. (Cordiner and Calthrop. From the 'British Journal of Surgery'.)

cholecystic 'deep tender spot'. On the other hand, the appendix may be undescended, and be situated as high as the usual level of the gall-bladder, and what is regarded as a cholecystic 'deep tender spot' may actually be due to tenderness of a highly placed, inflamed appendix. This information—the position of the appendix and the gall-bladder—is important to the surgeon not only from a diagnostic

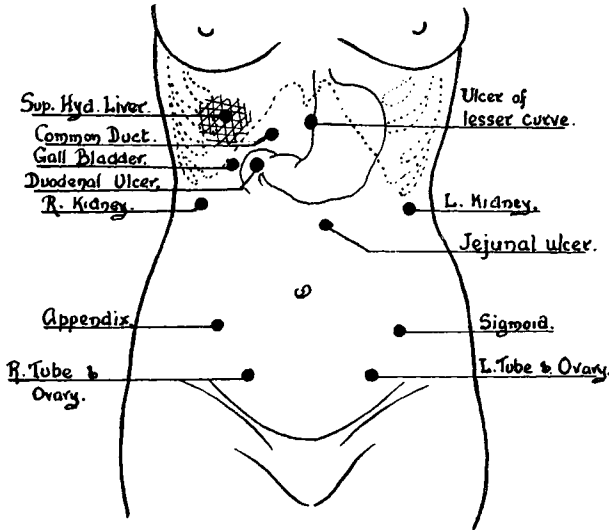


Fig. 173.—Diagram showing the typical positions of the various 'deep tender spots'.

but also from an operative point of view, for it tells him where to place his incision and therefore how to make the operation easy.

Fig. 173 shows the typical positions of the various 'deep tender spots'.

4. Gastritis or Intrinsic Neuromuscular Disorder.—If in the investigation of a case of painful dyspepsia with a definite 'deep tender spot', or with diffuse tenderness, neither chronic gastric or duodenal ulcer nor reflex dyspepsia can be demonstrated, then it becomes a question in the discussion with the physician whether or not the painful dyspepsia is due to either of the following: (a) that form of gastritis described by some as 'ulcer gastritis', and by Konjetzny and others as a definite entity; or (b) an intrinsic painful neuromuscular disorder of the stomach.

In regard to *gastritis*, I am not able to say from my own experience that the form of gastritis described by Konjetzny occurs as frequently in patients in Australia as it does in Central Europe. I have, however, seen many cases of painful dyspepsia of the gastric

ulcer type with rather *diffuse tenderness* over the stomach. These cases have come under notice because they have been diagnosed as gastric ulcer. At operation I found a gastritis but no ulcer. Some of these cases have come to my clinic many years later with definite gastric ulcer. There is therefore in my opinion a form of gastritis, precedent to gastric ulcer, which gives symptoms and signs like those of gastric ulcer.

In regard to *intrinsic painful neuromuscular disorder of the stomach*, this condition may be associated with diffuse sensitiveness in the epigastrium. Stigmata indicating instability of the nervous system or a gastric diathesis of the vagal type may be found to support a diagnosis of the condition. However, a diagnosis of neuromuscular disorder is a dangerous one to make in a case of a painful dyspepsia, and should only be made when it is possible to keep the patient under observation. Such a diagnosis may satisfy the physician's or the surgeon's conscience and prevent his continuing the investigation; for it is not uncommon to find that signs of organic disease, such as carcinoma, too early to be obvious when the diagnosis of neuromuscular disorder was made, are found at a subsequent radiological examination (*see* Chapter XXVII).

REFERENCE

- ¹ CORDINER, G. R. MATHER, and CALTHROP, G. T., "The Radiography of the Duodenal Cap", *Brit. Jour. Surg.*, 1936, **23**, 700.

CHAPTER XXIX

**RADIO-SURGICAL PROBLEMS IN THE DIAGNOSIS OF
DYSPEPSIA OF MALIGNANT OR SUPPOSEDLY
MALIGNANT ORIGIN**

Group 5.—**PAINFUL DYSPEPSIA WITHOUT A ‘DEEP
TENDER SPOT’**

THE discussion in regard to the radio-surgical problems in the diagnosis of a dyspepsia of malignant or supposedly malignant origin will not be concerned so much with those frankly malignant manifestations which as a rule are so easy to recognize by X rays. It will be concerned more with those forms of dyspepsia produced by certain forms of inflammatory disease which resemble the dyspeptic syndromes caused by malignancy, with those obscure forms of malignant disease the X-ray characteristics of which are not well recognized, and with those equivocal filling defects which constitute radio-surgical problems.

INFLAMMATORY CONDITIONS RESEMBLING MALIGNANCY

Of the inflammatory diseases which give a clinical dyspeptic picture like that of a malignant stomach, the most important are old penetrating ulcer of the posterior gastric wall, and old penetrating chronic ulcer of the posterior duodenal wall.

Ulcer of the Posterior Gastric Wall.—In the investigation of a case of painful dyspepsia, in which no ‘deep tender spot’ can be felt, the natural conclusion based on clinical grounds (*see* p. 139 on ‘Penetrating Ulcer’) would be that the case was one of gastric carcinoma. In such a case it frequently happens that a gastric carcinoma cannot be demonstrated.

The surgeon may then suggest that attention should be focused on the posterior wall of the stomach or of the duodenum, because in these situations a chronic ulcer may not give rise to a ‘deep tender spot’, and because it may give rise to a carcinoma-like syndrome which comprises a moderate grade of *gastric-ulcer-like painful dyspepsia*, recurrent small hæmatemeses and melænas, hypochlorhydria, some X-ray deformation, and delay in gastric emptying.

In the case of such a problem attention must be concentrated on lateral and oblique views, for this is the best way to demonstrate chronic ulcer in that situation.

Ulcer of the Posterior Duodenal Wall.—A dyspepsia, not necessarily painful, an intense acidity, attacks of melæna, and a

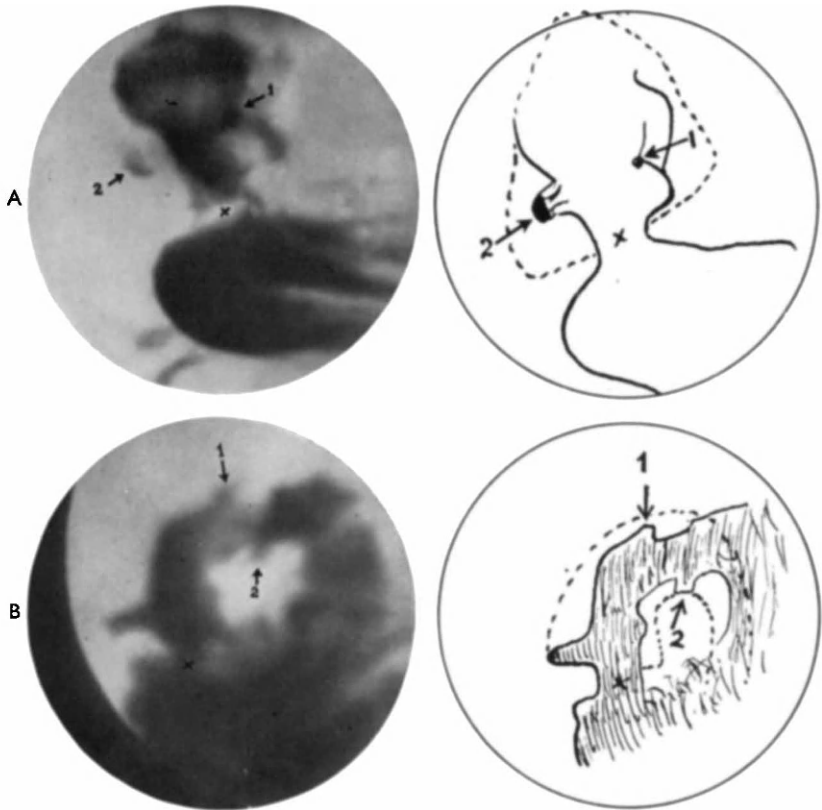


Fig. 174.—Posterior wall ulcer penetrating into pancreas. **A**, *En face* view. 1, Anterior wall ulcer. 2, Penetrating ulcer on posterior wall, showing accessory pocket and divergence of mucosal folds. **B**, Profile view of niches, V-shaped deformity of posterior wall with niche. Cap foreshortened in this view on account of fixation. X, Pylorus.

(Cordiner and Calthrop. From the 'British Journal of Surgery'.)

periodicity in such manifestations form the syndrome of ulcer of the posterior wall of the duodenum—a syndrome unlike that of carcinoma.

A 'deep tender spot' may not be obvious, although occasionally it is found. X-ray examination, too, may at first sight give little evidence of ulcer. Oblique views may, however, give an indication of its existence; but in some cases its presence can only be

inferred from deformation of the duodenal wall, the result of cicatricial contraction and muscular spasm. *Fig. 174* (Cordiner and Calthrop¹) shows the X-ray characteristics of an ulcer of the posterior duodenal wall.

OBSCURE FORMS OF MALIGNANT DISEASE

Invasive Gastric Carcinoma.—The investigation of a case of painful dyspepsia without a 'deep tender spot' has now arrived at a stage where any atypical chronic gastric or duodenal ulcer has been excluded. And it may be taken for granted that the common type of carcinoma would have been found.

The whole of the stomach should now be painstakingly examined in order to exclude any *early stage* of that invasive plaque-like type of fibro-cancerous gastric carcinoma which might easily pass unnoticed unless the radiographer had its possible presence prominently before him.

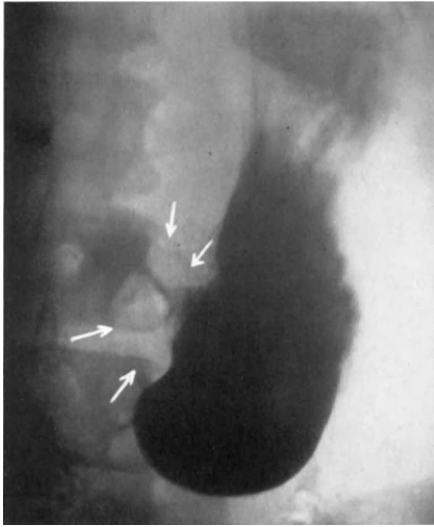


Fig. 175.—Radiograph of prepyloric filling defect, the early stages of which were mistaken for the spasm of ulcer.

In its early stages, this condition sometimes gives rise to a painful dyspepsia similar to that of gastric ulcer. It also produces such slight and

such sharp-edged deformities in the X-ray contours of the stomach that it is difficult to detect radiographically.

This form of carcinoma not uncommonly starts in the prepyloric part of the stomach, or in the gastric canal (*Magenstrasse*). *Fig. 175* is a radiograph which illustrates the type. It shows a prepyloric sharp-edged filling defect which in its early stages was regarded as the spasm associated with a small prepyloric ulcer. The clinical manifestations arising in this case of local invasive fibro-cancerous type of carcinoma were so like those from a gastric ulcer that they were regarded by a consulting physician as being caused by that condition. The X-ray appearances were regarded by the radiologist also as a result of a spasm associated with a small ulcer. The diagnosis was therefore gastric ulcer, and the patient was treated

for gastric ulcer for eight months without any doubt arising as to the correctness of the diagnosis.

In *Fig. 175*, taken nine months after the first radiographs (which were not good enough to reproduce), the edges in the density of the barium emulsion are still somewhat sharply defined. In the first radiographs the deformity was very slight and its edges were sharp and uniformly dense.

EQUIVOCAL FILLING DEFECTS IN THE BODY OF THE STOMACH

The Ordinary Type of Filling Defect.—As a general rule the radiologist experiences no difficulty in detecting a carcinoma of the stomach where it forms a definite filling defect recognizable not only by the defect caused by the tumour, but also by the contracting invasive infiltration with which it is associated. Even when gastric carcinoma takes the form of a definite papilloma-like tumour, it is usually accompanied by more or less invasive infiltration, which becomes obvious in the barium-filled stomach by contraction and deformity of the gastric wall in the neighbourhood of the tumour; and even when this papilloma-like carcinomatous tumour is small, or is hidden on the posterior wall, and therefore in danger of being missed as a filling defect, the effects of some invasive infiltration of the gastric wall—deformity, rigidity, interference with peristalsis—generally make it readily recognizable.

Fig. 152 (p. 235) is a radiograph which exemplifies this papillomatous type of carcinoma of the stomach, and shows the typical filling defect. It also shows the contraction that results from a certain amount of invasive infiltration of the gastric wall surrounding the base of the tumour.

Papilloma-like Carcinoma without Obvious Infiltration.—When the papilloma-like tumour exhibits no invasive tendencies, as sometimes happens, and therefore does not diminish the size of the stomach by contracting its wall, and does not interfere with peristaltic function, any filling defect caused by the tumour may not

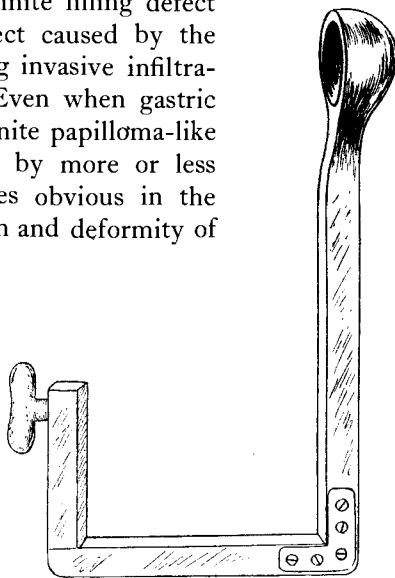


Fig. 176.—Type of wooden spoon (used by Howdek) for use in front of the X-ray screen.

show up in the dense shadow of the barium-filled stomach. If, in addition to this, a tumour of this nature lies on the anterior or the

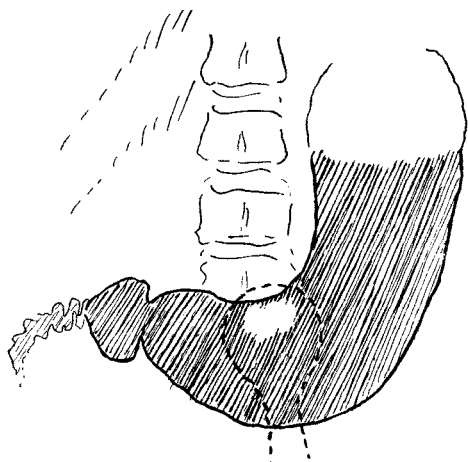


Fig. 177.—Drawing of a fluoroscopic image obtained while the wooden spoon exerts pressure, to demonstrate a small carcinoma of the stomach which would otherwise be radiologically invisible.

posterior wall, and thus comes within the shadow of the barium-filled stomach, it may be very difficult to detect. It is in such a type of tumour that pressure applied to the stomach during the X-ray screen examination, with a wooden spoon or with the hand, or with Berg's technique—'dosed compression'—will demonstrate it as a defect. Figs. 176, 177 illustrate the character and use of a wooden spoon suitable for this purpose.

PREPYLORIC EQUIVOCAL FILLING DEFECTS

There are certain types of prepyloric equivocal filling defects the nature of which may present a diagnostic problem. They may be caused by the following conditions: (1) Very local invasive carcinoma (*cancer en plaque*); (2) Prepyloric carcinomatous ulcer; (3) Malignant prepyloric defects; (4) Prepyloric filling defects due to syphilis; (5) Juxtapyloric small chronic ulcer; (6) Antral gastritis; (7) Non-pathological prepyloric filling defects.

1. Highly Invasive Carcinoma (Cancer en Plaque).—Under the heading of localized invasive carcinoma (p. 250), I have touched on the difficulty of making a diagnosis *in the early stages* of that invasive type of carcinoma called linitis plastica, the so-called carcinomatous fibromatosis. The condition must, however, be again briefly considered here in relation to equivocal prepyloric filling defects. This highly invasive form of carcinoma spreads in the coat of the gastric wall and produces a thickening, hardening, and contraction. It does not give rise to tumour formation, and therefore there is no filling defect. Its presence in the barium-filled stomach is only evident by a sharp-edged, often slight, deformation of the normal contours of the stomach; and when it occurs in the prepyloric region, the equivocal filling defect which it causes is particularly difficult to recognize.

A concrete example of this problem is the following:—

A patient suffering from a painful dyspepsia like that of gastric ulcer was radiologically investigated. A clinical diagnosis of prepyloric ulcer had been made; his free acid was normal, and his general health was good.

A radiograph (seen in *Fig. 160*, p. 249) showed a sharp-edged prepyloric alteration in the contour of the stomach. The radiologist regarded this as the muscular spasm which is found associated with chronic ulcer, and thought that it was caused by a prepyloric ulcer which was too small to be visualized.

Operation revealed a small invasive carcinoma limited to the prepyloric portion of the stomach.

I know quite well that not all radiologists, for some are more expert than others, would make a diagnosis of prepyloric ulcer in this case. But there are—and I have seen them—still more equivocal types of prepyloric invasive carcinomas, and this example, although it exemplifies a rather gross mistake, is useful as a pointed illustration. The radiologist finds great difficulty in making a diagnosis in these localized prepyloric malignancies. He obtains very little help from his consultative physician and surgeon, because these slow-growing fibrocarcinomatous conditions do not produce a clinically recognizable painful dyspepsia, or always occult blood in the fæces, or a palpable tumour; and he obtains little help from his radiographic screen because they produce little recognizable diminution of the size of the stomach—in their early stages, at any rate.

2. Prepyloric Carcinomatous Ulcer.—A prepyloric carcinomatous ulcer of the posterior wall can cause rather a curious equivocal prepyloric filling defect. Fortunately, however, this condition is rare.

Fig. 82 (p. 150) shows a radiograph of a prepyloric filling defect found in a patient who appeared to be healthy and who gave few clinical symptoms suggestive of carcinoma. At operation, it was found that a carcinomatous ulcer had caused the defect. *Fig. 80* (p. 148) shows the position of the ulcer and its type. It was a sharply defined malignant ulcer, with no macroscopical evidence whatever of permeation or dissemination, but with its base very definitely infiltrated. It was almost indistinguishable from innocent ulcer.

As will be seen from the radiograph, there is no sign of the very definite crater shown in the sketch. The X-ray evidence is only that of a deforming prepyloric lesion.

3. Malignant Prepyloric Defects.—Early and small malignant growths may cause filling defects in the prepyloric region which because of their smallness are difficult to distinguish from prepyloric spastic disturbances or sphincteric hypertrophy.

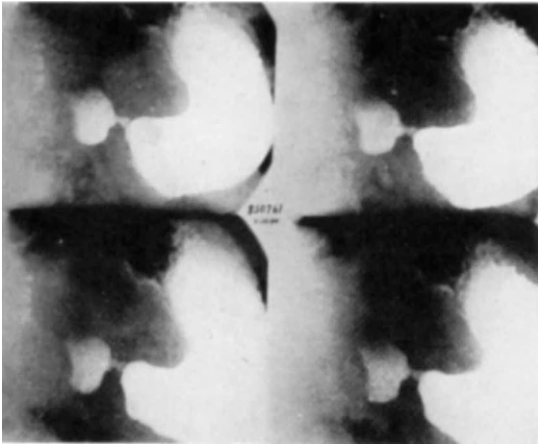


Fig. 178.—Small annular carcinoma of the prepyloric end of the stomach.
(*Balfour and Eustermann.*)

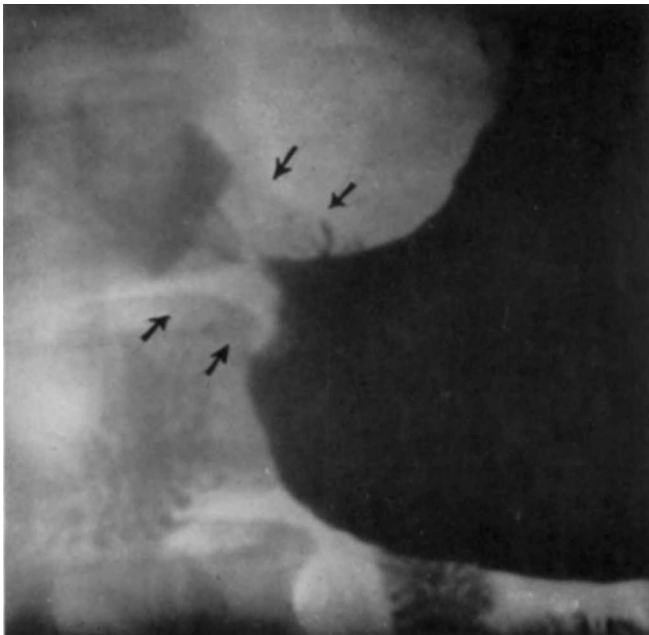


Fig. 179.—Prepyloric malignancy.

Fig. 178, taken from Balfour and Eustermann's book,² shows this type of small prepyloric filling defect caused by an early malignancy. In *Fig. 179* is seen a radiograph of a definite type of prepyloric malignancy, which can be compared with *Fig. 178*. The patient had for twelve months symptoms definitely indicative of cancer. The growth was of the invasive type, with very little tumour formation. The stomach was dilated and hypertrophied. It is in the early stage

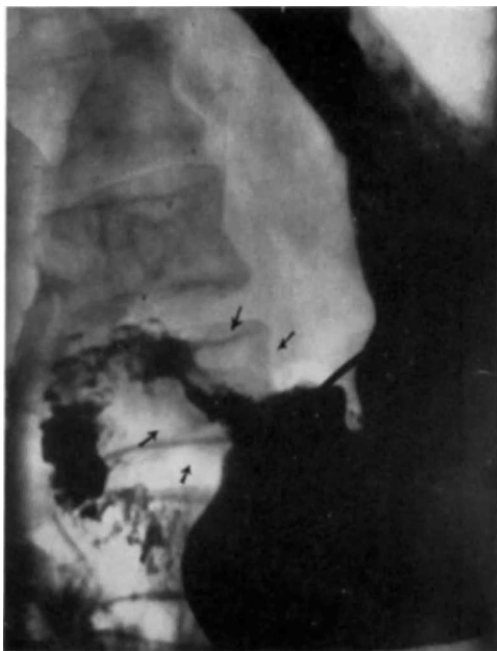


Fig. 180.—Definite prepyloric filling defect.

of such a growth (twelve months previously) that the recognition of the filling defect should be made.

Fig. 180 illustrates a case which had progressive dyspeptic symptoms and not a great deal of dilatation of the stomach, and in which it was clinically difficult to say whether the man was suffering from a malignancy or not. The radiograph shows an advanced prepyloric filling defect. Operation disclosed a highly invasive small carcinoma with permeating nodules spreading from it in all directions.

4. Prepyloric Filling Defects due to Syphilis.—Syphilis, when it occurs in the prepyloric part of the stomach—though it does so

rarely—causes an indefinite filling deformity which adds to the difficulties of the radiographic diagnosis of this region. It can produce prepyloric distortion, as seen in *Figs. 181, 182.*

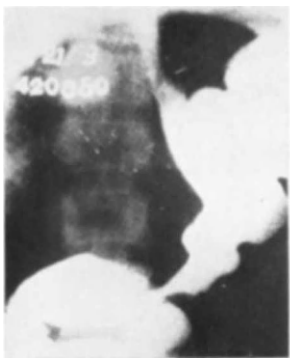

Fig. 181.—Extensive syphilis of the stomach.

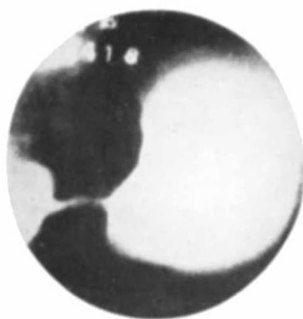

Fig. 182.—Syphilis of the prepyloric end of the stomach.

(*Balfour and Eustermann.*)

5. Juxtapyloric Small Chronic Ulcer.—A juxtapyloric ulcer will often cause a curiously extensive prepyloric filling defect, which may be mistaken for one of prepyloric carcinoma. The sharp-edged deformity of the defect, which is caused by spasm, is almost indistinguishable from that caused by invasive prepyloric carcinoma. The following case-history is an example :—

The patient suffered from a severe epigastric pain, which came on suddenly after meals. The taking of food would ease the pain, but in a little while it would return, and sometimes would persist throughout the whole of a night. His epigastrium was diffusely tender and very rigid. Operation showed a small chronic ulcer, situated close to the posterior edge of the pyloric orifice. *Fig. 183* shows the filling defect in this case.

Fig. 184 shows not only the filling defect caused by the muscular spasm of prepyloric ulcer, but also the niche of the very small ulcer which gave rise to the spasm.

A juxtapyloric ulcer on the duodenal side of the pylorus may cause a curious prepyloric filling defect. In *Fig. 185* can be seen a very definite constant prepyloric deformation which could quite well be mistaken for that of an invasive carcinoma. This defect was found in a case of a large ulcer of the posterior wall of the duodenum, which had penetrated into the pancreas.

At operation the prepyloric part of the stomach was found to be perfectly normal.

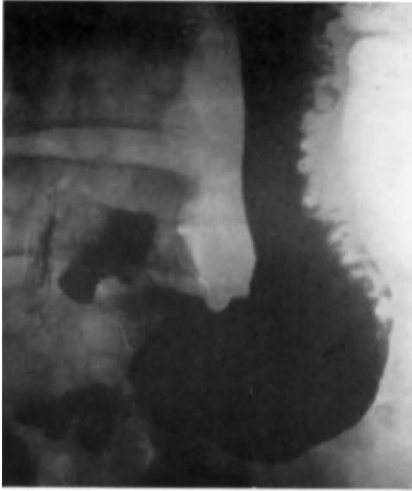


Fig. 183.—Ulcer of the posterior lip of the pylorus, showing a filling defect which for a time was regarded as a filling defect of carcinoma. Note that its edges are sharply defined, but it is a large defect, to be accounted for by muscular spasm.

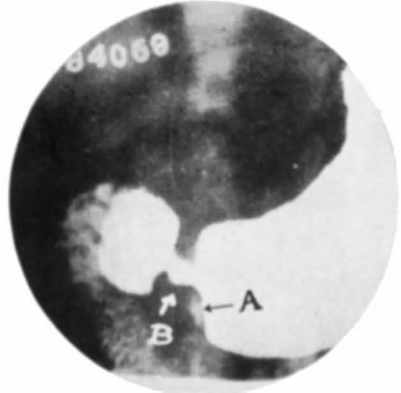


Fig. 184.—Gastric ulcer in the pyloric segment with some spasm of stomach. A, Ulcer; B, Filling defect due to spasm. (Balfour and Eustermann)

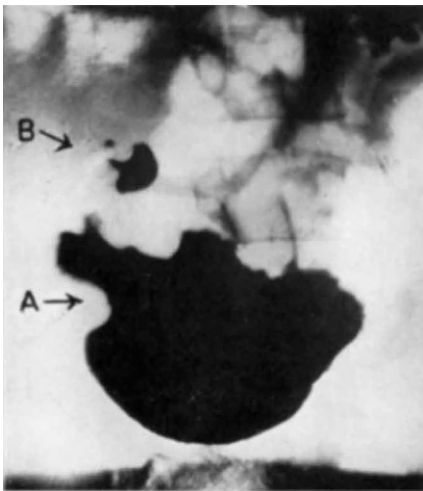


Fig. 185.—A, Fixed prepyloric spasm of the prepyloric part of the stomach; B, Very large penetrating ulcer of the posterior duodenal wall. (By courtesy of Dr. John O'Sullivan.)

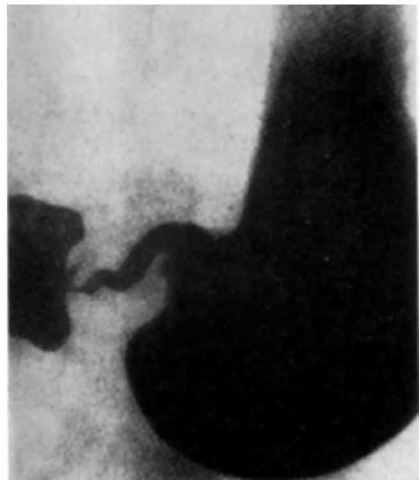


Fig. 186.—Prepyloric distortion caused by antral gastritis. (Wanke.)

6. Antral Gastritis.—Prepyloric distortion can also be caused by a chronic gastritis—the chronic antral gastritis of Konjetzny. In this condition, which involves only the pyloric part of the stomach, the prepyloric part may become pinched into a narrow isthmus with sharp edges about one inch long, as shown in *Fig. 186*, taken from Wanke.³

The patient to whom *Fig. 186* refers was a man, aged 37. For four years he had suffered from a periodical repetition of “stomach trouble”.

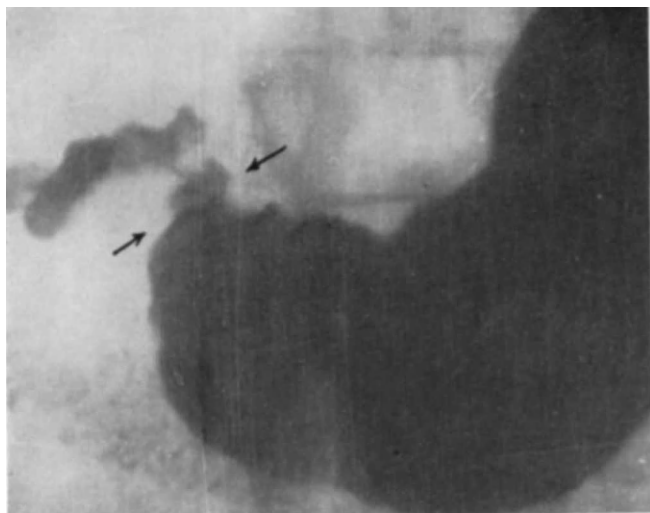


Fig. 187.—Prepyloric filling defect.

He had a feeling of pressure in the epigastrium one or two hours after meals. He had much eructation, and during the latter months of his history almost daily vomiting. In recent months he had lost 19 lb. in weight. On examination he had tenderness in the epigastrium. Occult blood was found in the stool. Test breakfast showed an acidity.

The operation disclosed a peculiar plastic thickening of the stomach wall in the pyloric region.

7. Non-pathological Prepyloric Filling Defects.—Prepyloric filling defects similar to and almost indistinguishable from those of prepyloric carcinoma are often found in the absence of any pathological lesion demonstrable at operation.

The following types exemplify these defects :—

Presphincteric Prepyloric Filling Defects.—There is a prepyloric defect which is probably due to abnormal distribution of sympathetically innervated prepyloric muscle-fibres. In the presphincteric

region of most hollow organs there is developed a fan of muscle-fibres, and these are supposed to be sympathetically innervated like the fibres in the sphincter itself. This fan of muscle-fibres varies in different animals, and I believe is more or less developed according to the particular hollow organ. I also believe, from my own clinical observations, that in man these presphincteric fibres are highly developed in some individual cases; and that where they are so developed they give rise to a type of prepyloric filling defect which is very like that of an early carcinoma.

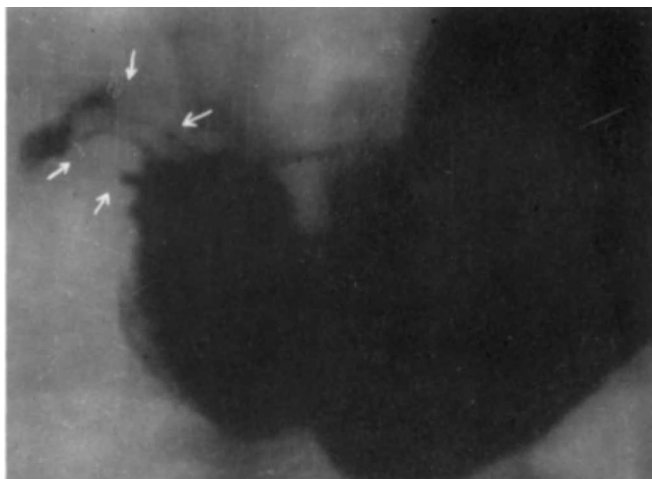


Fig. 188.—Same filling defect as in *Fig. 187*, taken five years later.

In the following case, the radiological problem which arose is a good example of the difficulty in diagnosis which can occur in regard to this type of filling defect:—

A patient complained of a mild dyspepsia. He was sent by his physician for an X-ray examination. The radiologist gave an X-ray report, the tenor of which was that he thought that the stomach showed a prepyloric filling defect, through which the peristaltic waves did not pass, and a filling defect which he felt was caused by an early prepyloric carcinoma. *Fig. 188* shows this radiograph. The defect was constant. Fortunately the patient had had a radiograph taken five years previously (*Fig. 187*), and when the two were compared it was found that the filling defect was almost exactly the same in the earlier radiograph. The patient was thus saved an unnecessary exploratory operation. Years later he was well.

Fig. 189 also shows this type of equivocal prepyloric defect (indicated by arrows). Note that the radiograph is a double exposure, and that the prepyloric filling defect is very sharp, showing its fixity.

In this case the patient was found at operation to have gall-stone disease. The prepyloric part of the stomach and the sphincter were somewhat hypertrophied.

The following somewhat similar case presented the same difficulty. The patient, who had been ill for a month suffering from difficulty in getting his bowels open, one or two vomiting

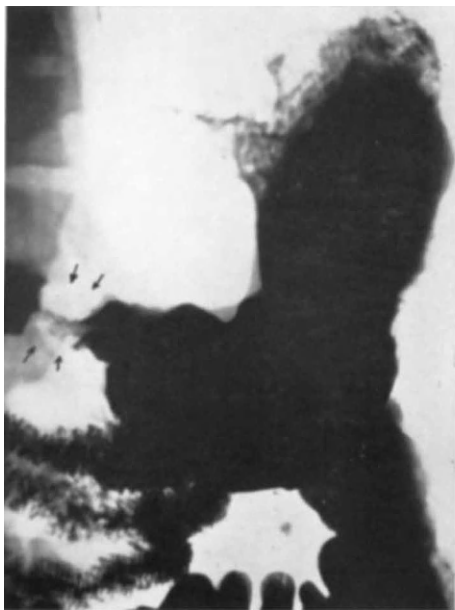

Fig. 189.—Equivocal prepyloric defect. At operation the patient was found to have gall-stone disease. The prepyloric part of the stomach and the sphincter were somewhat hypertrophied.

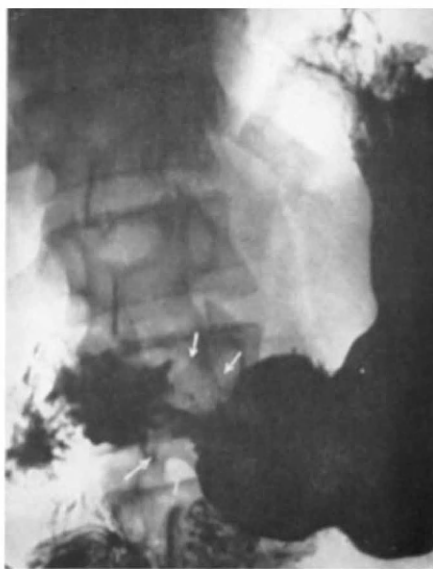

Fig. 190.—Persistent filling defect in prepyloric region.

(By courtesy of Dr. John O'Sullivan.)

attacks, and a certain amount of loss of energy, was sent to the radiologist for examination. The radiologist reported that the radiograph of the stomach showed a persistent filling defect in the prepyloric region (*Fig. 190*). The patient was explored, but no pathological condition was found in the region of the prepylorus, and no hypertrophied sphincter. This condition, too, is likely to have been a defect in the filling of the presphincteric region caused by an abnormal distribution of the sympathetically innervated muscle in the vicinity of the sphincter.

Hypertrophy of the Pyloric Muscle.—An unpathological prepyloric filling defect can also be caused by hypertrophy of the

pyloric muscle, and this condition is another factor causing confusion in a radiological diagnosis in the prepyloric region. In adults this hypertrophy produces a concentric prepyloric defect, the pyloric

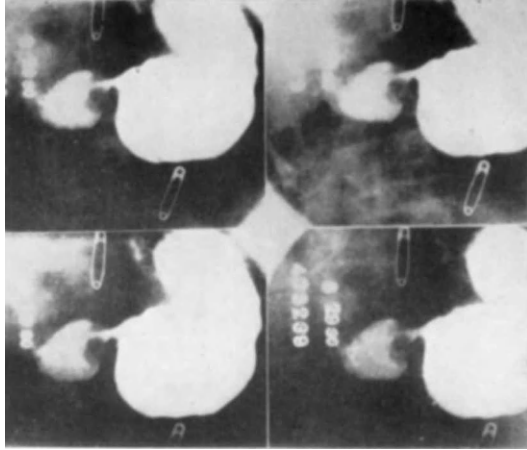


Fig. 191.—Simple hypertrophy of the pylorus, showing concavity of bulbar base. (Balfour and Eustermann.)

canal being narrowed and elongated, and either straightened or curved upwards.

Kirklín (Balfour and Eustermann²) shows that, in hypertrophy of the pyloric muscle, two common X-ray signs are present. The first

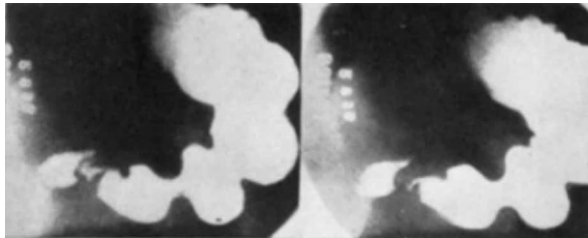


Fig. 192.—Simple hypertrophy of pyloric muscle, showing semilunar defect in lower border of pyloric canal. (Balfour and Eustermann.)

sign is that the normally flat, bulbar base is concave, the concavity evidently being produced by a partial invagination of the hypertrophied muscle into the bulb (*Fig. 191*). The second sign is that near the middle of the pyloric canal and on its lower border is a depression, appearing as either a narrow slit or a semilunar duct defect (*Fig. 192*).

The following case-record is a good example of this type of unpathological prepyloric filling defect.

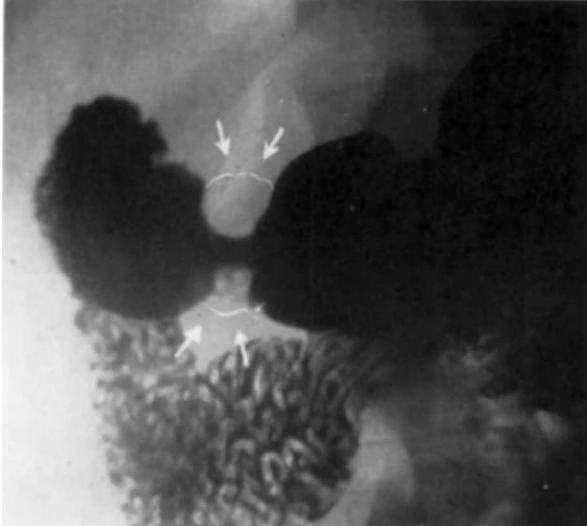

Fig. 193.—Filling defect (indicated by arrows) caused by hypertrophied sphincter. (By courtesy of Drs. Stuart Cowen and F. Stephens.)

Fig. 193 is a radiograph taken from a man who complained of indigestion. He consulted Dr. Stuart Cowen, who, regarding some points in the dyspepsia history as suggestive of early carcinoma of the stomach referred him for an X-ray examination. The radiologist reported a persistent prepyloric filling defect, probably caused by carcinoma. Arrows in *Fig. 193* indicate the defect caused by the hypertrophied sphincter.

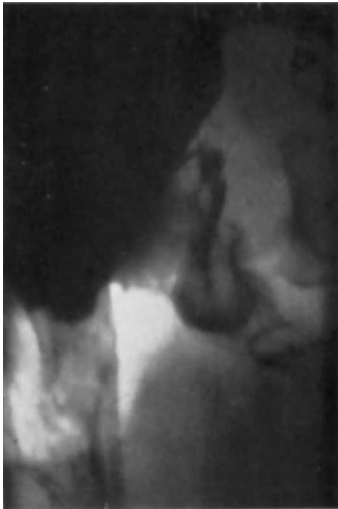

Fig. 194.—Prepyloric defect due to gall-bladder tumour. (Kirschner.)

At operation a very large hypertrophied sphincter was found. The width of the actual sphincter was about three-quarters of an inch. It had the appearance of a middle-grade hypertrophic stenosis of the pylorus.

Defect due to a Gall-bladder Tumour.—*Fig. 194* shows a filling defect in the prepyloric region which was caused by a gall-bladder tumour, the latter being the result of an enormous gall-stone.

MALIGNANT ULCER OF THE FUNDUS OF THE STOMACH

As I have already pointed out (p. 149), malignancy of the stomach not infrequently takes the form of a chronic ulcer which is macroscopically almost indistinguishable from an innocent chronic ulcer. The ulcer is sharply marked off from the surrounding gastric wall, has no obvious proliferation in its vicinity, and is not associated, at least in its early stages, with much contraction of the gastric wall. The main differences, however, from an innocent chronic ulcer are that it is much bigger; that its edges are shelving instead of being undermined as in innocent chronic ulcer; and that its base is hard and cartilaginous, and shows some evidence of contraction and wrinkling on the peritoneal side of the ulcer.

When an ulcer of this description occurs in the fundus of the stomach, as it did in the case illustrated in *Figs. 81, 83, 142* (pp. 149, 150, 226), it is very difficult to detect radiologically.

Although *Figs. 83* and *142* are excellent from a radiological point of view, yet they show very little sign of this malignant ulcer, except, perhaps, a slight distortion of the rugæ in *Fig. 142*, and a slight distortion of the line of the stomach in *Fig. 83*; signs seen readily enough after the operation but not before.

These malignant ulcers, although somewhat excavated like chronic ulcer, do not show the characteristic niche of the innocent chronic ulcer. The reasons for this are: (1) because the niche is not situated, as is that of the innocent ulcer, on the gastric canal, and consequently tangential to the line of X-ray observation; (2) because infiltration and contraction draw the base of the ulcer to the barium-filled lumen of the stomach where it is not well seen; and (3) because its edges are shelving.

In regard to clinical characteristics, the surgeon and the physician will be able to help the radiologist very little; for these malignant ulcers cause only a mildly painful progressive dyspepsia, extending over perhaps two years, with a very slow but rather progressive loss of health, and very little alteration in the patient's appearance.

THE CHRONIC INNOCENT ULCER WHICH BECOMES MALIGNANT

In 5 to 6 per cent of cases an innocent ulcer becomes malignant. The disappearance of the pain, and the loss of the 'deep tender spot', both of them typical of the florid innocent chronic ulcer, are warning signs of malignant degeneration of a chronic ulcer. These alterations in the manifestations are especially significant if at the same time the patient's general health begins to depreciate instead of

to improve, as it should if these alterations were due to the cure of the ulcer. They are additionally significant if a constant dull pain (the pain of carcinoma) again appears and nausea after food becomes a feature of the dyspeptic syndrome.

When a chronic ulcer becomes malignant, the radiograph shows the lesser-curvature side of any associated hour-glass contraction migrating towards the centre of the stomach, so that the isthmus of the hour-glass, which was previously on the lesser curvature, now appears to be situated more in the axis of the stomach. The base of the ulcer then comes to lie inside what should be the normal line of the lesser curvature. The ulcer also loses its sharp, excavated niche appearance, because its edges become shelved. Furthermore, palpation of the barium-filled stomach under the screen may show that it is more difficult to displace the barium in the vicinity of the ulcer: evidence that the gastric wall in the neighbourhood is rigid—the rigidity of infiltration.

PRONOUNCED PYLORIC OR DUODENAL STENOSIS

In the radiological diagnosis of the cause of a *high-grade pyloric stenosis*, the surgeon will always be interested. He will want to know whether the obstructing cause is the scar of a healed ulcer; the scar of a healed ulcer becoming malignant; or a scirrhus growth, often so slow-growing and so invasive that it is difficult to distinguish from an ulcer scar.

In the radiological diagnosis of *low grades of pyloric stenosis*, too, that is, in cases of mild obstruction, the surgeon will also be concerned. He will be on the look-out for the early stage of a prepyloric malignancy, or the beginning of organic stenosis in the case of ulcer.

In cases of high-grade pyloric stenosis, the clinical, the radiological, and the biochemical diagnoses may be equivocal: clinically, there may be an unrecognizable painless dyspepsia, no tumour, and, in the early stages, no constitutional evidence of malignancy; radiologically, the scirrhus may be so small that no filling defect may be obvious; biochemically, hydrochloric acid may be absent in all forms of pyloric stenosis. Therefore the culminating point in the diagnosis will be the comparison and correlation of the clinical, radiological, and biochemical findings—a consultation in front of the screen between surgeon, physician, and radiologist.

Fig. 195 is a radiograph in a case of pyloric stenosis following the scar of an old ulcer; and in this no filling defect in the pyloric region can be seen. *Fig. 196* is a radiograph in a case of duodenal

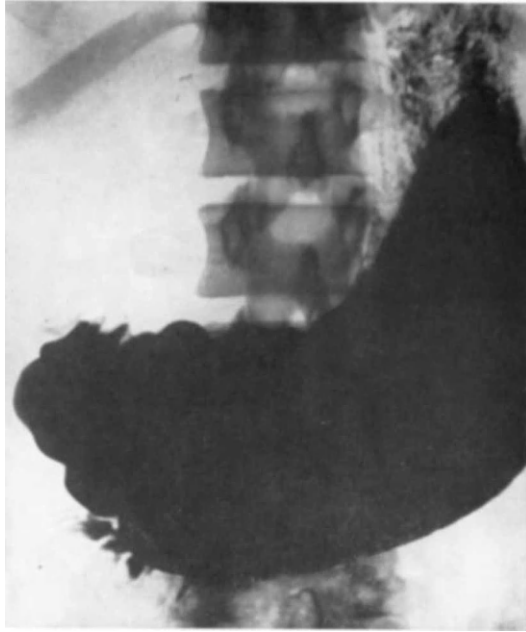

Fig. 195.—Pyloric stenosis following the scar of prepyloric ulcer. Note the bulbous end and the absence of a prepyloric filling defect.

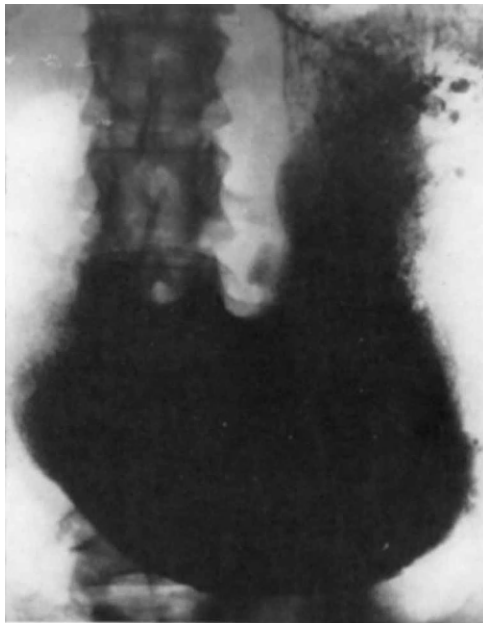

Fig. 196.—Duodenal stenosis following the scar of an old ulcer.

stenosis following the scar of an old ulcer. It will be seen that the radiological diagnosis of duodenal stenosis arising from the scar of duodenal ulcer may be almost indistinguishable from that of pyloric stenosis.

The distinction is important, because if a diagnosis can be made, a malignant condition can be excluded. On p. 165 the particulars are given of a case of duodenal stenosis in which there was enormous dilatation of the stomach (*Figs. 95, 96*). This in itself was sufficient to indicate that the stenosis could not be caused by a malignant pylorus; for the patient would, in most cases, have died from the effects of the growth before the stomach could attain such a degree of dilatation.

In most cases of pyloric or duodenal stenosis the radiological diagnosis will be in doubt. When such doubt arises in the consultation with the surgeon and physician the following questions will suggest themselves:—

1. Has there been any clinical evidence of a prepyloric or posterior wall duodenal ulcer? Such evidence may of course be years back and would be a history of a previous painful dyspepsia. If it is present it suggests that the stenosis is caused by the contracting scar of chronic ulcer.

2. What is the exact duration of the symptoms of pyloric stenosis, and how does this duration compare with the size of the stomach, as determined by X rays? In other words, what was the rate of the development of the pyloric stenosis? A *very large stomach* and a long history suggest innocency, for in the case of a carcinomatous pyloric obstruction the patient does not live long enough for a *very large stomach* to develop.

3. Is the constitutional disturbance due to nutritional loss only, or is it due to nutritional loss accompanied by a carcinomatous toxæmia? The patient with innocent stenosis has a starved appearance; but with malignant stenosis he has a starved and cachectic appearance.

4. When the barium in the stomach is 'hand-pushed' into the obstructed region, is the filling defect more than would be caused by an ulcer-scar—that is, is it the result of a scirrhus growth?

5. What is the rate of emptying compared with the power of the gastric muscle? Even a six-hour emptying time, if found in conjunction with a powerfully acting muscle, may indicate an early stage of organic pyloric stenosis—perhaps an early stage of carcinoma.

UNUSUAL TUMOURS OF THE STOMACH

If the radiological diagnosis up to the present stage has been fruitless, the surgeon must help to clear up the radiological situation by, as it were, a surgical drag-net: he must consider all the unusual pathological conditions which can occur in the stomach. These are as follows: (a) Sarcoma; (b) Adenoma; (c) Lipoma; (d) Myoma; (e) Polyposis.

Sarcoma.—As a rule, a sarcoma of the stomach, where its surface impinges on the lumen, shows an excavated ulcer with undermined

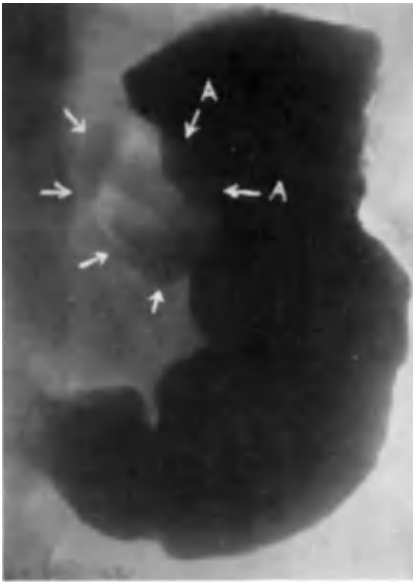


Fig. 197.—Sarcoma of the lesser curvature. Arrows point to the sarcoma. The arrows marked A point to the position of the ulcer.

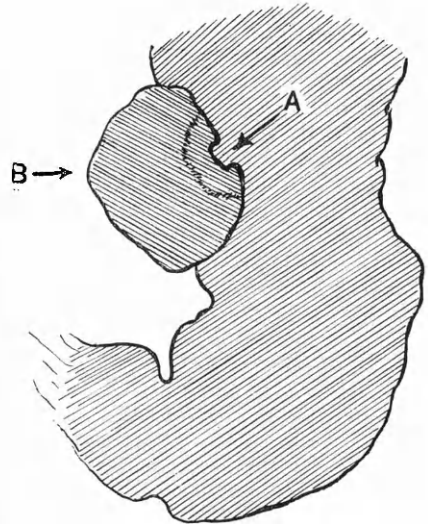


Fig. 198.—Illustrative sketch of the radiograph in Fig. 197. A, Ulcer; B, Sarcoma.

edges. Actually, many cases of sarcoma of the stomach have been diagnosed under X rays as chronic ulcer; for example:—

A patient complained of repeated attacks of hæmatemesis. These bleedings were not associated with any painful dyspepsia. The patient was young. A clinical diagnosis of acute ulcer was made. On X-ray examination (Figs. 197, 198) the niche of an ulcer could be seen. It was thought that this niche indicated a chronic peptic ulcer. The observation, however, which could have been but was not made, was that, surrounding the ulcer and in continuity with it, a lighter, regularly round shadow appeared. This shadow was caused by the sarcoma, and in the light of the operation findings was, of course, easily identifiable.

Operation revealed the fact that the niche was a shallow chronic ulcer on that part of an orange-sized sarcoma which projected into the lumen of the stomach.

Microscopical examination revealed the fact that the tumour was a spindle-celled sarcoma.

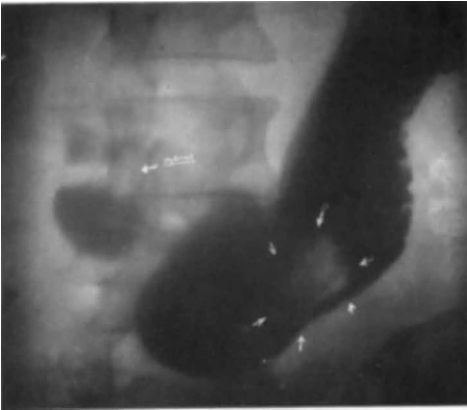


Fig. 199.—Radiograph of very chronic fibrosarcoma.

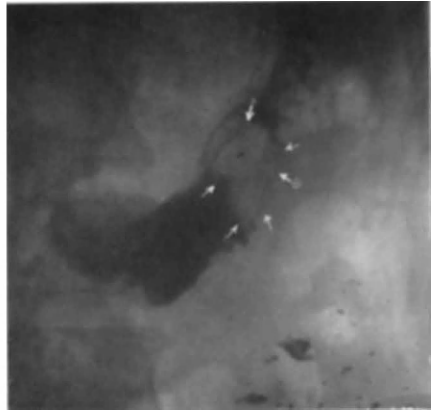

Fig. 200.—Radiograph taken after barium wash in the same case as Fig. 199.

(By courtesy of Dr. Cross.)

Fibrosarcoma.—

A deep niche was radiologically seen in a patient who suffered from continual hæmatemesis. The size of the niche indicated that it was caused by an ulcer about as large as a two-shilling piece.

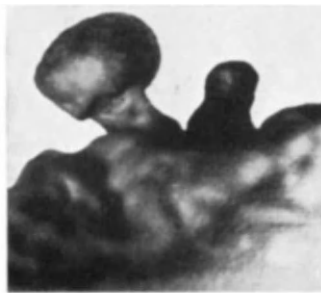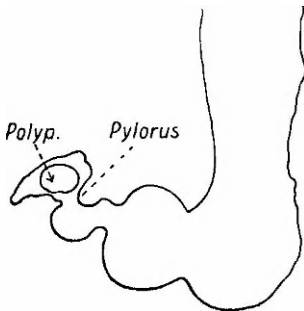


Fig. 201.—Intermittent pyloric stenosis from mucous membrane polyp in stomach. (From the 'Zentralblatt für Chirurgie'.)

At operation, a large fibrosarcoma of the stomach, adherent to the left lobe of the liver, was found, and on the surface of the tumour where it projected into the stomach a very large deeply excavated ulcer was situated. Microscopical examination showed that this was a fibrosarcoma.

Benign Type of Neoplasm.—A very *chronic fibrosarcoma* (a benign type) or an *adenoma* may show as a small filling defect without any accompanying deformity of the gastric wall. Radiographs of this type of fibrosarcoma are shown in *Figs. 199, 200.*

Myomas also show deeply excavated ulcers with undermined edges where the tumour impinges on the lumen of the stomach.

A *polyp* may show as a filling defect, and in addition it may give rise to pyloric obstruction, as shown in *Figs. 201* (taken from Hammesfahr⁴) and *202.*

As a rule, it is unusual for a negative shadow of an innocent tumour, such as a small myoma, to be seen. If it is big, it may show as a filling defect. Usually the bleeding and the X-ray niche draw attention to a gastric condition, and these manifestations lead to an erroneous diagnosis of chronic peptic ulcer. Generally, too, these benign gastric conditions give rise to only the mildest painless dyspepsia, and thus clinically there is very little to focus the radiologist's attention on them.

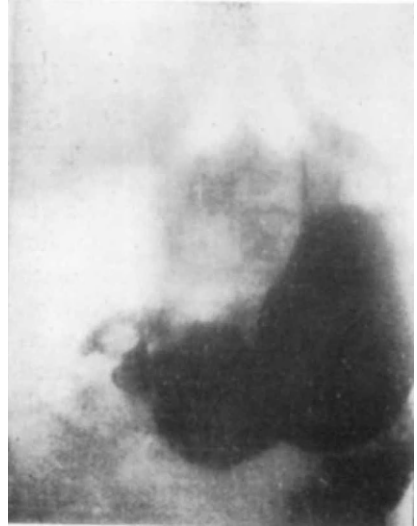

Fig. 202.—Intermittent pyloric stenosis from mucous membrane polyp in stomach.

REFERENCES

- ¹ CORDINER, G. R. MATHER, and CALTHROP, G. T., "Radiography of the Duodenal Cap", *Brit. Jour. Surg.*, 1936, **23**, 700.
- ² BALFOUR and EUSTERMANN, *The Stomach and Duodenum.*
- ³ WANKE, R., "Zur Röntgendiagnostik und Therapie der hypertrophischen Pylorusstenose auf dem Boden der chronischen Gastritis", *Zentralb. f. Chir.*, 1932, April 2, No. 14.
- ⁴ HAMMESFAHR, C., "Intermittierende Pylorusstenose durch Magenschleimhautpolyp", *Ibid.*, 1931, May 9, No. 19.

CHAPTER XXX

THE SURGEON'S SECOND POINT OF VIEW:
THE SURGERY OF THE LESION

FROM a diagnostic point of view the consultation will now have finished. The interest of the surgeon, however, will not yet have ceased. If a surgical lesion has been discovered in this consultation with the physician and the radiologist, the surgeon must study on the X-ray screen the pathology of the lesion with a view to its treatment.

Chronic Gastric and Duodenal Ulcer.—In the case of chronic peptic ulcer he must study this condition on the screen to see whether it is possible to treat it medically. He should compare the condition of the ulcer with the patient's clinical history, and with the amount and kind of medical treatment which has been carried out. The type of ulcer and its response to treatment should enable him to say whether it ought to be treated surgically.

Having decided that undoubtedly the lesion requires operation, the surgeon should study on the screen the difficulties and dangers in regard to its removal. In the case of a penetrating gastric ulcer, for example, it often happens that more useful knowledge in this respect can be obtained from the screen than at the operation table.

In *chronic gastric ulcer* questions like the following will crop up :

Is the ulcer so chronic that it will have to be resected? If this is necessary, should a partial gastrectomy be performed? Or would a local resection and gastro-enterostomy do? The answer to all these questions lies on the screen. The exact situation of the ulcer; evidence of great chronicity or of doubtful malignant degeneration; the presence of complications such as hour-glass, pyloric stenosis, etc.—all these indicate a partial gastrectomy.

Is the ulcer curable by a gastro-enterostomy? If the answer is in the affirmative, the screen will show the associated gastric physiological conditions—the gastric tone, the exact gastric emptying time, and so forth—all knowledge which is essential for the proper physiological performance of a gastro-enterostomy.

Certainly, all this is a study in the X-ray shadows of disease, but a surgeon well educated pathologically, and with this education enriched by his operative experience in 'living pathology', will

visualize to the last detail the whole operative problem. And what is more important, he will consciously or subconsciously reflect and plan, so that when he does operate it will be with preconceived notions, and a successful operation will usually be the result.

In *chronic duodenal ulcer*, the question will arise whether a patient in whom a diagnosis of indefinite duodenal ulcer has been made should be operated on. A patient may have a painful dyspepsia of the duodenal ulcer type, a 'deep tender spot' over his duodenum, a deformity of his duodenal bulb, yet he may not have a duodenal ulcer. The only X-ray sign which is pathognomonic of duodenal ulcer is the demonstration of the niche. Consequently, from the surgeon's point of view, where a case displays all the symptoms of duodenal ulcer, has a 'deep tender spot', but has no demonstrable niche, unless the patient is suffering from alarming attacks of hæmatemesis he had better be left to the care of the physician. A duodenal ulcer which requires surgical treatment should be clearly demonstrable by X rays.

A deeply penetrating duodenal ulcer on the posterior wall nearly always requires operation.

The Operability of Gastric Carcinoma.—There is another aspect of a surgical problem which the surgeon should inquire into at the X-ray examination, and that is the question of the operability of a carcinoma of the stomach.

In front of the screen is the place where it is often possible to say quite definitely that a patient suffering from gastric carcinoma should not be operated on. Many cases are unnecessarily operated upon when a more careful X-ray examination by the surgeon, in consultation with the radiologist and the physician, would disallow operation, and thus the patient would be saved suffering and might not lose the few months of life remaining to him.

In invasive carcinoma, even if only a small amount of stomach is involved, the case is often inoperable, for the edge of this type of carcinoma extends far beyond what appears to be the edge on the screen. Furthermore, such a type of carcinoma spreads rapidly in the peritoneum in the immediate vicinity of the growth. A wide involvement by this flat, fibromatous type of carcinoma is certainly inoperable.

On the other hand, a growth with a marked filling defect, without much contraction of the adjoining gastric wall—the papillomatous type of growth—no matter where it is or how big it is, is often operable. For example, *Fig. 152* (p. 235) shows a very local form of growth, without a great deal of X-ray evidence of invasive

infiltration round its base. Such a case is an operable type of carcinoma.

Fig. 203 is a radiograph of a case in which a large palpable tumour could be felt, and from a clinical point of view the case was regarded as inoperable. The radiograph, however, shows a rather local filling defect, without much evidence of an invasive phenomenon. The case was quite easily operable.

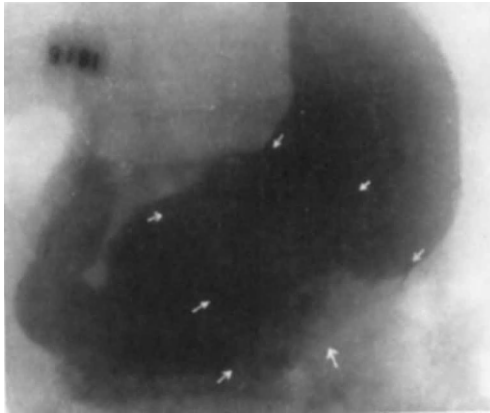


Fig. 203.—Large filling defect in the middle of the stomach, caused by a large fungating type of carcinoma. The tumour was mostly of the papillomatous type and only mildly invasive. It was operable. (By courtesy of the Melbourne Radiological Clinic.)

Fig. 154 (p. 236) shows a very large filling defect in the stomach, again without much evidence of invasion. More than fifteen years ago I performed a partial gastrectomy on this man, and he is still alive.

Between the extremes—a papillomatous carcinoma without much invasive infiltration, and the invasive type without any tendency to tumour formation—there are all grades and types. Each case, therefore, as seen on the screen, should be judged on its merits. It is surprising to see, when an effort is made by a surgeon to judge the operability of gastric carcinoma in front of the X-ray screen, how many cases it is possible to say are quite inoperable. On the other hand, examination on the screen will often encourage the surgeon to operate on a gastric carcinoma that clinically appears unpropitious in its operative outlook.

CHAPTER XXXI

CONSULTATION ON A CASE OF HÆMATEMESIS
AND MELÆNA

A CASE of hæmatemesis and melæna may be a problem for either the surgeon or the physician. It is not until the cause of the bleeding is clear that the question of its management—whether surgical or medical—is solved, consequently, a consultation is almost a necessary preliminary. Further, there is another important reason for surgical consultation in the initial stages of a bleeding, because if an operation should be necessary—and it often is—it should be carried out in the first forty-eight hours. Thus the surgeon ought most frequently to be confronted with a case of hæmatemesis in consultation, and it will be discussed from that aspect.

Pre-consultation Treatment.—If the hæmorrhage is a severe one, obvious by a progressive increase of the pulse-rate, pallor, low hæmoglobin value, and deterioration of the general condition of the patient, immediate treatment should be instituted while waiting for consultation. Morphia should be administered, a blood transfusion given, and followed by a continuous-drip blood transfusion.

THE PROBLEMS CONFRONTING THE SURGEON

To the surgeon, three problems will be presented :—

1. Is it a case of bleeding which will require an emergency operation—a bleeding from the erosion of a fairly large artery in the base of a chronic ulcer ?
2. Is it a case of a surgical lesion in which surgical interference is not required immediately, but in which operation may be necessary when the patient has recovered from the effects of the bleeding ; and is the immediate consultative function of the surgeon to make a diagnosis and to give his advice and help in regard to stopping the bleeding, counteracting the effects of the loss of blood, and preparing the patient for a future operation ?
3. Is it a case in which the surgeon is called in because there is a doubt whether the bleeding is due to a medical or a surgical lesion ?

1. Does the Patient Require an Emergency Operation?—If a severe bleeding is coming from an erosion in a chronic ulcer an urgent operation may be *imperative*. In this respect there are four questions.

The first question is: Has the patient a chronic ulcer? A previous history of typical gastric- or duodenal-ulcer painful dyspepsia will be evidence of the presence of chronic ulcer. At the same time, it should be remembered that chronic ulcer of the posterior duodenal or gastric wall and some grades of chronic ulcer may give little evidence of a previous painful dyspepsia. A history that the patient has had an X-ray examination may enable definite evidence of a chronic ulcer to be obtained.

The second question is: Is the bleeding coming from an arterial erosion in the ulcer? It may be accepted that the more chronic the ulcer is, the more likely the bleeding is to be coming from an artery: extensive fibrous ramparts are avascular and any bleeding is mostly from an erosion. Therefore, a long history, especially if its later stages show little periodicity and loss of the pain-free interval after food, and evidence of much fibrosis such as pyloric, duodenal, or gastric stenosis (from previous X-ray examination), suggests that the bleeding is arterial. Further, bleeding that is profuse and progressive and continues into the second day is likely to arise from an erosion. If, too, in such circumstances the patient has had two or three previous severe hæmorrhages, this fact must be regarded as further evidence of serious arterial bleeding.

The third question is: Will bleeding in these circumstances be controlled by natural processes or treatment? The answer is: if, on the second day, in spite of the continuous blood transfusion, the patient's hæmoglobin is still going down, an emergency operation is advisable—if not imperative. The surgeon must bear in mind that all bleedings from a chronic ulcer are not from an erosion. In the less chronic forms the bleeding is from inflammatory tissue or small vessels and is controllable by medical methods of treatment. The ulcer can then be more advantageously operated on when the patient has recovered from the effects of the bleeding. However, judgement to take such a risk in this respect will be perhaps guided by circumstances other than the actual bleeding. These comprise the operability of the patient apart from the ulcer condition; the danger of moving the patient to obtain suitable hospital facilities; dexterity of the operator and his experience in gastric operations, for a short skilful operation is the great essential for success in this emergency-operation treatment of bleeding chronic peptic ulcer.

The final question is: When should the emergency operation be performed? All authorities agree—Gordon-Taylor, Finsterer, and others—and it is, too, the author's conviction, that the operation should be carried out within the first forty-eight hours or not at all. In this respect it has been pointed out by G. A. Syme (personal communication) that normal repair of tissue, after the extensive operation usually necessary, will not readily take place unless the patient has a reasonable amount of his own blood; that is, reparative processes may not take place normally in patients who have repeatedly bled and been transfused, no matter how satisfactory the condition of the patient appears. The abdominal wound may break down and the sutured gastric and intestinal tissues may fail to unite.

2. If Operation is not Immediately Required, will it be Necessary when the Patient has Recovered from the Effects of the Bleeding?—

Chronic Peptic Ulcer (Bleeding not from Arterial Erosion).—As has just been pointed out, there will be some cases of bleeding from chronic ulcer in which the necessity for an emergency operation will be doubtful. But in such cases the hæmorrhage is not alarming and there will be no doubt what the surgeon should decide: he should operate when the patient has recovered from the bleeding.

Latent Chronic, Subacute, and Acute Ulcer.—The surgeon must not forget that, although a patient may have had no previous history of painful gastric- or duodenal-ulcer dyspepsia, he may still be bleeding from peptic ulcer. He may have a low-grade chronic, a subacute, or an acute gastric or duodenal ulcer, none of which may cause painful symptoms. As a rule, these ulcers occur in young people whose arteries are healthy and whose hæmostatic functions are good, and with medical treatment bleeding arising from them nearly always gets better.

There are, however, a very small proportion of cases which transfusion will not control and these may require an emergency operation (*see p. 296*).

In this group, where operation is delayed till the patient recovers, besides the bleeding from certain grades of peptic ulcer which may or may not require an operation, there are other surgical lesions which can cause bleeding but which practically never require an emergency operation. They do, however, require operation when the patient recovers.

The lesions which require such later operations are considered in the following paragraphs.

Papilloma.—This condition gives little indication of its presence. Hæmorrhage is often the first symptom. Though severe it is usually not alarming.

Carcinoma of the Stomach.—If the bleeding is from carcinoma of the stomach, the patient presents the appearance of a malignant subject. His illness will have a definite onset, and he will have a history of a mildly painful dyspepsia, in which nausea and vomiting are prominent features; and a history which is progressive in character, and typical of carcinoma. He will also give evidence of a definite onset of constitutional symptoms, such as loss of weight, appetite, etc., and of constipation which will have got progressively worse. Although his epigastrium may be rigid, it will not be tender; and other more obvious symptoms and signs of gastric carcinoma may also be present.

Splenic Anæmia.—If the bleeding is caused by splenic anæmia, the enlarged spleen can easily be felt without disturbance to the patient.

Sarcoma, Myoma, and Lipoma of the Stomach.—These conditions are rare, and generally give rise to a painless bleeding, which as a rule is not very severe. The bleeding generally comes from a shallow ulcer on the surface of the growth, an ulcer which is usually radiologically mistaken for chronic ulcer. These growths are not commonly associated with a previous history of a definitely painful dyspepsia. Thus radiologically there is evidence of chronic ulcer, but clinically there is none. They can usually be easily felt (except the lipoma). While they are rare conditions, they do occur more frequently than is generally thought, and they require surgical treatment after the patient gets better from the bleeding.

Jejunal Ulcer.—There will of course be the typical symptoms of jejunal ulcer following a gastro-enterostomy. A melæna, however, may take place from a jejunal ulcer without the patient having any of the typical symptoms of jejunal ulcer; that is, without his complaining of pain after meals and other dyspeptic manifestations.

Gastritis, Duodenitis, Jejunitis.—A hæmatemesis may arise from gastritis or duodenitis, or from a jejunitis following gastro-enterostomy. The symptoms of these conditions may be similar to those of gastric, duodenal, or jejunal ulcer, as the case may be (*see p. 100*). On the other hand, a bad hæmatemesis may arise from these gastritis-like conditions, and yet there may be only slight persistent dyspeptic symptoms.

Such conditions are not always curable by medical measures, and may ultimately require a partial gastrectomy.

In the conditions just described, where the surgeon is of opinion that operation will be necessary when the patient has recovered from his bleeding, he will give advice, not only for immediate treatment with the object of stopping further hæmorrhage, replacing the lost blood, and preventing a recurrence of the bleeding, but also in regard to various ways of preparing the patient for a future operation.

3. Is the Surgeon called in because there is Doubt whether the Bleeding is due to a Medical or a Surgical Cause?—In regard to this third question which may arise in the case of a consultation on a patient suffering from hæmatemesis or melæna, the surgeon must keep in his mind the fact that hæmatemesis or melæna is due to medical disease more often than to surgical disease. It is therefore necessary for him to be conversant with those less obvious medical conditions which cause gastric and duodenal bleeding, in order that if he does express the opinion that the bleeding does not require surgical treatment, he may check his diagnosis by identifying the cause of the bleeding.

Profound hæmatemeses which do not require surgical treatment occur under the following conditions:—

a. In very old people, probably caused by some degenerative vascular condition in the stomach.

b. In patients with high blood-pressure and with an associated congestive condition of the gastric wall; that is, in an incipient heart failure.

c. In renal insufficiency; or in the renal insufficiency which is found associated with chronic heart failure.

d. In the congestive conditions of early cardiac failure before the heart condition is recognized.

e. In mitral stenosis.

f. In leukæmic and anæmic states.

g. In cirrhosis of the liver, when profuse bleeding may occur either as a result of the toxic spoiling of the mucous membrane, or from a ruptured dilated œsophageal varix.

h. Following operation on the abdomen where there has been thrombosis of the gastric or duodenal veins.

i. Following operation for hernia where there has been a thrombosis of the veins in an incarcerated piece of omentum, and where this thrombosis has spread to veins in other parts of the abdomen and finally involved gastric or duodenal veins.

k. Following operation for hydatid in which formalin has been too lavishly used, and in which probably there has been some

thrombosis of the omental veins or the veins in the vicinity of the stomach.

1. As the result of acute cholæmia, when the clotting power of the blood is interfered with and the gastric mucous membrane is toxically spoiled.

From all the above conditions, most of which arise, as it were, 'out of a clear sky'—that is, give no previous history of dyspepsia—it is necessary to distinguish certain surgical conditions with equivocal manifestations. These conditions are: quasi-surgical lesions such as acute gastric and acute duodenal ulcer; and a definite surgical lesion—'silent' gastric carcinoma.

Acute Gastric Ulcer.—Acute gastric ulcer may be the cause of a hæmatemesis in a young person. It also is the immediate cause of the bleeding in patients who are suffering from general disease, such as anæmia, leukæmia, renal or hepatic insufficiency, or who have a focus of a portal or a systemic infection. The bleeding in all these cases will be 'silent', that is, will not be preceded by any definite painful dyspeptic pattern.

An acute ulcer usually has a cause, and if the surgeon makes a diagnosis of this condition he must also try to come to some conclusion in regard to its cause: he must look for an infective focus, —acute ulcer, we know, is often caused by infection; and he must also look for signs of general disease.

In regard to the question of surgical treatment, acute ulcer in a young person does not require a gastric operation; nevertheless, it may need one for the removal of an infective causative focus.

There is, however, one type of acute ulcer which may require surgical treatment. This is the acute ulcer which forms on the scar of a healed chronic ulcer, the acute ulcer which forms on a block of fibrous tissue uncovered and unprotected by mucous membrane, and therefore always at the mercy of the erosive activity of the peptic juice. Bleeding from such an acute ulcer tends to recur and may be serious. In this type of ulcer the bleeding is typical of an acute ulcer, in so far as it is 'silent', but it is usually found in a person who has a previous history—perhaps very remote—of an old ulcer.

Acute Duodenal Ulcer.—If a melæna is caused by an acute duodenal ulcer, it will be 'silent'—that is, unassociated with any dyspeptic pattern; and if it is caused by the acute ulcer which sometimes arises on the scar of a healed chronic ulcer, there will be some past history of a painful dyspepsia of the duodenal-ulcer type.

'*Silent*' *Gastric Carcinoma*.—It will sometimes be found most difficult to distinguish the hæmatemesis of 'silent' gastric carcinoma from these medical hæmatemeses which occur in patients who suffer from some profound constitutional disturbance, and who therefore present the appearance of one suffering from a carcinoma. X-ray examination, however, when the patient is better, will help, and may show a filling defect.

THE NATURE OF AN EMERGENCY OPERATION FOR HÆMATEMESIS

The type of operation depends upon the pathological condition presented and the condition of the patient. Bleeding from an eroded artery in a chronic gastric ulcer will require an immediate partial gastrectomy, with, in order to save time, a prepyloric closure (*see* Chapter XLVIII). This operation is perhaps the quickest, and the one which is most likely to ensure not only immediate but also ultimate success. If undertaken early in the bleeding and carried out under local anæsthesia, and combined with a transfusion, the patient bears it well and its mortality-rate is low.

Further, partial gastrectomy in these cases is a sound operation because it also removes the ulcer-bearing area—the pyloric part of the stomach—and thus it solves the problem of the multiple ulcer—a not uncommon occurrence in bleeding ulcer.

Resection of the ulcer with ligation of the bleeding vessels—the operation sometimes recommended—is more difficult to perform than a partial gastrectomy. Resections of ulcer combined with gastro-enterostomy take too long, and are more difficult than partial gastrectomy; moreover, they do not take cognizance of the multiple ulcer. Gastro-enterostomy does not stop the bleeding, and the effects of a useless operation, in addition to those that arise from the bleeding, may kill the patient. Oversewing the ulcer is unsatisfactory for it may not arrest the bleeding. Ligation of the artery is difficult on account of the inflammation surrounding the ulcer; or it is uncertain, because the wrong artery may be ligated (the common hepatic has been erroneously ligated).

My own custom is as follows :—

If I can make a diagnosis that the bleeding is coming from a chronic ulcer, and if the bleeding is a profound one, and I feel it is coming from an eroded artery, I operate as soon as possible after its onset and under the protection of a transfusion—if necessary a massive transfusion, two or three donors being used. I use local anæsthesia, or gas and oxygen administered intratracheally, or both

combined. I divide the stomach at the junction of the proximal and distal two-thirds. If the patient is fairly well, and if the bleeding comes from a gastric ulcer, I carry out a partial gastrectomy, and, for the sake of quickness, make if possible a prepyloric closure.

If, however, the ulcer should be widely adherent and difficult to resect, I perform a partial gastric exclusion, ligating vessels running to the ulcer, or compressing it with a band of rectus muscle aponeurosis.

If the bleeding is from an ulcer of the anterolateral duodenal wall, I wrap a fascial strip round the duodenum if possible, and do an extensive partial gastric exclusion, with resection.

If the bleeding is from an ulcer on the posterior duodenal wall, as it usually is, I find great difficulty in carrying out an effective surgical measure, for it is difficult to produce direct pressure on the ulcer. In this situation, too, it is most dangerous to resect, especially as the general condition of the patient will be bad. In these circumstances I usually fall back on a partial gastric exclusion with resection, and use compressing sutures either extra or intra-duodenally to occlude the artery.

Even when the hæmorrhage is acute, provided that the operation is not performed upon a subject whose strength has been sapped by hæmorrhage over a long period, and that the patient is protected by transfusion and given gas or local anæsthesia, it is surprising how well he will stand the operation.

BLEEDING AFTER GASTRO-ENTEROSTOMY

It not infrequently happens that a patient will have a gastro-enterostomy performed for the cure of a very painful dyspepsia associated with hæmorrhages and caused by a chronic duodenal ulcer. Following the gastro-enterostomy his painful dyspeptic symptoms will usually clear up, but after a year or two he may begin to suffer from more or less severe attacks of hæmatemesis and melæna, unassociated with any painful dyspepsia—just painless bleedings.

These bleedings may continue for years. In the intervals the patient may be fairly well. At operation, however, no definite jejunal ulcer may be found. Such a type of bleeding would be regarded by many surgeons as coming from what they would call a "bleeding ulcer"; that is, the original ulcer showed a tendency to bleed, and the recurrent one does so too.

In such a type of hæmatemesis and melæna, I believe that the proper method of treatment is to undo the gastro-enterostomy—an operation of not much severity. In the majority of cases the

physician may be able to prevent the original duodenal ulcer from recurring and bleeding. In such circumstances the mortality-rate of the orthodox operation, partial gastrectomy and enterectomy, is so much higher than that of undoing the gastro-enterostomy that it is safer to give the patient the benefit of the simpler operation and take advantage of modern medical treatment. Should this be unsuccessful, an extensive partial gastrectomy can be carried out a year or two later.

STOPPING THE HÆMORRHAGE AND PREPARING FOR A FUTURE OPERATION

Efforts to stop the bleeding should be made on the following principles:—

1. Complete rest of the stomach and duodenum should be attained: (*a*) by the administration of large doses of morphia—morphia paralyses the movements of the stomach rather than those of the intestine (*see* p. 781); (*b*) by giving nourishment of the type that does not produce peristalsis—albuminous fluids combined with dextrose solutions.

2. Attempts should be made to close the bleeding vessel. These should comprise the exhibition of whole transfused blood, and of clotting reagents such as clauden and similar remedies which may cause occlusion of the bleeding vessel.

3. The fluid loss should be replaced. This is best carried out by blood transfusions, which have also the effect of helping clotting to take place in a bleeding vessel. These transfusions can be supplemented by intravenous feeding in order to enable the patient to keep up his strength. Continuous glucose infusions can be extensively used; especially if they are used in conjunction with the administration of protein, which is supplied when the infusions are given in combination with blood transfusions.

4. The peptic action should be neutralized. The erosion of the artery has probably been caused by peptic influence and the aim should be to neutralize peptic activity. This neutralization can be effected by providing protein, with which the acid combines, in a form which will not cause active peristaltic movement of the stomach. The peptic juice can be diluted by the administration of fluid, that is, buffered as it is in nature (*see* p. 110). The digestive activity can also be neutralized by the administration of alkali. The lessening of the action of the gastric juice on the gastric or duodenal wall allows the vessel to close by a natural process of repair. This all means that the patient should be suitably fed and that Meulengracht's

method of dieting cases of hæmatemesis is based on sound principles and should be employed.

5. As soon as possible without detriment to the patient's well-being, the blood which fills the small and large intestine should be evacuated. If left in the bowel too long it decomposes and makes the patient sick. Paraffin and enemas at the right time help.

Preparing a Patient for a Future Operation.—Measures for the preparation of a patient for a future operation are best laid down by the physician. They comprise steps which will bring the patient's hæmoglobin and blood-volume to normal, and efforts to improve the tone of his peripheral vascular system as well as his cardiac muscle.

CHAPTER XXXII

GASTROSCOPY WITH THE FLEXIBLE GASTROSCOPE

By JOHN HORAN

St. Vincent's Hospital, Melbourne

GASTROSCOPY has become a practical method of investigation since the development of the Wolf-Schindler flexible gastroscope, and in

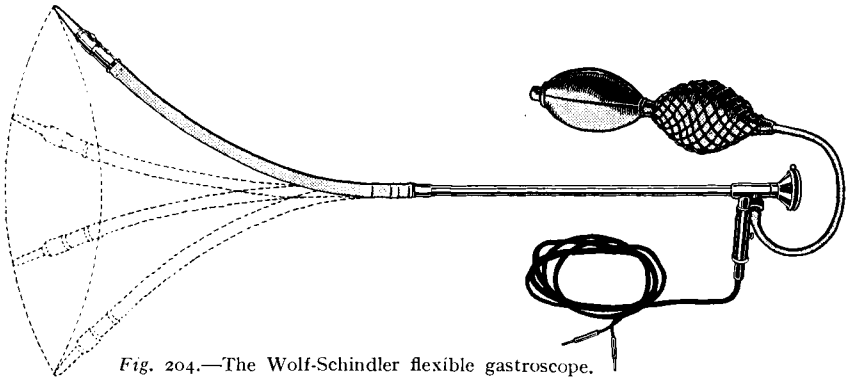


Fig. 204.—The Wolf-Schindler flexible gastroscope.

many clinics this procedure has been combined with radiological examination as a routine in the diagnosis of gastric disorders.




Fig. 205.—The ends of the Wolf-Schindler gastroscope. A, Upper end showing the ocular with button to indicate position of objective, the electric contact, and air channel. B, Lower end showing the objective, electric bulb, and rubber 'finger-tip' guide; note the perforations in the outer rubber sheath of the instrument for the admission of air into the stomach.

The Wolf-Schindler flexible gastroscope is illustrated in *Figs. 204 and 205*; its lower part can be bent, and contains a system of lenses which enables one to see a clear and well defined image, provided the angle of curvature does not exceed 34° .

With this instrument a gastroscopic examination may be made in the consulting room or in the out-patient department of a hospital with little discomfort to the ambulatory subject. The only indication for his hospitalization is the presence of pyloric obstruction with retention of gastric contents, in which case the patient is admitted to hospital twenty-four hours before the examination for repeated gastric lavage, in order to wash out the food residue and mucus which otherwise would obscure the field.

Several days before the proposed inspection, the patient should be given a 'barium swallow' and his chest screened; this is necessary to exclude the presence of any lesion which might hinder the safe passage of the gastroscope into the stomach, for the instrument is equipped with a 90° optic, and must necessarily be passed blindly through the œsophagus. Such conditions as aneurysm of the arch of the aorta, intrathoracic tumour, cirrhosis of the liver with possible œsophageal varices, severe grades of kyphoscoliosis, stricture of the œsophagus, and obstruction at the cardia are contra-indications to gastroscopy. Obstruction at the cardia is the one most frequently encountered; but if the stomach tube used for emptying the stomach passes the cardia without resistance, then the gastroscope may be introduced with safety.

TECHNIQUE OF GASTROSCOPY

The examination is made preferably in the forenoon, the patient having fasted overnight so that the gastric mucosa may be inspected under standard conditions. Firstly, he is given a subcutaneous injection of 0.43 mg. ($\frac{1}{150}$ gr.) of atropine sulphate together with 0.01 g. ($\frac{1}{8}$ gr.) of codeine phosphate into the right arm or right leg—because he must lie on his left side during the examination. Without atropine the flow of saliva may be troublesome, and it has been found that the above dose of atropine in no way affects the motility of the stomach. The codeine phosphate is used to depress the laryngeal reflexes. It is important that the patient should not be drowsy, as his co-operation is essential; for this reason an injection of morphia is not desirable. In order to obtain his confidence, the various steps in the procedure are explained to him in detail, and the positions to be adopted by him during the examination are first demonstrated by the gastroscopist.

Thirty minutes later, surface anæsthesia is commenced, and for this the patient is seated on a chair which is slightly higher than that occupied by the gastroscopist. This ensures that the patient's head is well flexed while the pharynx and hypopharynx are rendered

analgesic. The posterior third of the tongue, the pillars of the fauces, and the posterior pharyngeal wall are painted with a 2 per cent solution of decicain, and, if the patient is edentulous, the brush is swept over the gums. Five minutes later, Schindler's special tube for anæsthetization of the pharynx and hypopharynx is introduced into the patient's mouth. This tube (*Fig. 206*) consists of a piece of firm rubber tubing attached to a metal adaptor, which is fitted with a transverse bar. The distal end of the tube is closed, but spaced at regular intervals around its circumference are many pinpoint perforations. The tube is swallowed by the patient until the transverse bar rests against the lips, and in this position the tip of the tube lies in the œsophagus, having passed the pharyngo-œsophageal sphincter (*Fig. 207*). A Record syringe is attached to the adaptor, and 5 c.c. of decicain solution, to which 5 drops of 1-1000 adrenaline hydrochloride have been added, are injected briskly through the tube and sprayed over the wall of the pharynx and hypopharynx. The tube is then withdrawn, and five minutes later the procedure is repeated. After this second injection, the patient may give a slight cough if some of the solution has entered the trachea.

In fifteen minutes surface analgesia is effective, and the next stage of the procedure is reached when the stomach is emptied by gravity. For this purpose the patient kneels on the table designed by Schindler as shown in *Fig. 208*, and a stomach tube is passed. Then the patient lowers his head to allow the residual gastric contents to flow into a container. Useful information can be obtained from the quantity and character of the resting juice; for example, hypersecretion may be found in certain organic lesions of the stomach. (Some gastroscopists prefer to empty the stomach by suction, but this method may cause hæmorrhage and congestion of the mucosa, and hence is inadvisable.)

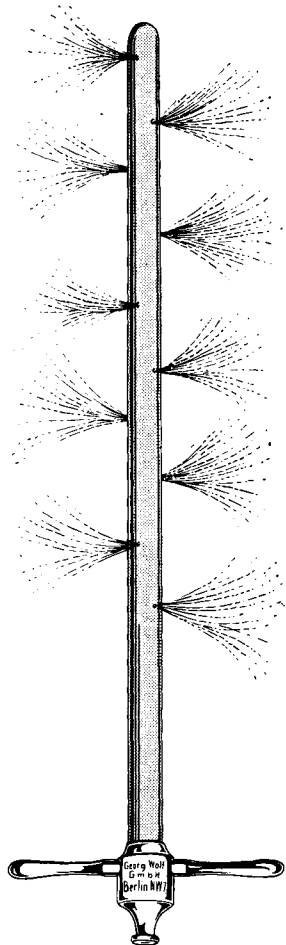


Fig. 206.—Schindler tube for anæsthetization of pharynx and hypopharynx.

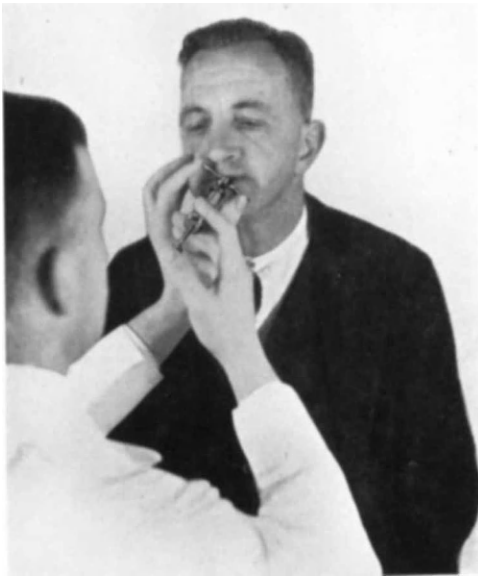

Fig. 207.—Schindler tube in position.

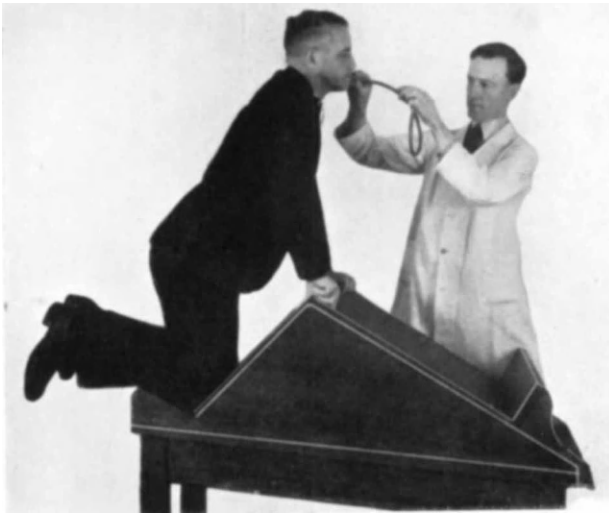

Fig. 208.—Position during the passing of the stomach tube.

The patient then lies on his left side on an examination table, with the left elbow pressed firmly into the side, the left leg flexed, and the right extended. The back is straight and the right arm hangs loosely over the side of the table. The tip of the shoulder is brought level with the top of the table, and the head projects over the end with the chin in its normal position in relation to the body. An assistant, seated in a chair as illustrated in *Fig. 209*, supports the

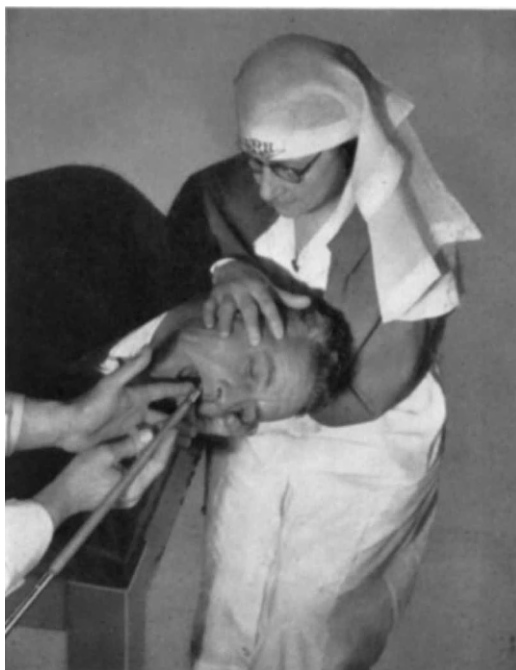

Fig. 209.—Introduction of the gastroscope. Note the position of the patient's head and the left index finger of the introducer.

weight of the patient's head with the left hand, the middle finger of which retracts the angle of the mouth to allow any saliva to run out during the examination. The right hand of the assistant rests lightly on the maxilla.

To reduce any anxiety on the part of the patient, some gastroscopists cover the eyes before the introduction of the instrument; an alternative and better method is to darken the room so that he may not see the eyepiece as it approaches the mouth. He is then instructed to remain quite still during the examination, and not to attempt to speak or try to swallow his saliva. The ocular end of

the instrument is placed on the right hand of a second assistant who stands behind the gastroscopist. It is not gripped, but rests on the palm. The gastroscope is introduced with the patient's head well flexed, as shown in *Fig. 209*. The flexible part of the gastroscope is held like a pen in the right hand of the person who is inserting the instrument, and its end is guided into the widely opened mouth by the tip of the left index finger, which is placed near the objective.

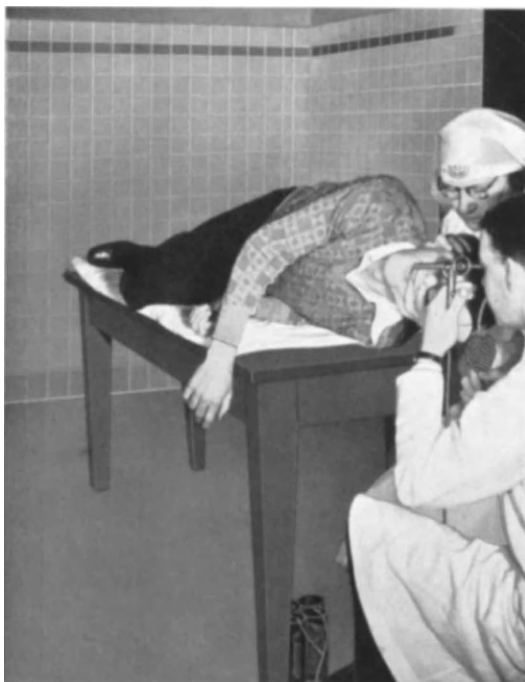

Fig. 210.—Position of the gastroscope during the examination. The rigid segment of the instrument emerges from the right side of the mouth.

The patient's upper lip is protected by the left thumb, and care is taken to see that it is not nipped between the teeth and the instrument. The tip is passed along the roof of the mouth and pushed up against the posterior pharyngeal wall, and in this position the rubber 'finger tip' guide lies along the posterior wall of the pharynx in the midline, and is well above the opening of the glottis. The index finger is depressed to cover the opening of the glottis and the left sinus pyramidalis, and the tip of the instrument slides into the hypopharynx. Some delay may be experienced at the pharyngo-œsophageal sphincter; but this is readily overcome by asking the patient to swallow.

Once the œsophagus is reached, the left index finger is removed from the mouth and the right hand slid along the shaft, which is held between the fingers and thumb. Avoiding pressure whenever resistance is encountered the tip is now passed quickly through the œsophagus to the lower pole of the stomach, the assistant extending and lowering the head a little to bring the upper rigid part of the gastroscope out of the right angle of the mouth, as shown in *Fig. 210*. With the gastroscope in this position there is no pressure on the larynx, and the patient does not experience any pain or discomfort. In this method of introduction, which is advocated by Schindler, one commences with the head flexed and takes advantage of the

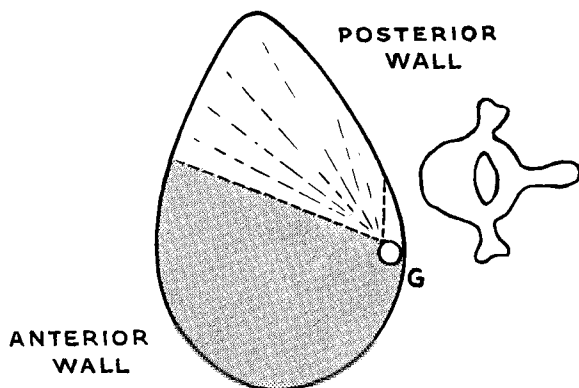


Fig. 211.—Diagram showing a transverse section of the stomach with the instrument at depth of introduction I. Note the gastroscope lying on the posterior wall. G, Gastroscope.

flexibility of the instrument in passing it through the pharynx into the œsophagus. Some gastroscopists prefer to introduce it with the head extended, but in this case the cervical spine is arched forward, and the end of the instrument is more likely to deviate from the midline into either sinus pyriformis.

After passing the cardia, the instrument's tip slides along the posterior wall and reaches the greater curvature at the lower pole of the stomach. This is known as depth of introduction I. A study of *Fig. 211*, which is a transverse section at this level, shows the instrument lying on the posterior wall of the stomach to the left of the spine. By virtue of its long depth of focus the pylorus and intervening parts of the stomach wall are visible in detail and with clear definition. Until recently that strip of the posterior wall of the stomach on which the gastroscope rests could not be examined; but just above the window of the objective H. Rodgers and H. Taylor

have fitted a rubber balloon which can be inflated after the gastro-scope has been passed; in this way the objective is lifted off the posterior wall of the stomach, which enables it to be examined. This attachment is sometimes of great help in defining the stoma of a posterior gastro-enterostomy, but even with its use difficulty is experienced in demonstrating those lesions of the posterior wall of the stomach immediately below the cardia.

After the instrument has been passed a small quantity of air is introduced, and, since the angle of vision is 85° , a large part of the stomach wall is brought into the visual field. At depth of introduction I (*Fig. 212*), with the button on the ocular at the 10 o'clock

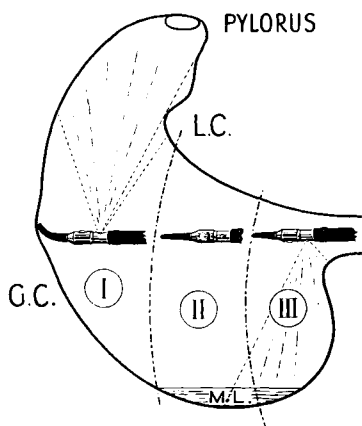


Fig. 212.—Diagram showing depths of introduction I, II, and III. L.C., Lesser curvature; G.C., Greater curvature; M.L., Mucous lake.

position, the musculus sphincter antri is seen in the lower part of the field; above this the greater curvature of the pyloric antrum can be seen leading up to the pylorus, with the anterior and posterior walls of the pyloric antrum to the left and right parts of the field. Above the pylorus is the crescentic angulus, which is an expression of the incisura angularis when viewed from within the stomach. That part of the lesser curvature of the antrum immediately behind the angulus is hidden from view (cf. *Fig. 213*), but in many cases it may be closely inspected during the passage of a suitable peristaltic wave which draws

the mucosa into the field. The button on the ocular is now rotated to 11 o'clock and then to 12 o'clock, to bring a part of the posterior wall of the stomach into view. From this position the objective is rotated slowly back in an anti-clockwise direction to the 5 o'clock position, and the stomach wall carefully examined. After this the course of the lesser curvature is followed to depth of introduction II (*Fig. 212*), and the objective is again rotated. Attention is paid to the amount of mucus, the number and character of the mucosal folds, the nature and colour of the mucosa, the presence of visible blood-vessels, congestion, or areas of hæmorrhage, and to the light reflex—an interruption of which may reveal on closer inspection a patch of exudate or a small superficial erosion. Next the instrument is withdrawn to depth of introduction III, where the fundus of the stomach may be examined. At this level there appears

a collection of gastric juice, which gathers at the most dependent part of the greater curvature and is known as the mucous lake. The examination lasts from two to five minutes, and then the gastroscope is gently removed as the assistant flexes the head.

The patient is kept under observation for about an hour until the effects of the surface anæsthesia wear off, after which he may go home or return to his work, so little does this method of investigation cause distress.

GASTROSCOPIC APPEARANCES

The Normal Stomach.—The mucosa is orange-red in colour, smooth, and glistening. On the anterior wall are numerous intersecting mucosal folds, which become thinner and wider apart and then flattened out as the stomach is gradually distended with air. In the fundus and on the posterior wall the folds are thick, heavy, and tortuous. On both surfaces their course is roughly parallel to the long axis of the stomach. The pyloric antrum is devoid of folds, and the lesser curvature is usually quite smooth throughout its course, or at the most may show a few shallow longitudinal grooves. It is now generally agreed that in many cases, even with the finest compression technique, the mucosal folds demonstrated radiologically do not agree with those seen through the gastroscope. Schindler has described the musculus sphincter antri (*Fig. 213*) which is seen when a small quantity of air is first introduced into the stomach, and which rapidly disappears on further inflation. This structure, which has a twisted rope-like appearance, commences at the end of the parabolic curve of the angulus and runs across the anterior wall and the greater curvature of the stomach in this region. It separates the body of the stomach from the pyloric antrum. A curious feature disclosed by gastroscopic examination is that peristalsis is confined to the pyloric antrum. This peristaltic movement always commences distal to the musculus sphincter antri, and sweeps over the smooth mucosal surface of the antrum towards the pylorus, which appears to approach the objective, contracts to a rosette-like figure, and then reopens as it recedes to its original position to await the next wave.

Gastritis.—The diagnosis of chronic gastritis is the most important function of the gastroscope. Schindler's classification of gastritis is based on the gastroscopic appearance of certain pathological changes in the gastric mucosa which he has correlated with the clinical course of the condition. He has subdivided chronic gastritis into four groups: (1) Chronic superficial gastritis; (2) Chronic atrophic gastritis; (3) Chronic hypertrophic gastritis; (4) "Gastritis

following operation on the stomach". A brief description follows of these types as observed through the gastroscope.

1. *Chronic Superficial Gastritis*.—Most prominent in chronic superficial gastritis are the ill-defined areas of intense hyperæmia scattered throughout the gastric mucosa. These hyperæmic areas vary greatly in size and are irregular in shape. They are readily seen on the crests of the mucosal folds, which have lost their normal silk-like lustre and are swollen and spongy in character as the result of œdema. In the valleys between the folds a tenacious exudate gathers and covers portion of the stomach wall. This adherent

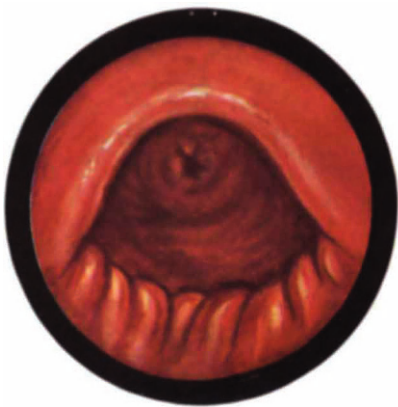

Fig. 213.—The normal pyloric antrum, showing the inusculus sphincter antri and the contracted pylorus below and beyond the crescentic angulus.

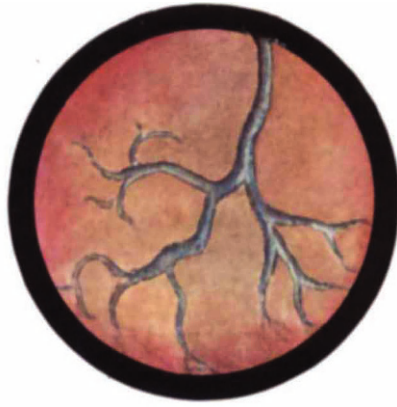

Fig. 214.—Atrophic gastritis.

exudate is airless, yellowish, milky white, or hyaline in appearance, and if observed closely may be seen to alter slowly in shape with the movement of the stomach. This type of gastritis may be observed in the mucosa immediately surrounding an ulcer, or at the edge of a carcinoma. Peristomal gastritis following some cases of gastroenterostomy is frequently of this variety. Apart from such factors chronic superficial gastritis is not often seen, though occasionally it may occur as a diffuse lesion affecting the superficial layers of the entire gastric mucosa, and in these cases the changes appear to be most marked in the body of the stomach. Generally this condition heals, but it is thought that it may progress to chronic atrophic gastritis.

2. *Chronic Atrophic Gastritis*.—In atrophic gastritis the rugæ are thin and narrow, and disappear quickly as the stomach is distended

with air. Though occasionally diffuse, the lesion usually occurs as a partial atrophy in isolated patches of the gastric mucosa. In marked contrast to the glistening orange-red colour of the normal mucosa, the affected areas are translucent and of a greenish-grey hue (*Fig. 214*). They are quite smooth, and are depressed below the level of the surrounding mucous membrane. Through this altered surface the network of vessels in the submucosa can be seen in detail, whereas in the normal stomach they are not discernible. Mucosal hæmorrhages are not uncommon, and their appearance is usually associated with some epigastric discomfort. In the mucous



Fig. 215.—Hypertrophic gastritis.

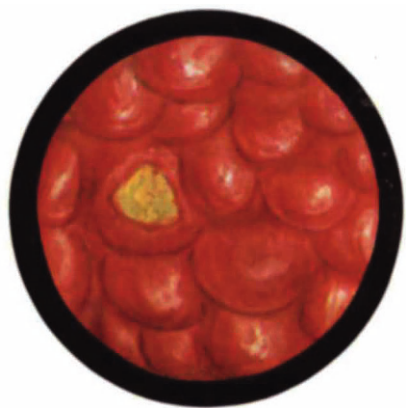

Fig. 216.—An erosion in hypertrophic gastritis on the posterior wall close to the objective.

membrane adjacent to a carcinoma of the stomach this type of chronic gastritis is frequently seen. Patients with pernicious anæmia usually show an incomplete atrophy, and in some of these cases so rapid is the regeneration of the atrophic mucosa after the institution of liver therapy that it is difficult to believe that this atrophy is the result of a chronic inflammatory process.

3. *Chronic Hypertrophic Gastritis.*—The condition is readily recognized through the gastroscope by the rigid character of the mucosal folds, which persist even when the stomach is distended with air. These folds, which are thick and tortuous, are traversed by fine creases, and as a result have a beaded appearance. On the lesser curvature and in the furrows between the folds there appear small nodules which are arranged like cobblestones (*Fig. 215*). These nodules are usually of the same size, but some may proliferate and become so large that they are mistaken for true polypi. On the

extremities of these nodes and on the crests of the segmented rugæ small erosions may occur. These erosions (*Fig. 216*) are usually multiple, and have yellowish bases with hyperæmic margins. Generally they heal quite rapidly, but they may be the site of gastric hæmorrhage. Their development is usually associated with an increase in the patient's symptoms.

4. *Gastritis Following Operation on the Stomach.*—Distortion of the stomach is frequently encountered following gastro-enterostomy, and this may lead to difficulty in orientation. However, by using small quantities of air for distension of the stomach, the stoma is

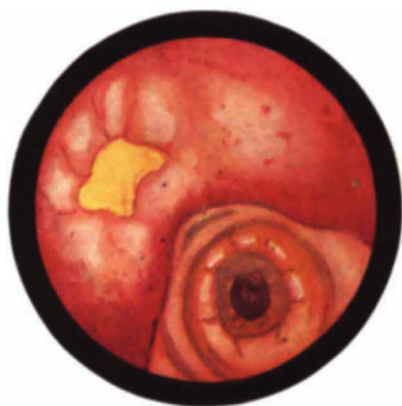


Fig. 217.—Chronic gastric ulcer on lesser curvature.

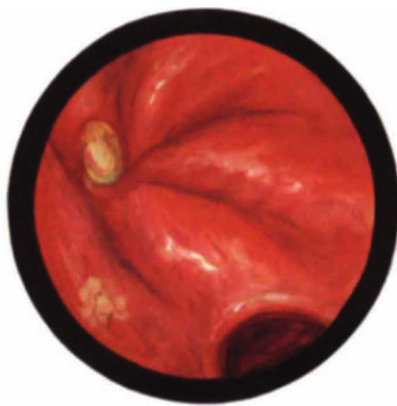

Fig. 218.—Healing gastric ulcer.

usually seen quite clearly. Sometimes the artificial stoma remains patulous during the inspection, and part of one or both loops of the jejunal coil can be examined. In these cases, lesions of the jejunum may be observed if they are situated directly opposite the opening. The view of a gastro-enterostomy is unfortunately often limited to the gastric aspect, as the stoma remains firmly contracted throughout the examination. The appearance of symptoms after a gastro-enterostomy has been performed may be due to an anastomotic ulcer; but gastroscopy has revealed gastritis as a frequent cause for complaint after operation. This post-operative gastritis, when present, is usually most intense in the mucosa immediately surrounding the stoma, and as a rule is of the chronic superficial variety described above.

Gastric Ulcer.—The appearance of the benign ulcer seen through the gastroscope is characteristic (*Fig. 217*). The transition

from the ulcer to the surrounding mucous membrane is abrupt, and the contrast between the yellow or whitish colour of the base of the ulcer and the orange-red of the gastric mucosa is striking. The ulcer is usually circular or oval in shape, but its margin may be crenated by small tags of mucous membrane projecting in from the periphery towards its centre. The mucosa immediately surrounding the site of ulceration is generally swollen and œdematous and appears inflamed, but occasionally the ulcer is set in a normal mucous membrane, the usual surrounding gastritis being noticeably absent.

During the healing process of an ulcer, elevated folds in the mucosa such as those shown in *Fig. 218* may be seen converging towards it. The course of an ulcer may be followed with the gastroscope, and one may observe its response to treatment. Complete healing of an ulcer can be determined with certainty by gastroscopic examination, and it happens quite frequently that the instrument will demonstrate an ulcer although the X-ray signs of gastric ulcer have disappeared.

The benign ulcer occurs most frequently on the lesser curvature, or on its anterior border just proximal to the angulus, and at this level it may be observed quite clearly through the gastroscope. On the other hand, an ulcer placed on the lesser curvature of the pyloric antrum immediately beyond the angulus cannot be seen, for in these cases the lesser curvature of the antrum appears to be drawn upwards and is hidden from view; yet such an ulcer may produce a deformity known as 'tenting' of the angulus, and this indirect sign may lead the examiner to suspect its presence. Difficulty may also arise in defining a posterior wall ulcer just below the cardia, for in this situation the lesion is placed too near the objective of the instrument, which rests on the posterior wall throughout the examination. It is therefore evident that in the diagnosis of chronic gastric ulcer the gastroscope has certain limitations.

Gastric Carcinoma.—The gastroscopic picture of the several forms of carcinoma of the stomach is most impressive. The conspicuous gross feature of a gastric carcinoma with ulceration, when examined through the gastroscope, is the brilliant colour effect which is produced by the active circulation of blood within the tumour and which is absent from the resected specimen. The necrotic material in the base of the malignant ulcer, for example, has not the smooth yellow or whitish appearance of the benign ulcer, but is uneven and of a brownish, violet, deep blue, or black colour. This difference in colour is of importance in differentiating the simple from the malignant gastric ulcer.

In *Fig. 219* is shown a fungating carcinoma filling the cavity of the pyloric antrum. When the examination of this case was made, large quantities of bile-stained duodenal contents were seen regurgitating through the central ulcerating mass into the body of the stomach.

The diffusely infiltrating carcinoma of the stomach presents a characteristic picture. In these cases the stomach can tolerate only small quantities of air, and only with difficulty is the wall of the stomach lifted off the objective of the instrument. The even contour

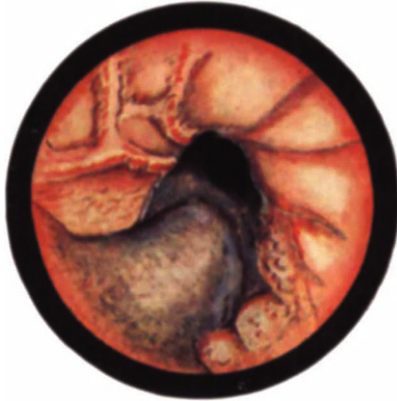

Fig. 219.—Ulcerating carcinoma of the pyloric antrum.

of the normal mucosa is replaced by an irregular surface from which dark red or pale nodules project into the lumen of the stomach, and in which areas of hæmorrhage and ulceration may be observed. There is no peristalsis, and if the anterior abdominal wall is palpated gently during the examination the infiltration of the stomach wall is evident, as it is no longer pliable.

To summarize, I should like to make it clear that gastroscopy makes no arrogant claims. It has its limitations. Its function is to co-operate with radiology in attempting to solve the problems of gastric disorder. These two objective methods, used in conjunction, replace, in large measure, such an unconvincing diagnostic procedure as the routine test-meal.

Section I

SURGICAL PROCEDURES

CHAPTER XXXIII

THE EQUIPMENT OF AN ABDOMINAL SURGEON

KNOWLEDGE AND JUDGEMENT

THE surgeon who would specialize in modern abdominal surgery must be specially equipped with :—

1. A Knowledge of Function.—The abdominal surgeon of to-day must have not only a knowledge of structure, but a profound knowledge of function, and of the disturbances and variations of function within physiological limits : he must be a good physiologist. He must be able to determine pre-operatively whether a function has become pathological, for the structure when seen at operation may give no indications of disturbance of function.

2. A Knowledge of the Structure of Abdominal Tissues.—The abdominal surgeon must have a knowledge of the intimate structure of the tissues of the abdominal cavity, of their various planes, of their tensile strength, of their delicacy of structure. Such knowledge cannot be obtained by dissection of subjects preserved in formalin, but must be acquired from dissection of the unhardened tissues of the cadaver in the post-mortem room.

3. A Knowledge of Comparative and Developmental Anatomy.—An understanding of comparative anatomy and of developmental anatomy is essential, because abdominal operations are often rendered difficult by disease having occurred in or as a result of an imperfectly developed organ, and such knowledge is a great help in the unravelling of these operative problems.

4. Diagnostic Judgement.—The abdominal surgeon must above all be a master in the art of diagnosis ; for not only must he be clinically sure of his grounds for operating—the day of the exploratory operation is past—but also he must be sure of his operative diagnosis when he reviews the contents of the abdominal cavity at the time of the operation.

Abdominal diagnosis is very difficult. To be able definitely to diagnose an abdominal lesion requires shrewd clinical judgement.

Even to be able to make the broader diagnosis that the patient has a lesion which requires an abdominal operation is difficult. And to be able to say definitely that an abdominal operation has been erroneously advised, that it is unnecessary, is still more difficult, and furthermore requires some force of character. But such diagnostic knowledge and the fearless use of it marks a great advance, for the blot on the escutcheon of abdominal surgery has been the morbidity caused by the wholesale performance of unnecessary abdominal operations, the responsibility for which lay with minds immature in surgical judgement.

Therefore this very necessary diagnostic acumen in relation to abdominal affections must be developed by constant and acute observation at abdominal operations: from constant study of the 'pathology of the living'. Thus the abdominal surgeon should be the high priest in abdominal diagnosis, and capable of assuming the responsibility for the diagnosis of an abdominal affection, and for saying whether an operation is required or not.

DEXTERITY

No matter how much knowledge the surgeon may possess, if he is unskilful he will not be able to make his knowledge available for the cure of his patients. Indeed, the lack of dexterity may account for almost as much post-operative morbidity and post-operative mortality as does lack of knowledge; for the delicate endothelial tissues and rich sympathetic nerve-supply of the abdominal cavity are often profoundly injured by the unskilful operator, who, unconscious of the damage he does, causes much shock and subsequent morbidity. The properly equipped abdominal surgeon must therefore systematically train his fingers to be gentle and dexterous.

The Art of Using the Knife.—In the abdominal cavity the knife is used in the same manner as an artist uses a paint-brush—with a gentle stroking action. It must be razor-like in sharpness, and the blade must be small. Small wafer-blades with long handles should be used in the deep parts of the abdominal cavity.

The Art of Dissecting with the Scissors.—For the dissection of some of the soft and filmy tissues of the abdominal cavity, the art of scissors-dissection should be cultivated. A specially constructed abdominal dissecting scissors should be used. Its weight and balance should never vary. It should be very sharp and have spade-like ends, with curved points which will cut to the very tip. Such a scissors in various sizes is illustrated in *Figs. 251, 252* (pp. 350, 351).

It is by dissection with such a razor-sharp, light scissors that the delicate abdominal tissues can be neatly cut or unravelled, the thin-walled abdominal vessels exposed, injury of the fine sympathetic nerves avoided, the tissue planes accurately followed, and firmly adherent loops of intestine safely separated. Expertness in the use of the abdominal dissecting scissors makes for accuracy and speed in dissections in the abdominal cavity. (*See also* p. 351.)

The Art of Using the Needle.—The art of suturing rapidly, subconsciously, and accurately can easily be acquired by practice on dead tissues (pigs' intestines), or even on cloth material. The abdominal surgeon should be able to sew like a woman. Because there are certain positions in the abdomen in which the right hand cannot be used effectively, he should be able to sew with the left as well as with the right hand.

It is best to cultivate the use of the straight needle, for greater speed and accuracy can be attained with this than with the curved needle. *Fig. 268* (p. 358) shows the method of holding and using the straight needle. This technique is very important for the rapid suturing often necessary in operations on the upper part of the abdomen.

The Art of Using the Curved Needle.—There are certain situations in the abdominal cavity where it is not possible to use a straight needle. The art of using the curved needle must therefore also be assiduously practised. The curved needle for routine use must be small, of the curve of a shilling, and should always be of the same size; it should, too, be used only with a needle-holder, and be flattened near its eye, so that it cannot rotate and penetrate a viscus when being manipulated by the holder. The abdominal surgeon should train himself to suture accurately and quickly in the deep cavities. He can do this by using a long needle-holder, and either a strong tissue-forceps or a second short needle-holder in the left hand to grasp and draw the needle through as the first needle-holder is unclamped (*see Figs. 271, 272, p. 361*). The movement is one of pronation and supination—not a push.

Thus it is possible for the suturing in the deep parts of the abdominal cavity to be carried out without inserting the hand into the cavity, and therefore without producing injury of the endothelial surfaces or causing neurogenic shock by traumatism of sympathetic elements.

The Art of Tying Knots.—Rapid ligation of vessels means prompt and perfect hæmostasis, an *essential requirement* in abdominal surgery. The art of knotting is therefore no mean part of the equipment of an abdominal surgeon. The technique is described on p. 363.

THE SURGEON'S TEAM

In abdominal as in neurological surgery, the modern surgeon can only efficiently realize his ideals in the art and science of surgery by team-work. In both diagnosis and operation, team methods are needed.

In the case of diagnosis, the modern abdominal surgeon, taking full advantage of the great advances in diagnosis, working in conjunction with his team, will avoid unnecessary exploratory operations.

In the case of operation, he will acquire from his team an intimate knowledge of the general condition of the patient, of his cardiac function, of the function of the organ in question, of the localization of the lesion, of the tendency to certain complications, and many other data in the particular patient—all of which will enable him to plan and so to organize the operation that he can shorten its time, and perform an operation exactly appropriate to the particular phase of the disease and the general condition of the particular patient: in short, perform a much more effective operation than if he operated without an intimate pre-operative knowledge of the particular circumstances.

The Operating Team.—An operating team should consist of an experienced surgical assistant, a trained instrument sister, the requisite nursing staff, and an anæsthetist who has been trained in the use of all modern anæsthetics, including local and spinal, and who has learnt to *co-operate with the surgeon*—a most necessary attribute in an anæsthetist. The anæsthetist is perhaps the most important member of the team. With the aid of his knowledge and art difficult abdominal operations can be successfully carried out which without his assistance would be unsuccessful. Such an anæsthetist is only to be obtained by choosing him for his aptitude, and training him in the surgical clinic. The services of a cautious, wise, and skilful anæsthetist form one of the greatest requirements of the abdominal surgeon.

Hospitals.—As a rule public hospitals are adequately equipped for the carrying out of surgical operations. In these hospitals proper post-operative nursing attention is also available. For operations on private patients, hospitals on the same scale are not available to the surgeon. In order to give his private patients the full advantage of his knowledge and skill he must organize an efficient operative and nursing service. To do this he will have either to build his own hospital and staff it, or arrange with some efficient private hospital to give him the necessary service. In his routine abdominal surgery the surgeon cannot do his best work if he is continually shifting from hospital to hospital.

INSTRUMENTARIUM

For the skilful performance of abdominal operations, the abdominal surgeon requires to be specially well equipped with instruments. Instruments specially designed for operating in the cavities of the abdomen; knives and scissors specially sharp and designed for dissecting the soft delicate tissues of the abdomen; shoulderless needles to avoid tearing when suturing hollow organs; aspiration devices to remove blood, air, and the contents of hollow organs; specially designed retractors for the purpose of adequately exposing the various parts of the abdominal cavity; lighting devices for illuminating certain parts of the abdominal cavity; operation tables which will move in every desired direction: all these make difficult abdominal operations easy, and therefore lessen the shock and the danger of such operations. The great value of a proper kit of instruments in abdominal surgery cannot be over-emphasized; particularly the value of instruments specially designed for certain difficult phases of the surgery of this region. Some are described in detail in the chapters that follow.

THE OPERATING THEATRE

In operations on the abdominal cavity, adequate lighting of the operating field is the most essential requirement, but unfortunately it is the very one which is often lacking, especially in operating-rooms in private hospitals.

The Operating-room Light.—

Direction of Light.—The light must come from immediately above the abdominal wound, so that it will shine into and illuminate its depths adequately.

Nature of Light.—The best kind of light is a combination of daylight coming through a top light and artificial shadowless light, so that either one or other can be used at will. The main incidence of the daylight coming from the top light window should fall on the abdominal wound and coincide with the main incidence of the shadowless light. Both can be used together, the daylight lessening the glaze on shiny peritoneal tissue. But the artificial light is often better used by itself, concentrated on the wound, with a weak lighting environment, which will give contrast lighting. One advantage of artificial lighting is that it is possible to move the artificial light laterally so as to illuminate the lateral parts of the abdominal cavity. A disadvantage is that it makes the tissues glisten, when it is difficult to see their intimate structure. *Fig. 220* shows




Fig. 220.—Simple and inexpensive method of contrast lighting. (Härtel.)

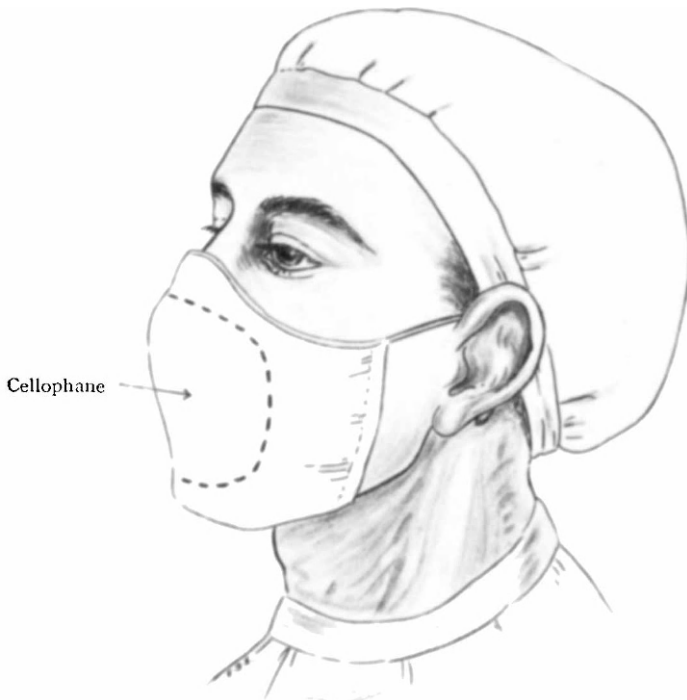

Fig. 221.—Specially constructed mask, between the folds of which a piece of cellophane can be slipped.

a method of contrast lighting, using daylight, which is inexpensive and suitable for country operating theatres (Härtel¹).

Anæsthetic Apparatus.—A theatre should contain an apparatus for giving vaporized ether, gas, etc., and provision for every form of anæsthetic.

Ventilation.—The theatre should have provision either for forced ventilation or for aspirating air. The air in the modern theatre is often ether-laden from the administration of ether by the open method or by a motor-driven air blast, and this has a bad effect on the operating surgeon, who is physically exerting himself to a high degree. Proper ventilation will enable him to work much more efficiently and with a clearer mind, and consequently with greater advantage to the patient. The custom hitherto followed of operating in the moisture-laden air of an overheated theatre is injurious to the patient, who being anæsthetized cannot regulate his temperature efficiently.

Operation Mask.—The operation mask should cover the nose and mouth, and should have an airway upwards, so as to avoid fogging the surgeon's spectacles. The part which covers the mouth should be impermeable. *Fig. 221* shows a specially constructed mask, between the folds of which is a piece of cellophane.

REFERENCE

- ¹ HÄRTEL, F., "Über die Verwendung von Tageslicht zur Operations-beleuchtung," *Der Chirurg*, 1935, **7**, 198.

CHAPTER XXXIV

**GENERAL PRINCIPLES UNDERLYING THE PERFORMANCE
OF OPERATIONS IN THE UPPER PART OF
THE ABDOMINAL CAVITY**

THE viscera should be operated on in the abdominal cavity where they are under normal physiological conditions. They should not be delivered for operative manipulation on to the abdominal wall,

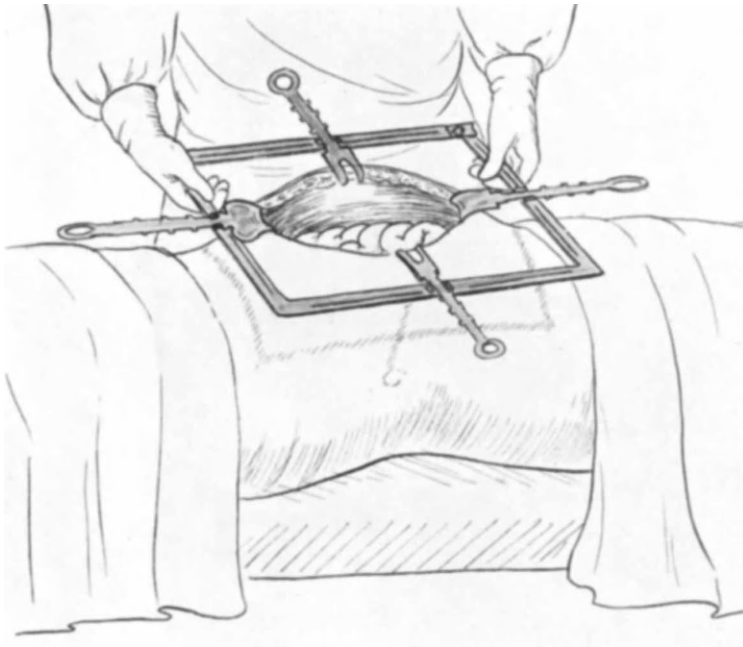


Fig. 222.—Showing intestines being operated on in the abdominal cavity with the aid of an operating frame. The diagram shows the frame being gently held up, when the intestines fall back into the abdomen.

where they become dry and transude gas, and where cooling and vascular congestion occur from the exposure and unphysiological surroundings.

A small space on each side of the wound, sufficiently big to hold a lateral wound retractor, is denuded of adhesions. Into these spaces lateral wound retractors are inserted, and firmly locked to the frame (*Fig. 238*). If possible, a small retractor is also placed in the upper angle of the wound and similarly locked. In some cases

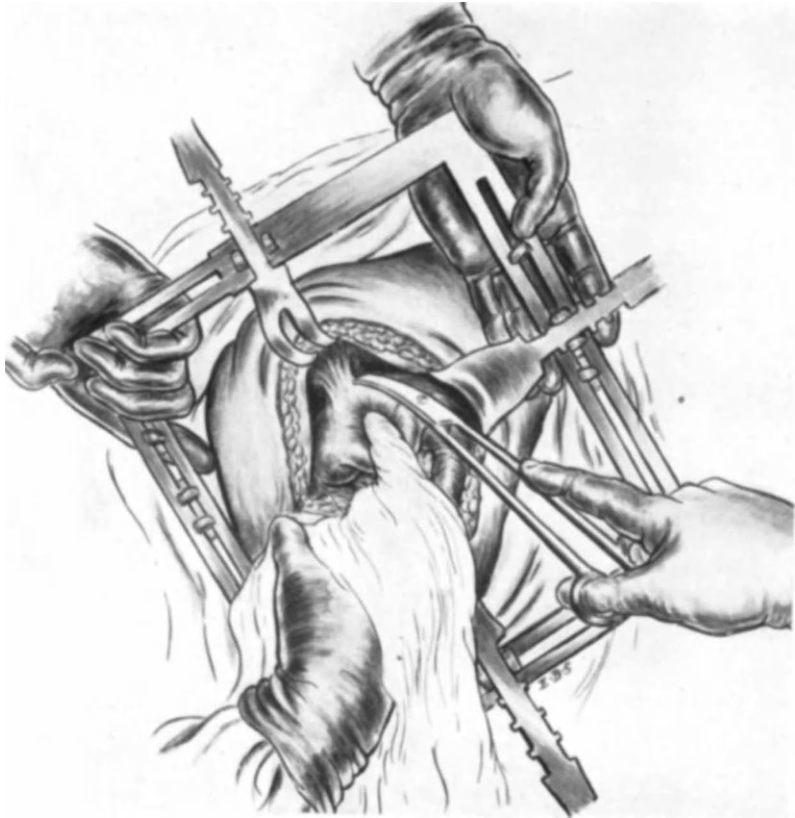

Fig. 238.—Showing the use of the operating frame for elevating the abdominal wall so that adhesions of the anterior abdominal wall far out from the wound may be cut neatly and cleanly.

it may be possible to lock all four retractors in position at this stage. The assistant now elevates the frame gently but firmly (*Fig. 238*), and as the patient breathes it will be found that, if the assistant keeps the same firm lifting pressure, the abdominal wall will slowly separate from the abdominal contents. It will be seen that the adhesions are now hanging from the anterior abdominal wall. These adhesions can then be put on the stretch, made tense, and neatly

severed along the plane of the original line of adhesion, a plane which avoids bleeding and leaves the smallest raw surface. As the abdominal wall is lifted away from the abdominal contents, and as the adhesions can then be seen far out under the wound on both sides, there is no difficulty in dissecting these adhesions with long

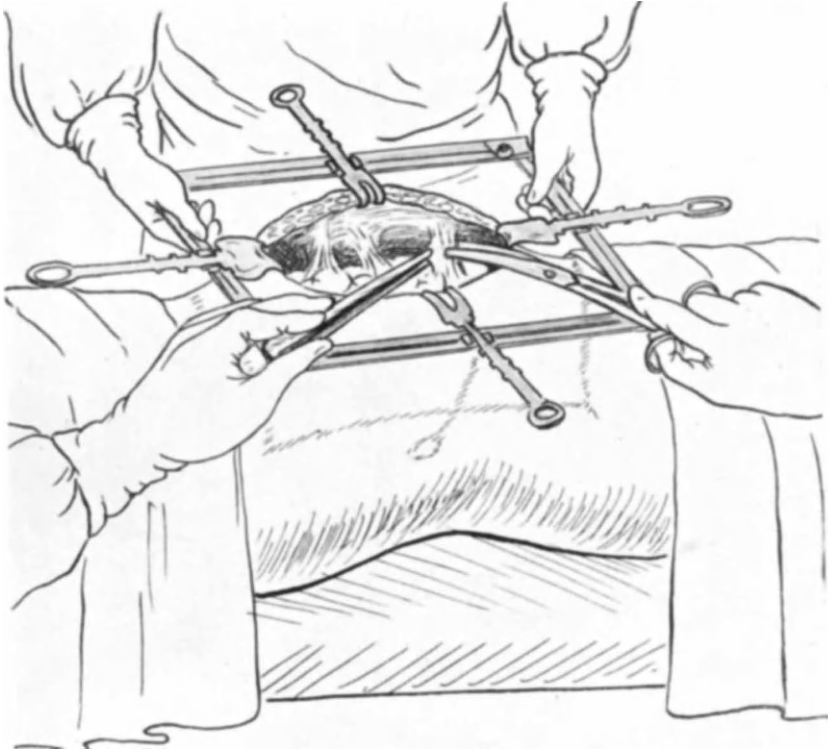


Fig. 239.—Another view of the operating frame locked into the wound and elevated by an assistant so that the anterior abdominal wall is separated from the abdominal contents, thus stretching the adhesions, which are then easily seen, put on the stretch, and divided along the original line of adhesion.

instruments, even for many inches from the edge of the abdominal wound, as shown in *Fig. 239*.

Suture of Rents in the Peritoneum of the Anterior Abdominal Wall.—While the anterior abdominal wall is being held up by the assistant by means of the frame, any rents in the peritoneum of this part of the wall made by the division of adhesions should be sutured. In order to accomplish this, a brightly silvered spoon is held opposite the rent in the peritoneum as the abdominal wall

is raised. This spoon (see *Fig. 228*, p. 328) facilitates the suturing, for it reflects light on to the peritoneal tear and protects the underlying intestines from injury by needle-pricks (*Fig. 240*).

It is most important that these rents should be accurately sutured, because adhesions of small intestines to the anterior

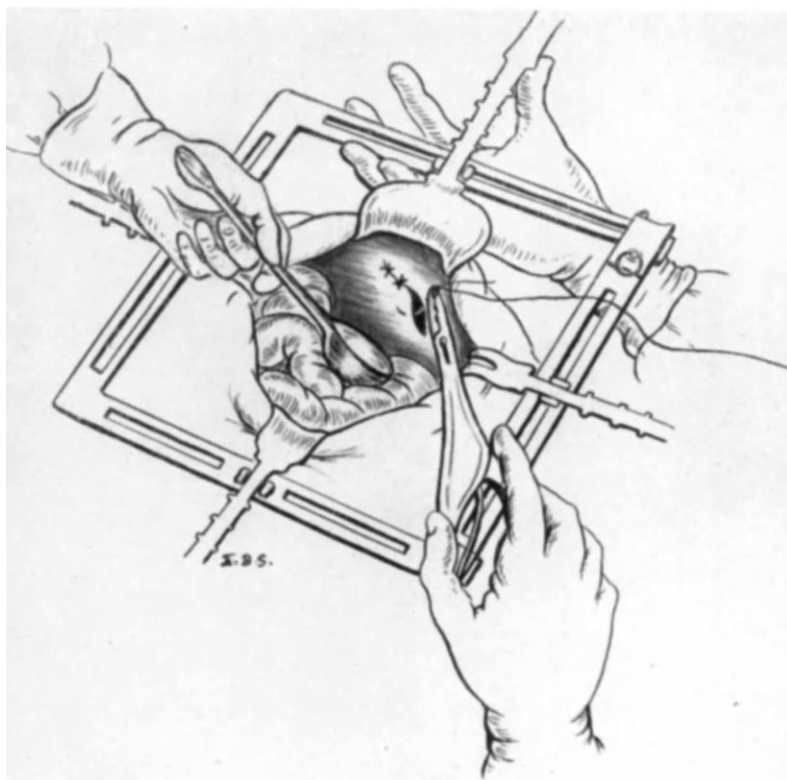


Fig. 240.—Showing the abdominal wall elevated by the use of the operating frame, the spoon being placed in position so as to reflect light on to the tear, which is being sutured with a very small round needle held in a needle-holder. On account of the awkward position and the danger of wounding the intestines, the needle should be picked up with a second needle-holder (see p. 360).

abdominal wall, the result of unsutured rents, cause much post-operative trouble. As there is a considerable amount of redundancy in the peritoneum of the anterior abdominal wall, due to variability of distension of the abdominal cavity, even surprisingly large rents can be repaired. The main difficulty in covering these raw spaces has always been a mechanical one—the difficulty of suturing in an almost inaccessible position.

Reinsertion of Wound Retractors and Covering of Wound.—

When the adhesions have been cleared away and the rents in the peritoneum sutured, the wound retractors should be removed, the wound covers placed over the wound, and the retractors again set into the frame.

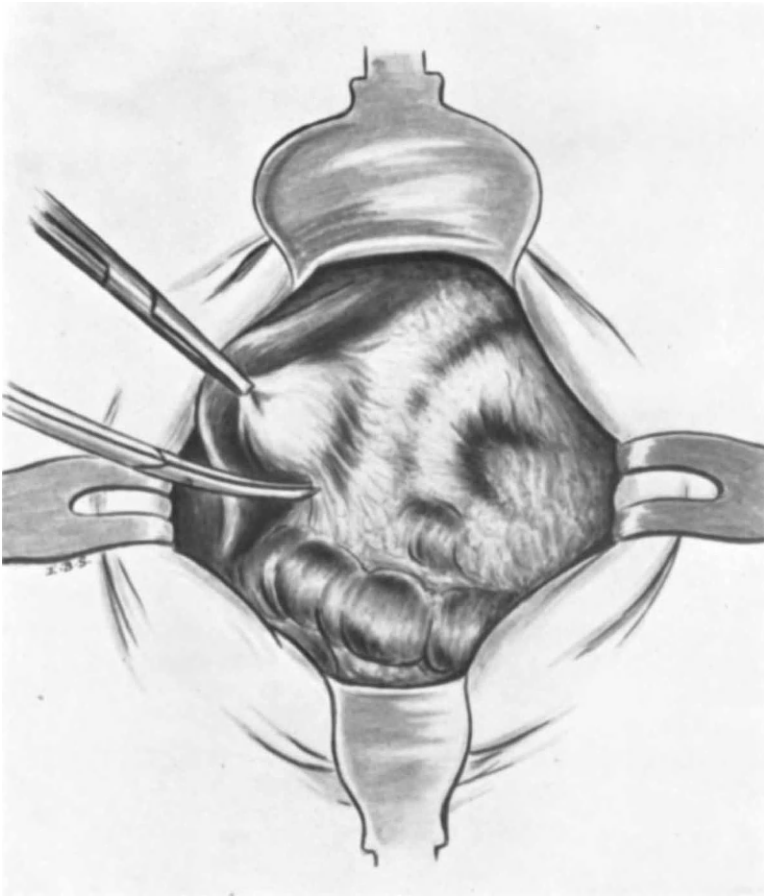


Fig. 241.—Dissecting gall-bladder free from surrounding structures with the aid of chisel-pointed dissecting scissors.

Isolation of the Field of Operation by Retraction of the Intestines.—There are three main physiological objectives in intestinal retraction: (*a*) to remove small intestines from around the organ which is to be operated on, so that they will not be injured by manipulations not intended for them; (*b*) to keep the intestines,

or any other abdominal organ which is not the subject of the operation, out of the operation area and under the abdominal wall, so that they will still be in their natural surroundings, where they will be kept warm and moist and free from unnatural conditions of gas exchange; and (c) to operate on the organ in the abdominal cavity—in its natural position, and not on the surface of the abdomen.

EXAMPLE OF THE USE OF THE OPERATING FRAME:
ISOLATION OF THE GALL-BLADDER

The best way to illustrate this principle of intestinal retraction is to take a concrete example, as for instance, an operation on the gall-bladder. In such a case the steps are as follows:—

Insertion of Wound Retractors.—The wound retractors, with the wound covers, are inserted in the manner already described (p. 330).

If the gall-bladder is adherent to the adjoining viscera, it must be dissected free with the aid of the chisel-pointed, middle-sized dissecting scissors (*Fig. 241*).

Exploration of the Abdomen.—It is at this stage, i.e., before beginning to remove the gall-bladder, that the abdominal cavity should be explored. The operation frame is elevated, thus lifting the abdominal wall from the viscera, and creating a space through which the operator can examine the contents of the abdominal cavity without handling the intestines, and through which he can remove the appendix (*see pp. 436, 437, and Fig. 311*).

Deflation of the Stomach.—Frequently the stomach is greatly distended with air and bulges into the wound, hampering the approach to the gall-bladder. The distended stomach should be deflated by means of a trocar attached to an air pump (*Fig. 242*), the small opening thus made being afterwards closed with a suture (*Fig. 243*).

Insertion of 'Mechanical Hands': Retraction of the Duodenum.—After the fundus of the gall-bladder has been freed from any adhesions which may attach it to the neighbouring organs, the gloved left hand is inserted into the abdominal cavity, and the fingers are placed on the lateral side of the second part of the duodenum where it touches the posterior abdominal wall. A veil is laid in folds over the duodenum. The frame and with it the abdominal wall is held up on its median side by an assistant in order to allow the intestines to be displaced medially. The crumpled-up veil with the duodenum and loops of small intestine is now moved slowly towards the midline and downwards to the left, so that the duodenum is made to creep forwards on the spinal column

to the left and downwards. This is accomplished by making a gentle continuous pressure which is only applied at each relaxation

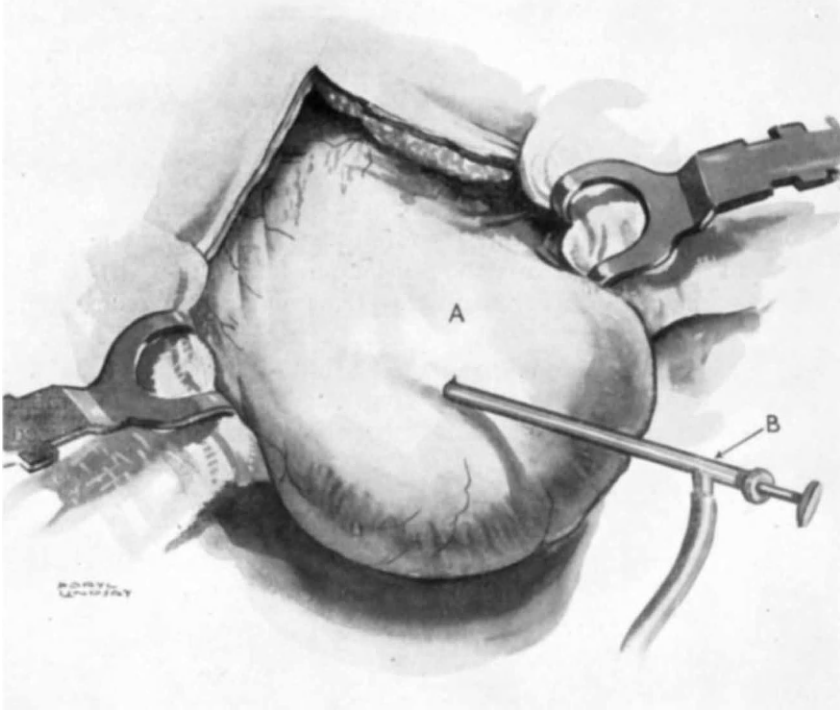


Fig. 242.—The stomach, which is nearly always full of air, is emptied in order to get a clear view of the gall-bladder. A, Stomach bulging into wound; B, Aspirating trocar inserted into stomach.




Fig. 243.—Diagrammatic representation of suture used to close the trocar opening. A, B, C, show the steps of the procedure.

period in the respiratory phase. When the duodenum and the intestines have been moved into a position well to the left under

the abdominal wall, the 'mechanical hand' (*Fig. 244, 5*) is placed in position instead of the gloved hand, and fixed to the single hook on the left at the point *B* in *Fig. 245*. The handle of the mechanical hand is now moved slowly down to the position *C* in *Fig. 245*. As the line *AC* is longer than the line *AB* the handle is thus fixed under tension at the position *C*, and jams into the opposing inclined planes of the single hook without in any way relaxing the

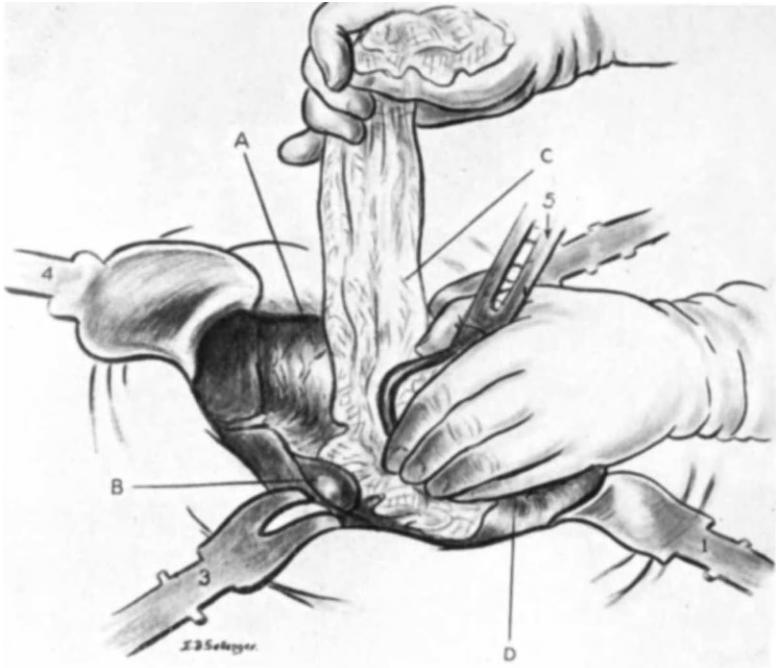


Fig. 244.—Gloved left hand with the pulps of the four fingers on the lateral edge of the second part of the duodenum, the scarf inserted, and the 'mechanical hand' (5) placed in position to draw the duodenum and intestines over to the left, out of the operation area. A, Stomach; B, Gall-bladder; C, Scarf; D, Duodenum.

tension on the 'buffer' veil. As a consequence, if the intestines have been carefully snarled in the thin single-layer veil, it is quite impossible (when the other 'hands' are in position) for them to move into the operation field, even should the patient vomit.

Retraction of the Hepatic Flexure.—The hepatic flexure, and with it any stray loops of intestine, is now pressed downwards into the abdominal cavity by means of the gloved hand, which has between it and the intestine a crumpled-up veil. As the intestines are gently incarcerated under the abdominal wall, another mechanical

hand (*Fig. 246, 6*) is locked in position in the same way as in the first case.

Retraction of the Stomach.—With the long deep ‘mechanical hand’ (*see Fig. 227, 3*), specially designed for this purpose, and a veil,

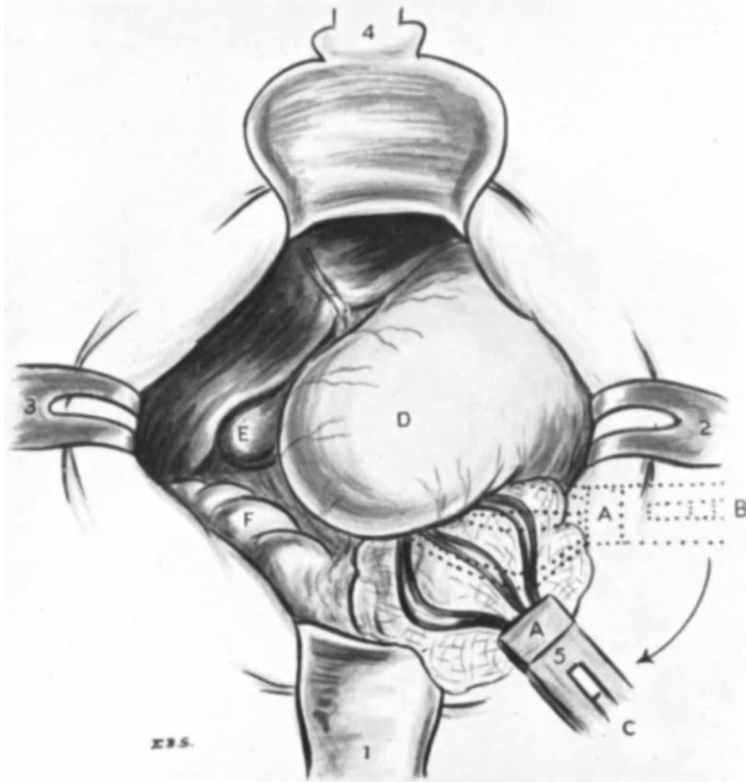


Fig. 245.—The ‘mechanical hand’ is placed in position instead of the gloved hand and fixed to the single hook on the left at the point B. The handle of the ‘mechanical hand’ is now slid down on the frame to the point C. As the distance AC is longer than AB, this manœuvre fixes the ‘mechanical hand’ firmly on the frame without losing its grip on the buffer veil. D, Prolapsing stomach; E, Gall-bladder; F, Colon.

the stomach, which often prolapses into the gall-bladder area, is moved from over the gastrohepatic omentum up towards the spleen, and the ‘hand’ is locked into position (*Fig. 247*). As already mentioned, it may have been necessary to deflate a very distended stomach.

The gall-bladder now lies quite clear of the intestines and stomach, and can be dissected free from its bed while it is actually in the

abdominal cavity, as shown in *Fig. 248*. So gently have the intestines, colon, and stomach been removed from the operation area that no endothelial surfaces are injured, and in their protected position none can be injured during the course of the operation. And no matter

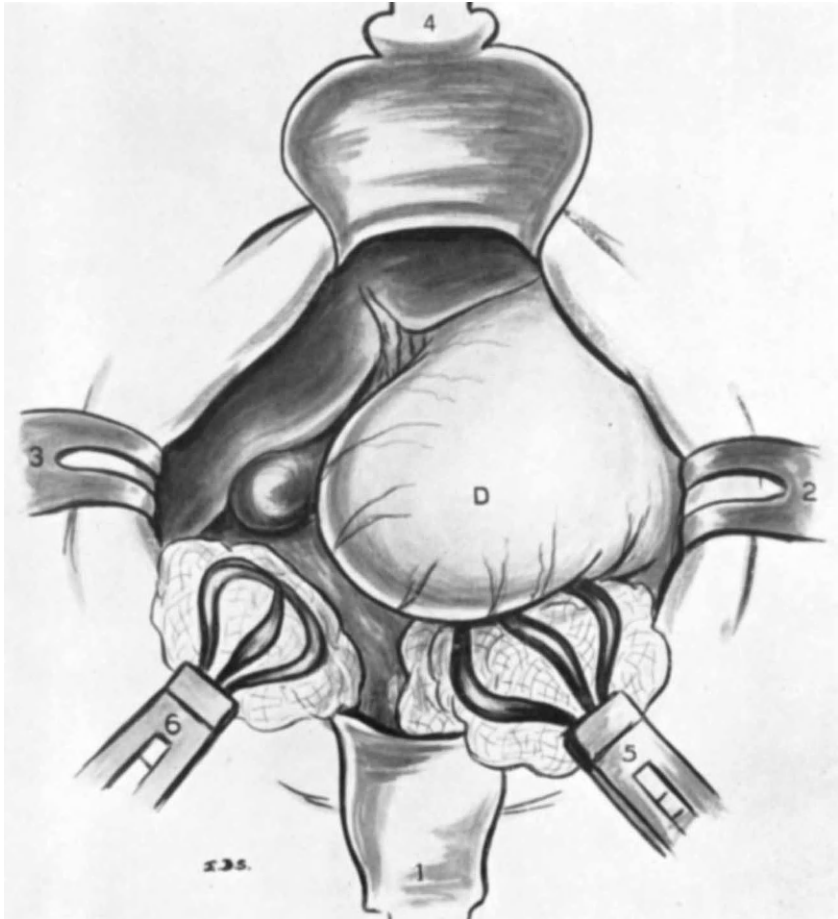


Fig. 246.—A second 'mechanical hand' (6) retracts the hepatic flexure out of the operation area, and is fixed to a hook in the frame. D, Prolapsing stomach.

how abnormally the gall-bladder is situated, it can, as exposed by this method of retraction, be removed without having to draw it on to the abdominal wall by using the liver as a tractor.

Any other organ may be isolated and operated upon on the same principle as has been here explained in relation to the gall-bladder.

The Use of the Adjustable Side of the Operating Frame.—

This is used for locking the wound retractors firmly into the abdominal wound. When thus locked the frame can be used to lift the lower edge of the thorax away from the upper surface of the liver in order to expose this area; or it can be used to lift the abdominal wall away from the abdominal viscera.

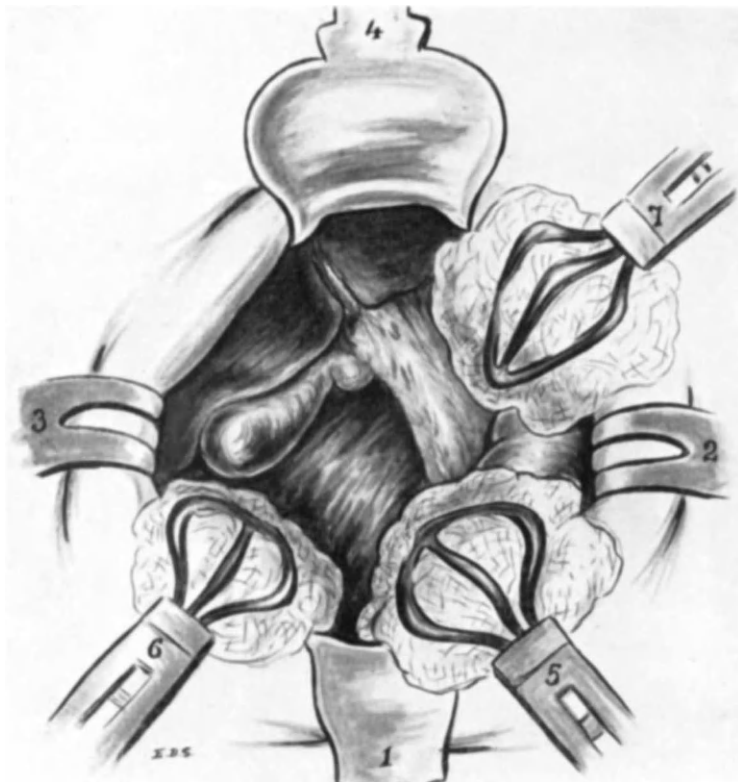


Fig. 247.—A third 'mechanical hand' (7) retracts the prolapsing stomach and moves it under the abdominal wall out of the operation area. The 'hand' is then locked to the frame.

Advantages of Operating with the Aid of the Operating Frame.

—The operating frame has been designed to enable the surgeon to observe certain important principles in abdominal operations. It allows him to see clearly what he is doing, for it exposes the operation field perfectly by spreading the abdominal wound wide open to its fullest extent. It avoids injury to the wound edges, for the light application of pressure, evenly and widely distributed, which it

permits, does not injure the edges of the wound as does constantly applied hand retraction. It greatly lessens the possibility of wound infection, because waterproof covers can be securely clamped on the wound edges. It enables the surgeon to lift the abdominal wall away from the intestines, thus creating an actual body-cavity out of a potential one, through which he can explore and palpate any

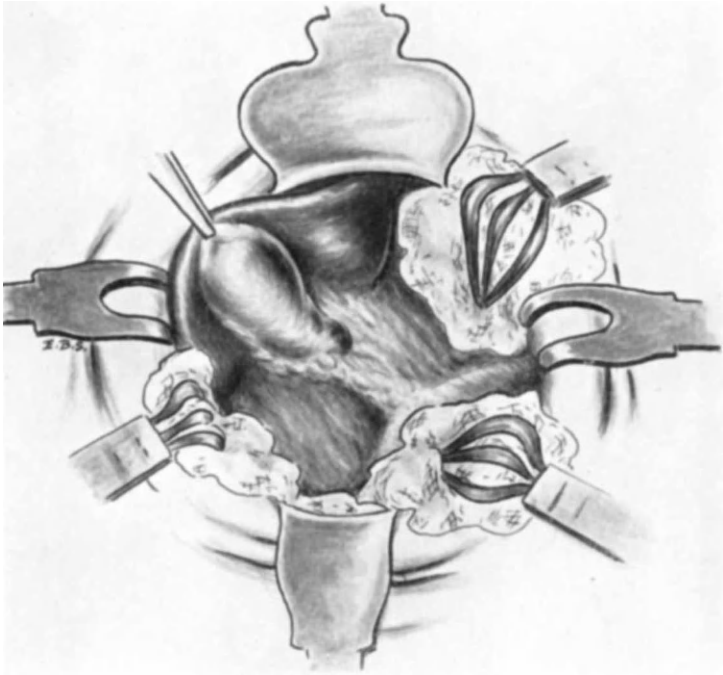


Fig. 248.—The gall-bladder exposed ready for operation.

abdominal organ without handling the shock-susceptible small intestine; and through which, by projecting into it the shadowless light of the operation room, he can inspect almost any part of the abdominal cavity.

The use of the operating frame prevents shock; for it involves a method of visceral retraction whereby the intestines can be held away from the field of operation and incarcerated in the abdominal cavity, and thereby protected from trauma, from exposure, and from loss of gas by transudation. It also enables operations in deep cavities to be performed under good vision; for it permits illumination of the cavity by the attachment

of small boilable lamps to the 'mechanical hand' blades. Moreover, it allows operations on the upper surface of the liver to be carried out from the abdominal cavity; for by means of the frame the lower part of the thorax can be lifted away from the anterior surface of the liver so as to make an approach to this area when, for example, the surgeon is operating for the

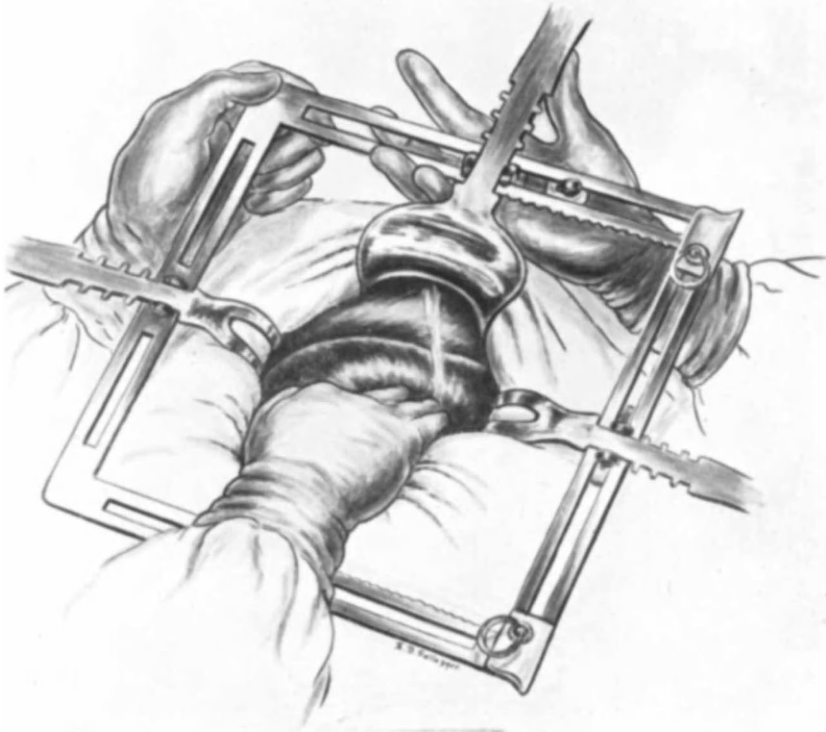


Fig. 249.—Exposure of the upper surface of the liver by using the frame to lift the thorax from the anterior surface of the liver while the latter organ is pressed downwards.

removal of a hydatid of the upper surface of the right lobe of the liver (*Fig. 249*).

Frame retraction serves another useful function, in that it enables the surgeon, when making intestinal or gastro-intestinal anastomoses, to adopt a method of 'guy-rope' retraction to the frame itself, so that intestinal segments can be kept in a fixed position, and therefore sutured neatly and very accurately and also against a constant tension (*Fig. 250*).

THE USE OF POSTURE IN ABDOMINAL OPERATIONS

In operations in the upper part of the abdomen it will be found a great advantage to place the patient in a high reverse Trendelenburg position. The intestines will then fall away from the operation field, the liver and the stomach will drop down into a more accessible

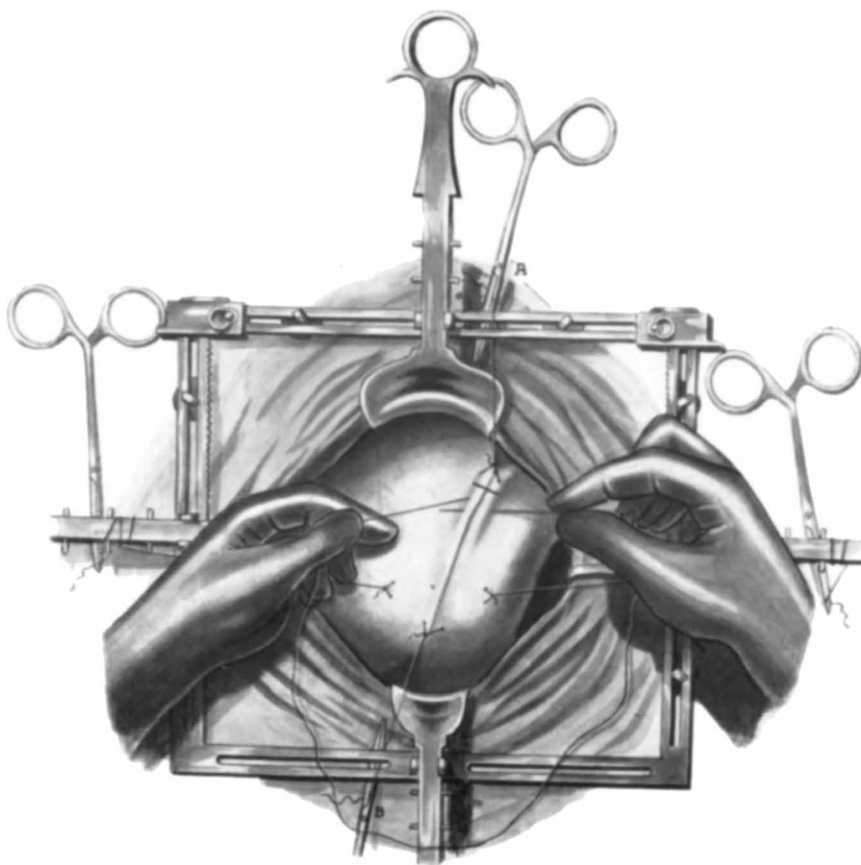


Fig. 250.—Showing how segments of stomach and intestine can be fixed to the frame by means of 'guy-rope' retraction (A and B), so that exact suturing and accurate adaptation can be obtained, and suturing carried out against constant tension.

position, and the operation field will be much better illuminated, because this position enables either the daylight from the window of the operation room or the artificial light to shine directly on the operation field. In some operations it is also a great advantage to tilt the operation table laterally (*see* p. 395, and *Fig. 296*).

CHAPTER XXXV

SURGICAL HANDICRAFT IN THE ABDOMINAL CAVITY

Scissors Dissection.—The tissues of the abdominal cavity are different from those of the rest of the body, and therefore a special surgical technique is called for. The delicate endothelial cells of the peritoneum are easily injured by even slight touch. The

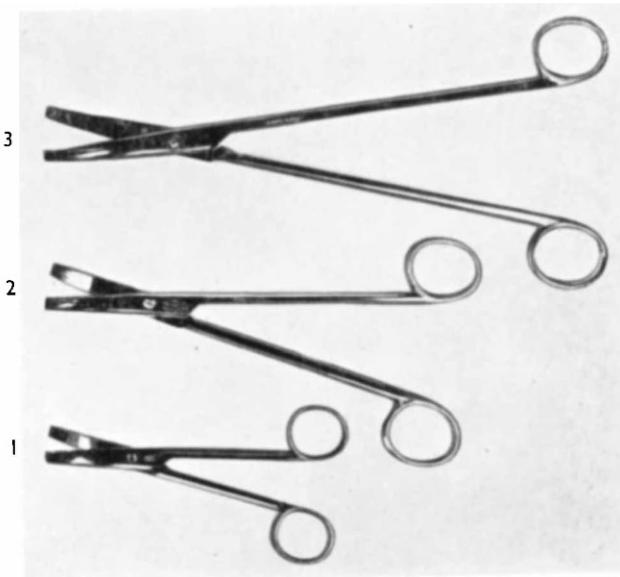


Fig. 251.—Set of abdominal dissecting scissors. 1, Small size, 5 in. long; 2, Medium size, 9 in. long; 3, Long size, 12 in. long.

abdominal tissues are soft and delicate. The abdominal blood-vessels have thin muscular walls and consequently are frail and easily injured, so that the slightest roughness may cause a sub-peritoneal hæmatoma; and the blood-clot of such a hæmatoma is culture material on which organisms can thrive. Thus even slight injuries predispose to adhesions and small hæmatomas lead to low infections.

Further, the tissue and organs in the abdominal cavity are supplied from the involuntary nervous system—nerve tissue which is composed mostly of unmedullated fibres—and comparatively slight injury of this delicate and sensitive tissue is productive of much shock.

It will thus be evident that these delicate tissues are not suitable for dissection with a knife, but require sharp, gentle, accurate, and bloodless dissection, which can best be accomplished by razor-sharp scissors of special construction. And such painstaking dissection is one of the secrets of success in abdominal surgery; for it leaves a minimum of after-effects and therefore no morbidity.

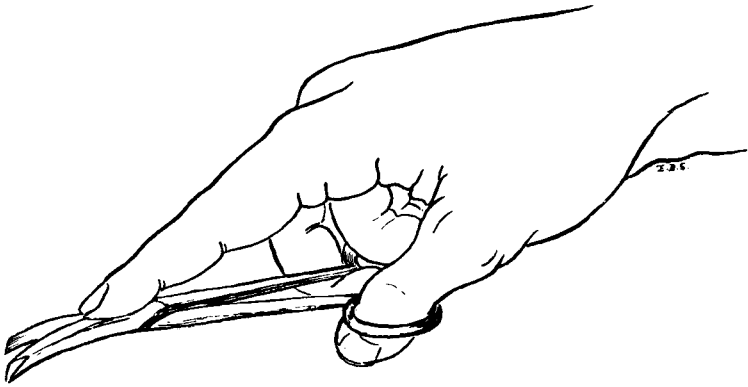


Fig. 252.—How to hold the small razor-sharp, knife-edged, spade-pointed dissecting scissors.

Abdominal Dissecting Scissors.—The scissors used for dissecting in the abdominal cavity must be light, razor-sharp, cut accurately to the tip, and have a thin chisel point for following tissue planes.

Fig. 251 shows a set of knife-edged chisel-pointed dissecting scissors which I have designed for abdominal work. These scissors are made of the finest specially hardened steel, and in three lengths: 5 in., 9 in., and 12 in. Their outside edges as well as their tips are just sharp enough to separate tissue planes, and to clean vessels without injuring them. Thus they serve as knife as well as scissors, and have also a chisel action. The ends of the blades are slightly curved, so that in their use the operator can look over the tip, and see exactly the plane of tissue that he is dividing. These scissors are kept very sharp. They are never used on hard tissues, so that they never become strained. To me they have been of great service in making rapid, neat, and bloodless abdominal dissections. After prolonged use of these scissors—always of exactly the same weight—I have been able to develop with them a sense of touch that enables

me to recognize with the tips of the scissors the slightest difference of tissue density, and therefore to identify blood-vessels and other essential structures by the feel of them. With the aid of this little instrument I have taught myself to unravel the abdominal tissues gently by this sense of touch. The method of holding the scissors is shown in *Fig. 252*.

During the whole operation the scissors can be kept in the palm of the hand, even when holding a knife. In this position they can



Fig. 253.—Photograph showing the method of separating loops of adherent small intestine. A, Surgeon's left hand covered with a single layer of soft scarf; B, His right hand using the spade-ended dissecting scissors to follow exactly the bloodless plane of the adhesion C; F, G, The two loops of intestine being dissected; E, D, Right and left hands of the assistant, covered with a scarf and making tension between the adherent loops.

be used by the surgeon to cut his own sutures—for he can cut them much more accurately and quickly than can the assistant—cut them as a continuation or a last phase of the knotting movement (*see Fig. 287*).

Method of Handling Stomach and Intestines.—As the stomach and intestines are slippery, they must be held very firmly if a rubber-gloved hand is used to secure a grip. This undue pressure injures the bowel wall, rubbing off the endothelial cells and causing adhesions, and it also disturbs the peristaltic function. *Fig. 253* shows a method of handling intestines. A veil (a thin single layer of fine

gauze) is thrown over each hand. With the aid of these veils the intestines can be held firmly but gently, and injury to the endothelial cells minimized.

The Use of the Diathermy Knife.—The diathermy cutting current which divides tissues cleanly and sharply, just as a knife does, may with advantage be used when operating on and making incisions into hollow organs such as the stomach or intestine. Fine wire loops energized by this current cut cleanly with the lightest touch. The slight electric coagulation of the edges of the wound which it makes, seals the lymphatics and thus gives the tissue some immunity against immediate infection until protective granulations arise.

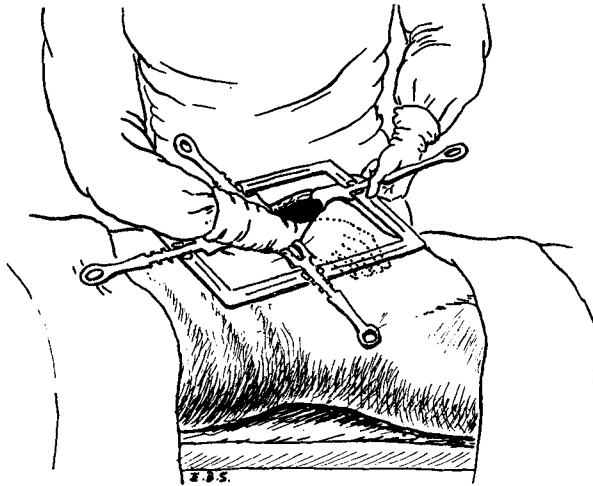


Fig. 254.—Method of making a body cavity for the purposes of exploration.

When damped down, the current coagulates tissue, and can be used for the hæmorrhage of moderate-sized vessels. This property is very useful in hæmorrhage from parenchymatous organs, such as the liver, spleen, or kidney. It is also useful in obtaining hæmorrhage in deep operation cavities where the bleeding vessels cannot be ligatured, a long Spencer Wells forceps being used to clamp the bleeding points and then touched with the coagulating current.

Method of Exploration of the Abdominal Cavity.—In order to avoid injury to intestines, the abdomen should be explored through the space between the abdominal wall and the intestines—the body cavity. Normally, of course, this cavity does not exist, but it can be created by lifting the abdominal wall away from the intestines by means of the operating frame (*Fig. 254*). Through this space

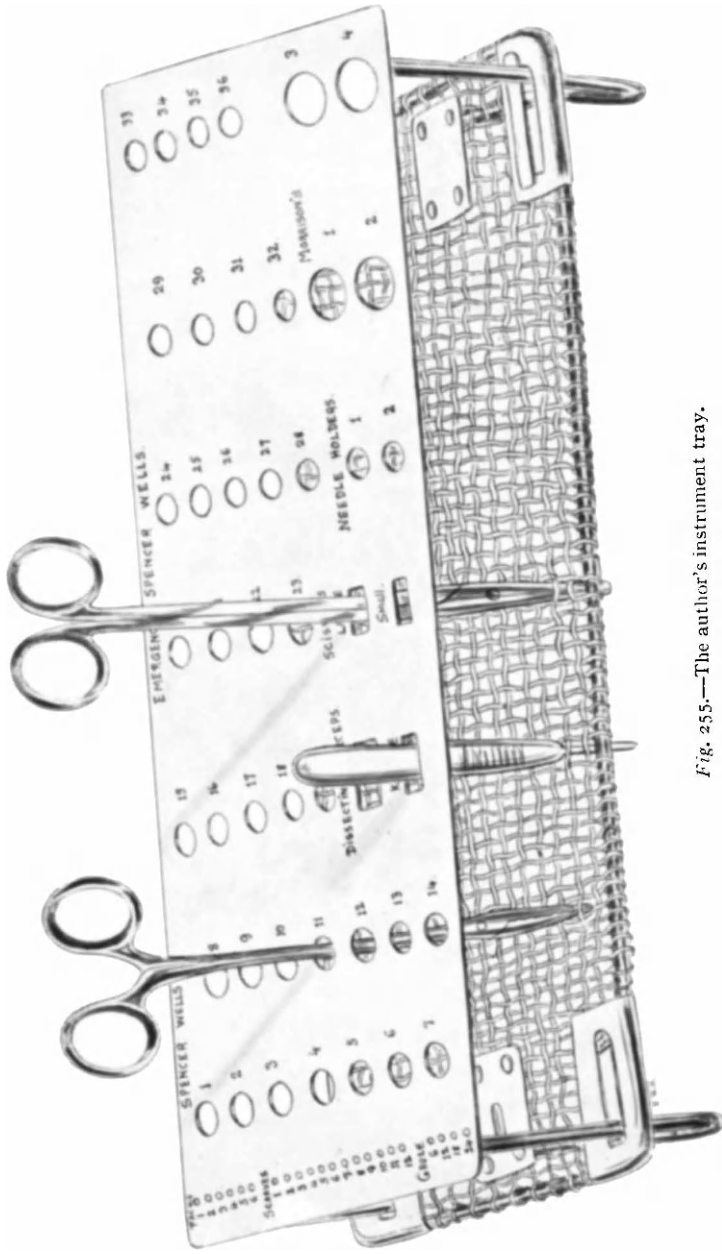


Fig. 255.—The author's instrument tray.

the whole of the abdominal cavity can be explored without the exploring hand being impeded by the intestines or omentum.

This method not only enables the surgeon to make a thorough exploration, but it also avoids a certain amount of the shock that usually results when an exploring hand is pushed indiscriminately around the abdomen through intestines.

Instrument Tray.—In order that the surgeon may be able to pick up instruments quickly, keep them all in neat array, and be able to check their number at a glance when the operation is finished, he must provide himself with some such device as an instrument tray.

The tray should be designed with the object of providing (1) a place and (2) a number for each particular instrument, and (3) a little marking-board for checking scarves and packs.

As each instrument is used, and discarded for the time being, it is washed, reesterilized, and placed in its proper hole in the instrument tray. The operator, who knows the exact position of each instrument, can then pick it up without a moment's delay. The tray thus serves (*a*) to keep the surgeon's instruments tidy; (*b*) to absolve the instrument sister from handling his instruments, and thus leave her free to attend to her sutures, scarves, and packs; and (*c*) to check automatically the number of instruments, packs, and scarves after the operation.

The use of such a tray encourages neat, quick, and exact technique. *Fig. 255* shows a tray which has been designed to attain the objects mentioned above.

Instruments.—Useful instruments for general use in operations in the abdominal cavity are shown in *Figs. 256–264*.



Fig. 256.—Lieferstrom's forceps for ligating arteries in deep cavities.




Fig. 257.—MacCormick long dissector and ligature carrier.



Fig. 258.—Barrel for silk.

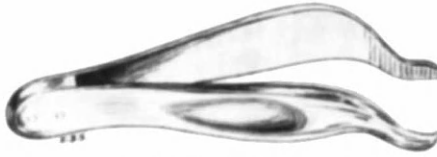

Fig. 259.—Very powerful thumb forceps for picking up needles.




Fig. 260.—Allis's forceps for grasping delicate tissues.



Fig. 261.—Wound retractor with small hook, used to lift tissues and avoid handling.

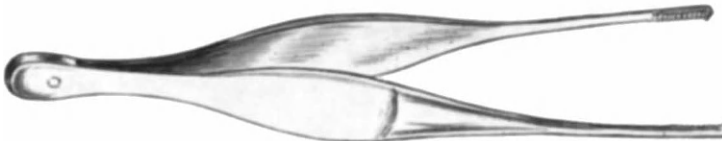


Fig. 262.—Long dissecting forceps.

Of special use in gastric resection are Deschamps' ligature needle (*Fig. 265*) and Kirschner's grooved director (*Fig. 266*), which can be used in conjunction with each other: The director is used

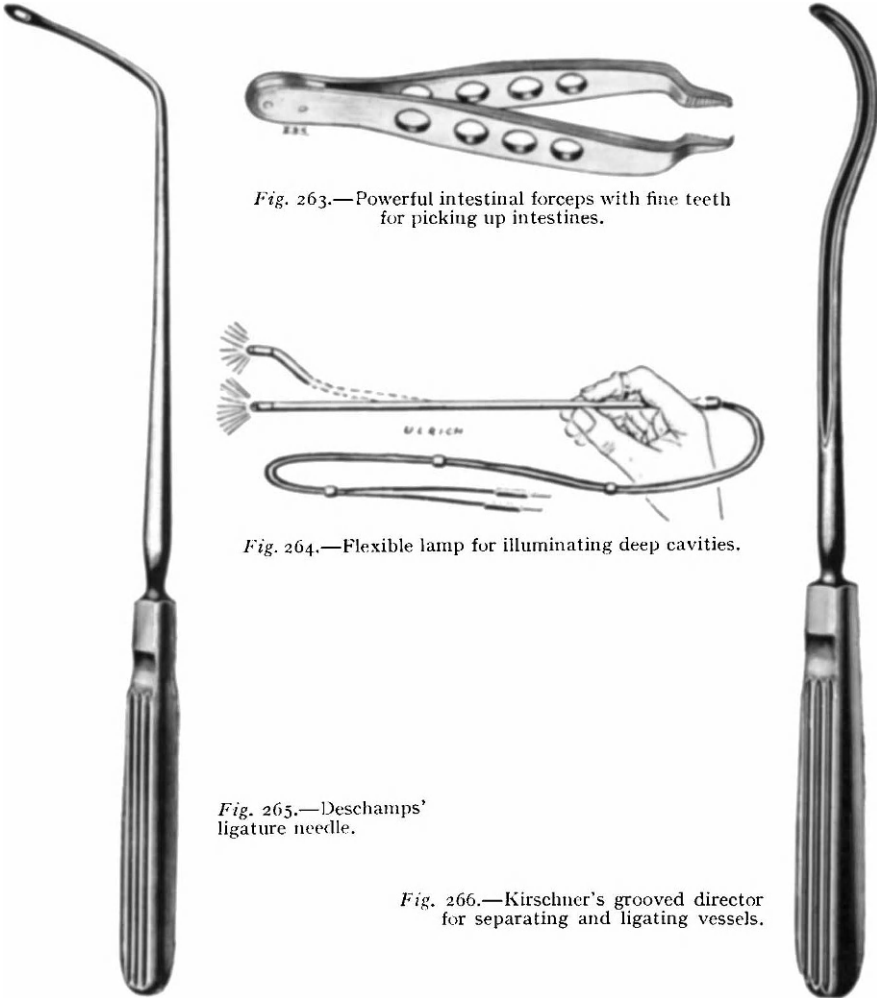


Fig. 263.—Powerful intestinal forceps with fine teeth for picking up intestines.

Fig. 264.—Flexible lamp for illuminating deep cavities.

Fig. 265.—Deschamps' ligature needle.

Fig. 266.—Kirschner's grooved director for separating and ligating vessels.

to isolate the vessel, after which the needle armed with thread is made to follow the groove in the former instrument, thus encircling the vessel.

A useful pedicle forceps is shown in *Fig. 508*, p. 609.

High-pressure Sterilization of Instruments.—Instead of boiling in a weak soda solution instruments to be used for operations on the alimentary canal, they should be dipped in soda solution and

sterilized in a high-pressure pure steam sterilizing apparatus at the pressure of $1\frac{1}{4}$ atmospheres (120° C.). Such a sterilizer is illustrated in *Fig. 267*.

The advantages of this method are: (1) speed—sterilization is complete in 10 minutes—important in the case of emergency operations; (2) complete sterilization—all spores are destroyed; (3) lessening of chemical irritation—a factor of importance in regard to the delicate tissues of the abdominal cavity.

Suture Material.—A No. 0 or No. 1 tanned or slightly chromitized catgut, provided with a shoulderless needle, should be the routine suture for all gastric or intestinal suturing.

In operations for carcinoma of the stomach, where the resistance of




Fig. 267.—High-pressure sterilizer for instruments. (*Lautenschläger*.)

the patient is very low, and where union is liable to be precarious, it is better to use fine silk or linen for the external layer of sutures. This material is well tolerated by the peritoneum, gives less local peritonitis and therefore entails a much smoother period of convalescence, and minimizes suture insufficiency.

Technique of Routine Suture of Gastro-intestinal Wounds.—

The Use of the Straight Needle.—The art of using the straight needle should be cultivated, for the surgeon can become much more

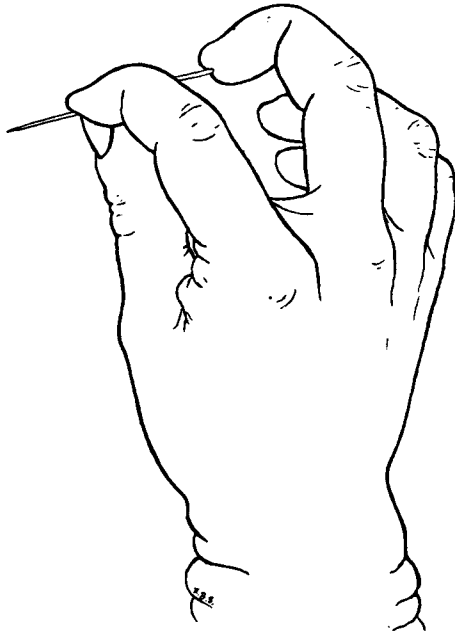


Fig. 268.—Method of holding and using a straight needle.

expert and stitch much more rapidly with it than with a curved needle, and accurate rapid suturing in big gastric operations sometimes means the difference between life and death. To be a good 'tailor' certainly saves much shock to the patient. *Figs. 268-270* show the method of using a straight needle.

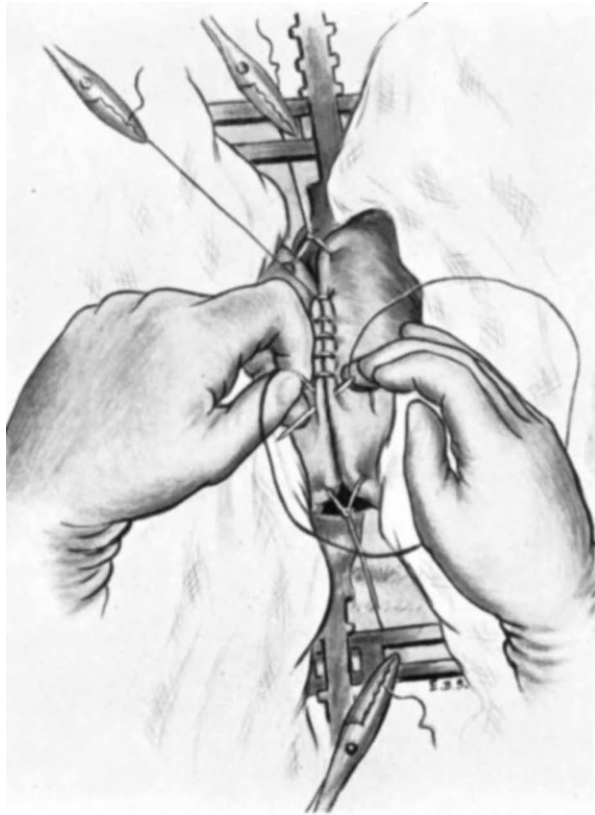


Fig. 269.—Showing how the intestinal segments should be fixed to the frame, so as to be able to suture with a uniform tension. Note the method of holding the thread with the left hand, close to the suture line; and how the fingers are disposed when suturing towards the surgeon.

The art of suturing with the left hand as well as with the right enables the surgeon to become very expert in the use of the straight needle, because there are certain regions in which suturing with the straight needle can only be done with the left hand.

The Use of the Curved Needle.—The curved needle should be small and have a long tapering point. It should be fully curved, so

that it can be used with a needle-holder and inserted by a supination movement. It should have a flat base, so that when used with the needle-holder it cannot possibly twist round in the holder and puncture the bowel. (*Fig. 271.*)

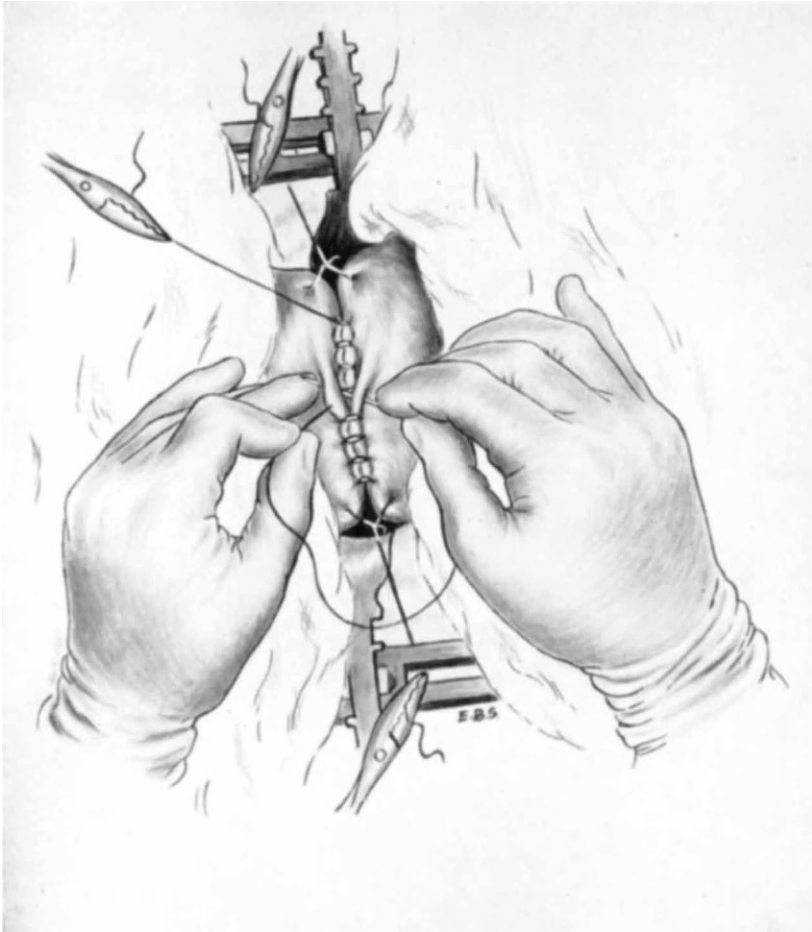
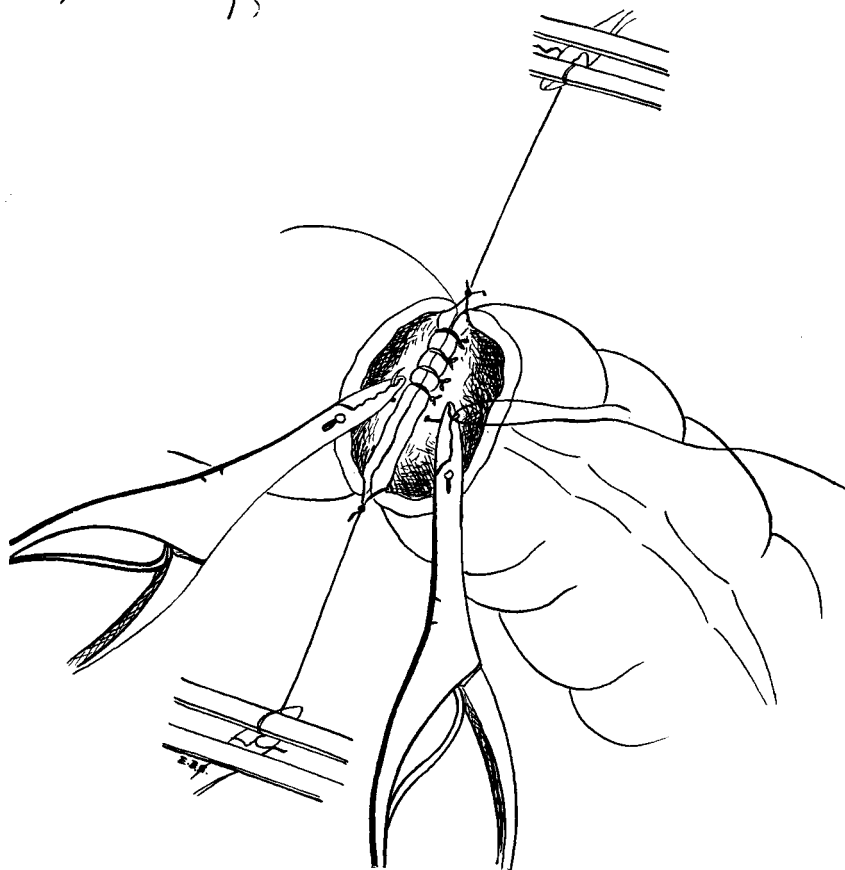
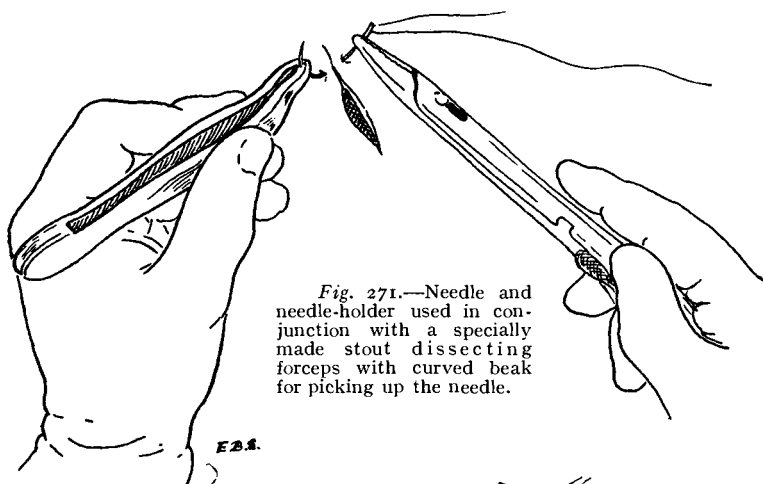


Fig. 270.—Method of suturing away from the surgeon. Note position of the third finger of the left hand, and how the thread is held with the first finger and thumb so as to produce a little ridge.

In suturing in deep cavities in the abdomen, such as the pelvis, the region of the common duct, or the lower ureter, the suturing must be done with two needle-holders, one in each hand, as shown in *Fig. 272.*



The Importance of Exact Hæmostasis in Abdominal Operations.

—In an abdominal operation exact hæmostasis is imperative. Indeed, when operating on the serosal, omental, or retroperitoneal tissues, every effort should be made to prevent the actual occurrence of bleeding. The reason for this is that shed blood extravasates very quickly into these very soft tissues and forms a hæmatoma which,

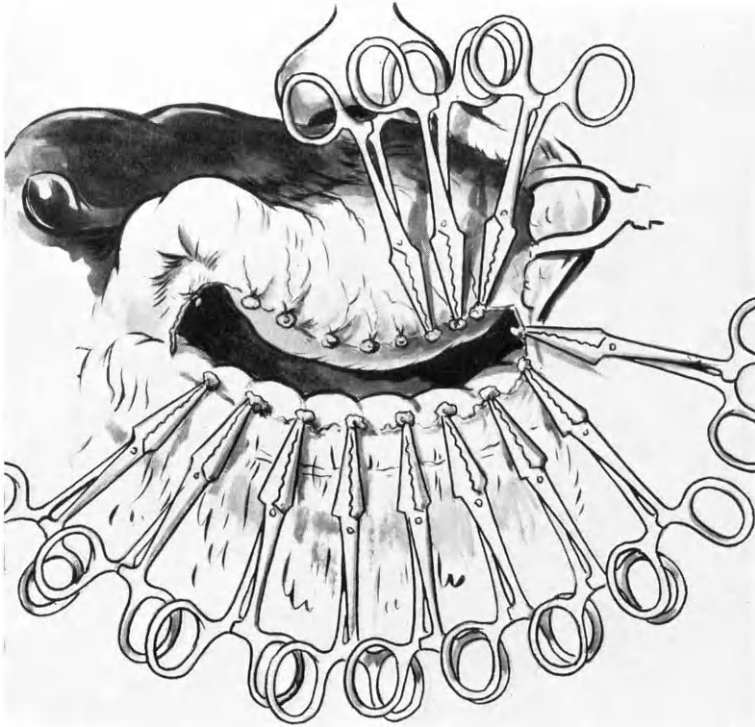


Fig. 273.—The method of isolating the stomach by the application of a number of Spencer Wells forceps and rapid ligation.

when once formed, cannot be wiped away. Such a hæmatoma is excellent culture material for germs, and not only predisposes to thrombosis, but also gives rise to adhesions.

Therefore, in all abdominal operations, the principle of attaining absolute 'dryness' should be aimed at. This should be obtained when dissecting tissues by first isolating and clamping the vessel, and then cutting it, so that no blood at all is shed. It is obtained in another way when dealing with the delicate omental tissues, by clamping these in small bites with artery forceps without having

regard to the actual vessels. *Fig. 273* shows this method of hæmostasis in the greater curvature in the operation of partial gastrectomy, where not the slightest hæmorrhage is allowed to occur.

This principle of obtaining absolute 'dryness' should obtain when operating on all hollow organs like the stomach, intestine, or colon. Perfect hæmostasis is not obtained by using bowel clamps and relying on suture for hæmostasis, by crushing the cut edges of the bowel, or by cutting it with a diathermy knife. In all these methods some bleeding can occur, and however little this may be, it may interfere with natural repair in a sutured intestinal wound, which, because of its narrowness, has very little margin for error; even a small hæmatoma may be the weak link in the chain, and cause a suture insufficiency. Therefore, in order to allow cut vessels in the wound to bleed so that they may be caught and ligated, it is important to avoid the use of clamps. In big operations, this painstaking hæmostasis is time-consuming unless some method of rapid ligation, as described below, is cultivated and practised.

The Surgical Knot.—The requirements of a surgical knot are that it should be so tight when tied that even the finest vessels cannot retract out of it; and also that it will not unravel.

A reef knot will not unravel. It has, however, the disadvantage that it is not possible to be sure that the first section of the knot is tied tightly, because the elasticity of the tissues must slightly loosen it while the second section of the knot is being made. The consequence of this is that it is not always a tight knot, and a fine vessel can retract out of its grasp when the patient vomits. Thus a reef knot is not a safe surgical knot.

The first section of a surgical knot must slip hard home around the vessel and remain tight while the second section of the knot is being tied. This can be done by making the first stage of the knot a granny knot, and when this is pushed tightly home, making it a reef knot by adding another tie in the appropriate way (*see Fig. 282*).

The modern abdominal surgeon should therefore cultivate the art of rapid, painstaking, and exact ligation of *even the minutest vessel*, for no vessel should be allowed to bleed and pour its clot-producing tissue-juice on to the delicate tissues of the abdominal cavity; all vessels should be first isolated and clamped, then cut and tied.

Method of Routine Rapid Ligation.—*Figs. 274-287* show the method of rapidly making a knot (modified from a Norwegian knot) which I employ. The knot can be made tight and will not unravel. The illustrations, which are self-explanatory, show how to tie the knot and cut the ligature in one combined time-saving set of movements.

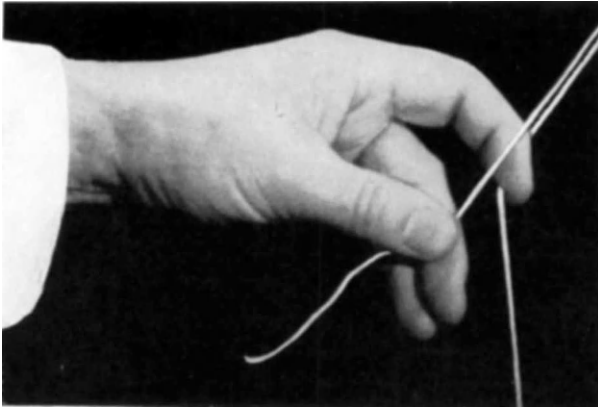


Fig. 274.—Loop made in long end with pulp of index finger.

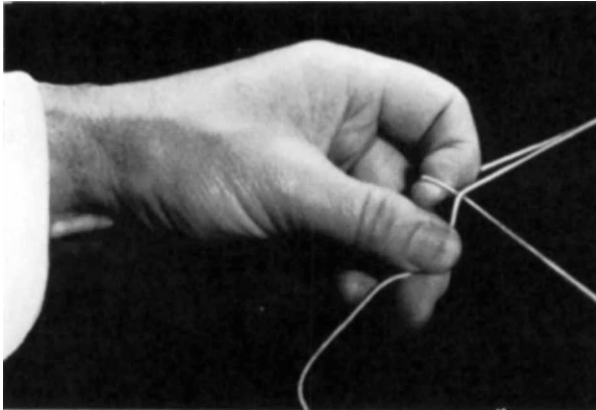


Fig. 275.—Short end in position for drawing through.

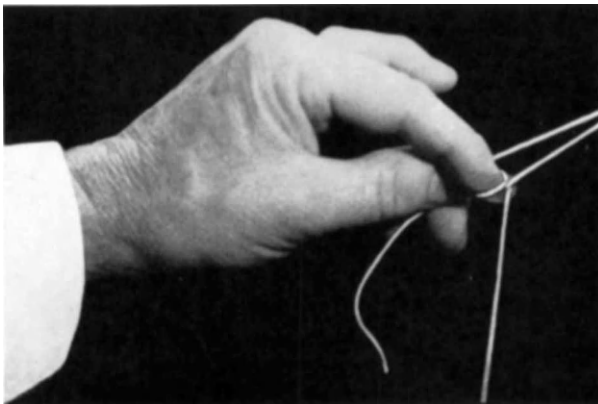


Fig. 276.—Short end pulled through on the dorsum of the nail of the index finger by a pronating movement.

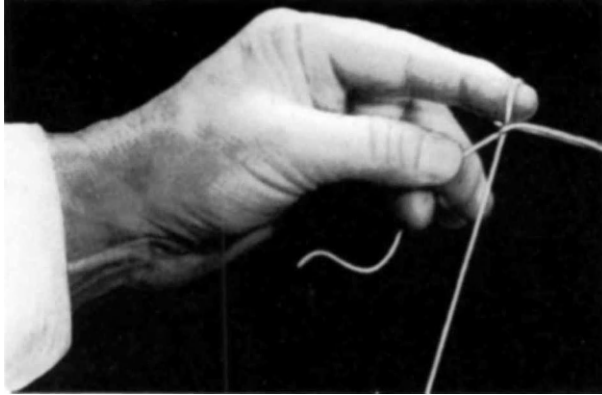


Fig. 277.—Short end in position ready to be grasped by the pulps of the thumb and the index finger.

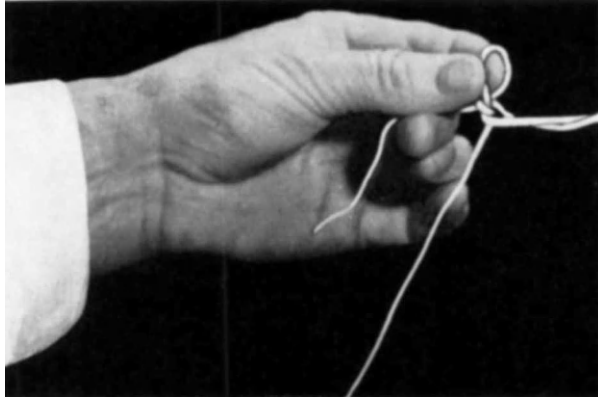


Fig. 278.—Short end grasped as described in *Fig. 277*.




Fig. 279.—Knot repeated as in previous movement to make a granny knot. Long end held straight in the air; short end held transversely so that granny knot can be made to slip tightly on to the vessel.

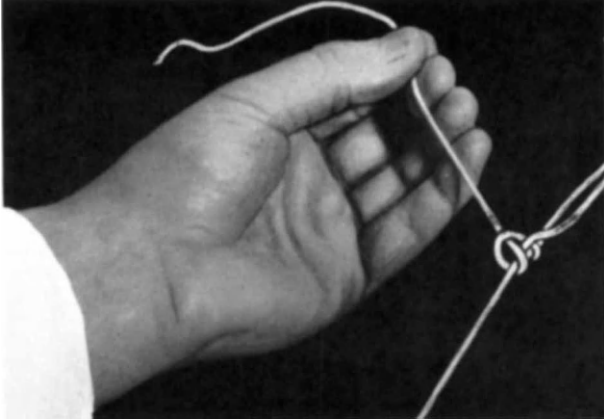


Fig. 280.—Hand in position for beginning the third stage of the knot.

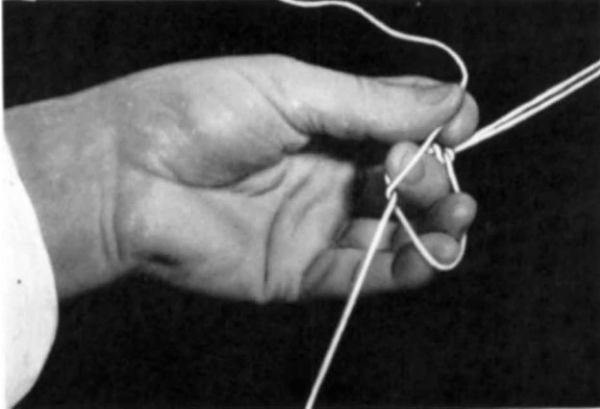


Fig. 281.—Position of second finger and thread for making the third stage of the knot—the locking knot.

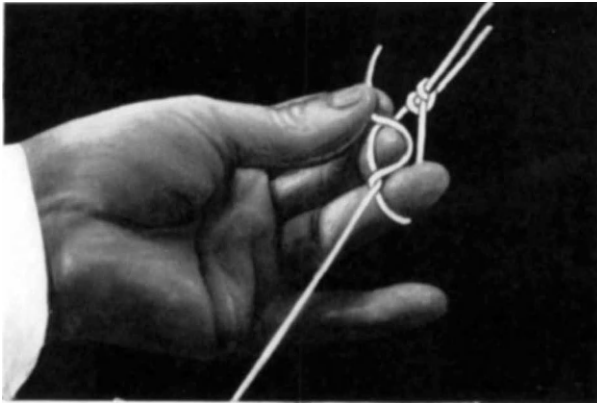


Fig. 282.—Drawing the short end through with the nail of the second finger to make the locking or reef knot.

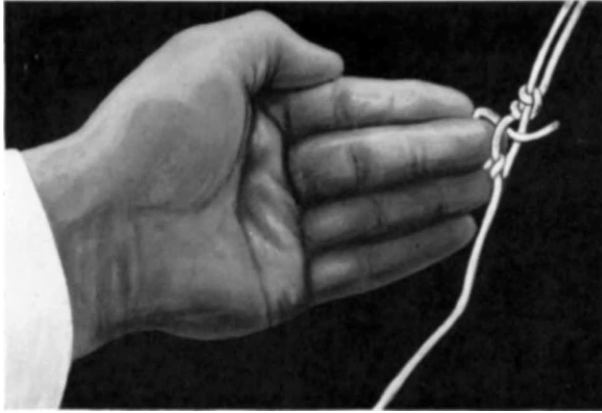


Fig. 283.—Short end drawn through with the nail of the second finger for the completion of the knot.

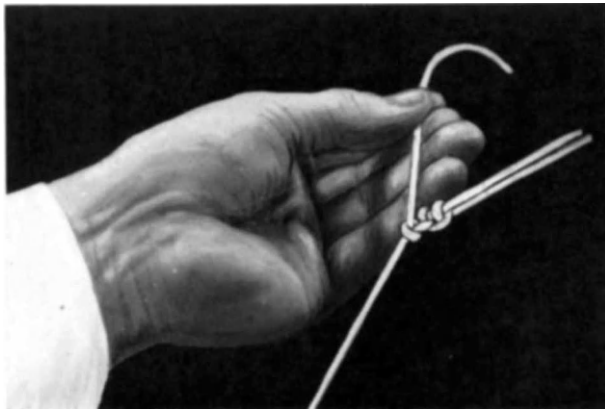


Fig. 284.—Knot completed.

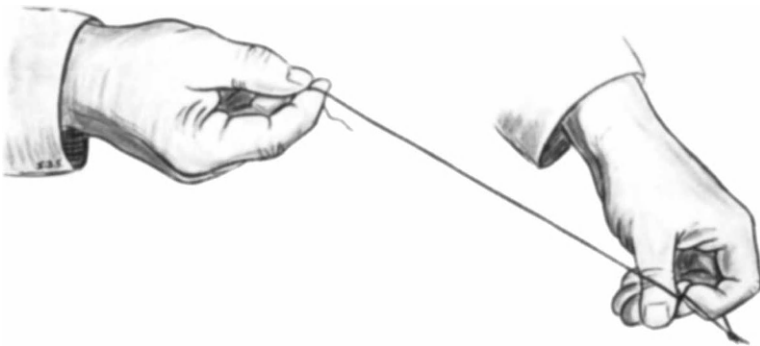


Fig. 285.—Tying knot in deep cavity. Shows the left hand in the cavity holding the short end of the ligature and the right hand a long way out of the cavity holding the long end quite straight. The illustration shows the first movement in making the knot.

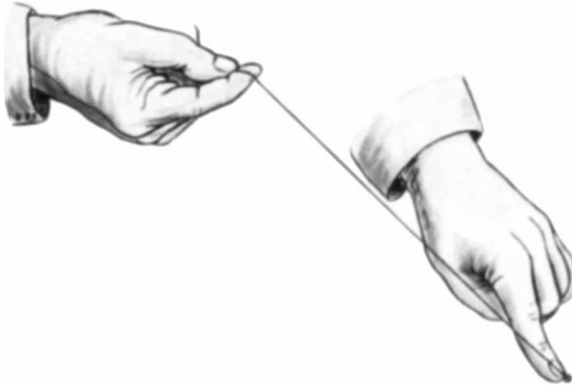


Fig. 286.—Tying knot in deep cavity. This shows the pulp of the index finger pushing tight the slip knot illustrated in *Fig. 285*.

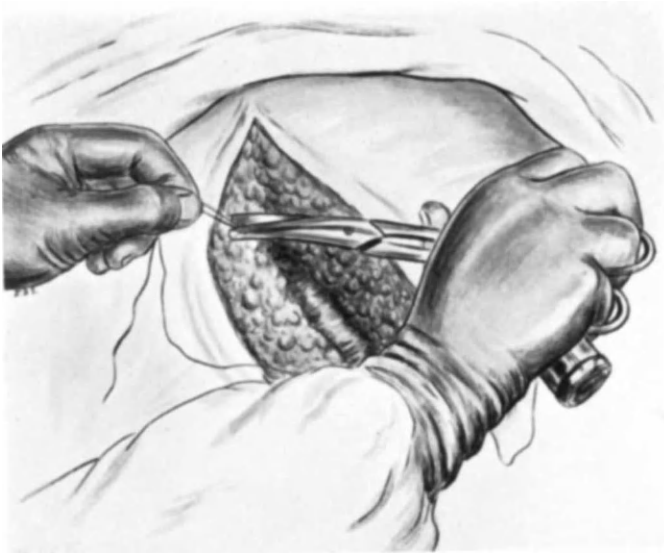


Fig. 287.—Showing how the surgeon can cut the ligature himself and do so very accurately, close to the knot, thus leaving as little silk as possible in the wound. The scissors are held in the palm of the hand while tying the vessel and then used to cut the ligature as the final movement of the ligation.

CHAPTER XXXVI

GENERAL PRINCIPLES IN THE TECHNIQUE OF
OPERATIONS ON HOLLOW VISCERA

OPERATIONS on the stomach, duodenum, and small intestine present certain operative difficulties peculiar to all hollow viscera—difficulties which must be recognized in order that a technique may be designed to surmount them.

These operative difficulties occur in regard to : (1) The contents of hollow organs ; (2) The management of the mucous membrane ; and (3) Bleeding from the cut edges of the wall of the viscus.

1. The Contents of Hollow Organs.—The contents of the stomach and intestines consist of fluid contents and air. Care has to be taken with regard to these contents (*a*) because they may be more or less septic and their leakage would cause peritonitis, and (*b*) because they cause distension of an organ like the stomach, and make operation on it difficult.

The contents of the normal stomach are not as a rule infective, because a normal percentage of hydrochloric acid acts as an antiseptic. In certain conditions, however, such as carcinoma of the stomach, pyloric obstruction, or pernicious anæmia, the hydrochloric acid is absent or its concentration is greatly reduced ; and in these circumstances the gastric contents are as a rule infective.

The contents of the upper part of the small intestine are mildly infective, those of the lower part and of the colon very infective ; and in pathological states, such as those due to intestinal obstruction or to peritonitis, the infectivity of the contents of both these viscera is much greater than under normal conditions.

In the case of a stomach where the fluid contents are either sterile or only mildly infective, the contents should be aspirated before operating on it, so that the organ becomes collapsed. This manœuvre minimizes the danger of soiling, makes the operation easier, and therefore lessens shock. Moreover, the retracted gastric wall permits more exact suturing.

2. The Management of the Mucous Membrane.—

The Mucous Membrane has a Protective Action.—The mucous membrane is adapted by nature to contain, without injury to itself,

the contents of an organ which may be irritating or injurious to other tissues. For example, the mucous membrane of the stomach is resistant to the action of its acid contents, but these contents are injurious to other tissues, as can be seen by their action on a gastrostomy wound, or by experiment (Dragstedt), in which it can be shown that normal gastric juice can erode submucous tissues.

From this physiological point of view, therefore, the accurate suture of the mucous membrane is a necessary preliminary to the secure and normal healing of a wound in a hollow organ. The role of the mucous membrane in repair is illustrated in the formation of a chronic ulcer of the stomach. Aschoff¹ has shown that small acute ulcers form in the pars pylorica and in the gastric canal. In the pars pylorica the ulcers heal quickly because the mucous membrane in this region is redundant and loosely attached to the subjacent muscular layers, and it therefore naturally tends to prolapse over a wound, protect it from the irritating action of acid, and thus allow it to heal. But in the gastric canal the ulcers do not heal; they become chronic, because the mucous membrane is sparse and firmly fixed to the subjacent tissue, so that it gapes and thus exposes the submucous tissues in the small ulcer to the eroding action of acid, with the result that normal repair is hindered.

The Mucous Membrane should be Sutured as a Separate Layer.—

The mucous membrane must move with the muscular layers in the expansion and contraction of a hollow organ. As it is not provided with muscle fibres, the only way it can do this is to fold itself as the muscular layers contract. To be able to do this, it must be very loosely attached to the muscular layers. Thus anatomically the mucous membrane has a loose connexion to the muscle layer and can move on it. It is therefore obvious that in order to permit this mobility it should be sutured as a separate layer, and not fixed to muscular layers as it normally is in the gastric canal. It is, for example, anatomically wrong in closing a wound in the stomach to suture, as is often recommended in text-books, the mucous membrane and the muscular layer in one tier of sutures, for this method causes the mucous membrane to adhere to the muscle by a strong scar, which is an excellent basis for the formation of a new ulcer.

3. Bleeding from the Cut Edges of the Wall of a Hollow Organ.

—Perfect hæmostasis before suturing the edges of a wound in the stomach or bowel is perhaps *the most important requisite* in order to obtain proper normal repair. The reason for this is that even the slightest bleeding will form a hæmatoma which may interfere with

the healing of the narrow suture line of an anastomosis and give rise to a suture insufficiency.

The usual methods adopted for obtaining hæmostasis in wounds of the stomach or intestine are : (a) the use of clamps which, while preventing the spilling of the contents of the organ, at the same time act like a tourniquet and temporarily prevent bleeding—a continuous suture is relied on to stop any bleeding which may occur after the clamp has been removed ; (b) the method of crushing the coat of the stomach or bowel by some form of crushing clamp such as Payr's, whereby the intima of any vessel is crushed and hæmostasis thereby attained ; (c) the use of the diathermy knife, the action of which is to coagulate tissue ; (d) contacting to the diathermy current the clamp which has been applied to a bleeding vessel.

All these methods have the disadvantage that there is no certainty that the bleeding is completely controlled. With the use of clamps, the hæmostatic suture does not always control the bleeding, particularly if from a large vessel, and fatal bleedings have not infrequently followed their use. When the tissues are crushed or when the diathermy knife is used, the bleeding from large vessels may still not be controlled. An additional disadvantage of these methods is that, if used in the stomach, the crushed or coagulated tissue, being deprived of its vitality, may be digested by the gastric juice, with the result that a gastric or jejunal ulcer may form.

Exact Hæmostasis.—There is only one sure way of attaining exact hæmostasis, and that is to avoid the use of bowel clamps, thus allowing all bleeding to take place, and then to clamp and tie each bleeding point. After a little practice, the vessels can be picked up very expertly and very quickly tied. Forceps on fine vessels may be momentarily contacted with the diathermy current.

In this method, any leakage of gastric or intestinal contents is avoided by a process of 'vacuum-cleaning'—that is, by aspiration.

In a long experience in gastric surgery, I have found that, although the clamp-and-tie method may be time-consuming, the most severe gastric operations are attended with little shock : if there is no bleeding there is no shock. On the other hand, when for some special reason I have relied on the use of clamps, even for simple gastro-enterostomy, patients have been unexpectedly shocked ; and the cause of this was usually obvious, for the vomit always contained much blood.

In one instance I had to operate on a very sick woman, terribly emaciated, who had a large penetrating ulcer on the proximal part of the lesser curvature which deeply penetrated the liver. No

worse risk could be imagined. The dissection was very extensive and difficult. Each vessel was ligated and tied, and the huge wound in the stomach was closed. Very little bleeding was allowed to take place, and, when finished, the sutured wound was quite dry. In addition, a gastro-enterostomy was performed with the same painstaking hæmostasis. After the operation this patient, notwithstanding her debility, experienced very little shock, and her recovery was uneventful.

In contrast to this case, I operated on a fairly healthy woman who had an ulcer of the duodenum, and performed a simple gastro-enterostomy. The operation only lasted twenty-five minutes. Clamps were used, and the sutures were depended upon to control the bleeding. After the operation she gradually got more shocked, and vomited quantities of blood-stained fluid. Her convalescence, notwithstanding the simplicity of the operation and her previous good health, was anxious, and in marked contrast to that of the first patient; and this unsatisfactory convalescence would in the ordinary course of events have been put down to the effect of the operation, if it were not for the fact that the patient vomited rather freely and the vomitus revealed evidence of the extent and continuity of her bleeding.

Exact hæmostasis, therefore, is one of the most important considerations in gastro-intestinal surgery.

REFERENCE

- ¹ ASCHOFF, L., *Pathologische Anatomie*, 1928, 740 (fig. 526).

CHAPTER XXXVII

THE OPERABILITY OF A PATIENT ON GENERAL GROUNDS

OPERATIONS in the abdomen—especially in its upper part—are attended with much shock and danger, and they leave little latitude for any general weakness of the patient. Consequently, every patient who is a candidate for an operation in this region must be carefully overhauled so that any general weaknesses may be discovered and pre-operatively treated. It is to the patient who appears to be a comparatively safe risk that surgical catastrophe often unexpectedly occurs, either at or after the operation: to the patient in whom with the usual examination no disease is obvious. Such catastrophes are seen for instance in cases of sclerosis of the coronary arteries with no obvious general arteriosclerosis, myocardial degeneration, renal disease, or hepatic insufficiency. The disease, latent under ordinary circumstances, comes to light as a result of the strain of the operation and the effect of the anæsthetic. A careful modern medical examination will uncover this latent circulatory or other type of disease, and enable pre-operative treatment to be carried out and precautions in regard to anæsthesia, operation, and post-operative treatment to be taken. Examples of this type of unsuspected pre-existing disease are given below.

Alcoholism.—It is surprising to find how often chronic alcoholism is unsuspected in a patient. It is only when serious pulmonary or other complications develop after the operation that inquiries elicit a history of alcoholism.

Sclerosis of the Coronary Arteries.—This condition may exist without other evidence of arteriosclerosis. Such patients may die suddenly after operation. Here is a signal example:—

An apparently healthy patient, a labouring man, aged 50, was operated upon for the closure of a large cæcal fistula. After the operation he had no untoward abdominal symptoms, and was well till the fourth day, when he died suddenly. At post-mortem it was found that his coronary arteries were so sclerosed that very little lumen was left; they were like a small clay-pipe stem and could be easily enucleated from the tissue in which they lay. An examination of the radial artery of this patient disclosed very little evidence of arteriosclerosis.

Renal Insufficiency.—It is not uncommon for a patient in ordinary life to be suddenly seized with uræmic fits. Previous to this happening, the patient may show no very obvious evidence of renal disease, and may have no albumin in his urine. Patients of this type, who, so to speak, are on the threshold of renal insufficiency, may, after an abdominal operation, develop renal complications or symptoms of obscure origin such as hiccup which are a result of this renal inadequacy.

The pre-operative detection of renal insufficiency in such cases is very difficult. An idea of the sufficiency of the kidneys may be obtained from the general appearance of the patient. Some notion, too, may be gleaned from the comparison of the height of the blood-pressure with the amount of urine excreted in twenty-four hours, and with its specific gravity—a high blood-pressure, a low specific gravity, and a small quantity of urine (instead of the usual large quantity) suggest renal insufficiency. If any doubt then arises, the patient should be sent for medical examination, when the various functional tests should be made. But even these examinations do not always help, because so much of the renal functioning tissue can have disappeared and yet no defective function be disclosed.

Hepatic Insufficiency.—Defective liver function is no doubt unexpectedly present in many cases. Observations made during abdominal operations have convinced me that in a number of patients who are operated upon for disease in the upper part of the abdomen, especially cholelithiasis, the liver is more or less diseased. Sometimes I have noticed that it was small, smooth, and atrophic; at other times that it was enlarged and smooth with rounded edges—obviously due to hepatitis or venous congestion. Frequently, too, I have observed that serious post-operative disturbances followed operation in those patients in whom I suspected a liver insufficiency.

I am sure it is the experience of many surgeons that some deaths after the operation can be ascribed to liver insufficiency. Professor W. Anschütz¹ reports the history of six cases of cirrhosis of the liver which developed severe ileus. His observations were verified by operations and autopsies.

Many patients with moderately pronounced liver insufficiency come through operations on the upper part of the abdomen fairly well; others develop a severe post-operative ileus and have a stormy convalescence; others, again, die as the result of the added embarrassment to their liver insufficiency caused by the operation. Those patients in whom the liver is large, smooth, with rounded edges, and who are probably suffering from hepatic congestion the

result of an early cardiac insufficiency, generally exhibit post-operative manifestations of circulatory failure, combined with those of a certain grade of liver inadequacy.

Both the types of liver deficiency which I have described would, I feel sure, show inadequate liver function if they were tested by one of the various dye methods, for they are cases which come to operation because they show indefinite manifestations of gall-bladder disease, and absence of a gall-bladder shadow—negative cholecystogram—which latter in itself may have been only a sign of liver insufficiency.

Suggestive of frequent association between disease of the gall-bladder and insufficiency of the liver are the results given by Rosenthal and Dyke's method for estimating the liver function, which Blomström and Sandström² have satisfactorily used in conjunction with the ordinary dye test for carrying out a cholecystography. They use a bromsulphthalein test, the technique of which is as follows:—

Firstly, in the cholecystographic method they employ, they use the fractional peroral method described by Sandström.³ According to this method the cholecystographic test is carried out in the following manner:—

First day: Half a dose of the opaque medium (Merck's 'Jodtetrag-nost') suspended in some alkaline mineral water. As a full dose they reckon 3 to 4 g. according to the body-weight.

Second day: The last meal on this day is taken at 4 p.m. This meal should be small in bulk and light, and should contain no fat or yolk of egg. In the evening, at 8 to 10 p.m., a full dose is given of the opaque medium suspended in ordinary soda-water.

Third day: Radiographic examination on fasting stomach at 9.30 a.m. Should no shadow of the gall-bladder be obtained at that time, further examination is undertaken three to four hours later, possibly followed by a yolk meal for studying the emptying of the gall-bladder.

An intravenous injection is made in the arm of a 5 per cent solution of bromsulphthalein in a quantity corresponding to 2 mg. per kilo body-weight. After thirty minutes, about 20 c.c. of blood is withdrawn from a vein in the other arm, and collected into two centrifuge tubes which are immediately closed with rubber stoppers to prevent evaporation. These tubes are then left standing until the following day, when a sufficient quantity of serum will have been obtained. Approximately 1 c.c. of serum is then drawn off with the pipette into two identical small test-tubes. To one of the tubes a drop of 10 per cent NaOH solution is added, as in the presence of bromsulphthalein the serum adopts a red-violet colour. To the second tube a drop of 5 per cent hydrochloric acid is added to free the serum from the result of hæmolysis if such has taken place. The alkalinized serum is then checked against a standard solution in a Walpole's comparator—the standard solution being placed behind the non-alkalinized serum—until similarity of colour is obtained. The standard solution is made up as follows: Bromsulphthalein 4 mg. is added to 100 c.c. distilled water, alkalinized with 0.25 c.c. of a 10 per cent solution of NaOH. This

solution is called 100 per cent standard solution, dilutions of which are prepared down to 5 per cent.

Where there is a high retention of the bromsulphthalein—over 40 per cent—suggesting that there is deficient liver function—these authors do not find a cholecystographic shadow: the liver cell which excretes the bile and also probably the bromsulphthalein is apparently defective. Such a finding, they say, indicates a liver deficiency.

A study of the curve of the patient's insulin tolerance will also yield valuable information as to his liver function. It follows that liver function tests should be carried out in those cases of suspected cholelithiasis in which the main, perhaps the whole, basis of the suspicion arises from a negative cholecystogram.

The patient with liver insufficiency should be given a diet rich in carbohydrate.

Circulatory Insufficiency.—It is difficult to assess the operability of a patient from the point of view of his circulatory sufficiency. He may show no evidence of cardiac or peripheral vascular disease when clinically examined. Electrocardiographic or X-ray examination may, however, reveal cardiac disease which is clinically undetectable. But even then the patient cannot be regarded as circulatorily sufficient; it is—even in an apparently normal heart—the quality of his *circulatory reserve mechanism* which matters, and which will carry him safely through a severe operation.

When a piece of hard work is imposed upon the human organism, an extra amount of circulating blood must be mobilized from its storehouses or blood-depots—the liver, spleen, and abdominal cavity—and thrown into the aorta and thus into the circulating blood. This is accomplished by extra effort on the part of the heart and the peripheral vascular mechanism in response to stimuli partly metabolic and partly nervous, both arising as the result of the increased work. It is the power of the patient's circulation to respond adequately to this increased work which is the function of his circulatory reserve mechanism, and it is this natural circulatory reaction of the body to cope with an unnatural interference—that is, with an operation—which constitutes the patient's circulatory efficiency: the quality of the circulatory reserve which he possesses for coping with effort over and above that required for his daily existence. In the old this circulatory reserve is very much decreased; in the young it is very great. It is lessened by disease, probably by the disease for which the patient is being operated on—as, for instance, by malignant disease. It is also reduced by inadequate function—as in the man who lives in his motor-car; by obesity; by race—as, for instance, the Hebrew type; by previous infective disease; and by age and

many other conditions. It is the estimation of this circulatory reserve before a severe upper abdominal operation which is often a difficult problem for the surgeon. Of course, if the surgeon has the shrewdness to recognize the fact that the patient has a poor circulatory reserve, he will hand him over to the physician for a further investigation, and if necessary for a pre-operative preparation of his circulatory mechanism.

Circulatory insufficiency may be detected if the patient gives an inadequate circulatory response to a measured amount of work—a response measured by alteration in his pulse-rate, his blood-pressure, and his respiration rate. It may also be found by an electrocardiographic examination or by radiographic investigation, which may show changes in the contour of the heart.

Circulatory deficiency can be inferred if the patient is of a certain type—for example, if he is pale and obese, plethoric and overfed, alcoholic, or has led a sedentary life—such a patient has very little circulatory reserve, no matter how clear his heart-sounds are, and how satisfactory his blood-pressure. Foged and Geill⁴ studied a series of 428 patients in whom a serious surgical operation was indicated. Of these, 351 were cases in which the heart had been clinically examined in the cardiac clinic and nothing abnormal had been found. In 253 of the latter, electrocardiography and radiography upheld the clinical findings that no heart lesion was present. In the remaining 98 either electrocardiography or X-ray photography, or both, gave an abnormal finding. In the first group the post-operative mortality from heart weakness was 1.1 per cent; in the second group the mortality was 11.8 per cent. Coronary sclerosis and myocardial degeneration were the cardiac lesions which indicated a bad operative prognosis.

Thus every patient, especially if he is old or fat, who is about to undergo serious operation, should be cardiographically and radiographically examined.

Where examinations show that he has a heart weakness and that this heart weakness is a coronary sclerosis or a myocardial degeneration, then operations such as gall-stones, hernias, and similar luxurious operations, which are not urgent, should not be performed. If the heart weakness is not great, then perhaps a less severe and more conservative operation may suffice.

The patient with a circulatory insufficiency should be prepared : (1) by the administration of an appropriate diet ; (2) by graduated exercises ; (3) by increasing the efficiency of the cardiac mechanism, for which digilanid (Roche) and other digitalis preparations are used.

It has been strongly maintained in many large clinics that the proper administration of digitalis can improve the circulation and build up reserve, and thus lessen not only the circulatory disturbances which would usually follow post-operatively, but also those disturbances which would arise out of a circulatory deficiency—such as thrombosis, lung emboli, etc. On the other hand, it is argued that whatever value digitalis might have for a crippled heart, it cannot be of service to build up an undiseased heart, and therefore cannot be useful in pre-operative circulatory preparation. However, as far as I can clinically judge, I have found digilanid of considerable value in improving a patient's circulatory reserve.

Drugs which have been used effectively in defective circulatory conditions are cardiazol and injections of glucose solution with sympatol; the latter is a synthetic preparation which has a prolonged action on the vessels, and, in combination with glucose intravenous injections, an action on the heart muscle. Veritol, which has a somewhat similar effect to sympatol, can also be given intravenously in doses up to 1 c.c.

Metabolic Disturbance.—Of the metabolic disturbances, the most important is that which occurs in *diabetes*. In this condition there are not only profound toxic disturbances in the tissues themselves, but also, as a rule, arteriosclerotic changes. Gross tissue insufficiency—inability to repair and liability to infection—is indicated by the presence of acetone in the urine, and the degree of insufficiency may be measured by the percentage of acetone.

In an abdominal operation, where there is usually adequate time for a proper preparation, the patient should, for a fortnight before the operation, have urine free from sugar, acetone, and aceto-acetic acid, and be capable of tolerating a normal carbohydrate diet. To accomplish this the physician must be called in and the patient must be given, under his direction, adequate insulin and appropriate dietetic treatment. It requires nearly two weeks before a metabolic equilibrium is established and operation can safely be undertaken.

In the case of an emergency operation, a more urgent preparation must be carried out, and glucose solution given intravenously in combination with injections of insulin.

Pulmonary Insufficiency.—Operations in the upper part of the abdomen are particularly prone to give rise to post-operative pulmonary trouble.

One reason for this tendency is that the same nerve—the vagus—supplies the peritoneum, the organs of the upper part of the abdominal cavity, the pleura, and the lungs; and irritation to the

upper abdominal part of the vagal field causes irritation to the lower part of the pulmonary vagal field, with the result that secretion forms in the bronchial tubes, and the foundation is laid for an infection and pulmonary affection.

Another reason is that the diaphragm becomes reflexly fixed, and the lower part of the lungs is thus hypoventilated, resulting in a diminished circulation, and therefore a predisposition to infection.

A further reason is that a painful wound in the upper part of the abdominal wall prevents deep breathing, and this also lessens the ventilation and therefore the circulation of the lower part of the lung.

Finally, there is a connexion between the lymphatics of the upper part of the abdomen and the lower part of the thorax, and infective processes from the upper part of the abdomen can spread up into the pleura and the lungs.

A history of previous attacks of bronchitis, or signs and symptoms of emphysema, may require special pre-operative preparative treatment.

Caution in regard to operation should be exercised during epidemics of influenza, or in patients who have travelled long distances by train. Sufficient time should be allowed to elapse to show that these patients are not suffering from any incipient pulmonary infection.

Thus, when a patient requires an operation in the upper part of the abdomen, particular care must be taken to see that he has no pulmonary weakness; and also no circulatory insufficiency, which, of course, is an important cause of a pulmonary weakness.

Where pulmonary insufficiency is present, not alone will it require to be pre-operatively treated, but special care will be necessary in choosing the anæsthetic.

REFERENCES

- ¹ ANSCHÜTZ, W., *Acta chir. Scand.*, 1932, **71**, 32.
- ² BLOMSTRÖM, H., and SANDSTRÖM, C., *Ibid.*, 135.
- ³ SANDSTRÖM, C., *Acta radiol.*, **10**, 271; **12**, 8.
- ⁴ FOGED, J., and GEILL, T., *Acta chir. Scand.*, 1936, **78**, 236.

*CHAPTER XXXVIII***IMPORTANT ANATOMICAL FEATURES IN THE
SURGERY OF THE UPPER ABDOMEN****THE RETROPERITONEAL TISSUE PLANE**

THE retroperitoneal tissue plane is a sheet of fatty tissue of varying thickness which is particularly well defined under the parietal peritoneum. This plane has a special importance in the surgery of the abdominal cavity, because not only has it a low resistance to infection, but also it permits of the spread of any infection over a very wide area; and such an infection, because of its wide extent, even though it may be of low virulence, is particularly fatal.

Infection of the retroperitoneal tissue plane may follow an acute appendicitis in which the inflammation has penetrated the parietal peritoneum; or in which the surgeon has inadvertently opened into the retroperitoneal tissue, and has not subsequently drained the subperitoneal space. I have seen the tip of an inflamed appendix perforate the peritoneum into the retroperitoneal tissues and cause a cellulitis-like infection of the plane. Further, when infection of this plane has occurred, I have seen it spread over the whole retroperitoneal tissue of the posterior abdominal wall, and even into the subpleural tissue plane of the thorax.

This retroperitoneal cellulitis can also cause a gastroduodenal ileus. In one instance, a patient was operated on for an acute gangrenous appendicitis. For five days after his operation he was comparatively well. His temperature then rose, his pulse-rate became rapid, and he started to vomit. Soon he vomited large quantities, and it was obvious that he was suffering from a gastroduodenal ileus. About the tenth day he died. An autopsy revealed a sheet of retroperitoneal cellulitis spreading over the posterior abdominal wall. This had originated from an opening in the peritoneum where the gangrenous tip of the appendix had been adherent. An inflammatory process had spread along the retroperitoneal plane, involved the duodenum, and caused a segmental paralysis, from which a gastroduodenal ileus resulted.

Another important feature in regard to the surgery of this retroperitoneal space is that, as it has a low resistance to infection, the

fatty tissue sloughs easily, and these sloughs help to pass the infection along the tissue plane. For example :—

A patient had had a retroperitoneal infection following a gangrenous appendix. The retroperitoneal tissue was opened and drained in various situations, and in each case sloughs of fat were found. Notwithstanding this treatment the infection slowly progressed, spreading by a series of sloughs, until finally it spread subpleurally to the chest wall, where abscesses developed around the ribs. Eventually, after an illness extending over two years, the patient died from this low-grade widely spreading infection of the subserous tissue planes.

The important practical point arising out of this consideration of the retroperitoneal space is that, where it is definitely infected, or even where it is laid bare by a wound in the peritoneum—and thus, in an operation for acute appendicitis for instance, rendered liable to infection—it should always be drained: the retroperitoneal tissue plane should never be trusted to deal with any form or degree of infection.

THE MESENTERIC ATTACHMENTS TO THE POSTERIOR WALL

In *Fig. 288* are shown the mesenteric attachments to the posterior abdominal wall. The arrow *A* indicates the paracolic gutter down which the contents from a ruptured gall-bladder or duodenum may run, passing down along the right side of the ascending colon, and often giving rise to symptoms similar to those of acute appendicitis. The arrows *B, C* indicate subphrenic spaces where fluid from pathological conditions of the liver, gall-bladder, or duodenum may accumulate, or pus may collect from an upward spread following a suppurative appendicitis. The arrow *C* indicates the lesser peritoneal cavity into which gastric contents may enter when perforation of the posterior wall of the stomach takes place.

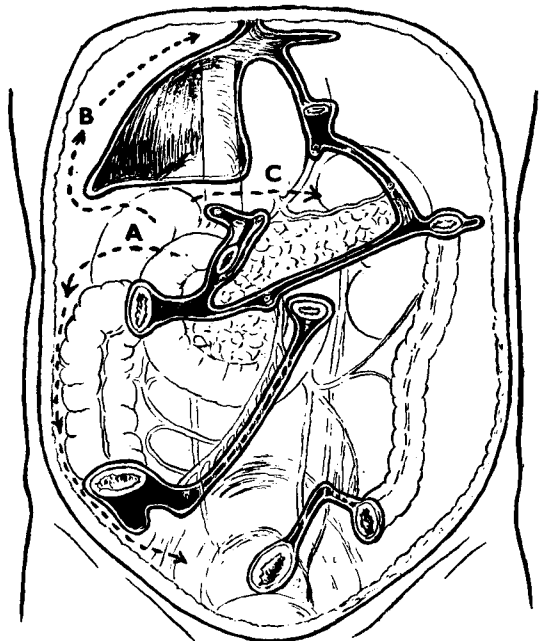


Fig. 288.—Showing mesenteric attachments to the posterior abdominal wall. *A, B, C* indicate directions which fluid, such as blood or pus, may take.

These mesenteric attachments are surgically important, because they determine the spread of pus in the various regions of the abdominal cavity, and because fluids such as blood and pus accumulate in the areas which they limit, so that through these the surgeon can more or less effectively drain large sections of the abdominal cavity.

They are also important because they form as it were watersheds which can be used to hold local anæsthetic solution, and thus to obtain an anæsthesia of certain parts of the involuntary nervous system of the abdominal cavity, as, for instance, in Mandyl's method of diffusion anæsthesia (*see* p. 471).

THE LYMPHATIC FIELDS IN THE ABDOMEN

The lymphatic fields of the abdominal cavity are not definitely separated from one another. For instance, the lymphatic field which drains the cæcum and the appendix is connected with the lymph-glands in the vicinity of the gastro-hepatic ligament and common duct. Thus an infection in the appendiceal area can be transmitted through the lymphatics into the area round the gall-bladder and the duodenum.

The lymphatic fields of the upper part of the abdomen connect freely with the lymphatic fields of the lung, but particularly with those of the mediastinum. Dye injected into the lymphatics in the upper part of the abdomen is quickly found in the mediastinal lymphatics. The lymphatic fields of the liver and the gall-bladder, and those of the gall-bladder and pancreas, are intimately connected, and thus the lymphatic field of the liver, through that of the gall-bladder, is connected to the lymphatic field in the pancreatic region. Infective processes in the upper part of the abdomen may therefore pass very readily into the mediastinum and even to the lung, and infective processes in the gall-bladder and liver may spread to the pancreas.

ABSORPTION OF FLUIDS IN THE ABDOMINAL CAVITY

The lymphatic vessels in the upper part of the abdomen, especially in the stomach and upper three-fourths of the intestine, are much bigger than those of the lower part of the alimentary tract, because they are more concerned with absorption of food products than those of the lower part. The consequence of this is that toxins from infective processes are rapidly absorbed. An infective process in the upper part of the abdomen, even though the infection is not very virulent, is therefore a more serious condition than an infective process of a similar nature in the lower part of the abdomen. Further, 'diffusion local anæsthesia' (anæsthesia produced by pouring a

solution of percaïn or other local anæsthetic drug into the abdominal cavity) is more dangerous in the upper part than in the lower.

If fluid is introduced into the peritoneal cavity the greater part is absorbed directly into the veins. If it is coloured with a dye, dye-stained fluid will be found in the veins in five or six minutes. On the other hand, if the dye-stained fluid is injected into the thoracic duct, it will be found in the blood only after a lapse of half an hour.

NERVE-SUPPLY OF THE ABDOMINAL VISCERA

The abdominal viscera have no nerve-endings similar to those in the body wall, the stimulation of which produces pain. Where local anæsthesia is used for making the incision in the abdominal wall, viscera can be handled without causing any pain to the patient. If, however, the stomach or intestines are roughly handled, dragged, or in other ways traumatized, the patient experiences a sensation of sickness, begins to vomit, sweat, become pale, and generally to present all the appearances of suffering from neurogenic shock. The organs of the abdominal cavity are, as it were, buried deeply in the centre of the body, and protected by the abdominal wall. It is not necessary for them to be provided with the mechanism whereby they can distinguish hurtful influences. They are therefore only provided with nerve apparatus of which the main function is concerned with the emptying and filling of the various segments of the alimentary canal.

The peritoneum and the organs of the abdominal cavity are innervated by that part of the nervous system called the autonomic system: the involuntary nervous system. This system is subdivided into the sympathetic and the parasympathetic systems, the latter of which is made up by the vagus nerves and the sacral outflow.

The peritoneum and the organs are richly supplied with afferent receptors. Some of the fibres from these run by the paravertebral or vagus, and some by the sympathetic, particularly by those sympathetic filaments which run by way of the vessels. These receptors are sensitive to stimuli of tension.

Some mesenteries and some abdominal organs are better supplied with these afferent receptors, and therefore more sensitive to appropriate stimuli, than others. The liver and spleen are comparatively insensitive; the stomach moderately sensitive. The mesenteries of the stomach and those in the region of the gall-bladder and common duct are very sensitive. The intestine is poorly supplied with afferent receptors, while its mesentery is highly sensitive.

A practical application of this unequal distribution of afferent sensory receptors in the abdominal cavity is that, when operating

under local anæsthesia, in order to avoid vomiting and shock and other effects in handling abdominal tissues, the highly sensitive mesenteries must be injected with novocain solution.

As the involuntary system nerve-supply to the abdominal organs consists mainly of a network of unmedullated nerve-fibres, very little traumatism produces widespread radiating impulses, and therefore much neurogenic shock. The abdominal wall, on the other hand, is supplied with sensory medullated nerves, for warning against hurtful influences, and injury to nerves of this type does not produce such widespread radiating impulses and such shock.

The practical application of this knowledge of the nature of the nerve-supply of the abdominal cavity and the abdominal wall is that, in operations in the abdomen, where there is a choice of the incidence of operative injury on the abdominal wall or on the abdominal contents, it should be in favour of the former, and as little injury as possible should be inflicted upon the contents; for injury to the wall will not cause nearly so much shock as will injury to the contents. It is on this basis that I have built the use of my operating frame in abdominal operations; that is, on the principle of throwing the traumatism of the operation on the abdominal wall rather than on the viscera, which are operated on in the abdominal cavity under natural conditions where they are handled as little as possible and where they do not transude gas or become dry or cool.

NERVE CONTROL OF THE WHOLE ALIMENTARY CANAL

The alimentary canal is supplied on the one hand by the vagus and sacral nerves—the parasympathetic system; and on the other hand by the sympathetic outflow—an outflow from the thoracic part of the cord.

The parasympathetic supplies the detrusor musculature of the hollow organs, and is therefore concerned with the emptying of the various segments of the alimentary canal—contraction of the detrusor, and relaxation of the sphincter.

The sympathetic supply innervates the sphincter apparatus, and is therefore concerned with retention—contraction of the sphincter and relaxation of the detrusor.

The muscle of the alimentary canal has also a neuromuscular mechanism in its own walls which is sensitive to appropriate stimuli, and which can therefore act automatically and independently of the involuntary nervous system.

Regarded from a clinical point of view, the motor functions of the upper and lower parts appear to be more stable than those

of the middle part of the alimentary canal; that is, the motor functions of the small intestine are less stable than those of the stomach, sigmoid, and rectum. Perhaps this is due to the fact that these latter are more dependent on the innervation they receive from the involuntary system than is the middle part.

Therefore, in every abdominal operation the small intestine is the danger area, and in the whole of the abdominal cavity it is the one region in which the surgeon must exercise the greatest gentleness, because its delicate functions—the intestinal pendulum and peristaltic movements—are so easily injured, and because disturbance of this function is attended with such dire consequences—that is, with post-operative ileus, or grades of intestinal stasis short of this. The surgeon should therefore invade the middle of the abdomen as little as possible: he should approach the abdominal cavity, as far as he can, from above or below.

The nervous interrelationship of the various sections of the alimentary canal through the involuntary nervous system must also be remembered, for it often explains the origin of gastric or other troubles. If, experimentally, the small intestine is cut across, the pylorus closes for eight to ten hours. If inflammation occurs in the lower part of the small intestine, such as an appendicitis, the pylorus also closes. Enemas given in a disconnected functionless distal colon will cause an enterostomy or a transverse colostomy to function.

Thus, operations on one segment of the alimentary canal disturb the functions of other segments. Disturbances of emptying of one segment cause a disturbance of emptying of other segments. Disease at one level, therefore, can disturb the functions and produce disease at other levels.

CHAPTER XXXIX

GENERAL PRINCIPLES IN REGARD TO INCISIONS
IN THE UPPER PART OF THE ABDOMEN

THE principles which determine the site of an incision are considered in this chapter.

The Nerves of the Abdominal Wall.—That the nerve-supply of abdominal muscles must never be injured ought to be a cardinal

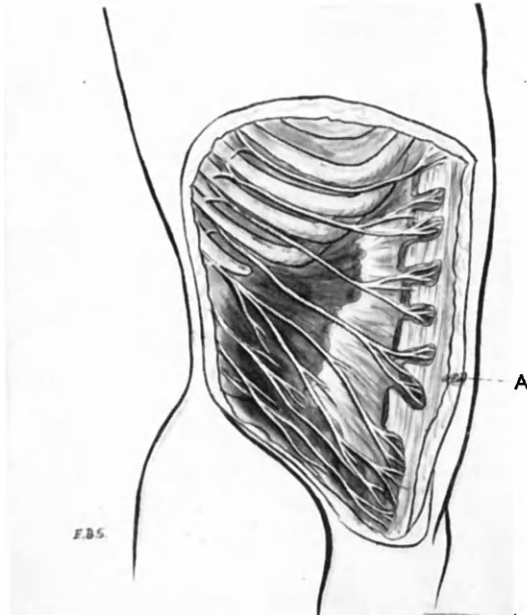


Fig. 289.—Nerves of the abdominal wall as they enter the rectus muscle.
A, Umbilicus.

principle which should govern the making of incisions in the abdominal wall (*Fig. 289*). If nerves are injured by incisions, for example, in lateral parts of the rectus, the muscle atrophies, and a hernia results.

The Postural Tone of the Abdominal Wall.—From my observations at the operation table, I believe that there is one area of the abdominal wall which has very much greater postural tone than the

remainder. This is an indefinite area about the centre of the abdomen, and is roughly represented by the part shaded in the diagram (*Fig. 290*). It corresponds with that part of the abdominal wall in which extra tone is required in order to hold the wall tense, and thus to keep the intestines in their proper place in the upright position—that is, on the oblique shelf of the posterior abdominal wall above the promontory of the sacrum (*see Fig. 291*).

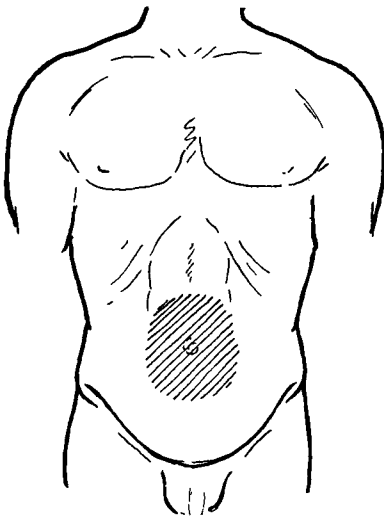


Fig. 290.—Diagram showing roughly that part of the abdomen in which the tone is greatest, and in which incisions should not be made. (The area is larger than represented here.)

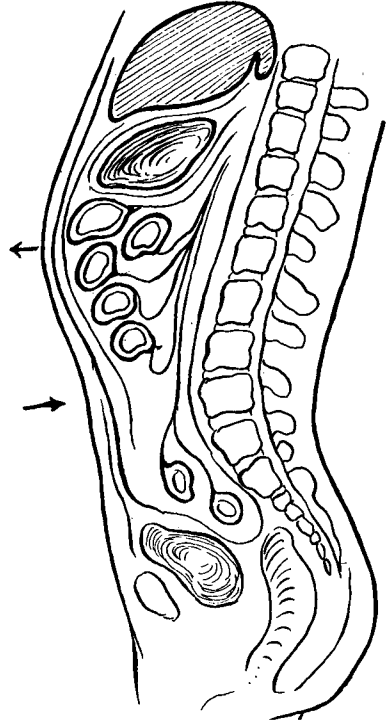


Fig. 291.—Position of the intestines when the abdominal wall is drawn in by an intense pathological spasm of the lower abdominal muscles.

The position of this area of postural tone is also shown when an intense pathological spasm occurs in the lower abdominal muscles (*Fig. 291*). The spasm occurs most strongly in this region, and presses the abdominal contents into the upper part of the abdomen, where the natural tone of the rectus muscle is much less, and this upper part becomes ballooned out into a tumour-like condition. Indeed, some individuals can produce this bulging of the upper part of the abdomen by contracting their lower abdominal muscles.

It will therefore be found in this region, where the postural tone is so marked, that the suture and coaptation of the rectus muscle and its sheath is more difficult than in any other part of the abdominal wall.

Hence, if possible, long incisions should not be made in or into this central area, because the sutures required to close them will be under greater tension, and because the resultant scar of the wound will be much more likely to stretch.

Incisions should not be made over the Area of the Small Intestine.—An additional reason for not operating through the central part of the abdomen is that behind it lies the small intestine, and the surgeon rarely needs to operate on this part of the gut. Further, as the small intestine has a function which is most easily deranged, it should not, if possible, be exposed. Moreover, an abdominal wall wound should, as far as possible, be kept away from the area of the small intestine because this viscus readily adheres to an abdominal-wall wound, and even its slight adherence causes disturbance of intestinal function and much morbidity.

The Role of the Position of Vascular Pedicles and Ducts.—The operative approach through the abdominal wall to the various organs in the abdominal cavity is generally determined by the positions of their vascular pedicles or ducts. Once the pedicle or duct is divided the organ is, as it were, untethered and bloodless, and it can therefore nearly always be dissected out without much trouble.

As developmentally the vessels of an organ must necessarily rise from, and the duct empty at, the midline of the body, the proper operative approach to most abdominal organs will be from the midline. Examples of this principle are given below.

The Gall-bladder.—The cystic duct empties into the common duct, and the cystic artery arises from the hepatic artery, very close to the midline. When each of these structures, which are most accessible from a midline incision, is dissected and divided, the gall-bladder has only to be dissected out of its bed and it comes naturally to the midline, because there are no important anatomical structures in the region of the fundus to tether it. On the other hand, if a vertical incision is made over the fundus of the gall-bladder, the ampulla and the cystic duct—most important structures—are not in an accessible position for dissection and division.

The Stomach.—In operations on the stomach, as a rule, the main difficulty—especially in the case of an ulcer or carcinoma of the stomach—is the mobilization of the lesser curvature. This difficulty is overcome by dividing the left gastric artery, which arises from the aorta close to the midline. Thus a paramedian or a costal incision (*see p. 475*) directly over the origin of the tethering left gastric artery is the key point of a difficult gastric operation. (*See also pp. 524–526 and Figs. 414–419.*)

The Colon.—The vessels of the colon originate from the aorta, and therefore from the midline. The peritoneum lateral to the colon and binding it to the abdominal wall contains no vessels. Therefore, in operations on any part of the colon, the pedicle of the colon, the crucial point of the operation, is situated in the midline. As any part of the colon can be brought to the midline without dividing vessels, the proper incision for any operation on the colon is one made in the midline.

The Spleen.—Even in the case of the spleen it will be found that it is held by its vascular pedicle; that it can be dislocated from all its adhesions to the diaphragm and to other areas, and mobilized towards a point not far from the midline, so that its pedicle is directly under the eye of the operator. Thus, a paramedian incision is better designed to expose the spleen than is a lateral one.

The Kidneys.—The pedicle of the kidney is also attached to midline structures—to the aorta and to the anterior vena cava. The peritoneum binding the kidney to the posterior abdominal wall contains no vessels. Consequently, in abdominal operations on the kidney, if the peritoneum is divided the kidney is delivered naturally and therefore easily into a midline incision, and the pedicle is directly under view and most conveniently situated for ligation. Indeed it is a surprise to see how easy an operation on the kidney becomes when it is performed through a midline incision.

CHAPTER XL

THE SURGERY OF ABDOMINAL ADHESIONS

ADHESIONS are caused by inflammation (i.e., by a peritonitis), by peritoneal trauma following abdominal operations, and by congenital anomalies. Profound and general peritoneal adhesions are also found in that unusual condition called encapsulating peritonitis, an illustration of which is seen in *Fig. 292*.

Adhesions a Feature of Modern Abdominal Surgery.—The operative problem of dealing with adhesions is a feature of modern abdominal surgery. It is often the most difficult part of an operation in the upper part of the abdomen; and nowadays it is a problem of frequent occurrence, because so many more abdominal operations are performed, and therefore so many more operations are done on a background of previous operations. Consequently, I cannot emphasize too much the great necessity for the surgeon to be skilful in dealing with adhesions if he is to carry through successfully the very difficult secondary operations which are now so frequently met with.

Post-operative Adhesions.—Adhesions following operations give by far the most trouble. These may be classified as follows: (1) Fine, filmy, easily separated, and therefore what might be called beneficent adhesions; (2) Firm, broad, and most difficult to separate, and therefore what might be called pernicious adhesions; (3) String-like adhesions which are liable to give rise to a strangulation of the intestines—'wire-drawn' adhesions.

1. *Beneficent adhesions* are due to slight endothelial injury, such as handling the intestine, or allowing it to become dry. They do not, as a rule, cause symptoms. They present a definite line of cleavage, and are easily separated.

2. *Pernicious adhesions* are caused by gross traumatism to the peritoneum, or by loss of peritoneal substance. They present no definite line of cleavage and are therefore extremely difficult to separate. Moreover, when separated, they nearly always recur, unless the areas left bare after separation are accurately peritonealized.

3. '*Wire-drawn*' adhesions are due to the constant pull on the ordinary adhesions. They are important because they are the kind

that remain latent for years and then suddenly give rise to strangulation of loops of bowel. These string-like adhesions are easy to deal with and do not as a rule recur.

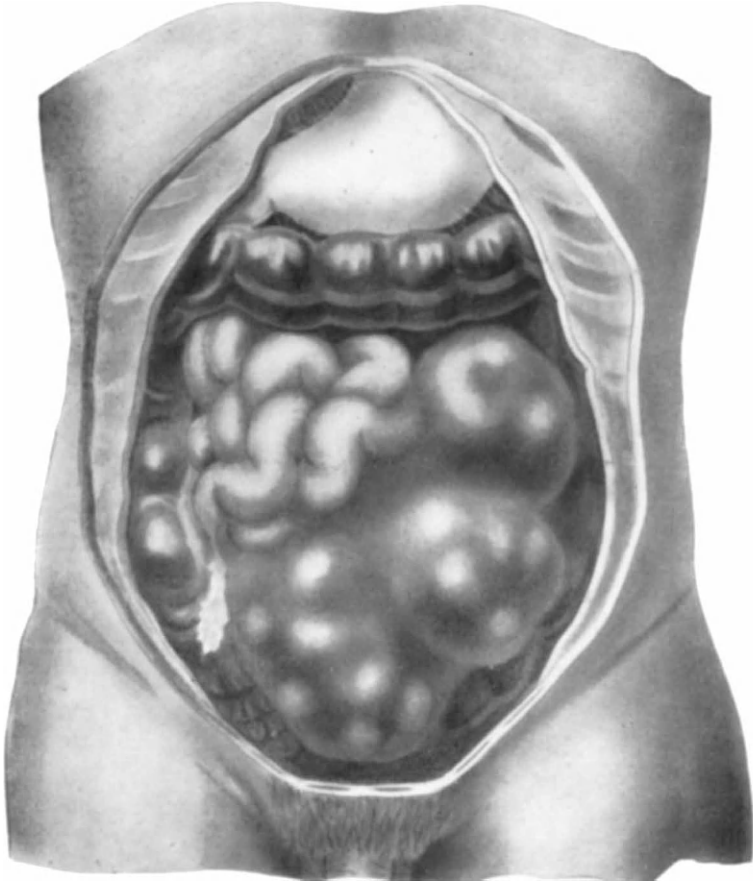

Fig. 292.—Tumour-like masses causing intestinal obstruction in a case of encapsulating chronic peritonitis. The stomach and small intestines are covered with a thick, opaque contracting membrane. The colon is normal. (*From the 'British Journal of Surgery'.*)

The Sites of Adhesions.—Adhesions are also of surgical importance according to their situation, that is, according to the serous surfaces and the abdominal viscera which they involve.

The sites of adhesions may be classified according to their importance as follows: (1) from the omentum to the anterior abdominal wall; (2) from the small or large intestine or from any other of the abdominal organs to the anterior abdominal wall; (3) from one abdominal organ to another, such as between loops of

small or large intestine, or between these and the liver or other abdominal organs.

Adhesions in each of these situations involve an individual operative problem.

The Art of Dealing with Adhesions.—As I have written, the surgery of the adhesions is usually the most difficult part of a secondary operation, the isolation of adherent abdominal viscera being difficult, dangerous, and time-consuming work.

In dealing with adhesions, the operative principles which should be followed are :—

1. The adhesion should be stretched firmly enough to make visible the true line of cleavage—the original line of adhesion, which is bloodless.
2. The line of cleavage should be accurately followed under vision, and dissected with a sharp scissors, so that a minimum of raw surface is left ; the adhesion should not be torn away with the hand, as is sometimes the custom, leaving large bare areas.
3. All rents in the peritoneum areas, and particularly those on the anterior abdominal wall, should be accurately sutured.

GENERAL CONSIDERATION OF ADHESIONS TO THE ANTERIOR ABDOMINAL WALL AND THEIR TREATMENT

In the first place, prophylactic measures should be taken : adhesions to the anterior abdominal wall of small or large intestines, or of stomach, which are nearly always of a pernicious type, should never be allowed to take place.

If at an operation it is seen that adhesions are likely to form—and it is difficult, sometimes, to prevent their forming—they should be allowed to occur between the omentum and the anterior abdominal wall. To attain this end, the omentum should always be spread out under the abdominal wound before closing the peritoneum, thus allowing any adhesions which may occur to form in the least harmful position. The adherent omentum will move with the abdominal wall and will not give rise to any unpleasant symptoms. The small intestines lying under the movable omentum, even if they do adhere to it, can move more or less freely. In these circumstances the omental adhesion to the peritoneal wound will be beneficent, and will not cause the pain or nausea which an intestinal adhesion to the rigid scar in the constantly moving abdominal wall would.

Where widespread adhesions to the anterior abdominal wall must be removed, a certain amount of technical subtlety must be exercised. After making the incision and opening the peritoneum,

two or three wound retractors should be inserted into spaces where there are no adhesions (*see Fig. 238*, p. 337). If there are no spaces for these retractors the necessary areas for them must be cleared by dissection, as shown in *Fig. 293*.

The wound retractors inserted into these spaces are locked to the author's operating frame. By raising the frame the assistant can then lift the abdominal wall away from the abdominal contents,

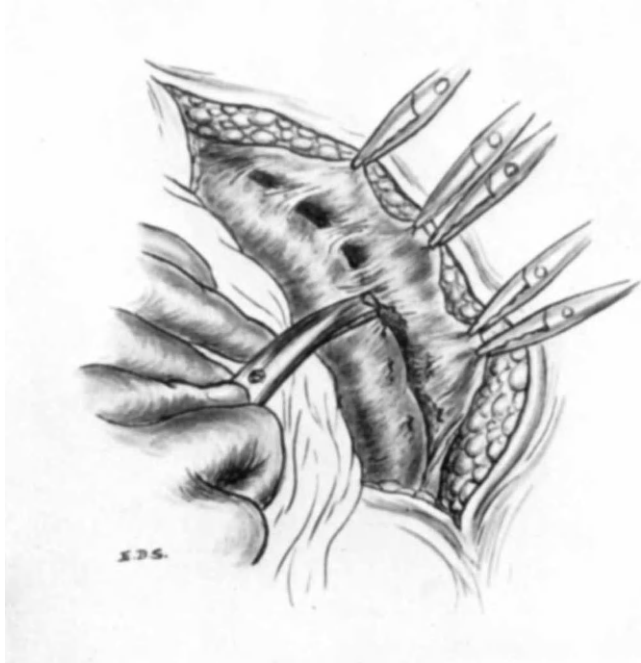


Fig. 293.—Method of clearing small areas of peritoneum from adhesions, in order to insert wound retractors for the further dissection of widespread abdominal adhesions.

so that the adhesions can be 'put on the stretch' by pressing them down with a swab on a holder, or with the scarf-covered hand. They can then be illuminated by throwing the rays from the shadowless artificial light of the operating-room into the temporary cavity made by lifting the abdominal wall away from the intestines, as shown in *Fig. 238*.

Still better illumination can be obtained by putting the patient in certain positions which are appropriate to the situation of the adhesions. For example, if they are in the upper part of the abdomen, the patient can be put in the reversed Trendelenburg

Fig. 294.—Patient placed in Trendelenburg position to enable adhesions of the intestines to the anterior abdominal wall below the incision to be cleanly dissected. It shows the shadowless light adjusted to shine into the cavity made by elevating the lower end of the operating frame.

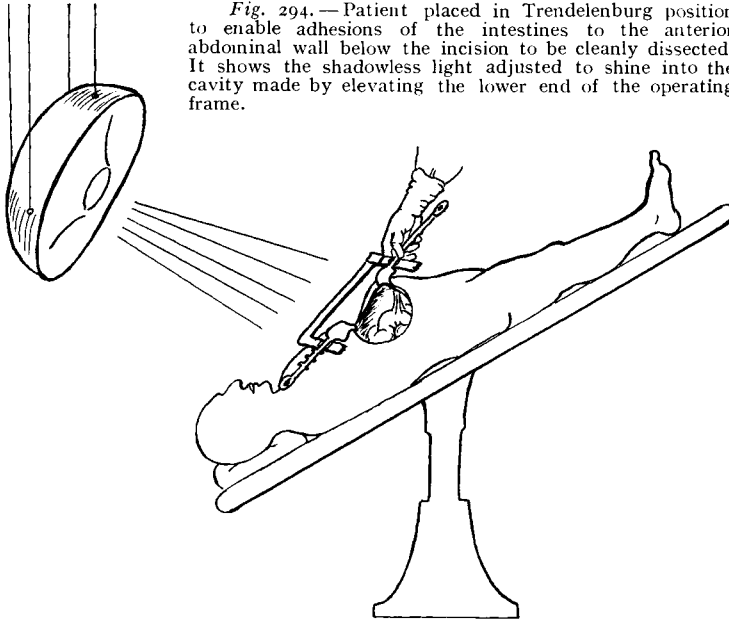
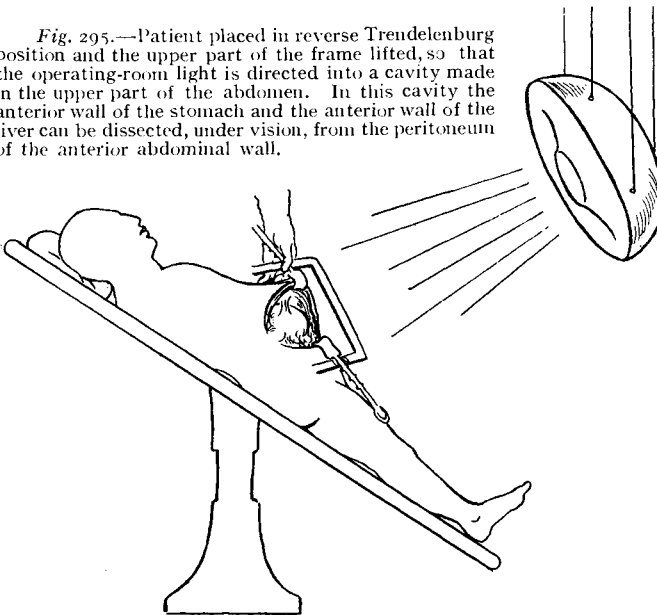


Fig. 295.—Patient placed in reverse Trendelenburg position and the upper part of the frame lifted, so that the operating-room light is directed into a cavity made in the upper part of the abdomen. In this cavity the anterior wall of the stomach and the anterior wall of the liver can be dissected, under vision, from the peritoneum of the anterior abdominal wall.



position; if they are towards the lower part of the abdomen, in the Trendelenburg position; and if they are lateral to the wound, in the lateral position.

In these various positions the adhesions are displayed by lifting the abdominal wall by means of the appropriate side of the operating

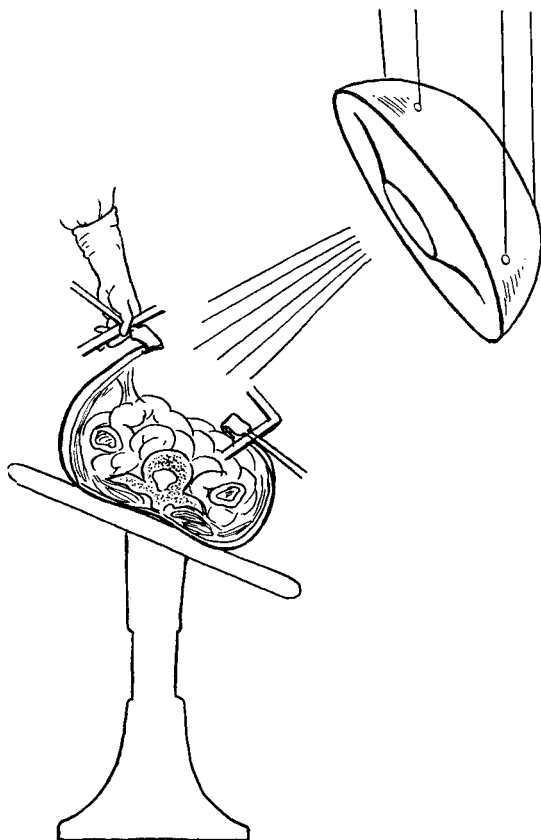


Fig. 296.—Diagrammatic section of the body of a patient on a table laterally tilted in order to direct the operating-room light on to adhesions to the abdominal wall lateral to the wound.

frame; and into the cavity thus made the operating-room light can easily be directed, when the adhesions can be dissected even far out from the edges of the wound—and dissected accurately because the dissection is made in a good light (*Figs. 294–296*).

Where the adhesion is too far out to be illuminated by the deflected rays of the operating-room light, a straight illuminated spoon is used to light up the adhesion. (*See Fig. 240, p. 339.*)

Thus, by the use of the artificial lighting, the operating-frame method described above, and the long-handled spade-pointed dissecting scissors, adhesions can be divided from a midline incision as far out as the lateral parts of the abdomen, as far down as the pelvis, and as far up as the hepatic and gastric areas.

TREATMENT OF PARTICULAR FORMS OF ADHESIONS

Routine Order of Procedure.—In a secondary operation, when dealing with the adhesions which have been caused by the previous operation, the routine order of procedures should generally be: (1)

The separation of omentum adherent to the anterior abdominal wall; (2) The separation of organs adherent to the anterior abdominal wall—the liver, the stomach, the large bowel, the small bowel—not only from the region of the incision, but also from the peritoneum of the anterior abdominal wall far out from the incision; (3) The separation of the loops of bowel from one another; (4) The repair of wounds of the visceral peritoneum thus caused; (5) The repair of wounds of the parietal peritoneum of the anterior abdominal wall.

Adhesions of Omentum to the Anterior Abdominal Wall.—Such adhesions do not, as a rule, cause trouble (*see* p. 393). Complete separation is therefore not always necessary. Disconnexion of omental adhesions from the abdominal wall presents no real operative difficulty. They are separated by the aid of the operating frame and chisel-pointed scissors (*see* p. 393).

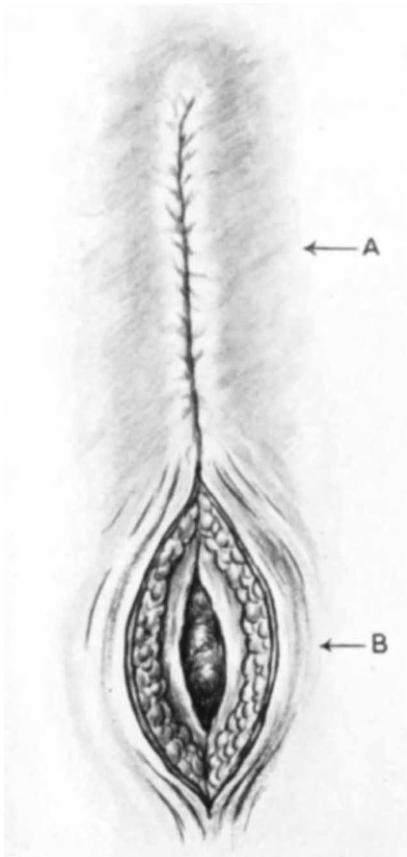


Fig. 297.—Method of opening the abdomen at the lower end of the old scar or at its upper end, so as to enter the peritoneal cavity in a place that is likely to be free from visceral adhesions. A, Old scar; B, Opening in abdominal wall below old scar.

Adhesions of Abdominal Organs not only to the Region of the Incision but also to the Neighbouring Peritoneum.—Very often a segment or several segments of small intestine are firmly united to the abdominal wall by the second type of adhesion—the severe pernicious type without a line of cleavage. They may even be deeply embedded in the scar of the abdominal wall. The anterior wall of the stomach or transverse colon, or the anterior surface of the liver, may also be adherent by this pernicious type of adhesion to the scar in the anterior abdominal wall or its vicinity. Such adhesions are the result of inaccurate coaptation of the peritoneal edges, of interruption of the peritoneal layer by the introduction of a drainage tube, or of the cutting-out of the peritoneal sutures.

In dealing with adhesions of this nature in the thin-walled abdominal hollow organs, the first danger is that the surgeon may, as he makes the incision, unexpectedly wound these organs or open into their lumen when he is incising the peritoneum of the abdominal

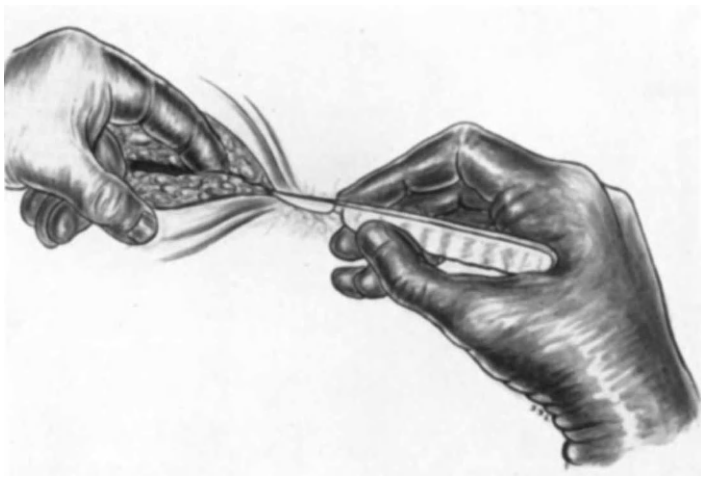

Fig. 298.—Opening the abdomen through an old scar. The finger is introduced through an opening above the scar, and guards any adherent intestine from injury as the scar is divided.

cavity. The way to avoid such a catastrophe is not to open into an abdominal cavity through the old scar, but to enter it by an extension of an incision beyond the original operation scar, either at its upper or at its lower end; that is, to open into the abdomen in as it were 'virgin country', in a spot which is likely to be free from adherent intestine (*Fig. 297*).

Once this small opening is made, the abdominal wall is divided in the line of the scar, and the peritoneum is then opened with a guiding finger in the abdominal cavity, as shown in *Fig. 298*. The operating frame is locked into the wound by inserting two or three wound retractors and fixing them firmly in the frame. The assistant elevates the abdominal wall by lifting the frame, when the intestinal loops hang from the abdominal wall by their adhesions. These are then put on the stretch and divided under sight along their line of cleavage (see *Fig. 238*, p. 337).

If the adhesion is of the pernicious type and if there is no line of cleavage, then the parietal peritoneum must be incised so as to leave a generous margin around the adhesion and this dissected from the abdominal wall along the subperitoneal plane, as shown in *Fig. 299*. The raw surface on the intestine can then be covered by suturing little flaps of parietal peritoneum over it.

In cases of adhesion of the stomach to the anterior abdominal wall some subterfuge is necessary, for the stomach is usually distended with air, and in such circumstances it is difficult to find and follow a line of cleavage. Its air should be aspirated, when it will hang flaccid from the abdominal wall. It can then be grasped firmly with the scarf-covered left hand and drawn downwards, while the abdominal wall is held up by the operating frame. A line of cleavage, or at any rate a plane in the abdominal wall, will then become manifest—a plane which can be followed with the chisel-pointed scissors.

When the liver adheres to the scar, special difficulty is experienced. The anterior surface of the liver may, as a result of previous operations, be adherent to the upper part of the anterior abdominal wall. It may also be adherent in the case of a chronic suppurating, or even a simple, hydatid of the liver.

In these circumstances, the best way to expose the anterior surface of the liver is first to isolate the round ligament, and cut it across between ligatures. The true plane between the serous layer of the liver and the serous layer of the anterior abdominal wall will then be readily found in the neighbourhood of the divided round ligament. Spaces are made for the wound retractors of the operating frame, which is locked into the wound as shown in *Fig. 238*, p. 337. The frame is used to lift the lower part of the thorax away from the anterior surface of the liver. The liver is pushed down with a scarf. Starting where the round ligament was divided, the surgeon finds the line of cleavage between the serous membranes of the liver and that of the anterior abdominal wall, and follows it with a *long*,

spade-pointed dissecting scissors. In this way the whole anterior surface of the adherent liver can be quickly separated. It may, however, be necessary to turn the operating table laterally, so as

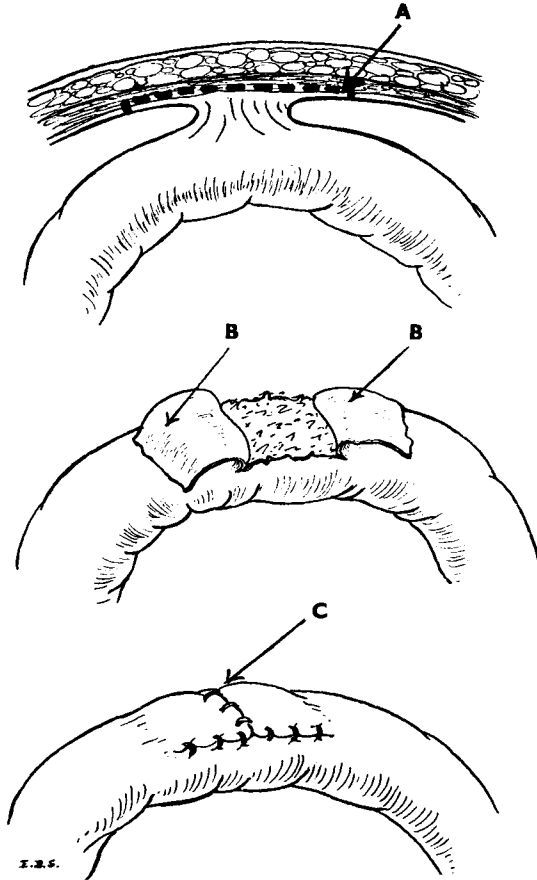


Fig. 299.—A, Dissection of intestine from anterior abdominal wall through the subperitoneal tissue plane; B B, Parietal peritoneal flaps left attached to intestinal loop; C, Suture of parietal flaps over raw area on intestinal loop. The raw area on the peritoneal surface of the abdominal wall is dealt with in the manner illustrated in *Fig. 240*, p. 339.

to throw the light into the lateral parts under the right and left domes of the diaphragm.

Adhesions of Loops of Bowel to One Another.—In separating adherent loops of bowel, the scarf-covered hand of the assistant makes tension on one loop, while the scarf-covered hand of the surgeon makes tension on the other loop, thus making a line

of cleavage which can be accurately followed with the dissecting scissors. *Fig. 300* shows the method.

Adhesions of Small Intestine to the Posterior Abdominal Wall.

—The upper part of the small intestine is found adherent to the posterior abdominal wall in the case of a jejunal ulcer which has occurred as a complication of gastro-enterostomy.

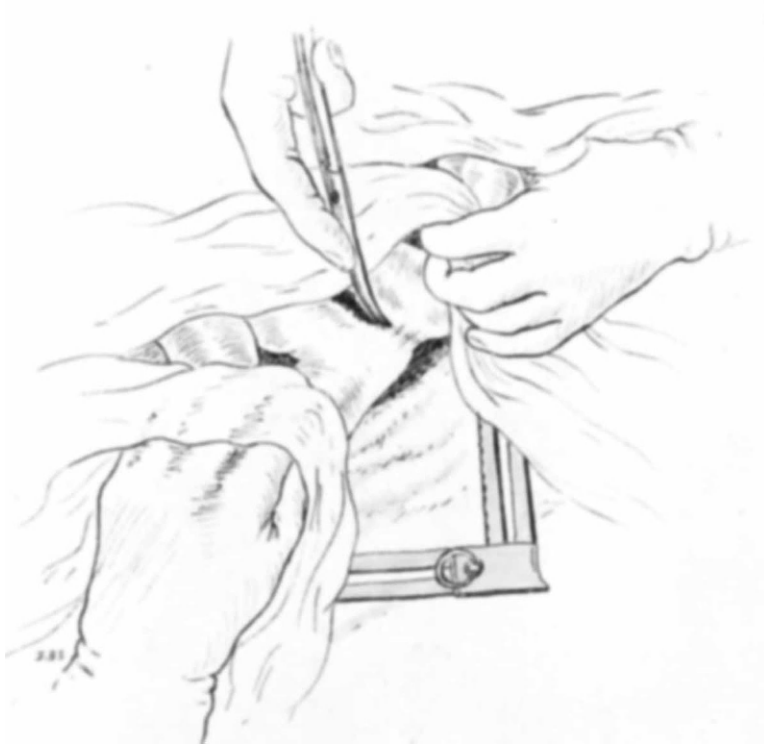

Fig. 300.—Method of dissecting the loops of intestine.

The separation of the adherent intestine from the posterior abdominal wall is a very difficult piece of surgical technique. The adhesion is massive, due to an infiltrating inflammatory process, and the tissue in the vicinity of the adhesion is friable and rigid. There is, however, usually a good line of cleavage if it can be found. The best way to find it is boldly to perforate a point on the margin of the ulcer where it is 'glued' to the abdominal wall. As the ulcer is usually penetrating, this perforation discloses the exact line of cleavage

between the intestinal wall and the peritoneum of the abdominal wall. This line of cleavage—a plane of inflamed tissue—separates easily, and can therefore be followed. Along this plane the ulcer can be readily shelled off the posterior wall with the gloved finger. A continuation

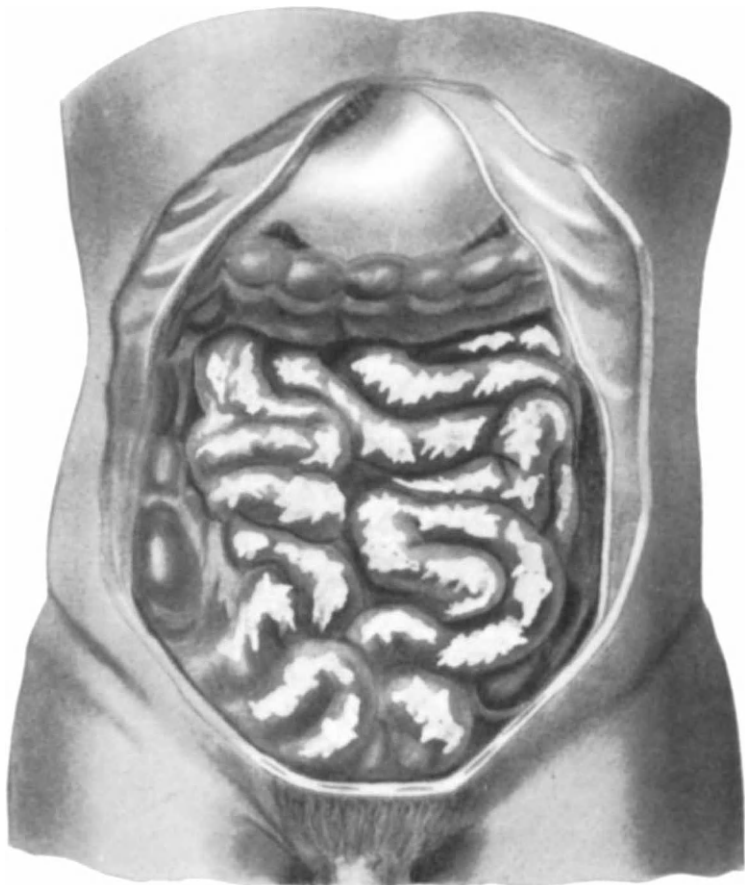


Fig. 301.—The intestines are shown after decapsulation; the white opaque patches on the antiperistaltic section of the gut cannot be stripped off; the dark parts are raw bleeding serosa. (*From the 'British Journal of Surgery'.*)

of this line of cleavage is then followed when separating adjacent adherent loops of bowel from the peritoneum of the posterior wall.

Repair of the Peritoneal Surface of the Anterior Abdominal Wall.—Areas on the anterior abdominal wall denuded of peritoneum should be accurately covered, otherwise loops of small intestine may become adherent to them and chronically obstructed, causing

pain, nausea, and constipation; or string-like adhesions may become attached to them, under which at any time intestinal loops may strangulate.

These bare areas are repaired in the manner described on p. 338.

Adhesions Caused by Encapsulating Chronic Peritonitis.—

This is best exemplified by an actual case,¹ in which an encapsulating chronic peritonitis caused an intestinal obstruction. *Fig. 292* shows the condition found at operation, which was as follows:—

The parietal peritoneum was about 2 mm. thick, and it was found difficult to open into the peritoneal cavity because of the subjacent adherent loops of small bowel and the extensive adhesion of these to one another. The extent of the peritoneal cavity was limited by these adhesions, and it contained a small quantity of straw-coloured fluid. The visceral peritoneum of the liver was uniformly adherent to the parietal peritoneum. The colon was normal. The stomach and the small intestine were almost uniformly covered with an opaque milk-white membrane 2 to 3 mm. thick, which here and there became thickened into cartilaginous plaques. The membrane had encapsulated groups of small intestinal loops into three smooth ovoid tumours, and the adhesions in the upper one, made up of jejunum, had caused an intestinal obstruction, for the segment of jejunum entering it was hugely dilated.

The obstruction and adhesions were dealt with as follows: After some prospecting, it was found that the encapsulating membrane was firmly adherent to the mesentery and to the antimesenteric border of the bowel, and comparatively loosely adherent where the peritoneum was reflected on to the bowel. At this spot was found a line of cleavage which could be followed when the membrane was incised; and by following this plane and using a process of peeling, dissecting, and unravelling, the intestines were liberated.

When this was done, the whole of the intestine presented the appearance shown in *Fig. 301*. The raised white plaques are the places where the membrane could not be separated from the intestine. The dark parts are red, bleeding surfaces of intestine, which is altered serosa because this false membrane is superimposed on the serous membrane. The patient got well and has remained so for more than ten years.

REFERENCE

- ¹ DEVINE, H. B., "The Surgery of Encapsulating Chronic Peritonitis", *Brit. Jour. Surg.*, 1932, **20**, 204.

CHAPTER XLI
TUMOURS OF THE ABDOMINAL WALL

Phantom Tumour.—The following case-record is an example of a condition which has by some writers been described as phantom tumour :—

A patient complained that she had a large round swelling in the middle of the upper part of her abdomen. When examined, a large definite swelling could be felt. It was tense, rounded, and on percussion somewhat dull, and extended from the umbilicus to the epigastric angle. It had all the outward appearances of a large hydatid cyst. It was examined and

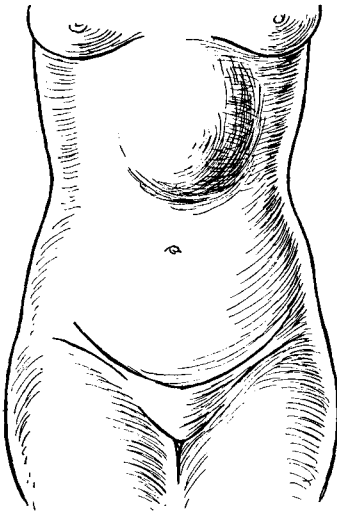


Fig. 302.—Diagram to show the position of a phantom tumour caused by bulging of the upper part of the rectus following a boardlike rigid contraction of the lower parts of the abdominal muscles.

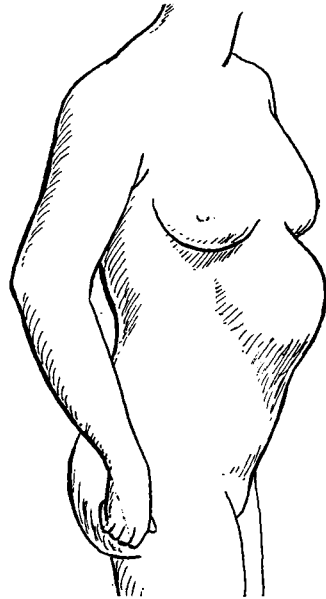


Fig. 303.—Side view of phantom tumour.

percussed out by many medical men at a clinical meeting, and no suspicion arose in their minds that it was not a large hydatid tumour. It had been present for eighteen months. Under an anæsthetic the tumour disappeared. This tumour was caused by intense contraction of the lower parts of the abdominal muscles, which were boardlike in their rigidity. The intense spasm of these muscles, which apparently have the greatest tone and power

in their middle and lower parts, forced the abdominal contents into the upper part of the abdomen, with the result that they tensely bulged forward the upper and weaker part of the recti muscles and the abdominal wall, giving the effect of a large abdominal tumour. *Figs. 302 and 303* show diagrammatically the appearance of the tumour.

Epigastric Hernia.—A deficiency in the midline of the upper part of the anterior abdominal wall is not uncommon. Through this deficiency subperitoneal fat prolapses, and gives the impression of a lipoma. Occasionally these epigastric herniæ become big enough, especially in old people, to allow a herniation of the intestines; and in such cases strangulation of the omentum or bowel may occur, as in the following case-history:—

The patient presented himself for examination because he had a good deal of pain in the epigastrium, and because his medical attendant could feel a hard firm lump in this situation. The patient had been ill, and was in bad health. His doctor had made a diagnosis of carcinoma of the stomach. Examination revealed the fact that the patient had an epigastric hernia, and that a piece of omentum had become strangulated in it, forming a hard firm epigastric tumour, which had been mistaken for a growth of the stomach.

Sometimes an epigastric hernia will come under observation, after it has been present for years, because some change takes place in it:—

A patient complained that a lump which he had always had in his epigastrium, and which had always been insensitive to touch, had developed some tenderness. He also said that he thought he felt a small lump in it. On examination a small hard lump was found in the hernia, and subsequent examination showed that this was a malignant nodule.

The first sign manifested by a malignant abdominal condition was this hard firm lump arising in an epigastric hernia.

Tumour in the Scar of an Abdominal Wound.—Sometimes a firm smooth round cystic tumour is found in the scar of an abdominal wound. It may feel and appear like a sarcoma. The history of the patient, however, will show that he has been operated on for a hydatid. The tumour is probably a hydatid infestation of the abdominal wound which occurred as the result of contamination of the wound during an operation for a hydatid of the liver or of the abdominal cavity.

Desmoids are not infrequently found in the scar of an abdominal wound. They are not encapsulated, and spread in an irregular fashion along the tissue planes. They are very hard and feel like a fibrosarcoma. They tend to recur when they are removed, but any recurrence is, as a rule, controlled by the application of radium.

Tumours of the Umbilicus.—Hard nodules are not infrequently felt in the umbilicus. As a rule, these arise from a lymphatic spread of an intra-abdominal malignant condition. Sometimes they are the first sign of intra-abdominal carcinoma. A slight prominence of the umbilicus, due to œdema, may precede a subumbilical and impalpable malignant infiltration. An endometrioma, which bleeds periodically, is occasionally seen.

Hæmatoma of the Rectus Muscle.—In old people a tumour may be found in the rectus muscle. This is not infrequently a hæmatoma which has developed almost painlessly after a slight injury to the friable rectus muscle of the old. It is sometimes difficult to distinguish from sarcoma.

Hydatid of the Abdominal Wall.—A hydatid may be found in the substance of the abdominal wall, particularly in the subperitoneal layer. When it is situated in this layer it appears to the palpating hand to be in the abdominal cavity itself, and as it is smooth and round, and so tense that it feels solid, it is easily mistaken for a sarcoma or even for a carcinoma.

Most of the other tumours that can occur in the abdominal wall present little difficulty in their recognition and treatment.

CHAPTER XLII

THE SURGICAL TREATMENT OF REFLEX DYSPEPSIA

IN the case of an operation for a reflex dyspepsia, the incision should be a right paramedian one (*see* p. 475).

An examination of the abdominal contents is then made. Radiographically obvious disease of the stomach having been excluded by an X-ray examination, the surgeon will leave the examination of this organ to the last, because he is most likely to find the cause of the dyspepsia in some other part of the abdomen. The following organs are in turn examined: (1) The gall-bladder, its ducts, and the pancreas; (2) The appendix; (3) The renal pelvo-ureteral junction and the renal pelvis; (4) The small and large intestines; (5) The abdominal lymph-glands; (6) The uterus; and (7) The stomach and duodenum.

1. THE GALL-BLADDER AND THE PANCREAS

The Gall-bladder.—In operations undertaken for the cure of a dyspepsia which is regarded as being reflexly caused, the first abdominal organ to be examined will be the gall-bladder.

Attention may have been focused on the gall-bladder because the patient has suffered from a dyspeptic syndrome definitely indicative of gall-bladder disease, and because cholecystography shows a 'negative' cholecystogram—that is, shows no gall-bladder shadow. Or, suspicion of gall-bladder disease may have arisen because the patient has complained of a dyspeptic syndrome only indefinitely suggestive of cholecystic dyspepsia, but cholecystography gives a 'negative' cholecystogram.

In the former case there will, as a rule, be no doubt about the diagnosis at the operation. Gall-stones or cholecystitis will usually be found, and the gall-bladder will be removed.

In the latter case, however, there may be considerable difficulty in making an operative diagnosis. No gall-stones may be found. There may be no adhesions round the gall-bladder to indicate that it has been the subject of a previous inflammation. The gall-bladder may appear to be healthy. In this case, the surgeon will be in doubt whether to trust the negative cholecystogram and remove the

gall-bladder, perhaps needlessly; or not to disturb it and perhaps leave a diseased gall-bladder in which a low-grade chronic cholecystitis is not obvious. He must therefore intimately examine the gall-bladder and also the liver in order to discover the cause of the negative cholecystogram or of the dyspepsia.

The following questions will arise: (a) Is a diseased liver the cause of the negative cholecystogram and the dyspepsia only the result of a functional disturbance of the stomach? (b) Is a lesion of the gall-bladder or of the cystic duct which is not macroscopically obvious responsible for both the dyspepsia and the negative cholecystogram? (c) Is early disease of the common duct the cause?

a. Disease of the Liver.—A negative cholecystogram is frequently seen in disease of the liver. In this case the liver may present some evidence of disease. It may show fibrosis, atrophy, irregularities of its surface, or opacities of its serous covering—evidence of cirrhosis or of syphilis. Or it may exhibit enlargement and thickened edges, an indication of venous congestion from an early stage of cardiac disease or some form of hepatitis. An enlargement of the spleen, if present, strengthens any suspicion of obscure affection of the liver.

b. Lesion of the Cystic Duct or of the Gall-bladder not Obvious Macroscopically.—

The cystic duct: The surgeon must see if the cystic duct is patent: he must make pressure on the gall-bladder to see if it will empty. He must draw off some of the bile and see whether it is normal in colour, or whether it is dark and contains mostly biliverdin—evidence of stale bile, and therefore of obstruction of the cystic duct. If the patency of the cystic duct is inadequate or the bile is stale and thick, it is advisable to remove the gall-bladder.

The gall-bladder: The surgeon must examine the lymphatic gland which lies in the vicinity of the cystic duct and the gall-bladder itself. If the gland shows signs of enlargement it indicates inflammatory disease in the gall-bladder. If the wall of the gall-bladder is thicker and more opaque than normal, if its fatty subserous layer is thicker than usual, if there is any injection of the small vessels, if there are any adhesions to the ampulla or the fundus, or if the subserous layer is adherent—then all or any of these signs afford evidence of disease of the gall-bladder wall.

If there is doubt as to whether the gall-bladder is diseased or not, it is better to remove the organ, because, in the absence of obvious disease of the liver, a negative cholecystogram is sometimes better evidence of disease of the gall-bladder than a macroscopical examination.

3. *Early Disease of the Common Duct.*—If no disease of the cystic duct or gall-bladder is found, the common duct should be examined.

An early affection of the common duct can produce a variable dyspeptic syndrome and one like that arising from disease of the gall-bladder; and it can also give a negative cholecystogram. An irregular stone in the common duct may not cause jaundice; but may cause pain from one and a half to two and a half hours after meals—pain just like the pain caused by stone in the gall-bladder; and it can produce a negative cholecystogram. Thus a stone in this situation, which may be easily overlooked, may cause a painful dyspepsia.

Again, the early stage of a carcinoma beginning in the ampulla of Vater or in the common duct itself can cause a painful dyspeptic syndrome like that of the gall-bladder and show no gall-bladder shadow when cholecystographed. Generally, however, it causes a jaundice fairly early, but before this occurs the patient may present himself with a typical gall-bladder syndrome. I have seen such a small growth overlooked and the gall-bladder removed in the belief that it was the cause of the painful dyspeptic syndrome (*see p. 738*).

It must not be forgotten that a negative cholecystogram may be caused by systemic disease, or by the general effects of local disease (*see p. 672*).

The Pancreas.—The pancreas should now be examined to find out if it is the subject of chronic pancreatitis. It should also be palpated to see whether there is a scirrhous carcinoma of the body—a growth that is sometimes not very obvious. Carcinoma of this type can give rise to great pain, which bears rather an indefinite relation to meals—a pain which may be mistaken for the pain of gall-stone disease or duodenal ulcer (*see p. 83*.)

2. THE APPENDIX

Whether or not the appendix is the cause of the dyspepsia is unimportant, except from the point of view of verifying the diagnosis. If the abdomen is opened for the surgical treatment of reflex dyspepsia the appendix will be removed as a routine. This can be done in the manner described in Chapter XLV—the appendix is found through the incision in the upper part of the abdomen, and pushed through a small stab incision in the region of the right iliac fossa (*see Fig. 312, p. 438*).

It is, however, very important to be quite sure that there is no kinking or constriction of the terminal ileum caused by any appendiceal disease. If there is, it may be necessary to make a small split-muscle incision over the appendiceal area in order to deal with this.

3. INCOMPLETE RENAL PELVO-URETERAL OBSTRUCTION

A painful dyspepsia-like syndrome closely related to meals may be due to incomplete renal obstruction caused by a small stone at the pelvo-ureteral junction. The increase in the fluid intake at meals and the consequent increased urinary excretion probably causes the dyspepsia-like picture. If this is suspected, it may be necessary to explore the kidney from the abdominal cavity.

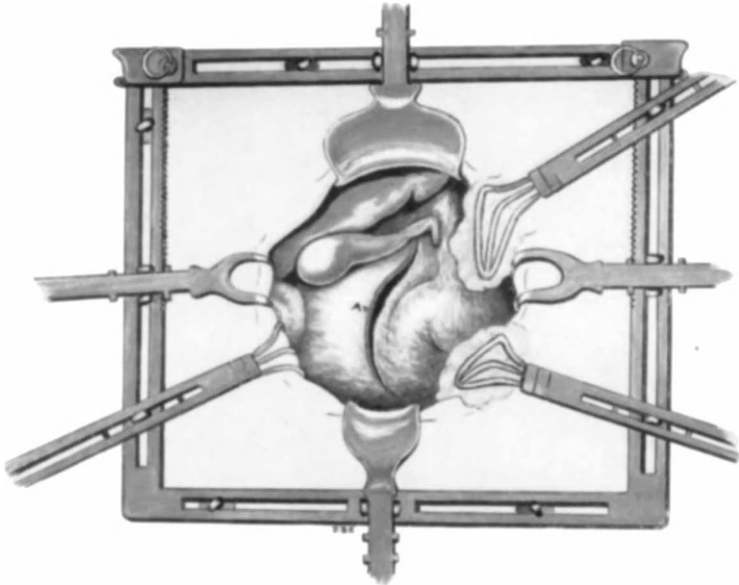


Fig. 304.—The operation field set with the operating frame in position, and the mechanical hands holding the stomach, duodenum, and colon out of the operation area. An incision (A) is made along the outer side of the duodenum, and continued upwards for $1\frac{1}{2}$ in. or more.

This is carried out in the following way: The operation field is set with the operating frame, the mechanical hands arranged in the same way as if the gall-bladder were to be exposed (*see p. 341*). An incision (*Fig. 304, A*) is then made along the outer side of the duodenum as if that organ were about to be mobilized. This peritoneal incision is continued upwards for $1\frac{1}{2}$ in. or more. The outer leaf of the peritoneum is then peeled back and the kidney displayed. As the pedicle of the kidney arises from the aorta and the vena cava, it is surprising to see how easily the kidney can be drawn forward and, with the pelvis and the upper part of the ureter, completely exposed for examination (*Fig. 305*).

The kidney and its pelvis should be examined. If necessary, the pelvis is opened and explored. If a small stone is found it can be removed (*Fig. 305*, inset), and the pelvis closed by sutures and covered with a fatty fascial flap. A small stab is made through the muscles of the back and through this a drainage tube is passed.

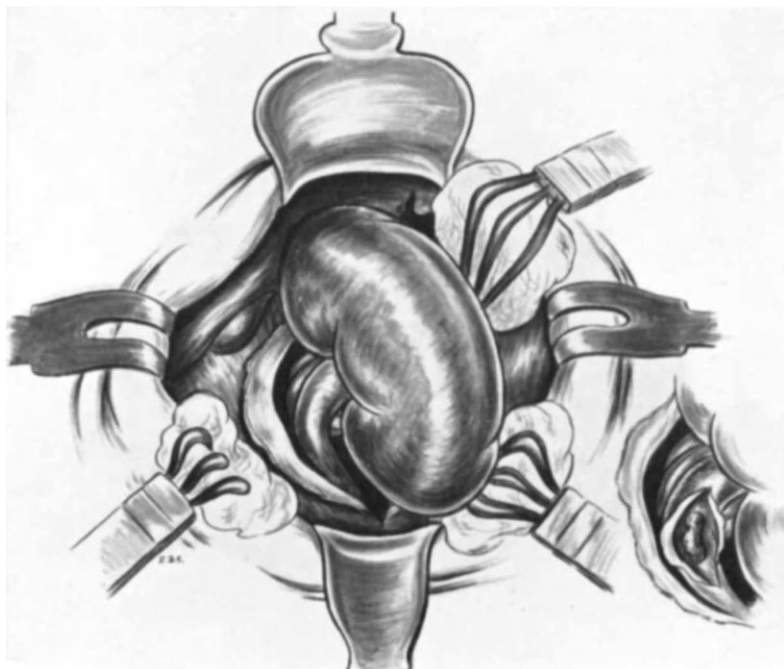


Fig. 305.—The outer leaf of the peritoneum is peeled back and the kidney is drawn forward with the pelvis of the kidney and upper part of the ureter exposed for examination. The inset shows the ureter opened and a stone exposed.

The kidney is then replaced and the peritoneum closed over it. The drainage tube which leads through the stab wound to the surface acts as a safety-valve through which any urinary secretions that may leak through the sutured pelvis can pass.

4. THE SMALL AND LARGE INTESTINES

The abdominal cavity will now be examined for any adhesion of the small and large intestine or for any evidence of chronic obstruction.

The treatment for adhesions has already been described.

The surgical treatment for chronic obstruction of the small or large bowel is, of course, a serious operation, and is dealt with in other sections.

5. THE ABDOMINAL LYMPH-GLANDS

The lymph-glands should be examined for evidence of ordinary inflammation (Chapter LXXIX) or tuberculous infection (p. 87), for it is not uncommon for these glands to give rise to a painless or a painful dyspeptic syndrome.

The treatment, of course, is non-operative—ultra-violet light and measures to increase the patient's general resistance.

6. THE UTERUS

The uterus should be examined for enlargements, or for a retroversion, both of which may be causing interference with the emptying of the sigmoid.

7. THE STOMACH AND DUODENUM

If, now, no reflex cause for the dyspepsia has been found, the question arises whether it is not really caused by disease of the stomach itself other than radiographically obvious chronic peptic ulcer of the stomach or duodenum or gastric carcinoma, which, of course, have been excluded in the X-ray examination.

Radiographically Unobvious Peptic Ulcer.—Small ulcers on the *Magenstrasse*, small ulcers in the duodenum, chronic ulcer of its posterior wall, or ulcer on the pyloric orifice—none of which are easy to demonstrate by X rays—must be looked for. It may be necessary to open the stomach to inspect its mucous membrane or to pass the bare finger through the opening in the stomach (*see Fig. 309*), through the pylorus, in order to examine the duodenum. If a small ulcer is found, it does not necessarily require an operation. Such small ulcers may be safely left to the care of the physician. But even if some of these lesions do not need an operation, the surgeon must identify them; for after an operation for a supposed reflex dyspepsia, he must be able to say either that he has removed the cause of the dyspepsia, or, if he has not removed it, that he knows what the cause actually is. This latter information is essential to the physician as a guide in his future treatment.

Radiographically Unobvious Carcinoma.—An obscure malignant lesion may be the cause of the dyspepsia (*see p. 268*).

Antral Gastritis or Duodenitis.—Antral gastritis will be recognized by certain features. The gastric wall is thickened, the vessels are injected. If the stomach is opened, the mucous membrane will be found to be hypertrophied, the folds being thicker and larger than normal; patches of atrophy may be seen; erosions and even small ulcers may be found. A small piece of the mucous membrane

should be removed for microscopical examination; but it must be put at once into 2 per cent formalin, otherwise the microscopical examination is worthless. In some cases of antral gastritis a partial gastrectomy may be necessary, but such a method of surgical treatment is rarely required.

Ileus of the Stomach or Duodenum.—Ileus of the proximal part of the stomach, of the whole stomach, or of the duodenum, is also a cause of dyspepsia, but not as a rule of a painful dyspepsia of the surgical type.

Ileus of the duodenum now and again gives rise to a certain amount of pain coming on from two to three hours after food, and causes a diffuse tenderness over the duodenum. It will be very obvious if it is present.

Ileus of the stomach may not be so obvious, because as a rule the stomach fills with air while an abdominal operation takes place.

In neither of these conditions should any operation be performed under any circumstances.

Occasionally an ileus of the duodenum may be due to mechanical obstruction, and in this case the obstruction should be removed, or, if it is irremovable, a duodeno-jejunostomy carried out.

Diverticula of the Duodenum or of the Jejunum.—Diverticula of the duodenum or the upper part of the jejunum may be the cause of a surgical dyspepsia.

Duodenal diverticula are discussed on p. 173.

A case of jejunal diverticulum is recorded on p. 193 (*see Fig. 117*). In this case pain occurred about an hour after food, when the food reached the jejunum; and there was an exquisitely tender spot which corresponded to a large jejunal diverticulum.

Painful Neuromuscular Disease of the Stomach Itself: Functional Dyspepsia.—It should be noted whether the stomach is one of those whose normal posture is that of the exaggerated emptying type—a posture which is found in the sthenic, or in nervous young men. This type of stomach gives rise to a painful dyspepsia caused by an intrinsic disturbance of the neuromuscular mechanism of the stomach, and to a type of dyspepsia which is clinically indistinguishable from that of the painful dyspepsia of reflex origin.

If the stomach is one of those whose normal posture is that of the exaggerated filling type, which is found in the asthenic, or in nervous women, it can be taken for granted that it is not the cause of a reflex dyspepsia, for it gives rise to a painless dyspepsia unlike that of reflex origin. This type of stomach is dilated, thin-walled, U-shaped, low, and full of air.

Hypertrophy of the Pyloric Sphincter.—Last of all, the sphincter of the pylorus must be examined. On many occasions I have found that a dyspepsia—not always, however, of the painful type—has been caused by a disturbance in the contraction of a highly hypertrophied pyloric sphincter and of the sympathetically innervated muscle fibres in the vicinity of the sphincter. These cases have come under notice because a most persistent prepyloric filling defect has been present which has been regarded by the radiologist as that of gastric carcinoma.

The following history is an example of this type of case :—

A man, aged 39, had been ill for six months. He complained of pain in the right side just above the umbilicus. It came on rather suddenly, and was associated with nausea. There was no tender spot when these attacks came on. The doctor who saw him said he had “gall-stone trouble”. He had several attacks, lasting sometimes a couple of days, sometimes ten days. He was only tender in some of these attacks. He also had bad attacks of indigestion—discomfort after meals with epigastric pain, no matter what the diet was—all coming on within an hour after food. The pain and the attacks of indigestion came together. His general health was good. The maximum tender spot was over his gall-bladder as the liver came down. He had one attack of pain on the left side and this was very severe. He was also constipated. *Fig. 189* (p. 278) is a radiograph showing the persistent prepyloric filling defect which was present in this case, and which was regarded by the radiographer as being caused by a prepyloric carcinoma. At operation, a very enlarged hypertrophied sphincter with spasm, probably of the sympathetically innervated prepyloric muscle fibres, was found to be the cause of this persistent filling defect.

Another case-history exemplifying this condition is given on p. 280.

Dilatation of the Pyloric Sphincter in supposed Reflex Dyspepsia.—On the principle that dilatation of the cardiac sphincter has given relief in bad cases of so-called cardiospasm, the author has not hesitated, in some cases of severe dyspepsia where no surgical cause could be found, to open the stomach and dilate the pyloric sphincter with two or three fingers. In many instances this simple procedure has given good results in those dyspepsias where an over-development of the pyloric and prepyloric musculature has probably played a part in their causation.

*CHAPTER XLIII***PRINCIPLES UNDERLYING THE TREATMENT
OF PEPTIC ULCER**

THE principles underlying the treatment of peptic ulcer vary according to its situation ; to whether it is duodenal or gastric ; to its degree of chronicity ; and to the presence of complications.

**THE QUESTION OF MEDICAL OR SURGICAL
TREATMENT**

In regard to the medical treatment of chronic peptic ulcer, there is always a most important preliminary consideration, and that is to be sure that the condition to be medically treated is really an innocent peptic ulcer and not a malignant growth : there should be accuracy in the diagnosis. Of recent years, since medical treatment of peptic ulcer has become 'fashionable', I have seen a number of cases of gastric cancer treated as gastric ulcer, until the lapse of time showed the true nature of the case. Certain forms of gastric cancer can give a painful dyspepsia clinically indistinguishable from that of gastric or duodenal ulcer ; and in some of these cases, even an expert radiologist may not be able to demonstrate a "filling defect" characteristic of carcinoma, for they are often of a plaque-like type, and produce only a sharp-edged deformation in the barium-filled stomach exactly like that of the spasm sometimes caused by a chronic ulcer. It is such a type of carcinoma that misleads both the physician and the radiologist, so that it is frequently diagnosed as peptic ulcer and—what is worse—treated as peptic ulcer.

In cases of both acute and subacute gastric and duodenal ulcer, the treatment will always be medical, even if these ulcers bleed.

In chronic gastric or duodenal ulcer with which are associated no definite ulcer diathesis and no secondary fibrotic changes, medical treatment gives every prospect of permanent cure. Here the ulcer may have originated as a result of some transitory vitality deficiency of the gastroduodenal wall, and have been prevented from healing by the action of acidity, gastric motility, and food irritation—factors which can be minimized by medical treatment.

But in chronic gastric or duodenal ulcer with which is associated a definite, perhaps causative, diathesis, although temporary cures may be obtained under medical treatment, a permanent cure cannot be expected; for medical treatment cannot permanently modify the inherent causative factors. For instance, the duodenal ulcer associated with a high acidity and a very quick emptying time will keep recurring after being 'medically cured', because the muscular stomach and the high acidity are the causative factors, and cannot be permanently removed by medical treatment. Such a type of ulcer, if very chronic, generally requires surgical treatment.

In the case of a gastric ulcer which is old and very chronic, and which is accompanied by secondary fibrotic changes, there is much danger in continued medical treatment. There is the danger of death from an intercurrent affection resulting from ill-health caused by the effects of the ulcer; there are the dangers of bleeding, of perforation, and of malignant degeneration. Such an ulcer, too, has very little chance of healing naturally, especially if it is complicated with a stenosed and therefore crippled stomach. In this type of peptic ulcer medical treatment should not be considered, for surgical treatment offers a permanent cure—removal of the ulcer and its causes—with a low mortality-rate.

Although in the case of duodenal ulcer associated with a diathesis, with penetration, or with secondary fibrotic changes, medical treatment does not offer much prospect of permanent cure, it should be remembered that surgical treatment is not so successful and satisfactory as it is in chronic gastric ulcer in similar circumstances. Simple operations like gastro-enterostomy are not very effective, for they may not cure the very chronic ulcer and often give rise to jejunal ulcer. Severe operations like partial gastrectomy and duodenectomy, though usually attended with a prospect of permanent cure, are formidable, have a relatively high mortality-rate, and are occasionally followed by unpleasant after-effects, such as nausea and vomiting. Thus it is for reasons such as these that even in the chronic type of duodenal ulcer medical treatment may be justified, especially since there is little danger of malignant degeneration.

Thus the question of medical treatment of peptic ulcer depends upon: (1) the factors in its causation; (2) the type and situation of the ulcer; (3) its response to treatment; and (4) the presence of secondary complicating conditions.

A time may, however, come when a peptic ulcer will not respond even to the most faithful medical treatment; when for economic reasons the patient can no longer continue with medical treatment;

when, as a result of secondary stenotic changes, nutritional disturbances begin to take place; or when the fear of cancerous degeneration arises. In these circumstances the question of surgical treatment has to be considered.

PRINCIPLES UNDERLYING THE SURGICAL TREATMENT OF DUODENAL ULCER

Before surgery can be considered as a treatment for duodenal ulcer, the ulcer should be so well established that it is capable of being definitely demonstrated by X-ray methods—the *Nische* should be clearly visible.

When the ulcer has been demonstrated by X rays, certain practical questions arise. Has it had medical treatment? Is it the type of ulcer that prolonged modern efficient medical treatment would cure? And do the dangers of perforation and hæmorrhage, and the extent of any complications, contra-indicate this further medical treatment? The presence of complications such as stenosis or penetration of the pancreas, or repeated hæmorrhages, are urgent reasons for surgical as against further medical treatment.

If it is decided that the ulcer should be treated surgically, the problem is: Will gastro-enterostomy, an operation which is not very dangerous, cure it? Or will a more dangerous operation, such as a partial gastrectomy and duodenectomy, a partial gastric exclusion, or a partial gastric exclusion with resection, be necessary in order to obtain a permanent cure?

The principles that determine the surgical treatment of duodenal ulcer should be based on its causation. This, as we have seen in Chapter XI, has not been definitely established. If we regard duodenal ulcer as originating through some deficient vitality in the gastric wall, accepting the infarction theory, then the operation of gastro-enterostomy, which reduces the acidity somewhat, and rests the ulcer by draining the stomach, should be the proper operation for the treatment of duodenal ulcer. On the other hand, if we agree with the theory of the peptic genesis of ulcer, a gastro-enterostomy, which does not materially reduce the gastric acidity, would be based on unsound principles; and some other operation, such as extensive partial gastrectomy or exclusion—operations which materially reduce the acidity—should be employed.

As a matter of fact, gastro-enterostomy can no longer be regarded as the routine operation for the surgical treatment of duodenal ulcer, for we now know that it is not uniformly successful. As experiences have accumulated, surgeons have become dissatisfied with its remote

results. In some cases, it gives brilliant results; in others, for no reason that is obvious, bad results: its therapeutic effects are uncertain.

My own experiences in regard to the value of gastro-enterostomy in duodenal ulcer are interesting. When I reviewed the case-histories of those patients on whom, over the last twenty-five years, I have performed gastro-enterostomies, I was able to make the following broad generalizations.

While the majority of my cases of gastro-enterostomy gave good results, a considerable number of them were unsatisfactory. In some cases the patients complained that the duodenal ulcer pain had disappeared, but that after every meal they suffered from such bad "sinking sensations" and such distressing sickness that their life was unbearable. In other cases the patients would say that they had been well for some years, but then all their old ulcer-pains had returned. It was obvious that the old ulcer had recurred or jejunal ulcer had formed.

Leaving out of consideration those gastro-enterostomies which were unsuccessful because the operation was followed by nausea and vomiting, etc. (probably due to faulty technique), there was one group in which the operation was successful and had relieved the patients of their painful ulcer symptoms; and another group in which it had not—a group in which the original ulcer was not cured, or in which the operation had been followed by a fresh ulcer—a jejunal ulcer.

It was interesting also to see that there were two very different types of individuals in whom duodenal ulcer had developed.

There was a group in which the individual was not very sthenic. The patients in this group were often sick-looking, thin types of overworked men. It contained also the women patients who had developed duodenal ulcer. In most cases, little disturbance of the emptying time was found. On an average the gastric acidity was not specially high.

There was another group which seemed to separate itself naturally and which was obviously composed of the sthenic type of individuals. In it was the man who developed duodenal ulcer in full health. In most cases a high acidity was found in combination with a muscular stomach. In this group were patients in whom digestive processes—peptic influences—seemed to be working to high capacity.

In these two groups of cases the response to the therapy of a gastro-enterostomy was most illuminating. In the first group gastro-enterostomy was a successful operation and more or less cured the

patients. In the second it was not a successful operation : some of the patients remained uncured, and in others jejunal ulcers developed.

I should regard the ulcers in the first group as having formed more on the lines of the infarction theory (*see* p. 105)—on a deficient vitality basis ; and I should look upon the ulcers in the second group as having a more solely peptic genesis.

As a result of these considerations, I think that in studying the principles on which the surgical treatment of duodenal ulcer should be based, the view must be taken (formed on clinical grounds) that there is more than one factor in the causation of duodenal ulcer. There are perhaps two main factors : variations in the vitality of the gastric wall ; and disturbances in the gastric juice or of the digestive process. And furthermore, I think it is probable that these factors can vary, one to the other, in their degree of causation, although they may give much the same macroscopic type of duodenal ulcer. It would thus seem that, as a principle of treatment, cognizance should be taken of the dominance of one or other of these aetiological factors, and the operation chosen accordingly.

It will thus be seen that in the carefully selected cases of duodenal ulcer gastro-enterostomy may be most efficient surgical treatment. On the other hand, it will be evident that where it is performed in cases for which it is unsuitable it becomes a surgical catastrophe and brings far more misery to the patient than ever his original disease could.

As a result of such clinical experience my views concerning the causation of duodenal ulcer—views which serve me as a working hypothesis and guide me in operative treatment—are as follows :—

That from the point of view of operative treatment there are two diverse types of duodenal ulcer : one which I call the ' infective ', and another which I term the ' acidic ' type.

The infective type originates as the result of a local or general loss of tissue vitality, generally of infective or circulatory origin, and in the presence of gastric juice of perhaps normal acidity, the continued action of which perpetuates it as a chronic ulcer. The acute ulcer represents the extreme of this type, when a deficient vitality of the duodenal wall is almost the whole factor.

The acidic type of ulcer arises in a person whose gastric tissue is of normal vitality. It is the result of the propulsion of gastric juice of high acidity against the duodenal wall by a powerful quick-emptying stomach ; and in some cases of very chronic excavating ulcers in healthy people this high acidic action is almost the whole factor.

If an ulcer is of the infective rather than the acidic type, I use a gastro-enterostomy. If it is more of the acidic type, however, I employ operations like partial gastrectomy or partial gastric exclusion.

The views of other surgeons concerning the efficacy of gastro-enterostomy are important in regard to rather fixed ideas about the value of this operation. The changing point of view in regard to the surgical therapy of duodenal ulcer is seen in the practice of Continental surgeons. In 1922, on the Continent, gastro-enterostomy was the operation of choice. In 1932 gastro-enterostomy had been almost entirely abandoned for partial duodenectomy combined with partial gastrectomy, because the results of gastro-enterostomy were so unsatisfactory; and in many large German clinics it is performed now in only 10 per cent of cases. In English-speaking countries, gastro-enterostomy, though not so frequently employed, is still the operation of choice, and for it a high percentage of cures is claimed.

The British schools are more inclined to believe that chronic duodenal ulcer arises from acute ulcer of infective origin, and that a deficient vitality is a necessary precedent factor in its formation. In this conception, then, we have the basis of the attitude of a proportion of the British schools towards the treatment of duodenal ulcer, in contrast to that of the Continental school. Its attitude is one of conservatism—either medical treatment, or the more conservative form of surgical treatment, gastro-enterostomy. There are, however, many surgeons in England, America, and Australia who are beginning to employ partial gastrectomy and duodenectomy, or at any rate a fairly radical operation, instead of gastro-enterostomy. But most English-speaking surgeons do not favour, as a routine operation, the very radical method of the Continental surgeon—the use of partial gastrectomy and duodenectomy for duodenal ulcer—an operation designed to reduce the gastric acidity profoundly.

It is not unlikely that the higher percentage of gastro-enterostomy cures in our country is owing to the fact that, in our peoples, chronic ulcer originates more on an infective than on a peptic basis—perhaps a question of diet or dietetic habits; and that this type of chronic ulcer is more amenable to treatment by gastro-enterostomy. It is also not improbable that gastro-enterostomy has been employed with us for many cases of the less severe type of duodenal ulcer—that is, for cases which could have been just as effectively dealt with by improved medical treatment; and that our percentage of cures is for this reason high.

My own experiences in regard to the surgical treatment of duodenal ulcer are as follows:—

Not satisfied with the results of gastro-enterostomy, and realizing that it would not cure the chronic acidic type of ulcer, and that the duodenectomy (with removal of a callosed ulcer) in the radical operation of partial gastrectomy and duodenectomy increased the risk to the patient by 8 to 12 per cent, I began, about 1920, to perform an operation which I called a partial gastric exclusion, in which about half of the stomach was excluded. In many of these cases jejunal ulcer developed, but in the others the results were satisfactory. It was not, however, until I excluded two-thirds or more of the stomach—and thus excluded a large part of the acid-bearing mucous membrane (*see Figs. 442, 443, p. 550*)—that I was able to obtain consistent curative results with the acidic type of ulcer.

In the later cases of this extensive partial gastric exclusion I found it advisable to reduce the redundancy of the excluded distal segment of the stomach by resecting part of it, as shown in *Figs. 447, 448, p. 553*. This is the type of operation which I now employ for a bad type of duodenal ulcer.

The curative effects of partial gastric exclusion were about the same as partial gastrectomy where two-thirds or more of the stomach was removed. Partial gastric exclusion had, however, advantages over partial gastrectomy. The preservation of the pyloric part of the stomach enabled the stomach and intestine to be reconstituted if a jejunal ulcer or a chronic gastritis should develop. In the case of a partial gastrectomy, the advent of either or both these conditions presented a dangerous, and in the case of the gastritis an almost insoluble, surgical problem.

Partial gastric exclusion had also another advantage. Since the hæmatinic substance described by Castle (not thought of when I designed the operation), the loss of which gives rise to anæmia, is supposed to reside in the pyloric part of the stomach, the preservation of this part permitted extensive exclusion of the acid-bearing part of the stomach without the sequence of a secondary anæmia.

The preservation of the pyloric part of the stomach had not, in my experience, been a factor in causing, by any hormone action, an increased acidity; that is, it had not given rise to a second phase of gastric secretion. In any case of partial exclusion (with partial resection) in which the acidity had not been sufficiently reduced, I always found that I had not excluded (or resected) enough of the stomach.

Of course I could not employ partial gastric exclusion if the duodenal ulcer was associated with any marked degree of stenosis.

To summarize, then, the surgical treatment of duodenal ulcer:—

1. Gastro-enterostomy in carefully selected cases ; that is, in cases where the ulcer is unassociated with a very high acidity, and where some other contributing cause than high acidity can be found.
2. Partial gastric exclusion, or partial gastric exclusion combined with a limited resection of the acid-bearing part of the stomach, in those cases in which the ulcer is associated with a high acidity, or with a high acidity and a definite ulcer diathesis.
3. Partial gastrectomy and duodenectomy in some few cases where it may be thought that the duodenal ulcer should be removed ; or where the duodenal ulcer is associated with too much stenosis for exclusion and resection.

PRINCIPLES UNDERLYING THE SURGICAL TREATMENT OF GASTRIC ULCER

The surgical treatment of gastric ulcer must be approached on principles different from those applicable to duodenal ulcer.

Gastric ulcer is probably not primarily caused by high acidity, as are certain types of duodenal ulcer. Acidity is only one big contributing factor. Other factors, such as gastric stasis, continual movement of the gastric wall, food infection, injury to the gastric wall, also play an important part in its causation—factors which could play a part in perpetuating a chronic ulcer in other tissue systems of the body.

Furthermore, in gastric ulcer there are other pathological conditions which do not obtain in duodenal ulcer. A gastric ulcer is liable to malignant degeneration (5 to 7 per cent of cases). It shows a definite tendency to penetrate the liver or pancreas, when its chances of a permanent natural healing are greatly reduced. It is often associated with organic pyloric stenosis, and consequently the emptying power of the stomach is permanently disabled and the organ is crippled. It causes disturbances of motility and therefore permanent disorders of gastric emptying, because it is always situated on the gastric canal—the ‘backbone’ of the sensitive peristaltic mechanism ; and these effects of the ulcer help to perpetuate its existence. Finally, gastric ulcer is perhaps more liable to cause death from hæmorrhage or perforation than duodenal ulcer.

It is obvious that not only the chronic ulcer, but the factors which cause it, and also complicating pathological conditions associated with it, can be removed by operation—that is, by partial gastrectomy. In addition to these considerations, there is also the very important fact that where gastric ulcer is not associated with

a high acidity, partial gastrectomy, the operation of choice for its surgical treatment, is not followed by jejunal ulcer. The surgical treatment of chronic gastric ulcer is therefore based on much sounder principles than in the case of chronic duodenal ulcer.

Finally, it is to be advanced in favour of the surgical treatment of chronic gastric ulcer, that perforation and hæmorrhage and the advent of malignancy render the mortality-rate of medical treatment higher than that of surgical treatment.

The Cod-liver Oil Treatment of Chronic Gastric Ulcer.—

Löhr¹ has founded a treatment for chronic gastric ulcer in which he gives generous doses of cod-liver oil by mouth. He bases its use on the following principles: (1) that its vitamin content is bactericidal and promotes the healing of ulcers anywhere in the body, its use on ulcerating surfaces having been very successful; (2) that the oil sticks to the mucous membrane for many hours, and thus protects the ulcer from the action of the gastric contents; (3) on the well-known physiological fact that the presence of oil in the stomach inhibits the secretion of acid.

He employs this treatment for those chronic gastric ulcers which are too big to resect. These he treats with cod-liver oil until they get small enough to resect. He also treats the type of chronic gastric ulcer that is scarcely old enough, callous enough, or medically incurable enough to require operation. He gives 20 g. four times a day between meals, and a larger dose on going to bed at night. He stresses the value of the large dose at night on the empty stomach. He reports very good results and shows many pictures of very large chronic ulcers which healed under the cod-liver treatment.

COMMENTS ON OPERATIONS FOR PEPTIC ULCER

Gastro-enterostomy.—Gastro-enterostomy is the simplest and safest of all operations for the treatment of certain forms of gastric and duodenal ulcer. It is especially suitable for: (1) the less chronic forms of duodenal ulcers, where the patient is old or where the acidity is not too high; (2) pyloric or prepyloric ulcers; (3) small ulcers of the lesser curvature near the pylorus.

If gastro-enterostomy is restricted to those cases in which there are sound indications for its use, it gives a high percentage of permanent cures. It has, however, a doubtful reputation, principally because it has been misapplied, its proper application to the various physiological conditions not always being understood. In suitable circumstances its efficacy is remarkable, a good instance of which is shown in the interesting case-history that follows.

In a woman who had been ill for two years suffering from a painful dyspepsia, I found evidence of an enormously dilated stomach, obviously the result of a pyloric stenosis. At operation, I discovered a large prepyloric 'ulcer tumour', the size of a mandarin, quite hard, having all the appearance of a malignant tumour. As the patient was very ill I carried out a gastro-enterostomy as a first stage, preparatory to a partial gastric resection. Four weeks later I reoperated with a view to carrying out the second stage of the operation. I passed my hand down to pick up the tumour, but to my surprise it had entirely disappeared: this big ulcer tumour had disappeared completely four weeks after a gastro-enterostomy.

Gastro-enterostomy Combined with Resection of the Ulcer.—

For the *chronic penetrating ulcer high up on the lesser curvature*—so high that if a partial gastrectomy were performed not much stomach would be left—resection of the ulcer combined with a gastro-enterostomy may be the best operation to choose. It is not a good operation, as the resection of the lesser curvature cripples the stomach. The alternative operation is partial gastrectomy with resection of the lesser curvature, carried out as described in Chapter L.

Partial Gastrectomy.—For most of the *very chronic ulcers of the stomach*, especially those which penetrate, partial gastrectomy gives the best results.

For the *acidic form of duodenal ulcer*, especially if it is situated on the posterior wall of the duodenum, or if it penetrates the pancreas, partial gastrectomy in which two-thirds of the stomach is removed, combined with duodenectomy, may be required.

Partial Gastric Exclusion.—In many cases, partial gastric exclusion, made at the correct level, will accomplish the same purpose as partial gastrectomy and duodenectomy, with a great deal less danger. It is the operation to employ if the patient is very ill or a prepyloric or duodenal ulcer is very difficult to remove. It is also the operation to use in very bad cases of jejunal ulcer. Should the jejunal ulcer not heal—a rare occurrence—it may be removed at a second operation when the patient's condition is much better and his jejunal lesion is less infiltrated and much easier to remove. Partial gastric exclusion is based on the same principle as the operation of resection with exclusion which the Continental surgeon now finds so satisfactory for the surgical treatment of duodenal ulcer.

REFERENCE

- ¹ LÖHR, W., "Die Lebertranvorbehandlung zunächst inoperabler Magengeschwüre," *Zentralb. f. Chir.*, 1935, **62**, 2362-71.

CHAPTER XLIV

PRINCIPLES ON WHICH GASTRO-ENTEROSTOMY IS BASED

IT is necessary to discuss in detail the theory and technique of gastro-enterostomy, because I find in modern surgical practice that scarcely any other operation is followed by so much morbidity.

PRELIMINARY INVESTIGATION OF THE PATIENT

Having decided that gastro-enterostomy is indicated in the pathological condition which is present in a certain patient, the surgeon should make himself intimately acquainted with the physiological conditions in the stomach and duodenum of this patient. He should also study carefully the pathology of the lesion as seen by X rays. This knowledge is necessary so that the technique of the gastro-enterostomy can be individualized.

The information required (obtained by X-ray and laboratory examinations) is as follows: (1) The shape and size of the patient's stomach. (2) The presence of even mild degrees of pyloric stenosis—a complication which is not infrequently associated with chronic peptic ulcer; the strength of the gastric muscle in relation to the exact emptying time is a good gauge of this—a six-hour emptying time with a powerful musculature may mean pyloric stenosis, but even a much longer emptying time with a weak musculature does not necessarily indicate obstruction, and is of no significance. (3) The situation and the degree of chronicity of the ulcer. (4) The degree of gastric acidity. (5) The possibility of any malignant degeneration.

The surgeon requires this pre-operation knowledge so that he may be able to come to the following decisions:—

1. Whether the physiological conditions of this particular patient's stomach will permit of the performance of a gastro-enterostomy without giving rise to distressing by-effects, such as vomiting and nausea—by-effects which usually follow in the wake of a gastro-enterostomy made in a weak-muscled stomach.

2. Whether the ulcer, judged from its situation and its degree of chronicity and other factors, will be amenable to the curative effects of gastro-enterostomy. Some ulcers are too unfavourably placed and too chronic to be cured by gastro-enterostomy.

Having acquired this pre-operative knowledge, he will be able to plan how to carry out those refinements in technique which are so necessary if a gastro-enterostomy is to be successful. For instance, he will be able to decide (1) where he should place the stoma—a question of the tone of the gastric muscle; (2) how big he should make it—a question of tone and the type and size of the stomach; (3) when to avoid performing a gastro-enterostomy in which a jejunal ulcer is likely to form—a question of the muscularity of the stomach, the youth of the patient, and the concentration of the gastric acid.

THE PHYSIOLOGY OF GASTRO-ENTEROSTOMY

The surgeon should understand the physiology on which gastro-enterostomy is based, so that he can vary his technique to get the best therapeutic effect for the particular lesion.

From the discussion already considered of the principles on which the treatment of peptic ulcer is founded (*see* p. 414), it will be apparent that for its cure the following requirements are necessary:—

1. The concentration of the gastric acid and the duration of its action on the gastric wall must be reduced.
2. The ulcer must be rested, that is, removed from the action of food and muscle movement—treated in the same way as an ulcer in any other part of the body.
3. The secondary effects of the ulcer must be removed—scar tissue resected and stenosis relieved.

A gastro-enterostomy, by its short-circuiting action, can lessen the action of acidity on the ulcer by hastening the emptying time. It can also reduce the action of a high concentration of gastric acidity on the ulcer by the regurgitation of alkaline duodenal contents through the stoma—the so-called *innig Apotheker*, or ‘internal apothecary’. The neutralizing effect of duodenal secretion is, however, very poor. Enderlen, Freudenberg, and Redwitz showed that four times as much duodenal juice of pH 6.98 was required to neutralize a dog’s gastric juice of pH 3.07. Therefore the duodenal juice regurgitating into the stomach through the gastro-enterostomy is not of great importance in regard to its neutralizing action upon a high gastric acidity. Paterson, Schmilinsky, Dahlgren and others have completely divided the intestine in a human being, and have implanted the afferent and efferent loops separately into the stomach wall, with no special improvement in results. Schmilinsky found in his cases only a slight decrease in acidity on re-examination. Enderlen and his co-workers performed the same operation on dogs and found only a slight decrease in acidity. Any reduction of gastric acidity

brought about by the regurgitation of duodenal contents into the stomach is therefore probably as much the result of the diluting as of the neutralizing effect.

Thus it will be seen that, to be effective in the cure of peptic ulcer, a gastro-enterostomy must primarily act as a drainage operation, and secondarily as an operation which permits an adequate regurgitation of the duodenal contents through its stoma.

In the case of duodenal ulcer, however, this drainage action of gastro-enterostomy is not so effective in reducing the acidic action, because a quick-emptying stomach is almost a constant association of this ulcer. In this case it is the short-circuiting action of the gastro-enterostomy, whereby the action of the gastric contents on the ulcer is minimized, which helps to heal the ulcer. On the other hand, there is the danger in these circumstances that, since the jejunal mucous membrane is less resistant to the action of acid than that of the duodenum, jejunal ulcer may form. On the whole, therefore, the physiology on which a gastro-enterostomy is based does not lend itself to the cure of the typical chronic duodenal ulcer.

It is in the case of stenotic conditions of the stomach and duodenum that gastro-enterostomy has its greatest usefulness, for here it functions essentially as a drainage operation.

It should be remembered that the disadvantage of gastro-enterostomy in the treatment of ulcer is that it does not remove or cure the effects of ulceration—the low-vitalized scar tissue.

A WORKING HYPOTHESIS

A working hypothesis in regard to the applicability of gastro-enterostomy will depend on whether it is being performed for duodenal ulcer, gastric ulcer, or pyloric stenosis.

Gastro-enterostomy for Duodenal Ulcer.—Since duodenal ulcer is caused and perpetuated mainly by a high acidity, it may be taken as a broad working rule that, unless the gastro-enterostomy adequately reduces acidity, it will not cure the duodenal ulcer. The main aim, then, in the technique of a gastro-enterostomy which is to be employed for duodenal ulcer is to exploit to the full its action of reducing gastric acidity—its regurgitant action. This technique is discussed on p. 430.

Gastro-enterostomy for Gastric Ulcer.—In the case of gastro-enterostomy for gastric ulcer, the aims are primarily to obtain good drainage and thus reduction of the duration of the action of acidity on the gastric mucous membrane. Gastric ulcers are usually found in stomachs which have a somewhat delayed emptying time, and in

which the gastric acidity is normal or low. Any action of acidity on the mucous membrane is thus a prolonged one. Consequently, in the application of gastro-enterostomy to a gastric ulcer, the main therapeutic principle to aim at, in order to correct these pathological conditions, is to obtain good gastric drainage. This will not only remedy the gastric stasis, but at the same time will lessen the duration of the action of the acidity or other functional factors.

Gastro-enterostomy for Pyloric Obstruction.—In gastro-enterostomy for non-malignant pyloric or duodenal obstruction, the main effort, of course, is to obtain complete drainage of the stomach ; the reduction of acidity is a secondary consideration. Therefore the gastro-intestinal stoma must be placed where it will most effectively empty the stomach. To decide on this position for the stoma in a very dilated stomach is not so simple as would appear. In gross pyloric obstruction, most of the dilatation of the stomach takes place in its cardiac part, where there is normally only a tonic muscular contraction. The very large radiographic shadow of a grossly dilated stomach contracts at intervals to almost half its size independently of the usual peristaltic movements of the pyloric part of the stomach. This gross retraction and relaxation takes place in the dilated tonic musculature—the cardiac part of the stomach. In such a grossly dilated stomach, if the stoma is placed in what in the ordinary-sized stomach would be the proper position, it will be found that when the obstruction is relieved the stoma will retract upwards towards the cardiac orifice—a position in which it cannot effectually empty the stomach. Thus in these very dilated stomachs, in order to achieve effective emptying, the stoma must be placed fairly close to the pylorus, a position which would not be correct if the main aim of the gastro-enterostomy were reduction of gastric acidity.

EMPTYING TIME AFTER GASTRO-ENTEROSTOMY

As one of the important therapeutic actions of gastro-enterostomy is its power to effect rapid drainage of the stomach, it is necessary to find out what factors contribute to this end.

A study of the rate of emptying the stomach in a series of patients on whom I have carried out gastro-enterostomies and partial gastrectomies goes to show that many factors are concerned in the rate of emptying of a stomach with a gastro-entero-anastomosis.

Factors which determined the rate of emptying were: (1) the situation of the stoma in relation to the cardiac orifice ; (2) the tone of the gastric musculature of the particular patient ; (3) the size of

the stoma; (4) accidental torsion or angulation of the afferent or efferent loop; (5) spur formation in the stoma.

1. Situation of the Stoma.—If the stoma is placed too near the pylorus, and in that area where the peristaltic waves are vigorous and deep (in the ‘gastric mill’ area), it will not greatly hasten the emptying time of the stomach. The reason for this becomes obvious if the action of an opening in any hollow organ is studied. If an opening is made in a hollow organ such as the intestine or the stomach, in which there is a vigorous peristalsis, most of the contents will go through the natural channel rather than through the artificial opening. Thus I have often observed in a sigmoid colon, which was

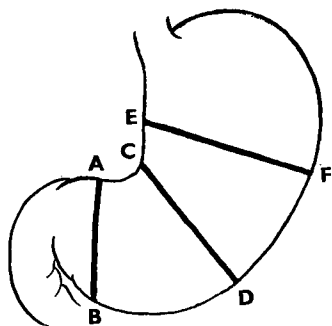


Fig. 306.—Diagram showing various levels at which the same stomach was anastomosed to the jejunum at three successive operations. See text.

partially obstructed by a carcinoma, and in which there was hypertrophied muscle, and therefore vigorous peristalsis proximal to the obstruction, that where an artificial anus (without a spur) was made some distance from the obstruction, the greater part of the bowel contents passed through the almost impatent obstruction rather than through the artificial opening. It is because of this action of vigorous peristalsis that it is necessary to make a definite spur in a sigmoidostomy; otherwise much of the bowel contents would pass the natural way even through a

partially obstructed bowel. It is probably for a similar reason that a stoma placed in that part of the stomach in which there is strong peristalsis will not adequately function in the presence of a patent pylorus.

Thus, the nearer to the œsophageal orifice the stoma is placed, the quicker is the emptying time. A stoma placed very far to the left in the fundus will effect emptying of the stomach in a few minutes—will, in fact, cause what has been called a ‘dumping stomach’. As a proof of this I put forward the following clinical evidence;—

I carried out on the same patient, at various times, three successive operations: (1) pyloric exclusion for duodenal ulcer; (2) a partial gastrectomy for jejunal ulcer; (3) a partial gastrectomy for a recurrent jejunal ulcer. In the first operation, the stomach was anastomosed at the level AB of *Fig. 306*, in the second at CD, and in the third at EF, in each instance to the same part of the jejunum; that is, in the same person, the stomach was successively anastomosed at different levels to the same part of the intestine. The emptying times were found to be respectively: 2 hours, 1 hour, 10 minutes.

I might add also further evidence from many unsuccessful gastro-enterostomies. I have had to undo many of these operations because they caused the stomach to empty so quickly that the patients had great distress after meals. In practically all these cases I found that, in the same size of stoma, the nearer to the cardiac orifice the stoma was situated, the more rapid was the emptying time.

I have therefore come to the conclusion that the best position in which to place the stoma, in order to obtain the desired emptying time, is on the fringe or in the beginning of the peristaltic area.

If a stoma is placed in the long axis of the stomach (transversely), it will increase the emptying rate more than one at right angles to the long axis of the stomach (vertically).

The nearer to the greater curvature a stoma is placed (that is, the farther from the *Magenstrasse*), the quicker the stomach empties.

2. The Tone of the Patient's Musculature.—If the patient's gastric musculature is hypotonic, an effective emptying time will be difficult to obtain. This hypotonicity is generally found in neurasthenic women. Thus there may be cases where the gastric muscle is so weak that it is unwise to perform a gastro-enterostomy.

If in these hypotonic cases, in order to obtain a rapid emptying time, the opening is made well towards the cardia, a new factor arises: it is found that the distal part of the stomach will not completely empty itself; a small food-rest acts as a continuous stimulus for the secretion of acid. Thus, not only does the gastro-enterostomy fail to improve the drainage, it also becomes a cause of a pathological secretion of acid.

3. The Size of the Stoma.—It has been said that the size of the stoma does not matter, because the outflow from the stomach is determined by the calibre of the intestinal lumen. This is not true. The stomach has more tone and stronger peristalsis than the intestine, and the intestine soon dilates and hypertrophies in response to the extra work. Its lumen then adapts itself to the size of the stoma. In gastro-enterostomies where the stoma has been large, I have found that the calibre of the efferent loop was often as big as a man's wrist. Therefore one may assume that the larger the stoma the quicker the emptying time.

4. Disposition of the Efferent and Afferent Loops.—In a gastro-enterostomy in which the afferent loop is *too short*, even the slightest axial rotation will seriously hinder the emptying of the short-circuited loop. Kinks in the efferent limb have not such an obstructive effect, because the long untethered loop permits a certain amount of readjustment.

Axial twist, or kinking of the afferent or the efferent loop, or of both, practically amounts to a chronic incomplete upper intestinal obstruction, as well as an interference with the effective emptying of the stomach.

5. Spur Formation.—Spur formation occurs if the loop of intestine is applied to the stomach in the wrong direction. It may also occur in a big stoma where the intestine, as it were, prolapses into the stomach. It is similar to the spur made in a sigmoidostomy.

Spur formation seriously interferes with the emptying function of the stomach. Dr. J. C. Lewis produced this spur condition experimentally in the stomach of a dog by a defective gastro-enterostomy combined with a pyloric occlusion. In this case the stomach became very dilated because, as the pylorus was occluded, it could not empty itself naturally; and because of the spur it could not empty effectively by the stoma. Yet the opening of the gastric stoma into the jejunum appeared to be mechanically unhindered.

Thus it will be seen that, in the technique of gastro-enterostomy, the situation of the stoma must be carefully chosen in regard to the particular stomach, and to the length of the afferent loop. Care must be taken to see that it is not too short, that there is not the slightest axial twist in it, and that spur formation does not take place.

REGURGITATION AFTER GASTRO-ENTEROSTOMY

The regurgitation of duodenal contents into a gastro-enterostomized stomach varies very much according to the circumstances surrounding the gastro-enterostomy.

Many authorities doubt its occurrence. I have, however, been able to demonstrate in the empty gastro-enterostomized stomach (at operation) that the greater part of fluid which I have injected through the pylorus passed back through the stoma into the stomach. I have found, too, in some of the unsuccessful gastro-enterostomies which I had to undo because of incessant vomiting, that the whole of the duodenal contents regurgitated into the stomach. This complete regurgitation was caused by a gross spur formation, which was produced by a badly constructed gastro-enterostomy—by a stoma that was too big and misplaced.

Furthermore, in the case of a gastro-enterostomy in the weak-muscled stomach of the neurasthenic female, the duodenal contents enter the stomach so freely that they give rise to unpleasant nauseous symptoms.

When gross spur formation develops in a gastro-enterostomy, then the so-called 'vicious circle' occurs. It fell to my lot to operate on a well-known surgeon in whom this catastrophe had happened; and to undo for him his gastro-enterostomy in which a spur formation had formed. He had very accurately observed the symptoms and signs of this condition. He vomited large quantities of duodenal contents, beginning about an hour after food; he never vomited food. He suffered from dreadful nausea after meals. Over a period of many years he found that his gastric contents were never acid. X-ray observation after a meal showed that his food emptied into the jejunum in a few minutes, and that after this his duodenal contents regurgitated into his stomach. When I undid his gastro-enterostomy, I found a very large stoma, situated far over to the left in the fundus of the stomach, and vertically placed. Into this large stoma the jejunum had prolapsed, giving rise to a gross spur formation. The efferent loop, probably owing to the fact that the spur deflected all the food at once into the upper part of the jejunum, was as large as a man's wrist. The afferent loop, on the other hand, was small. From the arrangement of the spur it was obvious that as the food filled the fundal part of the stomach it opened the efferent loop and thus closed the afferent limb of the spur; and later when the efferent loop ceased to function the whole of the duodenal contents passed into the empty stomach by the afferent loop, and as they filled the pyloric part of the stomach, they closed the efferent limb of the spur and ultimately had to be vomited.

From a consideration of this case it is obvious that an extreme degree of regurgitation of duodenal contents can be produced by a spur gastro-enterostomy. It is, however, a minor degree of spur formation which is required in a gastro-enterostomy: just enough to bring about a reasonable degree of regurgitation and therefore a therapeutic reduction of gastric acidity.

There can be no doubt that in a gastro-enterostomy regurgitation of duodenal contents does occur, and that in certain cases of malconstructed gastro-enterostomies, where the regurgitation has become, as it were, pathological, gastric acidity can be greatly reduced by a diluting and neutralizing action.

GASTRO-ENTEROSTOMY FAILURES

The surgeon should know the causes of failure in gastro-enterostomy, so that with a knowledge of these it should be possible for him, by careful attention to technique, to avoid, or at least to lessen, the percentage of unsuccessful results.

Gastro-enterostomy failures fall into three categories.

In the first are those cases in which there is persistence of pain after operation—those in which the original symptoms of ulcer do not clear up, or are soon followed by other and somewhat similar painful ulcer symptoms; that is, the gastro-enterostomy has either failed to cure the original duodenal ulcer, or, if it has cured it, a jejunal ulcer has developed. This form of failure in gastro-enterostomy, a failure associated with *painful dyspepsia*, is usually owing to the fact that the gastro-enterostomy has not reduced the acidity sufficiently to cure the original ulcer, or that the action of the unreduced high acidity on the jejunal mucous membrane has caused a new ulcer in the jejunum.

In the second category are those failures which are the result of errors in gastric motility, the manifestations of which are nausea and vomiting. In one group of this type of gastro-enterostomy failure the stomach empties precipitately—perhaps in five to ten minutes—because the stoma is too big or is placed too far towards the cardia; in another group the stomach empties too slowly because the stoma is placed too near the pylorus, or because there is obstruction in the afferent or the efferent loop.

In the third category are those gastro-enterostomies where gastric symptoms have formed the only indication for operation—that is, gastric symptoms without any demonstrable ulcer. In such cases, of course, a gastro-enterostomy has been erroneously performed. The gastric symptoms were the result of a disturbance of the neuromuscular centres in the stomach—actually the symptoms of a functionally diseased stomach—and in this form of stomach a gastro-enterostomy produces all sorts of motility errors and all sorts of unpleasant symptoms. Such a gastro-enterostomy is a surgical catastrophe.

CHAPTER XLV

THE TECHNIQUE OF GASTRO-ENTEROSTOMY

GASTRO-ENTEROSTOMY is an operation difficult to perform because the technique must be individualized; that is, it must be varied to fit the physiological and pathological conditions of the stomach of a particular patient. This is the reason why I have set out in so much detail what I consider to be the most satisfactory method of carrying out a gastro-enterostomy.

The illustrations are drawn from photographs of my own operations, and they represent the exact technique, even to the art of suturing (for there is a right way and a wrong way to suture tissues). They thus accurately reflect operation-room methods.

THE INITIAL STEPS

The Incision.—A left paramedian incision, 4 in. long, is made, as illustrated in *Fig. 307*.

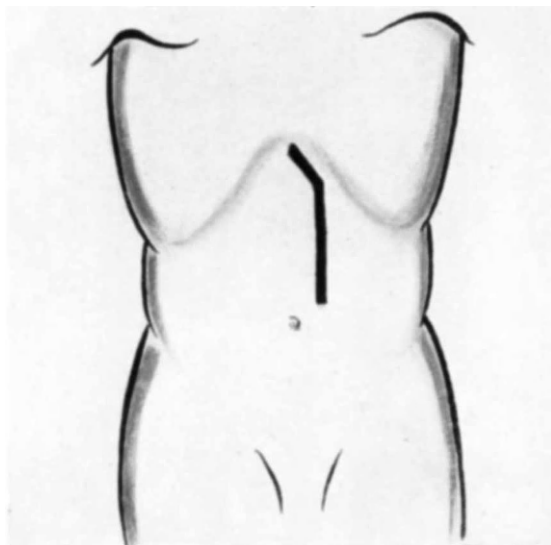


Fig. 307.—Left paramedian incision. (*Figs. 307, 309, and 311-316* by courtesy of the 'Australian and New Zealand Journal of Surgery'.)

Insertion of Operating Frame.—The edges of the wound are covered with closely woven cloth towels; the author's operating frame* is inserted into the wound, and used to expand the wound and clamp the towels firmly in position (*Fig. 308*).

Anæsthetic.—Light ether anæsthesia (*see p. 463*) should be the routine choice. Once the retractor is inserted, the anterior abdominal wall, which contains sensory nerves, is spared further handling, and

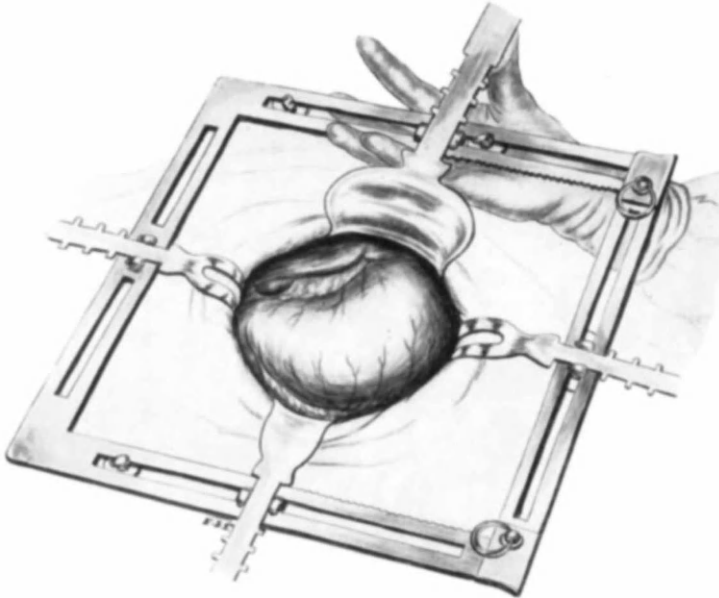


Fig. 308.—Insertion of the author's operating frame for exposure of the stomach and duodenum and exploration of the abdomen.

therefore further sensory stimulation. Since the intestines are insensitive, the anæsthetist can, if the surgeon is gentle in his movements, reduce the anæsthetic to a minimum. He can maintain this light anæsthesia until such time as the abdominal wound is to be closed, when he must increase the anæsthetic in order to get the necessary relaxation of the abdominal muscles to permit its closure. Thus with the use of the operating frame it is possible to administer a very light ether anæsthesia.

Where, however, the patient is a bad risk, nitrous oxide gas and oxygen, with a little ether now and then when relaxation is required, should be employed.

* Obtainable from J. Ludbrooke & Son, Melbourne, Victoria, Australia.

Routine Abdominal Exploration.—As a preliminary to a proposed gastro-enterostomy a general abdominal exploration should be carried out, in order to verify the diagnosis and detect any coexisting disease.

Verification of the Diagnosis.—When a gastro-enterostomy is being undertaken on a diagnosis of ulcer, this diagnosis must be verified. For example, in the case of duodenal ulcer it is first necessary to

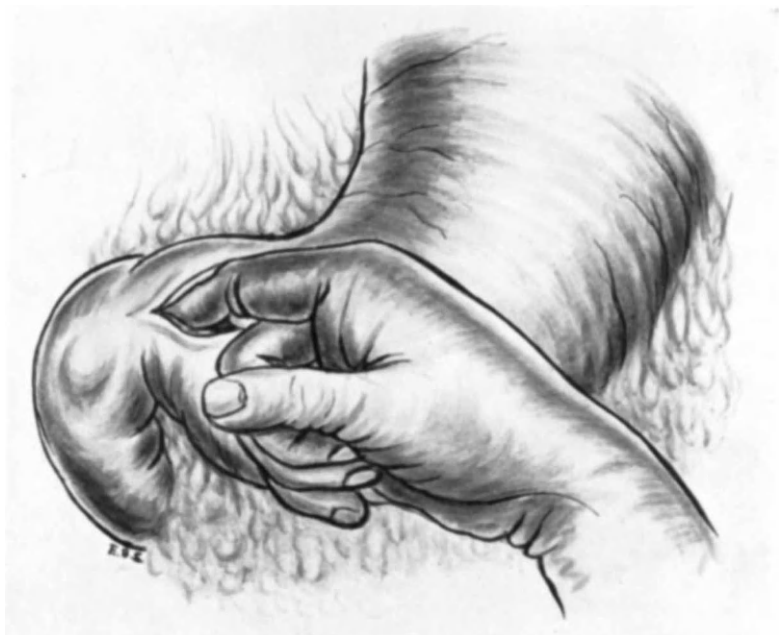

Fig. 309.—Incision in the prepyloric part of the stomach and exploration of the duodenum with the gloveless finger

demonstrate the ulcer. It may not give indications of its presence on the serous surface; or if it does, these may be difficult to distinguish from those of the scar of a healed ulcer. Or again, the ulcer may be on the posterior wall, where it cannot be felt or seen from the external surface of the duodenum. Therefore, when a doubt exists as to the presence of the ulcer, an incision should be made in the prepyloric part of the stomach sufficiently big to permit a gloveless finger to be inserted through the pylorus (*Fig. 309*).

An ulcer too small to be felt by external palpation of the duodenum can be detected by the bare finger exploring the mucous membrane in the lumen of the duodenum; the pulp of the finger

will stick to an ulcer in the same way as it will stick to the sucking-pad of a small shellfish.

General Abdominal Exploration: Search for Infective Foci and Coincident Disease.—The surgeon must as a routine explore the rest of the abdomen. He must search for possible causes of gastric or duodenal ulcer; for any source of infection, and for any evidence of associated disease which would lower the vitality of the gastroduodenal wall. He must therefore examine the gall-bladder, the appendix, and

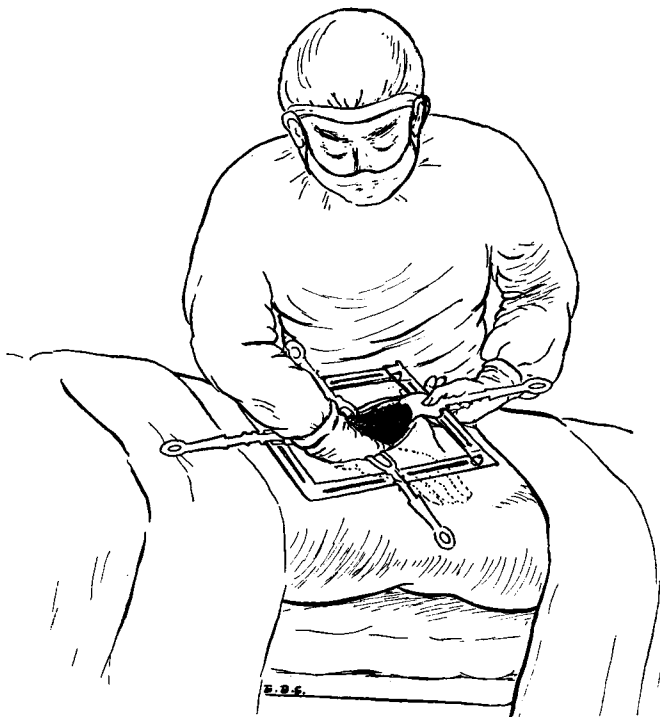


Fig. 310.—Examining the appendix.

the colon (for diverticulitis). He should look for inflammation of the abdominal lymph-glands, inspect the liver for early cirrhosis, and palpate the spleen (as an enlarged spleen may be the cause of any hæmatemesis).

Examination and Removal of Appendix.—As a general rule, it is better to remove the appendix before beginning the bigger operation of gastro-enterostomy. The surgeon cannot afford to leave an appendix in the abdomen, whether it is obviously affected or not; he must remove it, for it may at some time or another have been the source of infection, and the original cause of the ulcer.

The appendix is removed through this high *left* paramedian incision in the following way: Using the operating frame the surgeon lifts the abdominal wall away from the intestines, and creates, out of a potential body-cavity, an actual one into which

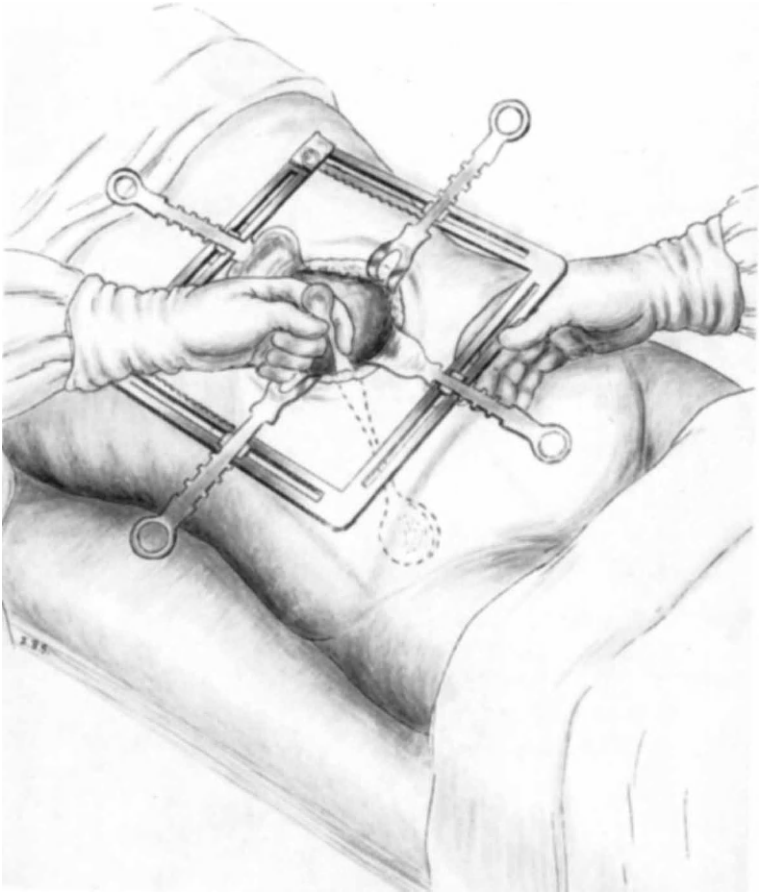


Fig. 311.—Spoon protecting intestines from injury when making stab wound through abdominal wall.

he can look and examine the appendix as it lies clearly in view (Fig. 310).

The abdominal wall is now held up by the operating frame in such a way that the artificial light shines through it; and the surgeon, looking through the wound and from the abdominal cavity, can see where the abdominal wall is tendinous and devoid of vessels, and where he can make a stab wound without causing bleeding. A spoon

(Fig. 311) is then placed inside the abdomen opposite this tendinous and bloodless spot, and a small stab is made through the abdominal wall on to the spoon, which protects the intestines from being wounded by the knife stab.

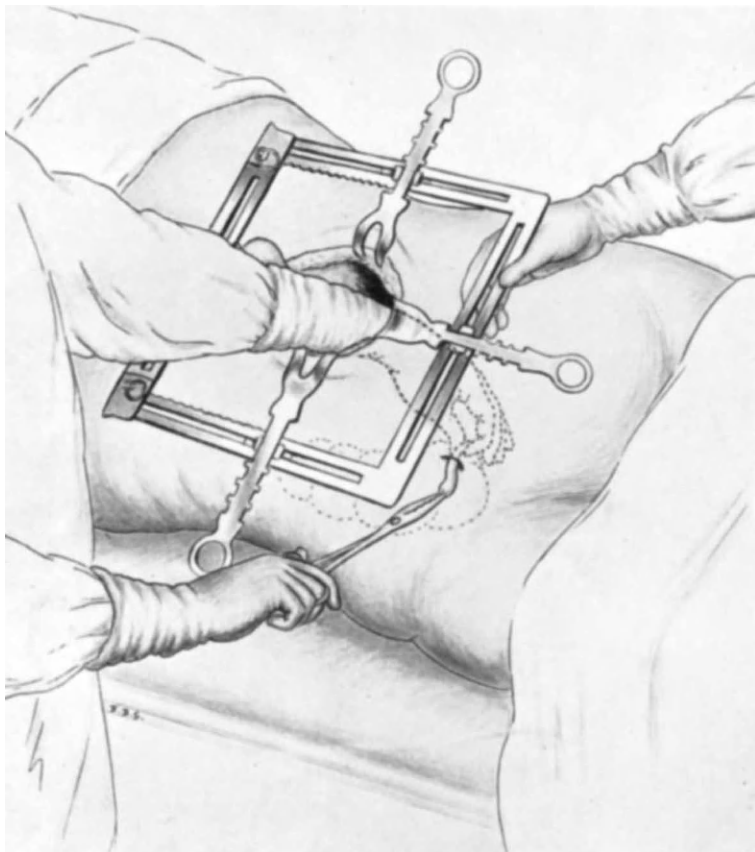


Fig. 312.—Appendix pushed through the stab wound with the left hand inserted through the upper wound, and grasped with the Spencer Wells forceps held in the right hand.

A Spencer Wells forceps is inserted through the tiny wound, and the appendix, which is plainly visible through the upper wound and held by the left hand, is grasped with the forceps, drawn through the stab wound (Fig. 312), and removed in the usual way. One suture suffices to close the stab wound.

In this way it is possible to remove the appendix through an upper abdominal incision made on the *left side*, and made so high

that a partial gastrectomy could, if necessary, be easily carried out. In this manner, also, the necessity is avoided for making a long *right-sided* paramedian incision, usually employed so that the appendix can be removed through it—an incision which not only lessens the virginal strength of the abdominal wall, but does not permit of the easy performance of any type of gastric operation that unforeseen circumstances may require.

THE OPERATION PROPER

Making an Opening into the Lesser Peritoneal Sac.—The first step in the gastro-enterostomy itself is, through an aperture in the gastrocolic omentum, to open into the lesser sac and make accessible

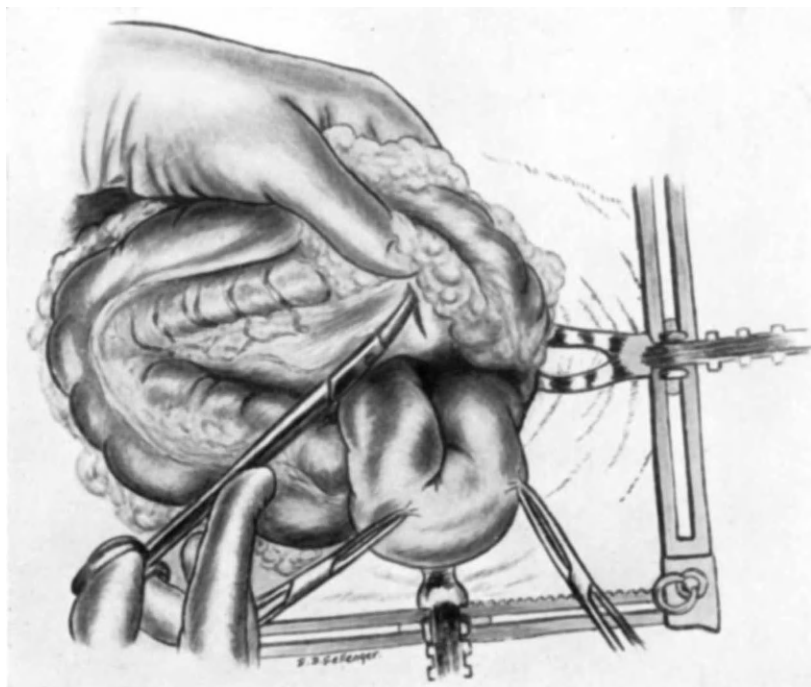


Fig. 313.—Making an opening in the transverse mesocolon.

the posterior wall of the stomach. This is done so that the anastomosis between jejunum and stomach can be made above the transverse colon, for it can be fashioned in this position much more easily and much more precisely than below the transverse mesocolon where it is usually made.

The lesser sac is opened by choosing a site in the gastrocolic omentum where there are no vessels, making a small hole into it, and gently enlarging the opening so that no vessels are torn.

Making an Opening in the Transverse Mesocolon.—Through this gastrocolic opening a slit is made in the mesentery of the transverse colon while it is stretched and held up against the light so that blood-vessels may be seen and avoided (*Fig. 313*).

Choosing the Site of the Stoma on the Stomach.—The site of the stoma is marked out on the stomach by scratching with a needle. The object of marking it out so accurately is to make sure that it is placed exactly as desired, for if this precaution is not taken, it is

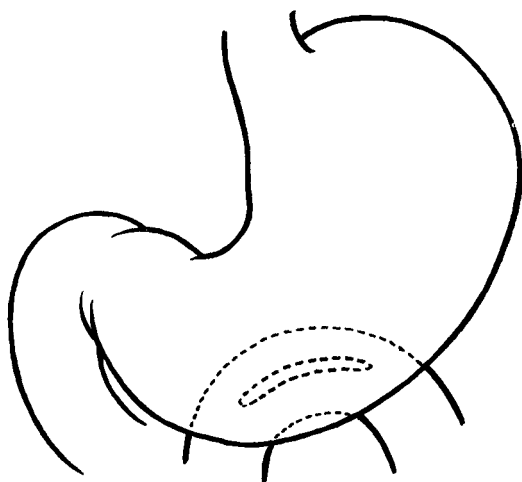


Fig. 314.—Diagram showing a usual site for a stoma.

very easy to misplace or to misshape the stoma when the stomach is turned over in order to apply to it the jejunal loop.

The ideal site, in my opinion, for the stoma of a posterior gastro-enterostomy, is indicated in *Fig. 314*. I believe, however, that in many circumstances it is better to make the stoma coincide with the greater curve. This is especially necessary in dealing with the small stomach with which a duodenal ulcer is often associated; or in the case of the stomach which is made small as a result of the extensive suturing which must follow a resection of an ulcer of the lesser curve. In both these cases, this greater-curve position of the stoma avoids the formation of shoulders or angles in the afferent and efferent loops, a complication very prone to occur in these small stomachs owing to the upward traction of the stomach on the transverse mesocolon. Moreover, the upward projection which this

site confers on the afferent loop facilitates regurgitation of the duodenal contents, and gives a better therapeutic result.

The convalescence in those cases of gastro-enterostomy with the stoma on the greater curve was so smooth that I have now

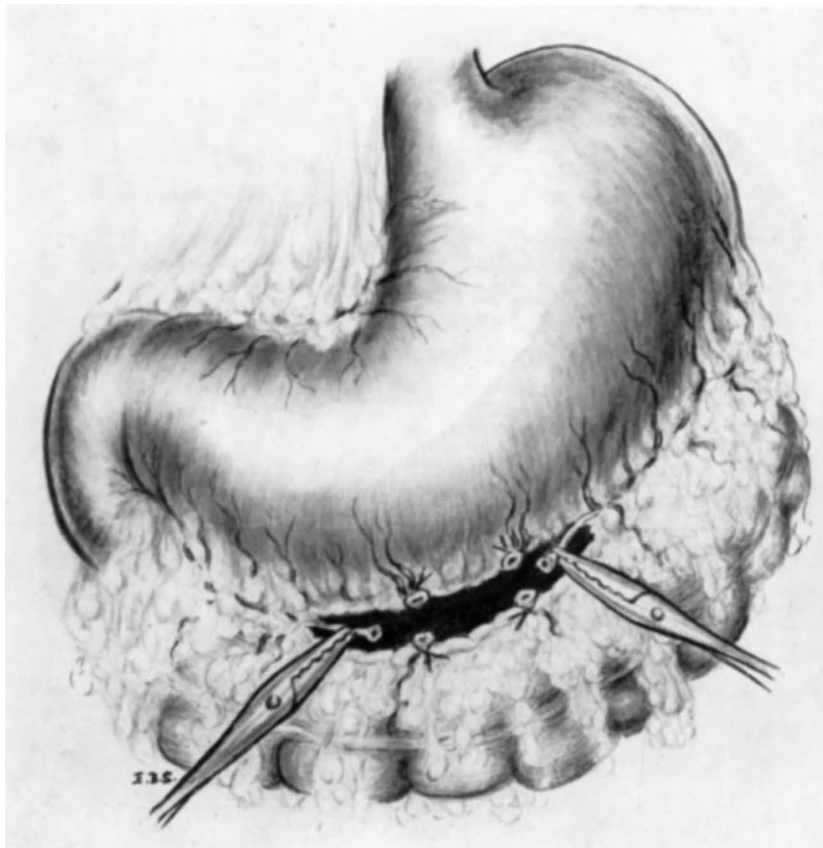


Fig. 315.—Amputation of the vessels of the greater curve, so that the stoma can be placed on it.

adopted this situation for the stoma in many gastro-enterostomies. It is then, of course, necessary to clear away the vessels from that region of the greater curve where the stoma is to be placed. They are separated from the stomach with the dissecting scissors, clamped, cut, and tied, as shown in *Figs. 315, 316.*

Choosing the Site of the Opening in the Jejunum.—When choosing the site for the opening in the jejunum, it must be remembered that the jejunum is continually contracting and relaxing in a

longitudinal direction, and that the site for the opening should be selected during the phase of contraction. If it is chosen during the phase of relaxation, the loop will be too short when it contracts, and the slightest torsion in such a short loop will produce a mechanical disability in the gastro-enterostomy. I am sure that short loops brought about in this way have been the cause of

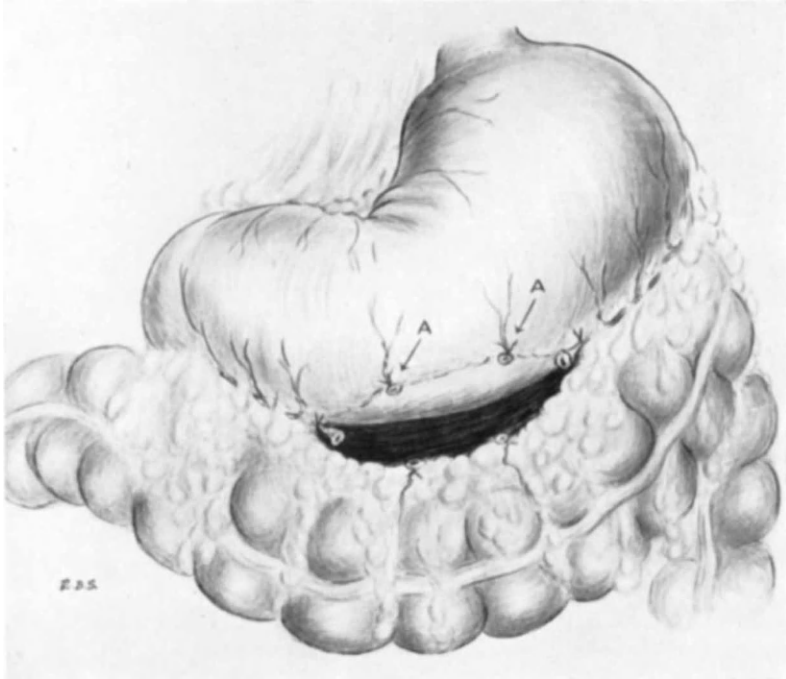


Fig. 316.—Diagram of stomach showing the vessels of the greater curve cut and tied (A), and the greater curve turned upwards, so that its actual line—the line of the proposed stoma—can be seen.

almost more mechanical errors than ever occurred in the previously used long loop.

The situation of this site should be such that the afferent loop is neither too long nor too short. It should be placed about 1.25 cm. ($\frac{1}{2}$ in.) posterior to the antimesenteric border, so that, when the first two layers of sutures are inserted, the line of the stoma will fall exactly opposite the mesenteric border.

The site is marked by placing at each end of it a 'guy-rope' suture, by means of which the jejunal loop is drawn up through the slit in the transverse mesocolon (*Fig. 317*), applied to the site of the

stomach, and attached thereto, the 'guy-rope' sutures being then fixed to the operating frame (*Fig. 318*).

Deflation of the Stomach.—The stomach is deflated. Air and any gastric contents in the stomach are aspirated by means of a trocar connected to a suction pump (*Fig. 318, A*) and the small opening

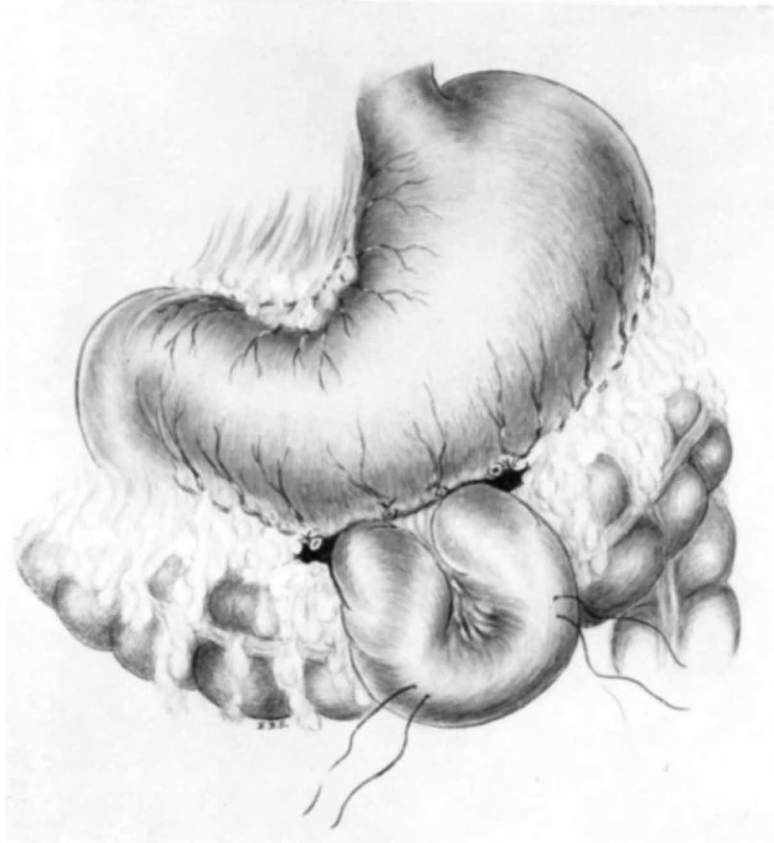

Fig. 317.—Jejunum drawn through the opening in the transverse mesocolon.

thus made is closed with a suture (*Fig. 318, B*). A deflated and collapsed stomach is much easier to operate on than one in its normally distended state, and permits of more accurate suturing.

Making the Anastomosis.—Clamps, usually used in making the anastomosis, to prevent soiling by gastric contents and to control bleeding, are not employed. Vessels are clamped and tied as they bleed. Soiling by gastric contents is avoided by 'vacuum-cleaning'

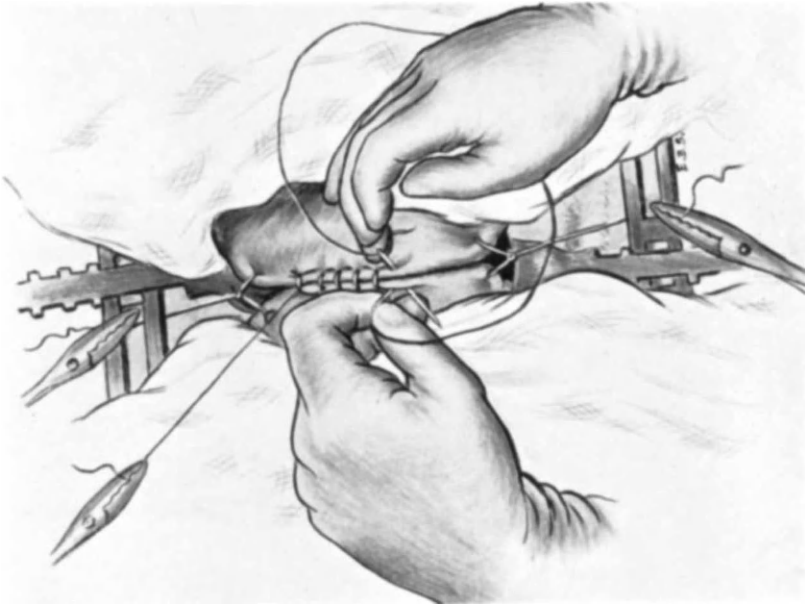


Fig. 319.—Serous suture. Note the method of holding the needle and the thread, suturing towards the surgeon.

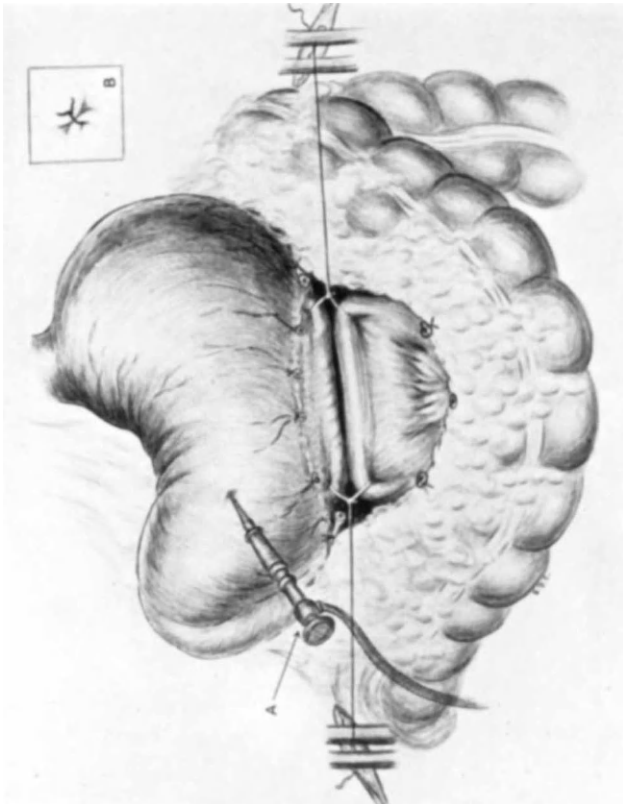


Fig. 318.—Site on stomach for stoma (greater curve) to which is applied the jejunal loop. 'Guy-rope' are seen holding the two segments together, stretching them tautly, and fixing them to the operating frame. A, Trocar inserted in the stomach for aspiration of air and gastric contents. B (inset), Opening closed with a suture.

the stomach by aspiration, and bleeding is prevented by clamping and tying vessels as they are divided.

As already stated, the gastric and jejunal segments are placed in position and held there with the right degree of tautness by means of 'guy-rope' sutures, which are fixed to the opposing sides of the frame. The 'guy-ropes' should have just sufficient tension to make a slight ridge at the line of junction of the gastric and jejunal segments; this can be accentuated by holding the suture firmly with the left hand, as shown in *Fig. 319*. It is a trick in technique which serves to make suturing easy and accurate. Any large vessels near the proposed stoma are underrun with catgut.

The anastomosis is made after a method used by Sir Alexander MacCormick, in which three tiers of sutures are inserted: (1) a serous, (2) a seromuscular, and (3) a mucous membrane tier.

1. *Serous Tier*.—The serous surfaces of stomach and intestine are united with a No. 0 or 00 chromicized catgut (*Fig. 319*), the suturing being made towards the operator. The most rapid and effective method of suture is as follows:—

a. Use a straight needle.

b. Keep a fixed constant tension on the jejunal and gastric segments by means of the 'guy-rope' retraction to the frame.

c. Make the first finger and thumb of the left hand pull on the thread, holding it close, so as to make the ridge more definite, and make the second finger act as a support against which the needle can be pushed.

d. Depress the shank of the needle with the pulp of the second finger of the right hand, at the same time directing its point upwards, so that it is in position to be grasped by the index finger and thumb of the right hand lying ready in position to pick it up. In this way rapid and accurate suturing is attained—not infrequently a life-saving measure in a gastro-enterostomy in a case of high-grade pyloric stenosis.

2. *Submucous Tier*.—The seromuscular layers of the jejunum and the stomach are incised down to the mucous membrane. These cut edges are sutured, and thus the second layer of sutures is formed (*Fig. 320*).

3. *Mucous Membrane Tier*.—The mucous membrane of the stomach and of the jejunum is incised. Vessels are clamped as they are divided and subsequently tied with No. 0 catgut. An aspirating tube is placed in the opening thus made, and the stomach is 'vacuum-cleaned' of its contents (*Fig. 321*). The tube must be pushed far into the fundus of the stomach, and up towards the dome of the left part of the diaphragm, for this is the place where stomach contents

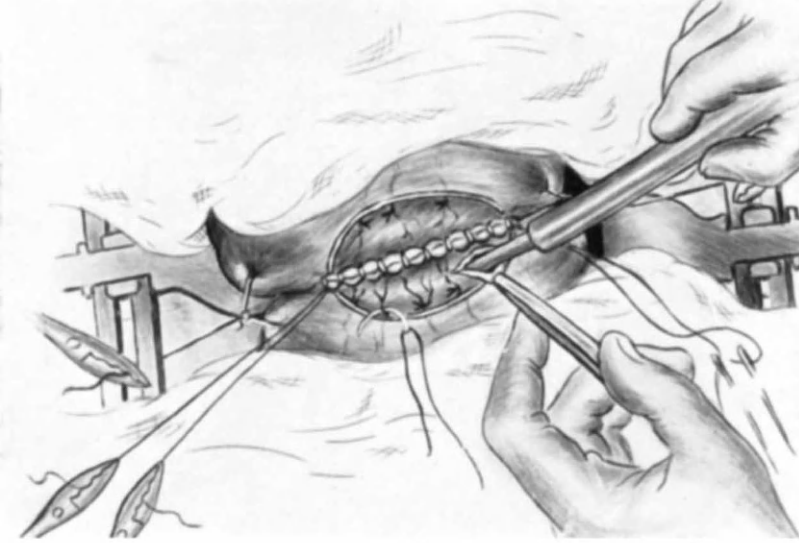


Fig. 321.—Underrunning vessels in the mucous membrane, and 'vacuum-cleaning' the stomach through an opening in the mucous membrane.

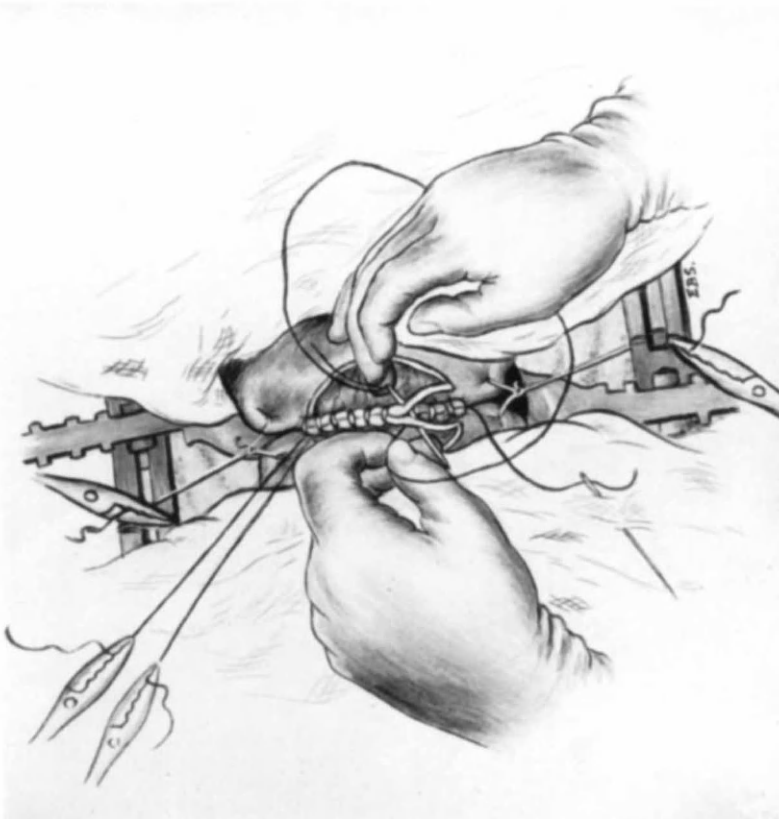


Fig. 320.—Seromuscular suture.

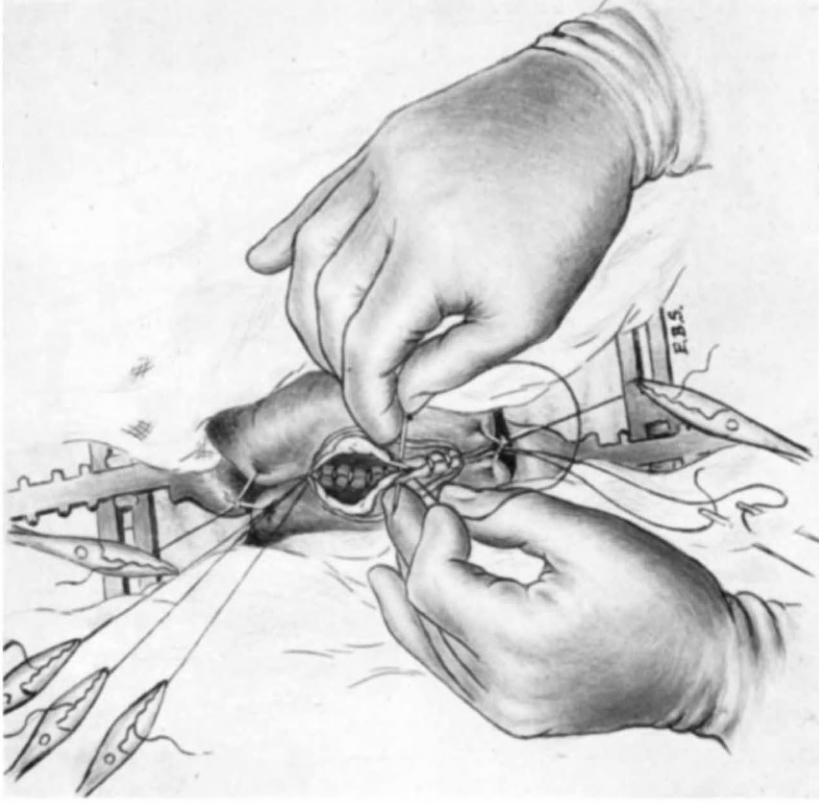


Fig. 323.—Suture of the anterior layer of the mucous membrane. (Note how the fingers are disposed in suturing the anterior layer, suturing away from the surgeon.)

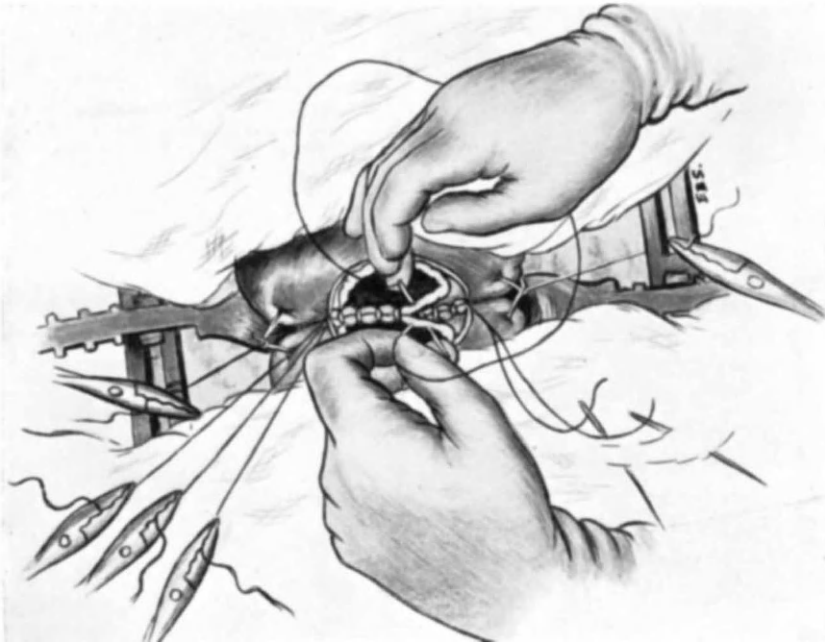


Fig. 322.—Suture of the posterior layer of the mucous membrane.

collect when the patient is in the recumbent position. The jejunum as its name signifies, is generally empty, and it need not be aspirated.

The mucous membranes are united by a continuous suture of No. 0 plain catgut (*Fig. 322*).

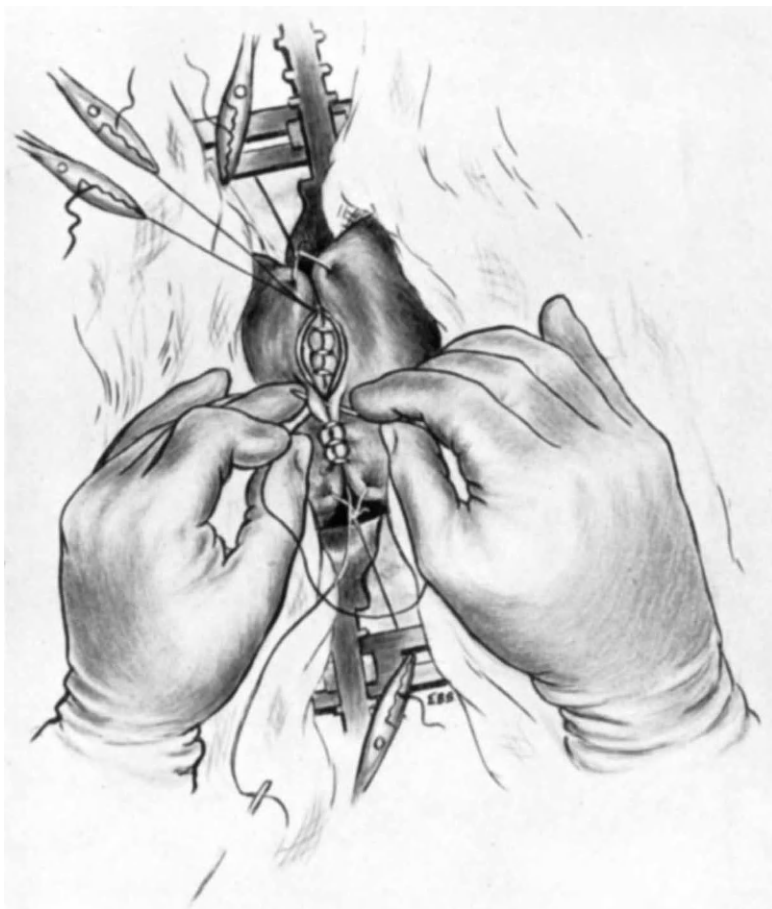


Fig. 324.—Suture of the anterior tier of the seromuscular layers.

The anterior rows of mucous membrane, seromuscular, and serous sutures are next completed, the suturing being carried out away from the operator (*Figs. 323–325*).

As each layer is finished it is painted with tincture of iodine. This antiseptic precaution is specially necessary when the contents are of low acidity and therefore probably not sterile—for example, in gastric cancer.

An anastomosis is thus made in three layers without the aid of clamps, and every bleeding vessel is tied. These are cardinal principles which ensure almost certain healing in sutured segments of bowel.

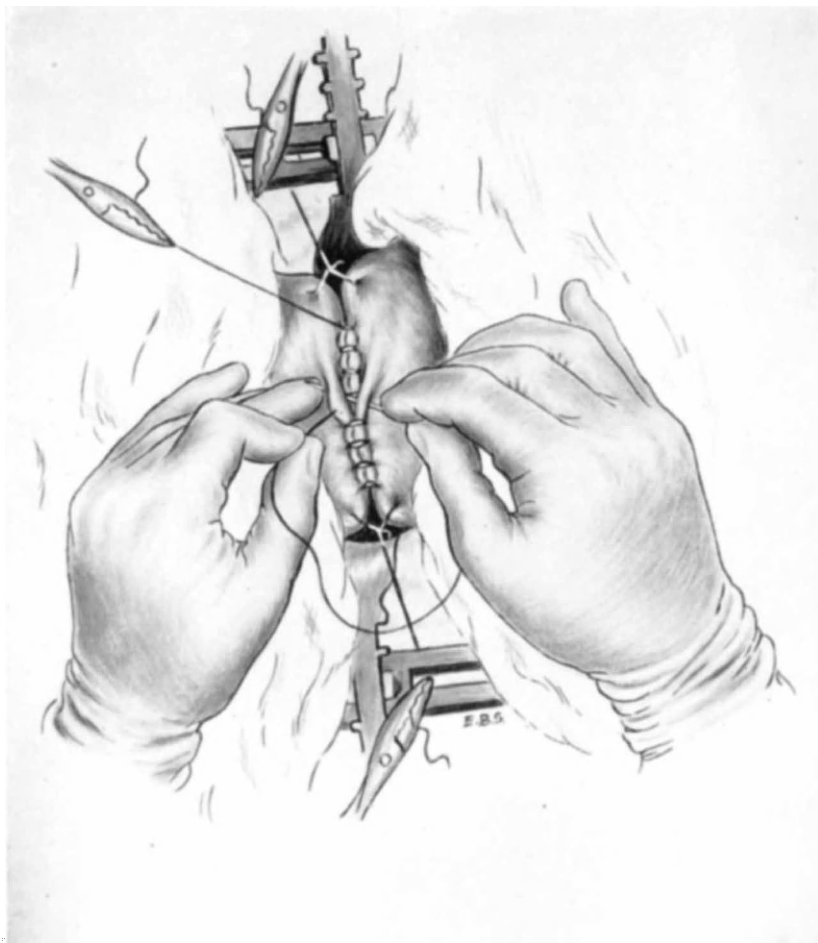


Fig. 325.—Suture of the anterior tier of the serous layer.

With the object of avoiding kinks of the afferent and efferent loops as they enter and leave the anastomotic opening, the sero-muscular sutures should be about 18 mm. ($\frac{3}{4}$ in.) longer than the actual opening in the stomach. It is important to take special care to avoid in the efferent loop as it leaves the stoma a kink or shoulder which would place the wall of the jejunum as an opposing surface to

the jet of acid chyme, and therefore in the same relative position as the anterior lateral wall of the duodenum (the favourite site for duodenal ulcer). Such a kink or shoulder would predispose to the formation of jejunal ulcer.

The anastomosis is now drawn through the opening in the transverse mesocolon, to which it is so anchored by means of interrupted sutures placed in the stomach that it projects about 2.5 cm. (1 in.) below the mesocolon opening (*Fig. 326*). The more

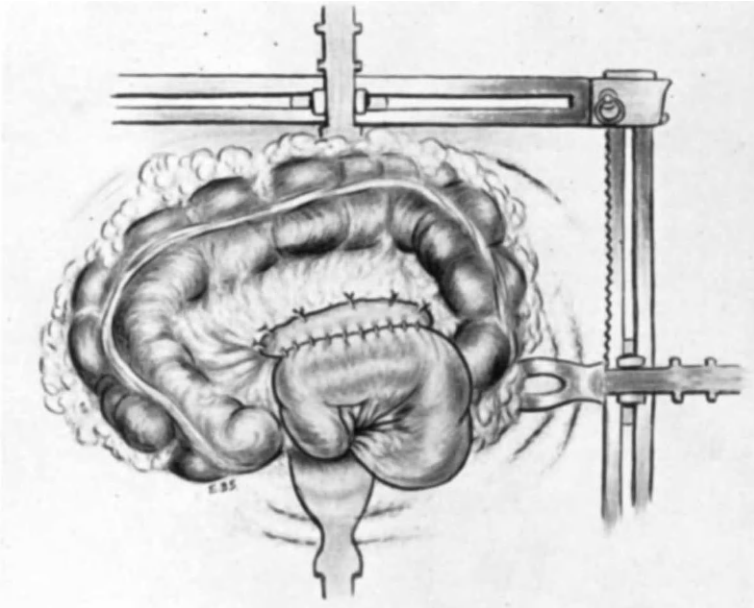


Fig. 326.—Showing the anastomosis well below the mesocolic opening and the stomach sutured into it.

the stomach can be made to project comfortably into the greater peritoneal sac, the less likelihood is there of the formation of torsions, angles, or shoulders where the afferent and efferent loops approximate the stomach. One of my objects in placing the stoma on the greater curvature is to attain this end in the small stomach.

The omentum is now displaced upwards so that it will lie behind the abdominal wound and thus keep the small intestines from adhering to the scar in the abdominal wall. It does not matter if they adhere to the omentum, but it does if they adhere to the abdominal wall.

The wound in the abdominal wall is closed in the usual way.

CHAPTER XLVI

PRINCIPLES ON WHICH GASTRIC RESECTION IS BASED

PRINCIPLES UNDERLYING THE TECHNIQUE OF ALL
METHODS OF GASTRIC RESECTION

IMPORTANT principles underlying all methods of gastric resection are : preliminary mobilization of the duodenum ; complete hæmostasis ; aspiration of gastric contents ; deflation of stomach ; separate suture of each layer of the gastric and jejunal walls ; and selection of the proper method of gastro-intestinal anastomosis to suit the case.

Preliminary Mobilization of the Duodenum.—Preliminary mobilization of the duodenum has a distinct value in the technique of gastric surgery, making the closure of the duodenum easier in the case of partial gastrectomy, and the resection of a duodenal ulcer much less dangerous in the case of partial gastrectomy and duodenectomy. As a preliminary to a difficult partial gastrectomy, it should always be considered.

The second part of the duodenum is mobilized by Kocher's method. An incision 3 cm. in length is made over the peritoneum on the lateral border of the descending part of the duodenum. The flap of peritoneum with the second part of the duodenum and the head of the pancreas is separated from the posterior wall by blunt dissection. In order to mobilize the first part of the duodenum, an additional incision is made over the peritoneum of the anterior layer of the duodeno-hepatic ligament just where this layer joins the superior part of the duodenum. The first part of the duodenum can then be gently drawn downwards without causing any bleeding. Thus, by employing these two simple methods, the duodenum can be almost completely mobilized, drawn forward, and any manipulations on it facilitated (*Figs. 327, 328*).

The mobilization of the duodenum is of particular value if a Billroth I type of partial gastrectomy is to be carried out ; but it is of use in any form of partial gastrectomy, particularly in that for carcinoma of the pylorus, in which it enables the cut end of the duodenum to be more easily infolded by suture—often a difficult procedure in gastrectomy for carcinoma in this position.

The Attainment of Complete Hæmostasis.—In making a gastro-intestinal anastomosis after gastric resection, sutures should not be relied upon for obtaining hæmostasis. In the first place, if they are sufficiently tight to stop bleeding, they must necessarily interfere with the circulation in the coapted edges of the stomach and intestine and therefore with normal healing. In the second place, the vessels in

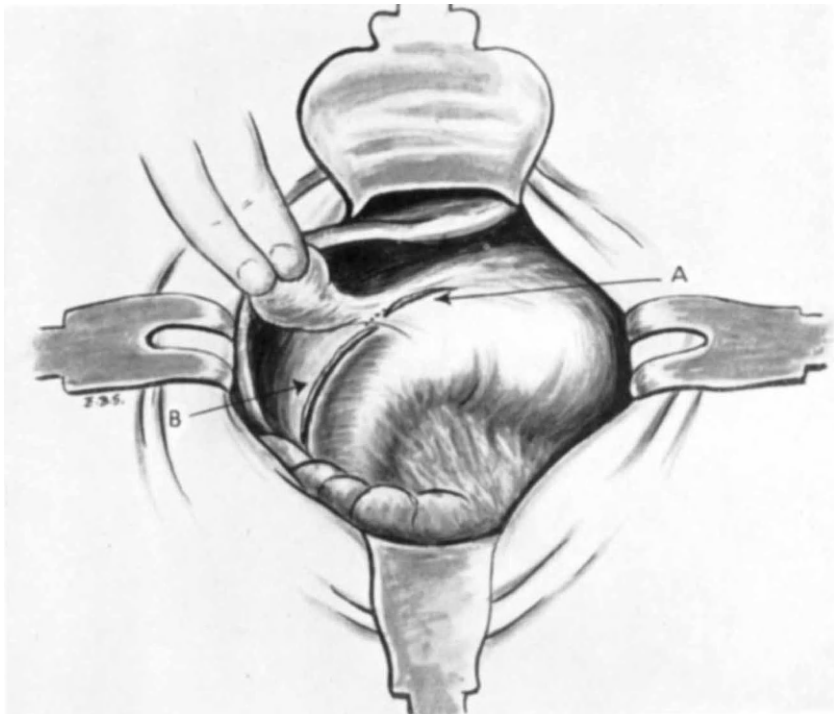


Fig. 327.—A, Incision over the superior border of the first part of the duodenum, which is continued into incision B over the lateral border of the second part. The first and second parts are now mobilized and can be brought forward into the abdominal wound, as shown in *Fig. 328*.

big gastric resections are so large that hæmostasis by means of suture is unreliable. Much of the shock and collapse following gastric resections in which the bowel-clamp and suture method are relied on for the control of bleeding is due to a quiet hæmorrhage. Where there is no post-operative oozing there will be little post-operative shock.

It is therefore inadvisable to use clamps for their tourniquet-like action. If they are used in order to retain gastric contents

temporarily, they must be released momentarily in order to allow bleeding to take place, so that it can be recognized and dealt with. To attain complete hæmostasis, vessels must be clamped and tied as they bleed (*see Fig. 388, p. 503*).

Aspiration of Gastric or Intestinal Contents.—If occluding clamps are not to be used to prevent soiling of the peritoneal cavity,

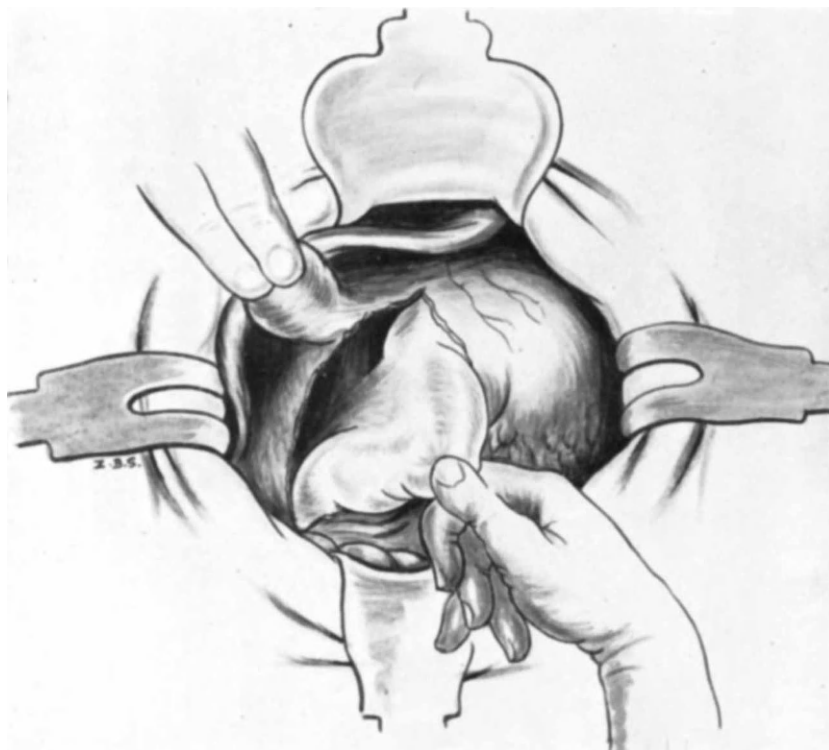


Fig. 328.—Dislocation of the first and second parts of the duodenum and the head of the pancreas.

then a suction pump must be employed to aspirate the gastric contents. As the patient lies on the operation table the gastric contents will be found in a pool in the fundus of the stomach; that is, towards the left cupola of the diaphragm.

Deflation of the Stomach.—As a preliminary to a gastric resection, the stomach, which at operation is usually abnormally distended with air, must be deflated by aspiration. The collapsed stomach is easier to manipulate and permits of more accurate suturing. (*Figs. 329, 330.*)

Separate Suture of Each Layer.—When anastomosing the cut ends of the stomach, duodenum, or jejunum, the three layers—mucous membrane, seromuscular, and serous membrane—must be

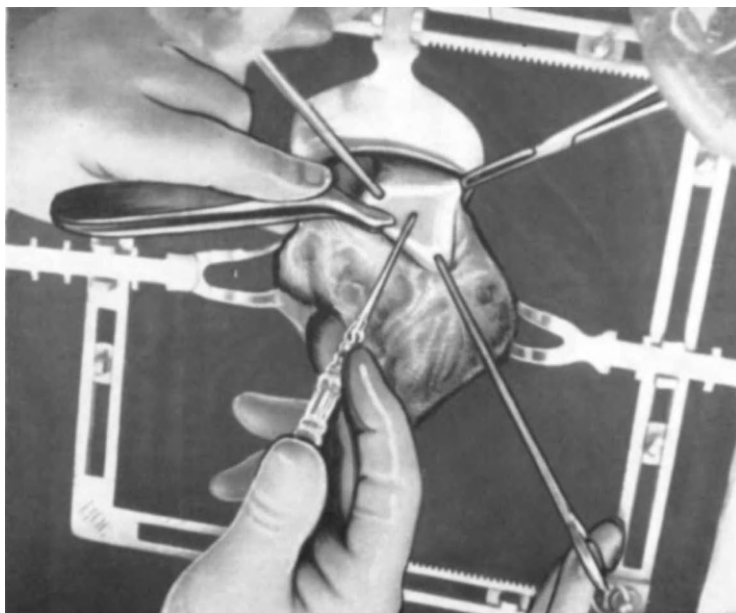


Fig. 329.—Photograph showing an air-distended stomach being aspirated of air as a preliminary to a gastric operation. A small area of the stomach is stretched by three Allis forceps as shown. Through this tightly stretched area the aspirating trocar is plunged.

separately sutured, as illustrated in Chapter XLV. For reasons given on pp. 369, 370 this method of suturing is the most physiological way of repairing wounds of hollow viscera. It is also an advantage that this three-tier suture can be made probably as quickly as and more neatly than the usual two-layer suture.

The Type of Gastro-jejunal Anastomosis.—Another important principle underlying the performance of gastric resections is that the particular type of gastro-intestinal anastomosis which suits the circumstances of the particular case should be employed.

Methods which fulfil different requirements are: the Billroth I, the Billroth II, the Polya, and the Schumaker. The stomach can be united to the intestine by that one of these methods which best suits the pathological circumstances present in a particular case. For example, the Schumaker should be employed for an ulcer of the

lesser curve, the Polya short-loop for duodenal ulcer, and the Billroth I or II for a gastric resection in a weak woman with poor gastric musculature.

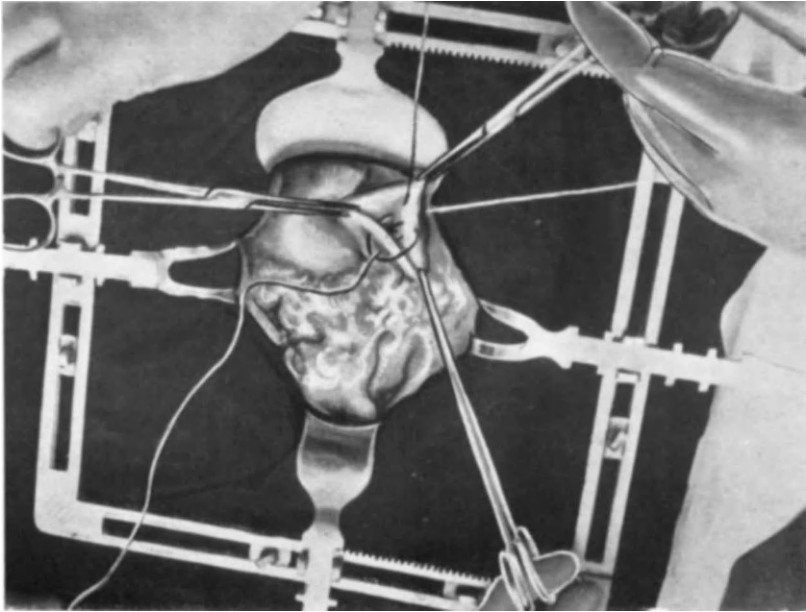


Fig. 330.—Photograph showing the small opening in the stomach made by the trocar being closed by one suture. This suture is then covered by using an X suture as shown in *Fig. 243* (p. 342).

VARIATION IN THE TECHNIQUE OF PARTIAL GASTRECTOMY

The technique of partial gastrectomy will vary according to the pathological condition for which it is required; that is, according to whether it is to be employed for a gastric carcinoma, a duodenal ulcer, a gastric ulcer, a jejunal ulcer, or a lesion in a stomach with feeble musculature.

Partial Gastrectomy for Carcinoma of the Stomach.—

Operation begun at the Fundal End.—As a general rule, in partial gastrectomy for carcinoma of the stomach, the operation should be started in a region which is as far away from the seat of the disease as possible. For example, if the carcinoma is close to the pylorus, the operation should be commenced at the proximal end of the stomach, as shown in *Fig. 331*, a photograph of the beginning of a partial gastrectomy for carcinoma of the stomach.

The reason for starting the operation at the fundal part of the stomach is, that the difficult and therefore the critical part of the operation lies in the dissection of the gastric carcinoma from the head of the pancreas and the lymph-glands—generally carcinomatous—in

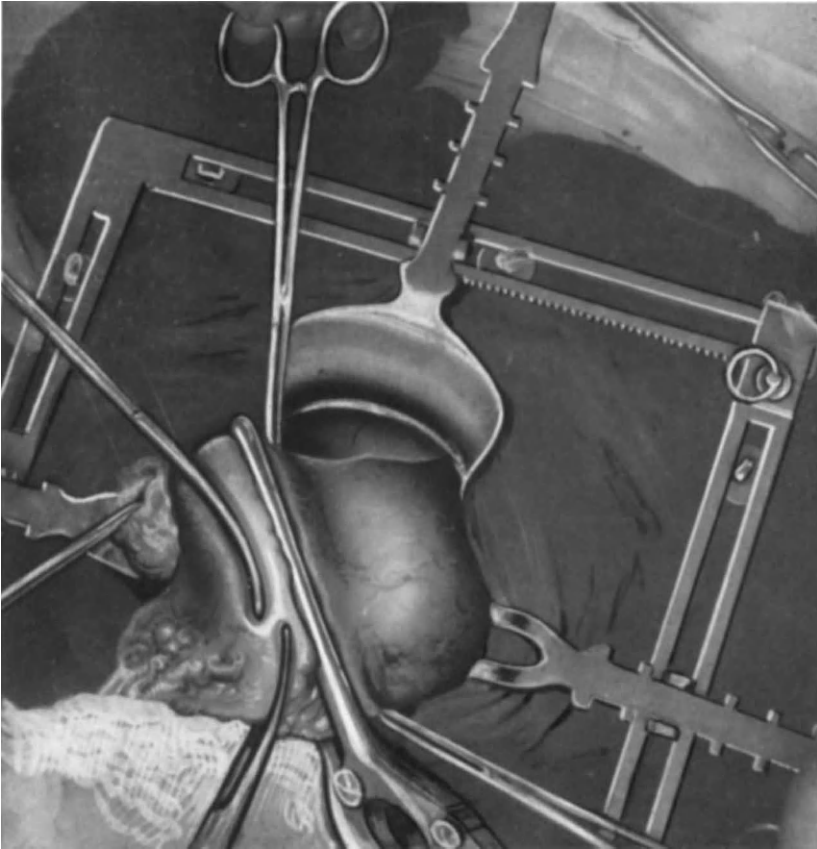


Fig. 331.—Partial gastrectomy for carcinoma situated in the pyloric part of the stomach. The operation is started by placing clamps on the stomach at the level where the division should be made proximal to the lesion. The photograph also shows the extent of the exposure of the stomach given by the operating frame.

this neighbourhood. Consequently, the posterior surface of the distal part of the stomach, the head of the pancreas, and the glands in this region must be freely exposed, so that a careful dissection *en bloc* with adequate illumination can be made. If the operation is commenced by dividing the duodenum first, malignant glands in its vicinity are liable to be bruised and their contents disseminated,

because the dissection which follows the division of the duodenum must necessarily be cramped.

An additional reason in favour of commencing the operation at the fundal end is that, in carcinoma of the distal part of the stomach, the transverse mesocolon with its contained middle colic artery is nearly always adherent to the posterior surface of the distal part of the organ.

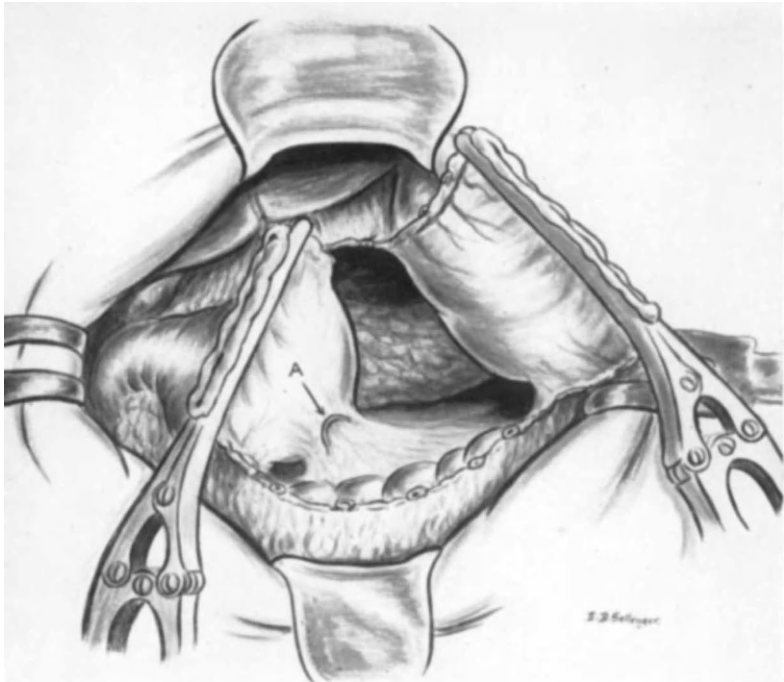


Fig. 332.—Stomach divided at the junction of the proximal third and distal two-thirds, and the distal part turned over. A, Middle colic artery.

Fig. 332 shows the stomach divided at the junction of the proximal third and distal two-thirds, and the distal part of the stomach turned over. A vessel A, apparently lying in its posterior wall, can be seen. This vessel is the middle colic artery lying in the transverse mesocolon which, as a result of carcinomatous adhesion, has become 'back-washed' and adherent to the posterior wall of the stomach.

If the dissection is started from the duodenal end, this important artery is liable to be injured. On the other hand, if the dissection

is started proximal to the disease, the transverse mesocolon and its artery are easily defined in the undiseased area. They can then be followed into the diseased area and thus be protected from injury.

Partial gastrectomy for gastric carcinoma requires extensive removal of the diseased area in the stomach, the lymphatic glands draining this area, and the omenta attached to this section of the

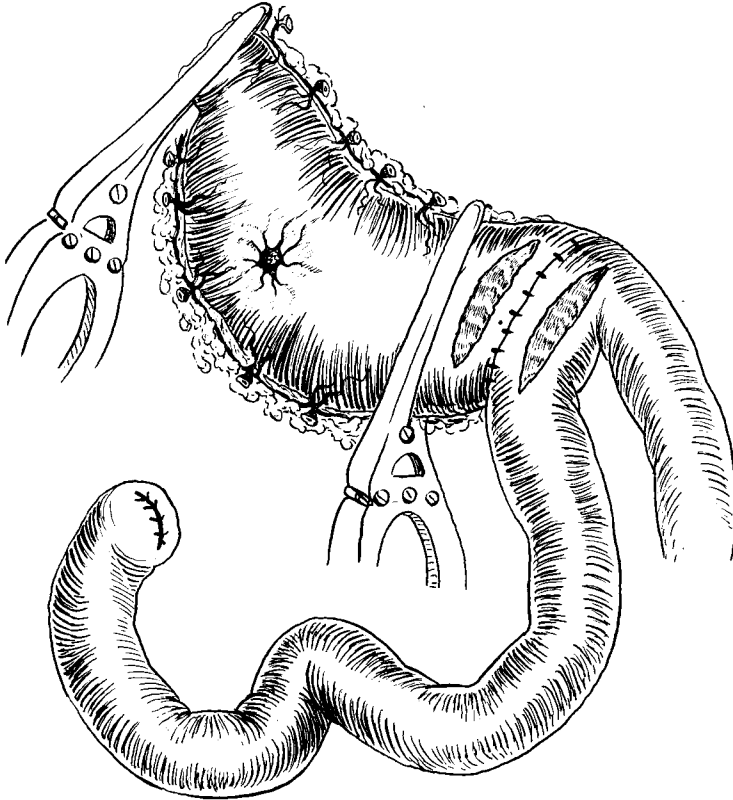


Fig. 333.—The stomach divided at the first part of the duodenum and held up so as to expose and dissect a carcinoma of the middle of the stomach, and to use the stomach as a tractor and thus aid in making the anastomosis. (After Balfour and Eusterman.)

stomach. The extent of the stomach removed will, of course, depend on the extent of the disease, but in extensive disease little of the stomach should be left: the more extensive the removal the more favourable the ultimate outlook.

Partial gastrectomy for carcinoma also requires that special precautions should be taken to avoid the formation of angles or kinks at that part of the gastro-jejunal anastomosis (Polya) which is situated

at the cut end of the lesser and the greater curvatures. Kinks are liable to form in these regions because the stomach is usually small and contracted to start with; and because after a lot of the stomach is removed the stump in consequence is small, and tends to retract towards the cardiac orifice, and to drag the jejunum into kinks at the points where it joins the stomach. This kinking is especially to be avoided in a partial gastrectomy for carcinoma of the stomach, because even when the kinking is slight it causes a mild upper intestinal obstruction, and with very little *vis a tergo* in the partially paralysed gastric stump a gastroduodenal stasis results, which quickly turns the scale in the weak malignant subject.

Further, in partial gastrectomy for carcinoma an unabsorbable suture—fine silk or linen—should be used in the outer layer of the gastro-intestinal anastomosis. With a silk suture in the outer layer, the convalescence immediately after the operation is much smoother. The reasons for this are that there is much less local peritonitis after non-absorbable sutures than after catgut sutures; and that suture insufficiency, the result of the poorly vitalized and slow-healing tissues—one of the dangers of the operation in the case of carcinoma—is guarded against.

Non-absorbable sutures should, of course, not be used in a partial gastrectomy for duodenal ulcer, because, in the presence of high acidity, they may form the basis or nucleus of a jejunal ulcer.

Operation begun at the Duodenal End.—Sometimes, in the case of carcinoma in the proximal part of the stomach, it may be necessary to begin the operation of partial gastrectomy at the first part of the duodenum. This may be necessary for two reasons: (1) because the stomach will have to be divided fairly close to the cardiac orifice, and the making of an anastomosis so high can be carried out more easily by using the whole stomach as a tractor, in the manner shown in *Fig. 333*; and (2) because it is always a good principle to proceed from the undiseased (here the pyloric) region to the diseased, so that this area is the last to be approached, and therefore the most freely exposed.

Partial Gastrectomy for Duodenal Ulcer.—In the case of partial gastrectomy for duodenal ulcer it may be taken as a working rule that duodenal ulcer is usually caused by a high gastric acidity. On this assumption a sufficient amount of the acid-forming part of the stomach must be removed to reduce the acid concentration to such an extent that a jejunal ulcer will not develop. But care must be taken not to remove too much, for a peculiar form of chronic gastritis sometimes follows extensive resection of the stomach; and

it is not unreasonable to suppose that this form of gastritis may be due to exogenous infection, which, in the absence of the antiseptic action of the normal percentage of hydrochloric acid, can take place.

Too much stomach must not be removed for another reason. Castle has shown that the stomach contains a substance which he calls an 'intrinsic factor'. This acts on an 'extrinsic factor' in

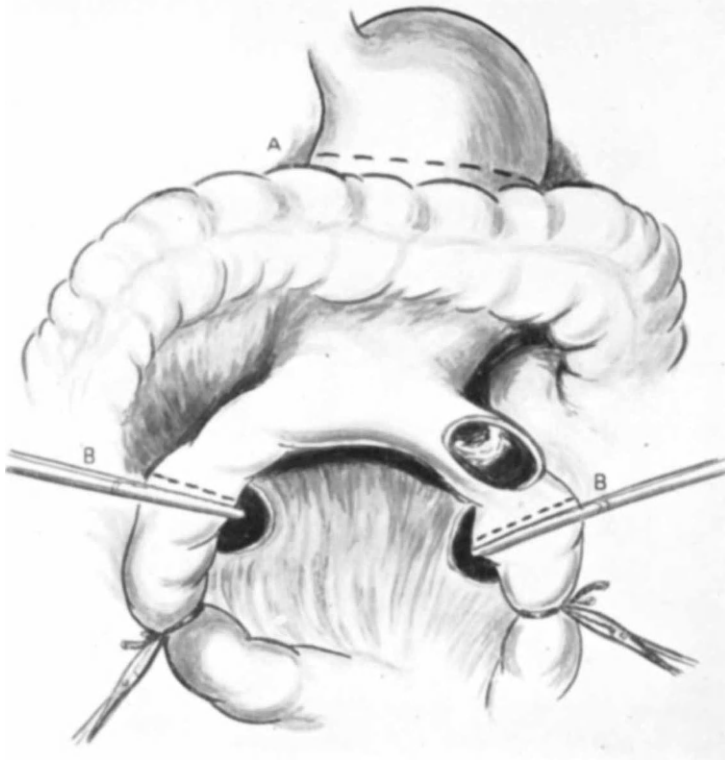


Fig. 334.—Method of attacking jejunal ulcer by dividing the small intestine and the stomach in normal regions. *See text.*

certain foods, and liberates a hæmatinic principle which is absorbed and stored mainly in the liver. An extract of the whole stomach contains this principle and is curative in pernicious anæmia. As far as can be ascertained, this substance resides mostly in the pyloric part of the stomach. Hence, if too much of the stomach is removed, a severe anæmia, closely resembling pernicious anæmia, may result.

In partial gastrectomy for duodenal ulcer, not much more than, and not less than, two-thirds of the stomach should be removed. The

gastro-intestinal anastomosis should not be made after the Billroth II method, but according to the Polya principle. The gastro-intestinal anastomosis should be made retrocolically, so that the opening in the jejunum will be as near as possible to the duodenum. And on no account should an entero-anastomosis be made.

Partial Gastrectomy for Gastric Ulcer.—In partial gastrectomy for gastric ulcer it is not necessary, for acid-reduction purposes, to remove such a large section of the stomach as in the case of duodenal ulcer, because gastric ulcer is not as a rule associated with such a high gastric acidity as is duodenal ulcer; in fact, it may be lower than

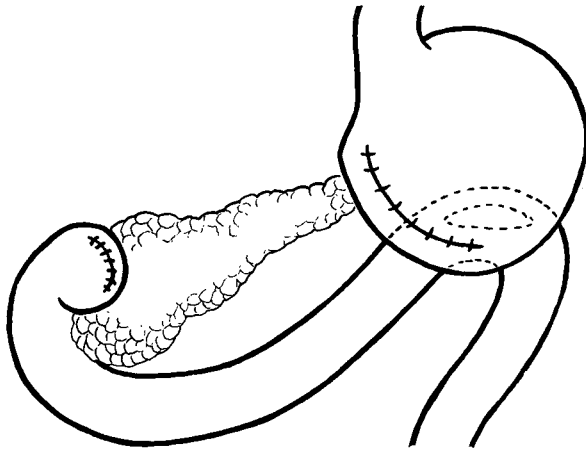


Fig. 335.—Diagram showing Billroth II method performed in women, with small gastrojejunal anastomosis.

normal. It is, however, essential that, as well as the ulcer-bearing area, a fairly wide region around this should be removed, since the ulcer is usually accompanied by surrounding tissue changes and a secondary gastritis.

Partial Gastrectomy for Jejunal Ulcer.—In partial gastrectomy for jejunal ulcer, there are so many adhesions and difficulties that the patient may die from the magnitude of the operation. A most important principle, therefore, is to save time by an operation carefully planned and boldly carried out. Acting on this principle, the surgeon should make no attempt to approach the adherent inflammatory mass in the vicinity of the jejunal ulcer, but should commence the operation in a normal area; he should divide the stomach and also the jejunum through normal tissue well away from the adherent ulcer site. *Fig. 334* shows a sketch of an operation for jejunal ulcer

following a limited partial gastrectomy. The stomach is divided at A, and the intestine at B, B.

When the inflammatory area has been isolated and devascularized, the adherent jejunal ulcer with its surrounding structures can be removed without much difficulty by following tissue planes. In this way an amount of normal intestine is no doubt unnecessarily removed, but this is not of practical importance; the important fact is that the carrying out of a considerable part of the operation through normal structures greatly lessens the magnitude and therefore the danger of the operation.

Partial Gastrectomy where the Gastric Musculature is Feeble.—In neurasthenic women, whose intestinal muscle may be feeble, the opening between the stomach and the jejunum should be made as small as possible. If it is made large, the contents of the stomach are ‘dumped’ into the weak-muscled intestine, thereby giving rise to an unpleasant nauseous sensation and other symptoms after meals. In women, therefore, the stomach is best joined to the intestine by the Billroth I or II method (*Fig. 335*).

CHAPTER XLVII

THE TECHNIQUE OF PARTIAL GASTRECTOMY:

I. THE CHOICE OF ANÆSTHETIC

IN the case of partial gastrectomy, the choice of anæsthetic is a particularly important factor in the success of the operation.

Pulmonary complications are prone to occur after all operations in the upper part of the abdomen, but particularly following partial gastrectomy. A general anæsthesia, especially if unskilfully administered, predisposes the patient still further to such complications. Local, spinal, or gas anæsthesia may be chosen with a view to lessening their incidence.

The toxic and general effects of a general anæsthesia contribute somewhat to the increase of post-operative shock, which, because the upper part of the abdomen is very richly supplied with splanchnic nerves, is often severe in operations in this region. Local anæsthesia, on the other hand, ensures the least shock and the least post-operative circulatory disturbance; but it has the disadvantage that it does not permit of free access to the diseased parts, and therefore does not permit thorough, skilful, and radical operating. It may, however, be the best choice of anæsthetic in patients with bad circulatory affections, or in carcinomatous cases.

The selection of an anæsthetic should therefore be carefully made, and should involve a consideration of all the circumstances connected with the operation. It will lie between the methods of anæsthesia described below.

Light Ether.—If the patient is young, or in good condition, or if the operation is for an ulcer and not for carcinoma, then warm vaporized ether sparingly given—‘light ether anæsthesia’—may be administered with a little or no preliminary narcosis. A surprisingly small amount of ether suffices if the surgeon is gentle in his manipulations, and if the anæsthetic is cleverly administered.

There are four main factors in the successful administration of this ‘light ether anæsthesia’: (1) vaporization of the ether, so that the dose can be uniformly graded; (2) very slow induction; (3) early insertion of a pharyngeal tube; (4) gradual reduction of the anæsthetic to a minimum after the operating frame has been

inserted, and while manipulations are being carried out on the insensitive viscera.

The relaxation and comfort obtained by this method of anæsthesia allow the full skill of the surgeon to be effective. With such a lightly administered ether anæsthesia, remarkably little post-operative shock follows a gentle, skilful operator. It is certainly the anæsthetic for the surgeon of moderate skill, for the advantages of a gas anæsthesia are lost if the surgeon is not skilful enough to control the prolapsing intestines. The shock caused by the exposure and replacement of the intestines is greater than that in the relaxed-muscle conditions of the more toxic 'light ether anæsthesia'.

In few circumstances do I allow ethyl chloride to be given in order to facilitate the induction of this ether anæsthesia, for in my opinion it greatly increases the danger of a difficult partial gastrectomy; the patient does not last out the big operation so well.

In a long experience of gastric surgery I have discouraged the lavish use of preliminary narcotics with ether anæsthesia. In the hands of the skilful etherist they are unnecessary, and they diminish the activity of the breathing centre, the normality of which is so important during the immediate post-operative hours.

Gas and Oxygen.—Of all anæsthetics that can be used in gastric surgery, gas and oxygen is the safest. It should be preceded by a narcotic, the most effective and least harmful of which is morphia ($\frac{1}{8}$ gr. of morphia or omnopon and $\frac{1}{150}$ gr. of atropine), and it should be employed in combination with the operating frame. Used in this way it does not limit the operative ambit of the surgeon.

In the sthenic type of patient an exaggerated respiratory excursion may embarrass the operator. This difficulty, however, can be overcome. The respirations can be damped down by giving the gas under light pressure through an intra-tracheal tube introduced through the nose, after the method of McGill; and the prolapse of intestines caused by the tense muscles can be avoided by the skilful use of the operating frame and its intestinal 'mechanical hands'. In a few cases it may be necessary to supplement gas and oxygen with a little ether now and then, and only for a few minutes, where a little deeper relaxation may be required for a specially difficult part of the operation. It is better, in the very big gastric operation, to give these 'supplements' of ether rather than to combine the gas and oxygen with large doses of morphia or hyoscine or basal narcotics such as avertin. The rests from the more or less prolonged anoxæmia are also good.

In certain types of patients—especially extremely nervous ones—avertin may be given rectally as a basal narcotic. In small doses—0.5 gr. to 0.8 gr. per kilo—and combined with gas and oxygen, this anæsthesia is ideal, for it is pleasant for the patient and minimizes psychic shock, and satisfactory for the surgeon. The addition, however, of any really effective basal narcotic to gas and oxygen somewhat lessens the power of the patient to stand up to very long gruelling operations.

In the asthenic patient who is bloodless or emaciated, gas and oxygen forms by far the best anæsthetic and requires very little pre-narcotic. Very feeble patients take this anæsthetic well, and in such patients sufficient relaxation is obtained.

Cyclopropane.—Cyclopropane is a gas anæsthetic which in its anæsthetic property stands halfway between nitrous oxide gas and ether, and it is therefore a satisfactory anæsthetic for operations on any part of the alimentary canal, but particularly for those in its upper part—the stomach, duodenum, and gall-bladder. Any injurious effects it may, as a general anæsthetic, exert on the body are less than those of ether and more comparable with those of nitrous oxide gas. Its advantage over the latter anæsthetic is that it gives much greater relaxation of the abdominal wall.

The administration of cyclopropane is associated with a rise in blood-pressure. This rise improves the pulmonary circulation, and lessens (or should lessen) the post-operative lung complications which are so frequently the result of a low-pressure pulmonary circulation. It does, however, increase the bleeding during the operation, but this is a good thing, because if all bleeding is properly stopped, as it should be, that slight reactionary hæmorrhage that sometimes follows an operation in which the blood-pressure is diminished by the anæsthetic does not occur.

The operation is started by giving oxygen to the patient in a closed apparatus provided with a soda-lime container to absorb the carbon dioxide. Cyclopropane is then slowly administered until the patient comes under its influence.

The criteria of satisfactory anæsthesia are the same as those for any other anæsthetic.

It should be specially emphasized that a disadvantage of this anæsthetic is its inflammability.

Cyclopropane can be administered in conjunction with nitrous oxide or ether.

Evipan.—With the present vogue of intravenous anæsthesia or medication, it is an advantage to have an apparatus for the exact

automatic intravenous or intramuscular administration of small quantities of any drug over a fairly long period of time.

The apparatus* here described was designed by Dr. John Devine, primarily for the slow administration of evipan. It can supply up to 10 c.c. of fluid automatically over a period of 30 minutes. (*Fig. 336.*)

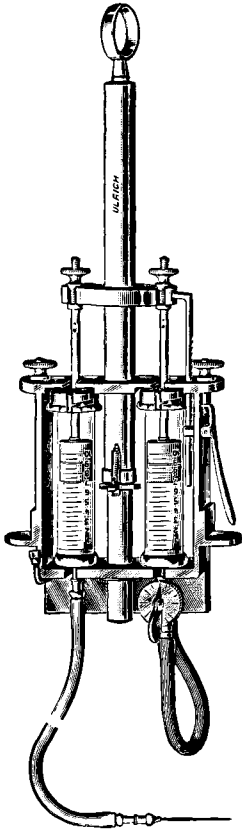


Fig. 336.—Syringe for the automatic, slow, and exact administration of evipan or other drug.
(Designed by Dr. John Devine.)

The apparatus consists of two syringes coupled barrel to barrel, plunger to plunger. To one syringe is connected rubber tubing and a hypodermic needle, to the other one (the control syringe) a reservoir by way of a control tap. This latter syringe controls the rate of administration of the drug. The plungers of both syringes are pushed home by means of a powerful spring sufficiently strongly to be unaffected by differences of resistance in the veins or tissues. The rate of release of the plungers is controlled by the flow of fluid from the control syringe by way of the control tap in the reservoir.

The apparatus is provided with a clicking device, which connects with a serration and makes an audible click with the passage of every $\frac{1}{2}$ c.c. of fluid.

In cases where finer observation of the amount of fluid administered is required, the reservoir may be disconnected, a fine hypodermic needle substituted, and the drops from this watched, and if necessary counted.

It has been found that if only one syringe and a spring is used, differences in venous pressure affect the flow, and that therefore it is very difficult to control the rate of flow accurately.

The fluid used in the control syringe can be either water, or light oil if the time of administration is very long.

By loosening the wing nuts, the apparatus may be taken to pieces in a few seconds for sterilization.

It will be found that the use of this apparatus simplifies and

* Made by Heinrich C. Ulrich, Ulm.

standardizes the slow measured method of giving evipan, on the exactness of which its safe use depends.

Local Anæsthesia.—Local anæsthesia is useful when dealing with very sick patients suffering from gastric carcinoma. Not infrequently in these patients I have been able with the aid of local anæsthesia successfully to remove large, fungating, ulcerating carcinomas. And the results of these removals have been worth while, for the malignancy of these apparently inoperable tumours is not as bad as it would appear; they are a papillomatous type of growth, and are usually less malignant than the small growths which infiltrate.

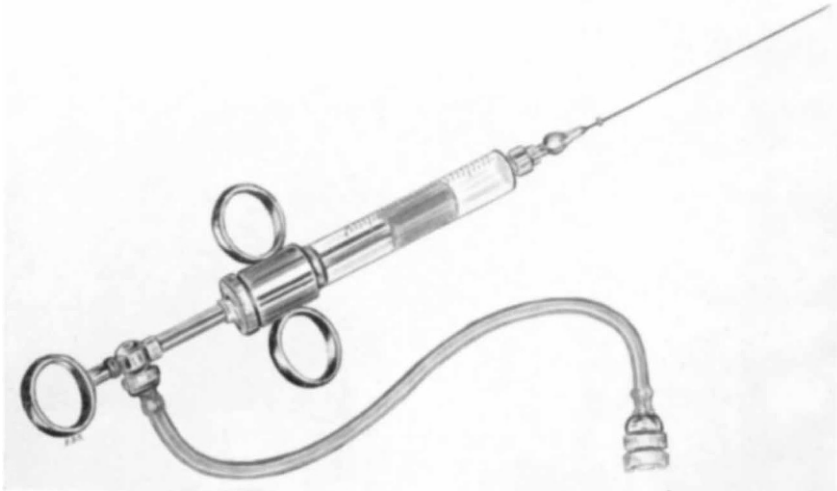


Fig. 337.—Pitkins' self-filling syringe for local anæsthesia.

Although local anæsthesia may be regarded as the safest anæsthetic in partial gastrectomy for carcinoma, it is not a method which can be used by everyone; for it cramps the full range of a surgeon's operative skill, and demands an operator highly skilled in gastric operations. In the hands of the 'occasional surgeon' it is more dangerous than general anæsthesia.

Technique of Local Anæsthesia.—The technique of local anæsthesia for partial gastrectomy is really an integral part of the operation, and must, therefore, be considered step by step.

It may be administered either by a syringe constructed for the purpose, or, in busy hospital practice, by Kirschner's high-pressure apparatus. A good syringe is depicted in *Fig. 337*—Pitkins' self-filling syringe, which fulfils all requirements.

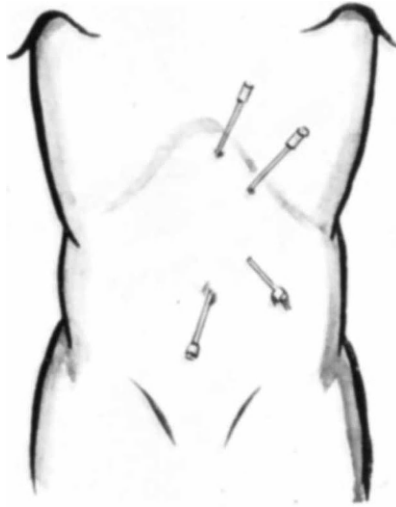


Fig. 338.—The subcutaneous fascia is first infiltrated.

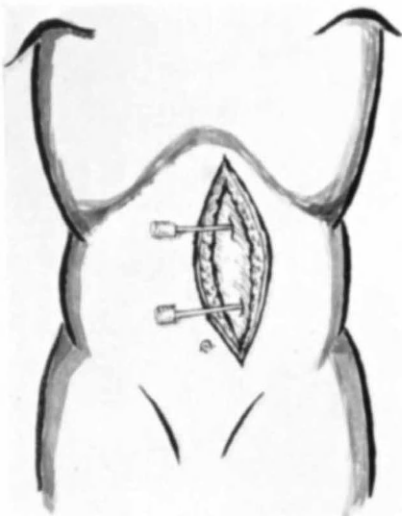


Fig. 339.—After the subcutaneous fascia is infiltrated, the incision is made down to the sheath of the rectus; an injection is made between the sheath and the muscle itself, and the needles are directed to the lateral side of the muscle, so as to catch the nerves as they enter it.

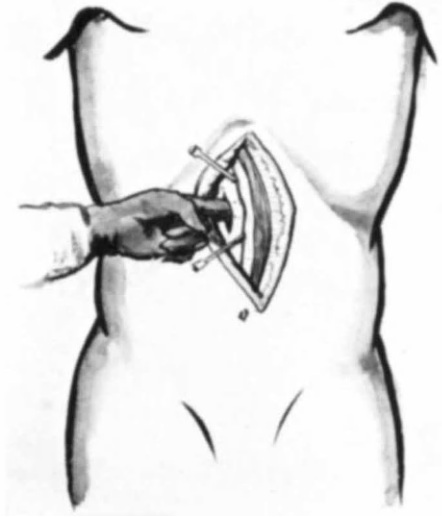


Fig. 340.—The rectus muscle is incised and the subperitoneal tissue is infiltrated by directing the needles into the subperitoneal space on both sides of the wound between the peritoneum and the posterior sheaths of the recti.

The abdominal wall is infiltrated and incised, layer by layer (the subperitoneal layer being extensively infiltrated), with 0.5 per cent novocain and adrenaline solution (*Figs. 338–340*).

When the peritoneum has been incised, the operating frame is gently inserted (*Fig. 341*). This exposes the stomach in order

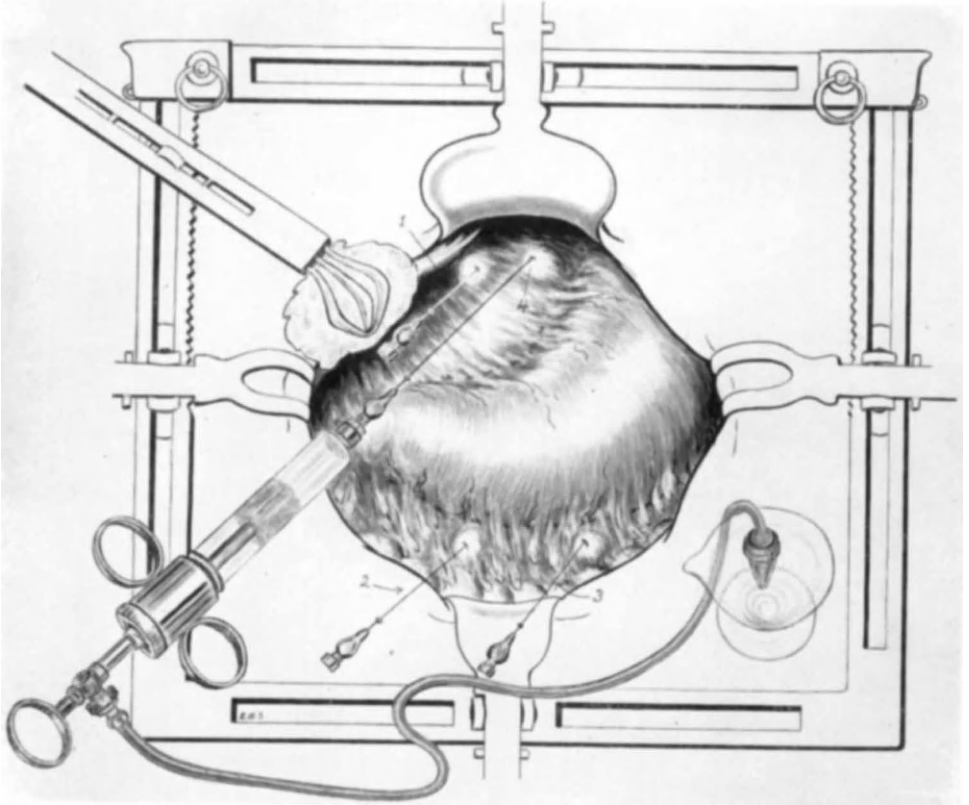


Fig. 341.—The operating frame is very gently inserted, and the gastrohepatic (1) and gastrocolic (2, 3) omenta are infiltrated, and also the vagus nerve (4).

that 0.5 per cent novocain solution may be used for the infiltration of the mesenteries, the anterior gastric plexus, the region where the vagus nerves enter the stomach, the subperitoneal plane near the cœliac plexus (*Fig. 342*), and the transverse mesocolon.

Kirschner's Method of High-pressure Anæsthesia—Kirschner's high-pressure local anæsthetic method facilitates the performance under local anæsthesia of operations on the upper part of the

alimentary tract, and especially gastric operations. It is suitable for a busy hospital operation clinic.

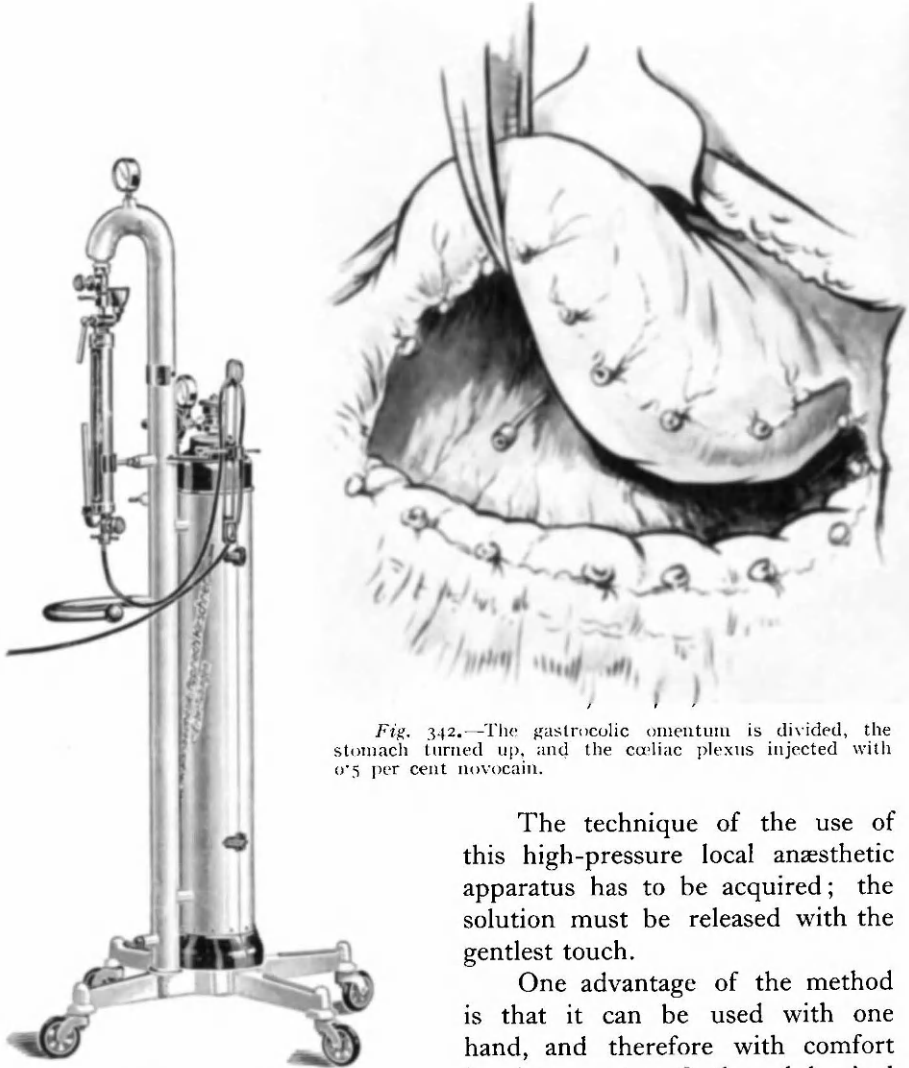


Fig. 342.—The gastrocolic omentum is divided, the stomach turned up, and the celiac plexus injected with 0.5 per cent novocain.

The technique of the use of this high-pressure local anæsthetic apparatus has to be acquired; the solution must be released with the gentlest touch.

One advantage of the method is that it can be used with one hand, and therefore with comfort in deep parts of the abdominal cavity. The apparatus is illustrated in *Fig. 343*.

Another advantage in abdominal work is that it œdematizes the tissues and displays all the planes, thus facilitating accurate dissection.

Local Anæsthesia Combined with 'Diffusion' Anæsthesia.—

Extensive gastric operations can be effectively carried out by a combined local and 'diffusion' anæsthesia. This is an anæsthetic method in which a novocain local anæsthesia of the abdominal wall and its peritoneum is combined with a peritoneal and mesenteric anæsthesia brought about by direct application of a weak solution of percaine. Percaine is a local anæsthetic drug which is peculiarly effective in producing anæsthesia of serous membranes, even when

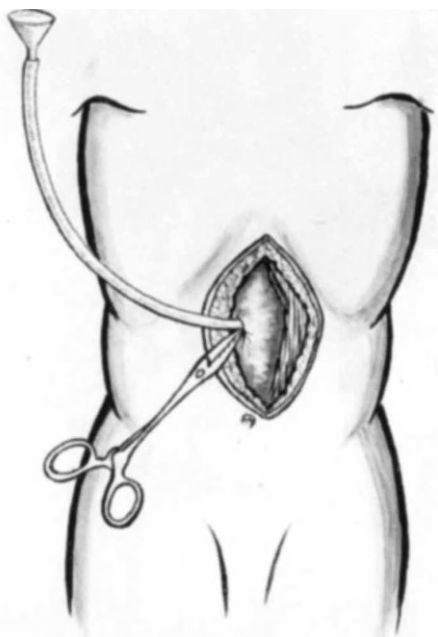


Fig. 344.—Vagosympathetic anæsthesia by injecting percaine solution 1-2000 into the peritoneal cavity in its upper part.

applied in very diluted solutions. Advantage is taken of this property to produce anæsthesia of the peritoneum, of the vagus nerves, and of the cœliac ganglia and the sympathetic nerves emerging from them. The method was introduced by Mandyl, and is called "Mandyl's diffusion anæsthesia". It is carried out as follows:—

When the peritoneum is reached in making the incision in the locally anæsthetised abdominal wall, a slight aperture is made in this membrane, a small rubber tube attached to a funnel is introduced (*Fig. 344*), and the opening is closed round the tube by clamping it with a Spencer Wells forceps. The patient is now placed in a slight

Trendelenburg position, and an injection of 50 c.c. of 1-2000 percaine solution is made into the abdominal cavity. Five minutes are allowed to elapse. After the peritoneum is opened, a further 50 c.c. is deposited in the lesser peritoneal cavity in the vicinity of the cœliac

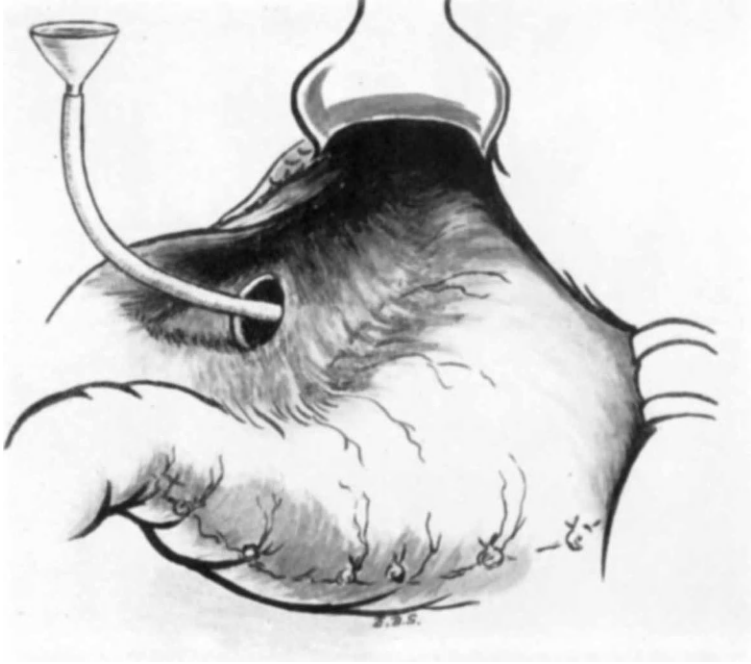


Fig. 345.—Injection of 50 c.c. percaine solution in the vicinity of the cœliac plexus.

plexus (*Fig. 345*). After a further lapse of five minutes, another 50 c.c. is poured into the peritoneal cavity with the patient at a normal level in order to anæsthetize the anterior gastric plexus. The patient is then ready for the gastric resection.

High Spinal Anæsthesia.—For spinal anæsthesia to be effective in a partial gastrectomy, it must extend as high as the nipple line. A spinal anæsthesia which reaches this level must cause extensive paralysis of the vasomotor system and thus a considerable lowering of blood-pressure. Added to the shock which is caused by an operation in the upper part of the abdomen like partial gastrectomy, this is a great disadvantage. A further disadvantage of spinal anæsthesia in gastric operations is that it does not anæsthetize all the sympathetic supply and the vagus nerves, which originate from the medulla.

If, however, it is essential that partial gastrectomy should be carried out under spinal anæsthesia, Kirschner's method of zonal percaine spinal anæsthesia, described below, is the best to use. If skilfully administered, it causes very little fall of blood-pressure. As it does not anæsthetize all the sympathetic supply and the vagi, it is used in combination with injections of 0.5 per cent novocain solution into the subperitoneal space around the cœliac axis and into the region of the vagus nerves round the cardiac orifice.

High spinal anæsthesia may be required for an operation on patients with pulmonary troubles in whom a chronic ulcer has penetrated either the pancreas or the liver. Under such circumstances, the surgeon will not only require to minimize post-operative pulmonary complications from the effects of a general anæsthetic, but he will also need good muscular relaxation in order that he may obtain unfettered access either to the ulcer on the posterior wall of the abdomen or to the region of the cardiac orifice of the stomach, where the lesser-curve ulcer lies attached underneath the left lobe of the liver. In a well-given high spinal anæsthesia the surgeon will obtain these requirements: the organs are presented to him, as it were, on a plate.

Kirschner's Improved Zonal Method of Spinal Anæsthesia.—

When I find it necessary to use spinal anæsthesia in the surgery of the alimentary canal, I employ Kirschner's *improved* method. It is simple and does not require any complicated apparatus. It can be localized to the abdomen (the lower extremity can usually be excluded) and therefore it involves little fall of blood-pressure. It lasts long enough for most abdominal operations.

The principles of the method are that the percaine solution is applied to a selected part of the spinal cord, and that the correct dosage is found by trial and error.

The technique is as follows:—

1. The patient is inclined, head down, at an angle of 25°, with his back, thighs, and knees flexed, and held in this position by a strap running round the knees and the back of his neck.

2. With a Kirschner's spinal needle the dura is punctured between the 11th and 12th vertebræ in operations on the upper part of the alimentary tract, and between the 1st and 2nd or 2nd and 3rd lumbar vertebræ in operations on the lower part.

3. Cerebrospinal fluid is aspirated until no more can be withdrawn. The amount may be from 20 to 30 c.c. In order to remove the last part of the cerebrospinal fluid—the part from the segment of cord to be anæsthetized—the patient is asked to cough.

4. With the lateral opening in the needle directed towards the head in the case of an upper abdominal operation, and towards the feet in a lower abdominal operation, $1\frac{1}{2}$ c.c. of a percaine solution which is lighter than cerebrospinal fluid (*see* formula below) is injected. The administration of the full amount is ensured by expressing the last drops out of the cannula by injecting one or two c.c. of air. The needle is then plugged and left in position.

5. Two c.c. of veritol are injected subcutaneously.

6. Five minutes are then allowed to elapse, when the extent and degree of the anæsthesia are tested. In the case of the puncture between the 11th and 12th vertebræ, the anæsthesia will be found to extend from the nipples to the groin. As a rule, the patient will be able to move his lower extremities and will have some sensation in them. Should the anæsthesia not be deep enough, or not have extended far enough, a further $\frac{1}{2}$ –1 c.c. of percaine solution is injected.

7. The operation takes place in the head-down position, and after the operation the patient is kept in this position for twenty-four hours.

The formula for Kirschner's percaine spinal zonal anæsthesia is as follows:—

Percaine	0.25	gramme
Dextrin	0.9	„
Alcohol (100 per cent)	11.6	„
Sodium monophosphate	0.2162	„
Sodium biphosphate	0.2126	„
Distilled water	ad	100.0	„

The solution is put up in ampoules by Ciba.

Headache is infrequent after this method of spinal anæsthesia. The fall in blood-pressure is not very great.

Pantopon gr. $\frac{1}{8}$ should be subcutaneously injected before operation.

In particularly nervous cases an ampoule of scopolamine and eukodal should be intravenously injected.

CHAPTER XLVIII

THE TECHNIQUE OF PARTIAL GASTRECTOMY:

II. THE STEPS OF THE OPERATION

I. The Incision.—The incision should be designed for the use of the operating frame; that is, as high as possible, and not too big (see p. 330). It is placed on the left of the midline, and paramedially (*Fig. 346*).

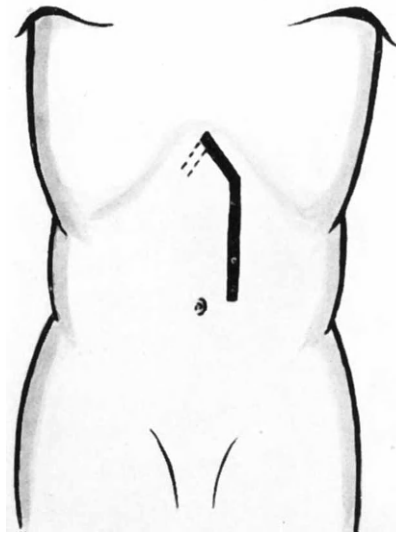


Fig. 346.—Incision extending from the ensiform cartilage along the lower border of the ribs for $1\frac{1}{2}$ in. and then down the rectus sheath paramedially.

This incision begins at the tip of the ensiform cartilage, extends for $1\frac{1}{2}$ in. along the lower margin of the thorax to the left, and then paramedially downwards over the rectus muscle, $\frac{1}{2}$ in. from its medial border, to within 1 in. of the umbilicus.

A valvular opening is made through the rectus muscle (*Fig. 347*): the anterior sheath of the rectus muscle is incised at B; the fibres of the muscle are separated longitudinally at C. The little

medial bundle of rectus muscle-fibres is left in order to have some longitudinal fibres running at right angles to the direction of the sutures, for the fibres of the rectus sheath run in the same

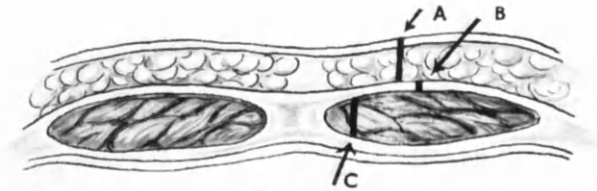


Fig. 347.—Cross-section showing the valvular nature of the incision. A, Skin incision; B, Incision in rectus sheath; C, Line of separation of muscle-fibres.

direction as that in which the sutures are placed, so that any undue strain can cause the catgut sutures to unravel these transversely running fibres and cut out.

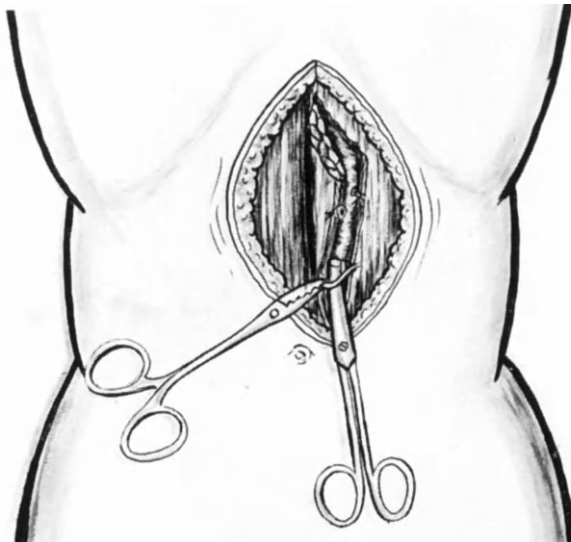


Fig. 348.—Diagram showing the separation of the vessels in the rectus and the clamping of these before they are cut. Note the small medial bundle of muscle-fibres which is left mesially.

Vessels in the rectus muscle are isolated, and clamped before they are divided, as shown in *Fig. 348*. By this manœuvre, extravasation of blood into the muscle is avoided.

The costal margin part of the incision is now completed. The rectus sheath and muscle is incised medially along the lower border

of the thorax towards the epigastric angle, where, if necessary, it may be extended a little over the midline. A small bunch of fibres of the rectus muscle must be divided transversely, but in this high situation this is unimportant, and the extra room obtained so high in

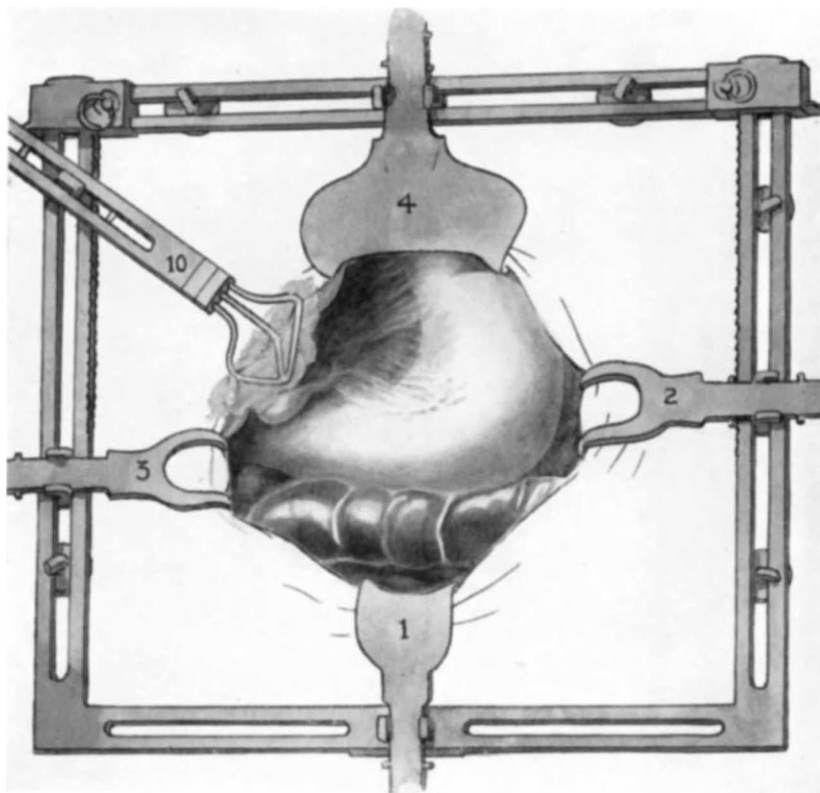


Fig. 349.—The stomach is here shown exposed by means of the operating frame, which permits not only the exposure of the stomach, but also the fixation of the dressings firmly into the wound. The left lobe of the liver is seen retracted medially by a small 'mechanical hand' so as to expose the upper part of the lesser curvature, a region in which an inflamed chronic gastric ulcer presents considerable operative difficulties.

the abdomen by the addition of this small transverse incision is of great advantage.

2. Exposure of the Stomach.—The edges of the wound are covered with waterproof towels, and wound retractors are inserted and clamped to the operating retractor frame (*Fig. 349*).

The use of this retractor mechanism permits of the full opening of the wound under gentle pressure, and of the complete exposure of

the stomach. Its use also enables the towels to be securely clamped to the edges of the wound so that they cannot be disarranged by subsequent manœuvres; and its employment, therefore, protects the wound from soiling by gastric or intestinal contents, and thus from infection.

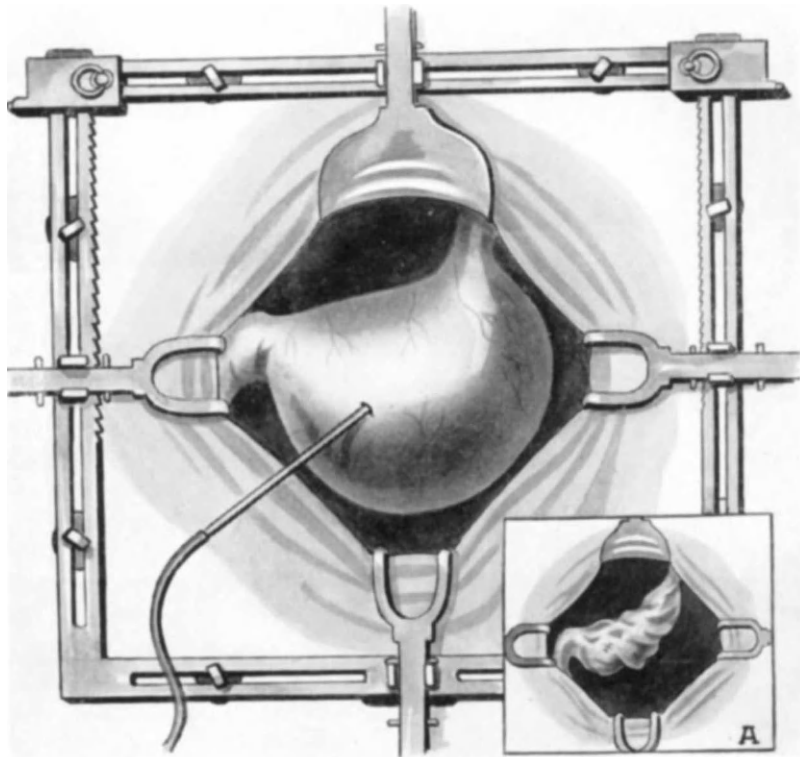


Fig. 350.—A stomach which is dilated and filled with air being punctured by a trocar attached to a suction pump. The inset A shows the stomach collapsed.

The upper part of the lesser curvature can be specially exposed, if necessary, by retracting medially with a 'mechanical hand' the left lobe of the liver (*see Fig. 349*).

3. Deflation of the Stomach.—The stomach is now deflated by inserting a trocar and aspirating the air (*Fig. 350*), after which the small trocar opening is closed with a suture. This manœuvre greatly simplifies any operation on the stomach, for in its collapsed condition it is much easier to operate on.

4. Mobilization of the Duodenum.—In partial gastrectomy and duodenectomy for a duodenal ulcer, or partial gastrectomy for a

carcinoma of the pylorus, it is an advantage to begin the operation by mobilizing the duodenum. This step is described on p. 451.

5. Isolation of the Affected Part of the Stomach.—The stomach is freed from any adhesions on its anterior wall; and the level at which it is proposed to divide the stomach is now chosen.

Openings are made in the gastro-hepatic and gastrocolic omenta through bloodless spaces opposite the proposed line of division (*Fig. 351*).

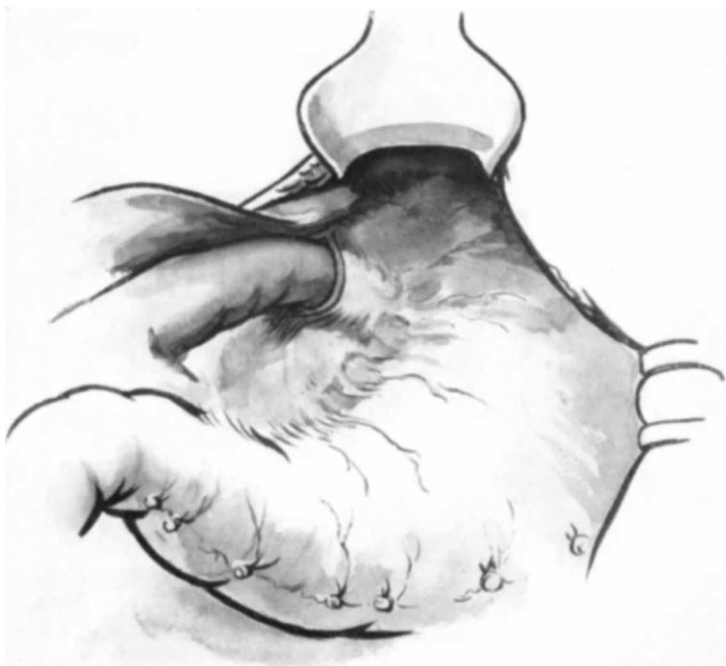

Fig. 351.—Opening in the gastro-hepatic omentum through a bloodless space.

In the gastro-hepatic omentum the index finger is placed under the vessels on the lesser curve, and the spade-pointed knife-edged scissors are employed to separate them from the stomach (*Fig. 352*). The vessels are clamped and divided (*Fig. 353*). A small section of the vessels running into the lesser curve proximal to the proposed line of division is also clamped and divided. This vascular denudation is necessary so as to permit the suturing of the lesser curve in the gastro-entero-anastomosis which is to be made subsequently (*Fig. 354*).

A small section of vessels running into the greater curve proximal to the line of division is treated in like manner.

The greater and the lesser omenta are divided between series of small Spencer Wells forceps (*Fig. 355*). In making this division, the plane of the posterior wall of the stomach must be found at the fundus and carefully followed, so as to be able, if the transverse

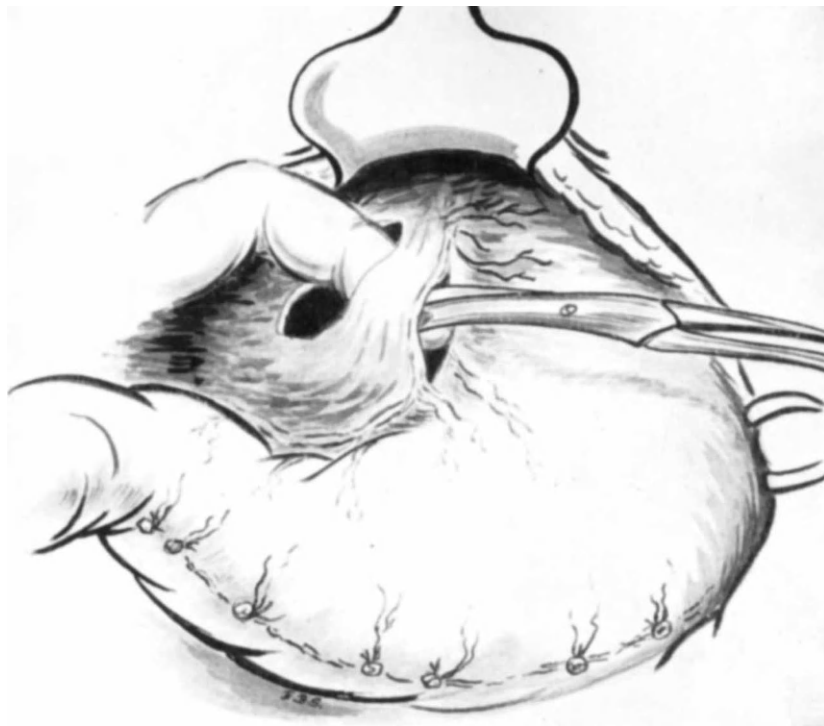


Fig. 352.—Vessels being separated from the edge of the stomach by means of the curved spade-pointed scissors.

mesocolon is adherent to the stomach, to identify it and thus avoid injury to the vessel running in it—the mid-colic artery (*see Fig. 332*, p. 457). This precaution is necessary because in carcinoma and in penetrating gastric ulcer, or indeed in any gastric ulcer, the transverse mesocolon with its mid-colic artery will often be found ‘backwashed’ on and adherent to the posterior surface of the stomach; and the vessel will appear to be running in its posterior wall. I have occasionally found the transverse mesocolon adherent even in the retropyloric region, where the mid-colic artery was in danger of

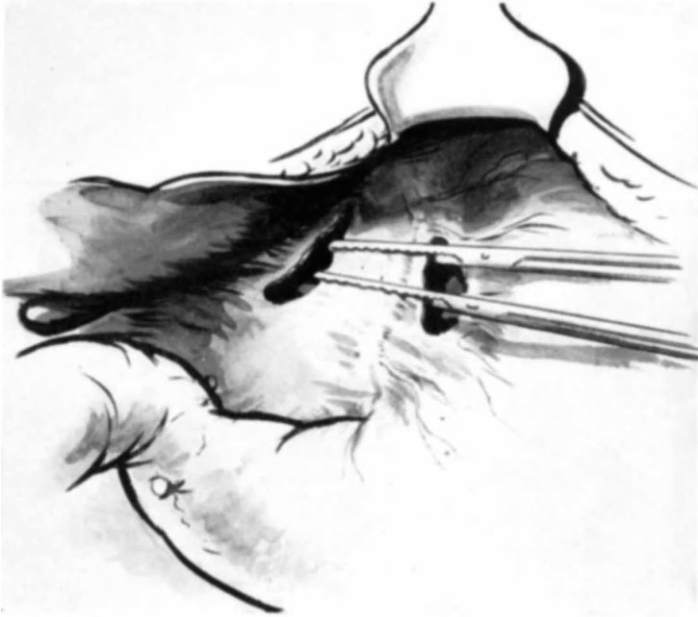


Fig. 353.—Division of the vessels of the lesser curvature.

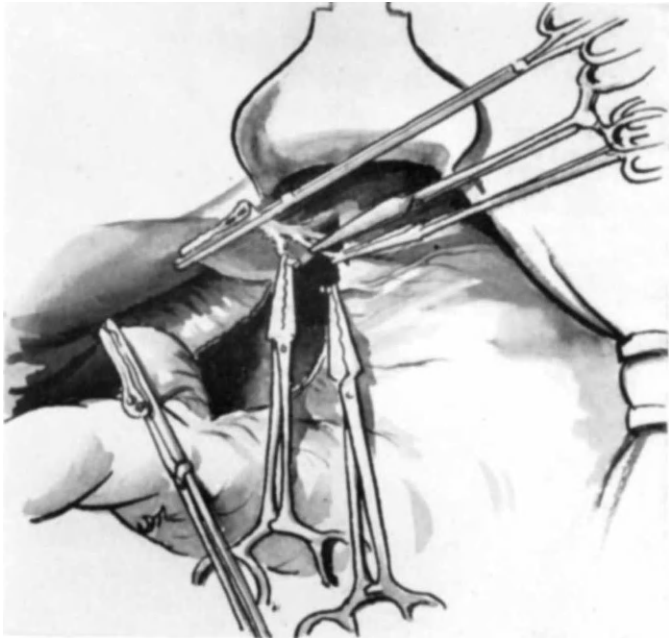


Fig. 354.—Vessels on the lesser curve, proximal to the proposed line of division of the stomach, being cleared for about one inch to provide for the suturing of the lesser curve in the gastro-intestinal anastomosis which is to be made subsequently.

being ligatured under the impression that it was a branch of the gastro-epiploic artery supplying the gastric wall.

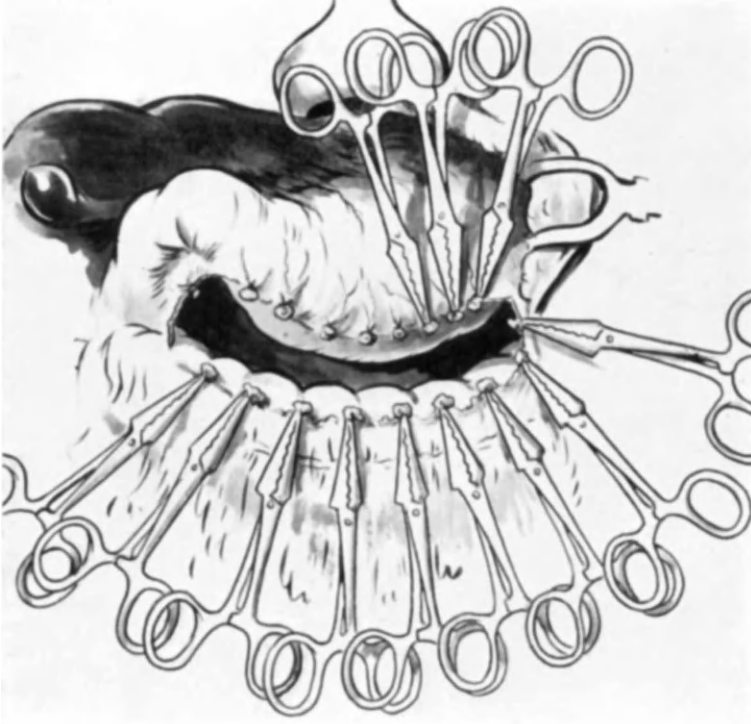


Fig. 355.—The stomach is isolated on its greater curve side by dividing the gastrocolic omentum between Spencer Wells forceps.

6. Resection of the Stomach and Dissection of its Retro-pyloric Region.—The stomach is divided on the fundal side with a diathermy knife, between two Payr's clamps (*Fig. 356*). The distal isolated part of the stomach, with the clamps attached, is allowed to hang over the patient's right side.

As has been mentioned previously, on the posterior surface of the antral part of the stomach the transverse mesocolon may be found adherent, and the mid-colic artery may easily be injured. Therefore the necessity to proceed slowly in this region and to follow carefully the plane of the posterior surface of the stomach is again emphasized.

The subpyloric and retropyloric regions are now exposed to view, showing the right gastric and the gastroduodenal arteries lying above

the duodenum, and the right gastro-epiploic artery lying below it; the head of the pancreas, adherent by loose tissue to the posterior wall of the duodenum; and the subpyloric and retropyloric lymph-glands (*Fig. 357*). These glands with the surrounding tissue are dissected free from the pancreas and surrounding structures, but left attached to the gastroduodenal and gastro-epiploic arteries and terminal part of the stomach.



Fig. 356.—Showing line of division of stomach on the fundal side.

The right gastric and right gastro-epiploic vessels as they lie along the first part of the duodenum are stretched taut by the weight of the Payr's clamp as it hangs over the right side of the patient; and as a result of this stretching they can be neatly isolated, ligatured, and divided far down the first part of the duodenum, thus denuding an area of duodenum sufficient to allow two rows of sutures to be turned in (*Fig. 358*).

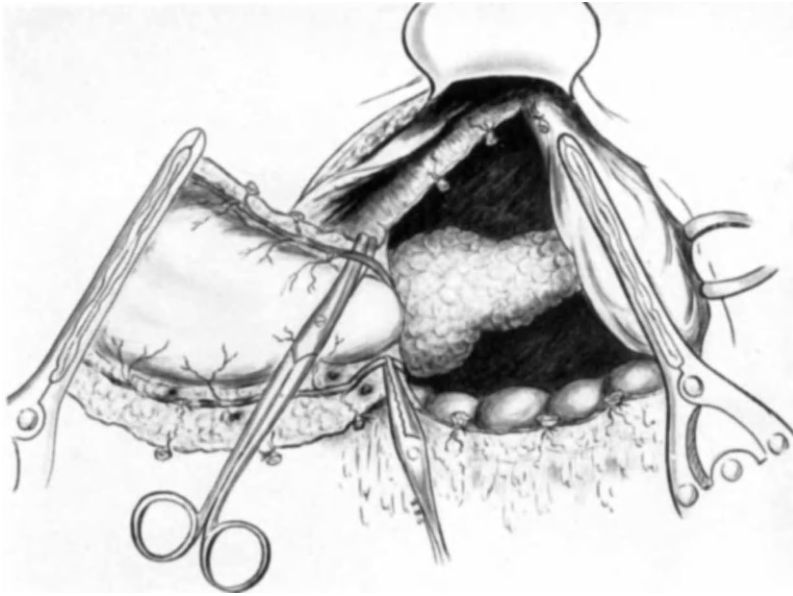


Fig. 357.—Drawing from a photograph of the stomach divided at the junction of the proximal third and distal two-thirds, with its greater and lesser curvatures isolated from the respective omenta, and the distal part of the stomach allowed to hang over the right side, so that the region posterior to the diseased pyloric part of the stomach—the region of the pancreas—is exposed to view in order that a careful dissection can take place.

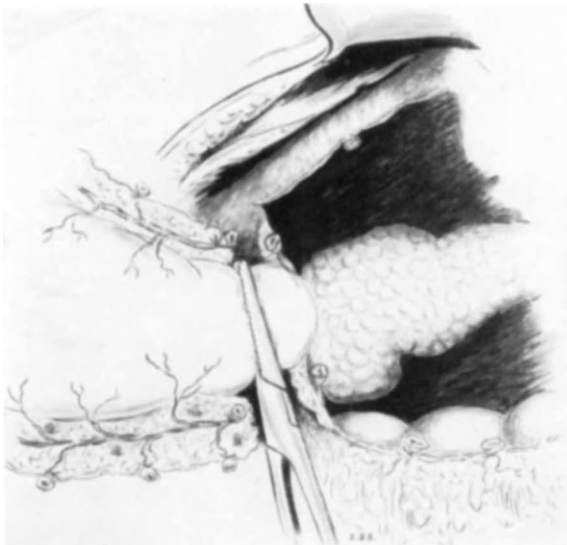

Fig. 358.—Right gastro-epiploic and right gastric arteries divided, leaving the first part of the duodenum bare of vessels.

7. Division and Closure of the Duodenum.—The duodenum is now divided, a clamp being put on above the level of the division to prevent leakage from the gastric segment (*Fig. 358*), but, as the duodenum does not leak, and it is advisable to avoid injury to its cut edge, no clamp is placed below.

The duodenum may also be divided as in *Figs. 359, 360*, a cuff of seromuscular layer being turned back and the mucous membrane

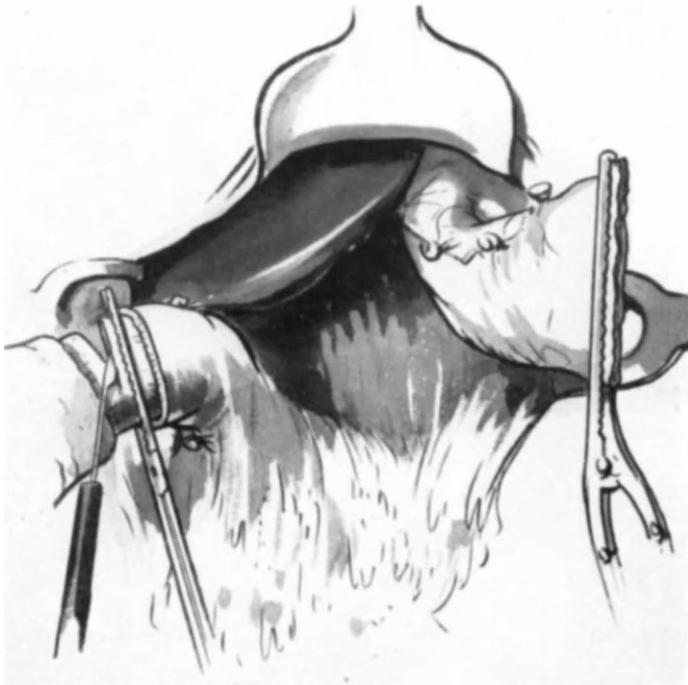

Fig. 359.—Dividing the duodenum with the diathermy knife after turning back a seromuscular cuff.

clamped separately and divided with the diathermy knife. The injury to the mucous membrane caused by clamping is not nearly as harmful as crushing of the whole three layers.

In the closure of the divided duodenum special attention is required. The insufficiency of duodenal suture is the cause of many failures in partial gastrectomy. It is probably due to the powerful digestive action of the duodenal juices. Thus it is necessary to employ a careful technique in the closure of the duodenal stump.

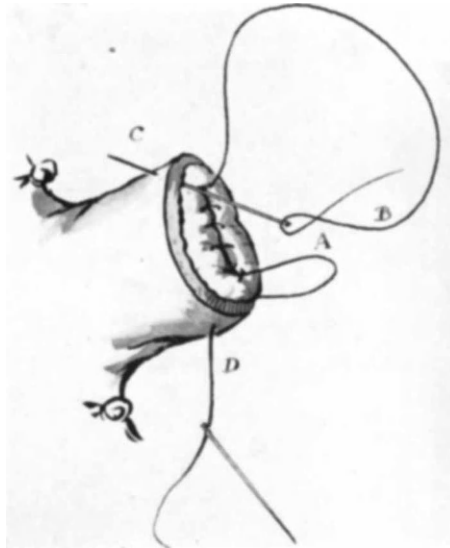
If no clamps have been used in its division, any severed vessels will bleed. These are clamped and tied, and the mucous membrane

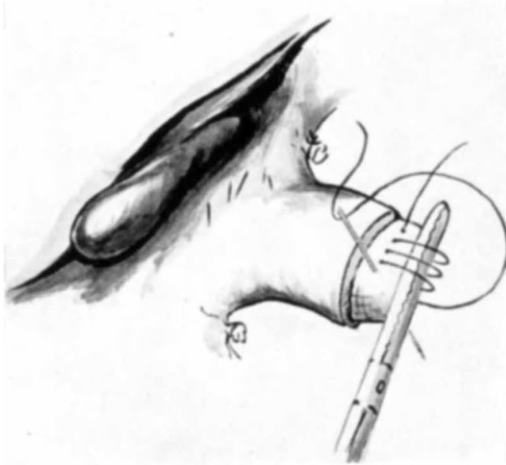

Fig. 360.—Method of suturing the mucous membrane of the duodenum when a clamp is used.

is sutured with No. 0 slightly hardened catgut. If clamps have been used on the mucous membrane, it is sutured with the clamp in

Fig. 361.—The loose end of the mucous membrane suture B is armed with a straight needle, and this is inserted between the mucous membrane and the seromuscular layer, coming out at C, $\frac{1}{4}$ in. below the cut edge. The same manœuvre is carried out with the other end of the mucous membrane suture A, which is made to come out at D.



position, as shown in *Fig. 360*; and as the clamp is removed, the thread is drawn taut.

In either case, the mucous membrane now lies sutured as in *Fig. 361*. Each end of the catgut suture is armed with a straight needle; and these needles are driven down between the mucous membrane

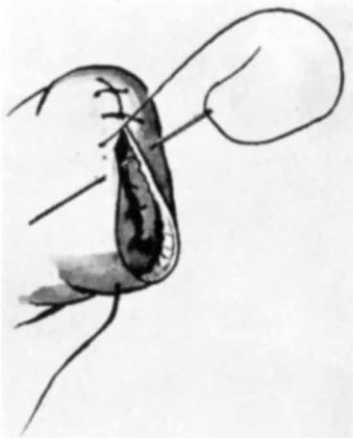

Fig. 362.—The suture is returned and the seromuscular layer is sutured.

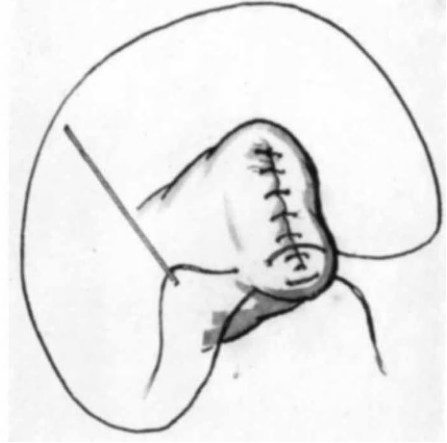


Fig. 363.—Insertion of X suture at one end of the suture line.

and the muscle layer (*Fig. 361*), and made to come out about $\frac{1}{4}$ in. from the cut edge. When the ends are pulled taut, the sutured mucous membrane layer is sunk below the cut edges of the seromuscular suture, thus facilitating the suturing of this layer.



Fig. 364.—Insertion of X sutures at both ends of the suture line.

The ends of the suture C and D are now used to suture the seromuscular layer (*Fig. 362*).

Two X sutures of linen thread or fine silk are now inserted to cover each end of this suture line (*Figs. 363, 364*) and to form the beginning of a third layer. When these X sutures are tied, the

corners of the seromuscular suture—the difficult parts to invert in duodenal closure—are neatly turned in without difficulty. Finally, a few unabsorbable interrupted sutures between the X sutures complete the third tier.

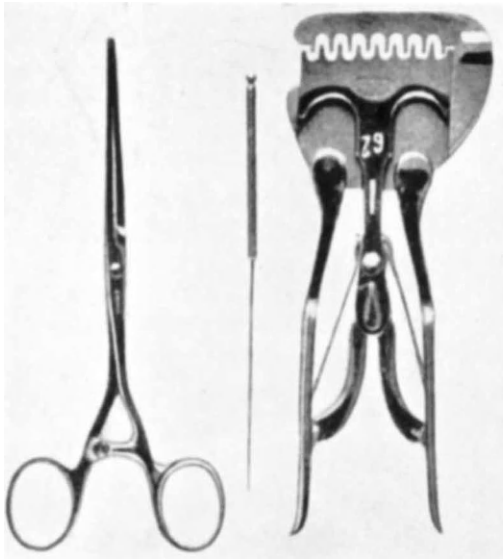

Fig. 365.—Essential parts of Donati's instrument. (Figs. 365-368 from 'Zentralblatt für Chirurgie'.)

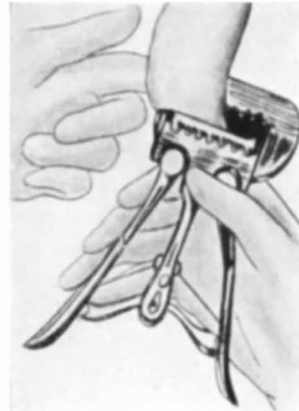

Fig. 366.—Application of the open instrument to the intestine.



Fig. 367.—The instrument is closed, and a straight needle on a needle-holder is pushed through the hole running through the blades of the instrument, thus transfixing the pleated and cut end of the duodenum.

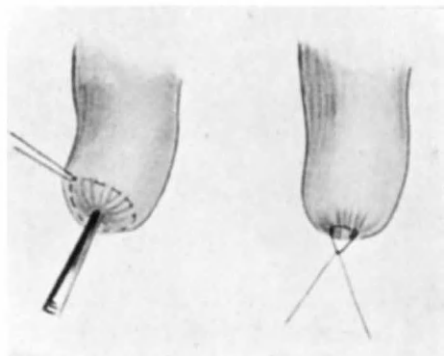


Fig. 368.—The instrument is removed, the thread which was attached to the needle is tied, and the duodenal end embedded with a purse-string suture.

Closure of the Duodenal Stump by means of Donati's Instrument.—The duodenal stump may be closed by means of an instrument which crushes the end of the duodenum, pleats it at the same time, and provides a mechanism whereby the pleated duodenal cut edge can be transfixed by a suture. This is accomplished by means of an instrument designed by Donati,¹ the essential parts of which are



Fig. 369.—Von Seemen's clamping apparatus.

shown in *Fig. 365*. The method of its application to the duodenum is shown in *Fig. 366*, and the method of invagination of the cut end of the duodenum in *Fig. 367*. The completed operation is shown in *Fig. 368*.

As the duodenum occasionally presents considerable difficulty in closing, alternative methods are described as follows:—

Closure with von Seemen's Clamping Apparatus.—The clamp illustrated in *Fig. 369* is used. It can be deflected in the direction



Fig. 370.—Friedrich's clamp.



Fig. 371.—Friedrich's clamp in use.

shown by the arrow to the extent of 180°, so that it will fit into the depths of the abdominal cavity—a necessity when a short duodenal stump is to be closed. By means of this clamp a double row of very fine interrupted silver sutures can be inserted.

Closure by Friedrich's Clamp.—The instrument used is illustrated in *Fig. 370*, and *Fig. 371* shows it in operation.

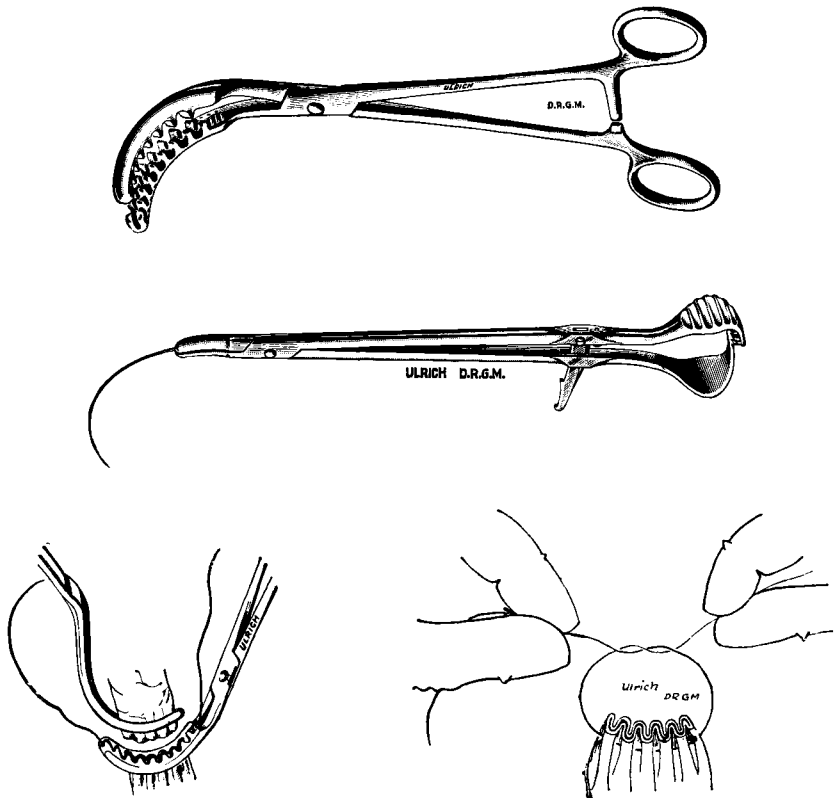


Fig. 372.—Showing semi-diagrammatically the curved infolding clamp and three steps in the closure of the duodenum by its aid.

Closure by an Infolding and Suturing Clamp.—The duodenum may be closed by using a curved and infolding clamp constructed on the principle of Donati's instrument. The instrument and its method of employment are shown in *Figs. 372, 373*. It will be seen that the curved needle is passed through a tunnel in the clamp.

8. Making the Gastro-entero-anastomosis.—This is described at length in the following chapter.

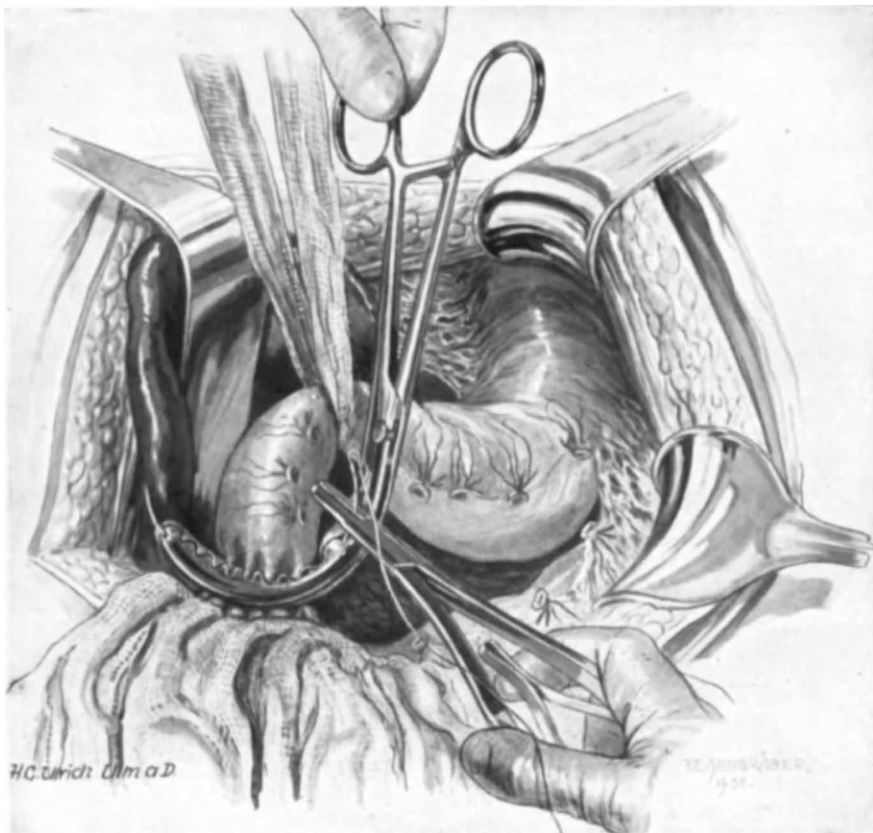


Fig. 373.—Showing the curved infolding clamp in actual use.

9. Disposition of the Omentum.—A paragraph dealing with this step will be found at the end of Chapter XLIX.

10. Closure of the Wound.—See Chapter LI.

REFERENCE

- ¹ STRAUSS, FRITZ, "The Use of the Donati Instrument for the Closure of Duodenal or Small Intestinal Stumps", *Zentralb. f. Chir.*, 1935, No. 49, Dec. 7, 2910-4.

CHAPTER XLIX

**THE TECHNIQUE OF PARTIAL GASTRECTOMY:
III. MAKING THE GASTRO-ENTERO-ANASTOMOSIS**

THE next step in partial gastrectomy depends on how the stomach is to be united to the jejunum ; that is, on the particular method of gastro-entero-anastomosis to be employed. In regard to this step, however, there are difficulties and dangers. Even slight kinks in the jejunum where it approximates the anastomosis with the stump of the stomach can produce gastroduodenal stasis, because neither in the partially paralysed gastric stump nor in the disconnected duodenum is there much *vis a tergo* to overcome a slight obstruction. Unless, therefore, a gastro-entero-anastomosis is quite free from angles or kinks in the adjoined jejunum, the patient begins, very soon after the operation, to vomit bile, duodenal and pancreatic secretions. This vomiting, immediately following a critical operation, is very dangerous, and is the point on which the success of the operation may turn, especially in the case of a weak cancerous subject. It is important, therefore, to pay particular attention to the construction of the anastomosis at the points where the afferent loop meets the stomach and the efferent loop leaves it.

Many sutural devices have been employed at these points, all more or less effective ; but the essential precaution is that there should be no upward drag on the jejunum by the gastric stump when it lies in its normal position.

In most methods of gastro-entero-anastomosis the author places the efferent loop at the greater curvature, for experience has shown him that the stomach empties better with the efferent loop in this position ; if it is placed at the lesser curvature, kinking and disturbance of gastric emptying are liable to occur.

Methods of Making the Anastomosis.—The following are the standard methods used for connecting the intestine to the stomach :—

1. *The Polya.*—In the Polya method the cut end of the stomach is joined to the side of the jejunum. It is the usual and perhaps the most satisfactory method of gastrojejunal anastomosis (*Fig. 374*).

In the case of a partial gastrectomy for carcinoma, a long loop of jejunum may be brought in front of the colon (antecolic) ; and in this

case it is wise to make an entero-anastomosis between the two limbs of the jejunal loop (Balfour). In partial gastrectomy for gastric or duodenal ulcer, a short (and therefore retrocolic) loop should be made, in order to lessen the danger of the occurrence of jejunal

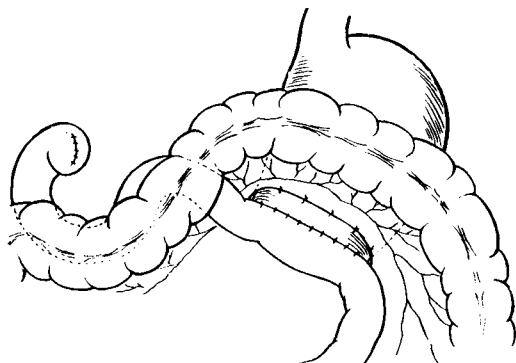


Fig. 374.—Diagram showing the jejunal loop lying behind the colon in a Polya operation.

ulcer. Here, however, as the stump of the stomach will be too short to bring below the transverse mesocolon, the satisfactory fixation of a retrocolic loop in the transverse mesocolon is difficult. In these circumstances, the formation and fixation of a retrocolic

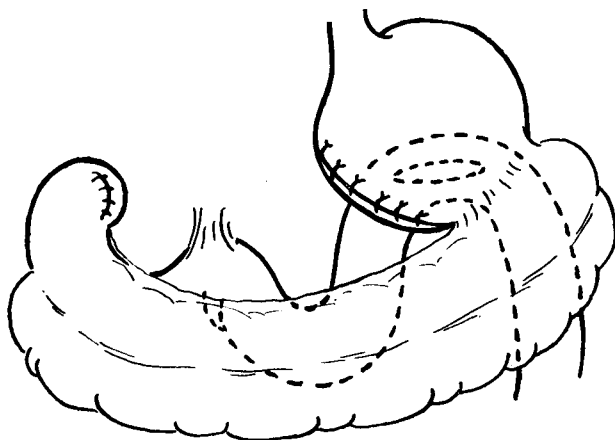


Fig. 375.—Billroth II method.

loop is best accomplished by mobilization of the duodenojejunal flexure as employed by the author (*see* p. 497).

2. *The Billroth II.*—In this method the end of the stomach is closed, and the jejunum is anastomosed to the posterior wall of the

organ (*Fig. 375*). The method is advantageous when the amount of stomach which has been left is very small or where it is necessary to control the emptying time by varying the size of the stoma. An ante- or retro-colic jejunal loop can be used as in the case of the Polya method.

3. *The Billroth I.*—In this method the divided end of the stomach is connected to the duodenum. The application of the method is limited, and it is only employable under special circumstances. (*See p. 517.*)

The Relation of the Jejunal Loop to the Transverse Colon.—In whatever way the stomach is joined to the jejunum, if the

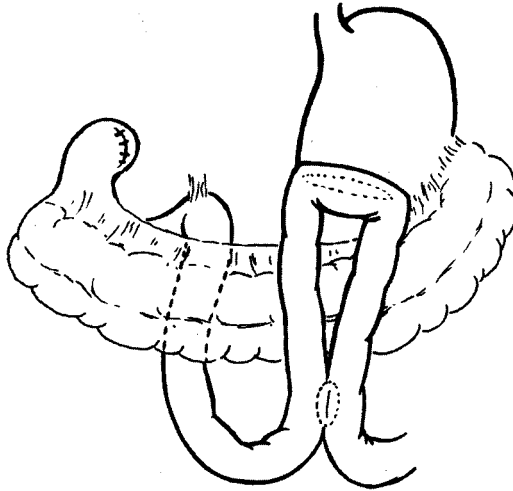


Fig. 376.—Diagram showing the antecolic method and its combination with an entero-anastomosis.

stump of the stomach is small, it is always a difficult problem to arrange the jejunal loop in proper relation to the transverse colon and its mesocolon.

In the case of the Polya method, if enough stomach is left for the gastro-intestinal anastomosis to lie without tension below the transverse mesocolon, then the jejunal loop can lie below the colon (*Fig. 374*). But, as a rule, so much stomach is removed that the anastomosis, if fixed below the transverse mesocolon, would retract upwards and draw the jejunum into angles where it is attached to the mesocolon. To obviate this retraction of the mesocolon the jejunal loop may be brought in front of the colon—the antecolic method (*Fig. 376*).

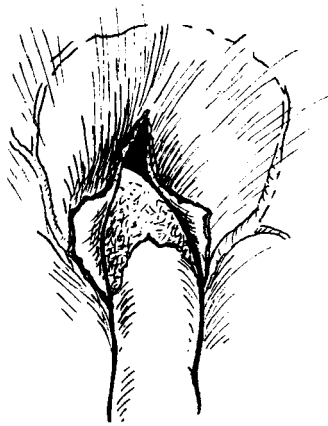


Fig. 377.—Incision of the peritoneum around the duodenojejunal flexure.

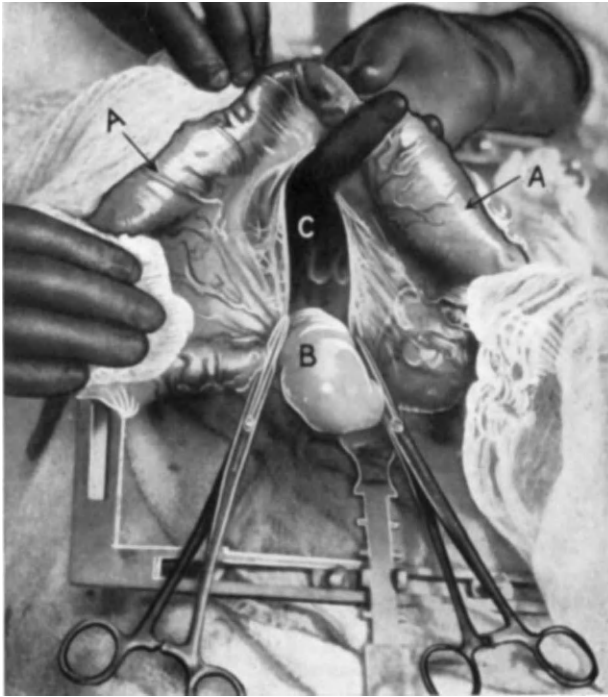


Fig. 378.—Photograph (retouched) of duodenojejunal flexure isolated and ready to be pushed into the lesser sac. A, Transverse colon; B, Duodenojejunal flexure; C, Opening in the transverse mesocolon above the flexure.

Where, however, the jejunal loop is brought in front of the transverse colon, and is consequently long and liable to drag, and therefore to kink, then it may be necessary, as a routine precautionary measure, to make an entero-anastomosis (after Balfour) as shown in *Fig. 376*. But this long loop and entero-anastomosis should not be made as a routine in the Polya operation when it is employed for a case of gastric or duodenal ulcer, because it predisposes to the formation of jejunal ulcer; for not only is the mucous membrane of the long loop less resistant to the erosive action of acid, but also the entero-anastomosis removes the effect of regurgitation of alkaline duodenal contents. Where, however, the operation is performed for carcinoma of the stomach, and where the gastric stump is necessarily small and liable to retract upwards, and to cause a kink in the afferent loop, an entero-anastomosis should be made as a routine; for in these circumstances there is a hypo-acidity, and therefore never any fear of a jejunal ulcer forming.

In most cases of the Billroth II method also this long jejunal loop must be made, for, as a rule, the gastric stump is so small that it is impossible to suture the anastomosis below the transverse mesocolon.

Short Retrocolic Loop with Displacement of the Duodenojejunal Flexure.—There are, as has been pointed out, definite difficulties and dangers attaching to the long loop where it is employed in cases of partial gastrectomy for ulcer; and there are many reasons why the surgeon should be in a position to use a short jejunal loop, to place it behind the colon while allowing the anastomosis to rest in the position it naturally takes—usually a high one.

In order to attain these ends, the author has for years used a method in which, by displacing the duodenojejunal flexure above the transverse mesocolon, he has been able, in the case of the *short gastric stump*, to employ a loose, fairly short, retrocolic loop. In this loop, only the efferent limb needs to be fixed into the transverse mesocolon. With it there is much less post-operative vomiting than after other methods. This loop can be used with the Billroth II method as well as the Polya. It is of interest, too, that Lahey of Boston had also hit upon this method. (The method should only be used for the short gastric stump, for which it is specially designed.)

The operation is carried out in the following way:—

1. The peritoneum around the duodenojejunal flexure is incised (*Fig. 377*), and the flexure is isolated. In some cases this is very easy; in others, because of the greater length of the flexure, it is difficult.

2. The upper part of this incision is continued upwards for a distance of one inch or more into the transverse mesocolon (*Fig. 378*).

3. The jejunum with its mesentery is now drawn up through the opening in the mesocolon, and so disposed that it forms a *loose* loop

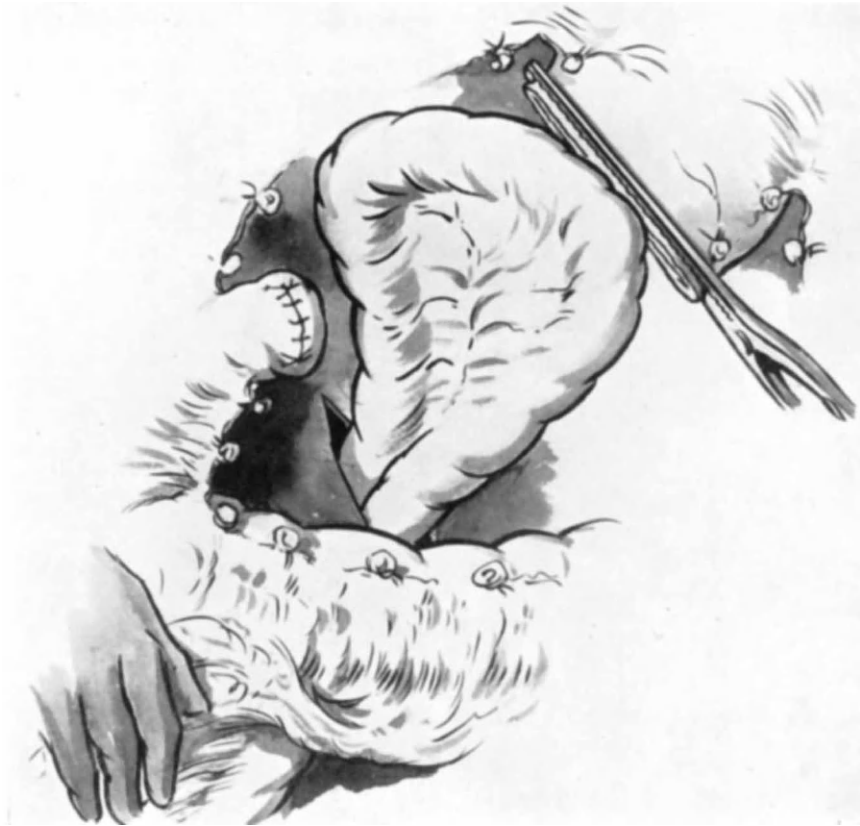

Fig. 379.—Jejunal loop drawn above the transverse mesocolon, which is seen just above the transverse colon. The loop is disposed so that there is a redundancy of it in apposition to the cut edge of the small gastric stump.

(with no sharp shoulders) which can lie without tension almost at the level of the œsophagus (*Fig. 379*).

4. The edges of the opening in the transverse mesocolon are now united to the efferent loop and its mesentery, no attention being paid to the peritoneally denuded duodenojejunal flexure which now lies in the lesser peritoneal sac (*Fig. 380*).




Fig. 380.—Efferent loop showing the mesentery being fixed into the transverse mesocolon by sutures; the duodenojejunal flexure is displaced up into the lesser peritoneal cavity. (Part of the mesentery of the jejunum is omitted in order to show the displaced flexure.)

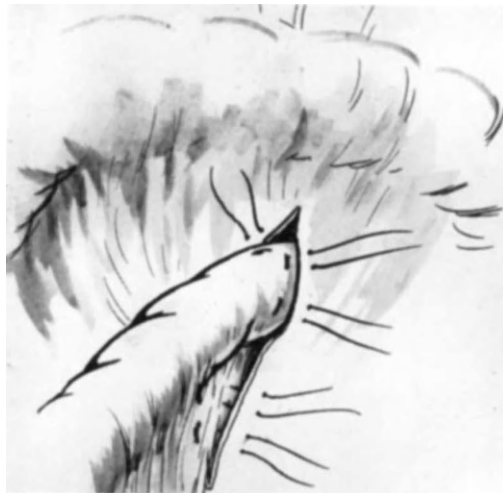


Fig. 381.—Further stage of the insertion of sutures which fix the efferent loop and mesenteries into the transverse mesocolon.

Figs. 381, 382 are further stages of the insertion of sutures which fix the efferent loop and its mesentery into the transverse mesocolon.

In this method, before any gastro-intestinal anastomosis is made, the jejunal loop should

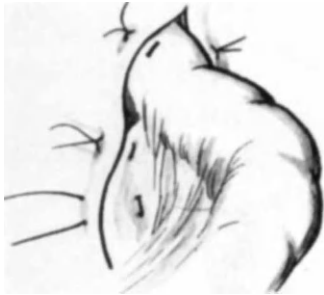

Fig. 382.—A still further stage.

always be very precisely formed and its efferent limb sutured into the mesocolon. The reason for this is that at this stage any slight inaccuracies in the loop, such as a slight twist or an insufficiency, can be easily detected and remedied. It is very difficult indeed to avoid making minor errors, such as a slight torsion or an angle, if the anastomosis is made before the loop is fixed in position in the transverse mesocolon.

Technique of Suturing in the Polya Method.—The steps in the suturing of the gastro-entero-anastomosis are as follows:—

A loose retrocolic loop is made and fixed into the transverse mesocolon as described above (*Fig. 383*).

The efferent loop is apposed to the greater curve, because the direction in which this loop will naturally lie, as it passes vertically down through the mesocolon in front of the mobilized and straightened duodenojejunal flexure, is that of the greater curve; and for this reason no kinks should form and the stomach should empty itself without any hindrance.

The Payr's clamp, which was applied proximally to the line of division of the stomach, is utilized as a handle whereby the assistant is able to turn the posterior surface of the stomach forward for suturing, and also keep the gastric stump from retracting under the ribs.

The jejunal loop is fixed on to the stomach by 'guy-ropes'. These 'guy-ropes' are attached tautly to the operating frame, so that the segments of stomach and jejunum which are to be sutured together lie accurately in position, at the proper tension, and therefore cannot be disarranged.

The serous layers of the jejunum and stomach are united by continuous No. 1 tanned catgut suture on an atraumatic needle (*Fig. 384*). The seromuscular layers of the jejunum and the stomach are incised down to the mucous membrane in each case (*Fig. 385*). Another layer of continuous catgut suture is inserted in the divided seromuscular layers (*Fig. 386*).

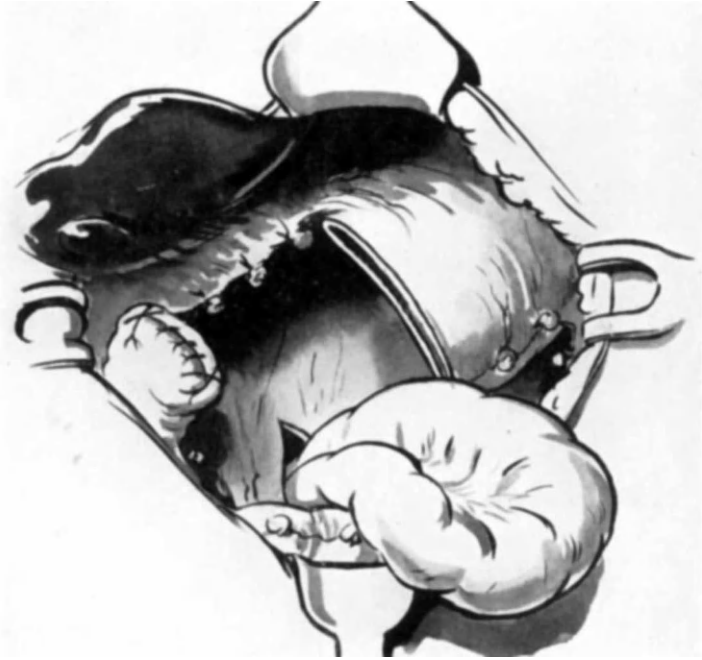

Fig. 383.—A retrocolic loose loop, fixed into the transverse mesocolon and lying ready to be apposed for suture to the cut end of the stomach.

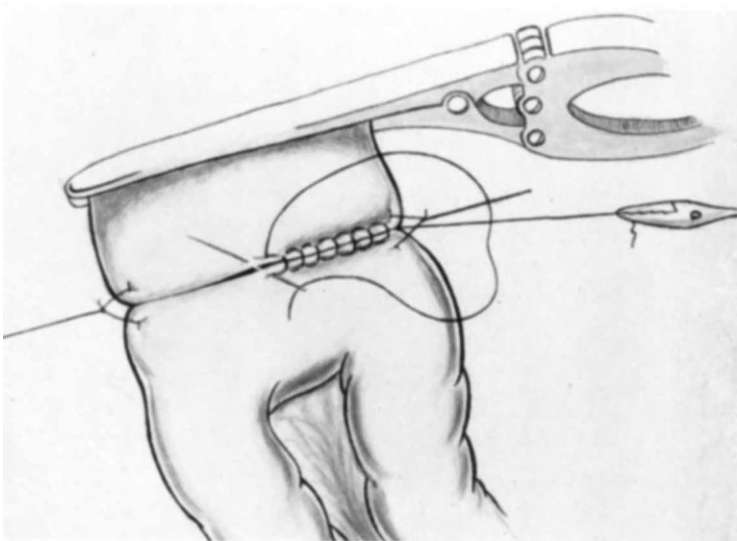


Fig. 384.—Diagram to illustrate the insertion of the sutures.

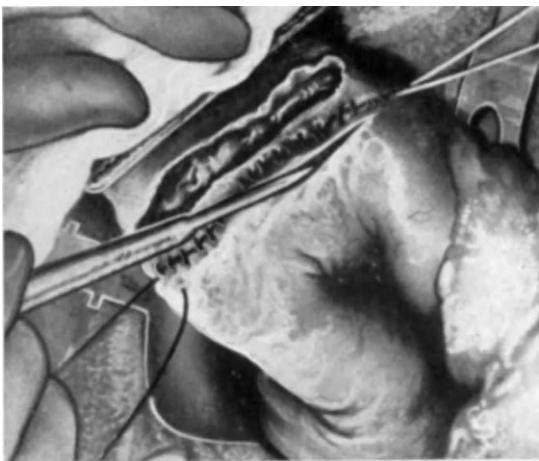

Fig. 385. - Photograph (retouched) showing the seromuscular layers of the stomach and jejunum incised down to the mucous membrane.

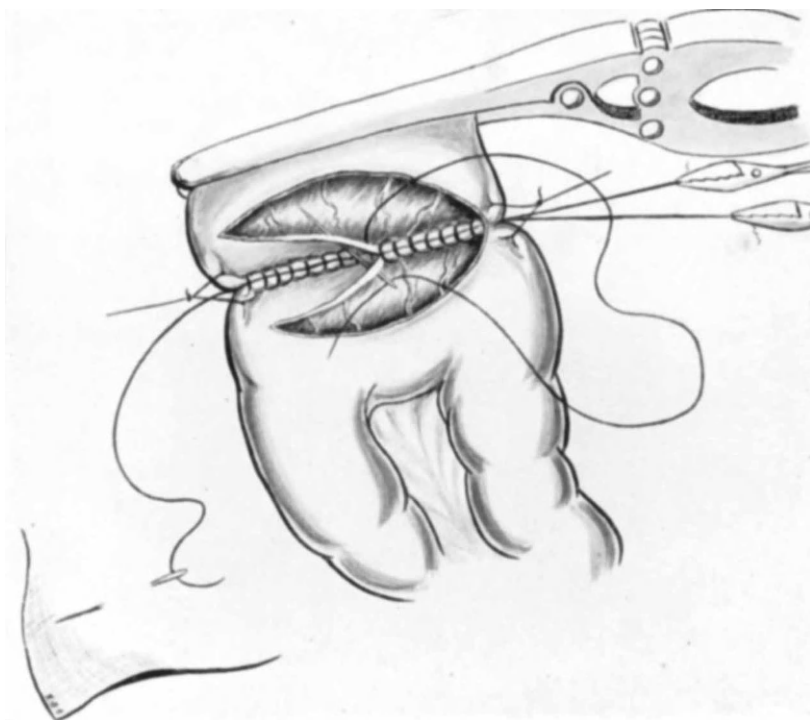


Fig. 386.—Diagram showing the suture of the seromuscular layers.

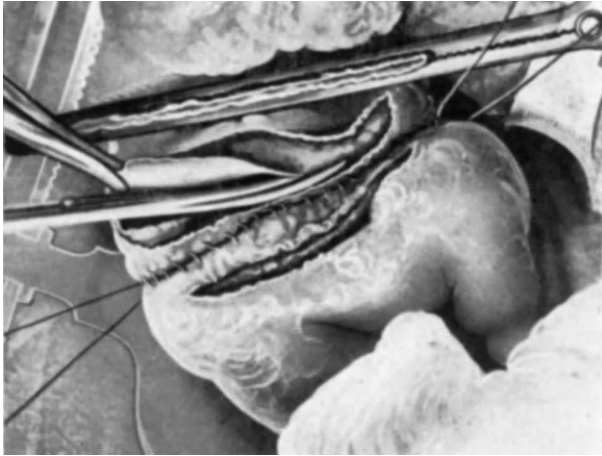


Fig. 387.—Photograph (retouched) showing the mucous membrane of the stomach opened.

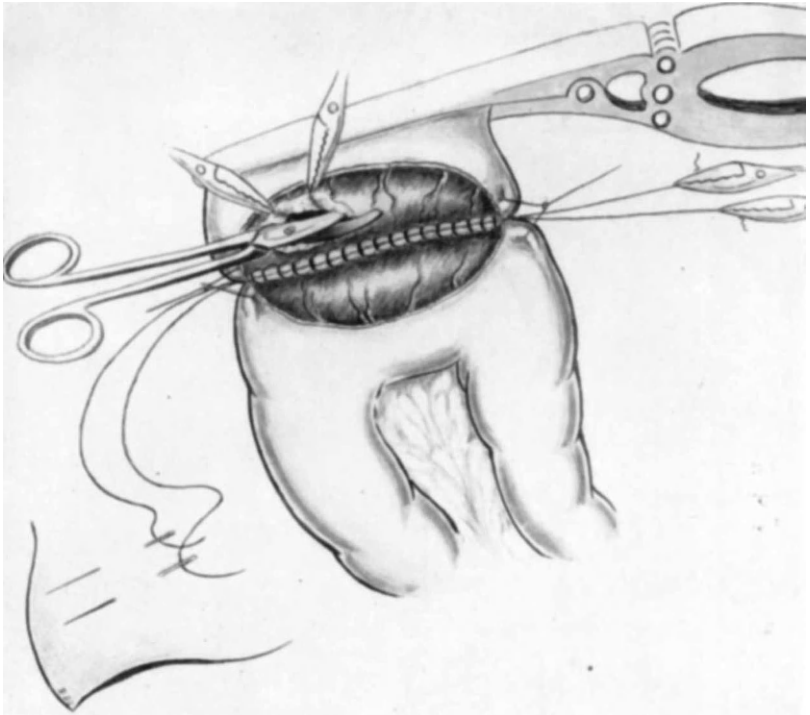


Fig. 388.—Bleeding vessels clamped and tied.

A small opening is made in the mucous membrane of the stomach, and its contents are aspirated. The rest of its mucous membrane is then incised and the bleeding vessels are tied (*Figs. 387, 388*). The jejunal mucous membrane is also incised.

The posterior layer of mucous membranes is sutured (*Fig. 389*), and the suture is continued and made to unite the anterior layers of mucous membrane. As a preliminary to the suturing of these mucous membrane layers, the anterior gastric wall, still in the grip of the Payr's clamp, is divided for half its length. The mucous membrane of this section is then sutured (*Fig. 390*). The remainder

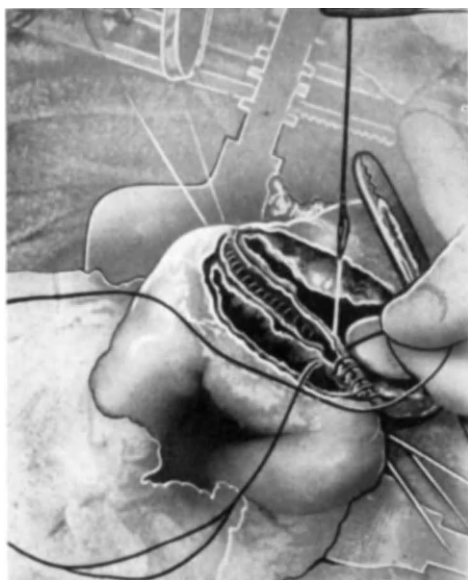


Fig. 389.—Photograph (retouched) showing suture of the posterior layer of the mucous membranes.

of the anterior wall is cut away from the clamp and the rest of its mucous membrane sutured. This piecemeal division of the anterior wall enables the butt-end of the stomach to be held up by the Payr's clamp until the mucous membrane suture is practically completed, thus facilitating the suturing and permitting the surgeon to make the anastomosis in a difficult position without the use of clamps, and yet without spilling any gastric contents. The anterior two layers of sutures are completed in the usual way (*Figs. 391, 392*).

In order to avoid angles or shoulders which would obstruct the current from the duodenum into the stomach or that from the stomach

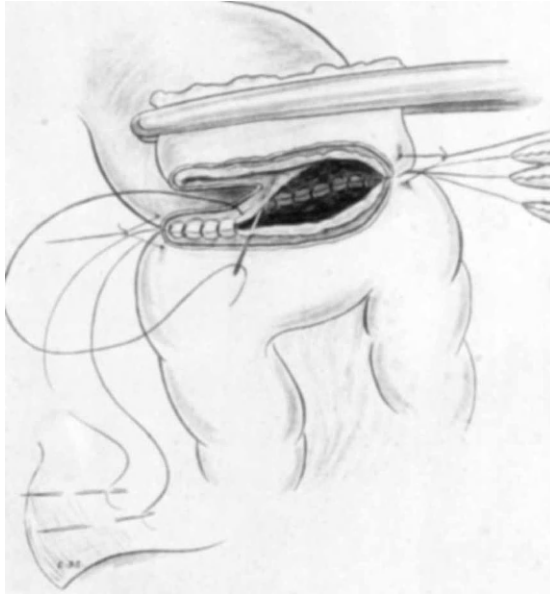


Fig. 390.—Piecemeal suture of the anterior layer of mucous membrane.

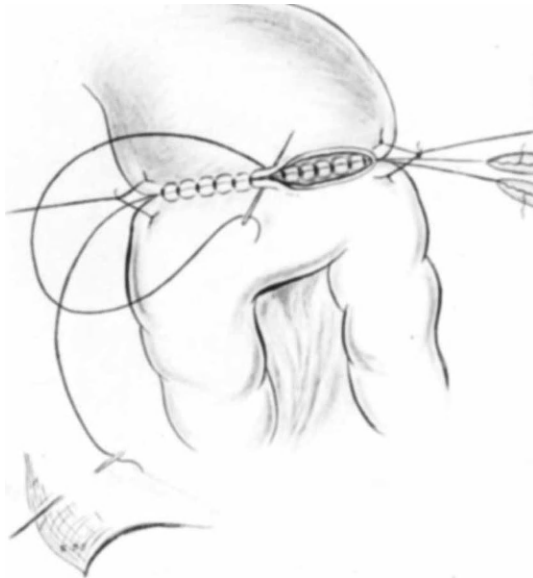

Fig. 391.—Insertion of the second layer of sutures, in the seromuscular layer.

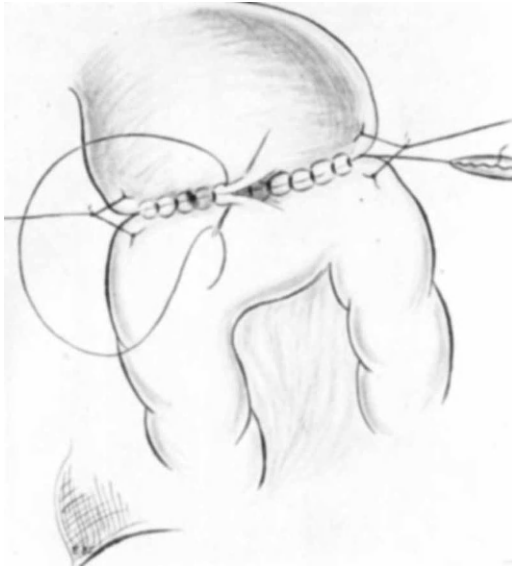


Fig. 392.—Insertion of the third layer of sutures in the serosa.

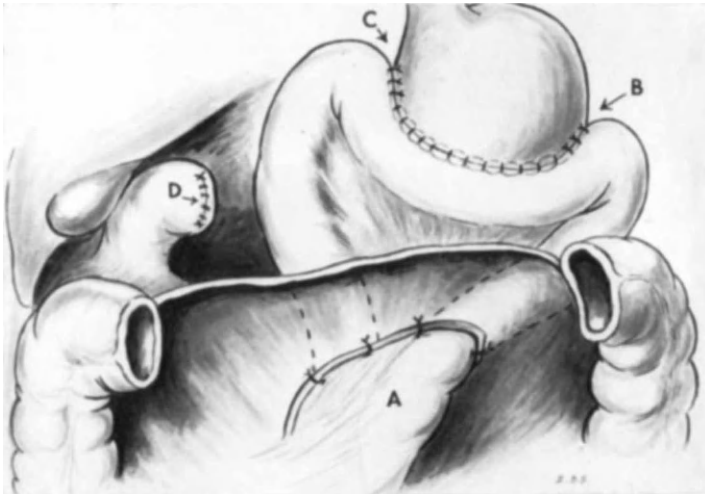


Fig. 393.—Semidiagrammatic drawing of the finished partial gastrectomy, showing the disposition of the afferent and efferent loops. Note the fixation of the beginning of the efferent loop at the greater curvature B, and the fixation of the end of the afferent loop at C into the lesser curvature. A, Efferent loop passing through the opening in the transverse mesocolon D, Prepyloric closure.

into the jejunum, about an inch of the terminal part of the afferent loop is sutured to the lesser curvature, and the same length of the beginning of the efferent loop is united to the greater curvature (*Fig. 393, C, B*).

Technique in Suturing in the Billroth II Method.—When the gastrojejunal anastomosis is to be made after the method of Billroth II, the divided end of the stomach may be closed: (1) By suture; (2) By using the Petz clamp.

1. *Closure of the Cut End of the Stomach by Suture.*—The Payr's clamp is released in order to allow any vessels to bleed, a light

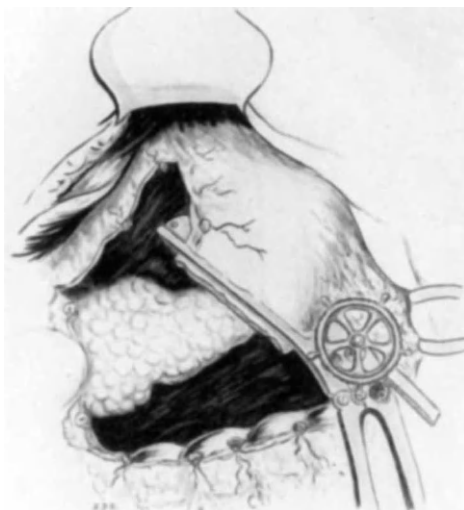


Fig. 394.—Method of applying the Petz instrument in order to close the cut end of the gastric stump with a row of metal clips.

clamp being applied to prevent the escape of any stomach contents. If any vessels bleed they are clamped and tied. The divided end of the stomach is then closed in two layers, with a No. 1 tanned catgut on a shoulderless needle.

2. *Closure of the Cut End of the Stomach by Petz Clamp.*—With this instrument the cut edge of the stomach can be closed with a row of metal clips. The method of applying the instrument is shown in *Fig. 394*.

The duodenum is closed in the manner already described (*see p. 485*).

Anastomosis of a Loose Retrocolic Jejunal Loop to the Stump of the Stomach.—A loop of jejunum placed behind the colon is

formed and fixed into the transverse mesocolon, by displacing the duodenojejunal flexure in the manner that has been already described (*see* p. 497). This retrocolic loop is then anastomosed to the posterior surface of the stomach by the three-layer method of suture set forth in Chapter XLV. A small transversely placed stoma is made.

The special advantage of this method of gastro-entero-anastomosis is that the gastrojejunal opening can be made quite small. This smallness is particularly advantageous where the gastrectomy has been

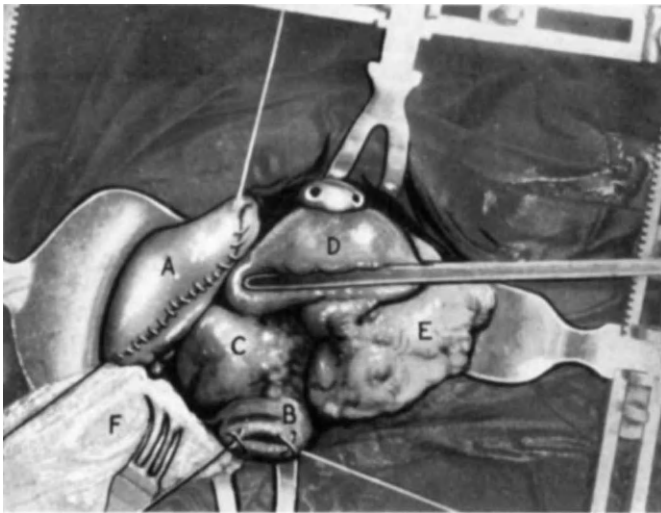


Fig. 395.—Photograph (looking from above) of a partial gastrectomy of Billroth II type. **A**, Sutured stump of stomach; **B**, Partially closed duodenum; **C**, Pancreas; **D**, Loop of jejunum (Murphy button of previous gastro-enterostomy still in it); **E**, Omentum; **F**, Scarf and 'mechanical hand' pulling the left lobe of the liver out of the way.

carried out in women, in whom as a rule the intestinal muscle is weak. The small opening prevents the gastric contents from entering the intestine too quickly and distending too rapidly the weak intestinal wall—a cause of the nausea and other troubles which so frequently follow in the wake of a quickly emptying stomach. Thus this method of gastro-entero-anastomosis can be chosen for women instead of the Polya method, in which the opening is so big that the stomach empties into the intestine far too quickly and causes nausea and trouble.

Fig. 395 is a photograph of a partial gastrectomy in which a Billroth II anastomosis is about to be made.

The photograph of the actual operation is given to show the excellent exposure of the small gastric stump which the operation frame gives. The cut end of the duodenum is shown partially sutured—the ends of the third layer have been started with X sutures ; a few interrupted sutures are still required to close this layer. The anterior surface of the pancreas is also seen. The loop of jejunum is drawn up through the transverse mesocolon into which it has been implanted, and lies ready to be apposed to the posterior wall of the gastric stump. The omentum is lying over the transverse colon, which is pushed downwards into the abdominal cavity. Note the scarf and 'mechanical hand' which pull the left lobe of

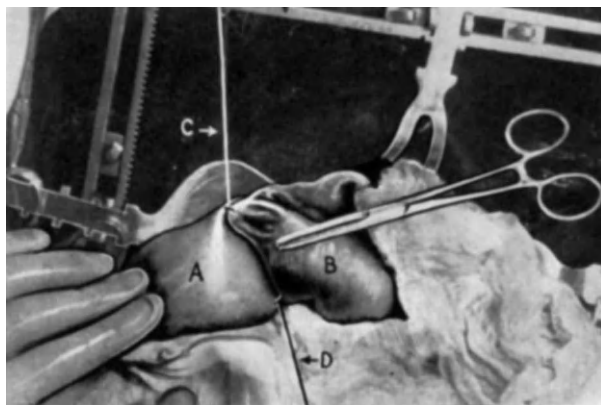


Fig. 396.—Photograph showing the stump of the stomach A, turned up so as to expose its posterior surface. The jejunal loop B is anchored to the stump and to the frame by 'guy-rope' sutures C and D.

the liver out of the way and expose the lesser curve of the stomach. The intestinal loop shows a Murphy button, which had been used to make a previous gastro-enterostomy in the case of a malignant obstruction of the pylorus, for which the gastrectomy was being done.

The steps of the suture of the gastro-entero-anastomosis are :—

The fundus of the stomach is grasped with two Allis's forceps and turned up as in *Fig. 396*.

Two 'guy-rope' sutures are used to anchor the loop of the jejunum to the posterior surface of the stump of the stomach, and these sutures are then used to anchor the two segments tautly to the operating frame.

A small anastomosis is next made in the usual way, as shown in the following illustrations. *Fig. 397* shows the first layer of sutures inserted, and the incisions, 5 cm. long, in the seromuscular layer.

Vessels which bleed are clamped and tied; vessels which can be seen in mucous membrane are underrun with a curved needle, armed with catgut. A Lembert suture of No. 1 tanned catgut is inserted to unite the cut edges of the serous and muscular layers (*Fig. 398*).

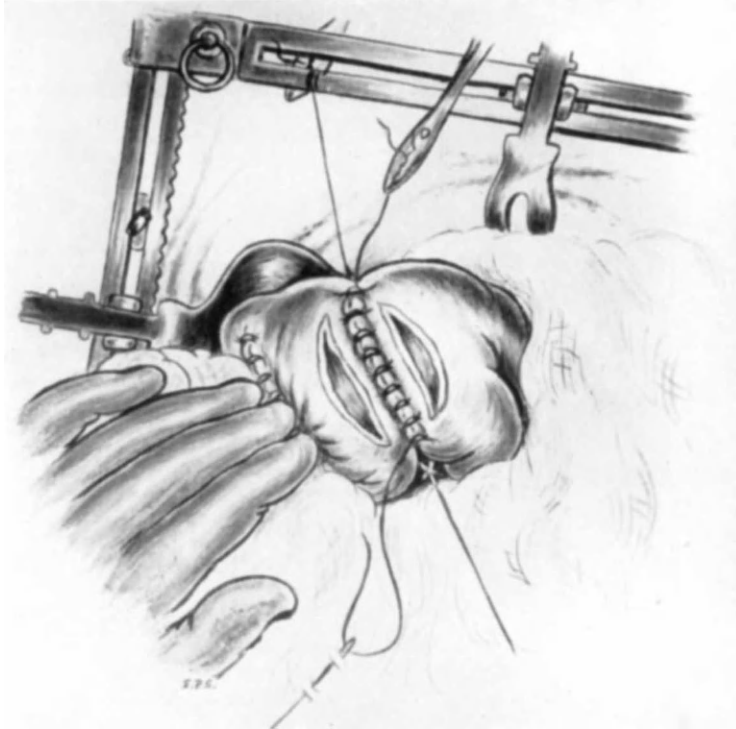


Fig. 397.—Insertion of the first layer of sutures, and the seromuscular incisions.

The mucous membranes of the stomach and jejunum are divided, and sutured with No. 0 plain catgut.

Fig. 399 shows the posterior tier of the mucous membrane suture just completed. This figure is interesting because it is an actual photograph of the operation. It also gives some idea of the size of the opening in the Billroth II operation.

When the posterior mucous-membrane tier is finished, the suture is then continued to the anterior layer, and tied to the loose end that was left where the suture was started (*Fig. 400*).

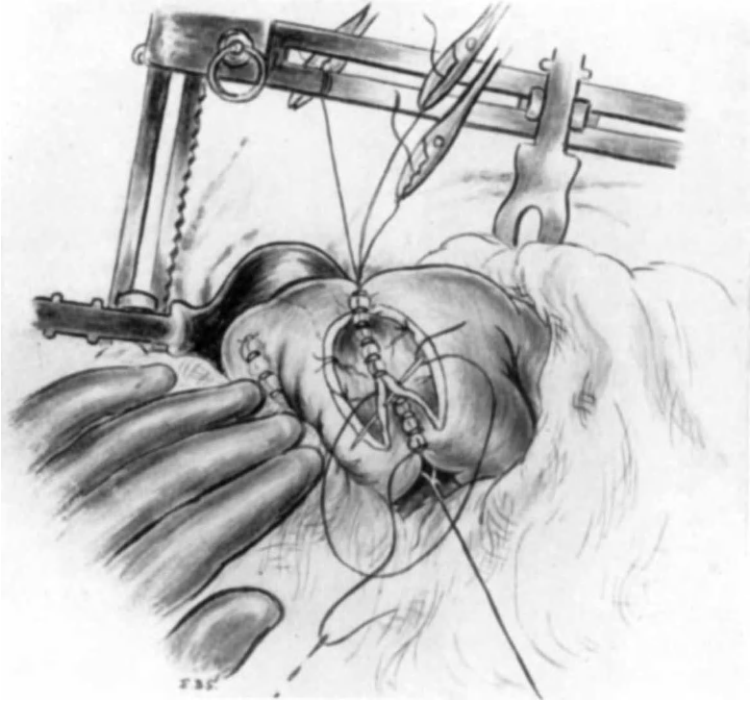


Fig. 398.—Suture of the seromuscular layer.

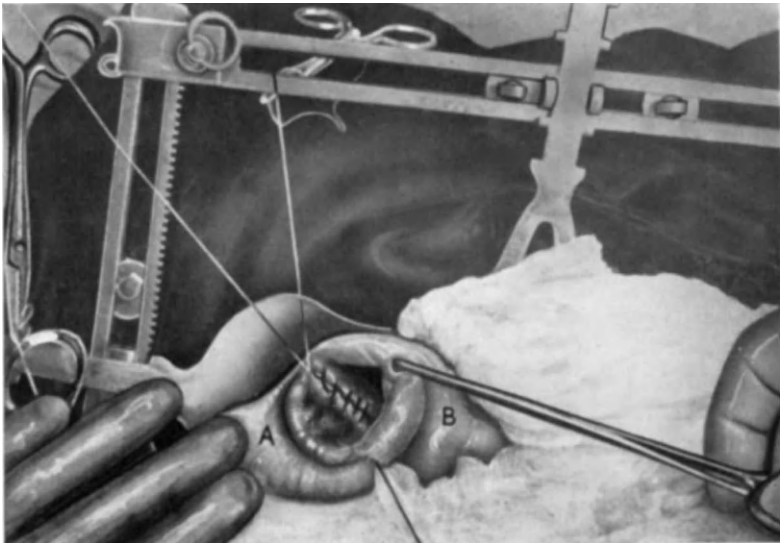


Fig. 399.—Photograph to show suture of the posterior mucous membrane completed. A, Fundus of the stomach; B, Jejunum.

An attempt should always be made to disinfect the two anterior rows of suture, for, as they are made subsequent to the opening of the stomach and jejunum, they will be soiled. In order to accomplish this, a narrow elongated swab, soaked in 1-1000 acriflavine, is laid for a few minutes on the line of sutured mucous membrane. The anterior layer of the seromuscular suture is then completed, and

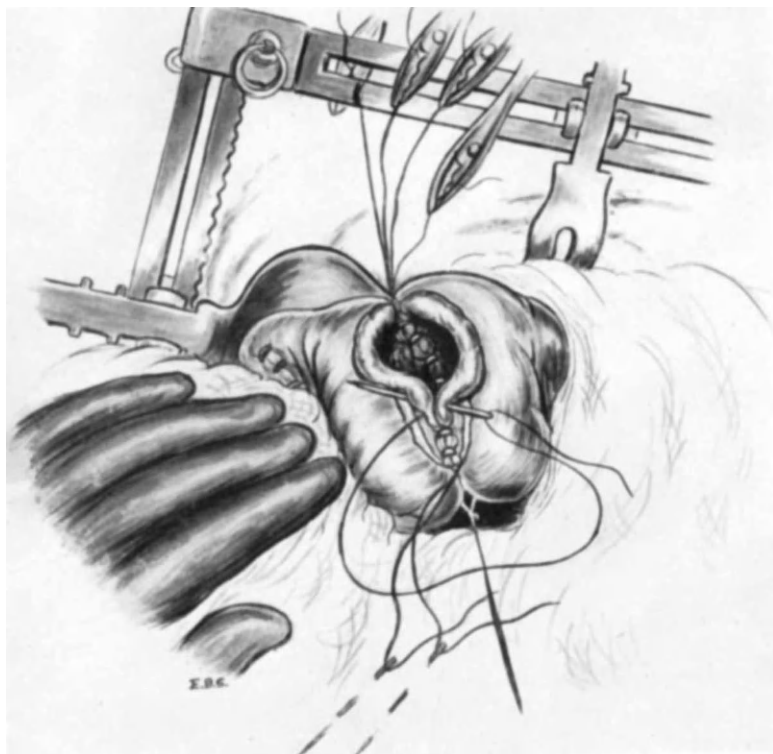


Fig. 400.—Suture of the anterior mucous-membrane layer.

another acriflavine-soaked swab laid on it. *Fig. 401* shows the seromuscular layer being completed.

The outer anterior layer is now completed. This layer is not disinfected.

Fig. 402 shows the finished gastro-entero-anastomosis made after the Billroth II method, and the retrocolic loop made by displacing the duodenojejunal flexure, the efferent loop only coming through the transverse mesocolon.

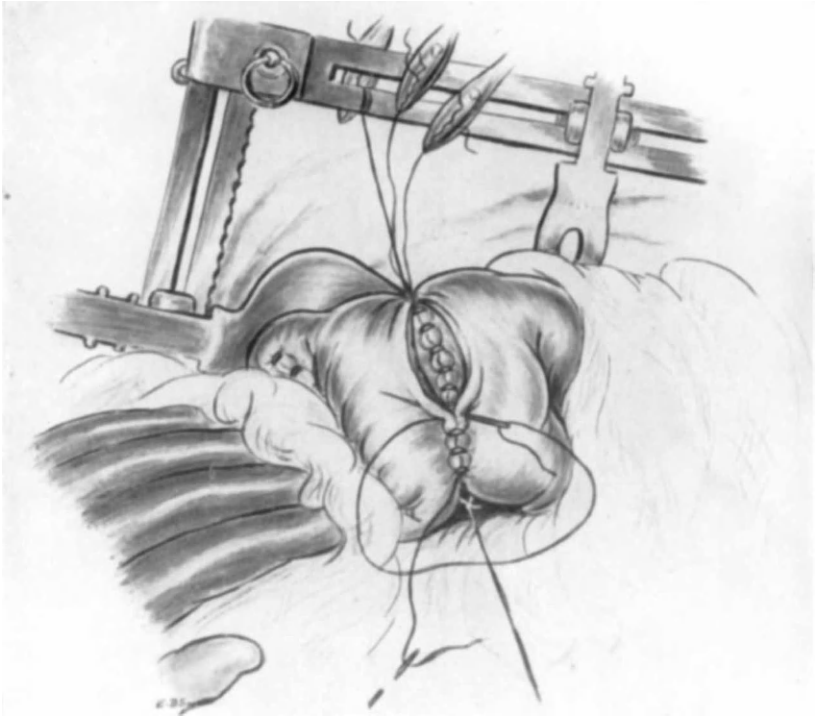


Fig. 401.—Suture of the anterior seromuscular layer.

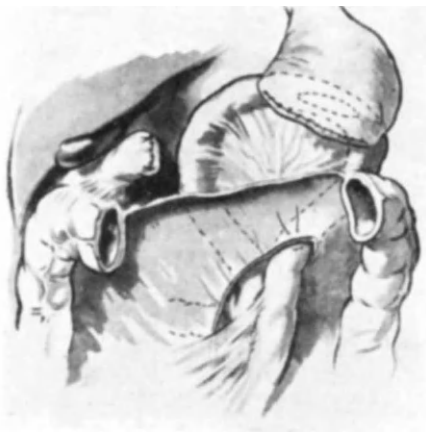

Fig. 402.—Finished gastro-entero-anastomosis, Billroth II method; showing also disposition of the short retrocolic loop made by displacing the duodeno-jejunal flexure upwards, and a prepyloric closure.
A. T.

The Billroth I Operation.—In the original Billroth I operation, the pyloric portion of the stomach was excised, and the duodenal stump was sutured to the greater curve. A disadvantage of this operation was that there was a tendency for a suture insufficiency to occur at the triangular point where the line of suture closing the lesser curve end of the stomach came in contact with the duodenum. For these reasons, the operation was more or less abandoned. But because it fulfils particular operative requirements in regard to the treatment of gastric ulcer or jejunal ulcer, it has, with certain modifications, again come into some favour, and these make it an operation

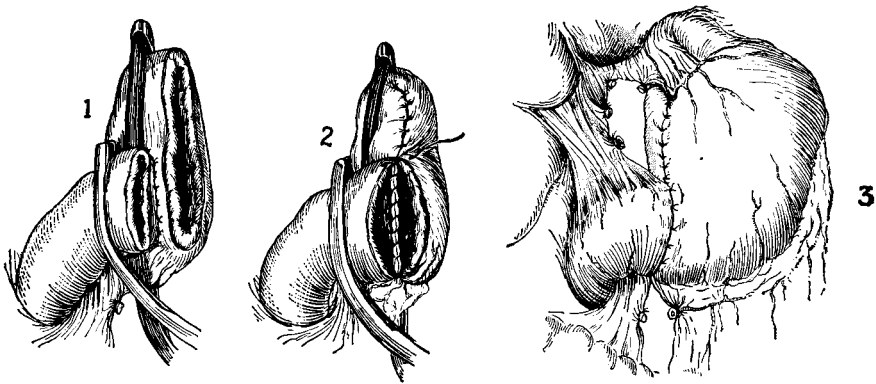


Fig. 403.—Billroth I operation. 1, After the removal of the affected portion of the stomach between Payr clamps the mobilized duodenum is placed on the side of the stomach as shown and there attached by a seroserosus suture, uniting the duodenum to the stomach. Note disposition of respective lumina. 2, The upper portion of the lumen of the stomach is closed. The suture upon reaching the junction of the stomach and duodenum is left long. The mucous membrane of the stomach and duodenum is united with a continuous suture. 3, The operation is completed by picking up the suture left long and uniting the anterior wall of the duodenum with that of the stomach. (Figs. 403-408 from Thorek's 'Modern Surgical Technic', by kind permission of J. B. Lippincott Co.)

which is easier to perform and more reliable than the original Billroth I.

Steps of the Operation.—

1. Mobilize the duodenum as described on p. 451.
2. Isolate the affected segment of the stomach by dividing arteries of the greater and lesser curves, and freely mobilize the lesser curvature.
3. Apply clamps to the mobilized duodenum and to the stomach proximal to the lesion, and resect the diseased segment.
4. The posterior wall of the duodenum is sutured to the posterior wall of the stomach where it approximates the greater curvature, and the cut ends are then approximated as in Fig. 403, part of the

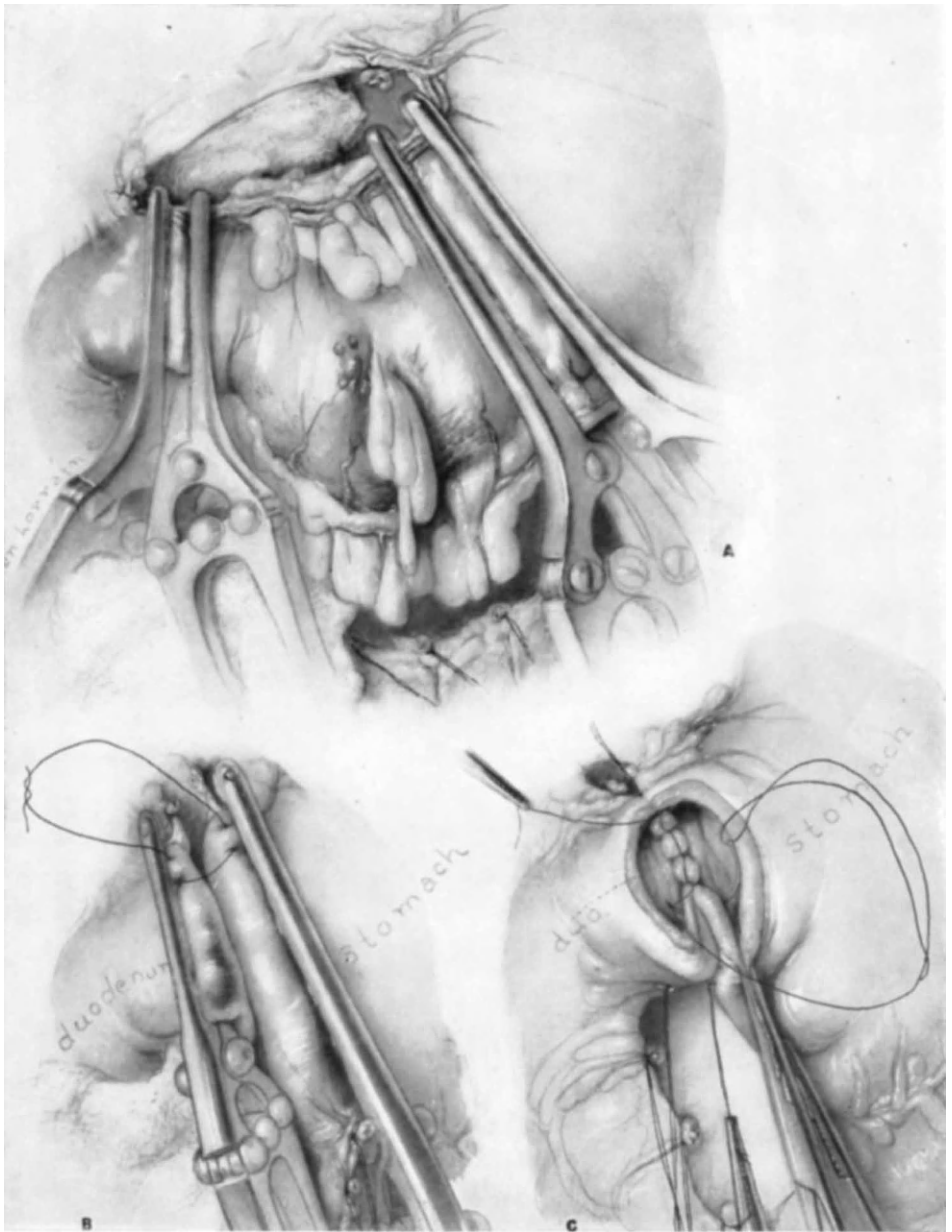


Fig. 404.—Horsley's modification of the Billroth I operation. A, Affected part of stomach isolated ready for resection; B, Suturing together the posterior margins of the stomach and duodenum; C, Insertion of inner row of sutures—the dotted line shows where the anterior wall of the duodenum will be divided longitudinally in order to widen the duodenal lumen. (From 'Surgery, Gynecology and Obstetrics'.)

lesser curvature being amputated in order to facilitate the closing of the free divided end of the lesser-curvature side of the stomach.

5. The triangular point where the suture of the lesser curvature approximates the duodenum is reinforced with omentum.

Horsley's Modification.—J. S. Horsley² has modified the technique of the Billroth I operation, and proceeds as follows:—

The gastrocolic and gastrohepatic omenta are divided and tied in sections. Payr clamps are placed on the body of the stomach and

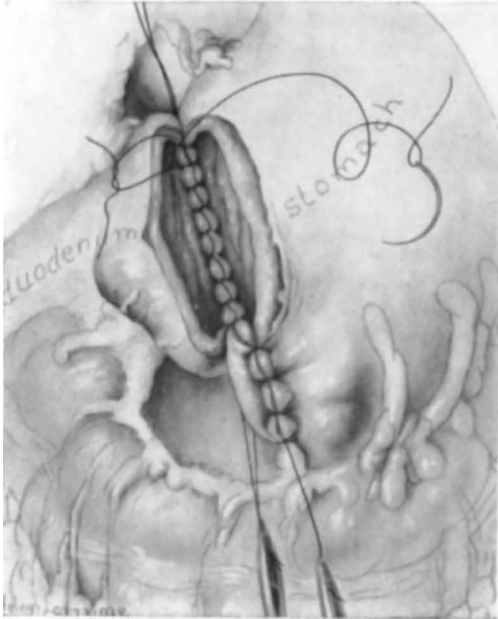


Fig. 405.—Completion of posterior and commencement of anterior line of sutures.

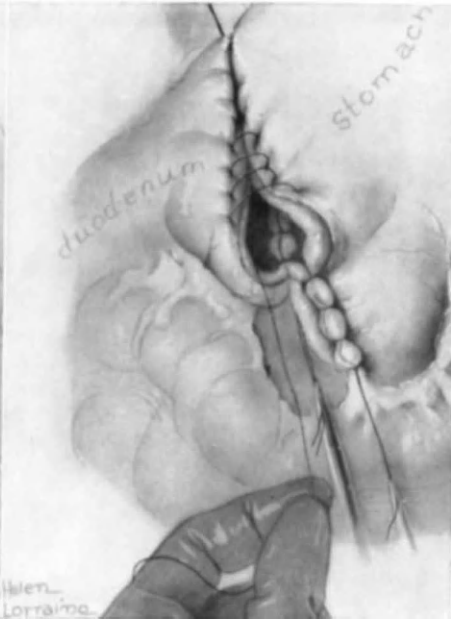


Fig. 406.—Continuation of anterior row of sutures and closure of divided end of greater curvature.

on the duodenum just beyond the pylorus (*Fig. 404, A*). The affected segment is then removed, preferably with the electric cautery, and the posterior margin of the stump of the stomach in the region of the lesser curvature is sutured to the posterior margin of the stump of the duodenum with interrupted mattress sutures of fine tanned or chromic catgut, first externally (*Fig. 404, B*) and then internally (*Fig. 404, C*). The duodenum is flared open, and the posterior line of sutures completed. The anterior row of sutures is now begun, the short end being tied to the short end of the posterior row of sutures (*Fig. 405*), and continued in such a way as to invert the margins of the duodenum and stomach (*Fig. 406*). The suture is drawn taut as it

emerges from the duodenal mucosa, while slight pressure with the thumb or finger is made on the wound just beyond the stitch. A purse-string suture of fine tanned or chromic catgut is placed at the lower part of the stomach, inverting the redundancy (*Fig. 407*), and is continued anteriorly as a continuous right-angled suture with an occasional back-stitch (*Fig. 408*). An additional interrupted or purse-string suture is placed over the lower border of the stomach and the duodenum, and brings over peritoneum-covered fat.

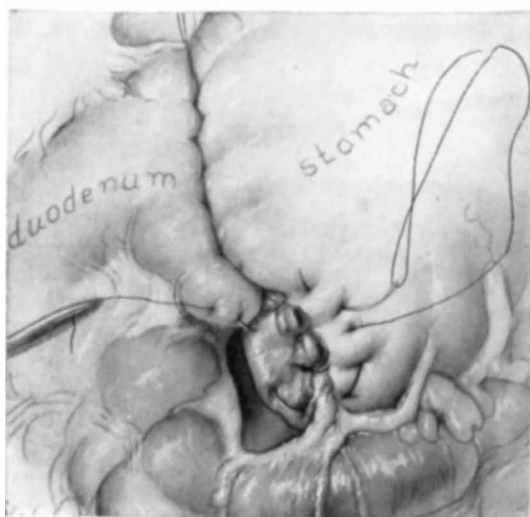


Fig. 407.—Purse-string suture inserted round the sutured greater-curvature end of the stomach to invert any redundancy.

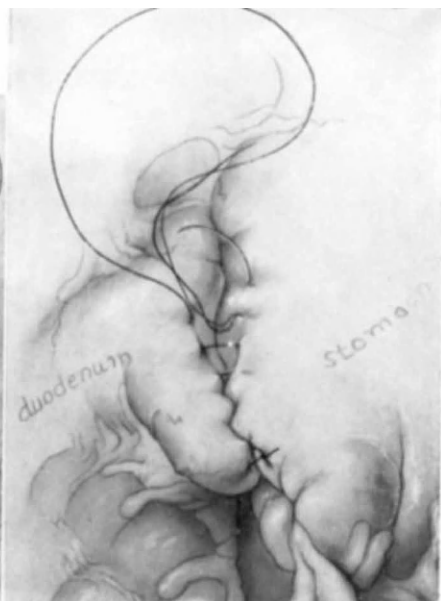


Fig. 408.—Purse-string suture continued anteriorly.

In this modification of the Billroth I operation, the function of the stomach is restored as nearly as possible to normal, the lesser curvature of the stomach being in line with the upper portion of the duodenum, and the gastric canal opens directly into the duodenal lumen.

The Billroth I operation is a good operation to employ in the case of an asthenic woman in whom gastro-enterostomy has been unsuccessful because of motility disturbances or because it has been followed by jejunal ulcer. One reason for this is that the visceral musculature in such a patient is often hypotonic, and a Polya with its large opening into the jejunum is likely to be followed by precipitate

emptying, which causes nausea after taking food, and other unpleasant symptoms. Another reason is that a Billroth I is easy to carry out in such a case, on account of the fact that the redundancy and mobility of the slack and large female stomach and duodenum facilitate its performance.

Billroth I is, too, the operation indicated in unsuccessful cases of gastro-enterostomy in which that unpleasant complication, chronic



Fig. 409.—The resection preparation. It shows the amount of stomach which can be removed.
(Figs. 409-411 by courtesy of Professor Grey Turner.)

gastritis and jejunitis, has developed. In these cases a Polya operation is just as likely to be followed by this chronic inflammatory condition as was the gastro-enterostomy.

In the hands of Professor Grey Turner, Billroth I has been a satisfactory operation. It is astonishing to see the amount of stomach that he can remove and the good results he has obtained with this method. The following case-histories and illustrations, kindly made available to me by his courtesy, exemplify, better than anything I can write, the practical application of this operation.

Case 1.—A man, aged 36, admitted to hospital with the following history: Since three years, had epi-

gastric pains and marked constipation. Duodenal ulcer was diagnosed. After 16 weeks' medical treatment, allowed to go home. Six months later had recurrence of pains and was admitted to hospital, when a gastro-enterostomy was done. Fourteen months later, symptoms returned. Gastroscopy revealed a moderate-sized ulcer on lower part of lesser curvature. A Billroth I partial gastrectomy was performed (Fig. 409), and end-to-end anastomosis of divided jejunum after excision of stoma.

Histology.—"Chronic peptic ulcer, size of shilling, on lesser curvature near gastro-enterostomy stoma. Also acute and chronic gastritis."

The patient made a complete and uninterrupted recovery, and was discharged fit and well, excellent result.

Case 2.—A man, aged 56, admitted to hospital in March, 1937, complaining of attacks of abdominal pain, beginning as a dull ache in the left hypochondriac region and radiating to the left loin, half an hour to an hour after meals. The pain was relieved by lying on the right side. There was no nausea or vomiting, but there was loss of weight. A barium meal showed a cascade stomach, but no other evidence of disease in the gastro-intestinal tract. Wassermann showed negative reaction, test-meals no free HCl, fæces occult blood. Radiograph showed no evidence of

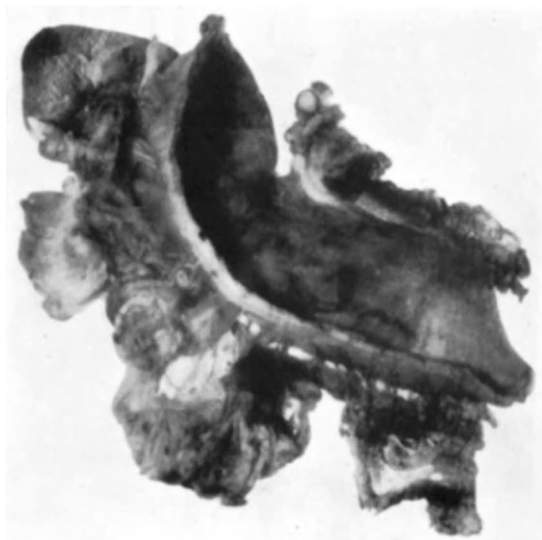

Fig. 410.—Operation specimen—the stomach, greater and lesser omentum, and spleen. The stomach is opened from behind. A scirrhus carcinoma is seen along the lesser curvature, and the cut surfaces of the glands show the spread of the disease.

disease in gastro-intestinal tract. At operation, a gastric carcinoma was found and a Billroth I partial gastrectomy was performed. The spleen was removed at the same time to facilitate the partial gastrectomy (*Fig. 410*). The result was very satisfactory. The patient remained very well, with no complaints, and put on over one stone in weight in four months.

Case 3.—A man, aged 57, 12 years' history of abdominal pain, of burning nature, beginning three inches from the left of the umbilicus and radiating to the left groin and both loins. Onset of pain at any time of day or night—lasting 1 to 3 hours then leaving gradually. Pain recurred every 2 or 3 days and was not related to food. Vomiting occurred with every attack. The vomiting somewhat relieved the pain. In 1932 hæmatemesis occurred while the patient was in hospital for observation. In 1934 hæmatemesis recurred, and a large posterior gastric ulcer was found. About this time, the patient was operated on. An anterior

gastro-enterostomy was performed. In 1935 a jejunostomy was made, and the patient was fed into the jejunum for 14 weeks. He was then free from symptoms for 9 months; at the end of this time no ulcer could be seen by X rays. In 1936 (after 7 months) the symptoms recurred. X rays showed a patent stoma, and a large lesser-curve ulcer. At operation, a Billroth I partial gastrectomy, including the stoma, was performed (*Fig. 411*), and end-to-end anastomosis was done. Microscopical examination showed a simple ulcer with liver substance forming the floor. The patient made a rapid and uninterrupted recovery.

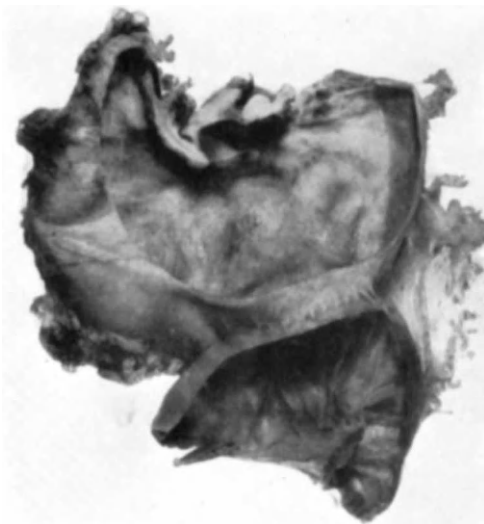

Fig. 411.—Stomach, pylorus, and cuff of duodenum. The stoma of the old anterior gastro-enterostomy with afferent and efferent loops is seen. On the lesser curvature is a deeply penetrating chronic ulcer attached to a piece of liver substance.

DISPOSITION OF THE OMENTUM

In any method of partial gastrectomy, before suturing of the abdominal wound, the omentum should be arranged as a screen under the wound, so that the coils of small intestine cannot become adherent to the peritoneal wound in the abdominal wall, although they may become adherent to this omental screen. This precaution is taken in order to prevent the small intestine becoming adherent to the abdominal wall, and causing minor degrees of chronic intestinal obstruction or pain and morbidity. Adhesion of the small intestine to the omentum rarely gives rise to any trouble.

REFERENCES

- ¹ THOREK, *Modern Surgical Technic*, 3, 1314-15. London and Philadelphia: Lippincott.
- ² HORSLEY, J. S., *Surg. Gynecol. and Obst.*, 1935, Feb. 15.

CHAPTER L

THE TECHNIQUE OF PARTIAL GASTRECTOMY :

**IV. VARIATIONS WHEN DEALING WITH DIFFERENT
TYPES OF ULCER AND WITH MYOMA OF
THE FUNDUS OF THE STOMACH**

It will be necessary to modify the technique of partial gastrectomy in the following types of ulcer: (1) Callous penetrating ulcer of the posterior wall of the duodenum; (2) Ulcer high up on the lesser curve, or ulcer of the lesser curve penetrating the left lobe of the liver; (3) Ulcer of the posterior wall of the stomach penetrating the pancreas; (4) Ulcer of the prepyloric part of the stomach, which is penetrating, which so infiltrates vital structures in its neighbourhood that it is quite irremovable—the so-called ‘ulcer tumour’ (see p. 142).

**CALLOUS PENETRATING ULCER OF THE POSTERIOR WALL OF
THE DUODENUM**

In partial gastrectomy and duodenectomy for ulcer of the duodenum, the ulcer may be found to extend down the posterior wall so far, or to penetrate so deeply, that the dissection of the duodenum from the surrounding important structures is attended with grave dangers.

Even if these difficulties are overcome, and the duodenal ulcer is removed, it may be found that the closure of the divided duodenum is difficult, that it cannot be satisfactorily closed in three layers, and that this unsatisfactory closure may be attended with suture insufficiency and leakage of duodenal contents.

In these circumstances, two methods are available: a partial gastrectomy with a duodenectomy in which the ulcer is resected; or a partial gastrectomy with a prepyloric closure, that is, practically a partial exclusion.

In the first method, the anterior duodenal wall, which is free from inflammatory infiltration, is cut as close as possible to the pyloric sphincter, and the posterior wall, bearing the ulcer, is removed with the distal two-thirds of the stomach. The duodenum is closed

by suturing the long redundant anterior wall to the short posterior wall—the redundancy of the former making up for the shortness of the latter. Omentum is used to reinforce the line of suture. *Fig. 412* illustrates the method. This is, of course, a dangerous operation. The removal of the ulcer is usually attended with difficulty, and the closure of the duodenum requires skill or a suture insufficiency may follow. It is not an operation to be recommended except in the hands of an expert.

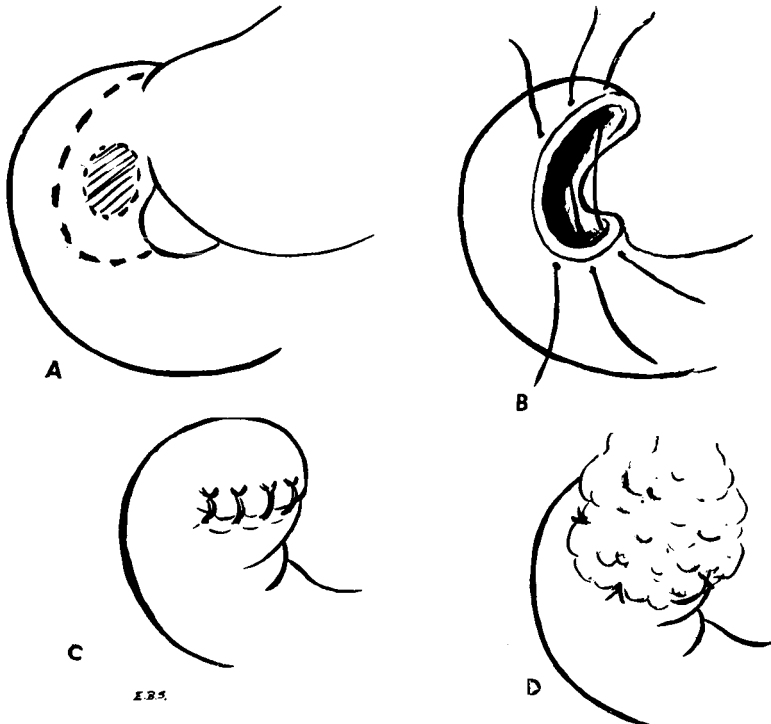


Fig. 412.—A, Line of incision in the duodenum, so as to leave its healthy anterior wall; B, C, Method of closure after resection of the ulcer; D, Omentum used to reinforce the suture.

In the second method the ulcer is excluded and a partial gastrectomy performed. The stomach is divided at a point about 6 cm. proximal to the pylorus, and closure is made at this point.

Such an operation, it is pointed out, involves the danger of leaving the ulcer. Its non-removal, however, is not a great disadvantage, firstly because experience has shown that it always heals, and secondly because, unlike a gastric ulcer, there is no danger of the duodenal ulcer which is left in situ becoming malignant.

This operation, it is also argued, is liable to be followed by jejunal ulcer. It is contended that the preservation of the prepyloric part of the stomach leaves in situ a mechanism which initiates a second stage of gastric secretion, and which therefore causes a high gastric acidity and jejunal ulcer. As a matter of fact, this is probably not true. In cases where I have at a first operation preserved the pyloric part of the stomach and then at a second operation removed it, there has been no difference in the acidity.

In using this method, it is necessary to remember a practical point. As the gastric wall is very thick in the neighbourhood of the pylorus, and as this thickness will interfere with the inverting of the wall, it is a most important point in technique to make sure that the stomach is divided far enough away from the pylorus to allow the cut edges to be turned in and properly sutured. Division of the stomach too close to the pylorus is a common mistake and a very serious one, for if insufficient stomach for proper closure is left, there is no alternative but to attempt to resect the duodenum and to make a duodenal closure—that is, to perform the operation which was originally avoided because it was thought too difficult to carry out.

Mucoclasia.—Sometimes it may be advisable to remove the mucous membrane of the prepyloric part of the stomach before it is closed. This may be considered because it is thought that in this part of the stomach there is formed a hormone which initiates a second phase of gastric secretion, and that the removal of the mucous membrane avoids this. The removal of the mucous membrane from this part may, however, be necessary for another reason; that is, to enable a prepyloric closure to be more easily carried out. If, for instance, the division of the stomach has been made too close to the pylorus, the removal of the mucous membrane will enable a prepyloric closure, which could not otherwise be made, to be effected.

The mucous membrane is dissected out as shown in *Fig. 413*.

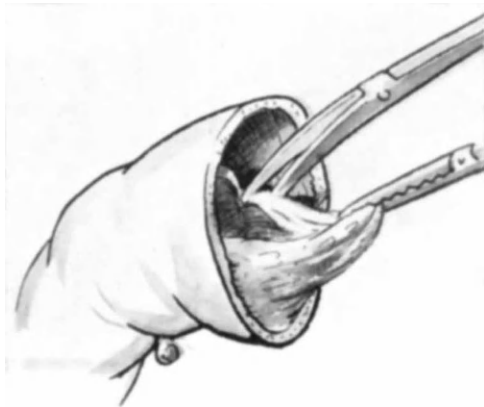

Fig. 413.—Mucous membrane dissected out of the prepyloric segment before it is closed.

ULCER HIGH UP ON THE LESSER CURVE

An ulcer in this situation necessitates variations of the usual technique of partial gastrectomy. These variations are as follows :—

The Costal Incision.—Where the lesion is situated high on the lesser curvature, and difficult to approach, I find that what I have called the costal incision provides an excellent approach. In special circumstances I have employed this costal margin incision, either alone or combined with a paramedian incision. Usadel¹ also writes on the value of this incision, and the illustrations of it (right side) are taken from his paper.

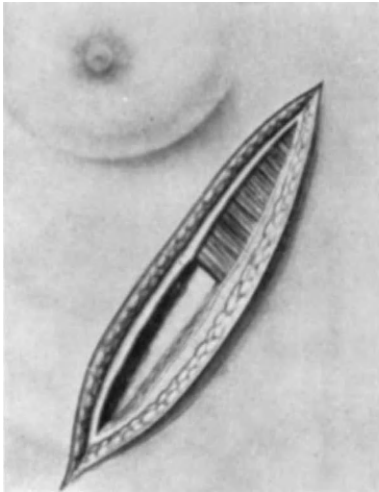


Fig. 414.—Skin, subcutaneous tissue, pectoralis fascia, and external oblique muscle cut through.
(Figs. 414-417 from 'Der Chirurg'.)

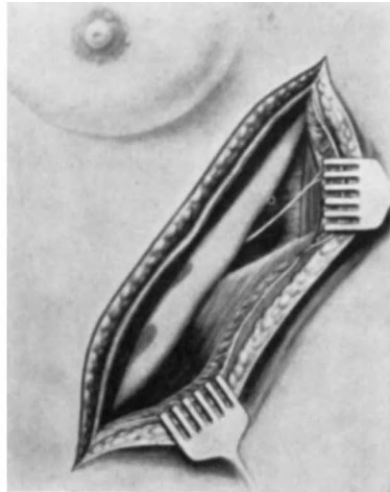


Fig. 415.—After the rectus muscle is cut through, the divided rectus and external oblique are drawn downwards. The base of the wound shows the rib, below this laterally the internal oblique muscle and its aponeurosis, and medially the transversalis muscle, on which runs the anterior twig of the 8th intercostal nerve.

This incision has certain advantages. The rectus muscle is divided well above, and its posterior sheath and the other muscles well below, the costal margin, and therefore it is a valvular one. The rectus muscle is divided where it lies on the thorax, where it fans out to obtain its costal attachments; in this position it has little postural muscle tone, and there is therefore no difficulty in closing the wound, and little danger of subsequent hernia. Lastly, no nerves are injured, and a majority of the muscle-fibres are separated in their line of direction.

The steps are :—

1. The incision starts at the base of the ensiform cartilage and runs laterally about an inch above the costal margin and parallel to it to where it is joined by the 9th rib.

2. The rectus muscle where it lies on the thorax and the external oblique muscle in the same situation are divided (*Fig. 414*).

It will be noticed that the rectus muscle retracts very little after division. The rectus muscle and external oblique are now retracted caudally and the costal margin is exposed (*Fig. 415*).

3. The second part of the incision is now made three-quarters of an inch below the costal margin, when the posterior layer of the

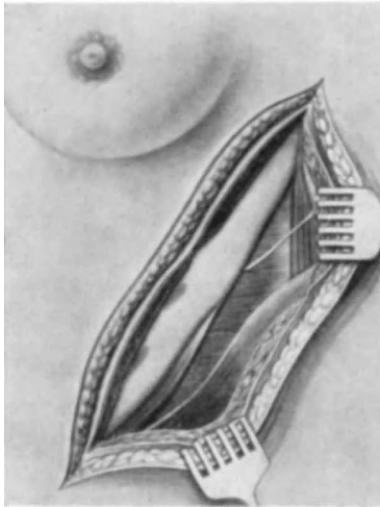


Fig. 416.—Internal oblique muscle cut through.

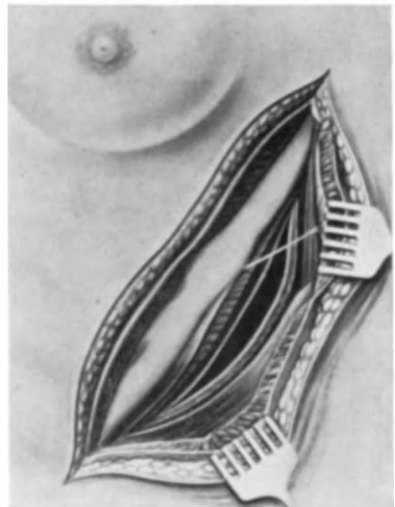

Fig. 417.—Division of the transversalis muscle and fascia, and incision of the peritoneum.

rectus sheath is divided or separated, and fibres of the internal oblique and transversalis are, where possible, separated along the course of their fibres; and where this is not possible they are divided (*Fig. 416*).

4. The peritoneum is then opened transversely (*Fig. 417*).

The incision is here illustrated on the right side, but the illustrations are equally applicable to the left side. The incision is valuable because it gives an approach to the abdomen in its highest part, and because the post-operative pain is not so great as in a paramedian incision, and therefore the patient can cough, clear his lungs, and lessen the incidence of pulmonary complications.

The Costal combined with a Paramedian Incision.—From the transverse costal incision just described, a vertical one is made in the rectus sheath about three-quarters of an inch from the midline, and the fibres of the rectus itself are separated in a vertical direction (*Fig. 418*). The posterior sheath of the rectus and the peritoneum are divided in the same direction (*Fig. 419*).

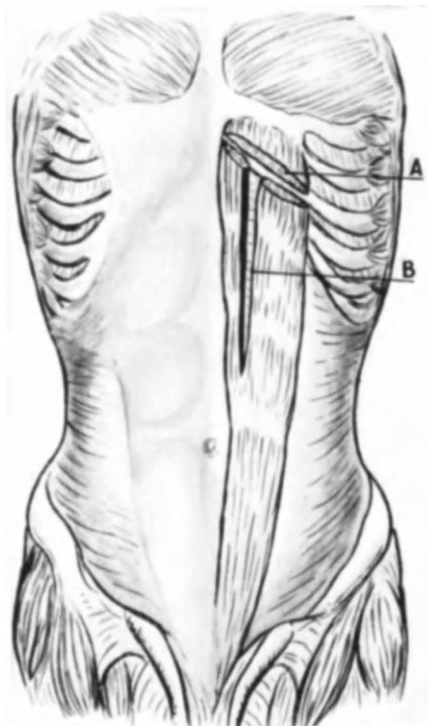


Fig. 418.—A, Transverse division of the reflection of the rectus muscle over the lower margin of the thorax. B, Paramedian vertical incision in the rectus connecting with the transverse incision.

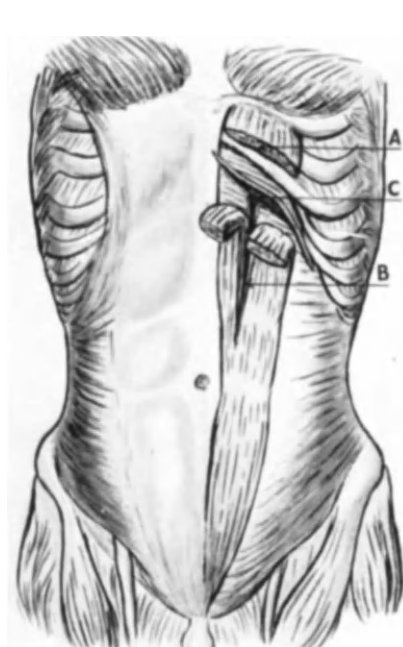


Fig. 419.—A and B as in *Fig. 418*. C, Transverse incision in the posterior sheath of the rectus extending into the lateral aponeurosis of the abdominal wall. This incision is at a lower level than that of the rectus muscle reflection lying on the lower edge of the thorax, and runs, of course, almost parallel with the nerves of the abdominal wall.

The combination of a vertical incision in the rectus with a high transverse incision gives an excellent exposure of the upper part of the lesser curvature—the critical part of the operation in the case of a partial gastrectomy for an ulcer in this situation.

Exposure of the Lesser Curvature with Operating Frame.—The operating frame is inserted in the usual way (*see Chapter XXXIV*); but for adequate exposure of the upper part of the lesser

curve, which is sheltered by the lower ribs and the left lobe of the liver, two additional 'hands' are used.

One of these (*Fig. 420, 1*) is inserted into the upper left corner of the wound and fixed to the frame. Its object is to obtain an

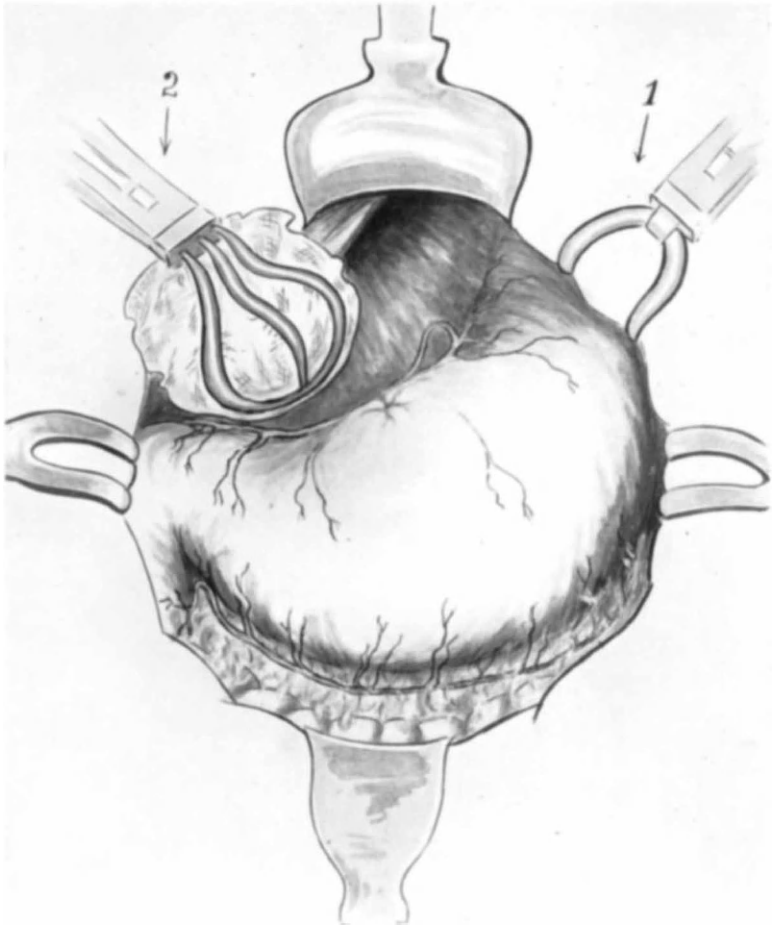


Fig. 420.—Extra 'mechanical hands' necessary for the exposure of the inflammatorily contracted lesser curve. 1, 'Hand' enabling the thoracic wall to be lifted; 2, 'Hand' with scarf to retract left lobe of liver.

additional grip on the thorax and enable the assistant, by raising the frame, to lift the chest wall away from the stomach and thus expose the proximal part of the lesser curve and the region of the œsophagus, in order to permit the surgeon to approach and suture in this region with comfort.

The second mechanical 'hand' (*Fig. 420, 2*), specially padded and shaped, is used to draw the left lobe of the liver to the right so as to lift this overhanging lobe away from the upper part of the lesser curve.

Thus, by the use of the operating frame and special 'mechanical hands', the calloused and contracted lesser curve—the dissection of which is the difficult part of the operation—is well exposed to

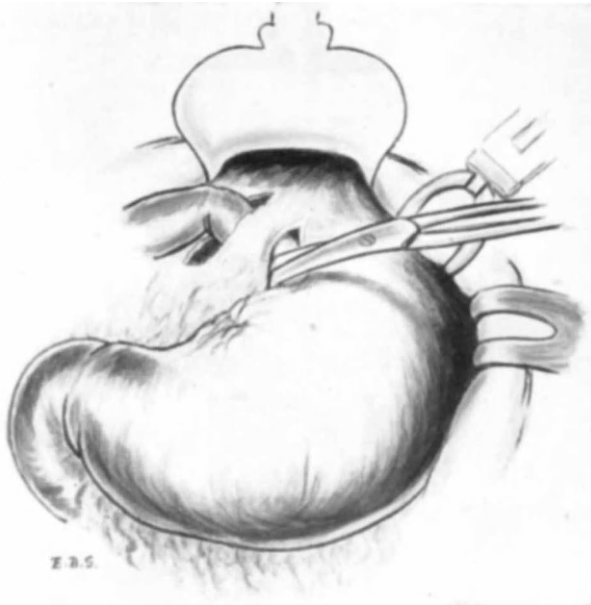


Fig. 421.—Curved spade-pointed scissors applied to the vessels of the lesser curvature, separating them from the stomach.

view, and manipulations untrammelled by a constantly prolapsing left lobe of the liver can be carried out.

Mobilization of Inflammatorily Infiltrated Gastrohepatic Omentum and Lesser Curve.—This may be extremely difficult and may sometimes require great ingenuity.

An opening in the thin part of the lesser gastrohepatic omentum is made as close as possible to the œsophageal opening, and the finger passed behind the stomach, towards the angle between the œsophagus and the lesser curve. In this area search is made above the upper limit of the dense infiltration for a part of the gastrohepatic omentum that is not infiltrated—that is, for an area of

normal omentum. In some cases such a point will only be found close to the œsophagus.

Using the pulp of the finger behind this spot as a counter-pressure, the surgeon employs the spade-pointed scissors gently to isolate the gastric wall from its leash of vessels for a length of at least half an inch (*Fig. 421*). The plane of the wall of the stomach must be followed with gentleness; for the slightest roughness will produce venous bleeding which is difficult to stop.

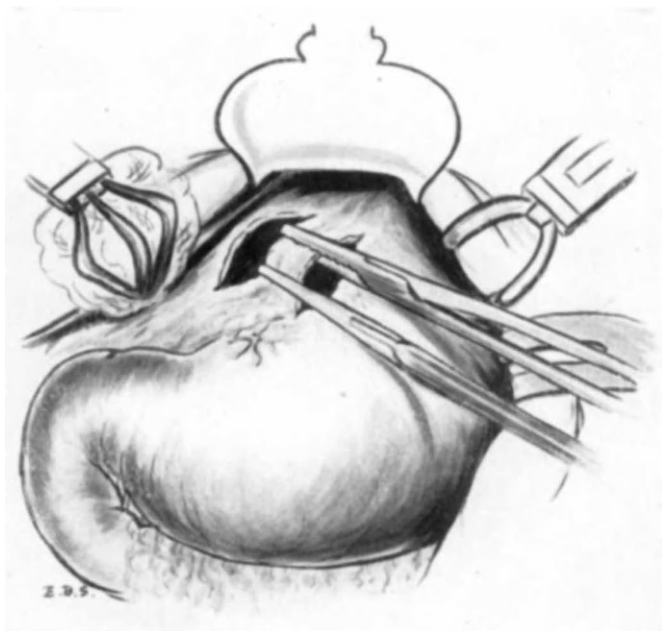


Fig. 422.—Leash of vessels and omentum separated from upper part of lesser curvature, which are divided between Kocher's clamps.

Two Kocher's clamps are applied to the leash of vessels and mesentery which have been isolated, as shown in *Fig. 422*, and these structures are divided between the clamps. Using the Kocher's clamp attached to the proximal end of the cut tissue to hold the mesentery and vessels away from the lesser curvature, and thus put tension on the small vessels running from the mesentery into the stomach, the surgeon clamps and cuts these vessels for a distance of 2 cm. proximally from the proposed line of division of the stomach. His object is to denude an area which will be sufficiently wide to allow the turning-in of the three rows of sutures (*Fig. 423*).

At the upper end of this denuded area (*Fig. 423, A*) a catgut 'guy-rope' (*B*) is inserted through all the coats of the stomach. Below this 'guy-rope', the lesser curve with its ulcer and infiltrated mesentery is longitudinally excised (*Figs. 424, 425*). When the first opening is made in the stomach, an aspirating tube is inserted and the interior of the stomach 'vacuum-cleaned'.

The excision of the lesser curve is made in sections. As a section is excised, in order to prevent the stomach opening too

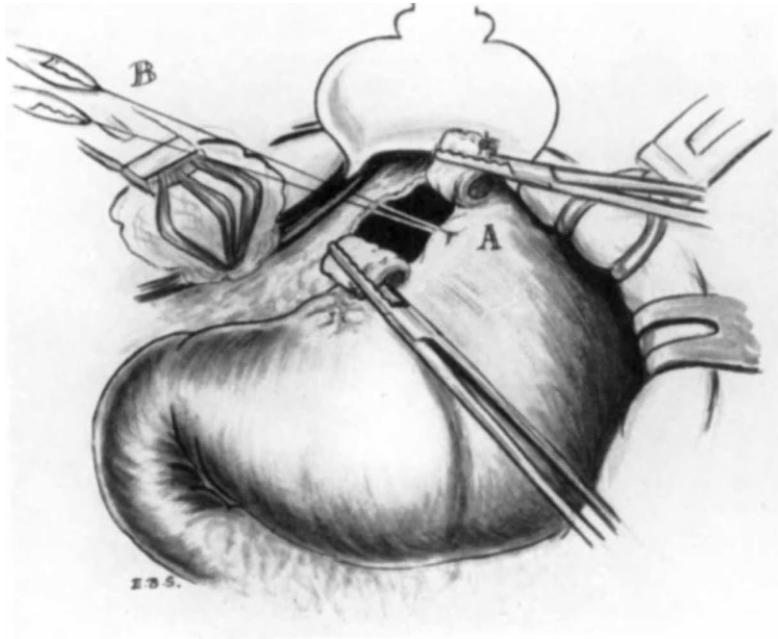


Fig. 423.—Part of the lesser curvature proximal to the proposed line of division of the stomach denuded of its vessels, to make a space which can be folded in when making the gastrojejunal anastomosis. Note the 'guy-rope' suture inserted in upper part of this area. A, Denuded area; B, 'Guy-rope' suture.

widely and spilling any residual contents, the divided mucous membrane of the gap left is at once stitched up. Meanwhile the ulcer-bearing flap of the lesser curvature which is being resected is used as a tractor, and greatly facilitates the suture of the defect. Proceeding in this way, the level of the stomach below the ulcerated area is reached (*Fig. 425*).

Still using the resected part as a tractor, the surgeon completes the suture of the seromuscular layers of the lesser curve. All vessels are, of course, clamped and tied as they bleed.



Fig. 424.—Beginning of the excision of the lesser curvature with its ulcer and mesentery. An aspirating tube is inserted in the stomach and the stomach 'vacuum-cleaned'; the tube is left in position to prevent leakage of gastric contents.

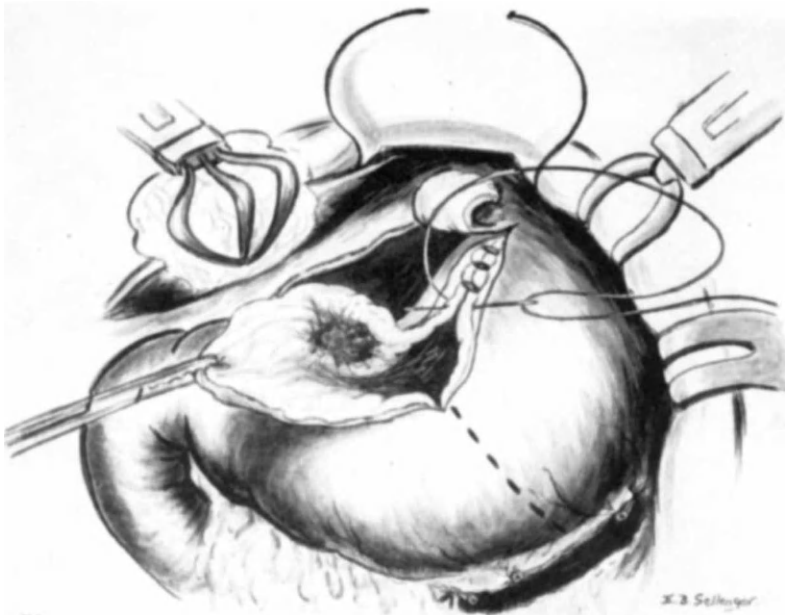


Fig. 425.—The ulcer-bearing flap of the lesser curvature resected, the flap being used as a tractor while sutures are inserted in the gap which has been left.

Completion of the Operation.—The gastro-epiploic vessels on the greater curvature, opposite the proposed line of section of the stomach, are now divided. Using a light gastric clamp to avoid leakage of contents, the stomach is divided transversely. The occluding gastric clamp is released momentarily so that any divided vessels may bleed and be ligated. The distal part of the stomach with the attached ulcer-bearing flap of the lesser curve is removed at a prepyloric level and a prepyloric closure made in the usual way.

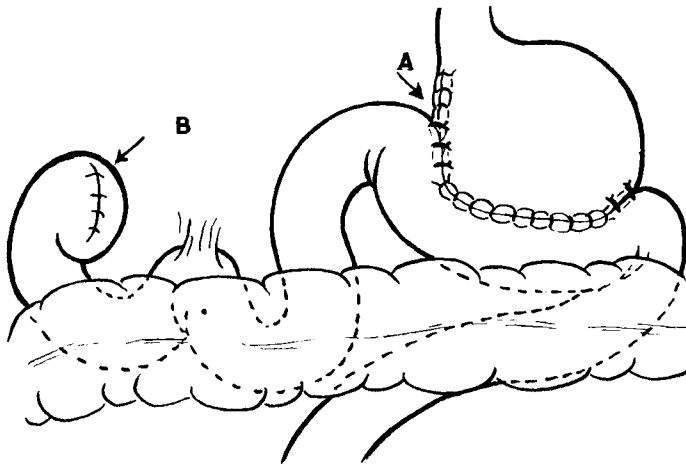


Fig. 426.—Diagram to show the finish of a partial gastrectomy for ulcer high up on the lesser curvature. **A**, Afferent loop stitched over the sutured lesser curvature; **B**, Prepyloric closure, which, in partial gastrectomy for ulcer of the lesser curvature, is usually all that is necessary.

A short retrocolic loop of jejunum is made by mobilizing the duodenojejunal flexure, as described on p. 497. The efferent limb is fixed by sutures to the transverse mesocolon. The divided end of the stomach is anastomosed to the jejunal loop above the colon, after the method of Polya. The afferent loop should be fixed by a few interrupted stitches over the sutured part of the lesser curve (*Fig. 426, A*).

RESECTION OF A CHRONIC ULCER HIGH UP ON THE LESSER CURVATURE COMBINED WITH A GASTRO-ENTEROSTOMY

A resection of the ulcer combined with a gastro-enterostomy is a useful method for dealing with ulcer high up on the lesser curvature. The operation is fraught with technical difficulties, but it is less dangerous than the extensive partial gastrectomy which is required

for an ulcer in this situation, and further, it gives a good percentage of permanent cures.

The objection to the operation is that the resection of the ulcer with part of the lesser curve destroys the ganglion centres which govern orderly peristaltic movement, and thus interferes with the emptying power of the stomach. But this loss of motility is somewhat compensated by the increased rapidity of emptying which the addition of a gastro-enterostomy confers on the crippled stomach.

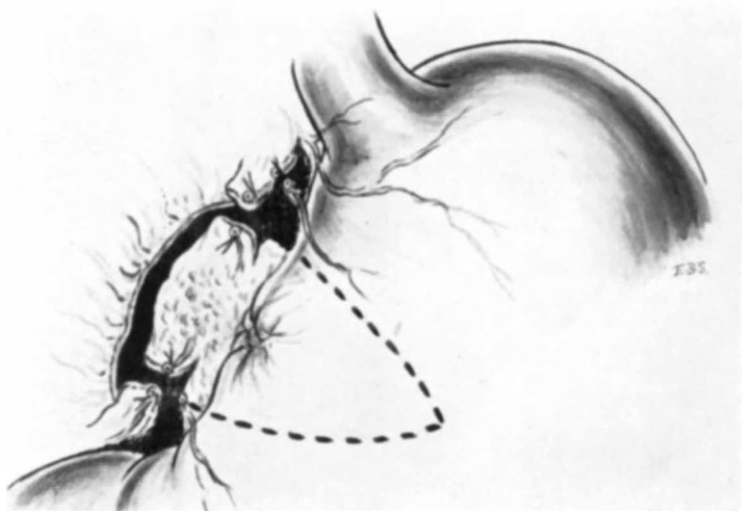


Fig. 427.—Distal and proximal areas on lesser curve cleared of vessels. The broken line indicates the incision to be made on the anterior surface of the stomach opposite the ulcer.

The steps in the technique of the operation (carried out without pressure forceps) follow.

Resection of the Ulcer.—In this case, in order to remove as little as possible of the lesser curvature, the ulcer is resected transversely. At points on the lesser curve, well above and below the inflammation surrounding the ulcer, the vessels are separated from the stomach by the spade-pointed scissors (*see Fig. 421*).

Each bunch of vessels is divided between Kocher clamps (*see Fig. 422*).

The proximal clamp is now used as a tractor, and an area of the lesser curve denuded of vessels as shown in *Fig. 423*. The distal clamp is then utilized in the same manner to clear a similar area for suturing purposes on the lesser curve below the ulcer (*Fig. 427*).

The resection of the ulcer is begun by making a V-shaped incision on the anterior surface of the stomach opposite the ulcer. Through the opening thus made the stomach is aspirated (*Fig. 428*).

The removal of the segment of the stomach which bears the ulcer is now proceeded with in steps, suture of the cut edges of the stomach following closely as each segment of the ulcer-bearing area is resected. In this way the opening in the stomach is never allowed to gape widely, and the spilling of contents can be avoided by the assiduous use of suction.

The resected segment is used as a tractor (*Fig. 428*), in order to facilitate the suturing of the incisions.

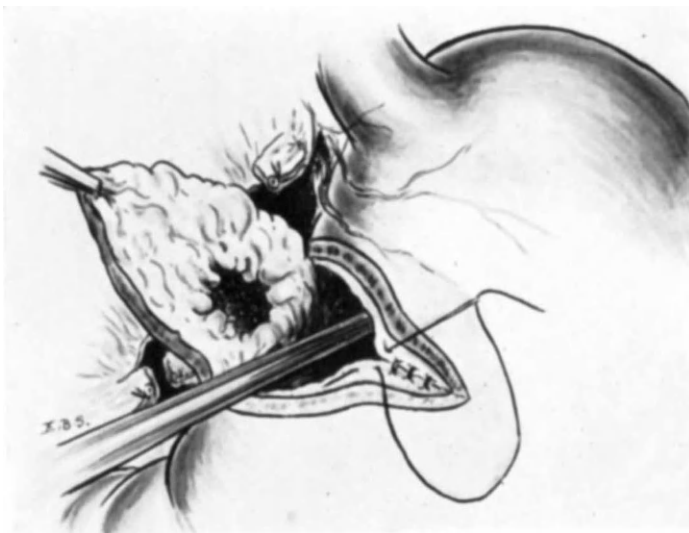


Fig. 428.—Stomach aspirated through V-shaped opening on anterior surface.

Incisions are now continued through the lesser curvature, and on to the posterior surface of the stomach, which for this purpose is turned upwards through an opening made in the gastrocolic omentum. The gap is closed as shown in *Fig. 429*.

In all cases, before suturing is begun, any bleeding vessels in the cut edges of the stomach are clamped and tied with fine catgut. The mucous membrane is sutured as a separate layer (*see Fig. 429*), because this can be done rapidly and the large opening in the stomach closed quickly, and thus the danger of leakage of gastric contents can be minimized.

When the mucous membrane is completely closed, and all danger of leakage from the stomach is past, the wound can be cleaned

of blood, small oozing points stopped, and a pad of gauze soaked with 1-1000 acriflavine solution laid for a few minutes over the sutured area. A seromuscular suture and a serous suture may now be inserted in comfort.

It will be noticed that no tourniquet-like gastric clamps are used. The vessels in this part of the stomach are large, and they must be separately ligated; and to attain success in these resections even the smallest vessels must be tied.

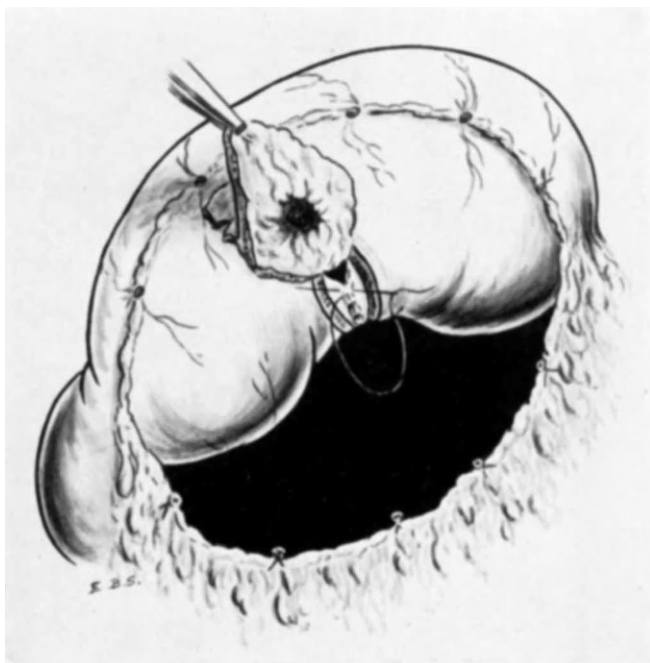


Fig. 429.—Suture of incisions on the posterior surface of the stomach. (An opening to expose the posterior surface has been made in the gastrocolic omentum.)

The Gastro-enterostomy.—In performing the gastro-enterostomy, it is necessary to keep as far away as possible from the sutured area. This is accomplished by placing the stoma exactly on the greater curve. For this purpose this area must be cleared of vessels for a distance of 2 in. in a manner similar to that illustrated in *Figs. 315, 316* (pp. 441, 442). The jejunum is applied to the stomach and anastomosed to it in the way already described (see *Figs. 317-325*, pp. 443-449). The anastomosis is drawn below the transverse mesocolon, and the edges of the stomach are fixed by interrupted sutures to the opening in the mesocolon (see *Fig. 326*, p. 450).

LESSER-CURVE ULCER PENETRATING THE LEFT LOBE OF THE LIVER

In this case there are two great operative difficulties: the dissection of the penetrating ulcer out of the liver, and the resection of the ulcer from the lesser curve.

The technique is as follows:—

The dissection of the ulcer is begun from the posterior edge of the ulcer on the under surface of the left lobe of the liver, for in

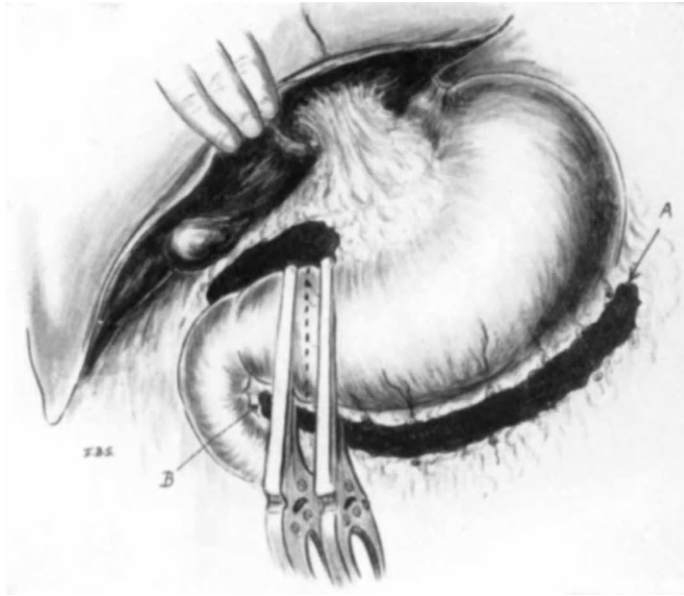


Fig. 430.—The whole of the gastrocolic omentum divided (A to B). Two Payr's clamps are placed side by side at a level about 6 cm. from the pylorus.

this situation the adhesions are most vulnerable, and the plane between the edge of the ulcer and the liver is found most readily.

In order to expose the under surface of the left lobe of the liver the gastrocolic omentum must be extensively divided along its whole length as far as the duodenum (*Fig. 430, A B*). The gastrohepatic omentum must also be divided. The stomach is then sectioned between clamps 6 cm. from the pylorus. It is next turned up, so as to expose the posterior wall high up on the lesser curve, and thus to demonstrate the attachments of the ulcer to the liver in this region—the easiest part in which to begin the dissection of the ulcer from the liver (*Fig. 431*).

At this spot an opening is boldly made through the friable tissue which unites the edges of the perforated gastric wall to the liver, into the base of the ulcer, which is formed of liver substance, and which is part of the gastric cavity. Through this opening an aspirating tube is introduced and the gastric contents are completely evacuated. The friable line of cleavage between liver and stomach is now followed at the margin of the ulcer, when it will be found that the edge of the ulcer can be easily shelled off the liver surface, probably because in this region the inflammation is recent and therefore the tissue is not fibrous.

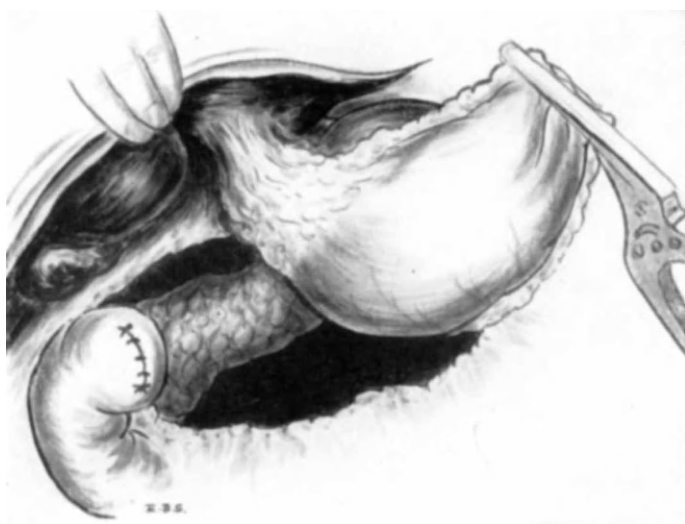

Fig. 431.—Posterior surface of the stomach turned over to the left and upwards, so as to expose the posterior edge of the ulcer which penetrates the liver.

When the edge of the ulcer has been separated from the liver, the opening thus made in the stomach is closed temporarily with a continuous silk suture, in order to prevent leakage of gastric contents. The lesser curve is now resected, and the cut end of the stomach anastomosed to the jejunum in the manner already described (pp. 528–532).

The infected base of the ulcer, as it lies in the liver, should be painted with metaphen or acriflavine. It should also be covered with a little flap of omentum which may be swung to it from some neighbouring region, and a drainage tube should be inserted to the site of the ulcer.

ULCER OF THE POSTERIOR WALL PENETRATING THE PANCREAS

This ulcer is approached in the same way as the ulcer of the lesser curve penetrating the liver.

The gastrocolic and gastrohepatic omenta are divided. The stomach is sectioned 6 cm. proximal to the pylorus and turned upwards so as to display the attachment of the posterior wall of the

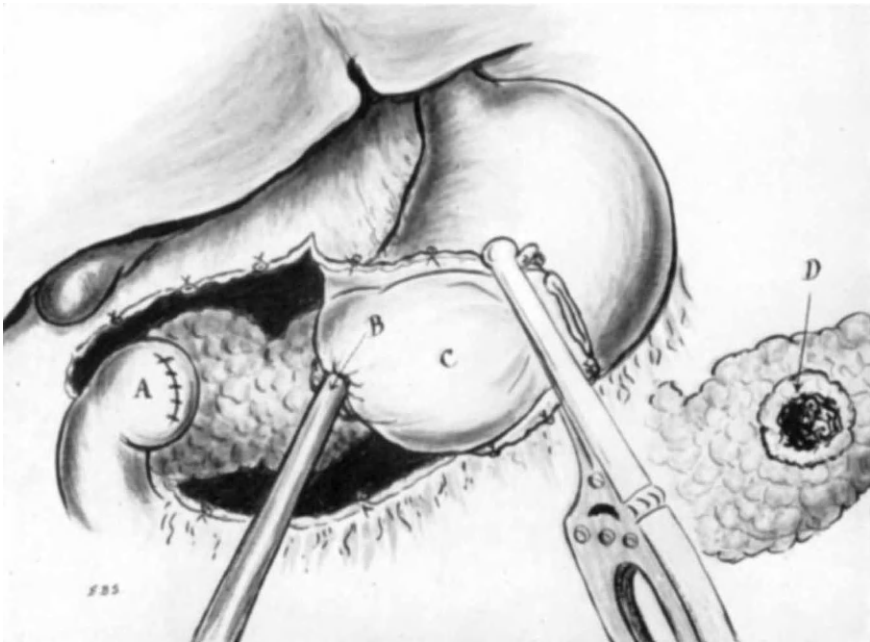


Fig. 432.—Operation for penetrating ulcer of the pancreas. A, Prepyloric closure of the stomach. The pyloric part is turned back to show the edge of the ulcer, and through this edge an aspirating tube B has been introduced in order to 'vacuum-clean' the stomach. C, Stomach turned back; D (inset), Pancreas showing the bed of the ulcer after the adherent stomach has been shelled off.

stomach to the pancreas. A line of cleavage between the pancreas and the stomach is sought, and along this plane an opening is made into the base of the ulcer (*Fig. 432*).

Through this opening an aspirating tube is inserted, and the stomach contents aspirated. The stomach is then shelled off the pancreas by following the margin of the ulcer, and divided in the usual way proximal to the ulcer. The operation may now be completed after the method of Polya or Billroth II. The infected

base of the ulcer which is formed by the surface of the pancreas is disinfected as far as possible, and a drainage tube is placed down to it.

'ULCER TUMOUR' OF THE PREPYLORIC PART OF THE STOMACH

Irremovable 'ulcer tumours' of the prepyloric part of the stomach can be dealt with most effectively by performing a partial gastric exclusion.

MYOMA OF THE FUNDUS OF THE STOMACH

A vertical paramedian incision combined with a transverse costal incision (*see* p. 526) is necessary in order to expose adequately a myoma situated in the fundus of the stomach, under the dome of the diaphragm.

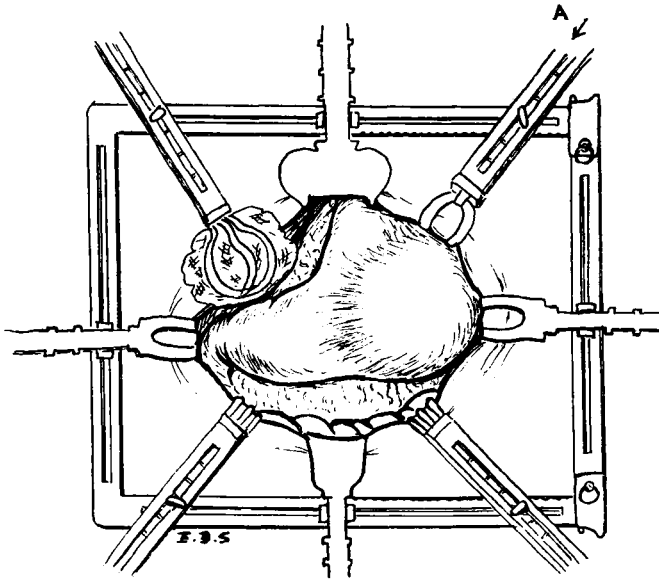


Fig. 433.—Exposure of a myoma of the fundus of the stomach.
A, Special wound retractor fixed to operating frame.

The operating frame is inserted, with a special wound retractor (*Fig. 433, A*) fixed to the frame to enable the costal margin to be lifted away from the stomach.

The actual steps in the removal of the tumour are clearly shown in *Fig. 434*.

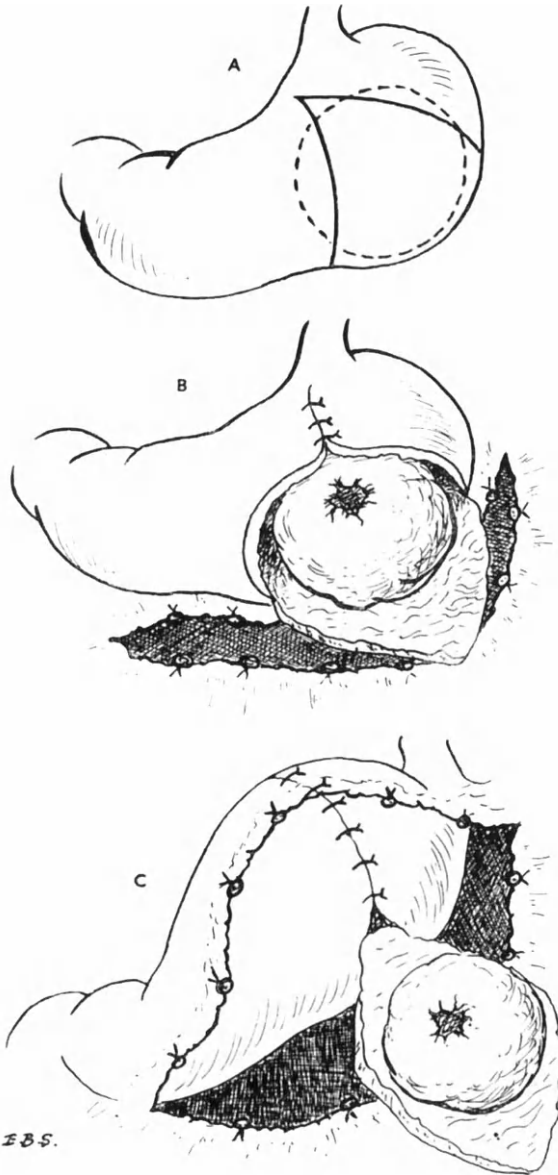


Fig. 434.—A, B, C, Steps in the method of removal of a myoma and closure of the resulting defect in the stomach.

REFERENCE

¹ USADEL, W., "Der Rippenrandkulissenschnitt", *Der Chirurg*, 1938, Dec. 1, No. 23, 825.

*CHAPTER LI***CLOSURE OF ABDOMINAL WOUNDS****LIGATURES AND SUTURES**

Two kinds of ligatures or sutures may be used: unabsorbable or absorbable. In the past the use of the unabsorbable sort was much more in vogue, because the difficulty of sterilizing catgut had not been overcome. The unabsorbable sutures that may be used are silk and silkworm-gut.

Silk.—Silk is not irritating, is very well tolerated by the tissues and the peritoneum, and causes very little reaction. Catgut, on the other hand, tends to cause reaction in the peritoneum and in consequence to give rise to adhesions. It is therefore my custom to use very fine silk for ligation of vessels in the mesenteries, and in the abdominal cavity—that is, of course, in cases where there is no infection. Silk has also the advantage that, as a ligature, it bites in very tightly round the delicate abdominal vessels and does not slip off them—an accident that may occasionally happen when catgut is used. Because of its unabsorbability and its tolerance by the peritoneum without reaction, it should be used in making the outer serous layer of sutures in a gastro-intestinal anastomosis following resection for carcinoma of the stomach. The reason for this is that, as patients with gastric cancer have very little tissue vitality and therefore healing power, and as their gastric contents are not usually sterile, an unabsorbable silk suture in the outer serous layer of the anastomosis is less prone to be followed by the mild suture insufficiency and peritonitis which sometimes follow the use of catgut in this layer.

Silk, too, may be used as a buried suture in clean abdominal wounds. It should, however, only be used in exceptional circumstances.

Silkworm-gut.—Silkworm-gut makes an excellent buried suture, where such is necessary. It can remain buried for years without the slightest irritation. I have removed silkworm-gut sutures which, in order to produce pyloric obstruction, had been used to tie round the pylorus; and even when they have been there for five years, there has not been the slightest peritoneal reaction.

I have also removed silkworm-gut sutures which have been buried—having been used instead of silver wire—in an abdominal wall ten years after their insertion, and there has been no tissue reaction round them.

Thus, where it is necessary in exceptional circumstances to fall back on the use of strong unabsorbable buried sutures when closing an abdominal-wall wound, it is useful to know how satisfactory a buried suture of silkworm-gut can be.

Catgut.—It has been the custom to use two kinds of catgut : the first unhardened, and the second treated with chemicals intended to harden it and delay its absorption in the body. For that purpose formalin, chromic acid, and tannic acid have been used.

Hardened gut, especially the chromic gut, is not very well tolerated by the body, and its absorption is capricious. It is therefore frequently followed by some mild infective trouble in the wound. As this often occurs when the patient leaves the hospital and occasions him much alarm, the use of the hardened gut should if possible be avoided.

As a matter of fact, the use of hardened gut in wounds of the abdominal wall is not called for. Unhardened gut which will last from fourteen to twenty days is easily obtained ; and if a wound has not healed by then, the use of a hardened chromic gut will not keep the edges of the wound coapted, for by this time the sutures will have loosened and partially cut through.

I have always used a catgut prepared by Bartlett's method, which provides a suture with the following advantages :—

It is sterile ; at any rate, as judged from my clinical results.

It is a little less absorbable than the plain catgut.

It does not unravel.

Its tensile strength is increased rather than decreased by the preparation.

Preparation of the Catgut.—The process is divided into three definite stages—drying, sterilization, and storage—which are effected as follows :—

1. The ordinary commercial 10-foot catgut strand is divided into four equal lengths, each of which is made into coils about an inch in diameter. These coils are then strung like beads upon a thread, so that any desired number can be conveniently handled by simply grasping the thread.

2. The string of catgut coils is dried in a bacteriologist's dry sterilizer for four successive hours at a temperature of 80°, 90°, 100°, and 110° C. Gauze is interposed between catgut and vessel. (This

drying process should not be attempted on a damp day, or in a room invaded by steam.)

3. The catgut is then placed in liquid albolene contained in an asbestos-lined kettle, which is so constructed that its contents can be electrically heated. The catgut is allowed to remain in the albolene until it becomes perfectly 'clear' in the same sense in which the term is used when preparing histological specimens. Usually the gut is allowed to remain in the oil overnight.

4. The oil is *gradually* brought up to 140° C., which temperature is maintained for a second hour.

5. By seizing the thread with a sterile forceps the gut is lifted out of the oil, any excess of which is allowed to drip off. The thread is cut and the coils dropped into a solution of iodine crystals in rectified spirit, the proportion of iodine to spirit (weight/volume) varying according to the diameter of the catgut. For No. 00 it should be 1/700; No. 0—1/600; No. 1—1/500; No. 2—1/400; No. 3—1/300; No. 4—1/200.

The material becomes ready for use in a few hours, and should remain in the solution indefinitely without deterioration.

A few coils may be removed at any time without risk of contaminating those left behind. The liquid albolene can be used repeatedly in spite of its colour growing darker with reheating.

In order to be certain that the temperature at the centre of the strand is as high as that of the oil surrounding it, the gut should be thoroughly 'cleared' before the oil is heated. The iodine rapidly permeates the strand, which will be found stained brown after a few hours.

Catgut treated in this way lasts in the tissues somewhat longer than the equivalent strand of *plain* gut treated by most of the other methods in vogue at the present time.

CLOSURE OF THE ABDOMINAL WOUND

A soft, filmy scarf is dropped into the wound, and a spoon laid over this (*Fig. 435*). The peritoneum is sutured with a rigid small round atraumatic Kelly needle,* and in order to minimize the formation of abdominal adhesions, the peritoneal edges are everted by the method of suture shown in *Fig. 436*. The suture should only be drawn tight during the expiratory phase of respiration when the peritoneum is relaxed. If tightened during the inspiratory phase the suture is liable to cut out of the peritoneum.

* Made by Merson, Edinburgh.

Should the abdominal muscles be tense, and as a result of this tension should it be difficult to bring the peritoneal edges together, the following manœuvres are adopted: A running peritoneal suture

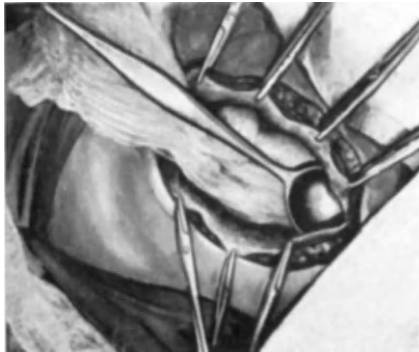

Fig. 435.—Abdominal wound ready to be sutured. Note the protecting spoon.

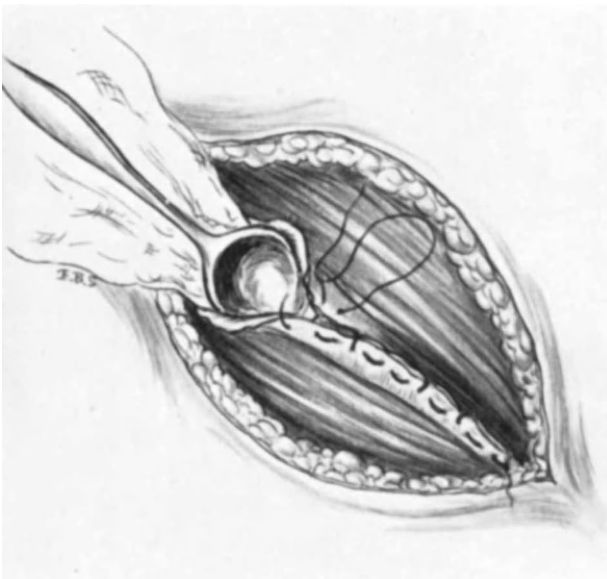


Fig. 436.—Method of everting the peritoneum—an attempt to avoid adhesions between the small intestine and the peritoneal scar in the anterior abdominal wall; such adhesions give rise to unpleasant post-operative symptoms.

is inserted for an inch or more, but not drawn tight. Mattress sutures are inserted far out from the cut edge of the aponeurosis, drawn tight, and knotted. These sutures take the tension off the

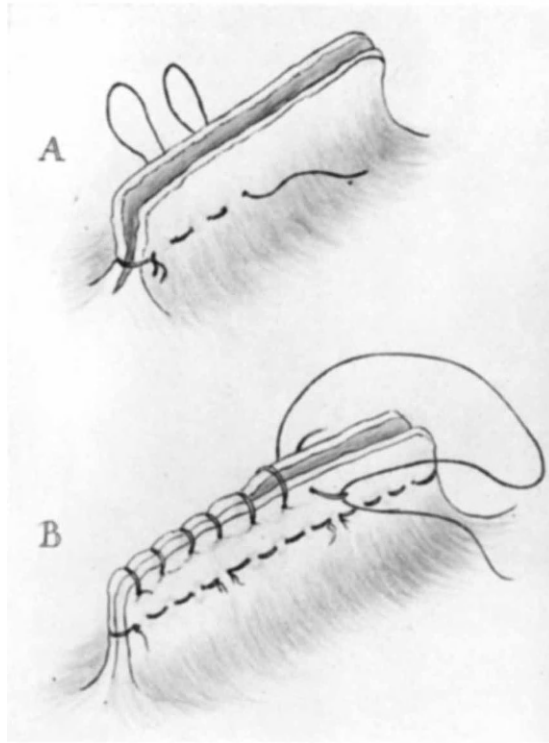


Fig. 437.—A, Suture of the aponeurosis by a vertical running mattress suture, which gives a larger area of coaptation and at the same time draws the separated muscle-fibres close together. A running suture is here used to close the edges of this keel suture, but an overstretch in continuity with the mattress will do as well. B shows the running suture being made.

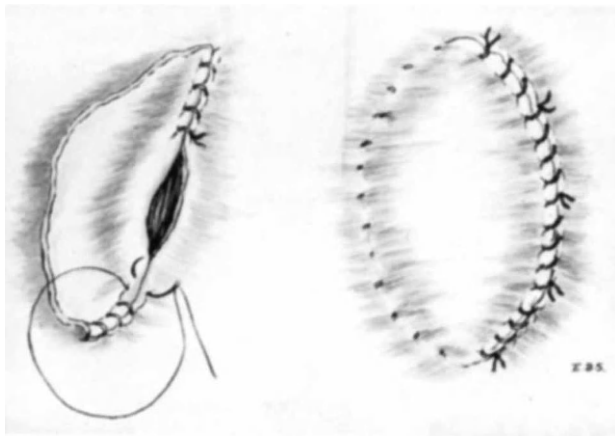


Fig. 438.—Another method of suturing the aponeurosis of the abdominal wall, which makes a very firm closure and takes very little longer time than the ordinary suture.

running peritoneal suture, which can then be easily tightened and locked. This device is most useful in closing the peritoneum when the patient is not properly under the anæsthetic and his muscles are rigid.

Under ordinary circumstances a good routine method of closing the aponeurosis is to bring it together by a running mattress suture

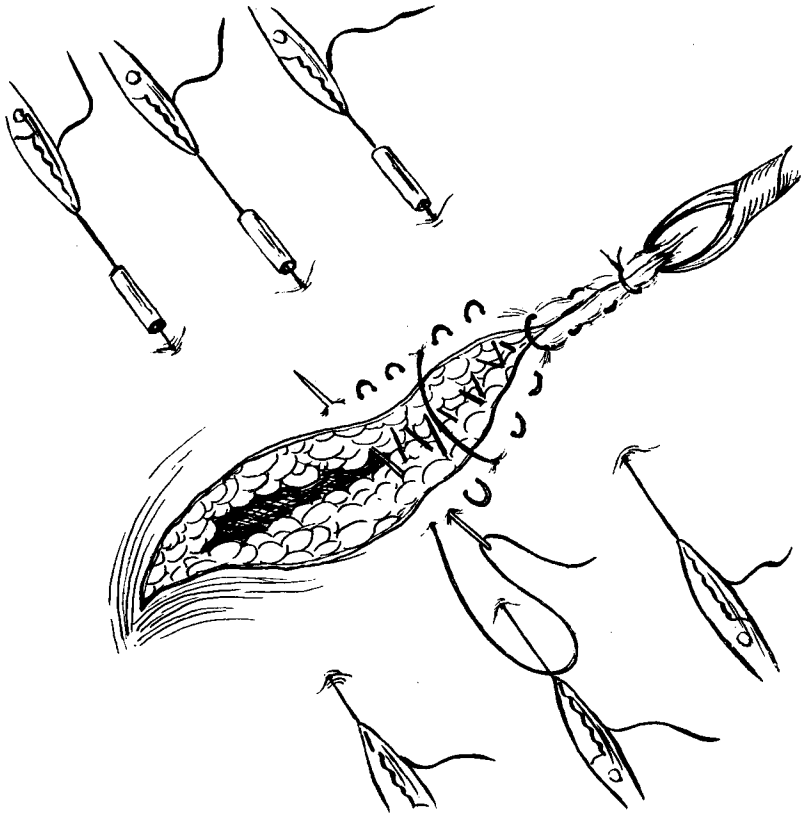


Fig. 439.—Method of introducing silkworm-gut sutures armed with small rubber tubes to prevent cutting.

passing through each flap of the aponeurosis half an inch from its edges, the mattress suture being interrupted by an overstitch about every three-quarters of an inch—a method of suturing which was used by Sir Alexander MacCormick. (*Fig. 437.*)

Another method of closing the aponeurosis which may be employed as a routine is to imbricate the aponeurotic flap (*Fig. 438*).

Reinforcing silkworm-gut sutures are not introduced through the muscle fibres, but only through the aponeurosis (*Fig. 439*).

Fig. 440 shows the method of making a 'kissing' suture (MacCormick) for the skin. No. 0 catgut is used. That prepared by the paraffin method is quite unirritating, and comes out in seven

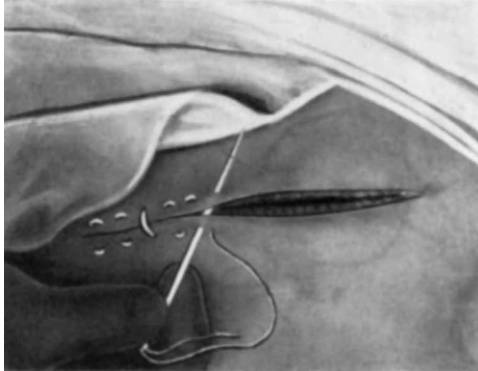


Fig. 440.—Method of making the 'kissing' suture in the skin with No. 0 catgut.

or eight days, thus sparing the patient the dread of having sutures removed, and the surgeon the trouble of removing them. Catgut prepared by the chemical method will not act in the same way.

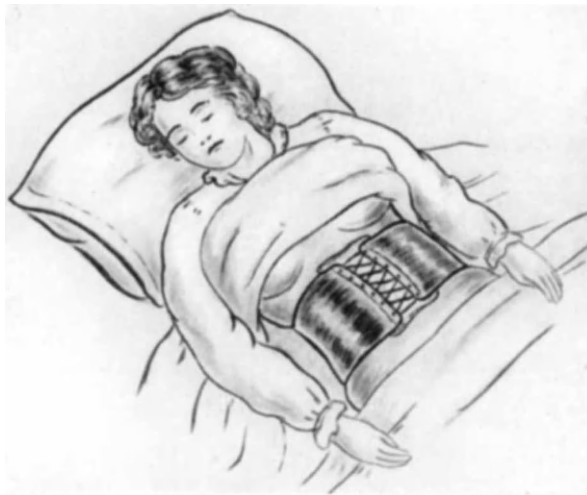

Fig. 441.—Method of taking the strain off wounds. Binder made out of split motor tube, in the form of a corset.

An abdominal rubber corset will help to reduce the strain on the abdominal wall (*Fig. 441*), and allow the patient to cough with reasonable comfort.

*CHAPTER LII***EXTENSIVE PARTIAL GASTRIC EXCLUSION (WITH RESECTION)****THE PRINCIPLES UPON WHICH IT IS BASED**

IN partial gastric exclusion, provided the pylorus is patent or partially patent, two-thirds of the distal part of the stomach is excluded and left in continuity with the duodenum, and the cut end of the proximal part of the stomach is anastomosed by the Billroth II or the Polya method to the jejunum, either in front or behind the transverse colon, according to which of these methods is more suitable to the circumstances of the particular case.

As the excluded segment is functionless, its muscle-layers retract. Some of its glandular elements atrophy from disuse, and it remains empty and gives rise to no symptoms.

The more of the stomach that is excluded, the greater the reduction of the gastric acidity, the quicker the gastric emptying time, the better the therapeutic effect in the cure of bad duodenal ulcer, and the less the possibility of the occurrence of jejunal ulcer.

The therapeutic effect of a partial gastric exclusion in the case of a duodenal ulcer is the same as it would be in a partial gastrectomy in which the same amount of stomach has been excised.

From my own experience of this operation there is abundant evidence to show that the retention of the pyloric and prepyloric part of the stomach in a partial exclusion has not a disadvantageous effect in producing a second phase of gastric excretion which would give rise to an increased gastric acidity. The percentage of gastric acidity in a gastric exclusion is no higher than in a partial gastric resection of the same amount of stomach. The retention of the pyloric and prepyloric part of the stomach has rather an advantage, for the hæmatinic substance, discovered by Castle, which is supposed to reside in this part of the stomach, is not lost. Where, therefore, a material reduction in gastric acidity is necessary, as in the case of a very chronic duodenal ulcer associated with a very high gastric acidity, and where, in order to obtain this reduction, an extensive amount of stomach must be resected, it is not uncommon, probably as a result of the loss of this hæmatinic substance, for the operation

to be followed by a secondary anæmia. But in partial gastric exclusion combined with perhaps a limited gastric resection the hæmatinic substance is not lost and no anæmia should follow. Indeed, so far as my experience goes, none has ever followed extensive partial gastric exclusion.

There is still another advantage of partial gastric exclusion over partial gastrectomy. If anything goes wrong with a partial gastric exclusion, such as the formation of a jejunal ulcer, the occurrence of mechanical errors of emptying, the development of that form of chronic gastritis described by Konjetzny which is frequently found following partial gastrectomy, then these conditions can be very simply remedied by disconnecting the gastro-entero-anastomosis and joining up the proximal and distal parts of the stomach. In the case of partial gastrectomy, however, it is extremely difficult to remedy such conditions. Nothing can be done for the anæmia; the jejunal ulcer can only be cured by further gastro-enteric resection, which in the circumstances is very difficult; and the chronic gastritis is practically irremediable.

However, one objection against the curative principle of the operation of partial gastric exclusion may be advanced. The very old, well established, highly fibrosed penetrating duodenal or jejunal ulcer may not heal, even when it is lying in an excluded section of the alimentary canal and therefore removed from its causal conditions—that is, removed from the effects of acidity, of movement, of secondary infection, and of the irritating action of gastric contents. To a certain extent this may be true. The ulcer may not heal for months, but it will be free from pain; it may, however, bleed. I have watched ulcers take a long time to heal as judged from clinical observation, but once they have healed they have remained healed.

But the two great dangers in partial gastric exclusion are the same as in partial gastrectomy. They are: (1) the development of that queer form of chronic gastritis which sometimes follows partial gastrectomy, and (2) the occurrence of a jejunal ulcer, the incidence of which, however, is not high.

THE INDICATIONS FOR PARTIAL GASTRIC EXCLUSION

Partial gastric exclusion is an operation which may be employed for disease in the distal part of the stomach or duodenum. It can be used: (1) In cases where gastro-enterostomy is indicated, but on account of the chronicity of the lesion it is unlikely to lead to cure; (2) In place of partial gastrectomy, where the prepyloric ulcer is

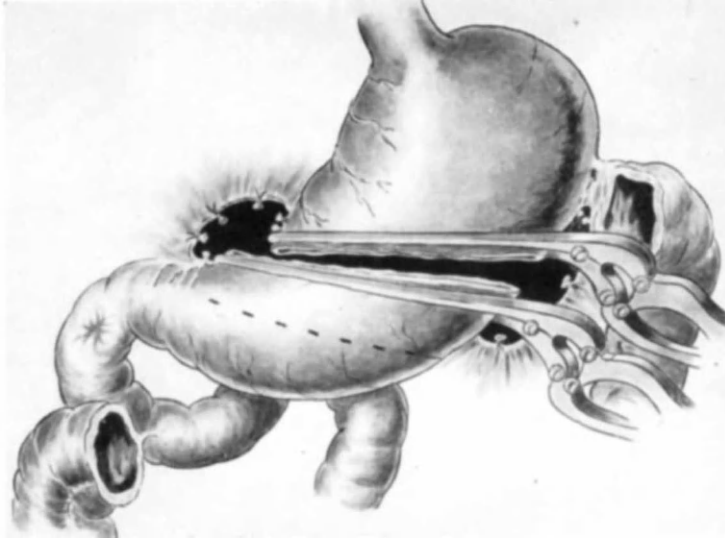


Fig. 442.—Division of stomach in partial gastric exclusion for duodenal ulcer.

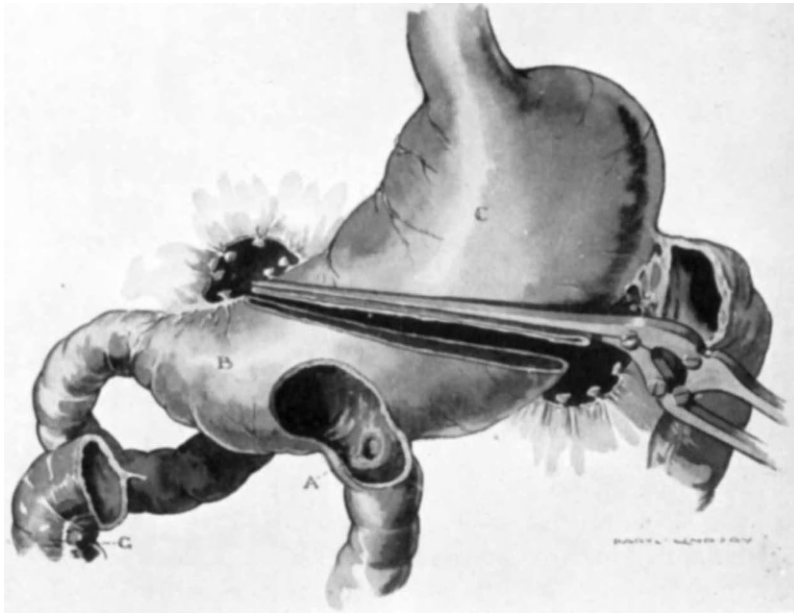


Fig. 443.—First stage of oblique partial gastric exclusion for jejunal ulcer. Note oblique division of stomach. A, Window cut to show jejunal ulcer and gastro-enterostomy stoma; B, Excluded segment; C, Portion of stomach to which anastomosis is made; G, Transverse colon.

so chronic and so adherent to surrounding vital structures that great difficulty would be experienced in removing it; (3) In those cases of prepyloric carcinoma in which there is both ulceration and partial obstruction, and in which the lesion is irremovable, but in which it is necessary not only to get the drainage effects of a gastro-enterostomy, but also to obtain a complete removal of the action of the gastric contents on a fungating and ulcerating carcinoma; (4) In constantly recurring bleeding from the duodenum or the pyloric part of the stomach in which there is no very obvious chronic ulcer—a condition that is probably the result of a gastritis and duodenitis; (5) In those cases of very chronic, bleeding jejunal ulcer which occur after gastro-enterostomy, and in which partial gastrectomy and partial enterostomy cannot be carried out owing to the patient's low state of health.

Technically, the partial gastric exclusion is very little more difficult to carry out than a gastro-enterostomy; for the closure of the cut end of the excluded segment is very easy, and the gastro-entero-anastomosis no more difficult to make. Even if there is any greater difficulty or danger, the more consistent therapeutic results of the partial gastric exclusion are an ample compensation.

It must be emphasized that partial gastric exclusion is an operation which is not designed for routine use, but for special application in certain cases. In selected cases, however, no other operation can attain its possibilities both as regards lessened risk and permanent cure.

THE TECHNIQUE OF THE OPERATION

The technique of partial gastric exclusion is somewhat similar to that of partial gastrectomy, except that the major part of the distal segment of the stomach is not removed.

Division of the Stomach.—Where a partial gastric exclusion is being carried out for chronic jejunal ulcer, chronic bleeding duodenal ulcer, or very chronic duodenal ulcer of the posterior wall, the stomach is divided obliquely at the junction of its distal two-thirds with the proximal one-third. (*Figs. 442-445.*)

This oblique division is designed to exclude as many as possible of the acid-forming glands of the fundus of the stomach, and also to allow of a transverse gastro-entero-anastomosis being made. The oblique division also permits of the closure of the distal part of the stomach in such a way that, when finished, it is merely an elongated intestine-like appendage of the duodenum, and of such a shape that it is unlikely to become a retention sac.

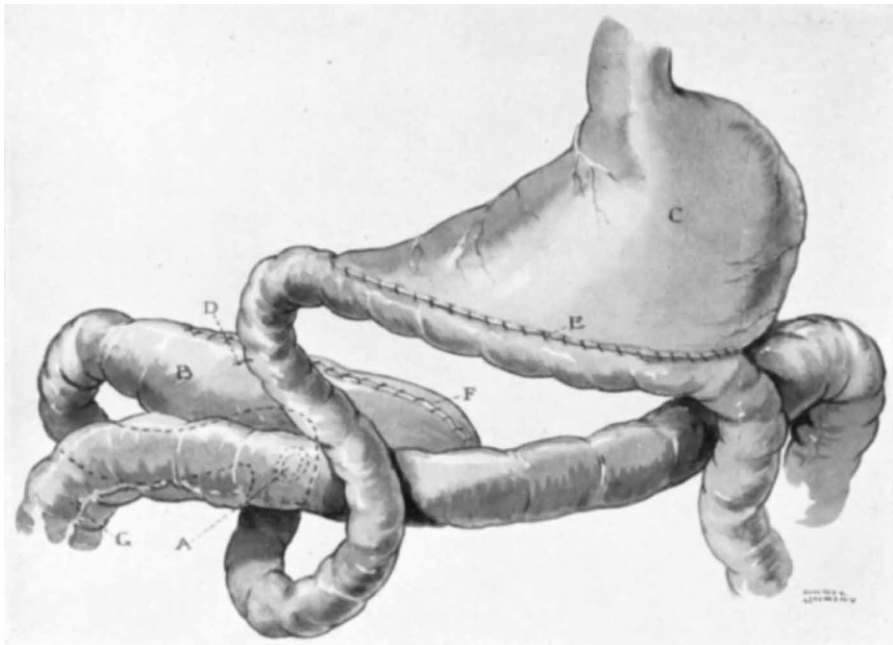


Fig. 444.—Second stage of oblique partial gastric exclusion for jejunal ulcer, made with an antecolic loop. A, Gastro-enterostomy stoma and jejunal ulcer; B, Excluded segment; E, Antecolic oblique anastomosis—the obliquity avoids ‘shoulders’ and ensures regurgitation where the afferent loop enters the stomach, while the almost transverse position of the intestinal loop removes any tendency to angulation, and facilitates emptying into the efferent loop; C, Portion of stomach to which anastomosis is made; D, Jejunum anchored to excluded segment to prevent angulation; F, Suture line of excluded segment; G, Transverse colon.

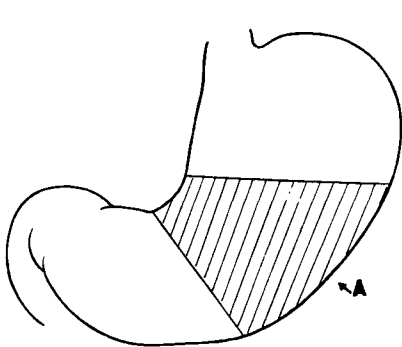


Fig. 445.—Diagram to show (A) the amount of stomach removed when a resection of part of the acid-bearing area is combined with exclusion.

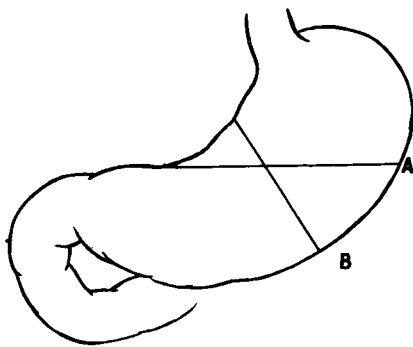


Fig. 446.—A, Line of division of stomach for duodenal or jejunal ulcer; B, Line of division for carcinoma.

Where the partial gastric exclusion is for an inoperable prepyloric carcinoma, the stomach is divided transversely, as in *Figs.* 446, B, and 452, so as to exclude the growth completely.

Closure of the Excluded Part.—The closure of the divided end of the excluded section is very easily accomplished, and is carried out in the following way:—

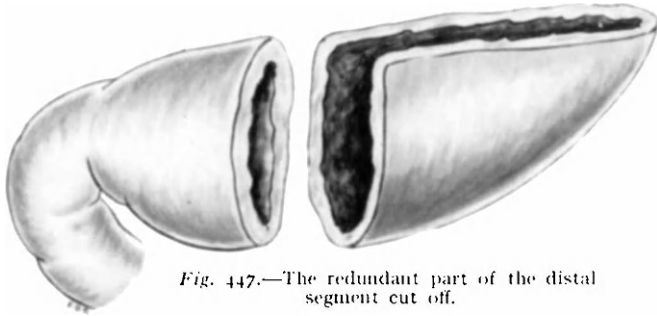


Fig. 447.—The redundant part of the distal segment cut off.

Any redundancy of the excluded part—especially necessary in a large stomach—is removed (*Fig. 447*). This permits an easier closure of the distal part and lessens the extent of the dead end.

The mucous membrane is closed with a running stitch of catgut, the end of each suture being passed down through the seromuscular layer, so as to depress the ends of the mucous membrane suture, and thus facilitate the carrying out of the second layer of sutures (*Fig. 448*).

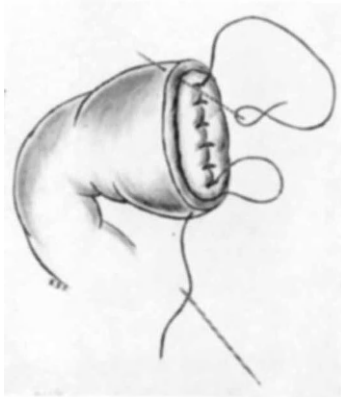


Fig. 448.—Closure of the mucous membrane.

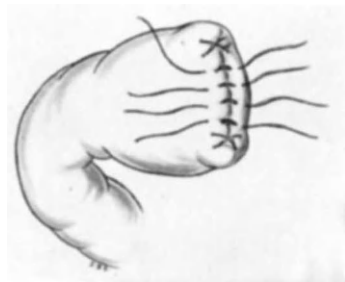


Fig. 449.—Two X sutures close the ends of the segment.

Two X sutures, one at each end, with a few interrupted sutures in between them, now make a third layer, which can be put in very quickly, and which gives additional security (*Fig. 449*).

The Gastro-entero-anastomosis.—This can be carried out in one of three ways: (1) As a Billroth II method, which is advisable in the case of women with poor power in their gastric muscle; (2) By the retrocolic short-loop method of the author; (3) By the antecolic method of Balfour combined with an entero-anastomosis—a convenient and suitable method in the case of inoperable carcinoma.

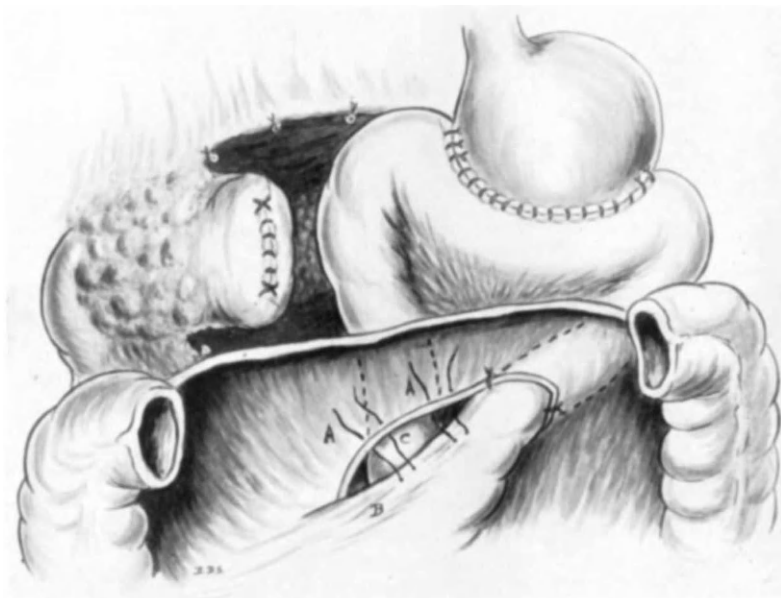


Fig. 450.—Gastric exclusion with a short retrocolic loop. A, Transverse mesocolon; B, Jejunum with mesentery; C, Denuded duodenojejunal flexure (jejunal mesentery cut away to show duodenal flexure).

1. *The Billroth II Method.*—The gastrojejunal anastomosis made by the Billroth II method is described on p. 494, and illustrated in *Figs. 375 and 451.*

2. *The Retrocolic Short-loop Method of the Author.*—Where partial gastric exclusion is being performed for the cure of a very chronic duodenal ulcer associated with a high gastric acidity, two-thirds of the stomach must be excluded. The gastric stump will then be too short to reach below the transverse mesocolon, and a Polya retrocolic gastrojejunal anastomosis with a short jejunal loop cannot be made. In this case, an antecolic anastomosis could be made, but a long jejunal loop would have to be used, and this, as has already been explained on p. 494, would predispose to the formation

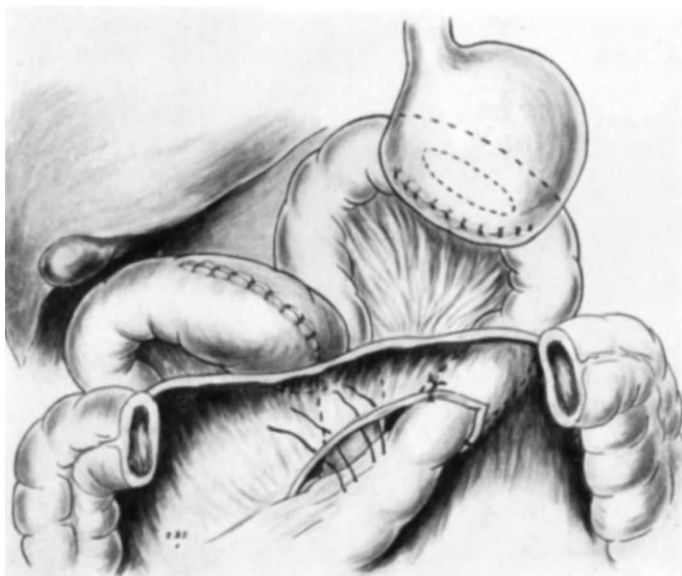


Fig. 451.—Exclusion with resection, a short loop being used, but the anastomosis made after the manner of the Billroth II operation.

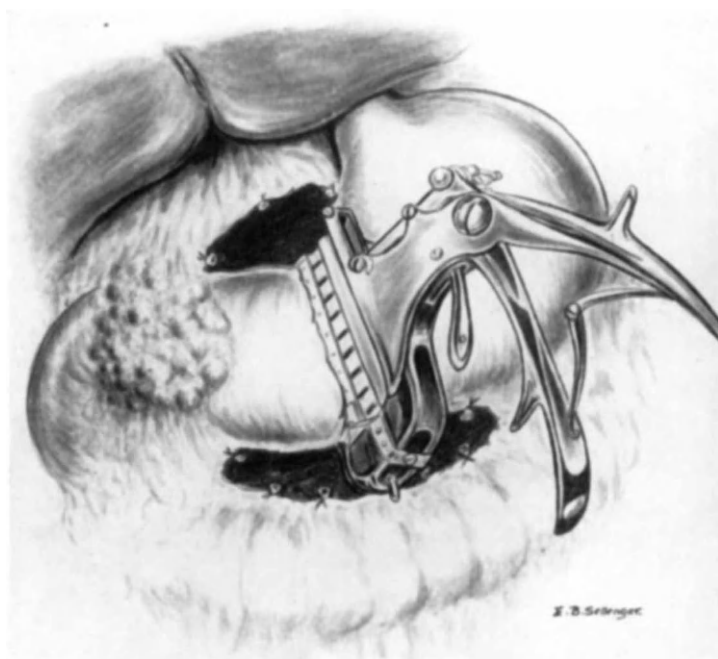


Fig. 452.—Gastric exclusion for carcinoma. Stomach divided as far as possible from the growth.

of jejunal ulcer. In such circumstances a retrocolic anastomosis with this short gastric stump can be made with a short jejunal loop by the method described on p. 497; that is, by displacing the duodeno-jejunal flexure into the lesser peritoneal sac.

In this short-loop method, the duodenojejunal flexure is isolated from the peritoneum of the transverse mesocolon. An adequate

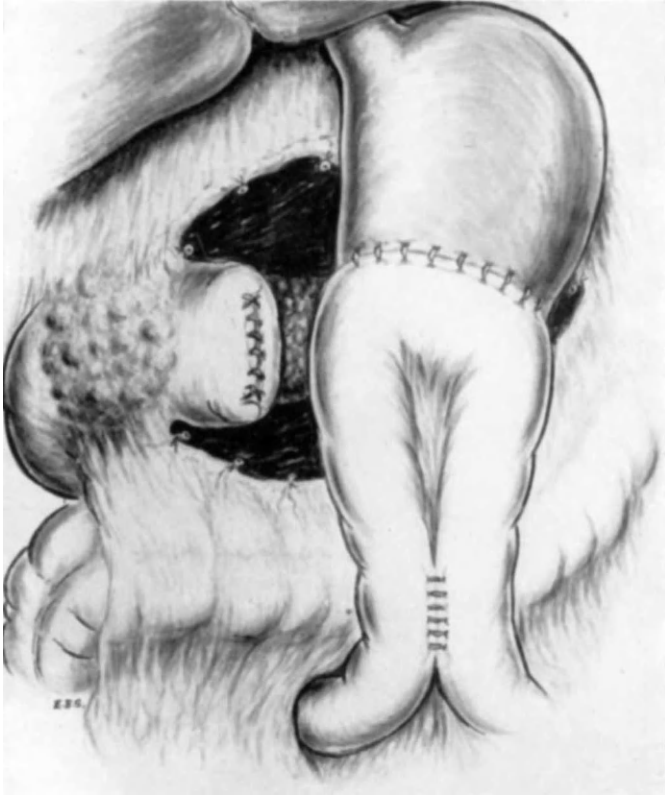

Fig. 453.—Gastric exclusion. Gastro-entero-anastomosis made after the antecolic method of Balfour, with the addition of an entero-anastomosis.

loop of jejunum with its mesentery is brought up through the opening thus made, and fixed to the edges of the opening in the transverse mesocolon by sutures to the mesentery and to the jejunum itself. The flexure now lies in the lesser peritoneal cavity, and only the efferent loop in the transverse mesocolon. *Fig. 450* shows this method of fixing the efferent loop in the transverse mesocolon, and the gastro-entero-anastomosis which is then made.

In many cases, however, the stump of the stomach will be long enough for the usual retrocolic gastro-entero-anastomosis to be made.

3. *The Antecolic Method of Balfour with Entero-anastomosis.*—Where the partial gastric exclusion is being carried out for an inoperable cancer of the prepyloric part of the stomach, some modification of the operation is required. The stomach is divided transversely, and as far as possible from the growth (*Fig. 452*). As in this case there is no danger of jejunal ulcer forming, because there is no hyperacidity, it is more convenient to make a long loop after the antecolic method of Balfour, for it is easier to anastomose this long loop to the small gastric stump. In such a case an entero-anastomosis, which only takes a few minutes to make, should never be omitted. (*Figs. 452, 453.*)

EXAMPLES OF THE USE OF PARTIAL GASTRIC EXCLUSION

Prepyloric Ulcer Tumour.—It is not uncommon to meet with a large inflammatory tumour in the prepyloric region of the stomach. This generally arises from a penetrating ulcer and has extensive adhesions to vital structures in the vicinity. It is very difficult and in some cases impossible to remove such a tumour, especially when it is associated with a chronic perforation, as it sometimes is. In addition, patients with these ulcer tumours are very sick, cachectic, and emaciated, either because such an ulcer causes great debility or is prone to occur in very feeble persons, so that there is not much latitude for the necessarily extensive operative manipulations.

The following is a history of such an operative gastric problem :—

A man, aged 50, had been sick for many years with pain two hours after meals. Latterly he developed intense epigastric pain, and had finally lost weight rapidly, and become very cachectic. He appeared ill, had a pulse rate of 130, and a tender and rigid epigastrium. Operation disclosed a very large inflammatory and apparently irremovable prepyloric tumour which had formed around a penetrating ulcer with a small chronic, well localized perforation. Partial gastrectomy was indicated, but the patient's condition would not permit of this, even if removal had been possible, so a partial gastric exclusion was done in forty minutes. The patient recovered, and has remained well for many years.

The criticism of the use of this operation in this case would be that carcinoma develops on such ulcers. Observation, however, goes to show that carcinoma arises only infrequently on the basis of old chronic ulcer—in 5 to 7 per cent of cases. The danger of cancerous degeneration of the ulcer may not then be advanced as a strong argument against gastric exclusion in these very sick patients who

suffer from a prepyloric ulcer tumour. Anyhow, the operation may be regarded as a first-stage preparation for a later, easier, and safer removal of the diseased area.

Chronic Duodenal Ulcer.—Partial gastric exclusion with or without resection is indicated in duodenal ulcer of many years' standing, in duodenal ulcer which is situated on the posterior wall or penetrates the pancreas, or in a very chronic duodenal ulcer in a young person, associated with a high acidity. Gastro-enterostomy will not cure these types of ulcer, and in such conditions it is most likely to give rise to a very vicious form of jejunal ulcer. Partial gastric exclusion is particularly indicated in the penetrating types of duodenal ulcer, the removal of which by a partial duodenectomy and gastrectomy is a dangerous procedure.

The application of partial gastric exclusion is illustrated in the following case :—

A patient had had the symptoms of duodenal ulcer for ten years. Every method of medical treatment had been tried. His gastric acidity was between 60 and 70. Operation disclosed that he had a very chronic ulcer of the posterior wall of the duodenum penetrating the pancreas.

A partial gastric exclusion was carried out, two-thirds of the stomach being excluded, and part of the redundancy of the distal segment of the stomach amputated. This patient has now been quite well for eight years.

This case is an example of many others of similar nature in which partial gastric exclusion has been successful.

Jejunal Ulcer.—Partial gastric exclusion without resection is also specially indicated in very weak patients suffering from jejunal ulcer complicated by severe bleeding. In such circumstances it is not possible to carry out an enterectomy and partial gastrectomy—the ideal method of treatment—especially where the performance of this operation is made most difficult by the presence of innumerable adhesions resulting from previous operations.

The following case-histories of jejunal ulcer are examples of the use of partial gastric exclusion in such circumstances :—

The first case was that of a man, aged 50, who had been operated on four times for jejunal ulcer. The ulcer had been repeatedly resected and the stoma enlarged. He was very weak, debilitated, and exsanguinated.

Operation disclosed a large jejunal ulcer adjacent to stomach, colon, transverse mesocolon, small intestine and its mesentery, all forming a tumour in which, because of the many operations and extensive inflammation, all lines of cleavage between these structures were lost. A partial gastrectomy and enterectomy in the circumstances would have been most difficult, and in the patient's condition very dangerous.

In this case a partial gastric exclusion was performed through an incision in the abdominal wall to the left of the previous incisions, and at a

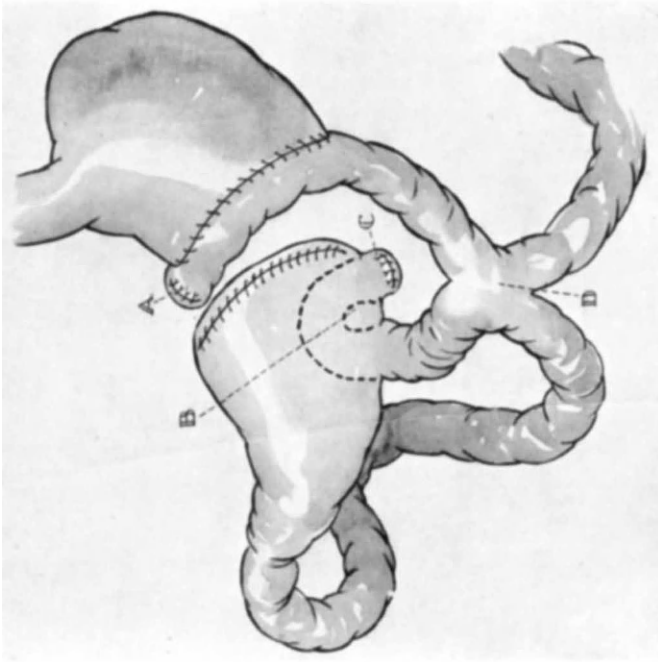


Fig. 455.—A, Effluent loop from gastro-entrostomy stoma divided, the end closed, and the loop brought up behind the colon to be anastomosed with the stomach; B, Gastro-entrostomy stoma (with jejunal ulcer) draining excluded segment; C, Effluent loop from gastro-entrostomy stoma divided and closed; D, Entero-anastomosis.

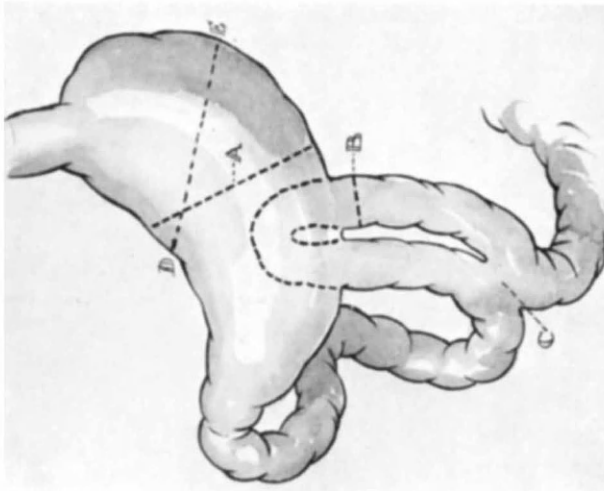


Fig. 454.—Diagrammatic sketch showing partial gastric exclusion for jejunal ulcer, with entero-anastomosis. B, Gastro-entrostomy stoma with jejunal ulcer—dotted line shows where jejunum was divided; C, Entero-anastomosis; A, Section of stomach previously practised; DE, Section now favoured.

level in the stomach which was well to the left of his previous gastro-enterostomies—a level which enabled all adhesions to be avoided and a gastro-entero-anastomosis to be made on a clean stomach.

Years later this man was in good health and had gained two stone in weight.

The second case was that of a man, aged 55. This patient had a history of duodenal ulcer for twenty years and was one of the worst cases I have ever seen. During the previous six years he had three operations upon the stomach without relief, one of which was a posterior gastro-enterostomy. Severe pain, vomiting, and frequent copious hæmorrhages had reduced him to a state of misery and weakness. He lived in daily terror of hæmorrhage, through which he had been almost exsanguinated on three occasions. He was extremely pale, and the upper part of his abdomen showed five laparotomy scars. Radiographic examination disclosed jejunal ulcer.

Operation revealed his stomach and bowel tangled in a confused mass by adhesions. Separation of these disclosed an old gastro-enterostomy and entero-anastomosis with jejunal ulcer at the site of the former. The patient was so ill, and the state of his upper abdomen so terrible, that it was considered wise not to explore the duodenum. The jejunum was divided just distal to the jejunal ulcer and both sides were closed. Somewhat more than half the stomach was excluded, and the remainder anastomosed into the distal piece of jejunum. *Figs. 454 and 455* show the modification of partial gastric exclusion which was employed in order to take advantage of the enterostomy in this case, thus side-tracking the ulcer and leaving it in a blind end, the old entero-anastomosis remaining for the passage of the duodenal juices.

It is conceivable that the retention of the entero-anastomosis, decreasing as it does intestinal regurgitation, might predispose to a recurrence of the ulcer, but under the circumstances it was difficult to do otherwise. Although apparently cured, the subsequent history of this patient was not quite satisfactory—probably because of the entero-anastomoses.

Bleeding Stomach or Duodenum.—There are patients who suffer from a syndrome somewhat like that of gastric or duodenal ulcer, and in whom repeated bleedings occur. If a gastro-enterostomy is done, the bleedings continue. In these patients a very definite ulcer can sometimes be demonstrated, but at other times none can be seen. Occasionally, when the bleeding has occurred after a gastro-enterostomy, I have not been able to demonstrate any jejunal ulcer, but only a patchy jejunitis. As a rule, these bleedings are not associated with much pain after meals. They are caused by a definite gastritis, duodenitis, and by a jejunitis in the case of gastro-enterostomy.

For such a condition, the best treatment is a partial gastric exclusion, for it excludes and puts out of action the duodenum and that part of the stomach which bears ulcers or is the subject of

gastritis. The following is an example of a case in which bleeding occurred after a gastro-enterostomy, and in which a partial gastric exclusion was successful:—

A man, aged 50, had symptoms of duodenal ulcer. He was operated on and a duodenal ulcer found. A posterior gastro-enterostomy was done. For the last four years since his operation he suffered from severe attacks of hæmatemesis and melæna, in one of which he nearly died. He had never had any pain after meals, or any other symptoms suggestive of chronic jejunal ulcer, except perhaps an acidity, which generally preceded an attack.

An extensive partial gastric exclusion was then done, and the patient has had no further bleedings.

Most of the cases clearly show that partial gastric exclusion gives a much quicker emptying time and a very much greater reduction of acidity than does gastro-enterostomy; therefore the therapeutic effects of the former should be much greater than those of the latter.

RESULTS OF PARTIAL GASTRIC EXCLUSION

While it is not possible yet to furnish reliable remote results in all the cases operated upon, some general conclusions may be drawn. The results are much the same as those after a partial gastrectomy of the same extent as the exclusion. Like partial gastrectomy for duodenal ulcer, if gastric exclusion is too limited there is danger of the occurrence of jejunal ulcer because there is an insufficient reduction of acid. Where two-thirds of the stomach has been excluded (with resection) by the oblique division, a uniform and satisfactory result both immediate and remote has been obtained. In fact, it will give the very same results as partial gastrectomy and duodenectomy for duodenal ulcer, with less than half the operative risk. As far as experience goes, partial gastric exclusion has been found to be practically free from any of the unpleasant after-effects that often attend gastro-enterostomy.*

* NOTE.—Recent observations not yet completed indicate that the incidence of jejunal ulcer in partial exclusion with resection and partial gastrectomy is higher than is indicated in the literature.

CHAPTER LIII

OPERATIONS FOR JEJUNAL ULCER

OPERATIONS for jejunal ulcer, a feature of modern gastric surgery, frequently present great difficulties and are attended with much danger to the patient. Special pre-operative preparation of the patient is necessary, and particular attention must be directed to the technique of the operation, which may be (1) a partial gastrectomy and enterectomy, (2) an undoing of the gastrojejunal anastomosis, or (3) a partial gastric exclusion.

Operability of the Patient.—If the jejunal ulcer is old and extensive and has penetrated the jejunum and invaded the posterior wall of the abdomen, it is prone to involve the colon, and to be surrounded with extensive adhesions. Resection of such an ulcer may be exceedingly difficult: great skill may be required even to approach it, and still greater to remove it. Furthermore, it is in circumstances such as these that the patient may be a very bad operative risk, for he may be suffering from continual hæmorrhages and serious nutritional disturbances, and will be extremely debilitated.

In such a case, the first problem for the surgeon is to decide whether the patient is strong enough to stand a partial gastrectomy and enterectomy; or whether he should have an operation of lesser severity—a partial gastric exclusion; or perhaps have the gastroenterostomy undone.

Pre-operative Preparation of the Patient.—If it is decided that the patient can stand a partial gastrectomy and enterectomy, then he must receive careful pre-operative preparation. Particular reasons for such pre-operative treatment are that this operation, as a rule, is long, difficult, and dangerous; that it taxes to the utmost the strength of even a fairly strong patient; and that its mortality-rate in good risks is from 6 to 10 per cent, or even higher.

The question of the need for a blood transfusion will arise, the answer to which will, of course, depend on whether the patient has suffered from any bleedings from the ulcer. If he has not lost much blood, intravenous infusions of glucose and isotonic saline may suffice to improve his general condition and render him fit to go safely through the operation.

The preparation for partial gastrectomy and enterectomy should be much the same as that for a partial gastrectomy for carcinoma of the stomach.

Anæsthesia.—For the average type of patient, the best all-round method is light ether anæsthesia; that is, vaporized warm ether, given as described in Chapter XLVII. In the case of patients who are bad risks, gas and oxygen, supplemented where necessary with a small amount of ether, should be used. Such patients, on account of their debilitated condition, take this type of anæsthetic very well, their weak musculature reducing the operative disability due to rigid abdominal muscles.

Light ether anæsthesia, however, if skilfully given, is the best in most cases, for it simplifies the operation by giving the surgeon a free approach to that very difficult operation region, the posterior wall of the abdomen, into which the jejunal ulcer so often firmly and widely infiltrates. It is a fact that where gas anæsthesia is used by the unskilful surgeon, or without the aid of the operating frame and its visceral retraction, what is gained by using the less toxic anæsthetic is often lost by the shock produced in the extra handling of the intestines which is required in such a difficult operation.

THE OPERATIVE TECHNIQUE

The Incision.—The incision should be made over the scar of the original wound. But, in order that there may be some part of it which goes through normal abdominal wall, it should be extended either a little higher or a little lower than the original incision, so that the abdominal cavity can be entered through a part as yet unoperated upon, and the risk of encountering intestinal or omental adhesions greatly lessened (*Fig. 456*).

Entering the Abdominal Cavity.—The entry into the abdominal cavity may present great difficulty. The whole wound is deepened to the peritoneum, and this membrane is opened

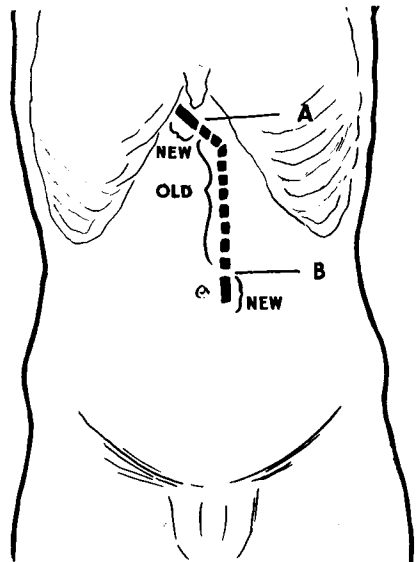


Fig. 456.—The incision, which may be extended through normal abdominal wall at A or B.

at first under the new part of the incision (*Fig. 456, A or B*), and then throughout its whole length with a guiding finger in the abdominal cavity.

A wound retractor is placed in each end of the wound, and both are firmly locked to the operating frame. The assistant then, by lifting the frame, can elevate the abdominal wall, so that the visceral adhesions to the scar are stretched, making it possible for them to be dissected accurately along their natural line of cleavage (*Fig. 457*).

The additions to the original incision may make the present incision too big to employ the operating frame, for, as it is the muscles

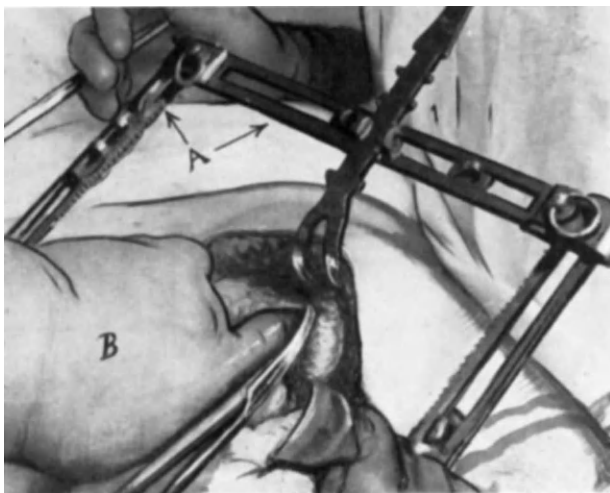


Fig. 457.—Showing use of operating frame to make adhesions taut and thus put them on the stretch. A, Operating frame held up by hands of assistant; B, Surgeon's hand pressing adhesions downward so that they may be divided along the line of cleavage.

of the abdominal wall which serve as a spring to hold the operating frame in place, it can only be used with an incision about 4 in. long. Therefore, as the use of the operating frame is essential to enable the extensive adhesions to be efficiently and speedily dealt with and the operation area to be properly segregated, the incision should be made smaller by the aid of a few sutures. This, of course, is only done after the abdominal cavity has been safely entered and the anterior parietal peritoneum on each side of the wound cleared from adhesions.

The operating frame is then inserted in the manner already described (*see Chapter XXXIV*).

Scissors-and-scarf Dissection of Adhesions.—In operations for jejunal ulcer, one of the most difficult parts of the operation is the

management of the enormous number of adhesions (often the result of many operations) which are sometimes found in these cases. The secret of success in these difficult secondary operations is the art of dealing with these adhesions.

In such operations where all the natural planes have disappeared, the author finds that a method of scissors-and-scarf dissection (*see* p. 352) enables him to dissect rapidly and accurately intestinal adhesions which are complicated and difficult to separate. These scarves are used to cover both gloved hands of the assistant, and the left gloved hand of the surgeon (*Fig. 458*). They enable a firm grip

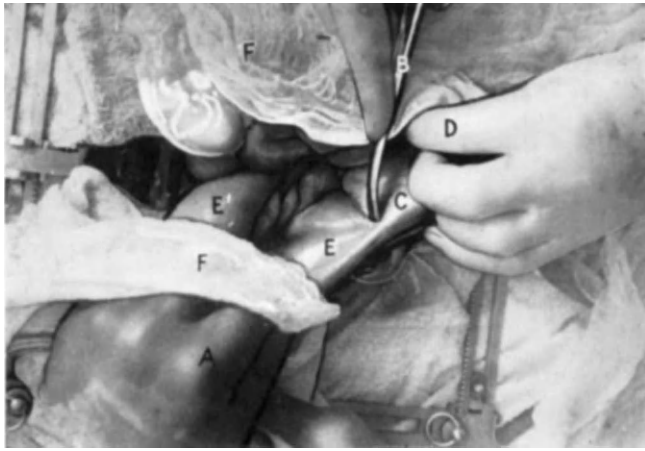


Fig. 458.—Photograph showing method of separating adherent small intestine or adhesions between stomach and intestine. Note how the spade edge of the special dissecting scissors **B** follows exactly the bloodless line of cleavage between the adherent intestinal loops. **A**, Assistant's gloved finger covered with scarf **F** making tension on efferent loop; **B**, Spade-pointed scissors; **C**, Loop of intestine adherent to efferent loop **E**; **D**, Surgeon's hand making tension on loop of small intestine **C**; **E'**, Afferent loop.

of the intestines to be taken with the least injury to peritoneal endothelial cells. And they permit the assistant to make firm distracting tension on an adherent loop of gut, and in this way to demonstrate a line of cleavage which is the plane where the original adhesion took place, and in which there are practically no vessels.

When the adhesions have been cleared from the peritoneum of the anterior abdominal wall, the gastric, colonic, and intestinal adhesions divided, and the anastomosis and the jejunal ulcer demonstrated, the completion of the operation, as already stated, will take one of the following forms: (1) Partial gastrectomy and

enterectomy; (2) Disconnexion of the gastrojejunal anastomosis and restoration of the stomach and jejunum to normal; or (3) Partial exclusion.

1. Partial Gastrectomy and Enterectomy.—In this operation the object should be to remove in one block the jejunal segment with the stoma and the jejunal ulcer, together with that part of the stomach which it is proposed to resect.

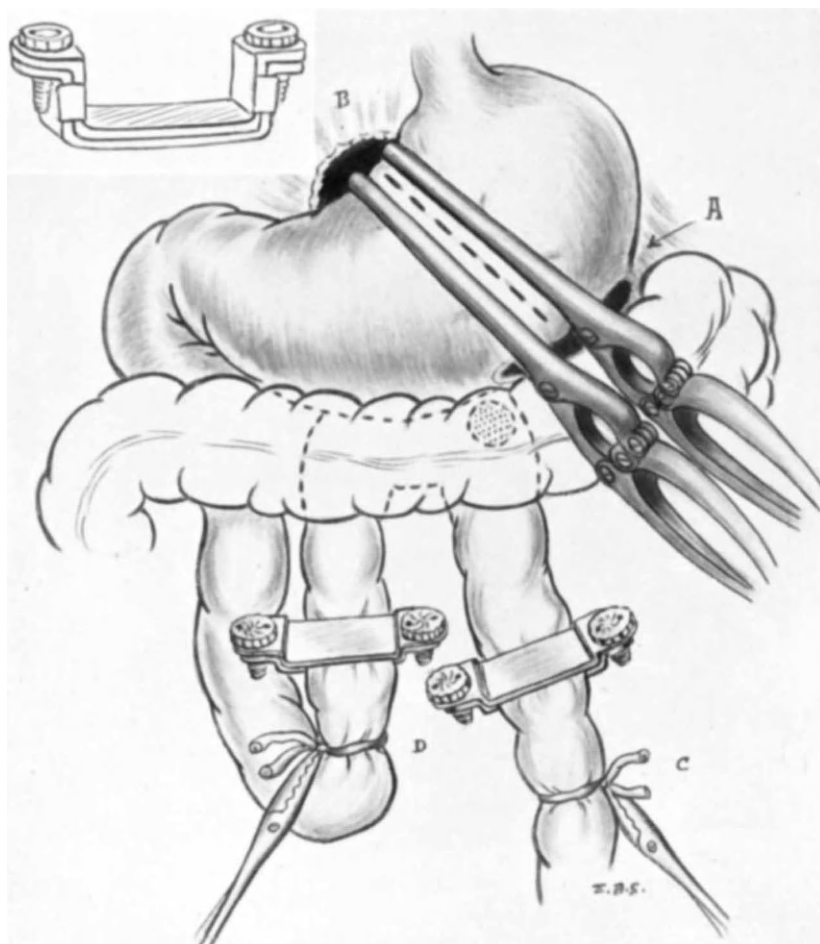


Fig. 459.—Stomach clamped with two Payr's clamps on either side of the proposed line of division, and box clamps placed on afferent and efferent loops of small intestine. To prevent leaking, the distal and proximal parts of the jejunal loops are occluded by encircling them with light rubber tubes clamped with hemostats. (*Inset*: Box clamp shown diagrammatically.)

The main steps of the operation are as follows :—

The vessels of the lesser and greater curves which are opposite the proposed line of division of the stomach are isolated from the stomach as in a partial gastrectomy. The stomach is divided with the diathermy knife between Payr's clamps. Box clamps are placed on the afferent and efferent loops of the small intestine above and below the proposed lines of division of the jejunum (*Fig. 459*).

Light rubber tubes are clamped round both ends of the jejunum with hæmostats in order to prevent leakage of jejunal contents. The jejunum is divided through normal tissue well away from the jejunal ulcer, at points proximal and distal to the stoma. The detached segments of stomach and intestine are isolated from their blood-supply. The gastrojejunal segment now remains attached in three ways. It is held by soft adhesions to the mesentery of the small intestine, the posterior abdominal wall, the opening in the transverse mesocolon from which it has probably been impossible to separate it in the early part of the operation, and perhaps to the colon. It is also fixed by firm inflammatory infiltration of the jejunal ulcer. And it is attached to the duodenum.

The dissection of the much infiltrated area of the jejunal ulcer is the most difficult part of the whole operation. Indeed, the object of first dividing the stomach and jejunum is to allow free access to this deeply situated region—to the posterior surface of the stoma and to the jejunal ulcer.

The secret of this dissection is to find the line of cleavage which is situated round the actual edge of the jejunal ulcer. Once this is found and faithfully followed, the ulcer (usually perforating), with the intestinal segment can easily be 'shelled off' the posterior abdominal wall. The isolated segment, aseptically closed by the box clamps and bearing the jejunal ulcer, is drawn up through the rent in the transverse mesocolon, and the stomach, with the intestinal segment attached to it, allowed to hang over the patient's side, so as to expose the posterior surface of the prepylorus and duodenum (*Fig. 460*).

The right gastric artery and the gastro-epiploic vessels lying respectively above and below the pylorus are thus exposed to view. The distal division of the gastrojejunal segment is made through the duodenum, and the duodenum closed in the manner already described. The gastrojejunal segment containing the jejunal ulcer and the stoma is thus removed in one piece.

The jejunum is anastomosed to the stomach in the manner already described, a short, loose, retrocolic jejunal loop being employed (*see* p. 497).

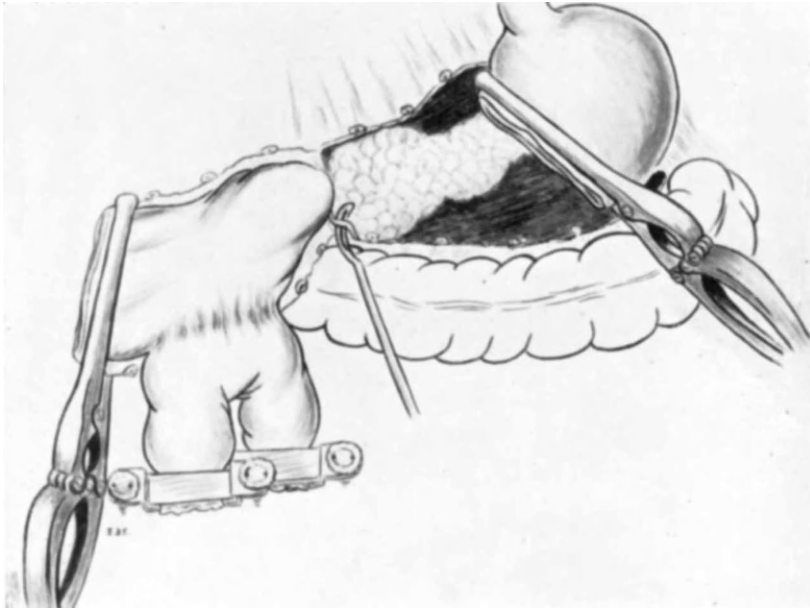


Fig. 460.—Stomach divided and lying over to the patient's right, so as to expose the gastric arteries in the region of the pylorus. To this segment of stomach is attached the anastomosis and the segment of jejunum bearing the jejunal ulcer, which has been mobilized and drawn up through the opening in the transverse mesocolon.

In circumstances where the duodenum has previously been affected by a callous duodenal ulcer, and where closure of its divided end would

be difficult and insecure, the distal division of the gastrojejunal segment should be made in the stomach about 6 cm. from the pylorus (*see Figs. 448, 449*); that is, a prepyloric closure should be carried out.

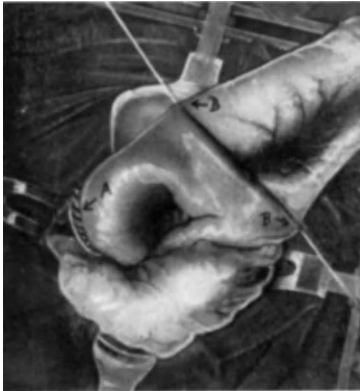


Fig. 461.—Photograph of partial gastrectomy and enterectomy which has been started by dividing the distal part of the stomach. **A**, Suture in the jejunum where it has been joined up; **B**, Jejunum 'guy-roped' to the stomach and the frame.

In some cases it may be easier to start this operation of partial gastrectomy and enterectomy by dividing the distal end of the stomach. The stomach, with the isolated and attached ulcer-bearing segment of jejunum, can be drawn up through the transverse mesocolon, held well up by an assistant, and anastomosed to the jejunum, the continuity of which

has already been established by suture. This method is shown in *Fig. 461*.

In this figure is seen the use of one other principle which it is necessary to take advantage of in some cases, namely, that the lesser curvature is so twisted that it will be situated in the middle of the new gastrojejunal anastomosis and not at its upper or lower corner.

2. Undoing the Gastrojejunal Anastomosis.—In certain cases of jejunitis, or mild forms of jejunal ulcer, it may not be necessary to

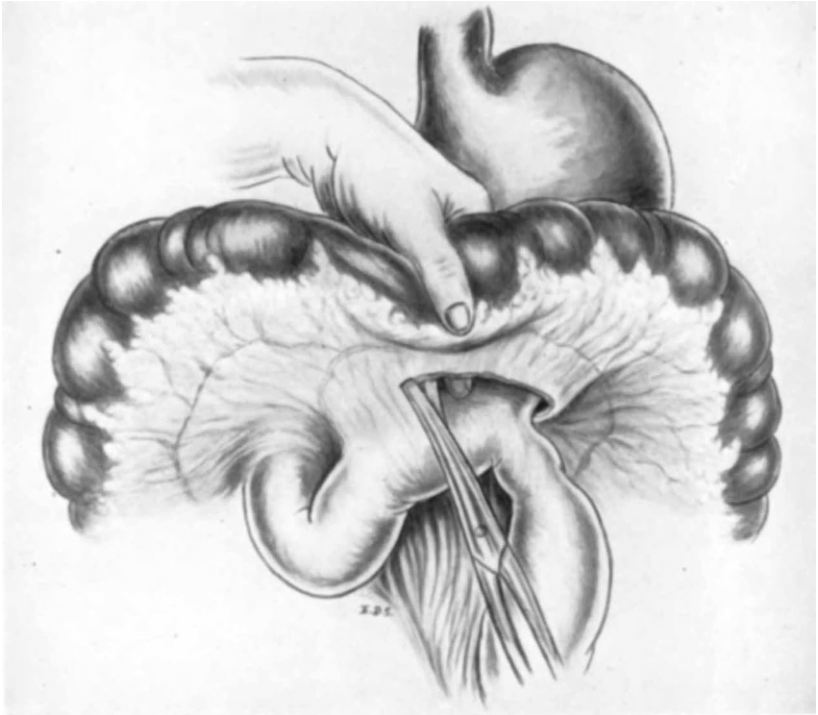


Fig. 462.—Drawing showing where the isolation of the anastomosis from the transverse mesocolon is started; that is, showing the easiest part in which to find the true plane between the anastomosis and the transverse mesocolon. The finger is seen in the lesser sac, and the dissection is made from below on to the finger, the plane of the serous membrane of the jejunum being followed. The inflammatory area of the jejunal ulcer lies more on the posterior surface, and away from this comparatively normal tissue area.

carry out the operation of partial gastrectomy and enterectomy. It may happen that the original duodenal ulcer, for which the gastroenterostomy was done, was not an ulcer of the severe acidic type, but rather one of the infective type, one perhaps which would have been cured or controlled with modern medical treatment.

In such circumstances it may be sufficient to undo the gastro-jejunal anastomosis, remove the jejunal ulcer, and reconstitute the independent continuity of the stomach and the jejunum; in other words, simply perform an operation for the undoing of the gastro-enterostomy.

The steps in this operation are as follows:—

Dissection of the Efferent Loop.—After all adhesions have been dealt with as in the operation for partial gastrectomy and enterectomy,

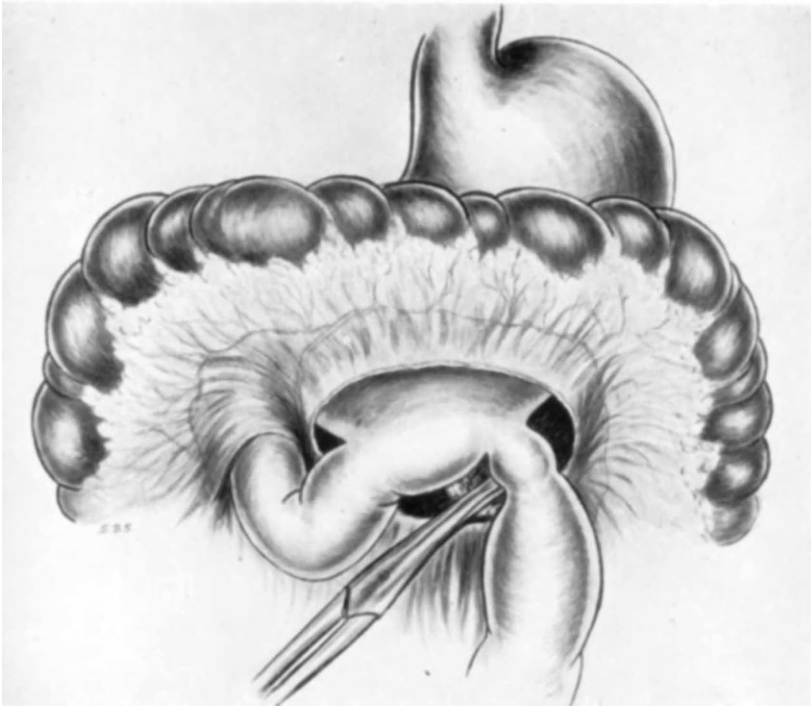


Fig. 463.—The last part of the anastomosis to be liberated—the region in the vicinity of the jejunal ulcer, which lies on the left side of and a little posterior to the anastomosis.

the efferent loop is sought for where it is not adherent. This loop is followed until it becomes adherent, and then dissected as far as the anastomosis. The efferent loop is the easiest part of the operation to begin on, for it will lead at once to the heart of the operation—to the jejunal ulcer, which is usually situated at the beginning of the efferent loop.

Isolation of the Anastomosis from the Transverse Mesocolon.—Working from below the transverse colon and on to the first finger

very emaciated. It is in such cases as these that the jejunal ulcer is found to be very chronic, and to penetrate the posterior abdominal wall deeply. The combination of a very chronic perforating ulcer and the emaciated, debilitated, and anæmic condition of the patient renders the operation of partial gastrectomy and enterectomy very dangerous, so that a less dangerous operation is indicated, namely, an extensive gastric exclusion.

In this operation the jejunal ulcer and two-thirds of the pyloric part of the stomach are excluded from the action of the gastric contents, a procedure that relieves the patient of his symptoms, improves his general condition, and in most cases heals his jejunal ulcer. Even should the ulcer not heal—a rare occurrence—it can be removed at a later operation, when the patient is in a very much better condition for operation, and when little danger will attend its removal.

This method of carrying out an extensive gastric exclusion for jejunal ulcer is described in detail and illustrated in Chapter LII.

The stomach is divided obliquely so as to exclude as much as possible of the fundal part of the stomach—the acid-bearing area. The oblique division has also the great advantage that it is made well away from the adherent area round the gastro-enterostomy stoma, and that it can therefore be easily and quickly made.

CHAPTER LIV

HERNIA

DIAPHRAGMATIC HERNIA

Varieties.—Diaphragmatic hernia may be either congenital or traumatic.

Congenital Diaphragmatic Hernia.—Diaphragmatic hernia of the congenital type is rare and is found as the result of an embryological defect in the diaphragm. The common sites are: (1) through the dome of the diaphragm; (2) through the œsophageal opening; (3) through an opening left by the absence of the left part of the diaphragm.

Traumatic Diaphragmatic Hernia.—Traumatic diaphragmatic hernia can occur as a result of knife or gunshot wounds which penetrate the diaphragm. It can also be caused by crushing violence or a fall from a height. In this kind of diaphragmatic hernia there is usually no sac.

Symptoms and Signs.—The clinical manifestations of diaphragmatic hernia can be divided into two groups: those in which the stomach only is incorporated in the hernia, which is usually of the para-œsophageal, gastric type; and those in which the stomach, large bowel, and small bowel are included in the hernia, which is generally of a traumatic type.

The symptoms of all forms of diaphragmatic hernia are usually very indefinite. They may be classified as follows: epigastric discomfort on taking a full meal; pain after meals or after a full meal, relieved by vomiting; pain in the left shoulder due to spasm of the diaphragm; dyspnœa on exertion; pain in the lower part of the left side of the chest; obstinate constipation, sometimes attacks of intestinal obstruction, caused by incarceration of the splenic flexure; and attacks of obstruction of the small intestine.

Treatment.—There are two methods of approach in diaphragmatic hernia—the transperitoneal and the transpleural.

The Transperitoneal Approach.—

A man, aged 35, was admitted to hospital complaining of crampy pains in the epigastrium. These pains were worse after a heavy meal. He also stated that he had a pain in the lower and left part of his chest. He gave

a previous history of having, eight years ago, fallen twenty-two feet on to the pavement on his left side. At that time his ribs were broken, he had some hæmoptysis, vomited a great deal, and was in hospital four or five weeks.

Fig. 471 shows the stomach, and *Fig. 472* the splenic flexure, in the hernia.

Operation.—Through a small incision in the neck, the phrenic nerve was exposed and crushed in order to paralyse the diaphragm temporarily.

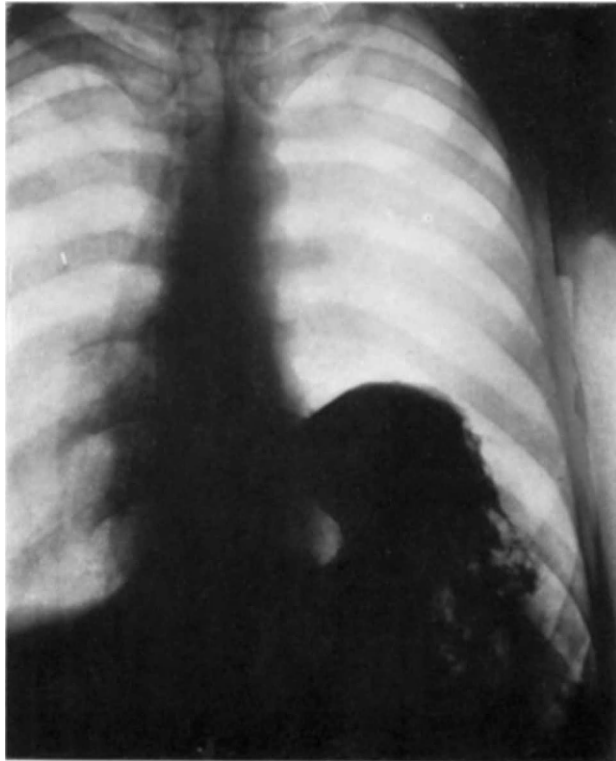


Fig. 471.—Radiograph showing stomach in diaphragmatic hernia.

The abdomen was opened through a combination of a left costal and a paramedian incision (see *Figs. 418, 419*, p. 526). When the abdomen was opened, a large opening was found in the diaphragm (*Fig. 473*). Nearly the whole of the stomach, much of the small intestine, the splenic flexure, and part of the transverse colon, with a small part of the left lobe of the liver, were incarcerated in the left pleural cavity. There was no enclosing sac. The lung was collapsed into a small compass on the lateral wall of the mediastinum. The diaphragm was exposed by means of the operating frame and 'mechanical hands'. Adhesions from the splenic flexure and the stomach were divided, and these organs, with the small intestine, which

was not adherent, were replaced in the abdominal cavity. The left lobe of the liver, which was adherent to the edge of the opening in the diaphragm and to the pleura, was next dissected away. All these organs, which tended to be sucked back into the chest, were then held into position in the abdominal cavity by means of 'mechanical hands' (*Fig. 474*). The diaphragm was thus perfectly exposed, so that the whole of the pleural cavity could be explored and manipulations for the purpose of closing the opening in the diaphragm made with ease.

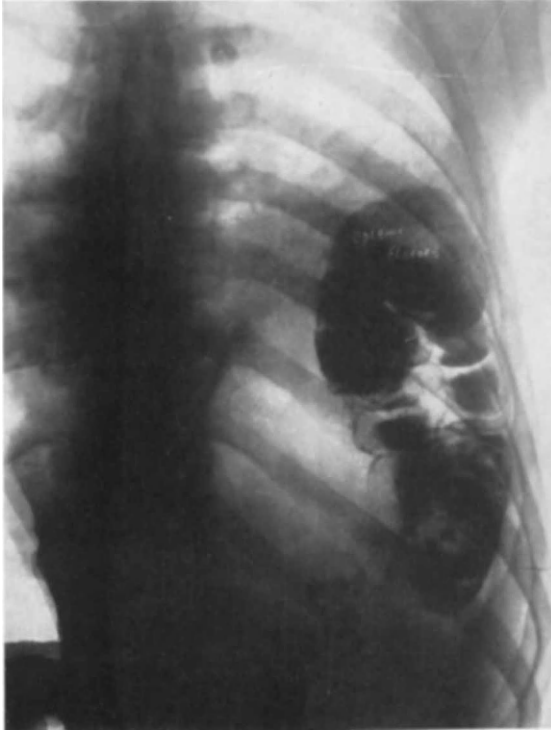

Fig. 472.—Radiograph showing splenic flexure in diaphragmatic hernia.

The opening in the diaphragm was closed as follows: A flap of peritoneum was turned back from the abdominal surface of the upper part of the diaphragm where it approximated to the upper edge of the hernial opening. The diaphragmatic pleura covering the pleural surface of the lower part of the diaphragm where it adjoined the lower edge of the wound was removed. The upper and lower edges of the wound in the diaphragm were now approximated and imbricated with sutures (*Fig. 475*).

The Transpleural Approach.—The transpleural has certain advantages over the abdominal approach. It permits of division of adhesions of the viscera high up in the pleural cavity. It also gives a free approach

to the dome of the diaphragm, in which position it is easier to suture the hernial opening.

The approach described by Roberts gives satisfactory results. The usual incision is made in the soft tissues, and the 7th and 8th ribs are divided posterior to the tubercles. The pleura is divided

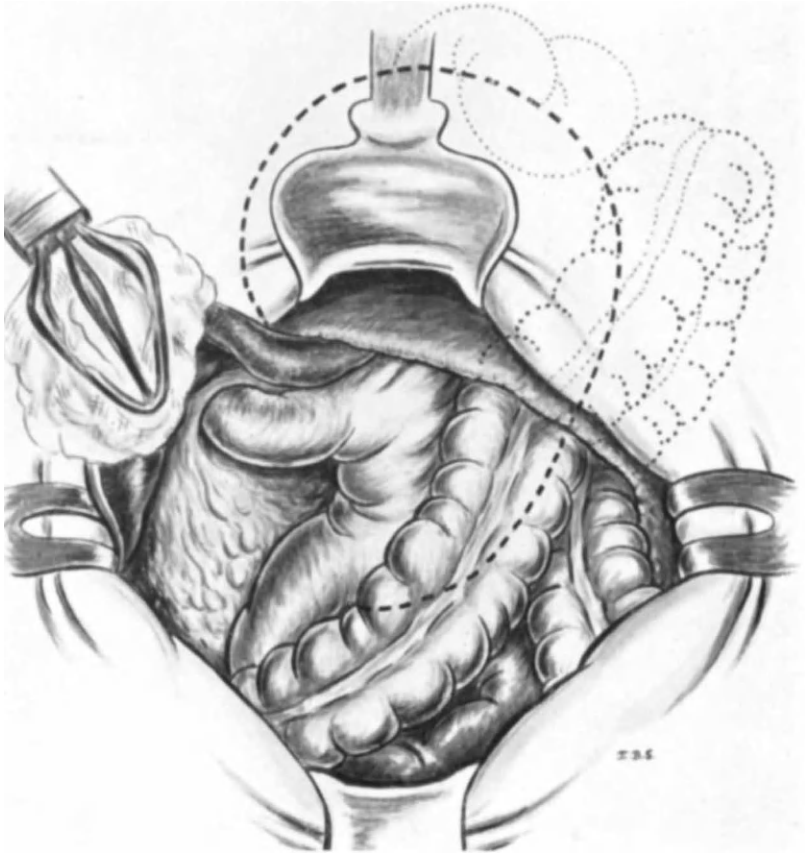


Fig. 473.—Stomach, splenic flexure, small intestine, and part of the left lobe of the liver passing through opening in the diaphragm.

for the length of the incision. A rib spreader is inserted in the wound. If there is no sac, any adhesions are divided and the abdominal contents are reduced. If there is a sac, it is dissected free from adhesions and free from the diaphragm. The opening in the diaphragm is then closed with interrupted sutures by a method of imbrication.

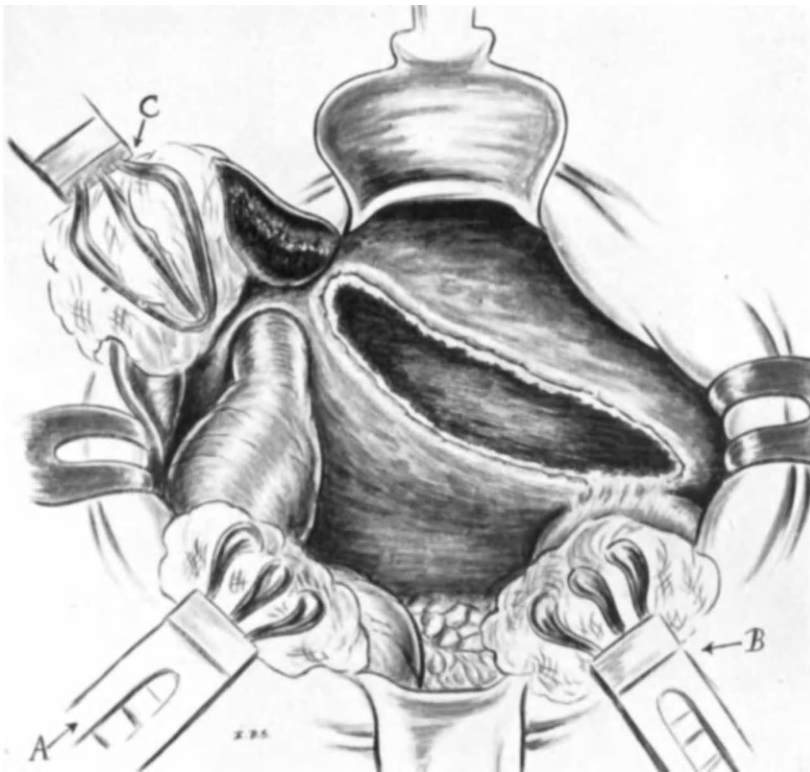

Fig. 474.—Opening in the diaphragm exposed after the contents of the hernia had been withdrawn. The stomach is held in position in the abdominal cavity and prevented from being sucked into the chest by 'mechanical hand' **A**; **B** performs the same office for the colon and small intestine, and **C** for the liver.

Strangulated Diaphragmatic Hernia.—In some cases of diaphragmatic hernia, in old debilitated people, partial strangulation of the colon takes place, when the adhesions may be so great that it is almost impossible to disconnect from the pleural cavity the colon or any other abdominal organs which the hernia may contain. In such a case it may also be impossible to return these organs to the abdominal cavity, even if the general condition of the patient would permit the severe operation necessary for their dissection and replacement.

In these circumstances, there are three possible palliative procedures, as follows:—

1. Division of the phrenic nerve for the purpose of paralyzing the diaphragm.

2. Enlargement of the opening in the diaphragm to make it so big that it cannot cause strangulation.

3. Fixation of the incarcerated loop of the large bowel in the abdominal cavity by means of omentum and sutures in such a way that it cannot be completely drawn into the chest.

In one very feeble old man, who developed strangulation of the large bowel which was incarcerated in a diaphragmatic hernia, the author adopted the last course. This patient has been well for years.

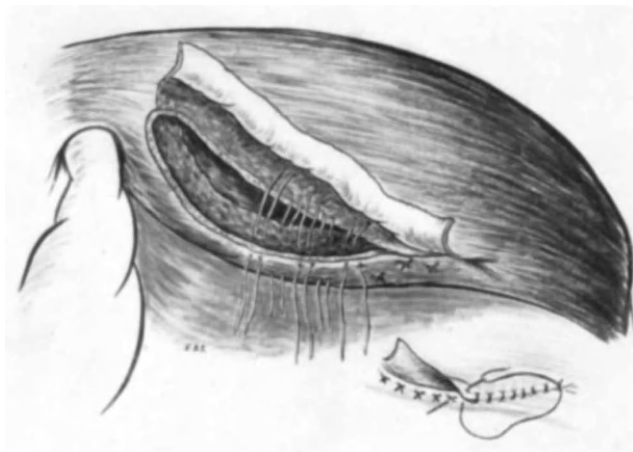


Fig. 475.—Imbrication of edges of diaphragmatic hernia. *Inset.*—Covering the imbrication with the peritoneal flap from the diaphragmatic surface of the upper part of the opening.

A STANDARD TECHNIQUE FOR INGUINAL HERNIOTOMY UNDER LOCAL ANÆSTHESIA

There are many methods of operation for inguinal hernia. Most of these are well described in text-books, and no essential purpose would be served by including descriptions of them in this work. It may, however, be useful to include here a method for the routine performance of the operation for inguinal hernia under local anæsthesia which in the author's hands has been most satisfactory. In a careful follow-up of the last 100 cases, in most of which the patients were old or had had previous operations, 90 were traced. In these there were four recurrences.

The steps of the operation are as follows:—

An area of skin and superficial fascia about 3 in. by 6 in. in the vicinity of the inguinal canal is anæsthetized by subcutaneous

injection of 3 oz. of $\frac{1}{2}$ per cent novocain-adrenaline solution, and five minutes is then allowed to elapse.

The use of a self-filling local anæsthetic syringe (*see Fig. 337*, p. 467) facilitates this injection. The employment of Kirschner's high-pressure local anæsthesia apparatus, however, which the author now uses (*see p. 469*), entirely does away with the usual time-consuming technique of local anæsthesia.

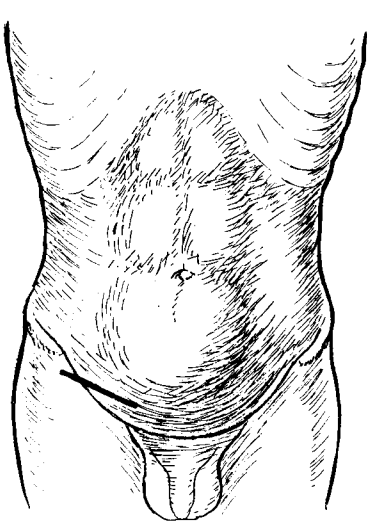


Fig. 476.—The incision.

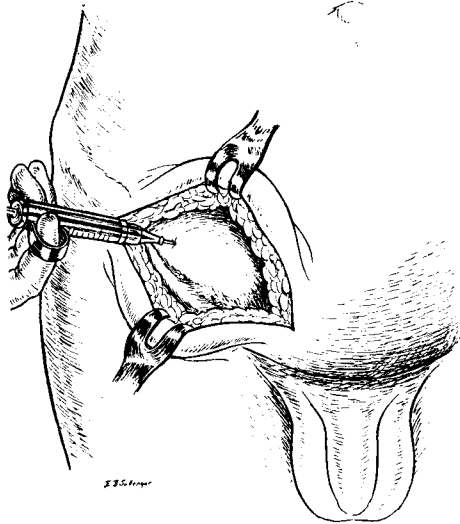


Fig. 477.—Injection of novocain-adrenaline solution in the vicinity of the internal abdominal ring.

The incision is made along the natural creases of the skin, as shown in *Fig. 476*, and, in the first place, only through the skin itself.

In a fat person, where deeply situated sensitive blood-vessels may not be reached by the subcutaneous injection, the incision in the superficial fascia is deepened in one part only, and through this the inferior layer of the superficial fascia is injected with more local anæsthesia, and a few minutes is again allowed to elapse.

The incision is deepened as far as the aponeurosis of the external oblique, and all vessels are clamped and tied.

One ounce of 1 per cent novocain-adrenaline solution is injected underneath the external aponeurosis in the vicinity of the internal abdominal ring (*Fig. 477*). This solution, incarcerated as it is under a certain amount of tension, will completely anæsthetize all the structures of the cord, if given sufficient time.

The external oblique aponeurosis is incised.

By means of the spade-pointed dissecting scissors the cord is isolated from Poupart's ligament, as shown in *Fig. 478, A*. It is also isolated from the lower edge of the internal oblique and transversalis muscles (*Fig. 478, B*).

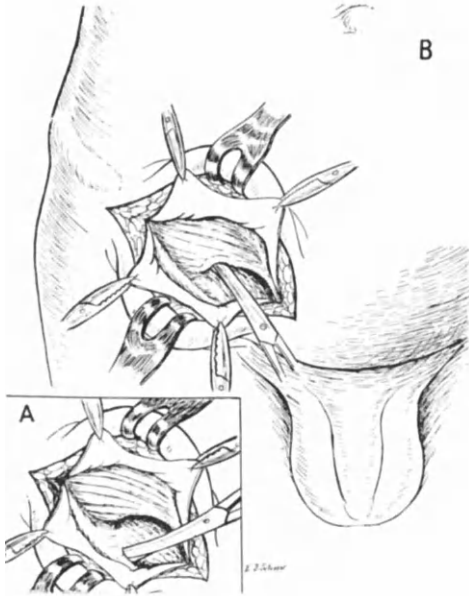


Fig. 478.—Spade-pointed dissecting scissors isolate the cord from Poupart's ligament (*A*) and the lower edge of the internal oblique and transversalis (*B*).

If there is omentum or bowel in the hernial sac, this latter is opened, and the bowel or omentum returned into the abdominal cavity.

The cord is now dislocated by inserting the finger underneath it, and bringing the point of the finger up in the vicinity of the pubic ramus; that is, at a spot where the cord does not lie over the transversalis fascia and where there is a definite line of cleavage and a firm wall behind it (*Fig. 479*). At this stage a few cubic centimetres of 1 per cent novocain solution may have to be injected into the posterior wall of the cord just as it emerges from the internal abdominal ring—a region of the cord

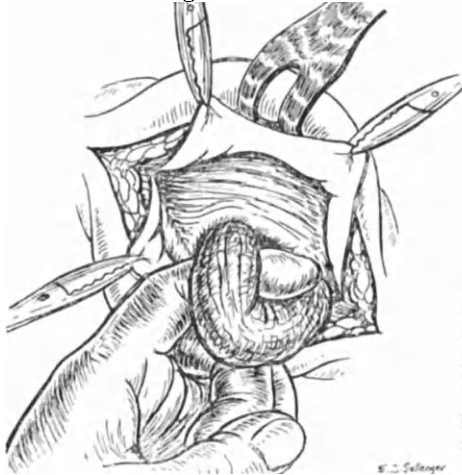


Fig. 479.—The cord is dislocated by inserting the finger underneath it, and bringing the point of the finger up in the vicinity of the pubic ramus.

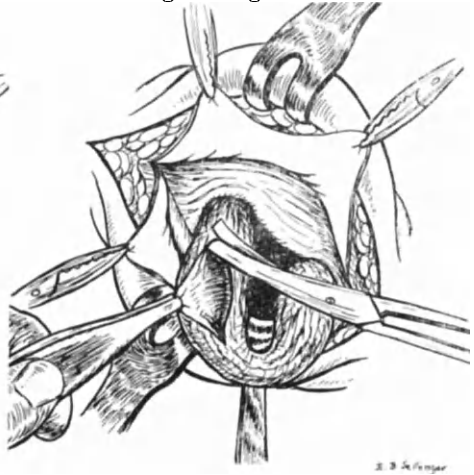


Fig. 480.—Incision of the sac.

which may not have been reached by the injection made beneath the external oblique. If the sac has not already been opened, it is now incised as shown in

Fig. 480.

The posterior wall of the sac close to the internal abdominal ring is 'floated away' from the vascular structures of the cord by injection of $\frac{1}{2}$ per cent novocain solution, using an exceedingly fine needle (*Fig. 481*).

The spade-pointed dissecting scissors (utilizing their spade action) are inserted between the wall of the sac and the other structures of the cord, and the wall of the sac is divided (*Fig. 482*). The division of the posterior wall of the sac close to its neck, where there is always a definite plane on account of

the proximity of this part to the peritoneal cavity where of course the subperitoneal plane is very definite, enables the true plane of the hernial sac to be accurately discovered.

The proximal part of the sac can then be isolated with a stroke of the dissecting scissors and tied in the usual way (*Fig. 483*). Along the plane thus formed—the true plane—the hernial sac will strip without any bleeding. (It is almost impossible to find this plane accurately if the dissection is started from the fundal end.) Forceps are attached to the distal cut end of the hernial sac and this structure is *very slowly* and *very gently* drawn away from the cord. If a continued gentle pressure is applied—a pressure not great enough to break the vessels but only sufficient

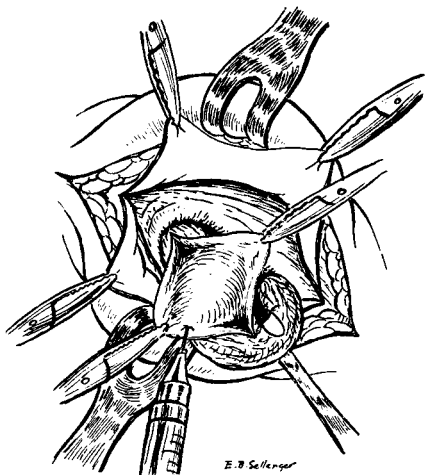


Fig. 481.—The posterior wall of the sac close to the internal abdominal ring is 'floated away' from the vascular structures of the cord by injecting novocain solution.

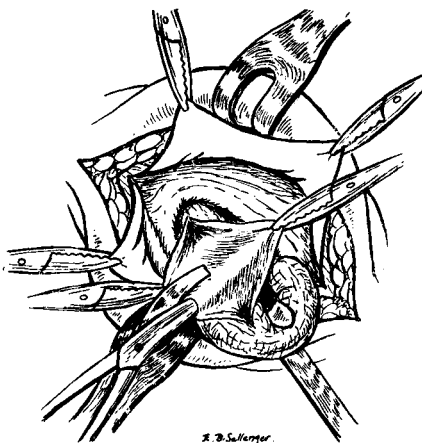


Fig. 482.—Scissors, inserted between the wall of the sac and the other structures of the cord, dividing the sac.

this is done under local anæsthesia, are factors which make for almost uniform success in this hernial operation. The extensive imbrication makes sure of a wide application of surface to surface and the union of a fibromuscular structure to Poupart's ligament; and the absence of vomiting after the local anæsthesia leaves the sutured layer undisturbed.

The imbrication of muscle described here, which is based on the principle of Bassini's operation, is especially necessary in adults or old people, for in these there is nearly always a muscle insufficiency. In the author's experience a muscle insufficiency, either congenital or acquired, is the cause of a hernia just as frequently as, if not more frequently than, the presence of a preformed sac.

He has been led to place great importance on the painstaking

repair of the abdominal wall in the manner described above because of observations in a large number of cases of hernia and recurrent hernia. He has often found a very definite muscle insufficiency; and has noticed that the recurrences have taken place through a break in the abdominal parietes which has occurred

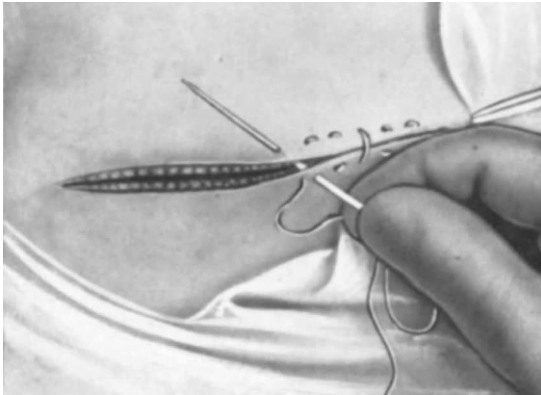


Fig. 488.—Kissing skin suture used to close the skin of the abdominal wall.

at the junction of Poupart's ligament with the rectus—that is, at the medial end of the inguinal canal, where the repair of the parietes must necessarily be always precarious.

The external oblique and the skin are closed in the usual way (*Figs. 487, 488*), a kissing suture being employed to close the skin of the abdominal wall.

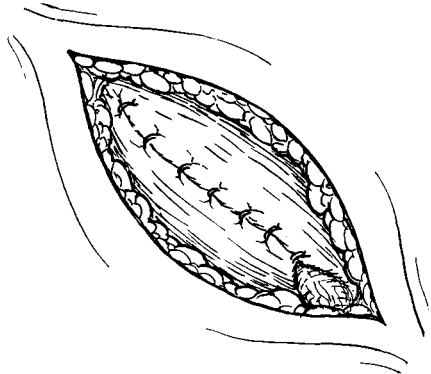


Fig. 487.—Closure of the external oblique.

The scar which results from a wound made in the direction and closed in the manner described leaves scarcely any blemish. This is, perhaps, not a necessity, but certainly it is an indication to a patient of surgical efficiency.

The technique of this operation can be carried out so exactly as almost to avoid shedding any blood—a technique which makes for almost certain and exact repair, and for standard results.

OPERATION FOR EXTENSIVE SLIDING HERNIA

The following illustrative case describes how this difficult hernial problem may be dealt with:—

A patient of 48 presented himself with an enormous inguinal hernia of the right side. He gave the history that he had had an operation previously, but that the hernia had returned almost at once. An examination gave the impression that it was a very large hernia of the sliding type (*hernie en glissade*).

Operation.—The patient was dealt with in the following way:—

The region of the hernia was locally anæsthetized with Kirschner's high-pressure local anæsthetic apparatus.

When the hernia was exposed, it was found that it consisted of two sacs—a large medial one (a direct hernia) the size of a baby's head, which was composed of bladder, and a lateral, which was separated from the medial one by the epigastric vessels. This latter was a large sliding hernia containing the cæcum.

The condition was dealt with by a slight modification of Schmieden's¹ method of operation for inguinal hernia:—

1. The lower edges of the internal oblique transversalis muscles (paralysed and flaccid from the local anæsthesia) were lifted up from the peritoneum and extensively mobilized. An opening was made in these muscles about an inch and a half above their lower edge directly above the internal abdominal ring.

2. The testicle was drawn up from the scrotum (*Fig. 489*), disconnected from the gubernaculum, and passed up through the opening described above; and the edges of this opening were then neatly closed round the cord with interrupted catgut sutures (*Fig. 490*).

3. The patient was placed in the exaggerated Trendelenburg position, and the cæcal and bladder sacs were reduced.

4. The mobilized internal oblique and transversalis were imbricated to Poupart's ligament and the adjoining external oblique throughout the whole length of the inguinal canal, by mattress catgut sutures, as illustrated in *Figs. 485* and *486*.

5. The external oblique was divided vertically opposite the new exit of the cord from the internal oblique in order to allow the cord to be brought under the superficial fascia.

6. The upper flap of the external oblique was brought down over the line of sutures of the internal oblique and transversalis, and with interrupted sutures, incorporating conjoined tendon, Poupart's ligament,

In the diagnosis of an abdominal tumour in the upper left part of the abdomen—that is, one which is suspected of being an enlarged spleen—examination must be made to determine the following points :—

1. The shape of the tumour.
2. The axis along which it has extended.
3. Whether it can be pushed through into the loin, and felt there by a palpating hand.

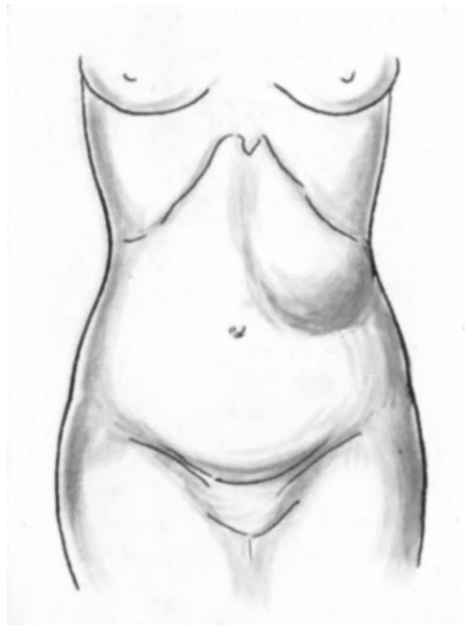


Fig. 491.—Sketch of position of renal tumour which was difficult to distinguish from a splenic tumour.

4. Examination of the tumour on the radiographic screen, by palpation, and the relation of the tumour to the barium-filled colon and to the left cupola of the diaphragm.

5. Pyelographic examination : if the tumour is an enlarged spleen, a pyelogram will show that the kidney is displaced downwards and medially. The dislocation of the pelvis of the kidney in this direction may be regarded as pathognomonic of a tumour of the spleen (*Fig. 492*) (V. Rapant and J. Bedrna¹). Sheele describes a method whereby it is possible to detect whether a movable tumour in the left hypochondrium involves the kidney or not. He makes a

pyelogram of the kidney, and notes the relation of the pyelogram to the skeleton. He then manually displaces the tumour, when any alteration of the pyelogram in relation to the skeleton denotes involvement of the kidney.

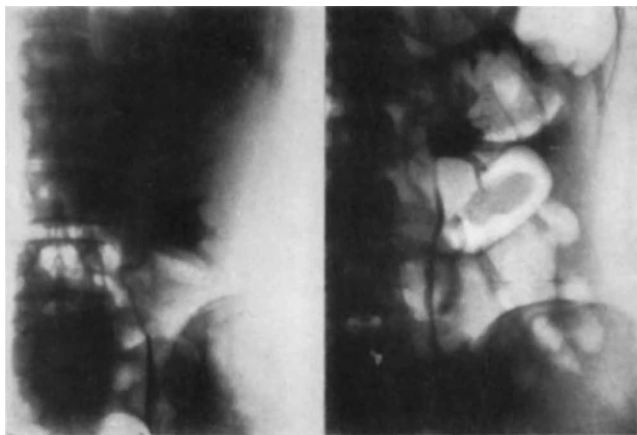


Fig. 492.—Large splenic cyst dislocating the kidney pelvis downwards. Pyelograms before and after extirpation of the cyst. (*From 'Der Chirurg'.*)

FUNCTIONS OF THE SPLEEN

In order to understand the various causes of splenomegaly, it is necessary to understand the functions of the spleen. In spite of an immense amount of research, we are still in doubt even as to the place held by the spleen in that group of tissues that constitute the reticulo-endothelial system. We are still uncertain whether the spleen functions by the local activity of its cells, or by the formation of hormones which exert their effect in other parts of the body. As far as we know at present, the functions of the spleen—at any rate, so far as they concern the causes of splenomegaly—may be grouped in relation to four separate systems: the hæmatopoietic, the sympathetic-endocrine, the digestive, and the reticulo-endothelial.

The Hæmatopoietic System.—During embryonic life, red cells and leucocytes are manufactured in the spleen.

Leucocytes arise from the Malpighian bodies, and endothelial cells of the splenic type may proliferate under certain circumstances and be thrown off into the circulation. A return to this function is seen in the leukæmias, and in adult life. The spleen also serves as a *depot for the storage of blood* which is only required during periods of activity, and it plays an important part in the metabolism of iron.

The Digestive System.—The volume of the spleen varies during the day, an increase occurring some time after meals. It may be that there is some connexion between the variation in the size of the spleen and the leucocytosis which occurs during the process of digestion.

The Sympathetic-endocrine System.—The sympathetic nervous connexions of the spleen are very intimate, and it has been shown that the injection of splenic extract causes a contraction of smooth muscle.

A connexion has been suggested between the spleen, thyroid, and thymus gland.

The Reticulo-endothelial System.—The spleen constitutes the most important single member of the reticulo-endothelial system, which is a widespread group of tissues, one of whose functions is to produce white blood-cells. The other reticulo-endothelial tissue groups are—the cells of the lymph and blood sinuses, the Kupffer cells of the liver, the cells of the capillaries of the bone-marrow, of the adrenal cortex, and of the hypophysis.

In addition to the production of white blood-cells with their varied functions, such as phagocytosis and repair, another function of the reticulo-endothelial system is to bring about the destruction of red blood-cells (and, it is supposed, of blood-platelets), the broken-down products of which form bile, and which are filtered from the blood-stream by the liver.

As the spleen is one of the largest aggregations of the reticulo-endothelial tissue, its functions as a member of this system are therefore (1) destruction of blood-cells and blood-platelets; (2) production of phagocytes, lymphocytes, and other white cells; and (3) defence against infection—phagocytosis. In this last capacity it will act, as it were, as a filter for micro-organisms present in the blood.

A function of the spleen, too, is to store lipid in its reticular cells. This is especially seen when the blood-cholesterol is high.

Of practical importance is the fact that, since the spleen is only a part of the reticulo-endothelial system, it is obvious that it can be surgically removed without causing a gross change in the functions of the body; for the other tissues of the reticulo-endothelial system can take on its function.

Splenectomy is followed by a temporary secondary anæmia. The main disability, however, is due to loss of an extensive blood depot. As a result of this, hæmorrhage is not well tolerated; less exercise can be taken, as there is little reserve of blood to supply the extra needs during exertion.

VARIOUS CONDITIONS ASSOCIATED WITH SPLENOMEGALY

After a practical experience of a number of cases of splenomegaly, it is very difficult indeed to divide them into types, at any rate into such types as are found in text-books.

In practice, it will be found that the standard classification of splenomegaly is merely an arbitrary one, and that there are many types which seem to differ from one another only in grade or degree. It will also be found that biochemical tests often confuse more than they help; that reticular forms vary; that fragility may appear for considerable periods in a particular type, and then disappear. It also happens that the shape of the red blood-cells may vary and receive different descriptions.

There are, however, certain well-known types of splenomegaly which are usually described, associated with particular diseases, and these are considered below.

Splenic Anæmia.—The cause of this disease is unknown. It is progressive, and is supposed to be caused by infective organisms caught up in the spleen—organisms of which the toxin causes destruction of splenic pulp-cells, fibrosis, and thrombophlebitis.

The result of these changes is an enlarged spleen, with, perhaps, an increased function. It is supposed that this increase of function, by causing greater destruction of red cells, brings about a secondary anæmia.

The First Stage of Splenic Anæmia.—The enlarged spleen and the secondary anæmia constitute the first stage of the disease. During this stage very severe bleeding from the stomach may occur. This is probably due to a toxic spoiling of the gastric mucous membrane, which results in the formation of tiny acute ulcers, but even at this stage it may be due to rupture of an œsophageal varix.

To the surgeon, the interest of this stage of the disease lies in the fact that gastric hæmorrhage from the condition is frequently confused with and diagnosed as bleeding from an acute gastric ulcer, as for example :—

A man, aged 40, was seen because he had had a very severe attack of hæmatemesis, from which he was in danger of dying.

He had suffered for years from flatulence and discomfort after meals, and this was his third attack of hæmatemesis, the first having been six years earlier. He had no other symptoms, and in between the attacks his general health was good. It was thought that his hæmatemeses were due to gastric ulcer and that the question of operation should be considered.

X-ray examination showed an enlarged spleen, which had not been discovered by the abdominal examination, and further examination showed that the patient was suffering from splenic anæmia of the first stage.

Splenectomy was performed, and the patient remained well till four years later, when he died from a recurrence of the gastric bleeding.

The Second Stage of Splenic Anæmia.—The second stage is characterized by changes in the liver. The toxic splenic blood proceeding by the splenic vein to the liver probably causes at first an enlargement of the liver, and later a degeneration of the specialized elements of the organ and a fibrosis, which lead to contraction round the portal venules. Thus a condition similar to a portal cirrhosis finally develops, and the liver may have a hobnailed appearance. Jaundice and ascites soon supervene.

This second stage of splenic anæmia is extremely difficult to diagnose from a cirrhosis of the liver, in which, of course, there is also an enlarged spleen. The distinction is of surgical importance, because splenectomy in the second stage, while not so efficacious as in the first stage of the splenic anæmia, is nevertheless of considerable value. As a rule it will be found that in cirrhosis of the liver the enlargement of the spleen is secondary and not very great, and the liver condition arises early and predominates; but that in the second stage of splenic anæmia the liver condition arises late, and the splenic enlargement is the dominating feature.

Hæmolytic Icterus : Acholuric Jaundice.—The jaundice which is present in this disease is acholuric; that is, although the patient is jaundiced, bile is present in the stools and absent from the urine. There is no itching or wasting as there is in obstructive jaundice caused by a stone in or a carcinoma of the common duct.

In acholuric jaundice exacerbations of epigastric pain, of pyrexia, of malaise, of jaundice, of anæmia, occur coincident with an increase in the size of the spleen. These are probably caused by paroxysms of increased fragility and hæmolysis of red cells following crises of excessive activity of function of the enlarged spleen.

Thus the disease, in its intermittent periods of activity, in its symptoms and signs, resembles a 'ball-valve' gall-stone in the common duct. The similarity to stone in this position is still greater when, as very often happens, pigment stones and 'biliary mud' occur in the common duct; for in this case obstructive jaundice occurs in addition to the attacks of acholuric jaundice and further complicates the clinical picture. These pigment stones may be found even when the disease occurs in young children.

Acholuric jaundice may occur in families and is then not as a rule a serious disease, and patients suffering from it may live to an advanced age; they are really "more jaundiced than ill". Less often it may be acquired, when it is of a more serious type.

The fact that the jaundice arising from this disease is similar to that found in stone in the common duct, and that pigment stones occur in the common duct in association with it, leads to curious mistakes, as, for example, the following :—

A man, aged 55, was sent for operation by his family doctor with a diagnosis of a stone in the common duct. He gave the history that he had had an operation for gall-stones about two years ago, and since then he had suffered from attacks of epigastric pain, followed by jaundice, and other symptoms. His operation, he said, had been performed for symptoms similar to those which he now had. He had been told that at the previous operation adhesions had been present, but that no stone had been found either in the gall-bladder or in the common duct. He also said that, many years previous to his last operation, he had had an operation, when gall-stones had been found, after which he had been well for some years.

Careful cross-questioning elicited the fact that this patient had had attacks of epigastric pain and jaundice in his youth. Further examination proved that he was now suffering from a hæmolytic jaundice. Thus it was probable that the gall-stones found at his first operation had merely been an accompaniment of the disease which he had had all his life.

Splenectomy effected a cure.

Another interesting confusion in diagnosis with regard to acholuric is related by Mr. Balcombe Quick. He operated on a patient who complained of attacks of epigastric pain and jaundice, and who was found, on examination, to have an epigastric tumour. Mr. Quick had regarded the tumour as a hydatid, and the jaundice as resulting from it. At the operation, he found not only the hydatid but also an enlarged spleen. He thereupon suspected that the jaundice might be due to the splenic condition and be really an acholuric jaundice—a suspicion that was confirmed.

In some cases of familial acholuric jaundice there are strange changes in the bones. The following most interesting history of a child, aged 11 years, whose brother had an enlarged spleen, shows the bone changes, and also illustrates the association of pigment in the common duct with acholuric jaundice, even at this early age :—

A girl, aged 11 years, suffered from attacks of epigastric pain, jaundice, and pyrexia. During the attacks of jaundice, the urine did not contain bile, and the fæces were not clay-coloured. Her brother had similar symptoms, and there was also a history that her grandmother had had signs and symptoms of the same nature.

On examination, a very enlarged spleen could be felt. She had a peculiar appearance, her forehead being high, the skull box-shaped, and the lower jaw protruding. She had a slight obliquity of the eyes. The X-ray appearances of the skull were also peculiar—radiating lines, like hairs, ran at right angles to the plane of the bone (*Fig. 493*). *Fig. 494* is a photograph of the child. At the operation a very large spleen was removed, and small pigment stones were found in the common duct.

This patient died suddenly a few days after the operation, and at the post-mortem no reason for the death could be determined. She had not been shocked after the operation.

At the autopsy it was found that the spleen had a large irregular surface, moderate diaphragmatic adhesions, much obvious fibrosis, but no phlebitis or thrombosis. The bone of the skull was enormously thick, the frontal region being 1.25 cm. and the occipital region 0.9 cm. thick. The head of the right hip was flattened, and the cartilage was of a yellowish colour. The bone-marrow in the upper third of the femur was bright red in colour. Section of the head of the femur showed an area of yellowish discoloration in the head of the bone near the insertion of the round ligament.

The post-mortem findings were (Dr. Eric Cooper) acholuric jaundice, Perthes' disease of the right hip, and thickening of the membrane bones of the skull.

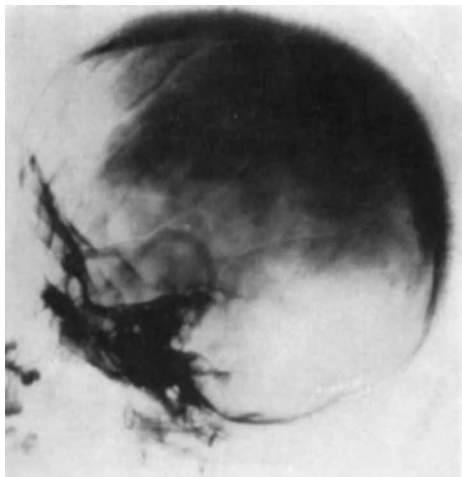


Fig. 493.—Radiograph of skull, in case of acholuric jaundice.



Fig. 494.—Photograph of the child whose skull is shown in *Fig. 493.*

In this case, therefore, it is clear that other constitutional factors, such as disturbances in the calcium metabolism, were associated with the usual symptoms of familial acholuric jaundice.

Pernicious Anæmia.—Splenectomy preceded by blood transfusions was the surgical treatment for many cases of pernicious anæmia before the discovery of the use of liver. It was thought that, as one of the functions of the spleen was to destroy red corpuscles, its removal should therefore lessen an anæmia, in which some hæmolytic factor was at work, by lessening the destruction of red cells. While in a few cases splenectomy was attended with success, in the majority it had very little effect on the disease. It was my experience, however, that splenectomy did improve, for a time at least, those cases of pernicious anæmia associated with an enlarged spleen, an example of which is seen in the following case-history—a case of pernicious anæmia apparently true to type :—

A woman, aged 65, became very sick with pronounced anæmia, rapidly getting worse. Her blood-picture was: Red blood-cells, 2,500,000; Hæmoglobin, 48 per cent; Leucocytes, 4000. The films showed marked anisocytosis, poikilocytosis, a few cells with basophilic degeneration, some polychromatophilia, several nucleated reds, and many megaloblasts. The hæmoglobin index was just below 1. Her spleen was about three or four times the normal size. Her gastric acidity was not estimated. Splenectomy was performed, and the manifestations of pernicious anæmia disappeared.

The patient was then well until twelve years later, when the manifestations of pernicious anæmia returned. She became so ill that she nearly died. Her blood-picture was much the same as that given above. She had now tenderness and pain over her gall-bladder. This time she was treated by the administration of liver extract. She again recovered and is still alive.

Case showing Anæmia of both Pernicious and Aplastic Type, with Thrombosis Migrans.—In a case carefully recorded by Dr. J. G. Hayden, a bronchopneumonic infection seemed to start a train of events in which the patient developed a secondary anæmia, what appeared to be an aplastic anæmia, and finally a condition which seemed to be a pernicious anæmia. At the various stages of her history her spleen enlarged and diminished, and she developed venous and arterial thromboses.

The detailed history of this case is as follows :—

The patient, a woman aged 52, was first seen in August, 1934, with bronchopneumonia. Three months later she complained of dyspnœa on exertion, and it was found that her spleen was slightly enlarged. The blood-count at this time was normal.

In March, 1935, her spleen was markedly enlarged, and she had lost weight and felt very tired. Her blood-count now indicated a secondary

anæmia, and the Wassermann reaction showed a 'strong partial'. With treatment her general condition improved, the spleen receded, and by August, 1935, the blood-count had returned to normal.

In November, 1935, she again developed marked fatigue and dyspnœa, and the spleen enlarged as far as the umbilicus. A study of the blood-count, which showed absence of reticulocytes, indicated an acute aplastic anæmia. She now became jaundiced, and so ill that it was thought she would die. However, after transfusions she gradually improved. While recovering, she developed a thrombosis in her femoral vein and in two of the arm veins. She also developed an acute attack of abdominal pain followed by enlargement of the liver—probably caused by a portal thrombosis. Following this attack of pain, she nearly died.

From now on she continued to improve: the enlargement of the liver gradually subsided, the size of the spleen abated; the blood-film came to resemble that of a pernicious anæmia.

From January, 1936, she was treated with liver extract, and improved remarkably, her blood-count becoming practically normal.

About this time she developed an epigastric pain of moderate severity, followed by jaundice, which became deeper, and now there was bile in the urine and an absence of bile in the stools—obviously an obstructive jaundice. At this stage an operation was performed.

The spleen was found to be very much enlarged, and the whole of its outer surface to be adherent to the diaphragm. The pancreas was firm and enlarged, its lobules were clearly defined, and it appeared as if the arterial supply to the pancreas had been partially or wholly occluded, for the whole of the pancreas was a red infarct. The liver was almost normal in size, and was soft and pliant. The gall-bladder was a hard firm mass adherent to the colon. When it was opened it was seen to be full of degenerating mucous membrane and blood-clots, with walls thickened and hæmorrhagically infiltrated. The vessels of the gall-bladder were thrombosed, and it was the subject of hæmorrhagic infarction. The gall-bladder was drained, and the patient recovered sufficiently to have her spleen removed at a later operation. She recovered and has now been well for three years.

This patient's troubles started with an infection. The infection preceded the enlargement of the spleen, and persisted throughout the whole course of her illness.

The splenic enlargement preceded the various grades of anæmia. Never at any time could the anæmia be said to be truly pernicious, although it approached that type, and never could the aplastic type be said to be truly an aplastic anæmia, although it very closely approached that condition. Then there was the general improvement of the patient as the infection disappeared, followed by the diminution of the size of the spleen until, after a period, the patient practically recovered, although the enlarged spleen was not removed. Finally, there was the occurrence of arterial and venous thrombosis and cure when the spleen was removed.

In this case a splenic enlargement was associated with various types of anæmia. Infection was obviously the primary cause of the train of events.

Erythrocythæmia.—In the disease known as erythrocythæmia the number of the red blood-cells is enormously increased—up to 12,000,000—and the spleen may be greatly enlarged. It is not known what part the enlarged spleen plays in the production of this blood dyscrasia, but in some of the cases where the spleen has been removed

on empirical grounds, the patients have got well. The case-history that follows is typical of the disease :—

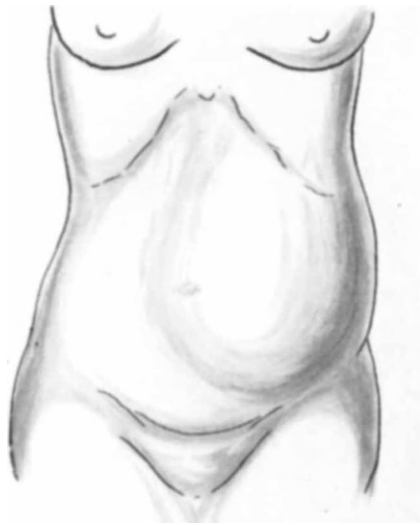


Fig. 495.—Enlarged polycythæmic spleen filling almost the whole abdominal cavity.

A woman, aged 40, consulted a doctor fifteen years ago because she had pain under the left costal margin, and difficulty in breathing. The doctor found that she had an enlarged spleen, and gave her some medicine which, she said, caused the spleen to shrink. She was then well for many years. About six years ago her spleen again began to enlarge, and during the last three years its size increased rapidly. She now complained of a great deal of pain and tenderness over the left side of the abdomen. On examination it was found that the spleen was enormously enlarged, and

nearly filled the whole abdomen, extending as far as the left groin. The patient's complexion was a deep dull-red colour. Her blood-pressure was 125 systolic, 95 diastolic. Blood-count—red blood-corpuscles, 8,000,000; hæmoglobin value, 85 (Tallquist), 90 (Haldane). Colour index, 0.56. Film: cells well formed, leucocytes appear increased in number, mostly normal in appearance, with a few immature polymorphonuclear cells. Examination showed that the spleen was enormously enlarged and filled practically the whole of the abdominal cavity (*Fig. 495*).

An interesting case-history, which serves to show another surgical aspect of polycythæmia, is the following :—

A man, aged 63, became ill, complaining of pain and tenderness over the region of his liver. He developed a mild jaundice. Cholecystographic examination showed absence of the gall-bladder shadow. His condition was then regarded as being due to gall-stones. He had another attack a few months later, but this time the pain was more to the left and lower down,

and he had no jaundice. His surgeon decided to operate on his gall-bladder. Consultation, however, showed that he had a cyanotic appearance and an enlarged liver and spleen; and blood examination that he had 7,000,000 red cells. His was a case of polycythæmia, and the absence of a cholecystographic shadow was probably due to some loss of liver function.

Hæmorrhagic Purpura.—Besides breaking down the red cells, a function of the spleen is to break down platelets. In order that normal clotting of the blood may take place, a normal number of platelets is required. It is thought that bleedings occur in hæmorrhagic purpura because the blood has lost the power of normal clotting, and that this loss is in part due to great deficiency in the blood-platelets. This deficiency, it is considered, may be caused by the excessive functional activity of an enlarged spleen, with which purpura hæmorrhagica is sometimes associated.

Purpura is characterized by a rash which, in the case of the extremities, is on the extensor surfaces. The purpuric spots are characteristic, and they may be distinguished from other similar conditions by the fact that when a rubber catheter is tied rather tightly around the arm of a patient suffering from purpura, petechial hæmorrhages appear distal to the constricted area.

The main interest of purpura to the surgeon is that it may give rise to: (1) subserosal hæmorrhages in the intestines, which may cause intussusception and produce signs and symptoms similar to those of acute intestinal obstruction; (2) a profound hæmaturia, or an alarming hæmorrhage from the mucous membranes of the body, or into the joints.

Splenectomy is indicated in cases of recurrent or chronic purpura which have been shown to have a diminished blood-platelet count. The operation should be preceded by a transfusion.

Diseases Associated with Abnormality of the White Blood-cells.—

Splenomedullary Leukæmia.—Splenomedullary leukæmia is a disease of the white cells of the blood which are formed in the reticulo-endothelial system. As the spleen forms a large part of this system, it takes its share in the causation of the disease—but only a share. In this condition there is an enormous increase in the number and a variation in the type of white cells in the blood, and the spleen attains an enormous size. Because that function of the spleen concerned with the formation of white cells may be excessive in its action, the question of the surgical removal of such an enlarged spleen may arise.

Von Jaksch's Anæmia.—Von Jaksch's anæmia is a condition occurring in children, and presents many of the features of splenic anæmia. It is supposed to have a toxic or specific infective origin, and that it may end in recovery. It is, however, usually impossible to find any toxic source. It is probably caused in the same way as other forms of splenic anæmia, and should therefore not be looked upon as a distinct clinical entity. It occurs in children between the ages of about 3 and 9 years. As in splenic anæmia, there is a profound anæmia, a considerable enlargement of the spleen, and sometimes a slight enlargement of the liver. Sometimes enlargement of the superficial lymph-glands is seen. Examination of the blood shows a diminution of hæmoglobin, and in the number of red cells.

Definite Infective Conditions.—One function of the spleen is concerned with immunity; and this is carried out by the splenic cells, which are powerful phagocytes. It is probably in the exercise of this function that the spleen has the faculty of filtering germs out of the blood. These germs may lie latent in it for years, causing a fibrosis and enlargement of the spleen by their chronic infective action. They can, as it were, hibernate in the spleen. This affords an explanation why enlarged spleen is so often associated with such chronic affections as chronic pyæmia, malaria, tuberculosis, and syphilis. With this type of enlarged spleen is associated, as a rule, a mild grade of secondary anæmia.

Portal Cirrhosis.—It is scarcely necessary to discuss here the enlarged spleen which occurs in association with portal cirrhosis. There are two types of this condition. The spleen may be enlarged as a result of the congestion of portal cirrhosis giving rise to portal obstruction. In this case the toxic condition has primarily affected the liver, and the enlargement of the spleen is secondary to the liver condition. In the second condition the spleen is equally affected by the toxic condition which is supposed to cause the cirrhosis of the liver. The enlargement of the spleen in this case is not secondary, but a primary condition, and one which is frequently associated with venous thrombosis. The distinction is important in view of the possibility of the value of a splenectomy. In the former case it would be of little value but in the latter it might have an ameliorating influence on the course of the disease.

CYSTS OF THE SPLEEN

Cysts of the spleen are rare, and are, therefore, not of much surgical importance. They comprise the types that follow.

1. Single, unilocular, non-parasitic cyst. This type of cyst may reach a large size. Its pathogeny is unknown.

2. Small multiple cysts, usually only encountered at an autopsy. These are of no clinical significance.

3. Polycystic spleen. The polycystic disease may sometimes be confined to the spleen only, but generally it is found associated with congenital cystic disease of the kidneys and of the liver.

4. Hydatid cyst. Of all the cysts of the spleen, this is by far the most important, especially in Australia and New Zealand.

Hydatid Cysts.—Splenic hydatid cysts often coexist with hepatic and pulmonary cysts. The cyst is usually simple, but daughter cysts may be present. In children the cyst is generally univesicular. The spleen may be entirely replaced by the hydatid, which may attain an enormous size.

A hydatid cyst in the spleen may grow upwards towards the diaphragm, downwards towards the pelvis, or towards the midline. It rarely gives rise to pressure symptoms, such as chronic intestinal obstruction; but sometimes it may press on the stomach and give rise to dyspepsia, such as epigastric discomfort on taking a full meal. There are as a rule no symptoms that attract attention and the patient's health is good.

A hydatid of the spleen may cause a widening of the intercostal spaces. Suppuration of a splenic cyst is unusual. Rupture into the peritoneal cavity may occur, and this may be followed by symptoms of anaphylactic shock.

Where the cyst grows medially, it is sometimes very difficult to distinguish from hydatid of the liver. The signs of hydatid of the spleen are usually those of a tumour of doubtfully cystic nature, rounded, smooth, and tense, which moves well on respiration. The tumour is generally movable medially, and can be distinguished from a tumour of the kidney if a pyelogram is made of the kidney pelvis, when the movement of the tumour will be found not to coincide with the movement of the kidney.

Rarely, a hydatid which grows upwards towards the diaphragm gives rise to a pleural effusion or to pulmonary or pleural signs, such as pain on breathing, dyspnoea, cough, perhaps slight hæmoptysis, as well as deficient vocal resonance and diminished breathing at the base of the lung. It is possible with X-ray examination to demonstrate the cyst, especially if it extends up towards the lung. The Casoni test will be positive in 80 or 90 per cent of cases (Dew). The usual immunological reactions are useful in making a diagnosis.

NEW GROWTHS OF THE SPLEEN

New growths are rare. Cases of primary sarcoma of the spleen have been reported.

PERISPLENITIS

The best example of perisplenitis is seen in association with multiple serositis. In this obscure malady the spleen appears as though covered with icing-sugar (*Zuckergussmilz*). Its covering is hard, structureless, and gives staining reactions similar to hyaline cartilage.

WANDERING SPLEEN

Sometimes a spleen has a very long pedicle, and is found in different parts of the abdomen. Occasionally it is found on the floor of the pelvis. The following case-history is an example:--

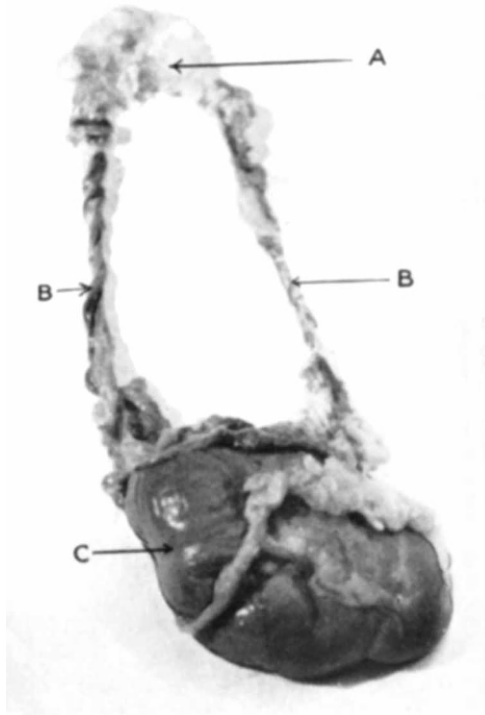


Fig. 496. - Photograph of wandering spleen which gave rise to painful symptoms on account of twisting of its pedicle. **A**, Part of the omentum which was amputated with the spleen; **B**, Veins and arteries running in the omentum to the spleen; **C**, Spleen. The spleen was situated in the omentum, through which its pedicle came. (By courtesy of Dr. J. G. Hayden and Mr. F. Colahan.)

A young woman complained of attacks of pain in the hypogastrium and towards the right iliac fossa. She was operated on in the belief that she had an appendicitis. At the operation a normal-sized spleen was found in the pelvis. The attacks of pain had been caused by an intermittent torsion of the pedicle of this wandering spleen. When

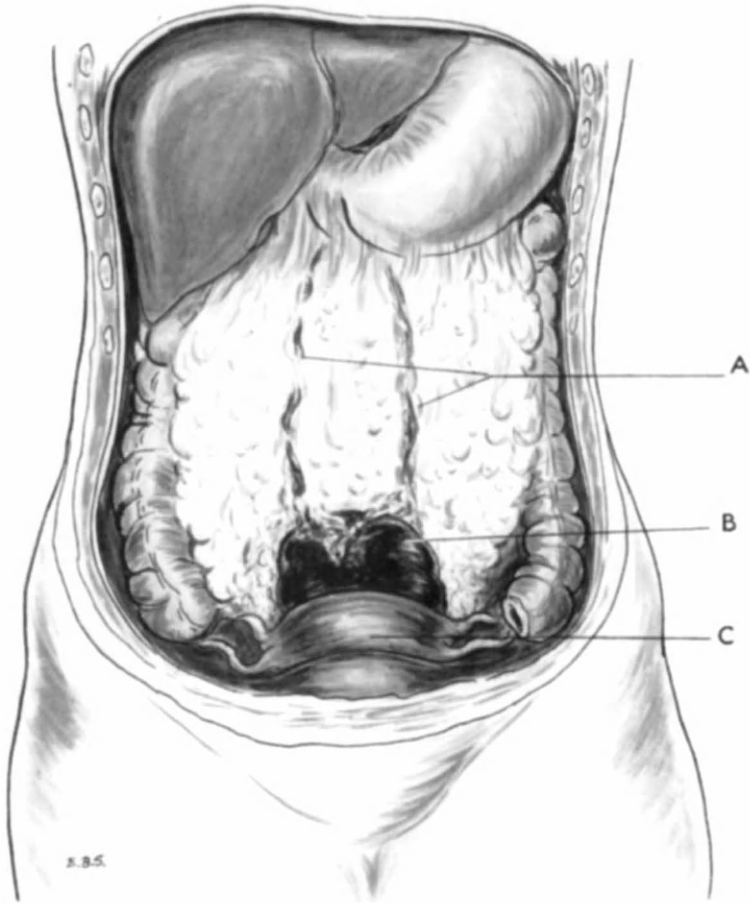


Fig. 497.—Sketch showing wandering spleen lying behind uterus. *A*, Arteries and veins running in omentum to spleen; *B*, Spleen; *C*, Uterus.

it was delivered and the twist unravelled, it was found that the pedicle consisted of omentum, in which ran large vessels to the organ. There was no spleen in the normal situation. *Fig. 496* shows the spleen and the relative length of the pedicle and *Fig. 497* its situation behind the uterus. This case is reported by the courtesy of Dr. J. G. Hayden and Mr. F. Colahan, the latter of whom operated on the patient.

RUPTURE OR LACERATION OF THE SPLEEN

Splenectomy is usually indicated in rupture or laceration of the spleen. Such cases may be divided into three groups :—

1. *Massive Bleeding*.—The patient never recovers from the initial shock, and in these cases the vessels of the hilum are torn, and death takes place in a very short time.

2. *Severe Bleeding masked by Shock*.—After the accident, the patient recovers from the initial shock of the injury, and then signs and symptoms due to internal hæmorrhage come on quickly. These are : an increasing pallor, and a rising pulse-rate ; abdominal rigidity, which is most marked over the upper left part of the abdomen ; local tenderness ; shifting dullness in the flanks ; abdominal distension (probably due to paralytic ileus) commencing about three or four hours after the accident ; Kehr's sign (pain referred to the left shoulder, and perhaps hyperæsthesia in this area).

3. *Mild Bleeding*.—In a few cases the initial loss of blood is small, and symptoms of bleeding are not observed until a second effusion of blood occurs. The delay in bleeding may be due to the great omentum shutting off that portion of the general peritoneal cavity and stopping the bleeding for a time, or it may be due to a blood-clot temporarily sealing the rent.

Treatment.—In most cases of rupture of the spleen, immediate operation with splenectomy is the proper treatment. If the bleeding has not been severe, intravenous injections of saline and 10 per cent glucose may be sufficient to restore the circulation, for as a rule this accident occurs in previously healthy persons. In children, or in patients where the bleeding has been very great and rapid, or where the patient is very shocked, autotransfusion should be carried out.

Autotransfusion in a Case of Ruptured Spleen.—The following is an illustrative case :—

A boy was brought into hospital with the history that he had fallen from a balcony. On examination he was found to have recovered from a period of unconsciousness which followed the fall ; to have a fractured wrist and various other injuries ; and to be suffering from severe shock. Abdominal examination revealed nothing unusual.

Some hours later, the nurse reported that his pulse-rate was rising in an alarming way, and that he was getting paler. Abdominal examination now revealed evidences of internal bleeding. By the time the theatre could be prepared, the boy was almost moribund. Under the influence of very little ether—*Rausch* narcosis—the abdomen was opened, and was found full of blood. This was at once pumped into a vessel containing citrate solution, and, after being strained, was reintroduced into the veins. While this was being done, attempts were made to suture up the rent in the spleen, so as to prevent further bleeding. By the aid of omentum and sutures,

the splenic rent was closed. The large quantity of blood which had accumulated in the abdominal cavity was almost all reintroduced into the veins of the patient. It was remarkable to see the effect of the reintroduction of this massive quantity of blood: the boy's colour changed from that of a marble-white to a pink-and-white almost normal appearance.

In this case the massive autotransfusion saved the patient's life. In severe cases of bleeding from a ruptured spleen, when it is not possible to make a massive autotransfusion, a massive blood-transfusion, several donors being used, should be made.

Post-operative Complications after Splenectomy for Ruptured Spleen.—

1. *Peritoneal Effusion.*—The result of a wound of the tail of the pancreas. It is generally accompanied by a slight pyrexia.

2. *Left Pleural Effusion.*—Caused by injuries of the diaphragm at the time of the accident, or during the removal of the spleen. Aspiration may be necessary.

3. *Hiccup.*—Probably the result of injury to the left phrenic nerve on the under-surface of the left side of the diaphragm.

4. *Subphrenic Abscess.*

THE INDICATIONS FOR SPLENECTOMY

The question of splenectomy will arise in the following conditions: (1) Splenic anæmia; (2) Acholuric jaundice; (3) Thrombocytopenic purpura; (4) Splenomedullary leukæmia; (5) Splenomegaly resulting from infection; (6) Von Jaksch's anæmia; (7) Wandering spleen; (8) Gaucher's disease; (9) Hydatid of the spleen; and (10) Rupture of the spleen.

1. Splenic Anæmia.—As a rule, in cases of splenic anæmia, splenectomy is followed by striking improvement, and occasionally by cure. In one male patient who suffered from splenic anæmia in its first stage, and who had frequent profound hæmatemeses, I carried out a splenectomy. This man was well for four years, and then died as a result of another severe hæmatemesis.

In the later stages of splenic anæmia, when liver changes (cirrhosis) have taken place, splenectomy is attended with danger, and the curative result is not so good. As, however, the medical treatment in such cases is without value, the patient should be given the benefit of a splenectomy. In the late stages this operation is a serious undertaking, because extensive perisplenic adhesions have developed, which make extirpation of the organ very difficult. Blood-transfusion should precede and follow the operation in all cases of splenic anæmia.

2. Acholuric Jaundice.—In cases of acholuric jaundice either of the familial or of the acquired type, splenectomy has its greatest use.

But even in this disease, though the icterus may be abolished, the splenectomy does not completely arrest the progress of the illness.

Splenectomy should never be delayed until pigment stones form, obstruct the biliary cavity, and produce obstructive jaundice.

In cases where pigment stones have formed, splenectomy must be combined with the removal of these stones from the common duct, and also from the gall-bladder if there are any in it; indeed, it may be necessary to drain the common duct and remove the gall-bladder.

In some cases of familial acholuric jaundice, the general health may be so good that splenectomy is not justified. In these cases indications for splenectomy will always be not so much the enlargement of the spleen as the condition of the patient's health.

3. Thrombocytopenic Purpura.—The difficulty in deciding whether a case of thrombocytopenic purpura will benefit by splenectomy or not is wrapped up in the question whether there is a deficiency of blood-platelets, for such a deficiency is an indication of an overaction of the function of the spleen. Unfortunately, however, the number of platelets fluctuates a great deal, and it is difficult to say definitely whether a patient is deficient in platelets or not. In cases, therefore, where splenectomy is carried out in the absence of a deficiency of blood-platelets, a favourable result may not be obtained; and even in some where there is apparently a deficiency on estimation of blood-platelets, a good result may not be forthcoming. In many cases, however, dramatic results are obtained by splenectomy in this disease, bleeding from the mucous surfaces of the body ceasing at once.

4. Splenomedullary Leukæmia.—Splenectomy is not a very sound treatment for splenomedullary leukæmia, because, as the spleen forms *only a part* of the reticulo-endothelial system, this operation can only ameliorate the disease; it can only lessen the power of the reticulo-endothelial system to form white cells.

Moreover, in this condition the removal of the spleen can be a dangerous procedure, because it is usually very large and very adherent to the surrounding structures. But a large leukæmic spleen can very often be successfully removed after the application of radium or following irradiation. These procedures so reduce the size of the spleen that its surgical removal can be safely effected. Cases are reported in which, after these measures and splenectomy, considerable improvement has taken place, and the patients have been alive several years later.

5. Enlarged Spleen Resulting from Chronic Infection.—In these cases (*see* p. 604) there is a certain amount of justification, on

surgical principles, for removing the spleen. Splenectomy will get rid of a storehouse of 'hibernating' germs, and furthermore, may cure the secondary anæmia which is supposed to be caused by the increased hæmolytic action due to the increased function of the enlarged spleen.

In considering splenectomy in relation to infective conditions of the spleen, it is necessary to make special mention of Hodgkin's disease, in which the spleen is enlarged. Surgery has often been mooted as a cure in this disease, but as the splenic enlargement is only part of a general condition, it is obvious that splenectomy is unsurgical.

6. Von Jaksch's Anæmia.—As the disease is progressive, those cases which do not respond to medical treatment should be splenectomized. This measure combined with blood-transfusion has given encouraging results. A series of blood-transfusions both before and after splenectomy should never be omitted.

7. Wandering Spleen.—In this condition, splenectomy is of course the only treatment. It is usually called for in cases where the pedicle becomes twisted—one form of an abdominal emergency operation.

8. Gaucher's Disease.—In point of fact Gaucher's disease is an endothelioma of the spleen and not associated with any blood dyscrasia. Splenectomy is indicated.

9. Hydatid of the Spleen.—In hydatid of the spleen where there are no adhesions, and where removal is therefore possible without undue danger, splenectomy should be the routine procedure. In some cases of hydatid of the spleen where the cyst is single and not very large, the hydatid cyst can be removed, the cavity filled with saline and closed, and the abdominal wound sutured without drainage. Sometimes, where the hydatid has suppurated, it is wiser to marsupialize the cyst and drain it.

Occasionally, operation may be required for the rupture of a splenic cyst. In this case splenectomy cannot be carried out. The peritoneal cavity should be opened, fluid in the hydatid membrane removed, and a drain inserted into the pelvis.

10. Rupture of the Spleen.—In splenectomy for ruptured spleen, the problem, as already pointed out (p. 608), is not so much the removal of the spleen, which is small, as the management of the patient's exsanguinated condition.

THE OPERATION OF SPLENECTOMY

Preliminary Injection of Veritol.—In order to express as much blood as possible out of the spleen, which serves as one of the blood depots in the circulation, 1 c.c. of veritol should be injected about

an hour before the operation. Veritol is a synthetic preparation which causes the spleen to empty its blood-cells into the general circulation.

The Incision and Exposure of the Spleen.—The incision should be a paramedian one, extending from the lower margin of the ribs down as far as the umbilicus or a little below it. An incision at the outer margin of the rectus should not be made, for it will injure

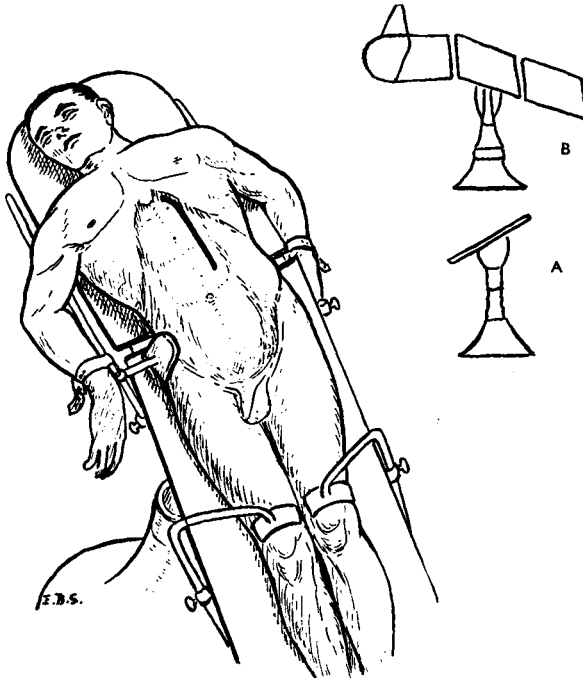


Fig. 498.—Showing the incision and the position of the operating table for splenectomy. *Inset.*—The table is laterally tilted (A) and placed in the reverse Trendelenburg position (B).

the nerves running to this muscle. The incision is placed to expose the vessels of the pedicle of the spleen, the dissection and ligation of which is the important part of the operation. The use of the operating frame enables the spleen to be reached easily through a paramedian incision. If the spleen is very big, more access may be obtained by extending the incision upwards and towards the median line. (*Fig. 498.*)

The operating frame should be locked into the wound, and the abdominal wall elevated, the spleen pushed down into the abdomen by the assistant's hand, and a space made between the anterior surface of the spleen and the diaphragm (*Fig. 499.*) Through

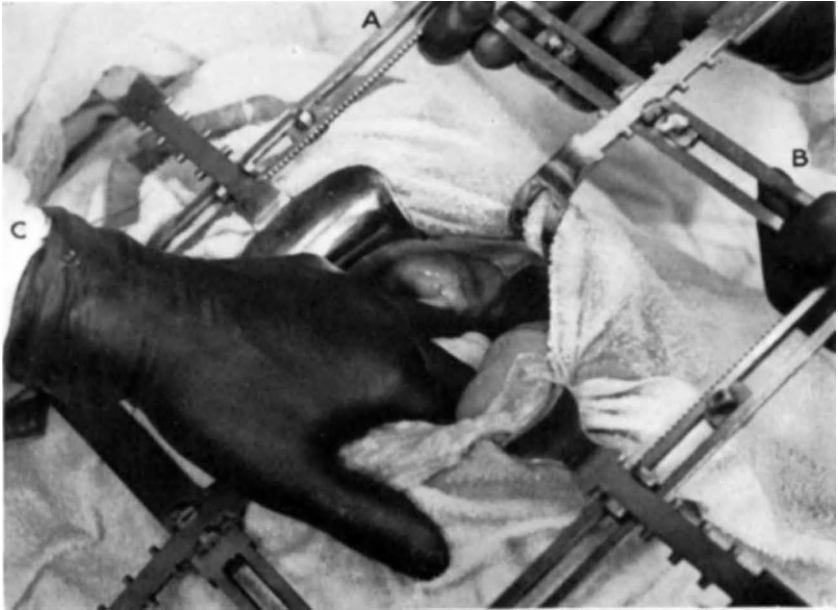

Fig. 499.—Retouched photograph showing the operating frame locked into the incision. The retractor is held at **A** and **B** by the hands of the assistant, and the thoracic wall thus elevated. The left hand **C** of the operator presses down the spleen, which exposes a space between the thorax and the spleen where adhesions can be seen, divided, and if necessary clamped and coagulated with the diathermy current.

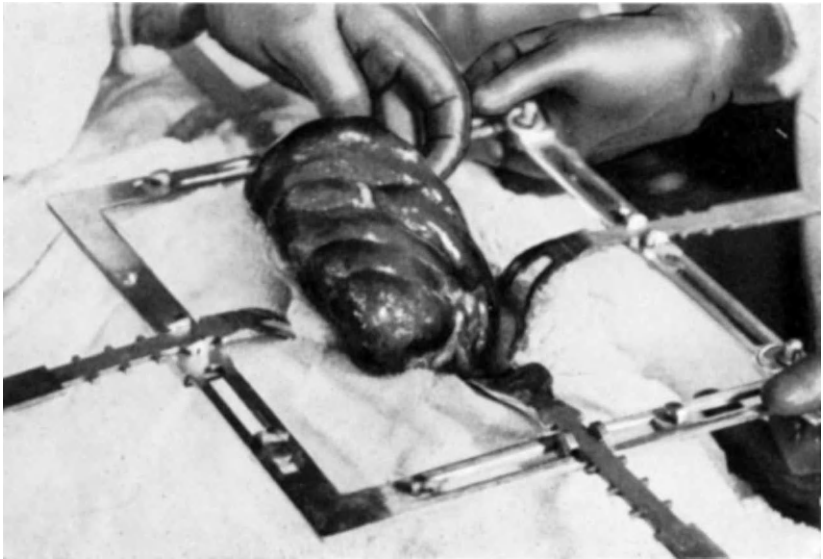


Fig. 500.—Photograph of spleen dislocated and delivered on to the surface through the abdominal wound. The size of the spleen can be gauged from the size of the retractor frame, which is nearly 12 in. to its outside edges.

this space, any adhesions are divided. If necessary, where there are large veins connecting the spleen to the diaphragm, these can be clamped with a long Kocher forceps, and the forceps contacted with a diathermy current so as to coagulate these veins and thus stop profuse bleeding.

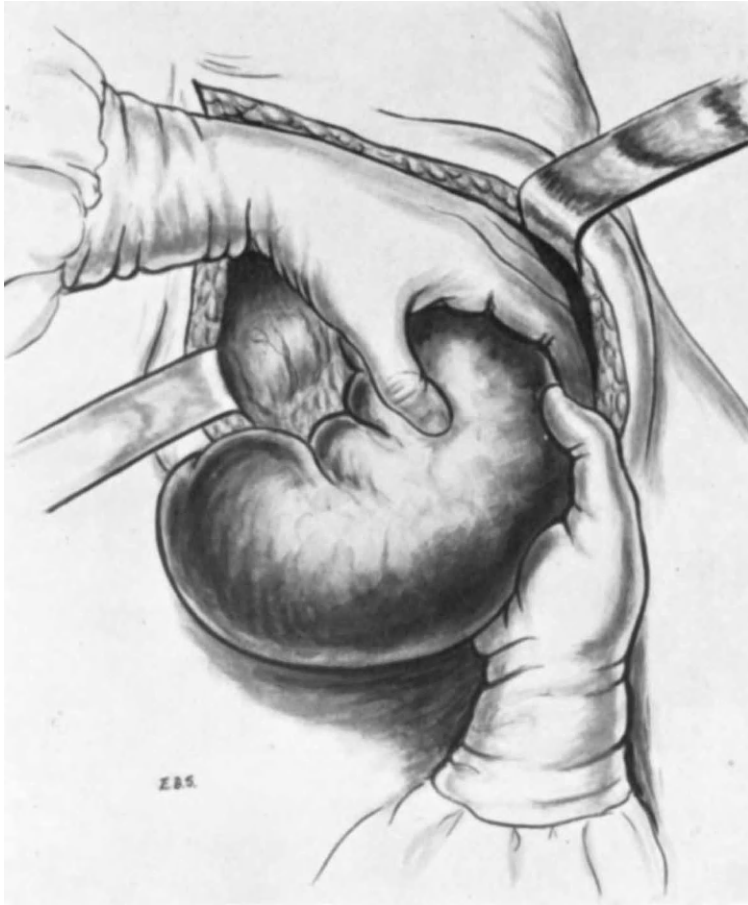

Fig. 501.—Delivery of large spleen before the operating frame is set in the wound.

The spleen is now dislocated into the wound, and it is best dislocated with its lower end coming foremost, that is, along its long axis, its upper end being delivered last. As a rule, it can be delivered through the retractor which is set in the wound (*Fig. 500*).

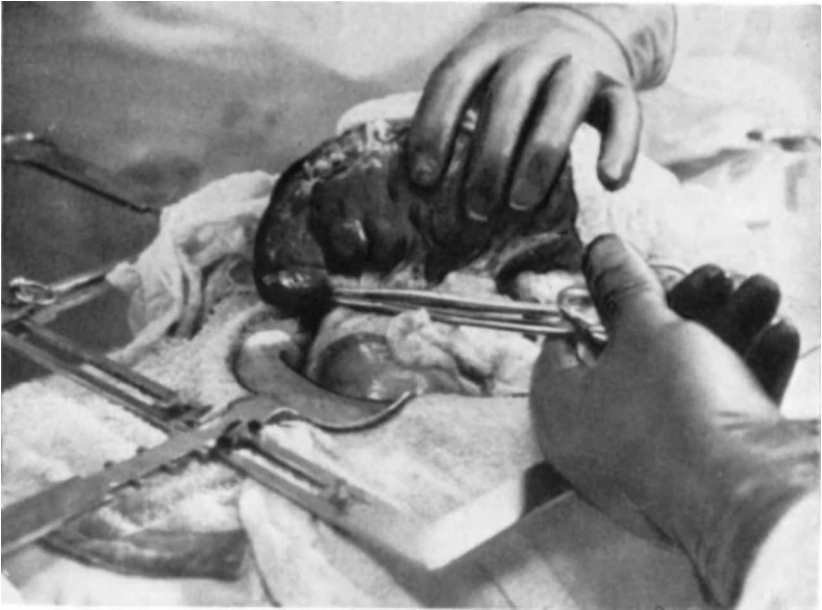

Fig. 502.—Photograph showing the isolation and clamping of the vasa brevia.

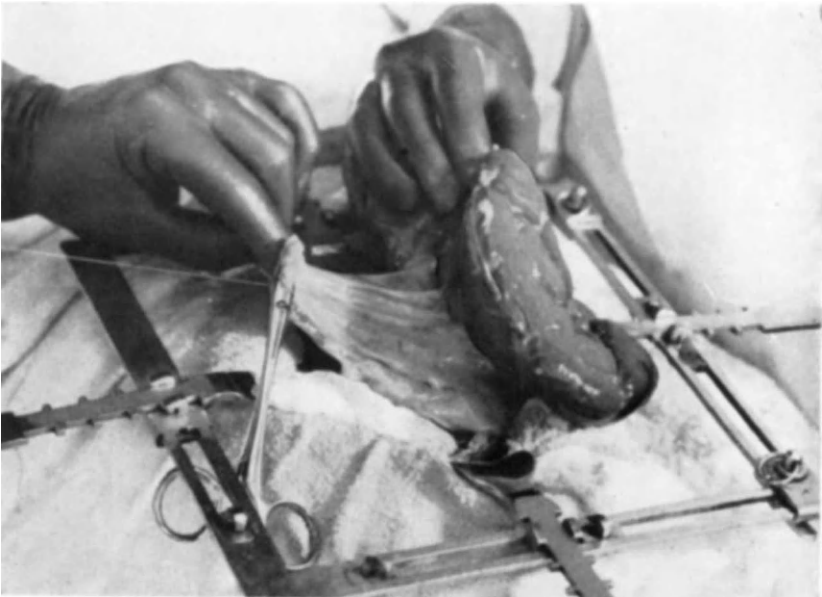

Fig. 503.—Photograph showing ligation of peritoneal adhesions in the vicinity of the pedicle.

If the spleen is very big, it may be necessary to deliver the organ through the wound first, and then set the operating frame in the wound (*Fig. 501*). The edges of the wound are then covered with impermeable material, and the retractor locked in, as shown in *Fig. 500*.

The pedicle of the spleen—the part which requires the most critical attention—is now almost in the middle of the opening made

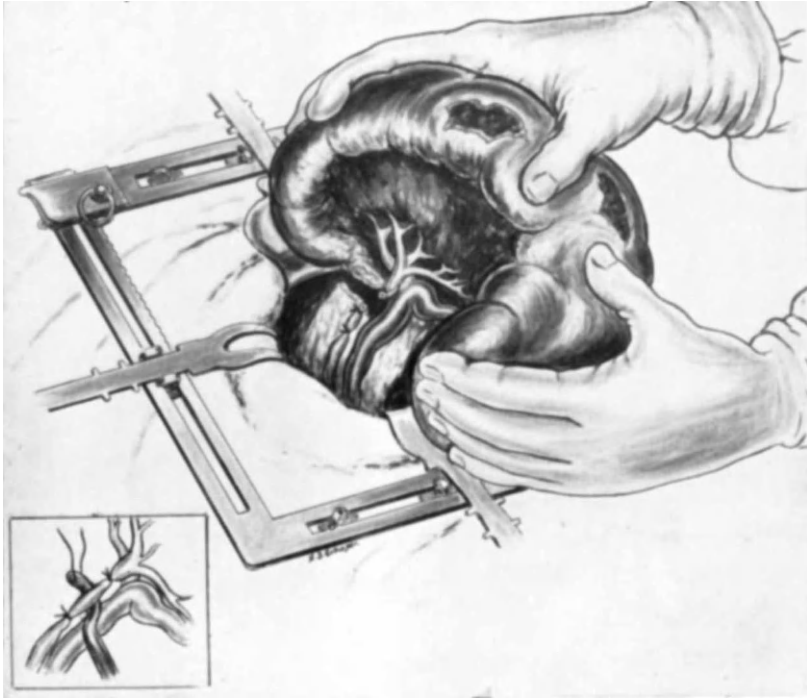


Fig. 504.—The splenic artery ligated, the splenic vein intact, and the spleen held up to facilitate the return of the blood into the general circulation. *Inset.*—The ligation.

by the operating frame, so that it can be quite easily approached and its vessels safely isolated (*Fig. 502*).

Isolation and Ligation of the Pedicle.—The pedicle is isolated by first disconnecting the vasa brevia (*Fig. 502*). The peritoneal covering of the pedicle is then dissected from it until the arteries and veins are isolated (*Fig. 503*). In the preparation of the pedicle for ligation, great care must be taken to separate the tail of the pancreas from it.

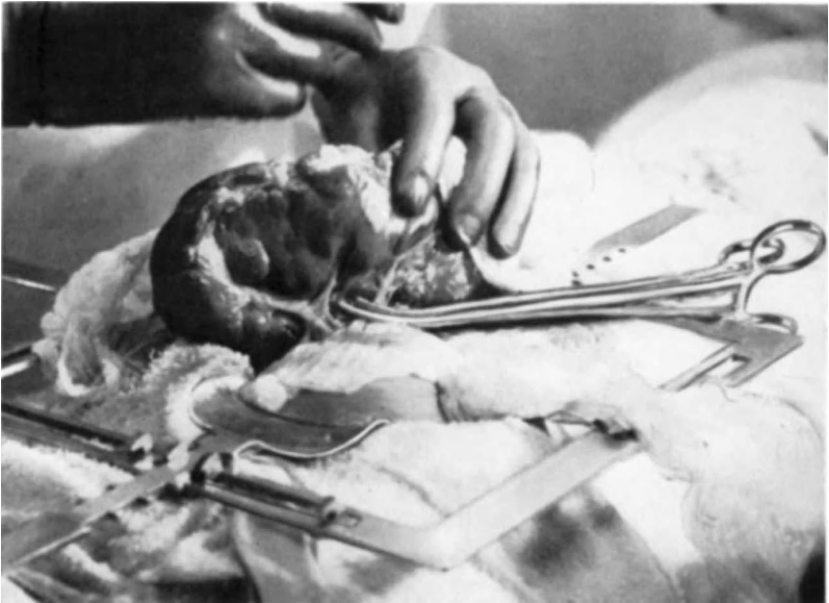


Fig. 505.—Photograph showing pedicle of the spleen laid bare of its peritoneal covering, and two curved Kocher clamps applied to one section of the pedicle.

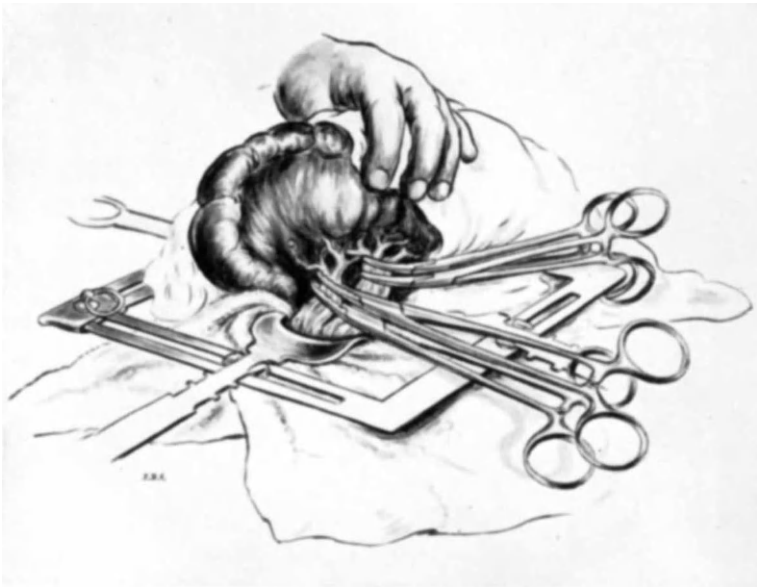

Fig. 506.—Two more Kocher clamps applied to the other section of the pedicle.

In the ligation a certain amount of autotransfusion should be attempted. The pedicle should be ligated piecemeal, the artery being first tied (*Figs. 504, 505*).

The spleen should then be held up so that most of its blood can be gently pressed back into the general circulation through the untied vein, after which the vein is ligated.

Two Kocher clamps applied to each division of the pedicle may be used as in *Figs. 505, 506*. *Fig. 507* shows the ligation of

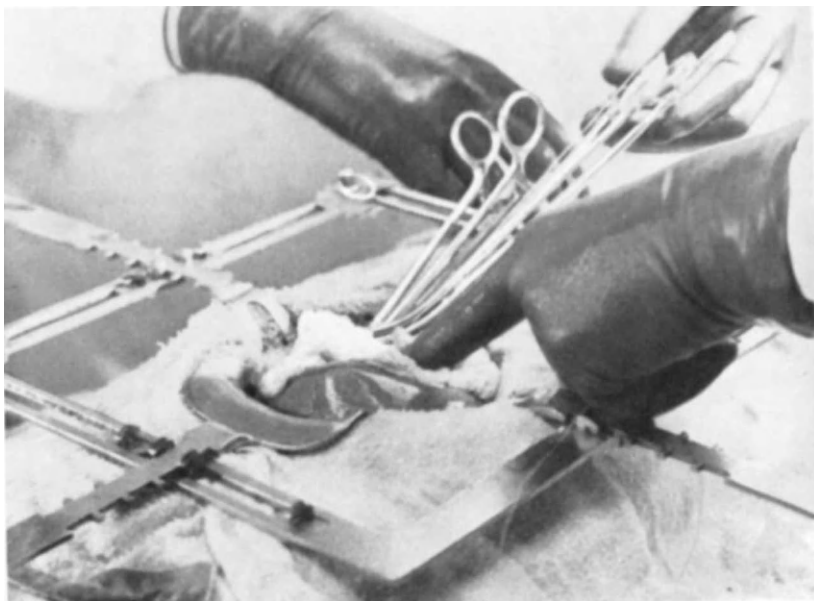


Fig. 507.—Ligation of the pedicle.

the pedicle when the spleen is removed. Four ligatures are placed on the pedicle, two on each vascular division of it.

The pedicle of the spleen may in certain circumstances be ligated *en masse* by means of the author's pedicle clamp (*Figs. 508, 509*). This pedicle clamp has a screw at the end which, when screwed home, prevents the pedicle from slipping out at the end of the clamp—a frequent occurrence when the ordinary type of pedicle clamp is used.

It is therefore a very safe clamp for ligating *en masse* a rather bulky pedicle such as that of the spleen.

The procedure is as follows: the pedicle clamp is placed in position as in *Fig. 509*; curved Kocher clamps are now placed

distal to the clamp, and between these the splenic pedicle is divided.

The pedicle clamp is now loosened by loosening the handles but not the screw, and a ligature tied in the groove which it has made.



Fig. 508.—The author's pedicle clamp. A, Clamping screw which, when the clamp is placed on the pedicle, is screwed home before the handles of the clamp are closed.

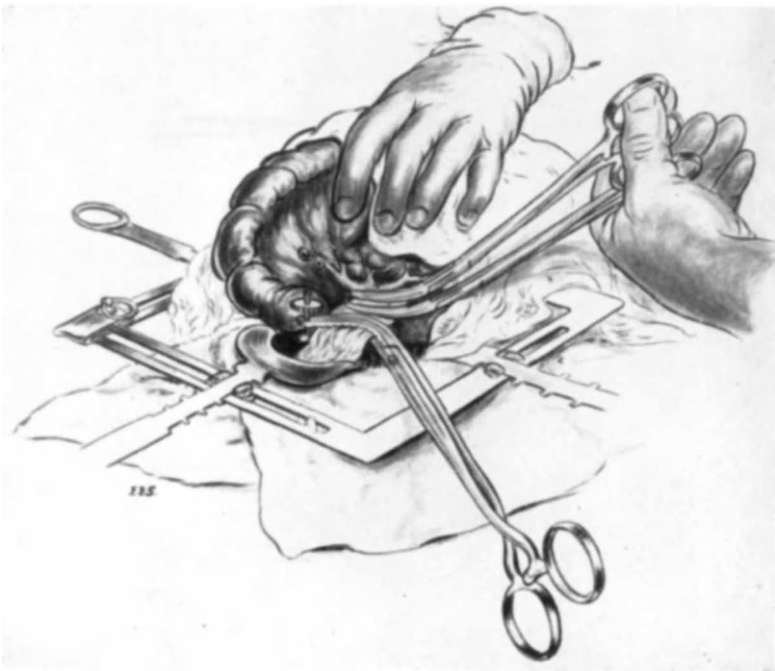


Fig. 509.—Ligation of the pedicle by means of the author's pedicle clamp.

Another ligature is placed behind this clamp and tied as the clamp is removed. A third ligature is put on when the Kocher clamp is released.

After-treatment.—As a rule, so much blood is contained in a large spleen that when this quantity is removed a blood-transfusion is always necessary.

REFERENCE

- ¹ RAPANT, V., and BEDRNA, J., "Die Bedeutung der Pyelographie bei Milztumoren", *Der Chirurg*, 1933, **5**, Feb. 15, 133.

*CHAPTER LVI***THE LIVER AND HEPATOMEGALY****FUNCTIONS OF THE LIVER**

A LIVER dysfunction or insufficiency is an important consideration in regard to any operation on the alimentary canal, but a specially important one in the case of operation for diseases of the gall-bladder or its ducts, where there may be an associated affection of the liver and therefore a disturbance of its function. In order that appropriate pre-operation preparation and post-operative treatment may be instituted—on which the success of these operations may depend—the surgeon must have a working knowledge of the functions of the liver.

From the point of view of the surgeon the most important function of the liver is that it acts as a storehouse for carbohydrates. According to Best,¹ quoted by Sampson Wright, the liver plays an important role in carbohydrate metabolism, and is concerned with many of its aspects as follows: "It transforms lævulose and galactose into glucose. It deposits glycogen from the glucose which reaches it in the portal blood from the small intestine. This change is brought about by the enzyme glycogenase; it seems that insulin is also necessary for this reaction. When the blood-sugar tends to fall, the chemical change is reversed and glycogen is mobilized for tissue use by being converted into glucose (glycogenolysis). Liver glycogen is diminished for this reason in muscular exercise, exposure to cold, and starvation.

"The liver can form glucose from non-carbohydrate sources—certainly from the non-nitrogenous residues of many amino-acids and possibly also from fats. This process is probably constantly taking place in the normal person and is chiefly responsible for the maintenance of the normal level of the blood-sugar during starvation.

"The liver is thus vitally concerned with the regulation of the normal level of the blood-sugar. When the blood-sugar rises it stores glycogen and it is aided in this process by insulin. When the blood-sugar level falls the liver responds in two ways: (1) it mobilizes glycogen by converting it into glucose (it is probably stimulated to act in this way by impulses reaching it from the sympathetic and

by adrenaline); (2) it forms new glucose mainly from protein and is stimulated to do this by the diabetogenic hormone."

Other functions of the liver which are not so important from the point of view of the surgeon are as follows: It forms bile, which includes the excretion of bile-salts and bile-pigment; loss of bile can be counteracted by the administration of bile-salts. It destroys red blood-cells as a result of the action of the reticulo-endothelial cells of Kupffer. It metabolizes protein; amino-acids, the end-products of protein digestion, are deaminized. It metabolizes and desaturates fats. It has a detoxicating action on poisons that reach it from the intestines. The heparin that it contains is concerned with the coagulation of blood. It stores a hematinic factor (Castle) which is formed by the union of an intrinsic factor secreted either in the duodenum or stomach and an extrinsic factor present in the food. It is the principal site for the formation of fibrinogen.

HEPATOMEGALY OF MEDICAL IMPORT

An enlargement of the liver usually indicates some non-surgical and therefore doubtfully curable condition. In Australia and New Zealand, however, such an enlargement is most frequently caused by hydatid disease and is generally curable. Consequently in these countries the diagnosis of the nature of a hepatomegaly is of considerable surgical importance.

Liver enlargements of medical import are of interest to the surgeon because they are frequently confused with those which concern him. They are: (1) Enlargements of obscure origin; (2) Enlargements of circulatory origin, such as the enlarged, perhaps painful, liver which sometimes develops in the early stages of heart failure; (3) Early stages of a hepatic cirrhosis when the liver is enlarged; (4) Late stages of a splenic anæmia when the liver may be enlarged; (5) Enlarged liver caused by polycythæmia; and (6) Enlargements due to malignancy. These last are, of course, inoperable.

i. Hepatomegaly of Obscure Origin.—The case-history that follows is an example of this type of enlargement:—

A woman was operated on in 1923 because she had a greatly enlarged liver, which was thought to be caused by hydatid.

At operation no hydatid could be found.

Three years later she was again operated upon, because the liver was now enormously enlarged, and it was thought that possibly she might have a *central* hydatid which had been missed at the previous operation—a central hydatid in its early stages being difficult to find. At operation nothing but a huge liver with a smooth surface was found.

A few years later she developed pleural effusion, and when the fluid was drawn off it was found to be blood-stained. Later she developed ascites and was tapped a great number of times before she died.

The whole course of the disease extended from eight to ten years. A post-mortem was not obtained.

2. Hepatomegaly of Circulatory Origin.—Hepatomegaly caused by circulatory disturbance may ultimately arise from a rather insidious form of heart failure. Some of these circulatory enlargements mimic very closely those found with hepatic hydatid.

I can remember being asked to operate on a patient who had an enlarged firm liver and who was slightly jaundiced. Although the doctor in attendance had examined her heart, he had not detected any affection; he thought that she was suffering from a suppurating hydatid of the liver. What she really had was an enlarged and diffusely tender liver, with the slight jaundice which is occasionally found associated with certain forms of heart failure.

In my experience, patients with this kind of enlargement of the liver have occasionally been subjected to an unnecessary operation; mainly, I think, because they live in a country in which hydatid of the liver is common, and therefore the enlargement of the liver associated with slight jaundice at once suggests suppurating hydatid.

3. Cirrhosis.—The hepatomegaly resulting from the early stages of cirrhosis is usually recognizable by the history obtained from the patient, and by its association with attacks of slight jaundice. As a rule it does not present a difficult problem in the surgical diagnosis of a liver enlargement.

4. Splenic Anæmia.—Hepatomegaly in cases of splenic anæmia may be so noticeable that it comes into consideration in a case of surgical diagnosis.

5. Polycythæmia.—The importance of recognizing an enlargement of the liver due to polycythæmia is illustrated in the following case-history:—

A man, aged 62, developed a fairly severe pain over the region of his gall-bladder, and became slightly jaundiced. A cholecystograph showed absence of filling of his gall-bladder—a negative cholecystograph—and examination revealed an enlarged liver. He was about to be operated upon on the assumption that he had a diseased gall-bladder. A review of his case showed that he had a polycythæmia, and that not only his liver but also his spleen was enlarged.

6. Malignancy.—Hepatomegaly may be the result of a secondary malignancy and the primary may be 'silent'—that is, it may not give rise to symptoms. In this case the primary growth is generally

situated in either the body of the pancreas, the fundus of the stomach, the colon, or the rectum.

This hepatomegaly gives a characteristic syndrome. The liver is large and lumpy, and yet the patient is not very jaundiced, for it requires much destruction of the liver cells to produce jaundice. If viewed on the radiographic screen, it may show bosses on the diaphragmatic surface. Furthermore, if thorotrast is injected intravenously, a radiograph of it will show less density in the secondaries than in the other parts of the liver, because the Kupffer cells of the liver—its reticulo-endothelial cells—are not present in the secondaries to take up the radiographically opaque thorotrast. Palpation of the lower surface of the liver may give a lumpy sensation.

In primary sarcoma, secondaries may be found in the lung, easily recognizable by radiographic examination.

In secondary sarcoma there is, too, the classical clinical picture—a patient who, about five years previously, has had an operation for removal of the eye, or for a small tumour somewhere on the surface of the body, and who has an enormously enlarged, nodular liver. This is, of course, secondary melanoma of the liver following primary melanoma of the retina or of the skin surface, in which the development of the secondary metastases in the liver has been slow.

HEPATOMEGALY OF SURGICAL IMPORT

The enlargements of the liver which are of surgical import are as follows: (1) Tropical abscess; (2) Enlargements of the liver associated with jaundice; (3) Solitary cyst of the liver; (4) Infective conditions; (5) Hydatid of the liver.

1. Tropical Abscess.—In regard to tropical abscess Choyce writes as follows:—

Tropical or dysenteric abscess generally results from infection by the *Amœba dysentericæ* (*Entamœba histolytica*). It may appear years after all dysenteric symptoms have disappeared, and long after the sufferer has left the tropics, and it may even occur in those who have never been abroad. Sometimes amœbic abscess arises in those in good health who have never shown any recognized signs or symptoms of dysentery. Probably these last cases are 'carriers', and as many as 33 per cent of the troops returning from Mesopotamia were found to be so. In about 70 per cent of cases the abscess is confined to the right lobe. Though usually spoken of as 'solitary', in about 30 per cent of cases there is more than one abscess.

Clinical Features.—Pain is a constant feature; it may be dull and over the liver region, or it may be referred to the acromion, the 'shoulder-tip' pain of the ancients. The temperature may be continuously elevated or regularly variable, simulating malaria; or it may show a 'spike' associated with a rigor; or it may be very little elevated, and in some chronic cases

may be normal or subnormal. The pulse rate is relatively slow, 100 to 110. Sweating is usually profuse, the skin yellowish and 'earthy', and wasting pronounced.

Loss of appetite, malaise, languor, and general debility are very marked features of the chronic cases. Leucocytosis is usually present, except in very chronic abscesses with thick walls.

Physical Signs.—The liver is enlarged, usually upwards, producing dullness almost as high as the scapular angle. The whole hepatic region is commonly slightly bulged and, later, tender on deep pressure. Radioscopic examination with the fluorescent screen is very helpful. It usually shows the upward enlargement of the liver and the limited excursion of the right half of the diaphragm.

TREATMENT.—The modern treatment of tropical abscess tends more towards conservatism, because prompt incision and drainage has been attended by a rather high mortality-rate. The patient is given emetine daily till his general condition improves. Attempts are made to localize the abscess by radiographic examination, or by exploration with a suitable needle. If the cavity is found, the contents of the abscess are aspirated, and it is partially filled with a solution of 1-1000 quinine or yatren. The abscess may be repeatedly aspirated. If the pus becomes secondarily infected, the abscess must be opened and drained. The drainage is very often best carried out through a very large specially constructed cannula, through which a tube can be inserted which fits accurately the hole made in the liver.

2. Enlargement with Jaundice.—Enlargement of the liver accompanied by deep jaundice may be the result of an impacted stone in the common duct causing complete obstruction. It may also be caused by a carcinomatous growth, either in the head of the pancreas or in the duct itself. In such cases, however, the enlargement of the liver is only a secondary consideration; it is the cause of the jaundice which is the primary interest.

Another very different type of enlargement of the liver associated with deep jaundice, which is confused with the above condition, is exemplified in the following case-record:—

A man, aged 67, developed over a period of three weeks a deep and permanent jaundice without any constitutional symptoms. His liver was enlarged and very hard. Operation disclosed an enlarged, very hard, nutmeg type of liver, which was similar in appearance to the type of liver found in the jaundice following excessive doses of arsenical preparations. No cause of the enlargement could be found. He had a toxic hepatitis.

TREATMENT.—The remedy for these conditions is the removal of the cause of the jaundice (*see* Chapter LVII).

3. Solitary Cyst of the Liver.—Solitary cyst of the liver is a rare condition, but it is important because, being of a cystic nature,

the enlarged liver to which it gives rise must be diagnosed from that caused by a hydatid.

Where heart failure occurs the solitary cyst may greatly enlarge, and the enlargement may be erroneously regarded as being entirely due to a circulatory disturbance. The importance of keeping in mind, in a case of hepatomegaly, not only the possibility of the presence of a solitary cyst of the liver, but also the changes which take place in such a cyst in the case of heart failure, is seen in the following case-history :—

A woman, aged 68, complained of shortness of breath, tightness of the chest, and some swelling round the ankles. Examination of her chest disclosed a dilated heart and also signs suggesting aortic regurgitation. Examination of her abdomen showed a large liver three finger-breadths below the costal margin. She had a blood-pressure of 260-140. The right side of the diaphragm was markedly elevated. Subsequent examination revealed an extremely large liver with rounded edge. The right thoracic parietes were quite obviously bulged. The hydatid complement-fixation test and the Casoni reaction were negative. The easily palpable liver felt cystic.

A diagnosis of a large hydatid cyst had been made. On close investigation of the history it was found that at one of her confinements many years previously her doctor remarked that she had a large liver. Five or six years later, another doctor who attended her also remarked that she had an enlarged liver. Furthermore, although the liver contained a cyst, it had not the tenseness of a hydatid cyst.

Because of the absence of tenseness, the absence of hydatid reactions, and the presence of a large liver over a period of ten or twelve years, a diagnosis was made of a solitary cyst of the liver, enlarging rather suddenly in the last few months as the result of heart failure—probably from increase of fluid content. Operation confirmed the diagnosis. The wall of the cyst was thin and smooth, and it held almost a gallon of old blood-stained fluid.

This case exemplifies very well the distinction between a large simple solitary cyst of the liver and a hydatid.

TREATMENT.—The treatment in the above case was as follows : The cyst was evacuated ; as much as possible of its wall was excised ; it was closed and the sutured part fixed close under the skin where it could be easily aspirated in the future.

4. Infective Conditions.—In enlargement of the liver resulting from infective conditions, such as pylephlebitis or portal pyæmia, the original infective cause is generally so obvious that no difficulty is experienced in making a correct diagnosis as to the cause of the liver condition. The infective condition, however, overshadows the liver enlargement. In this type of case there is a history of either a recent attack of acute appendicitis, or of some infective condition in the abdominal or the hæmorrhoidal area.

Nevertheless, there are cases of enlargement of the liver caused by chronic abscess of the liver, or by pylephlebitis, in which the enlargement dominates the clinical picture, and its infective cause is not at all obvious. Such a case is seen in the following illustrative case-history :—

A man, aged about 60, became ill with a continuous fever, the cause of which was not obvious. After a few weeks he started to develop rigors with a steeple-like rise of temperature up to 103–104°, followed by periods of remission. His liver became enlarged and diffusely tender. He became slightly jaundiced. I made a diagnosis of centrally situated suppurating hydatid, and explored the upper surface of his liver from the abdomen (by the method described on p. 647), when I found an abscess about the size of a small orange, but it contained no hydatid membrane. Examination of the liver did not reveal any other abscess cavity. His fever and rigors continued, and other liver abscesses developed. He died about four months after the beginning of his illness. A primary cause of the liver infection was never found.

5. Hydatid Disease.—This is considered at length below.

HEPATOMEGALY CAUSED BY HYDATID DISEASE

A hydatid cyst is the intermediate cystic stage of a tapeworm of the dog (*Tænia echinococcus*). The eggs of this worm are passed in the fæces of the dog, and reach the human stomach by the medium of uncooked food, such as salads, etc. The ovum develops into a small six-hooked (hexacanth) embryo, which enters the stomach wall and arrives at the liver through the portal vein.

In the liver, it develops into a cyst consisting of two layers. The outer one—the adventitia—is formed by a reactive type of fibrous tissue and derived from the liver itself. The inner one is provided by the hexacanth and consists of an inner granular layer and an outer hyaline layer. The cyst cavity contains clear fluid containing salt and a little protein. Buds may form on the granular layer, and form little vesicles which are called brood capsules. In the lining of these capsules small cellular buds may form, which quickly develop into the heads of future tapeworms. These are called scolices.

Following trauma, or some interference with the normal evolution of the parasites, daughter cysts may form. They have two layers and accumulate inside the main cyst—endogenous daughter cysts. These daughter cysts may extrude from the main cyst, and they are then called exogenous daughter cysts.

In the liver, a hydatid cyst can rupture into a large vein (rare), into the bile-ducts, the gall-bladder, the pleural cavity, or the abdominal cavity. Occasionally it ruptures into the organs in the vicinity of the liver, such as the stomach, duodenum, or kidney.

A hydatid cyst should never be 'needled' for exploratory purposes. The reason for this is that two catastrophes may occur: a large vein may rupture into the hydatid cavity; or acute anaphylactic shock may occur.

A rupture of a large vein may take place because, when the needle is inserted into the cyst and fluid drawn off, the cyst wall collapses. If there should be in the ectocyst in the wall of the cavity of the liver a large vein which has been the subject of pressure from the tense hydatid, the wall of this vessel will be thin and atrophic from the continuous pressure. When the tension in the hydatid is removed by aspiration, the unsupported thin venous wall may burst—and occasionally with fatal hæmorrhage.

Acute anaphylactic shock may be caused by needling in this way: The body has become sensitized to hydatid toxin as a result of repeated small leakages. When a needle is inserted into a hydatid cyst, although most of the fluid is aspirated, a certain amount may leak round the tube when the cyst collapses, and therefore become absorbed by the body tissues. This leakage results in acute anaphylactic shock.

In regard to this condition, it must be remembered that hydatid should only be operated on under general anæsthesia, because this type of anæsthetic (ether) obliterates anaphylactic shock.

A most common cause of hepatomegaly in Australia and New Zealand is hydatid cyst; indeed, an enlarged liver in a patient with good health is almost certain to be due to this cause.

Generally speaking, hydatid of the liver presents to the surgeon two sorts of problems, diagnostic and operative.

Diagnostic Problems.—A hydatid of the upper surface of the liver may merge into the base of the lung, and be difficult to distinguish from a hydatid or other affection of the base of the lung.

Hydatid in the centre of the liver may enter the ducts and give rise to signs and symptoms indistinguishable from those of gall-stones in the common duct.

A small suppurating hydatid in the vicinity of the gall-bladder may give the symptoms and signs of empyema of the gall-bladder, and be difficult to diagnose from such a condition.

Suppurating hydatid may be difficult to distinguish from other infective liver conditions.

Operative Problems.—Operative problems are nearly always a question of approach. The route of approach depends upon the exact situation of the cyst in the liver, the determination of which may present a problem of some difficulty.

A cyst situated low on the posterior surface of the liver may have to be approached and drained by resection of the 10th rib posteriorly.

A cyst situated on the upper surface of the liver may be approached anteriorly through the abdomen (*see* p. 647), or through the ribs posteriorly. In the case of such a cyst, if it is approached anteriorly, it may be found that its lowest part lies posteriorly, when it may be necessary to drain it through the ribs posteriorly by a counter-incision. If it must be approached posteriorly through the ribs, it is difficult to avoid infecting the pleural cavity.

Other operative problems comprise the management of a hydatid which opens into the thorax; of a suppurating hydatid; and of a rupture of a hydatid into the peritoneal cavity and the associated anaphylactic shock.

General Characteristics of Hydatid of the Liver.—Hydatid finds its most frequent situation in the liver, where it grows towards the serous surfaces: that is, towards the upper, lower, or posterior surface.

A striking characteristic of hydatid of the liver is its latency—cysts may be present for years without giving any symptoms.

Pressure effects are rare even in the case of large cysts, although ascites and enlargement of the abdominal thoracic veins have been recorded.

The extreme tension of the hydatid cyst is also a striking feature, and distinguishes it from simple cyst of the liver. An enlarged liver in children is nearly always due to hydatid, because other causes of hepatomegaly are rare in childhood.

Most cysts of the liver are multivesicular.

Suppuration in hydatid of the liver, the result of the entry of bile into the cyst, occurs very readily. In some cases it may not give rise to noticeable symptoms of sepsis, the only symptoms being those of general ill-health. This is owing to the fact that the infection usually is mild; and for this reason hydatid cysts are, at operation, unexpectedly found to be suppurating. The suppurating hydatid usually gives rise to a *mild jaundice*, and this symptom, taken in conjunction with the symptoms of an infection and the signs of some tenderness over the region of the liver, frequently gives rise to a clinical picture which is confused with that of a cholecystitis or a cholangitis arising from gall-stones.

Hydatid cysts sometimes rupture into the larger bile-ducts, and the more centrally situated the hydatid, the more liable it is to rupture into these ducts. When such rupture occurs *severe*,

jaundice, somewhat similar to that caused by a gall-stone in the common duct, is seen. The jaundice is of a yellowish type, is accompanied by colicky pain and intermittent fever, and is thus similar in manifestations to that caused by a 'ball-valve' calculous obstruction in the common duct. This severe type of jaundice caused by

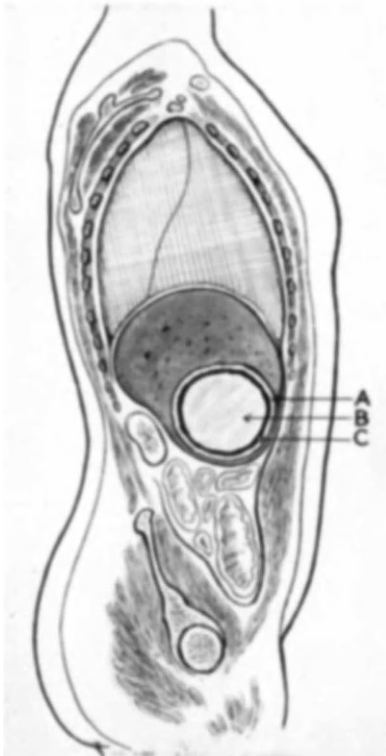


Fig. 510.—Simple hydatid cyst bulging into abdominal cavity from the lower surface of the right lobe of the liver. A, Adventitia; B, Hydatid fluid; C, Hydatid cyst wall.

hydatid cysts rupturing into the bile-ducts must be distinguished from that caused by a suppurating hydatid, in which the jaundice is only slight and the result of an infection of the smaller bile-ducts.

Occasionally a hydatid may rupture into the peritoneal cavity. In one case in which this occurred, the patient came into hospital with symptoms of great pain in the right upper part of his abdomen; with the symptoms of shock—an ashen-grey appearance, pulse of 130, and sweating; with an extensive urticaria; but with no fever. As he had had previous symptoms indicative of gastric ulcer, his condition was thought to be due to the perforation of a gastric ulcer. It was, however, found at operation that it was the result of a rupture of a hydatid cyst of the liver into the peritoneal cavity, and that his collapsed condition was the result of anaphylactic shock.

As most hydatid cysts of the liver come to its surface, the superficial part of the liver capsule investing the hydatid cyst is thin and collapsible. The more there is of this thin and collapsible capsule, the quicker the hydatid cavity will close when the cyst is removed. The greater part of the capsule, however, is made up of solid, uncollapsible liver substance, and the more centrally the hydatid cyst is situated, and consequently surrounded by rigid walls of liver tissue, the longer time it takes to close after the cyst is removed.

When hydatid of the upper surface of the liver has been present for a considerable time, it sometimes opens into the lung, penetrates

the bronchus, and hydatid daughter cysts—stained in most cases with bile—are coughed up. Such a happening is, however, an unusual occurrence.

Hydatid of the Lower Surface of the Right Lobe of the Liver.—The simplest form of hydatid is the cyst which occurs on the lower surface of the liver, and bulges downwards into the abdominal cavity (*Fig. 510*). As a rule, a cyst in this position is found as a tense, globular, painless, insensitive swelling—obviously a hydatid, and, characteristically, such a cyst does not give rise to symptoms.

Hydatid of the lower surface of the right lobe must be distinguished from the downward displacement of the liver caused by a hydatid of the upper part of this lobe. Such a distinction in regard

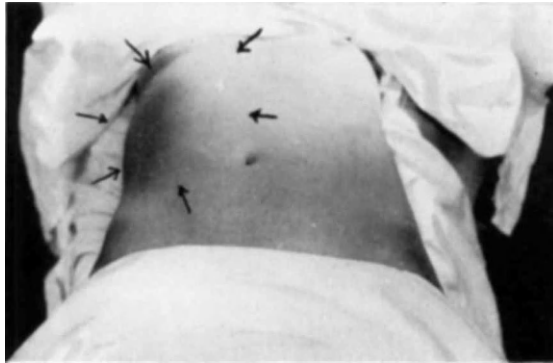

Fig. 511.—Bulging of the right side of the chest caused by hydatid of the right lobe of the liver.

to the exact position of a hydatid in the right lobe is very necessary, for on this position will depend the decision whether the operative approach shall be to the upper or to the lower surface of the liver—an important practical point.

Hydatid in the lower part of the right lobe of the liver may bulge the lower and right part of the chest, causing widening of the intercostal spaces and of the epigastric angle (*Fig. 511*).

Hydatid Occupying the Whole of the Right Side of the Liver.—A hydatid may occupy the whole of the right lobe of the liver. In these cases the left lobe of the liver hypertrophies, becomes nearly as big as the right, and may be operatively approached under the impression that it is the hydatid (*Fig. 512*).

Where a hydatid of this type, that is, one which takes up the right lobe, is operated on and cured, or where, as happened in the

early days of hydatid surgery, the hydatid cyst has been aspirated, the right lobe of the liver shrinks almost on to the diaphragm. When this occurs, it takes with it the gall-bladder. Should a patient with such a condition develop gall-stones, the operation of cholecystectomy then required becomes extremely difficult, because the gall-bladder lies almost on the diaphragm (*Fig. 513*).

Hydatid of the Posterior Surface of the Liver.—The surgical importance of hydatid cyst on the posterior surface of the liver is that a cyst in this position can only be approached from the posterior

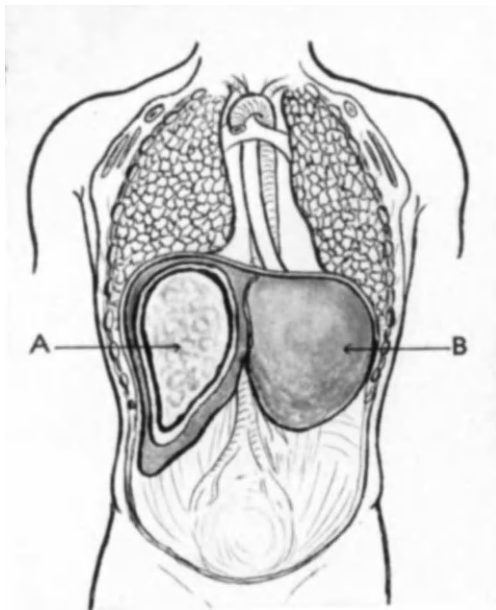


Fig. 512.—A, Hydatid occupying the whole of the right lobe of the liver; B, Hypertrophied left lobe.

aspect. It cannot be approached from the abdomen by the author's method to be described later, as can a hydatid of the upper surface. It must be approached by resection of the 9th or 10th rib posteriorly. *Fig. 514* shows diagrammatically the position of such a cyst, its drainage being illustrated in the inset.

Centrally Situated Hydatid of the Liver.—A centrally situated hydatid of the liver is not only one of the most difficult types to diagnose, but is also one of the most difficult upon which to operate. The nearer the hydatid is to the centre of the liver, the more liable it is to open into the larger bile-ducts. It would seem as if there

was so much solid liver tissue round the hydatid that, as it grows, it naturally must cut into some of the centrally placed and larger ducts.

Central hydatid of the liver may give rise to curious clinical pictures, in regard to which many mistakes may be made. Thus it can bring about four characteristic syndromes :—

1. *Uniform Enlargement of the Liver.*—A uniform enlargement, the cause of which is not obvious because the hydatid is centrally situated and hidden.

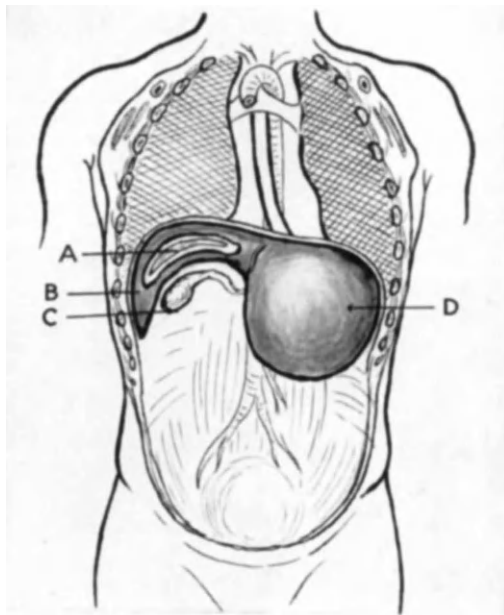


Fig. 513.—A, Remains of hydatid cyst ; B, Atrophied right lobe of liver ; C, Gall-bladder lying almost on the diaphragm ; D, Hypertrophied left lobe.

2. *The Syndrome of a Stone in the Common Duct.*—An intermittent jaundice and fever, associated with rigors and colicky pains, brought about by daughter cysts entering and passing down the large bile-ducts ; that is, a clinical picture similar to that of a 'ball-valve' stone in the common duct.

3. *The Characteristic Symptoms of Liver Sepsis.*—Symptoms such as could be given by single or multiple abscess of the liver.

4. *A Syndrome Similar to that of Cholelithiasis.*—Pain and tenderness over the gall-bladder, which is accompanied by a mild jaundice.

CLINICAL EXAMPLES OF THESE SYNDROMES.—

1. *Enlargement of the Liver without the Hydatid being Obvious.*—

A patient was operated on for a very enlarged and irregularly shaped liver, which was thoroughly explored with an aspirating needle, when no sign of a hydatid could be found. As the liver was rather irregularly nodular, and the nodules were large, an operation diagnosis of primary sarcoma of the liver was made. The patient died. At the post-mortem a hydatid, deeply situated in the liver and in the vicinity of the large branches of the portal vein, was found. The enlargement appeared to be due, not only to the presence of the hydatid, but also to its pressure on the large branches of the portal vein, causing a general, firm, congestive, irregular enlargement of the liver.

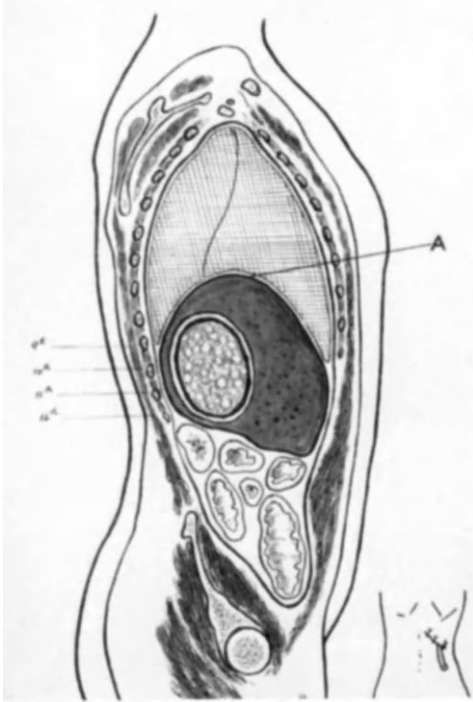


Fig. 514.—Hydatid cyst of the posterior surface of the liver. A, Diaphragm. Inset: Incision and drainage tube.

2. *The Syndrome of Stone in the Common Duct.*

—The following case-history is that of a patient who was operated on in the belief that he was suffering from the effects of a stone in the common duct:—

A male patient, fourteen years previous to his admission to hospital, had complained of severe pains across the upper part of the abdomen, had been diagnosed as suffering from gall-stones, and had been operated on, his gall-bladder being drained.

After the operation he was well for five or six years, when he began to suffer from severe epigastric pains, which made him double up and roll about, and from rigors associated with vomiting and sweating. He was again operated upon, and his gall-bladder was removed on the assumption that it was the subject of a cholecystitis. It was thought that the gall-bladder was diseased, and that its condition was responsible for the patient's symptoms.

The patient was then well for some weeks after the operation, when he again developed moderately severe epigastric pain coming on three hours after meals; he also became intermittently jaundiced and feverish. His condition was now diagnosed as that caused by a stone in the common duct.

Operation disclosed a central hydatid of the liver, with daughter cysts in the common duct.

It is almost certain that the symptoms which led to all his operations were caused by the central hydatid of the liver, which was not obvious in, perhaps, a cursory examination of the liver made at the time of the operations.

3. *The Characteristic Symptoms of Liver Sepsis.*—I have seen cases where a central hydatid gave symptoms characteristic of an abscess of the liver. There was high, steeple-like rise of temperature with sharp remissions, and other symptoms of an infection—all lasting over a period of two or three months, and sometimes with very few hepatic signs to indicate that the liver was the seat of the septic focus.

4. *The Syndrome of Cholelithiasis.*—

A theatre sister complained of 'attacks' of epigastric pain, accompanied by vomiting, slight jaundice, and a mild fever (temperature 100°). These attacks lasted a few days. Her pain was bad enough to require morphia for its relief. A diagnosis of cholelithiasis was made. At operation, although no gall-stones were found, her gall-bladder was removed in the belief that it was the subject of chronic cholecystitis.

A few months later she developed the same symptoms, except that the attacks of pain lasted longer, and that she was tender in the region of the epigastrium. The radiograph of her liver showed an elevation on its upper surface, indicating the presence of a hydatid. A second operation disclosed a suppurating hydatid with small daughter cysts, burrowing well down into the centre of the liver, opening into the bile-ducts, and passing down the common duct.

Central Hydatid Undiagnosed.—The tragedy of a misdiagnosis in regard to a central hydatid of the liver is shown in the following case :—

A middle-aged man became ill, with clinical manifestations which were regarded by the attending physician as those of cholelithiasis. He was operated upon, and his gall-bladder was found to be full of small hydatid cysts. Under the false impression that this was a case of hydatid of the gall-bladder, the surgeon removed this organ and its contained hydatid cysts. Following the operation, a discharging sinus persisted for months.

The patient sought further advice, with a view to getting relief from this persistent sinus. His doctor was advised that the hydatid cysts which had been present in the gall-bladder had really come from a central hydatid cyst of the liver. The radiograph (*Fig. 515*), which shows lipiodol injected through the sinus into the central cavity in the liver, was adduced as proof of this, but nothing further was done.

Some years afterwards, the patient was admitted to hospital under the care of another surgeon. He was then suffering from a deep jaundice, and was very ill. He said nothing about his previous examination. The

operating surgeon, after a great deal of dissection, found the common duct and removed some hydatids, but could not find the central cavity in the liver from which they originated.

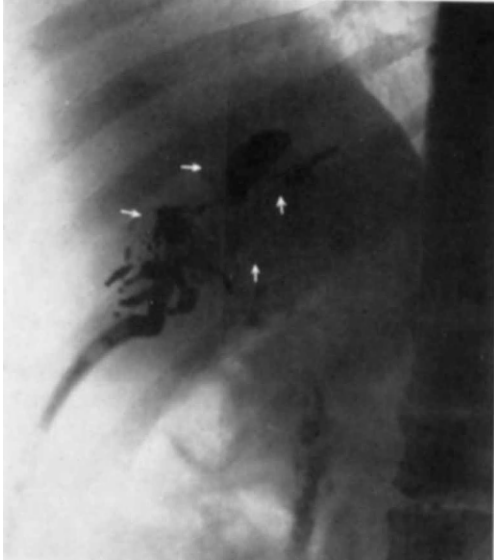

Fig. 515.—Lipiodol-filled central hydatid cavity (indicated by arrows) in the liver.

of epigastric pain, with which was associated an intermittent fever and a slight jaundice. Her liver was found to be enlarged, but *was not tender*. She was tender over the epigastrium. She had a history of having had hydatids of the peritoneal cavity.

Operation disclosed a large liver of normal colour, and a very dilated common duct containing hydatid membrane and a number of gall-stones. The gall-bladder contained no gall-stones. An old scar (Fig. 516, A) was found where a hydatid had previously been removed, and when this was incised an old hydatid cavity with detritus was found.

Central Hydatid Associated with Hepatitis.—

A female patient, aged 57, was operated on because she

The patient recovered, but some months later again became deeply jaundiced and very sick. He was again operated on, and this time he died, without the cavity in the liver from which the hydatids originated being found; when all the time, if the patient had been candid, the exact diagnosis of the situation of the cavity of the hydatid was on record—information which would have enabled the operating surgeon to have found the hydatid without approaching the common duct.

Central Hydatid Combined with Stones in the Common Duct.—

A woman, aged 45, began to suffer from attacks

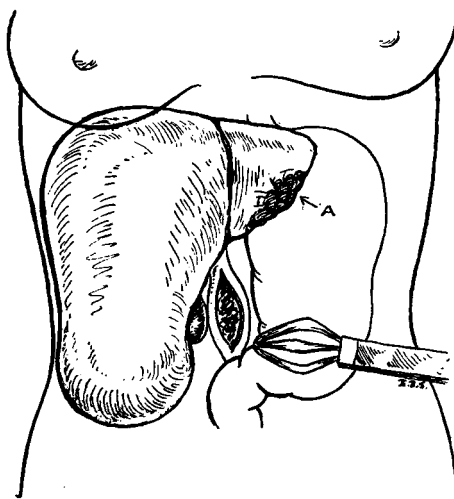


Fig. 516.—Common duct containing hydatid membrane and gall-stones. No gall-stones in gall-bladder. The diagram shows also the enlarged right lobe of the liver. A, Scar of previous operation.

had the symptoms of gall-stones—epigastric pain of a colicky nature, slight jaundice, mild constitutional signs, and a tender spot to the right of the epigastrium. At the operation gall-stones were found, and a hydatid in the left lobe of the liver was also seen and removed.

She was then well for some years, when she again suffered from attacks of epigastric pain, associated with mild jaundice and with a fever which ranged from a temperature of 99° to 100° . The pain was of a more or less constant nature, and was not colicky. She gradually became very sick, and for a fortnight developed an intense diarrhœa and a general tenderness over the abdomen. Finally this tenderness became localized to the liver, which became diffusely tender.

A radiograph showed a hydatid of the upper surface of the liver, with calcified walls, extending towards the centre of the liver (*Fig. 517*).

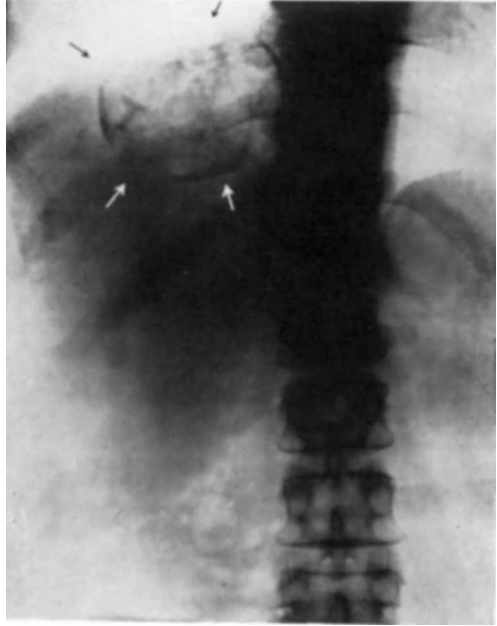


Fig. 517.—Radiograph showing calcified hydatid of the upper surface of the liver.

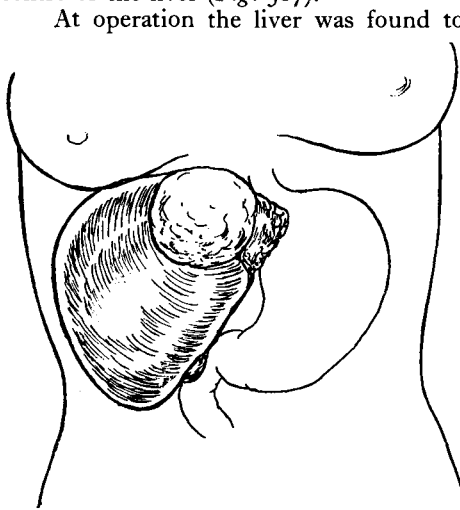


Fig. 518.—Operation sketch showing old hydatid associated with high-grade hepatitis. The liver was almost round in shape.

At operation the liver was found to be small and almost completely round, just like a football. It had no sharp edges. It was "as hard at a board", and of a high grade of nutmeg type. The left lobe was almost completely atrophied as the result of the previous hydatid which had been removed. On the upper surface of the liver was a fairly large hydatid with calcified walls, as shown in the diagram (*Fig. 518*). The common duct was not dilated, and did not appear to contain any hydatid cyst. The liver was of the same type as is frequently seen in cases of jaundice following the administration of arsenical preparations—like an acute toxic hepatitis

The hydatid was opened with great difficulty, by the method illustrated in *Fig. 528*, p. 648. It was full of detritus, granular material, and pus; its walls were calcified. Drainage tubes were inserted. The cavity was washed out, but there was no drainage of bile. The patient remained very ill.

The cavity was now frequently washed out with hydrochloric acid, and 'vacuum-cleaned' with a suction apparatus. A large amount of granular material and detritus was gradually aspirated through the suction tube, and the calcareous wall, as shown by X rays, began to disappear as the result of the use of the acid. Finally, five weeks after the operation, the cavity began to discharge bile. From this time on, the patient gradually improved, lost the liver tenderness, and began to eat well. She recovered.

Obviously this was a case of hepatitis arising from an infection of most of the ducts, as the result of becoming choked with detritus and infected from the old degenerating and suppurating hydatid.

Hydatid of the Left Lobe of the Liver.—Hydatid of the left lobe of the liver (*Fig. 519*) presents no special difficulties in regard

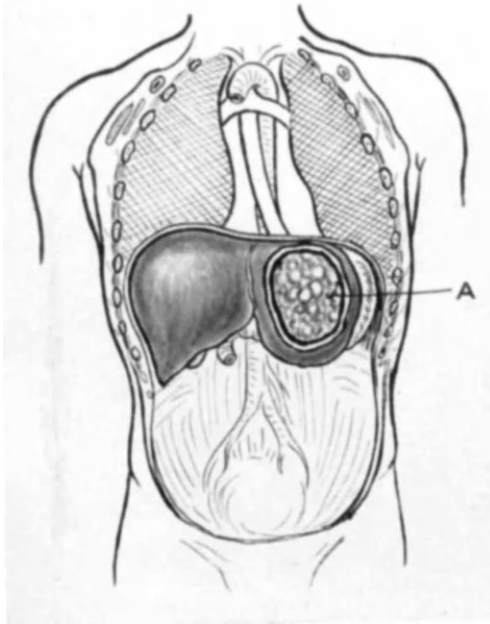


Fig. 519.—A, Hydatid of the left lobe of the liver.

to operation, because it lies freely exposed in the left upper quadrant of the abdomen, and is easily accessible by an approach through the upper and left part of the abdominal wall.

When the hydatid cyst in the left lobe extends downwards and backwards, it presses on the stomach and gives rise to a form of dyspepsia only experienced on taking full meals (a filling dyspepsia). The dyspeptic symptoms disappear as the stomach empties; and they do not occur if only small quantities of food are taken at a time.

Apart from radiological and serum tests, hydatid in this situation is distinguished from other tumours—gastric and the like—which may occur in this neighbourhood by the fact that although it is a large tumour, it will have produced practically no pressure effects; and this happens notwithstanding the fact that it is situated in a

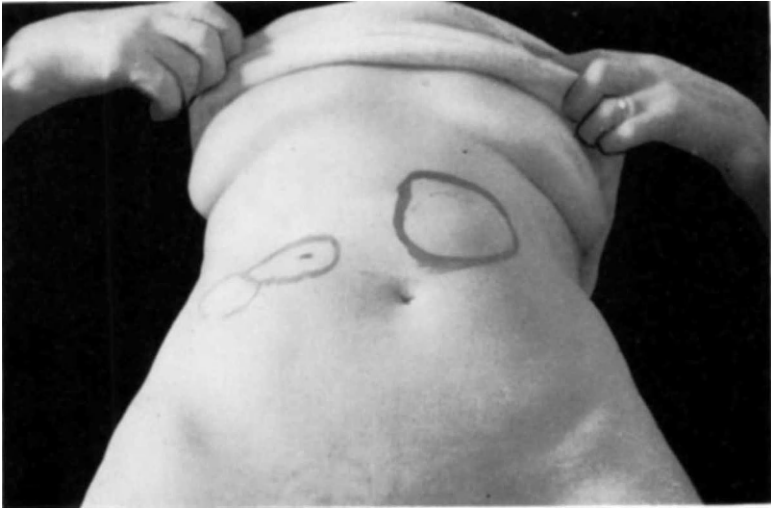

Fig. 520.—Photograph of the abdomen of a patient who had hydatid of the left lobe of the liver. The circles indicate tumours.

region where many vital organs are grouped. It is also characterized by the fact that although it is a large tumour it has not affected the patient's health, even over a period of years. *Fig. 520* is a photograph of the abdomen of a patient who had a hydatid of the left lobe of the liver, extending downwards and to the right side.

Hydatid of the left lobe of the liver is also of surgical diagnostic interest by reason of the fact that sometimes a natural cure takes place, leaving a hard, irregular, nodular tumour. Such a tumour, which lies in the region of the lesser curvature of the stomach, may remain unnoticed for years because it gives rise to no symptoms. If felt when the patient presents himself or herself for examination, perhaps suffering from some general symptoms of ill-health, the feel of such a tumour—so like a carcinoma—naturally leads to a diagnosis

of carcinoma of the stomach. The likeness to a gastric carcinoma is still greater if the radiologist describes a 'filling defect' of the stomach, for these old hydatid tumours can cause filling defects from external gastric pressure.

Such a case occurred in my own practice, and even at the exploratory operation I was in doubt for a time whether this hard, cartilaginous irregular tumour of the left lobe of the liver was a secondary malignant tumour or an old retrogressed hydatid (*Fig. 521*).

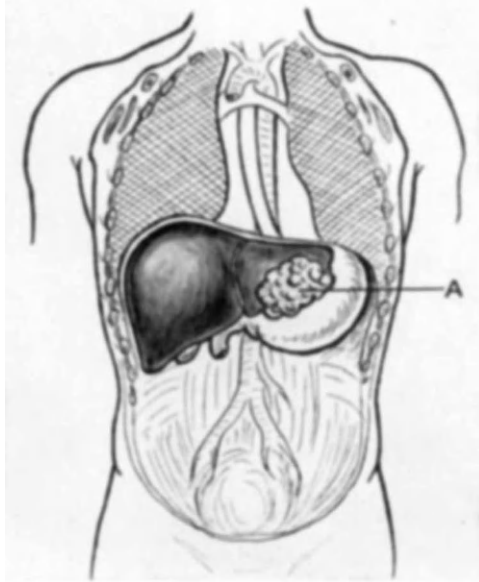


Fig. 521.—A, Retrogressed hydatid of the left lobe of the liver, lying over the lesser curvature of the stomach and simulating carcinoma.

Hydatid in the Vicinity of the Gall-bladder.—One of the chief interests which attaches to a hydatid in the vicinity of the gall-bladder is that, if mildly suppurating as such a hydatid in this exposed position often is, it is mistaken for an inflamed gall-bladder. The operation sketch in *Fig. 522* shows the shape and position of a small suppurating hydatid which, in a young man aged 27, was diagnosed as an inflamed gall-bladder.

Sometimes when a hydatid lying close to the gall-bladder suppurates, it opens into the gall-bladder, and then symptoms arise which are really due to an empyema of the gall-bladder; symptoms, of course, that are indistinguishable from those arising from empyema of the gall-bladder resulting from cholelithiasis.

The following case-history illustrates such a condition:—

The patient presented all the symptoms of gall-stones, and the gall-bladder appeared to be enlarged and tender. At the operation it was seen that there was an inflammatory mass in the situation of the gall-bladder. This mass looked like an empyema of the gall-bladder, except that it was a little too medially situated. Gall-stones were present in the gall-bladder, which formed part of the inflammatory mass. The cystic duct

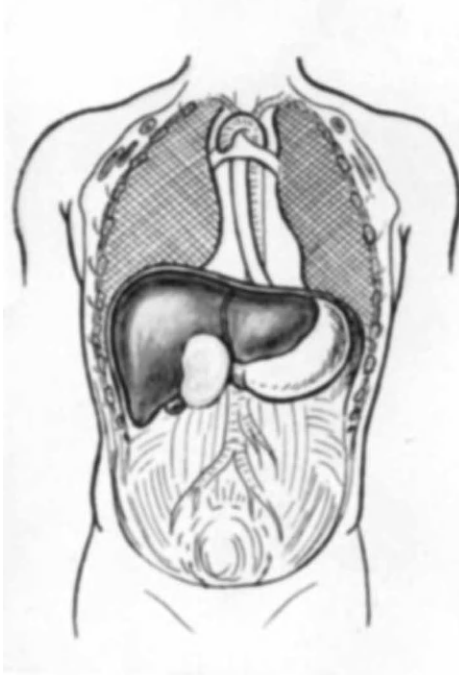


Fig. 522.—Diagrammatic sketch showing the shape and size of a small suppurating hydatid cyst lying close to the gall-bladder which was mistaken for empyema of the gall-bladder.

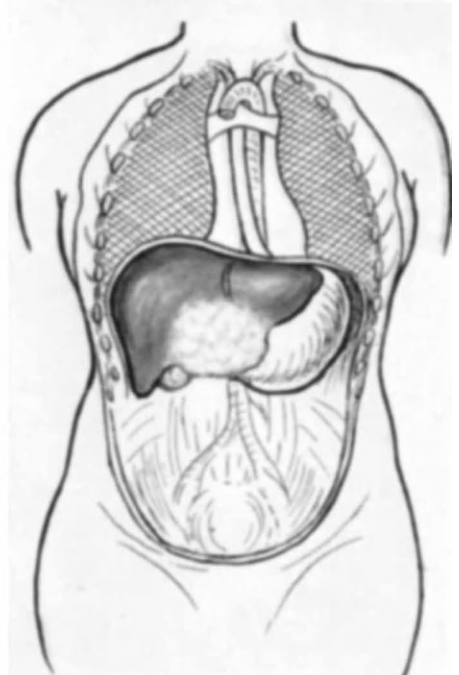


Fig. 523.—Suppurating hydatid lying close to the gall-bladder and opening into it, giving rise to the symptoms of gall-stones.

and artery were divided, and as the gall-bladder was removed it was seen that it communicated with another sac which, as well as the gall-bladder, was full of pus. Finally it was found that the main part of the mass was a suppurating hydatid which, lying close by, had opened into the gall-bladder. *Fig. 523* is an operation sketch to show the condition which was found.

Hydatid of the Portal Fissure.—Hydatid of the portal fissure is rare. Its clinical importance lies in the fact that it can press on the hepatic ducts and cause a jaundice which is unremitting,

painless, feverless, and of a green type—a jaundice indistinguishable from that produced by carcinoma of the common duct or by carcinoma of the head of the pancreas.

In surgery in Australia and New Zealand, therefore, the possibility of a hydatid of the portal fissure must never be omitted from the surgeon's thoughts when making a diagnosis in the case of a jaundice of suspected malignant origin; for jaundice arising from this cause is curable, while that from malignant disease of the pancreas is incurable.

Hydatid of the Anterior Surface of the Liver.—Hydatid in this situation usually presents no difficulty in diagnosis, and does not offer any operative problem, for not only can it be approached, but it can also be drained, from the anterior abdominal wall. Occasionally, however, it may be necessary to make a counter-opening posteriorly, so as to drain the most dependent part of the cyst. (See Figs. 529, 530.)

Hydatid of the Upper Surface of the Liver.—Hydatid cyst of the upper surface of the liver presents problems in diagnosis and also in surgical treatment.

The problems in diagnosis arise from the fact that being situated close under the diaphragm and bulging into the lower lobe of the lung, hydatid of the upper surface of the liver causes dullness and loss of vocal resonance over the position of the lower lobe of the lung. Thus it is liable to be confused with affections of the lung. Moreover, the diaphragmatic pleuritis which it sometimes causes, gives rise to persistent cough and a friction-rub and pain—all of which are also manifestations of an early tuberculous pulmonary condition. And further, a pleurisy with effusion which may arise from spoiling of the pleura by a subdiaphragmatic hydatid may be mistaken for the effusion caused by tuberculous pleuritis.

In hydatid cyst of the upper surface of the liver, it is important to try to make a diagnosis of the direction in which it spreads: whether forward or backward. This knowledge is necessary in order to determine whether the *operative approach* should be from the front or from the back. It is further necessary from the point of view of *efficient drainage*, in order to decide whether to drain it from the front or from the back; that is, whether the most dependent part of the cyst is situated more towards the front or the back of the liver.

Rupture through the Diaphragm but not the Pleura.—Hydatid of the upper surface of the liver may perforate the diaphragm and push the parietal pleura covering the diaphragm in front of it, as is

diagrammatically shown in *Fig. 526*. The condition is illustrated in the following case-history :—

A patient was found to have an enlarged liver, which extended four finger-breadths below his costal margin, but otherwise he was in fair health. *Fig. 524*, the radiograph of the case, shows an unusual-shaped shadow projecting into the base of the lung.

Feeling that this was a hydatid of the lower lobe of the lung, the surgeon opened the pleural cavity, but could sweep his hand round the whole of the lower part of the cavity without finding any evidence of hydatid. At a second operation the hydatid was approached from the abdominal cavity

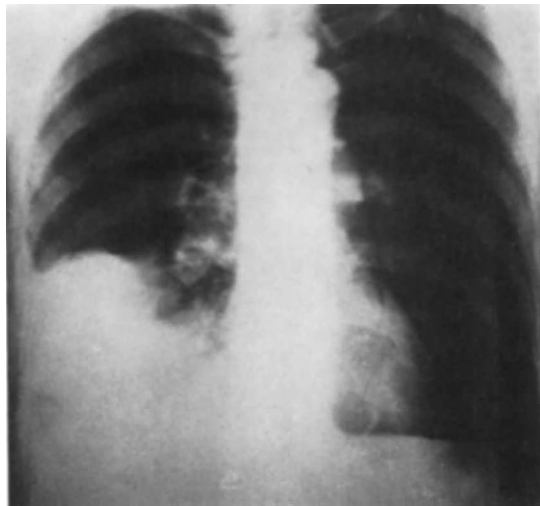


Fig. 524.—Radiograph showing projection of diaphragmatic pleura caused by hydatid of upper surface of liver.

the round ligaments of the liver were divided, the lower margin of the thorax was elevated, and the liver depressed (*see Fig. 528*).

When the contents of the hydatid were evacuated, a large hole could be felt in the diaphragm. This opening communicated with a smoothly covered diverticulum into the thoracic cavity, that is, into a cavity made by the parietal pleura, which had been pushed off the upper surface of the diaphragm. *Fig. 525* is a lateral radiograph of the condition, which is also illustrated diagrammatically in *Fig. 526*.

The *radiographic diagnosis* of hydatid of the upper surface of the liver is often difficult. In some cases of hydatid in this situation, a pleural effusion arises as the result of toxic spoiling of the parietal pleura, and this effusion disguises the characteristic radiographic appearance of hydatid in this position. Sometimes, however, if a little air is injected into the abdominal cavity, it

will enable the diaphragm to be more clearly defined by radiographic examination.

Rupture into Pleural Cavity.—Hydatids of the upper surface of the liver may open through the diaphragm, the diaphragmatic pleura, and into the pleural cavity, and the right pleural cavity may become filled with daughter cysts, the lung being collapsed into a small lump the size of a fist on the spinal column. Such a condition is shown in the following case-history :—

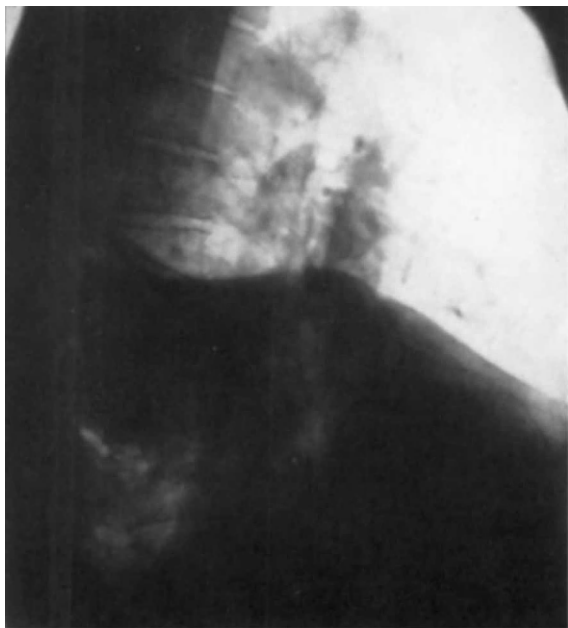

Fig. 525.—Lateral radiograph in same case as *Fig. 524*. Note the lung tissue lying below the shadow caused by the hydatid, which extends into the base of the lung.

The patient, a woman aged 50, had been operated on eight years previously for a ruptured gall-bladder and for a choleperitoneum. The gall-bladder was removed and contained one small stone. The common duct was not explored.

Four years after this the patient began to suffer from pains similar to those which she had had before the operation. These pains occurred at frequent intervals, beginning in the right hypochondrium and radiating to the right shoulder-blade, and were colicky in nature, but not accompanied by vomiting.

Three weeks before admission to hospital the patient developed one of her usual attacks. She lost her appetite, her stools became clay-coloured, and her urine dark, and she noticed that she was jaundiced. She had

shivers and sweats before her attacks of pain came on. On examination, the whole of her right chest did not move with respiration, and was dull from the clavicle in front and midscapular region behind, while the apex beat was $6\frac{1}{2}$ in. from the midline. The liver was enlarged and tender. Clear fluid was aspirated from the chest, and pus from the subphrenic region.

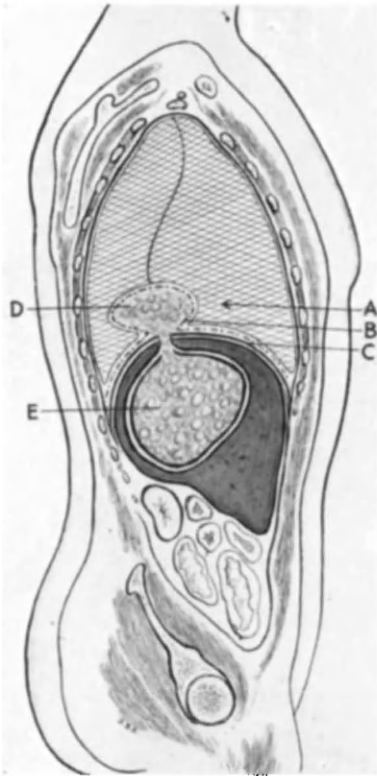


Fig. 526.—Sagittal section showing diagrammatically what was found in the case shown in *Figs. 524, 525*. A, Lung; B, Pleura; C, Diaphragm; D, Hydatid pushing the diaphragmatic pleura in front of it; E, Hydatid in the liver.

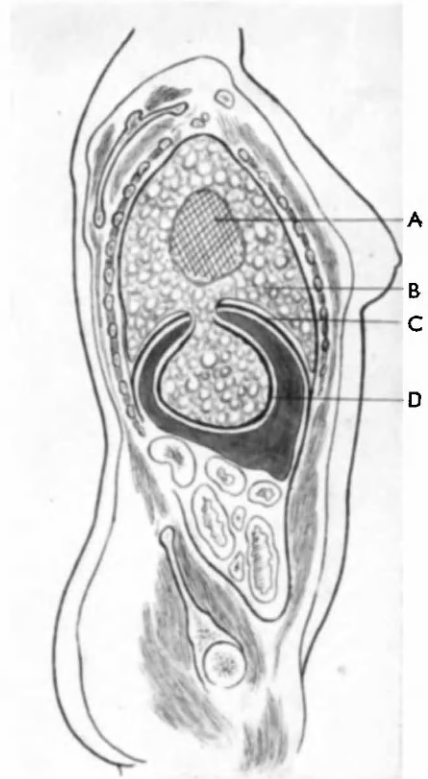


Fig. 527.—Sectional diagrammatic representation of a hydatid of the liver opening into the pleural cavity. A, Lung contracted down to middle line; B, Pleura full of hydatids; C, Diaphragm; D, Endocyst of hydatid.

At operation it was found that this patient had a hydatid of the upper surface of the right lobe of the liver with a subphrenic abscess; that daughter cysts had opened through the diaphragm and into the pleural cavity; and that the pleural cavity was full of hydatid cysts. *Fig. 527* represents the condition diagrammatically.

A hydatid of the liver breaking into the pleura may cause symptoms and signs like those of a pneumonia; indeed may lead

to the treatment of the condition as a pneumonia. The following case is an example of such a mistake :—

A middle-aged man began to suffer from what he thought were influenzal joint pains. Some days later he got a rigor, his temperature rose to 105° , and he became short of breath. He was examined by a doctor, who found tubular breathing all over the right lung—particularly its base—but no adventitious signs. He had a slight cough but no rusty sputum. He complained bitterly of a pain in the right shoulder. His temperature ranged from 101° to 102° .

About the seventh day of his illness it was noticed that he had a tumour on the right side continuous with the liver. This tumour was not tender, moved with respiration, and extended for more than a hand's breadth and a half below the ribs. The patient looked dusky and his apex beat was down one interspace and about an inch and a half more lateral than it should have been. He was 'flat dull' over the whole right part of his chest, and he had tubular breathing over the whole of the right lung. He was being treated as a case of pneumonia.

He had had an old hydatid of the liver which had been operated on.

A needle was inserted in the chest and fluid aspirated. As the fluid was drawn off, the lump in the right side gradually disappeared. Obviously this was the right-lobe of the liver pushed down from the pressure of the accumulation of fluid in the pleura. Examination showed that the fluid was from a hydatid and that it contained pus and daughter cysts.

Rupture into a Bronchus.—A hydatid of the upper surface of the liver may occasionally rupture into a bronchus. In this case the daughter cysts and fluid are usually stained with bile, a characteristic which marks it as a hydatid of the liver and not of the lung.

The surgical approach to hydatid of the upper surface of the liver is described below.

Hydatid of the Liver Opening into the Kidney.—Very occasionally a hydatid of the liver lying over the upper pole of the kidney will open into this organ, and eventually into the pelvis of the kidney. The presence of hydatid will then become apparent by the passage of daughter cysts through the pelvis of the kidney and down the ureter. The passage of these cysts may cause renal colic indistinguishable from that caused by a stone. Secondary infection usually occurs, and finally the kidney must be removed, when the hydatid in the liver may be dealt with.

In one case the patient's attention was drawn to the fact that he was passing small 'grape-skins' with his urine. Subsequently suppuration took place, pyuria occurred, and it became necessary to remove the kidney. When removing the kidney (from the abdomen) it was found that the wall of the duodenum was involved in the calcified wall of the hydatid, and part of the posterior duodenal wall had to be removed. The hydatid of the liver was dealt with, the

opening in the duodenal wall closed, and reinforced by the omentum. Fifteen years later the patient was still alive, and had no further recurrence of the hydatid.

OPERATION FOR HYDATID CYST OF THE UPPER PART OF THE RIGHT LOBE OF THE LIVER

The usual operative approach for the exposure of a hydatid cyst (or abscess) of the upper part of the right lobe of the liver is through the lower part of the thorax posteriorly, the 9th rib being resected, and the parietal and diaphragm pleura being closed off by sutures. It may be possible to push up the costo-diaphragmatic pleural reflection so as to avoid opening the pleural cavity.

The exposure of the cyst, however, through this region is very limited. Furthermore, on account of this cramped exposure the cavity of the hydatid cannot be explored, and the most dependent part of the abscess or cyst, a knowledge of which is necessary in order to institute proper drainage, cannot readily be found. In addition, where the pleura is divided, infection of the pleural cavity may occur through the cutting out of the sutures closing off the diaphragmatic and parietal pleura.

An alternative method, and one which I have found to give a much better operative approach, is to expose the upper surface of the liver from the abdominal cavity. This method has been made possible by the use of the author's operating frame, which, locked tightly into the wound, can be used to lift the thoracic wall away from the upper surface of the liver, and thus make a space between the surface of the liver and the anterior thoracic wall. In this way the under surface of the right side of the diaphragm can easily be exposed. The method is as follows:—

A paramedian incision may be employed—one made from the epigastric notch along the ribs for $1\frac{1}{2}$ in., and then downwards paramedially through the median edge of the rectus, the same as for the exposure of the gall-bladder (*see* p. 702); or the costal incision may be used (*see* p. 524).

The operating frame is inserted and ratcheted firmly into position, so that it tightly grips the abdominal and chest wall. The assistant gently lifts the frame and with it the chest wall. The falciform and coronary ligaments which hold the liver on the anterior abdominal wall are divided. As the thoracic wall is lifted by the assistant, the liver is pressed downward by the hand of the surgeon, a large space being thus made between the upper surface of the liver and the chest wall (*Fig.* 528).

The hydatid, which generally can be seen coming to the surface somewhere on the upper surface of the liver, is injected with 5 to 10 c.c. of formalin and then aspirated. The removal of fluid from the liver by aspiration leaves a still bigger space between the under surface of the diaphragm and the upper surface of the liver, and renders the approach to this surface quite easy, even permitting the exposure of the upper part of the posterior surface.

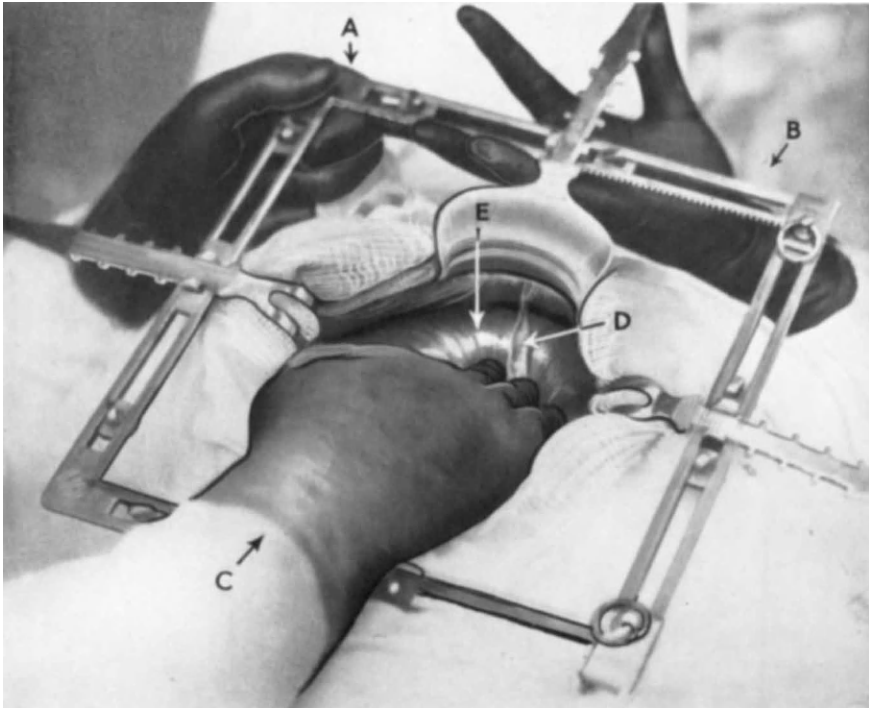


Fig. 528.—Showing approach to a hydatid of the upper surface of the liver. The upper end of the operating frame is elevated at A-B and with it the thoracic wall; C, Liver pressed down by the surgeon's hand; D, Ligament of the liver divided; E, Upper surface of the liver where the hydatid is situated.

The hydatid cyst is now opened and its contents removed. As it empties and the hydatid cavity collapses, the space between the upper surface of the liver and the diaphragm will become still larger.

When the hydatid is opened, it will be found that part of the upper surface of the liver, which covers the cyst, is composed of fibrous tissue and contains no liver substance. This area can be so freely opened that the hand of the operator can be inserted into the hydatid cavity with a view to exploring it for pockets and also

determining its dependent part. Sometimes the most dependent part is more towards the lower and back portion of the liver, as in *Fig. 529*, so that a counter-opening must be made below the 10th rib posteriorly. Sometimes the most dependent part extends forward, as in *Fig. 530*, so that it is drained better by a stab wound anteriorly

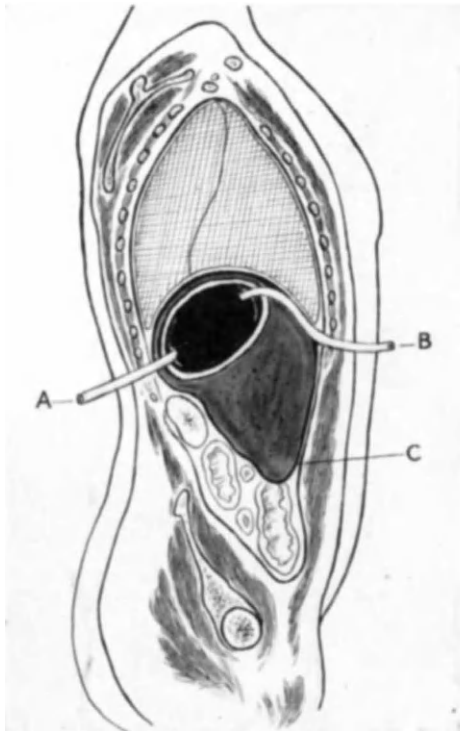


Fig. 529.—Cavity of hydatid cyst of the upper surface of the liver, which extends towards the posterior surface, and must be drained posteriorly at the lowest part of the cyst. A, Counter-drainage; B, Opening in front; C, Liver enlarged downwards.

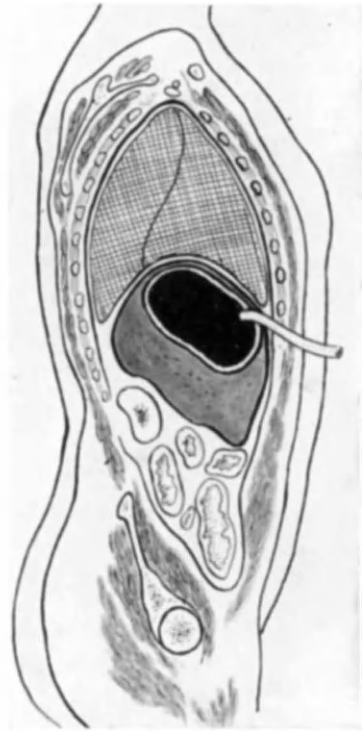


Fig. 530.—Cavity of hydatid cyst of the upper surface of the liver which extends forward and can be drained at its lowest part anteriorly. (In this figure the drainage tube should be placed at the lowest part of the cavity.)

below the edge of the thorax, or sometimes even through the abdominal wound itself. The fact that the surgeon can make any counter-opening with his hand in the hydatid cavity renders this part of the operation easy and safe. It is one of the advantages of the abdominal approach to a hydatid of the upper surface of the liver.

The falciform and coronary ligaments are sutured before closing the abdominal wound.

CALCIFIED HYDATID

Old hydatids may become calcified and firmly adherent to the liver. As a rule such a cyst, unless it is suppurating, is better left alone. Sometimes, where the cyst lies very superficially and can be approached, such as for example a cyst on the lower surface of the liver, it can be dissected out.

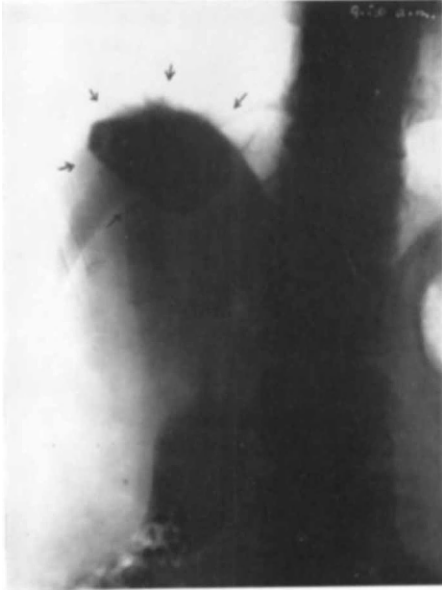

Fig. 531.—Calcified hydatid of the liver: gall-stones can be seen in the cholecystographic shadows.

Where a calcified hydatid is opened and the degenerate daughter cysts are removed, the cavity cannot collapse, and therefore it cannot close. The consequence is that a cavity holding stagnant secretion, and a sinus, persist for years. Sometimes where a calcified hydatid has been opened and drained for a long time, the calcified plaques gradually separate from the cavity in the liver, when it is possible to dissect out the calcified parts and permit the cavity to close up. The calcified wall may be partly dissolved out by continuous treatment with weak hydrochloric acid (*Figs. 532, 533*).

Fig. 534 is a radiograph of a calcified hydatid in the right lobe of the liver. This patient complained that when she walked she developed a pain in the lower right side of her chest. At operation it was seen that the anterior surface of the hydatid was

Fig. 531 is a radiograph in which is shown a calcified hydatid in the upper part of the liver.

Where a calcified hydatid is opened and the degenerate daughter cysts are removed, the cavity cannot collapse, and therefore it cannot close. The consequence is that a cavity holding stagnant secretion, and a sinus, persist for years.

Sometimes where a calcified hydatid has been opened and drained for a long time, the calcified plaques gradually

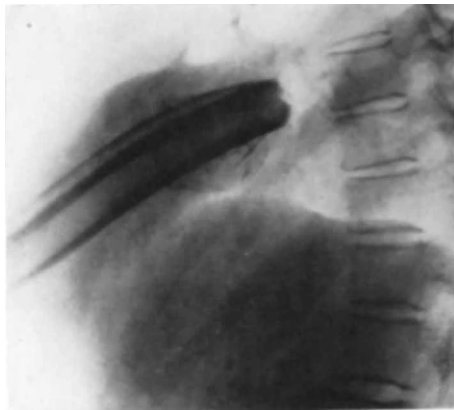


Fig. 532.—Calcified hydatid before hydrochloric acid treatment.

adherent to the anterior surface of the liver by a great number of string-like adhesions, which on movement could easily be dragged upon. The dragging on these adhesions was probably the cause of the pain which she experienced on walking.

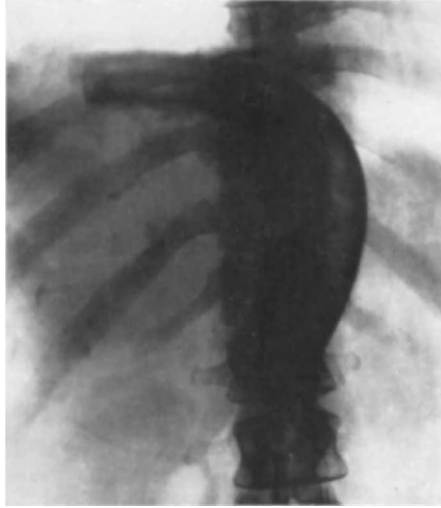

Fig. 533.—Calcified hydatid after hydrochloric acid treatment. There is now very little evidence of lime remaining.



Fig. 534.—A, Calcified hydatid. B, Barium in stomach.

Infection of Gall-bladder from Uncollapsed Cavity left after Removal of Hydatid.—The cavity left after removal of a calcified hydatid is liable to become infected, and this infection may spread through the ducts of the liver, and finally into the gall-bladder.

A man, aged 53, had been operated on for hydatid. The ectocyst, which was calcified and firmly adherent to the liver, could not be completely removed. A permanent drain was inserted. Several years after the operation he became sick, with intense epigastric pains, high steeple-like rise of temperature, mild jaundice, and a large tender swelling in the region of the gall-bladder.

At operation an empyema of the gall-bladder without any gall-stones was found, and when the old cavity of the hydatid was opened, pus and bile were seen.

Evidently the empyema of the gall-bladder had been caused by an infection spreading through the bile-ducts from the suppurating hydatid cavity.

REFERENCE

- ¹ BEST, C. H., *Lancet*, 1934, I, 1216, quoted by SAMPMON WRIGHT, *Applied Physiology*, 1937, 569. Oxford University Press.

CHAPTER LVII

DISEASES OF THE GALL-BLADDER AND THE
BILE-DUCTS: GENERAL CONSIDERATIONS

PHYSIOLOGY AND ANATOMY

The Origin of Bile.—Bile-pigment is formed in the reticulo-endothelial system, which comprises groups of a special type of cell of wide distribution in the mammalian organism, characterized by the fact that they have special *intra-vitam* staining qualities. These reticulo-endothelial cells can form bile-pigment extra-hepatically—for example, certain animals deprived of their liver can form bile-pigment after intravenous injections of hæmoglobin. Bile-pigment, therefore, is formed in the blood from the reticulo-endothelial elements: that is, from certain splenic cells—the splenocytes—from the endothelial cells of lymph capillaries, from the Kupffer cells of the liver, and from other reticulo-endothelial cells. The pigment is secreted or elaborated in some way by certain of the liver cells.

Functions of the Gall-bladder.—The gall-bladder is first developed as a bud from the foregut. This bud finally becomes hollow to form the gall-bladder. Thus the gall-bladder was originally a diverticulum of the intestine, and it is interesting to note that just as the intestine absorbs fats, salts, fluid, and other material, so the gall-bladder absorbs lipoids, salts, and fluids, but of course to a much less extent. It would appear, therefore, that some of its functions are related to those of the intestines. This hypothesis, suggested by Langenbruck, enables us to appreciate the basis of the resorptive function of the gall-bladder. In relation to this function Boyd has pointed out that if the fundus of the gall-bladder is viewed with a binocular microscope when it is full of fluid, it is like looking into marine depths. The walls are thrown into folds which float in the fluid like seaweed—obviously absorbing surfaces.

Bile-pigment formed from broken-down blood-cells by the cells of the reticulo-endothelial system, particularly those of the spleen and liver, comes in contact with certain liver cells, and these cells elaborate and excrete it in the ducts of the liver, whence it finds its

way into the common duct. At the termination of the common duct is the sphincter of Oddi, a very definite sphincter, said by some to be really formed from the duodenal musculature. This sphincter closes during fasting and dams the bile back into the gall-bladder through the cystic duct, which also is armed with a sphincter. Thus when the stomach is in a fasting state, the sphincter of Oddi closed, and the gall-bladder quiescent, resorption of water, lipoid, and salts takes place. The bile in the gall-bladder is sometimes ten times as strong as that in the ducts of the liver.

Resorption takes place through the lymphatics, the capillaries, and the venules, so that any inflammation (cholecystitis) which interferes with these interferes also with the resorptive function.

This function has the effect of equalizing the bile pressure in the ducts and in the gall-bladder. It is surprising to see how quickly the pressure in the ducts and in the gall-bladder reaches normal by this process. In relation to this equalizing effect of resorption of bile, Aschoff made an interesting experiment. The dog has his gall-bladder attached to one of the hepatic ducts instead of, as in man, to the common duct. It is therefore possible so to ligate the duct that the gall-bladder is left in continuity with the duct of the left lobe. Thick, green concentrated bile soon forms, because of the concentrating action of the gall-bladder. But if the right hepatic duct is ligatured, with which no gall-bladder is connected, the pressure in the duct gradually rises, because there is no gall-bladder to concentrate the bile and thus reduce the pressure; and the bile gets thinner and thinner, until finally, as the pressure continues to rise, bile secretion stops altogether and the bile becomes white.

Emptying of the Gall-bladder.—The gall-bladder empties in the following ways:—

1. By muscular contraction; but this cannot be the whole mechanism, Graham says, because the monkey's gall-bladder is embedded in its liver and in its case a muscular contraction could not take place.

2. By elastic recoil (like a rubber sac).

3. By a process of 'massage' from abdominal movement.

The gall-bladder empties at meal-times, particularly in response to ingested fatty material, such as yolk of egg.

The functions of the gall-bladder, therefore, are as follows:—

1. Resorption of water, salts, and lipoids, a process which takes place mainly between meals.

2. Discharge of bile into the duodenum at meal-times in response to a stimulus of food in the duodenum, particularly fatty food.

3. By reason of its concentrating action, it acts as an efficient reservoir for bile, and also prevents pressure on the bile-passages from rising excessively.

Lymphatic Connexions of the Gall-bladder.—Kodama,¹ working in Graham's clinic, showed that when dye is injected into the lymphatics of the gall-bladder in a dog, it travels to the first part of the duodenum and even farther down the duodenum. Thus there is a basis from comparative anatomy for the relationship known to exist between disease of the gall-bladder and that of the duodenum. Kodama also showed that these lymph-vessels around the gall-bladder and the first part of the duodenum connect with the head of the pancreas. He proved, too, that injections into lymph-vessels to the appendix—which in the dog is high—travel to lymph nodes around portal veins. Graham points out that there is also a rich lymphatic connexion between the gall-bladder and the adjacent liver, and that there is therefore a basis for a relationship between infection of the liver and disease of the gall-bladder.

From the work of Deaver and Sweet² it has been shown that the head of the pancreas and the gall-bladder are in the same lymphatic field, and that infection in the gall-bladder can spread by continuity to the pancreas; and on the other hand, that infection in the pancreas can spread to the gall-bladder. Experiments made by Kodama in Graham's clinic suggest that this lymphatic connexion to the pancreas is not quite so definite as suggested by Deaver and Sweet, but that the lymph passes over the pancreas and not into it unless the peritoneum is adherent. We know, however, as a clinical fact that a chronic inflammation of the head of the pancreas is very often associated with gall-bladder disease.

Thus we can understand how, anatomically, the gall-bladder can become infected from the liver or can infect the liver; how it can infect or become infected by the first part of the duodenum or the head of the pancreas; and how the appendix, pancreas, duodenum, and gall-bladder, through subserosal lymphatics, can infect the glands around the portal vein.

Nerve-supply and Sphincters of the Gall-bladder.—There is a sphincter, which is not very well defined, round the cystic duct. In conjunction with this sphincter there is a nerve-cell node (Keith)—just the same sort of ganglion cell-node which is found in the gastric wall in association with the sphincters of the stomach. There is also a sphincter around the opening of the common duct into the duodenum. The vagus nerve supplies the muscular fundus of the gall-bladder, and the sympathetic nerve the sphincters—a system of

balanced innervation arising from the autonomic nervous system on parallel lines to that of the stomach (*Fig. 535*). Thus, neurogenic disease of the gall-bladder may arise in the same way as it does in the stomach.

Aschoff describes a hypertonic gall-bladder in which spasm of the cystic duct sphincter prevents the organ from emptying normally; and also a hypotonic gall-bladder in which hypotonic muscle is responsible for stasis in the organ. There can be little doubt but that this neurogenic gall-bladder disturbance is wrapped up with the habitus of the patient.

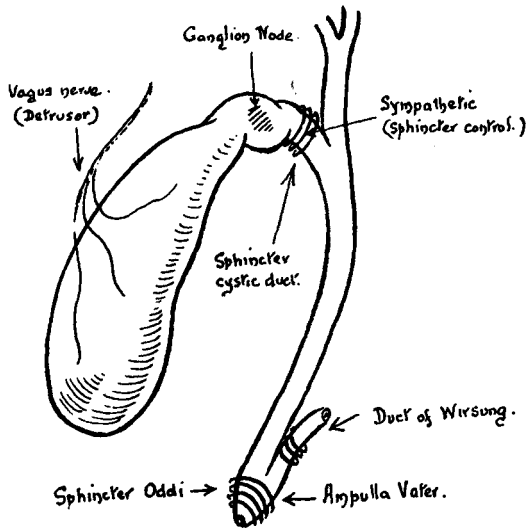


Fig. 535.—Diagram of sphincters and innervation of the gall-bladder and its ducts.

Thus there is a spastic type of gall-bladder musculature similar to a somewhat analogous condition in the stomach. The clinical manifestations of this neurogenic type of gall-bladder disturbance are liable to be confused with those of a cholelithiasis, because pain is a feature just as it is in the analogous condition in the stomach.

There is likewise a certain type of asthenic patient with a large, thin-walled, lowly situated gall-bladder in which there is stasis and in which the bile is dark from concentration—a hypotonic type likely to come under notice in the case of an equivocal clinical cholecystitis syndrome in which a cholecystograph shows a delayed emptying of the gall-bladder. And in this latter respect it is obvious that too much stress must not be placed on a gall-bladder which empties slowly. It is probably present in a patient who also has a slowly

emptying stomach and a slowly emptying colon—a patient who has a general loss of tone and a painless dyspepsia. Cholecystectomy in such a case is disappointing, for it does not relieve the dyspepsia, which of course may be due to some neurogenic gastric disturbance.

Situation of the Gall-bladder.—The gall-bladder may be situated much higher or much lower than normal. Its position seems to depend upon the type of individual: on whether he or she is of the sthenic or asthenic type. In the thin, enteroptotic woman, the gall-bladder may lie as low as the appendix; but in the fat, thick-necked, deep-chested man it may lie high up under the ribs, extending towards the midline and even towards the left side. In the first instance, if it becomes inflamed the symptoms may be confused with those of appendicitis; in the second instance, the symptoms of this highly situated gall-bladder may be confused with those of gastric ulcer, or may even be regarded as those of anginal attacks.

THE MANNER IN WHICH INFECTION OF THE GALL-BLADDER (CHOLECYSTITIS) IS BROUGHT ABOUT

Infection may reach the gall-bladder in the following ways:

- (1) By hæmatogenous (or hæmatogenous hepatogenous) infection;
- (2) By infection from the duodenum by way of the common duct;
- (3) As a result of infection from the presence of gall-stones;
- (4) As a result of infection arising from stasis of bile.

1. Hæmatogenous Infection.—Infection may reach the wall of the gall-bladder from the systemic circulation, giving rise to a cholecystitis, generally of a chronic nature. Wilkie, Rosenow, and many other observers are of opinion that this is the main avenue of infection. In cases of chronic cholecystitis they find, in the sub-mucous layer of the gall-bladder, a streptococcus which, they say, has a selective affinity for the wall of the gall-bladder. They believe that this is the reason why this organism, coming as it does through the systemic circulation, does not affect other organs as well as the gall-bladder. They find that bile inhibits the growth of this organism, and that therefore it cannot be isolated from the bile. They find the organism in the cystic gland which drains the gall-bladder. Thus, if this hypothesis is true, it is obviously useless to treat cholecystitis by the draining of the bile by medical measures, by a duodenal tube, or by cholecystostomy.

On the other hand, Graham suggests that infection from some focus in the portal system enters the portal vein and through it reaches the liver, where it gives rise to foci of hepatitis. He believes that from the liver the infection reaches the lymphatics of the wall of the

gall-bladder, with which those of the liver are in direct connexion. He thinks that this hæmatogenous hepatogenous route is a much easier and more direct one than the roundabout hæmatogenous route postulated by other observers.

2. Infection from the Duodenum.—It is known that infection from the duodenum, perhaps passing through an impotent sphincter of Oddi, and by way of the common duct, can infect the bile, and through this medium can also infect the mucous membrane of the gall-bladder.

Probably this infection arises in much the same way as we know infection arises in a cholecystenterostomy or a cholecystgastrostomy, where, of course, there is no sphincter, and where, after a lapse of time, cholecystitis or cholangitis is prone to develop.

A greater infectivity of the duodenal contents may possibly predispose to this infection by way of the duodenum; for it has been shown that disease of the gall-bladder wall, as indicated by a negative cholecystogram, is often found in association with a hypo-acidity, in which condition the gastric contents are more infective than in the case of normal acidity.

3. Gall-stones.—We know that a cholesterol stone can form in the gall-bladder from metabolic disturbance—probably as the result of an excess of cholesterol in the blood. The presence of such a stone in the gall-bladder can contribute to the occurrence of an infection—a cholecystitis—by the chronic irritation, as a foreign body, which it causes to the wall of the gall-bladder; or by interference with the emptying of the cholecystic contents.

4. Stasis of Bile.—Stasis of bile in the gall-bladder, neurogenically caused, provides a pabulum suitable for the development of an infection, which may give rise to a chronic cholecystitis.

THE FORMATION OF GALL-STONES

Gall-stones may arise in the following ways: (1) As a result of an infection of the gall-bladder wall, that is, as the result of a chronic cholecystitis, the tissue effects of the inflammation interfering with the normal resorption of lipoids such as cholesterol; (2) As a result of a disturbance in cholesterol metabolism, when cholesterol deposits take place in the wall of the gall-bladder, even in the absence of any inflammatory process; (3) As a result of stasis in the bile, when stones may occur in the gall-bladder, perhaps as the result of infection of the retained bile; (4) As a result of some dyscrasia in bile, which is probably responsible for the formation of pigment stones.

Thus we have two main varieties of gall-stones : (1) *Gall-stones of non-inflammatory origin*—cholesterol and pigment stones ; (2) *Gall-stones of inflammatory origin*—mixed gall-stones.

Gall-stones of Non-inflammatory Origin.—

Cholesterol Stones.—These are characterized by the following features : They consist of pure cholesterol, show a coarsely crystalline structure, occur singly, and are not usually associated with a cholecystitis. They are often found in persons who have never shown signs of gall-bladder disease. They occur at all times of life, even in childhood, and very often in women after pregnancy.

The origin of cholesterol : Cholesterol is secreted by the liver cells from the cholesterol present in the blood, without being disintegrated in the process. Experiments show that the *amount of cholesterol in the bile* depends upon the *amount of cholesterol in the blood*.

Cholesterol in the bile has also been experimentally shown to come from the gall-bladder epithelium when it is inflamed. Therefore an inflammatory condition of the mucous membrane, as well as disturbance in the metabolism consisting of a transitorily increased secretion, can give rise to cholesterol stones.

An increase of cholesterol metabolism follows pregnancy, especially if the patient does not nurse the child, and this explains the association of cholesterol gall-stones with pregnancy. An increase in the formation of cholesterol and therefore cholesterol gall-stones is prone to follow the rapid loss of fats, either from the treatment of obesity or following infective diseases.

Cholesterol is held in solution by the bile-salts, the amount of which depends largely on the excretory power of the liver cells. The bile of lower animals contains a large amount of bile-salts and a little cholesterol. Human bile, on the other hand, contains much more cholesterol in proportion to the bile-salts. It is therefore obvious why animal bile has been used to try to dissolve cholesterol gall-stones.

Cholesterol stones resulting from metabolic disturbance form one-third of all varieties of gall-stones, and appear either singly with the peculiar structure described, or in the form of so-called 'combination' stones. Cholesterol stone is therefore of metabolic rather than cholecystitic origin, and is either latent in its manifestations, or gives rise to slight and frequently misleading symptoms.

Cholesterol stone is, of course, not opaque to X rays, and so throws a negative shadow in a cholecystograph.

Pure Pigment Stones.—These are small and like coarse black sand. Their surfaces are black—sometimes brightly coloured by

a thin layer of pigment calcium. They are most frequently found in the bile-ducts.

Gall-stones of Inflammatory Origin (*Mixed Gall-stones*).—

The steps in the formation of mixed gall-stones, that is, gall-stones with probably a central cholesterol nucleus, are, according to Wilkie, Boyd, and others, as follows:—

1. An intramural streptococcal infection of the wall of the gall-bladder.

2. Lipoid accumulation in the mucosa and subepithelial layer of the wall of the gall-bladder.

3. Formation of subepithelial lipoid (cholesterol) papillomata.

4. Shedding of these papillomata to form the nuclei around which more cholesterol is deposited, and around which calcium bilirubinate and calcium biliverdinate will deposit to form a mixed stone.

A mixed gall-stone may also occur as follows: A pure cholesterol stone may partly block the cystic duct, when the retained bile and secretion may become infected and cause a chronic cholecystitis. Thus a mixed stone may follow in the wake of a cholecystitis produced by the metabolically produced gall-stone. Mixed stones may also be attributed to a cholecystitis brought about by stasis of bile, the result of a reflex spasm of the sphincter surrounding the cystic duct.

CAUSES OF DISEASE OF THE BILIARY SYSTEM

Disease of the biliary system can arise in any of the following ways:—

1. Neurogenically, due to a disturbance of the nervous mechanism concerned with the filling or the emptying of the gall-bladder: *Pre-cholecystitic disease*.

2. By an infection of the wall of the gall-bladder: *Non-lithogenous cholecystitis*.

3. As a result of the presence of gall-stones in the gall-bladder or in any of the bile-ducts: *Cholelithiasis*.

PRE-CHOLECYSTITIC DISEASE

It has been the experience of most surgeons that patients have exhibited the signs of disease of the gall-bladder, such as epigastric pain and tenderness over the gall-bladder, yet at operation the organ has appeared to be normal.

In such cases, the symptoms and signs may be due to a neurogenic disturbance—according to Aschoff, the neuromuscular apparatus of the gall-bladder is especially sensitive and easily deranged. This neurogenic disturbance is probably some incoordination of the

filling and emptying mechanism of the gall-bladder which may give rise to pain. As has been earlier pointed out, overaction of the vagus causes contraction of the gall-bladder wall and relaxation of the sphincter, while excessive activity of the sympathetic causes the reverse. Thus, as Aschoff points out, in some circumstances a hypertonic stasis gall-bladder and in others an atonic stasis gall-bladder can occur. In the hypertonic stasis gall-bladder, he writes, a spotty lipoid deposit may be found on the mucous membrane, and the musculature and the crypts of Luschka may be seen to be strongly developed, the combined effect giving the appearance of the so-called 'strawberry gall-bladder.' In the atonic stasis gall-bladder he says that there may be a remarkable thinning of the muscle wall and a disappearance of Luschka's crypts, together with a slackening of the folds of the mucous membrane.

NON-LITHOGENOUS CHOLECYSTITIS

Non-lithogenous cholecystitis occurs in 10 per cent of cases. As has been previously indicated, the infection is of a hæmatogenous origin, and is caused by a particular strain of streptococcus which exhibits a predilection for the wall of the gall-bladder.

This infection may come from some focus of systemic infection, such as infected tonsils or teeth. It may also arise from some septic focus in the portal circulation, such as appendicitis. From a focus of this kind the infection may enter the systemic circulation and reach the gall-bladder wall; or it may pass through the lymphatics to the glands around the common duct and thus to the lymphatics of the wall of the gall-bladder. According to Graham, if the infection is in the appendix, it can travel from the venous circulation in the vicinity of the appendicitis to the portal vein and thus to the liver, and from infective foci in the liver, by way of its lymphatics, to the wall of the gall-bladder.

Rarely, infection spreads up from the common duct. In certain circumstances—hypochlorhydria and infective duodenal contents in association with hypotonicity of the sphincter of Oddi—it is conceivable that infection is liable to spread up through the common duct to the contents of the gall-bladder, and from these to the gall-bladder wall, causing a cholecystitis.

A Striking Clinical Example of Non-lithogenous Cholecystitis.—

A patient had been ill for two years, complaining of pains in the epigastrium which had an indefinite relation to food. These pains came in attacks, sometimes very severe, and in one of them he was slightly jaundiced. He was tender over the gall-bladder. He said he was afraid

to eat because the taking of food brought on the pain. At operation the surgeon, finding no gall-stones present and a gall-bladder which appeared to be normal, did not perform a cholecystectomy. The attacks continued and became so bad that two years later it was again necessary to operate on him during a very severe attack, when an empyema of the gall-bladder without gall-stones was found.

This case is interesting in that it shows that a case of non-lithogenous cholecystitis can exist over a period of years, without forming gall-stones, and then go on to suppuration.

So much attention has been paid of late years to non-calculous disease of the gall-bladder that we have come to understand it better, and to recognize its minor forms. Experimental work on animals and studies of gall-bladders removed at operation have aided much in this, but Graham's test—cholecystography (*see* Chapter LVIII)—has perhaps done more than anything else to give us new knowledge in relation to non-calculous cholecystitis.

DISEASE DUE TO THE PRESENCE OF GALL-STONES: CHOLELITHIASIS

Gall-stones can cause disease in the gall-bladder or in the bile-ducts by acting as an irritating foreign body; or by blocking—completely or incompletely—the neck of the gall-bladder, the cystic duct, or the common duct, or all three.

Gall-stones in the Gall-bladder.—Biliary calculi in the gall-bladder of themselves cause: (1) Dyspepsias of various types; (2) A chronic cholecystitis with all its symptoms and signs; (3) Pain as a result of muscle spasm of the gall-bladder wall around a large stone, or a gall-bladder full of stones, or due to the jamming of a fairly large stone in the S-shaped part of the gall-bladder.

The Dyspepsia of Gall-stones.—The dyspepsia caused by gall-stones has already been described (*see* p. 76), and the following types of dyspepsia should be specially noted:—

1. A flatulent dyspepsia which is irregular in its occurrence and duration.

2. A painless dyspepsia—a 'full feeling' after taking food, especially after certain articles of diet, such as potatoes and fatty foods, which are naturally avoided because they aggravate the discomfort.

3. A nauseous dyspepsia—nausea after meals, irregular in its onset and duration; and in association with these dyspeptic symptoms, a muddy complexion.

4. An acidity, heartburn, and water-brash, accompanied by severe epigastric pain at a definite time-interval after food (gastric-ulcer-like symptoms).

5. Symptoms of dyspepsia accompanied by a severe pain about three hours after food (duodenal-ulcer-like symptoms).

An important characteristic of all these dyspeptic symptoms is the irregularity of their occurrence, duration, and severity.

Chronic Cholecystitis.—Chronic cholecystitis often manifests itself by an aching pain under the right costal margin and in the right scapular region; by an epigastric pain of indefinite relation to food; by pain after turning on the left side; by tenderness over the region of the gall-bladder, though this may not always be present.

When a 'tender spot' is present, it may be difficult to distinguish from that of duodenal ulcer. The distinction can be made by altering the axis of the pressure without removing the finger from the tender spot—tenderness when the axis of the pressure is directed upwards against the descending liver signifies an inflamed gall-bladder; tenderness when the axis of the pressure is directed towards the posterior abdominal wall indicates duodenal ulcer (*see Fig. 38, p. 82*).

Muscle Spasm around a Large Stone.—Painful spasm of the gall-bladder wall may intermittently occur around a large stone. Severe pain is caused by the jamming of a large stone in the S-shaped part. Occasionally a gall-bladder, so tightly packed with stones that it cannot hold any more, gives rise to the symptoms of duodenal ulcer. In such a case, pain may come on two to three hours after food and be followed by vomiting, which gives relief. This condition is distinguished from duodenal ulcer by the facts that, unlike the duodenal ulcer, the pain does not occur after every meal; and that at one time or another the patient suffers from a sudden attack of severe pain with much shock, a pain which requires morphia for its relief.

Gall-stones Blocking the Ducts.—

Stone Impacted in the Cystic Duct.—Following the blocking of the cystic duct by a stone there may be an attack of severe colicky pain associated with shock and sweating, somewhat relieved by pressure, heat, or vomiting, and almost always completely relieved by morphia. The onset of the pain is sudden and its cessation usually just as sudden. All the signs and symptoms of acute cholecystitis may follow on the attack of colic. *Fig. 536* shows a stone impacted in the cystic duct.

On the other hand, the colic may subside, and a large painless tumour in the region of the gall-bladder may develop. This tumour may be shaped like a cucumber and may extend towards the umbilicus. It is the gall-bladder distended with mucus—a mucocele



Fig. 536.—Colour photograph of stone impacted in the cystic duct, with the gall-bladder acutely inflamed as the result of the impaction. Patchy lipid deposits are seen in the wall of the gall-bladder, the result of a previous chronic cholecystitis—actually a ‘strawberry gall-bladder’.

(*Fig. 537*). Rarely a stone may encyst in the cystic duct with unnoticeable pain, and a huge mucocele of the gall-bladder form painlessly. In this case, since the tumour is firm and insensitive, it may be mistaken for a malignant tumour.

The impaction of a stone in the cystic duct may cause an acute cholecystitis with the following symptoms and signs.

Acute cholecystitis: In this condition, all the symptoms and signs of an acutely inflamed abdominal organ are present. The abdominal muscles in the upper and right part of the abdomen are rigid, and there is an area of tenderness over the affected gall-bladder. Sometimes the gall-bladder can be felt as a tender tumour, this tenderness being, of course, always worse when the inspiration presses the organ down on the palpating hand. There may be slight

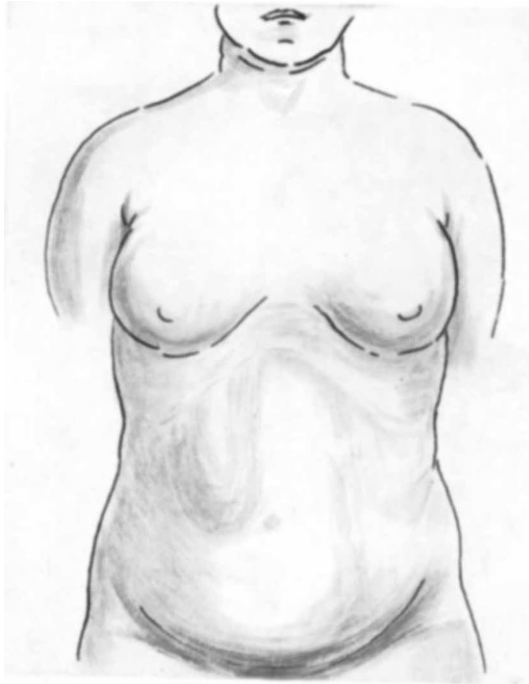


Fig. 537.—Diagrammatic sketch of a large tumour of the abdomen, of peculiar cucumber-like shape; a tumour quite insensitive to touch, and caused by a large mucocele, the result of a stone painlessly impacted in the cystic duct.

jaundice due to the inflammatory condition spreading from the cystic duct into the common duct. In addition, there may be pulmonary signs caused by reflex inhibition of the movement of the right side of the diaphragm (comparable to a reflex inhibition of the upper part of the right rectus), and therefore at the base of the right lung low-pitched crepitations, friction, and slight dullness. There will usually be the symptoms and signs of an infection—fever, rapid pulse, etc. If the stone impacted in the cystic duct slips back, the cholecystitis may get better; but if it remains impacted an empyema may develop, or gangrene or perforation may occur.

Even in the absence of an operation, a severe cholecystitis resulting from an impacted stone may slowly get better, but generally the gall-bladder becomes fibrosed and contracted, and permanently crippled. Such a fibrous and slowly contracting gall-bladder may gradually, by a continuous process of pressure and dilatation, force its contained stones through the cystic duct into the common duct.

Stone at the Junction of the Cystic and Common Ducts.—Occasionally, a stone will become impacted at the junction of the cystic and common ducts.

When this happens the gall-bladder will become dilated, forming a gall-bladder tumour, and the patient will rapidly become deeply jaundiced. The jaundice will not be intermittent, and will not be associated with infective symptoms like that caused by a 'ball-valve' stone in the common duct. It will be a persistent, progressive jaundice, unassociated with any infective symptoms: a syndrome which, if taken in conjunction with the presence of the gall-bladder tumour, is almost identical with that of a carcinoma of the head of the pancreas—an inoperable malignant condition.

Thus, it is particularly necessary to keep in mind the syndrome brought about by a stone in this situation; for otherwise this eminently operable and curable gall-stone condition may be regarded as that of a malignant pancreas, and therefore an inoperable condition—a mistake which actually happened in the following case:—

A doctor became ill with *slight epigastric pain*, of which he took very little notice. Subsequent he gradually developed a jaundice which progressed without any intermission, until finally it became deep 'black' jaundice.

He had no constitutional symptoms such as fever, malaise, rigors, etc. This and the comparatively painless onset of his symptoms suggested to him that he was suffering from a jaundice of malignant origin. When, on examination, it was found that he had a large painless tumour in the region of the gall-bladder—apparently a dilated gall-bladder—he was more than ever convinced that he was suffering from a carcinoma of the pancreas, and he refused to have an operation. Feeling hopeful by reason of the rather sudden onset of this condition and the slight initial pain that it might not be malignant, I persuaded him to allow himself to be operated upon.

At the operation I found that a stone had become wedged (almost painlessly as we have seen) at the junction of the cystic and common ducts; that the gall-bladder was very distended and contained only mucus; that the liver was very much enlarged; and that the bile was white. I removed the stone, after which he gradually recovered. (*Fig. 538.*)

The following history is another clinical example of the same kind of difficulty:—

A man, aged 43, three years previous to being seen, suffered from a severe pain in the epigastrium. He had no further pain until nine weeks

before his admission to hospital, when he had a similar pain to that which he had had three years ago. It was of a very dull nature and was present all the time. It used to have a definite relation to food ; now it had no relation to meals. He had become deeply jaundiced. He vomited occasionally after meals, but this did not relieve the pain. On examination, a large tumour over the region of his gall-bladder, slightly tender, and associated with some rigidity, could be felt.

His own account of his pain, which indicated that it was not very bad ; the enlarged gall-bladder, which was not very tender ; the jaundice, which

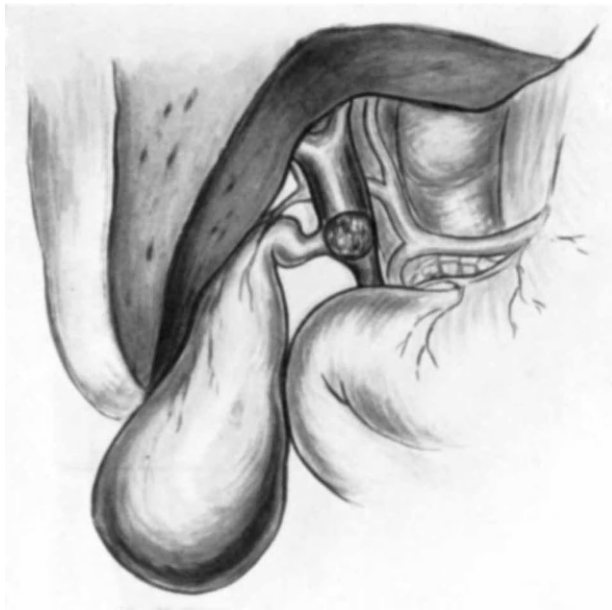

Fig. 538.—Operation sketch showing a round smooth stone impacted at the junction of the cystic and common ducts. In this drawing the enlarged gall-bladder, the complete block of the cystic and common ducts, the dilatation of the common duct, and the enlargement of the liver, are all portrayed. (The liver is shown as partly cut away, in order to let the cystic duct be seen.)

was getting progressively worse, and which was unassociated with fever, or remissions—all these were manifestations which, to the attending doctor, indicated that the patient was suffering from a carcinoma of the pancreas, and that the condition was therefore inoperable. Operation, however, disclosed a stone wedged in the junction of the cystic and common ducts.

The crucial diagnostic point in these cases of stone impacted at the junction of the cystic and common ducts was that a careful investigation of the onset showed that the illness was definitely ushered in with pain ; whereas the onset of a carcinoma of the pancreas is usually painless.

It must, however, be remembered that in jaundice arising from a carcinoma of the common duct, sometimes—perhaps because of the more rapid obstruction—considerable pain is experienced with the onset of the jaundice (*see* p. 738).

Stone in the Common Duct.—*See* p. 678.

Intra-hepatic Gall-stones.—In some rare instances, gall-stones are found in the bile-ducts of the liver. Lavric and Kobe³ report the following interesting case :—

The patient complained of stomach trouble for four years, but he had no definite pain, only a feeling of oppression in the stomach region. Before his admission to hospital, he began to suffer severe pain in the upper part of the abdomen. This pain increased very rapidly until it became almost unbearable. The pains were not of a colicky type, but were

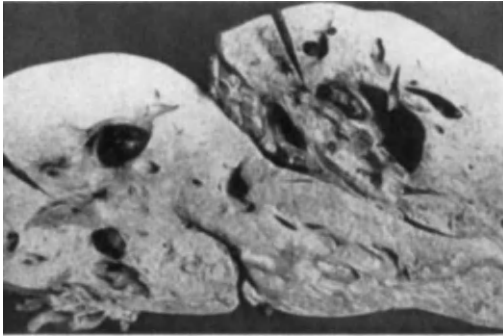


Fig. 539.—Cut through large liver with intra-hepatic stones.
(From the 'Zentralblatt für Chirurgie'.)

accompanied by vomiting. The patient had no jaundice. The upper and right side of the abdomen was rigid. This situation, too, was tender. The edges of the liver could be felt three finger-breadths below the edge of the thorax. The urobilin test was strongly positive. The pulse was 120, and the temperature 100°. (*Fig. 539.*)

Thus, this possibility must be considered when, at operation, no cause is found for symptoms and signs suggestive of a cholelithiasis.

OBSCURE CONDITIONS OF THE GALL-BLADDER

If we consider disease of the gall-bladder from the point of view of diagnosis, it will be seen that, in the majority of cases, the symptoms and signs are so obvious that no doubt arises. The impaction of a stone in a duct, the advent of inflammation of the gall-bladder, give rise to definite characteristic symptoms.

There is, however, a proportion of cases in which a mild, non-lithogenous cholecystitis is present, or in which cholesterol stones are

present without an associated chronic cholecystitis. In such cases the symptoms may be most indefinite and the diagnosis therefore extremely difficult, as for example in cases of flatulent, nauseous, or painful dyspepsia. It is in this type of doubtful case of cholelithiasis that the cholecystographic test devised by Graham has proved so useful.

It will therefore be well at this juncture to consider cholecystography—the basic principles underlying the method, and the reliance which may be placed on it in making a diagnosis. Moreover, it will be appropriate to consider this test before dealing with other conditions of the biliary tract—complete and incomplete obstruction of the common duct—to which it has little relevance.

REFERENCES

- ¹ KODAMA, SHUICHI, "Lymphatics of Extrahepatic Biliary Passages", *Surg. Gynecol. and Obst.*, 1926, **43**, Aug., 140-6.
- ² DEEVER, J. B., and SWEET, J. E., "Prepancreatic and Peripancreatic Disease, with a Consideration of the Anatomic Basis of Infections from the Gall-bladder to the Pancreas", *Jour. Amer. Med. Assoc.*, 1921, **77**, 194. Quoted by E. A. GRAHAM in *Diseases of the Gall-bladder and Bile-ducts*.
- ³ LAVRIC and KOBE, *Zentralb. f. Chir.*, 1938, No. 34, Aug. 20, 1863.

CHAPTER LVIII
CHOLECYSTOGRAPHY

CHOLECYSTOGRAPHY is now one of the most important means for determining early disease of the gall-bladder.

To obtain a cholecystographic shadow of the gall-bladder, the bile must be normally secreted, that is, the liver cell which has to do with its elaboration must be healthy; the wall of the gall-bladder must be healthy, so that its resorbing function is normal; the cystic duct must be patent to admit the bile into the gall-bladder; and, last of all, the sphincter of Oddi must be closed—the patient must be fasting—so that the bile does not escape into the intestine, but is dammed back, and entering the cystic duct passes into the gall-bladder.

Principles Underlying Cholecystographic Tests.—Bile pigment, formed extrahepatically—probably mainly by the reticulo-endothelial cells in the spleen—enters the liver by the portal vein, and is elaborated or secreted by liver cells. It is then discharged into the hepatic ducts, and if the patient is fasting, becomes dammed back by the sphincter of Oddi, and by way of the cystic duct enters the gall-bladder. Here, between meals, if the wall of the gall-bladder is healthy, absorption of water, salts, and cholesterol takes place by way of its lymphatics, capillaries, and venules. If sodium iodotetra-phenolphthalein is given either by mouth or by intravenous injection, it also is secreted by the same liver cells that elaborate the bile, and becomes a constituent of the bile that enters the gall-bladder.

As resorption of fluid takes place in this organ, and the bile becomes concentrated, the percentage of the radiopaque salt becomes sufficiently strong to give a fairly dense X-ray shadow.

The denseness of the cholecystographic shadow is thus dependent on the power of the gall-bladder wall to concentrate bile, and this power is dependent on the function and therefore on the normality of the gall-bladder wall. The normality and function of the cholecystic wall are usually disturbed by chronic inflammation.

It follows that there is an absence of cholecystographic shadow—a 'negative' shadow—under the following circumstances:—

1. Absence of the dye (sodium iodotetra-phenolphthalein) in the liver, and therefore in the bile. If the oral method is used, this may

be due to lack of absorption of the phenolphthalein from the alimentary canal.

2. Disturbance of the function of the liver cells which are concerned with the excretion of bile. This may be due to disease of the liver cells or to interference with their function by congestive heart failure.

3. Failure of bile to enter the gall-bladder. This may be the result of blocking of the cystic duct by inflammation or by a stone.

4. Deficient concentration of the bile stored in the gall-bladder. This may be caused by inflammation of the gall-bladder wall blocking the lymphatics and capillaries.

5. Patency of the sphincter of Oddi; the bile is not dammed back into the gall-bladder. This happens when the patient has not been fasting and when the sphincter of Oddi relaxes in response to the stimulus of a meal, and the bile is poured into the duodenum. It may also occur in certain general diseases, and sometimes in disease of the duodenum.

Some importance also attaches to the rate of emptying—that is, to the normality of the emptying function of the gall-bladder in response to a fatty meal.

The Technique of Cholecystography.—Two methods are in vogue, the intravenous and the oral. The oral has almost completely superseded the intravenous, because of the discomfort to the patient of the latter. There is no doubt, however, that the intravenous method is the more reliable, and it is still being employed as a confirmatory test in cases where there is no clinical evidence to support an absence of the cholecystographic shadow obtained by the oral method.

The Oral Method.—One of the most useful cholecystographic methods is that employed by Sandström,¹ which is carried out in the following manner :—

First day : Half a dose is given of the opaque medium suspended in some alkaline mineral water; as opaque medium he uses Merck's iodotetragnost. A full dose is reckoned as 3 to 4 g. according to the body-weight.

Second day : The last meal on this day is taken at 4 p.m. It should be small in bulk and light, and should contain no fat or yolk of egg. In the evening (8 to 10 p.m.) a full dose is given of the opaque medium suspended in ordinary soda-water.

Third day : Radiographical examination on fasting stomach at 9.30 a.m. Should no shadow of the gall-bladder be obtained at that time, further examination is undertaken three to four hours later, possibly followed by a yolk meal for studying the emptying of the gall-bladder.

In some cases a fractional administration of the opaque medium is carried out in the following manner :—

First day : In the evening, 1½ g. opaque salt.

Second day : In the morning, 1½ to 2 g. of the opaque salt, the same dose in the evening.

Third day : Radiographical examination.

What Reliance can be Placed on the Cholecystographic Test ?

—In regard to this point, two questions arise :—

1. Does a normal cholecystogram exclude the presence of cholelithiasis or of all grades of cholecystitis ?

2. Does the absence of a cholecystographic shadow (a negative cholecystogram) always indicate disease of the gall-bladder ?

In regard to the first question, in a series of 146 cases in which a normal cholecystograph was obtained, 16 per cent showed pathological conditions of the biliary tract in spite of the normal gall-bladder shadow (Foged²). Of the 24 cases in which gall-bladder disease was present, 14 were cases of cholelithiasis, 9 were cases of cholecystitis, and 1 a case of pericholecystitis. Many other authors (Geill, Radojevic, Case, Berard and Mallet-Guy, Ostergaard, Bauer, and Wolke) have shown that a normal cholecystogram does not always exclude pathological conditions of the biliary tract. Extensive collective statistics show a percentage of error in this respect. However, it may be taken that a normal cholecystogram corresponds to a normal condition in the gall-bladder and biliary tract in about 90 per cent of cases.

In regard to the second question, in the absence of any abnormal liver function, an absence of shadow, or a faint shadow, in the opinion of a great majority of authors, may be taken as evidence of a pathological condition of the biliary tract in 94 per cent of cases. Many authors, however, are more or less sceptical over the significance of the negative cholecystogram, and point out that many extra-biliary diseases are associated with the absence of a cholecystographic shadow, probably as a result of reflex disturbances of the function of the liver or of the biliary tract. For example, the absence of the cholecystographic shadow has been reported in cases of duodenal ulcer, of diseases of the stomach (ulcer, cancer, ptosis), and of appendicitis. Orator reports 25 cases of peptic ulcer with absence of the gall-bladder shadow in 60 per cent ; Grebe found a negative cholecystogram in 6 out of 46 cases of peptic ulcer. Foged quotes observations by Eisler and Kapstein, Bauer and Strasser, Flick and Traum, Thom, and Levyn to show that absence of a cholecystographic shadow is the rule with a normal gall-bladder in cases of exophthalmic goitre and diabetes mellitus and in the last months of pregnancy.

In regard to the significance of a faint cholecystographic shadow, the general opinion seems to be that it is not a reliable criterion; significance may be attributed to it only if it remains faint also in the motility test (Kirklin and Kolbe).

Thus, not only in the absence but also in the presence of a cholecystographic shadow, radiography must be regarded as only a diagnostic support, and clinical findings must always carry the most weight in making a diagnosis.

The Significance of the Absence of a Cholecystographic Shadow.—When, therefore, there is an absence of the cholecystographic shadow without any clinical evidence of disease of the gall-bladder, and the question arises as to whether an operation is indicated, the following factors must be taken into consideration: (1) Failure to absorb the dye; (2) Errors in technique; (3) The presence of extra-biliary disease; (4) The presence of disease of the liver; and (5) Obstruction of the common duct.

1. *Failure to Absorb the Dye from the Bowel.*—In a few cases of absent cholecystographic shadow, Foged discovered that radiographs of the gall-bladder taken some days later showed a deficient cholecystographic shadow. Apparently in these cases there was some error in the absorption of the dye. In such cases it should be given intravenously to confirm or disprove the absence of shadow. Iodotetragnost 3 g. should be dissolved in 20 c.c. of water and given intravenously from an ordinary 20-c.c. Record syringe.

2. *Errors in Technique.*—The absence of shadow may be due to the fact that the patient has had a meal, permitting the opening of the sphincter of the common duct.

3. *The Presence of Extra-biliary Disease.*—Conditions such as prepyloric or duodenal ulcer must be excluded. It is possible that the presence of an acute inflammatory lesion in the duodenum may cause a disturbance of the sphincter of Oddi, for this structure is supposed to be formed of duodenal musculature.

4. *The Presence of Disease of the Liver.*—A previous hepatitis, or a biliary obstruction, or the venously congested liver—an early manifestation of a failing heart—may each cause an absence or a faintness of a cholecystographic shadow.

In one case in which the radiologist, even after repeated examinations, had reported that the patient showed a negative cholecystographic shadow, I found at operation a normal gall-bladder but evidence of a previous hepatitis. This patient had had a previous history of two months' jaundice.

In other operation cases where there was a negative cholecystographic shadow, and where I proved that the gall-bladder was normal, I found that the patient had a large liver with round edges—probably a venously congested liver from early heart failure, or a moderate grade of hepatitis.

5. *The Presence of Obstruction of the Common Duct.*—In cases of even a mild grade of obstruction of the common duct, no cholecystographic shadow or only a faint one may be found. A patient was X-rayed because he had symptoms of gall-stones—pain, etc. He showed a faint cholecystographic shadow. At operation a slightly dilated gall-bladder was erroneously removed. Subsequent operation showed an early stage of carcinoma of the common duct.

Test of Liver Function where there is Absence of a Cholecystographic Shadow with no Clinical Evidence.—In those cases where a negative cholecystographic shadow is found in the absence of clinical signs of disease of the gall-bladder or bile-ducts, Blomström and Carl Sandström³ have a plan whereby they carry out, either simultaneously or in immediate succession to the cholecystographic test, the bromsulphthalein test of liver function.

The technique of this test is as follows :—

An intravenous injection of a 5 per cent solution of bromsulphthalein is made in the arm in a quantity corresponding to 2 mg. per kilo body-weight (the syringe, a 5-c.c. Record syringe, should be of special construction, long and narrow, to allow careful dosage). After exactly 30 minutes about 20 c.c. of blood is withdrawn from a vein in the other arm and collected into two centrifuge tubes which are immediately provided with rubber stoppers to prevent evaporation. These tubes are then left standing till the following day, when a sufficient quantity of serum will have been obtained. Approximately 1 c.c. of serum is then drawn off with the pipette into two identical small test-tubes. To one of the tubes a drop of 10 per cent NaOH solution is added, and in the presence of bromsulphthalein the serum becomes a red-violet colour. To the second tube a drop of 5 per cent hydrochloric acid is added to free the serum from the result of hæmolysis, if such has taken place. The alkalized serum is then checked against a standard solution in a Walpole's comparator, the standard solution being made up as follows: Bromsulphthalein 4 mg. is added to 100 c.c. distilled water, alkalized with 0.25 c.c. of a 10 per cent solution of NaOH. This is the 100 per cent standard solution, of which dilutions are then prepared down to 5 per cent.

The authors think that the bromsulphthalein is excreted by the same part of the liver parenchyma as the iodotetraphenolphthalein; and that a high retention of the bromsulphthalein—over 40 per cent—excludes the possibility of getting a positive shadow of the gall-bladder.

In an investigation of a large series of cases they were able to show that a high retention of bromsulphalein with a negative cholecystographic shadow was usually due to disease of the liver and lessening of its function. They write: "Where the bromsulphalein test showed that the liver was normal, absence of a shadow or faintness of a shadow indicated: (a) disease of the wall of the gall-bladder—chronic cholecystitis; (b) impatency of the cystic duct."

Cholecystographic Gall-stone Shadows.—Gall-stones may show in a cholecystographic shadow (1) as negative shadows where there are cholesterol stones, or (2) as typically concentrically marked radio-opaque gall-stones—the mixed or combination gall-stone of calcium biliverdinate or calcium bilirubinate with perhaps a cholesterol nucleus. These cholecystographic gall-stone shadows are frequently found in a faint cholecystographic shadow.

The radiographs in *Figs. 540–542*, showing cholecystographic shadows with gall-stone shadows within them, are typical examples of both the negative and positive shadows of gall-stones, and also of the faint cholecystographic shadow.

The Significance of the Emptying Function of the Gall-bladder.

—The rate at which a gall-bladder empties in response to a fatty meal is of importance in making a diagnosis of disease of the gall-bladder, but only of minor importance, for the emptying rate varies

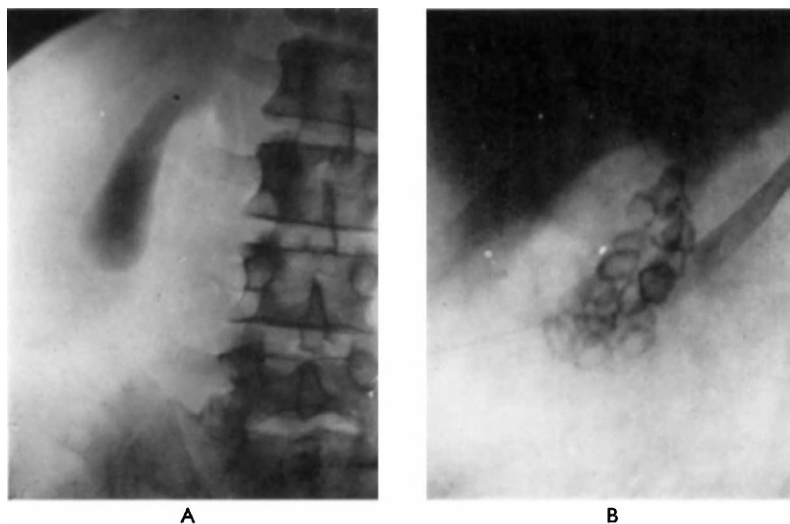


Fig. 540.—Examples of cholecystograms. A, Normal cholecystographic shadow; B, 'Straight' radiograph of the gall-bladder showing it packed full of stones of the usual mixed type.

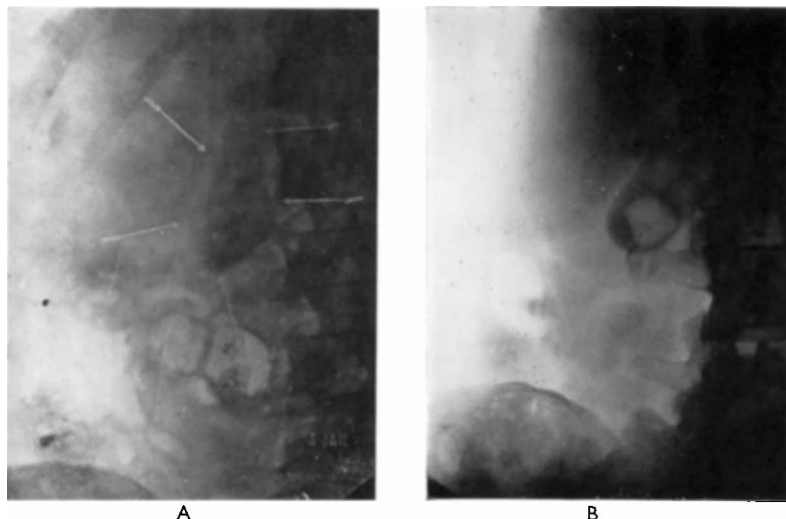


Fig. 541.—Examples of cholecystograms. A, B, Gall-stones thrown up in cholecystographic shadows faintly outlined.

very much within normal limits, and according to the habitus of the patient.

The Significance of the Contour of the Shadow.—A distortion of the contour of the gall-bladder, as the result of a

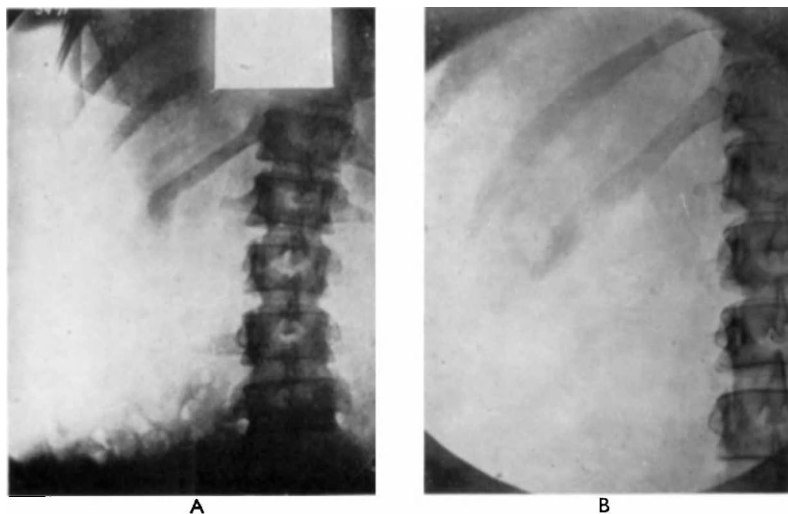


Fig. 542.—Examples of cholecystograms. A, Single small cholesterol stone which gave rise to nausea, and which is seen lying in the fundus of the gall-bladder well outlined by the dye; B, Large cholesterol stone in a gall-bladder fairly well outlined by the dye.

disease in the neighbouring organs, may be shown by deformity of the shadow. Deformity of the gall-bladder wall is generally due to a congenital cause, or to disease adjacent to the gall-bladder; it is not as a rule due to intrinsic disease, except perhaps the rather rare adenoma; for in disease of the gall-bladder concentration of the bile will not take place, and therefore a shadow will not be present.

The Significance of the Position of the Shadow.—The position of a gall-bladder shadow is often of considerable diagnostic importance to the surgeon. For example, a more or less distinct shadow which is high up and towards the left, may, in the case of a suspected anginal pain, indicate disease of the gall-bladder. On the other hand, a gall-bladder shadow situated in the region of the appendix will indicate that the tenderness in the appendiceal region is probably not due to an appendicitis, but to an inflamed, lowly situated gall-bladder.

REFERENCES

- ¹ SANDSTRÖM, C., *Acta radiol.*, 1929, **10**, 271; **12**, 8. (Quoted by J. FOGED, *op. cit.*)
- ² FOGED, J., "Cholecystography", *Acta chir. Scand.*, 1934, **75**, June 8, 105-28.
- ³ BLOMSTRÖM, H., and SANDSTRÖM, C., 1931, *Ibid.*, **71**, 135.

CHAPTER LIX

GALL-STONES IN THE COMMON DUCT AND THEIR
DIFFERENTIAL DIAGNOSIS

GALL-STONES are found in the common duct as follows :—

1. Impacted in the common duct at the junction of the cystic and common ducts, and causing complete obstruction of the ducts.
2. Loose in the common duct, a 'ball-valve' stone—that is, a stone causing incomplete obstruction.
3. Impacted firmly in the ampulla of Vater, and causing complete obstruction of the common duct.
4. As an irregular gall-stone, not of 'ball-valve' type, and not causing any definite obstruction.
5. As a number of small rectangular gall-stones, a 'filter-bed' as it were, causing mild obstruction, and often found in the dilated common duct which occasionally follows cholecystectomy.
6. As a small gall-stone in the ampulla of Vater—a stone so small that it can block the ampulla and yet lie below the opening of the duct of Wirsung, that is, the kind of stone which causes retrojection of bile into the pancreatic duct.

1. Stone at the Junction of the Common and Cystic Ducts, Causing Complete Obstruction.—This condition has already been dealt with (*see* p. 666).

2. 'Ball-valve' Stone.—A gall-stone in the common duct may give rise to obstruction when it completely plugs the duct. As a result of the obstruction, a dilatation occurs above the point of obstruction, and the stone then falls back into the dilated part, whereupon, the obstruction being relieved, the bile flows into the duodenum. The dilated duct now contracts and an obstruction is again produced. Thus the stone gives rise to an intermittent and therefore incomplete obstruction, as diagrammatically shown in *Fig. 543*.

Such a calculous obstruction of the common duct may give rise to the following symptoms and signs: (*a*) A colicky pain situated in the mid-epigastric region; (*b*) The onset of jaundice from twenty-four to forty-eight hours after the onset of the pain; (*c*) Tenderness over the common duct; (*d*) Rigor, fever, and other evidence of infection.

Generally, in this 'ball-valve' calculous syndrome, a dilated gall-bladder is not found. As a rule it is associated with a small fibrous gall-bladder which has resulted from much inflammation, and which has propelled, by the effects of its constant cicatrizing pressure, a large stone into the common duct. Stones which are forced into the common duct by the muscular action of the gall-bladder are generally small, and likely to pass through this duct into the duodenum.

There are, however, a few cases where a 'ball-valve' calculous obstruction is accompanied by a palpable gall-bladder, thus conforming to Courvoisier's law—that in 80 per cent of cases of obstruction of the common duct due to stones there is contraction of the gall-bladder.

The characteristic of the jaundice caused by a 'ball-valve' stone in the common duct is that it is intermittent and associated with symptoms of infection; that is, that the onset of pain and jaundice is usually accompanied by fever (temperature 102° to 103°), by rigor, malaise, and other constitutional symptoms. As the jaundice gets better, the infective symptoms get better. The jaundice is of the "yellow-as-a-guinea" type, a jaundice caused by absorption of bilirubin—a

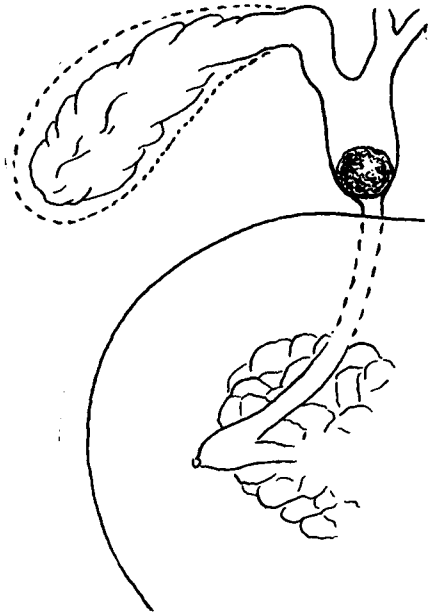


Fig. 543.—'Ball-valve' stone in common duct.

gall-stone type of jaundice, which should be contrasted with the 'black' jaundice type which is indicative of malignancy, and which is caused by the absorption of biliverdin found abundantly in stale bile.

3. Stone Impacted in the Ampulla of Vater.—A large round stone wedged firmly in the ampulla of Vater causes symptoms like those produced by a stone at the junction of the cystic and common ducts, that is, it gives rise to a persistent and progressive 'black jaundice' without infective or constitutional symptoms. It is a jaundice similar to that caused by carcinoma of the pancreas, except that its onset is usually associated with colicky pain. It should be particularly noted that in jaundice from this cause the gall-bladder is only rarely dilated.

The absence of a dilated gall-bladder and the onset of the jaundice with a certain amount of pain, are the two points which should enable the symptoms of this condition to be distinguished from those of carcinoma of the head of the pancreas. How important and life-saving such a differential diagnosis may be is illustrated by the following history :—

A nurse, aged 45, became ill after her evening meal with vomiting and slight pain. A few days later she became jaundiced. When seen, three months later, she had a deep jaundice which was of the 'black' type. She had had no remissions of the jaundice, and no infective symptoms. Her liver was very enlarged.

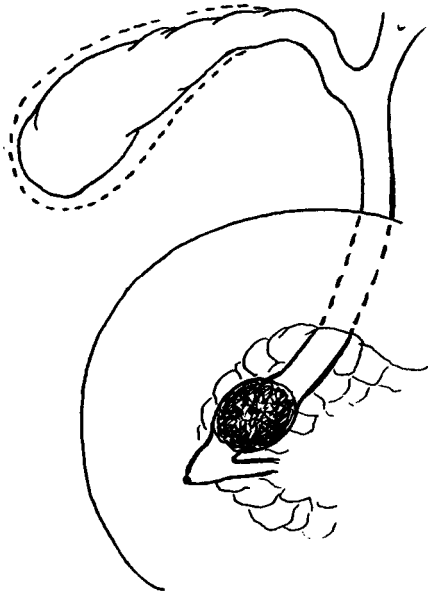


Fig. 544.—Large stone impacted in the ampulla of Vater.

Because the jaundice was unremitting, had set in practically painlessly, and was unaccompanied by infective symptoms, a diagnosis of carcinoma of the head of the pancreas had been made.

Knowing the hopelessness of such a condition, the nurse herself had refused to be operated on. I pointed out, when called in to consultation, that, although the liver was enlarged, the gall-bladder was not palpable, and that it was possible that it might be a large round stone impacted in the ampulla of Vater, and I persuaded her to agree to have an operation.

At operation a fairly large stone was found firmly impacted

in the ampulla of Vater, and was removed. Fig. 544 is a diagrammatic representation of the condition.

Although the bile was white from the prolonged complete obstruction, the patient completely recovered. Careful cross-examination could not elicit from her that the onset of her jaundice was accompanied by any appreciable pain ; it was more discomfort, she said.

4. Large Irregular-shaped Stone in the Common Duct.—In a few cases which have come under notice, large irregular gall-stones have been present in the common duct, and yet the patients have not manifested any sign of jaundice. Obviously, the irregularity of these stones prevented them from completely blocking the common duct, and allowed the bile to trickle along the irregularities. In one instance of a stone of this type in the common duct, the patient suffered from acute colicky pain between one and two

hours after meals. His pain would be followed by vomiting, after which he would get relief. He had no jaundice. His condition had been regarded as due to a chronic gastric ulcer (*Fig. 545*).

5. Multiple Stones in the Common Duct after Cholecystectomy.

—Following cholecystectomy, I have seen cases in which a dilated common duct has been packed with angular stones. The patient has suffered from a mild, slightly infective jaundice. The stones formed a sort of filter-bed through which the bile trickled into the duodenum.

In cases, too, where the gall-bladder has been almost completely destroyed by inflammation, I have found the common duct packed with small irregular-shaped stones, and the patients suffering from only the mildest form of jaundice. Sometimes, in this 'filter-bed' type of common-duct obstruction, the patient may be free from any sign of jaundice, and even from definite painful manifestations.

6. Small Stone Causing Retrojection of Bile into Pancreas.

—Acute transient pancreatic complications may occur in cholelithiasis, caused by a stone so small that it can become fixed, and so disposed at the exit of the ampulla of Vater into the duodenum that it causes bile (perhaps infected) to be retrojected into the pancreas through the duct of Wirsung (*Fig. 546*). In such circumstances the patient may become alarmingly ill with acute abdominal pain, collapse, a running low-pressure pulse, subnormal temperature, and he may show a board-like abdominal rigidity. The clinical picture will be that of an abdominal catastrophe simulating a perforated gastric or duodenal ulcer, or an acute pancreatitis.

In a case like this, if the gall-bladder is promptly drained, the patient will usually recover dramatically.

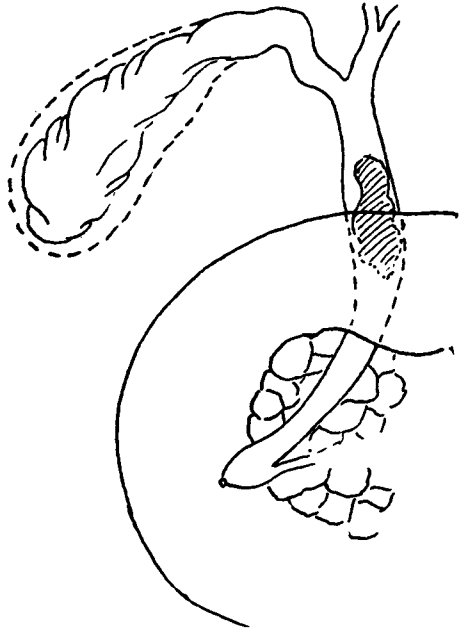


Fig. 545.—Large irregular-shaped stone in the common duct.

Here is a clinical example of such an occurrence :—

A man, aged 40, had been sick for ten years, suffering from attacks of fairly acute epigastric pain, which would last from one to two weeks, and would radiate to the left shoulder. In the interval he had a little indigestion. He would also have periods of pain from one to two hours after food, with very little relief from vomiting. For years he had been treated for duodenal ulcer.

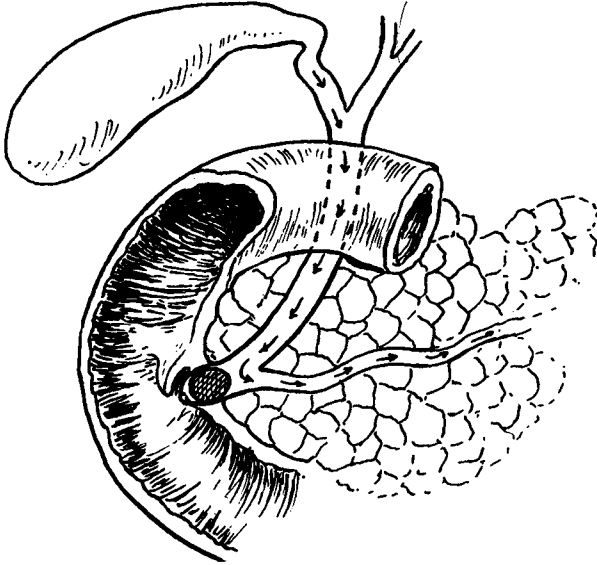


Fig. 546.—Small stone blocking exit of ampulla of Vater and causing retrojection of bile into pancreas through the duct of Wirsung.

Three hours before I saw him he got a sudden acute pain in the upper part of the abdomen. His abdomen became as rigid as a board, and he was very shocked. It was thought that he had a perforated duodenal ulcer. At operation I found a small stone in the common duct and considerable changes in the pancreas, but no acute pancreatitis—probably a pancreatosis. Apparently the small stone had caused retrojection of bile into the duct of Wirsung. Following the operation he obtained immediate relief.

CHAPTER LX

DIFFERENTIAL DIAGNOSIS IN GALL-BLADDER SYNDROMES

As there are so many phases of disease of the gall-bladder and its ducts—phases which are liable to be confused with syndromes of other diseases—it will be advisable, in discussing the differential diagnosis, to deal separately with the various phases of cholelithiasis.

The phases of gall-bladder disease which require detailed discussion from the point of view of differential diagnosis are :—

1. Jaundice.
2. Epigastric pain.
3. Right hypochondriac pain and tenderness.
4. Gall-bladder dyspepsia.
5. Acute cholecystitis (diagnosis from a suppurating central hydatid).
6. Acute cholecystitis (diagnosis from acute appendicitis in a high appendix).
7. Acute cholecystitis in a low gall-bladder (diagnosis from acute appendicitis).
8. Left-sided epigastric and thoracic pain (diagnosis from anginal pain).
9. Cholangitis (diagnosis from portal pyæmia).

JAUNDICE**Remittent and 'Yellow' Jaundice, with Infective Symptoms unaccompanied by a Palpable Gall-bladder, Originating with Pain.**

—Such a jaundice may be caused by 'ball-valve' stone in the common duct.

The clinical manifestations arising from this condition are confused with those of the following diseases : (1) Acholuric jaundice ; (2) Central hydatid of the liver with daughter cysts entering the common duct ; (3) A carcinoma of the ampulla of Vater or of the common duct ; (4) Chronic pancreatitis.

1. *Acholuric Jaundice*.—Distinguished by the fact that the jaundice is acholuric in nature—the stools showing the presence of, and the urine the absence of, bile ; that the patient has an enlarged

spleen; and that there may be a history of familial jaundice. Unfortunately, however, in an acholuric jaundice it is not uncommon for pigment bile-stones to be present in the common duct, and thus an obstructive jaundice may be found associated with a hæmolytic jaundice.

2. *Central Hydatid of the Liver.*—The symptoms of jaundice caused by daughter cysts entering the common duct from a central hydatid of the liver are difficult to distinguish from those of a ‘ball-valve’ stone in the common duct. A hydatid will, however, be suspected if any evidence of a tumour is found in the liver, or if the intradermal (Casoni) or complement-fixation tests for hydatid are positive.

From a practical point of view, however, the pre-operative differential diagnosis is not so important, for both conditions need operation. It is the operative diagnosis that is important, because the surgeon, operating on a case of supposed gall-stone and finding the gall-bladder free from calculi, and feeling nothing abnormal in the common duct—hydatid daughter cysts are, as a rule, impalpable in the common duct—fails to open the duct and find the hydatid, and perhaps removes the gall-bladder under the mistaken impression that it is diseased and the cause of the trouble. Thus he closes the abdomen without finding the real cause of the jaundice, and the patient’s symptoms recur.

An example of such a happening is seen in the following case-history:—

A patient, a man about 50, came into hospital complaining that he had been having attacks in which he had epigastric pain, severe rigors, with vomiting, sweating, and high fever, after which he developed yellow jaundice. After a short time his symptoms would get better, and the jaundice would begin to disappear. He had been operated on some time previously for a similar attack and his gall-bladder removed, on the assumption that it was affected with a cholecystitis, and that this condition had been the cause of his jaundice and his infective symptoms.

The patient was well for a month after his operation. He then began to suffer from a fairly severe pain in the middle of the epigastrium, and from all his previous symptoms.

At operation this patient was found to have a central hydatid of the liver, and daughter cysts in his common duct. The bile found in the common duct was mixed with pus, so that the patient had a cholangitis, possibly as the result of the partial obstruction.

3. *Carcinoma of the Ampulla of Vater or of the Common Duct.*—This may cause jaundice, unremitting and without infective symptoms, but originating with pain of moderate severity. Symptoms

such as these may be confused with those arising from a 'ball-valve' stone in the common duct, because the jaundice, although like that caused by carcinoma of the head of the pancreas, arises with more pain—probably because the obstruction is fairly sudden.

The following instructive mistake is an example of how this confusion can occur:—

A patient became ill with an acute attack of epigastric pain which his doctor regarded as the pain of gall-stone colic. Ten days after this attack of pain his skin became itchy, he became jaundiced, and began to suffer from pain after every meal. He had two attacks of what his doctor regarded as colicky pain. Finally he became very jaundiced.

He was operated upon in the belief that he had gall-stones. The gall-bladder was distended, but no stones were found in it, and it was removed. The operation was followed by a permanent biliary fistula, which lasted for nine weeks.

He was then reoperated upon, and the common duct was anastomosed to the duodenum. At this operation the surgeon could not pass a probe through the common duct, but this did not shake his diagnosis, for the onset of the condition with acute pain and jaundice kept his mind fixed on some complication of gall-stones. Subsequent examination showed that the patient had a carcinoma of the ampulla of Vater.

Apparently, when the surgeon examined the common duct at the time of the operation, the growth was too small to be detected by the palpating hand.

4. *Chronic Pancreatitis*.—Little difficulty arises in the distinction of the jaundice caused by chronic pancreatitis from that of 'ball-valve' stone in the common duct. The capability of a chronically inflamed pancreas to cause obstruction of the common duct is usually overestimated. It takes a very large tumour of the head of the pancreas of chronic inflammatory origin to produce even a mild obstruction, and therefore a mild jaundice. A deep or even a moderate grade of jaundice in the presence of a moderate-sized tumour in the head of the pancreas indicates a carcinoma rather than a chronic inflammation of the head of the pancreas. The explanation of this is that the carcinoma quickly invades the duct, infiltrating it and causing constriction early. Chronic pancreatitis, on the other hand, pushes the duct to one side, and does not infiltrate it, but only obstructs it by external pressure. Thus, it requires a large inflammatory pancreatic tumour to produce sufficient compression to give rise to a pronounced obstruction of the common duct, so that *deep* jaundice as a result of pancreatitis is unusual.

Unremittent 'Black' Jaundice, without Infective Symptoms.

—This syndrome, which may be caused by complete obstruction of the common duct from an impacted round stone (*see* p. 679), is very

liable to be confused with the jaundice of carcinoma of the head of the pancreas or that of carcinoma of the common duct.

The impaction of a smooth stone may take place so painlessly that its presence is unsuspected. The absence of any association of pain with the onset of an unremitting type of jaundice, which usually denotes complete obstruction of the duct, gives a clinical picture identical with, and naturally regarded as, that of carcinoma of the head of the pancreas or carcinoma of the ampulla of Vater.

The clinical differentiation, however, lies in the fact that in the case of stone the gall-bladder is usually impalpable, whereas in the other two conditions the gall-bladder is usually dilated, enlarged, and therefore palpable.

Unremitting 'Black' or 'Green' Jaundice, without Infective Symptoms, and Accompanied by a Dilated Gall-bladder.—This syndrome may be caused by an impacted stone at the junction of the common and cystic ducts, and may be confused with that arising from *carcinoma of the head of the pancreas*.

In both conditions the jaundice, which is of the black or green type, is complete, and not associated with fever and constitutional symptoms. In both the jaundice is accompanied by a dilated gall-bladder. In the case of the impacted stone, however, the jaundice usually comes on with severe pain, while in cancer of the head of the pancreas it comes on painlessly and is associated with constitutional symptoms resulting from the presence of a cancerous growth and from a disturbance of pancreatic digestion.

Jaundice of Mild Type.—A mild jaundice with an indefinite epigastric pain, caused by an infective catarrh of the common duct following inflammation in the gall-bladder or by a small gall-stone in the common duct, is often confused with the mild jaundice sometimes found in a suppurating hydatid of the liver.

EPIGASTRIC PAIN

Epigastric pain—the referred pain of a diseased gall-bladder—may be the only symptom of an affected gall-bladder. But epigastric pain is also the referred pain of disease of the appendix.

Pelvic Appendicitis.—Sometimes there is a recurrent condition in which rigors and infective symptoms are found associated with a diffuse epigastric pain and absence of a 'deep tender spot'. In this condition it is difficult to discriminate between a chronic infection of the gall-bladder or common duct and a pelvic appendicitis of the type which occurs in a long appendix with a bulbous end containing a pocket of pus.

In such circumstances it is very likely that the gall-bladder will be blamed for what are really appendiceal symptoms, because the inflamed appendix, on account of being deeply situated in the pelvis, gives no 'deep tender spot'. An example of this is seen in the following case:—

A patient who periodically had attacks in which she had rigors and fever, and whose condition had been consistently diagnosed as a cholecystitis or cholangitis, was explored. It was found that the condition was caused by a pelvic appendicitis, the very long appendix having a large bulbous end containing pus, which intermittently emptied into the bowel, thus giving a period of relief.

The long pelvic appendix gave rise to no local manifestations, but only to reflexly produced epigastric pain. The small intra-appendiceal abscess caused the rigors. *Fig. 547* is a diagrammatic representation of the appendix.

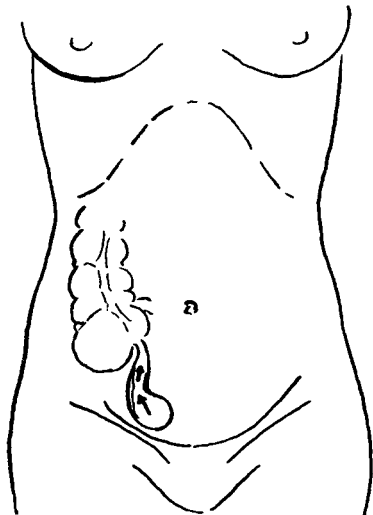


Fig. 547.—Pelvic appendix with long bulbous end containing a pocket of pus.

RIGHT HYPOCHONDRIAC PAIN AND TENDERNESS

Suppurating Hydatid.—Pain and tenderness over the right hypochondrium can be caused by a small suppurating hydatid in the vicinity of the gall-bladder.

A young man, aged 27, complained of pain and tenderness over the region of the gall-bladder. Neither the pain nor the tenderness was exactly over the gall-bladder. At operation a diffuse swelling was found lying in the liver close to the gall-bladder, of which *Fig. 548* is a semi-diagrammatic illustration. This tumour was a suppurating hydatid about as large as an orange.

This small, thick-walled, suppurating hydatid cyst situated in the liver, about one inch medial to the gall-bladder, was the cause of his gall-bladder-like symptoms. The suppuration in such a case is always mild and may go on for months, causing recurrent attacks of pain and tenderness just like those caused by gall-stones.

Suppurating Central Hydatid.—Sometimes a hydatid deep in the liver, which is therefore invisible at the operation and also too small to cause enlargement of the liver, is the cause of an epigastric pain or of a right hypochondriac pain, and of a mild jaundice—all of which manifestations may be regarded as being caused by disease of the

gall-bladder. In one case a patient who suffered from attacks of epigastric and right hypochondriac pain was operated upon twice in the belief that these symptoms were caused by gall-stone disease. No lesion of the gall-bladder was discovered at either operation. Years afterwards, a careful exploration of the liver revealed a hydatid deep in the liver, which obviously had been the cause of his previous trouble.

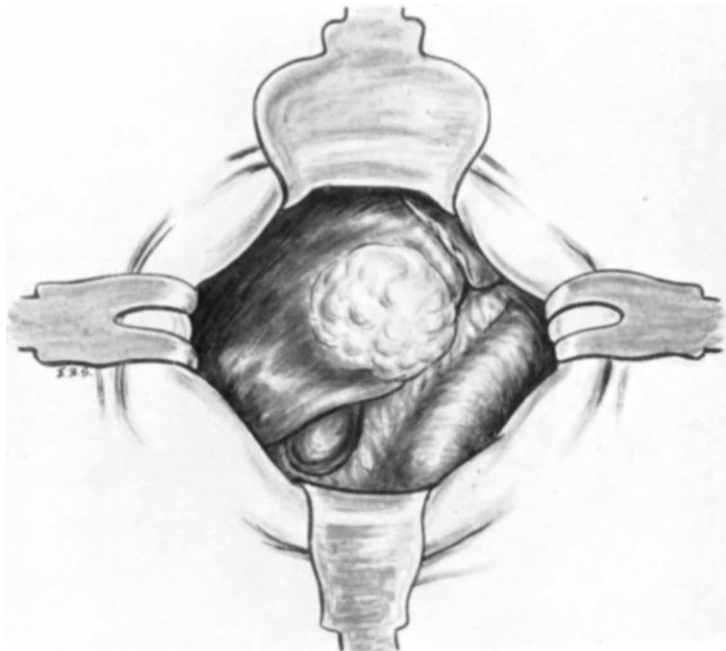


Fig. 548.—Hydatid of the liver about one inch medial to gall-bladder.

Suppurating Hydatid Communicating with the Gall-bladder.—Tenderness and pain over the gall-bladder region can also be caused by a hydatid of the liver communicating with the gall-bladder, as in the following case :—

A woman, aged 60, gave a history of attacks of acute pain in the epigastrium and over the region of the gall-bladder. When examined she was very tender over what appeared to be an inflamed and enlarged gall-bladder.

A diagnosis of empyema of the gall-bladder, the result of gall-stones, was made. At operation it was seen that there was an inflammatory mass in the region of the gall-bladder. It appeared to be an empyema of the gall-bladder except for the fact that it was situated too far medially. Gall-stones could be felt in the fundus of the gall-bladder, which was fused with

this inflammatory mass. The cystic duct and artery were divided, and while the gall-bladder was being removed it was seen that it communicated with another sac, which was full of pus. Finally it was found that this was a hydatid, which had opened into the gall-bladder (*Fig. 549*).

Tender Liver from Congestive Heart Failure.—Indefinitely localized right hypochondriac pain and diffuse tenderness are often indications of a painful and tender liver resulting from an early

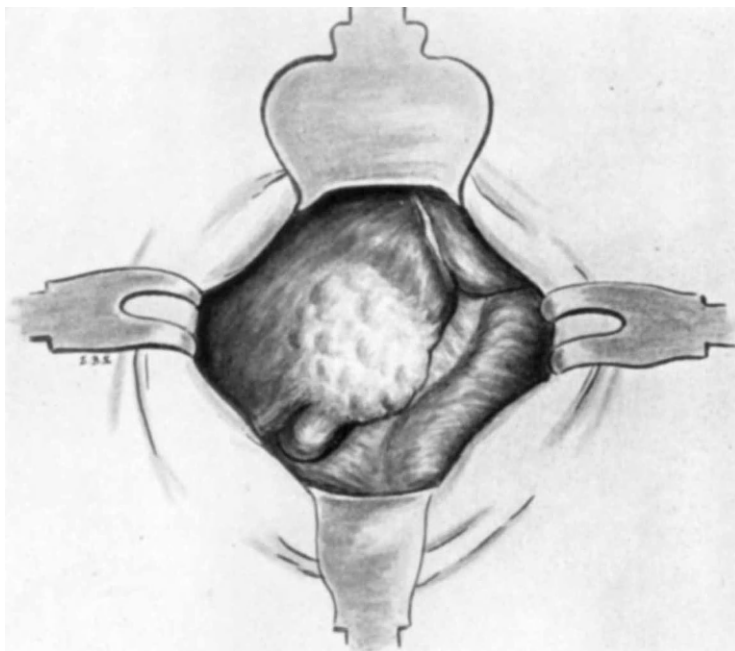


Fig. 549.—Hydatid of the liver communicating with the gall-bladder.

congestive heart failure. As these symptoms and signs, if loosely observed and appraised, are very like those of a cholecystitis, and, furthermore, as there is usually a negative cholecystographic shadow—the result of a disturbance of liver function—such cases often find their way to the operation table under the belief that they are due to gall-stones.

The great importance of discriminating between this congestive liver condition and a cholecystitis lies in the fact that operation, even an exploratory one, is frequently followed by fatal results, because the congestive heart failure may result in post-operative pulmonary trouble or a complete breakdown of the circulatory mechanism.

The following is an example of a case of this type :—

A female patient complained of hypochondriac and ill-localized epigastric pain. The pain came in attacks and was fairly severe ; sometimes nausea was associated with it. The tenderness was a little diffuse, and besides being over the gall-bladder, it was situated over an area of adjoining liver. The patient was a little short of breath, and had a blood-pressure of about 160 mm. A diagnosis of gall-stones was made, and the patient was sent into hospital for operation.

At operation difficulty with the anæsthetic was experienced. Even when given a very little ether, she at once became cyanosed. When the abdomen was opened, the liver was found to be very much enlarged and venously congested, its edges being rounded, not like the sharp edges of the normal liver. The gall-bladder appeared to be normal, and was not removed. A few days after the operation the patient died of heart failure.

To the out-patient physician the patient presented no very evident signs of heart failure before her operation.

The confusion in such a case is even greater when the pain and tenderness are accompanied by a slight jaundice, which not uncommonly arises from a ' congested ' liver.

GALL-BLADDER DYSPEPSIA

Gall-stones may cause either a nauseous or a flatulent painless dyspepsia, or a painful dyspepsia with gastric or duodenal-ulcer-like symptoms.

Nauseous Dyspepsia.—The following case-history is an example of the nauseous type :—

A middle-aged woman complained that she used to feel a little nauseated after meals. She said she always felt " bilious ". She had no other symptoms. Her cholecystogram showed that she had one small stone—a cholesterol stone. When this stone was removed, with, of course, her gall-bladder, the patient had no more nauseous symptoms.

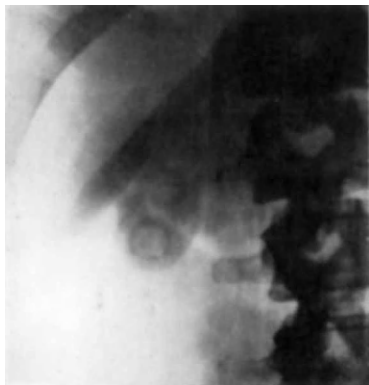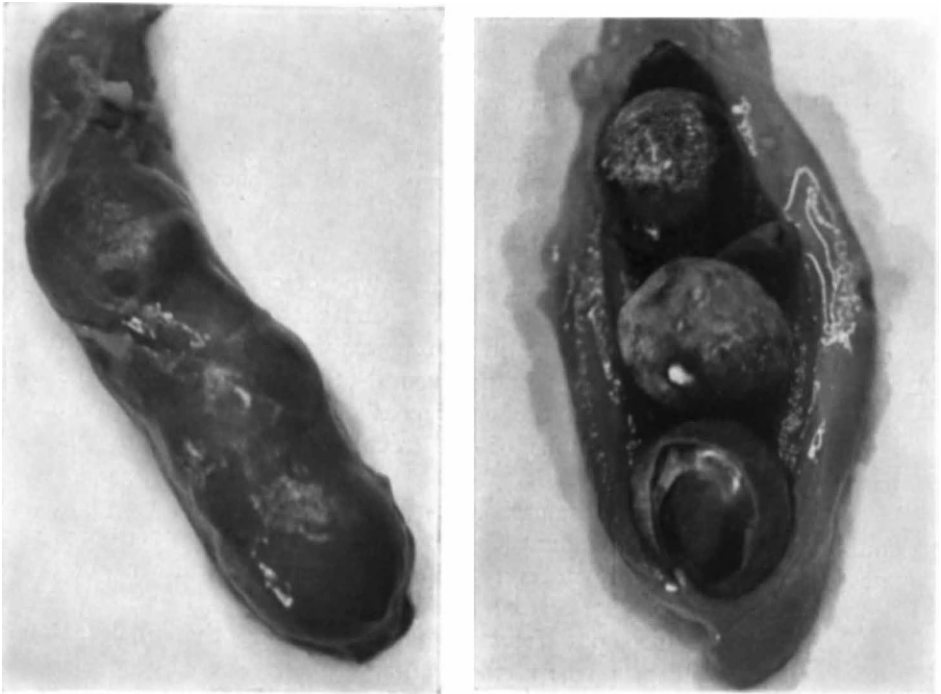


Fig. 550. — Radiograph showing faint shadow of gall-bladder with large cholesterol gall-stones.

Flatulent Dyspepsia.—Since it is known that gall-bladder disease is characterized by a flatulent dyspepsia, there has been a tendency to regard most cases of intractable flatulent dyspepsia as possibly caused by gall-stones, for the very natural reason that if such is the cause it is curable by operation, whereas if it is of gastric origin and neurogenically caused it is difficult to cure. Since, too, the pathology of

the gall-bladder has come to be better understood, and we have learnt more about neurogenic gall-bladder and non-calculous chronic cholecystitis, the gall-bladder has come to be still more blamed as the cause of flatulent dyspepsia.

Furthermore, cholecystographic evidence based on careless technique and lack of understanding of the true nature of the absence of a cholecystographic shadow is often adduced as confirmation of a diagnosis that a flatulent dyspepsia is caused by disease of the



A

B

Fig. 551.—Same case as *Fig. 550.* A, The gall-bladder after removal;
B, The gall-bladder opened, showing large cholesterol stones.

gall-bladder. In many such cases no pathological condition of the gall-bladder has been found at operation, although the surgeon has consoled himself with the reflection that the gall-bladder had been the subject of infective chronic cholecystitis. The subsequent history of these patients has proved that the lesion causing the dyspepsia was other than disease of the gall-bladder. The truth is that a flatulent dyspepsia is often caused by neurogenic disorder of the stomach, and that many cholecystectomies which have been

undertaken for flatulent dyspepsia, where no definite pathological lesion is visible in the gall-bladder, are failures.

Dyspepsia due more to Gall-stones than to Cholecystitis.—The following case-record shows a typical case of flatulent dyspepsia due to large cholesterol gall-stones :—

A female patient came under notice because, for the first time, she had developed a pain—not at all severe—under both shoulder-blades. For years she had had a flatulent indigestion, complaining of marked belching of wind and sour eructations, but had never had any painful symptoms. She also had a feeling of distension after meals. X rays showed a faint shadow of the gall-bladder with large gall-stones in it—stones so large that she must have had them for years. *Fig. 550* is a radiograph of her gall-bladder, and in *Fig. 551* are shown colour photographs of the same case.

At operation, many large cholesterol gall-stones were found. Microscopical examination of the wall of the gall-bladder showed flattening of the mucous membrane, with scanty, patchy, round-celled infiltration (*Fig. 552*).

Fig. 553 is a radiograph of a similar type of case. Microscopic examination of this gall-bladder showed that there was a degree of chronic cholecystitis, that the mucous membrane was papillary in type, and that there was a patchy round-celled infiltration in the mucous membrane and in the outer coat of the gall-bladder wall. In *Fig. 554* are photographs of the microscopical section in this case (Dr. A. Brenan).

Although in both these cases gall-stones were present for a great number of years, the amount of cholecystitis caused by them was not great, and certainly not great enough to prevent quite a good concentration of the bile.

These cases are put forward as illustrations that in cases of flatulent dyspepsia where the gall-stones may not be as big or as numerous as these are, and may not show as definitely as these do, an almost normal cholecystographic shadow may be present and yet cholesterol gall-stones may be the cause of a flatulent dyspepsia.

Dyspepsia due to Cholecystitis only.—On the other hand, it must not be forgotten that in a case of cholecystitis without stones the gall-bladder may at operation appear normal. It has been the experience of many surgeons that a woman has suffered from flatulent dyspepsia, that she has been operated upon by a surgeon with perhaps a poor knowledge of the 'living pathology' of the gall-bladder, and her gall-bladder pronounced normal. It has then happened that at a subsequent examination a negative cholecystogram



A



B

Fig. 552.—Microphotographs of a section of the wall of the gall-bladder shown in *Figs. 550, 551.* A, High-power; B, Low-power.

has indicated disease of the gall-bladder and a cholecystectomy has cured the dyspepsia. In these cases, microscopical sections have demonstrated that the gall-bladder was actually the subject of a chronic cholecystitis.

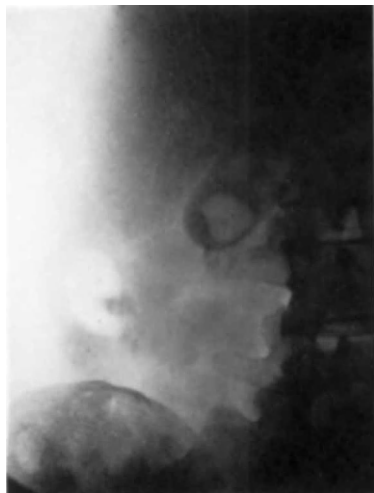


Fig. 553.—Radiograph showing negative shadow in a case of cholelithiasis.

Painful Dyspepsia with a Duodenal-ulcer-like Syndrome.—

The following case record is a good example of a phase of cholelithiasis the manifestations of which may be mistaken for those of duodenal ulcer :—

A man, aged about 50, complained of pain coming on very consistently three hours after meals. He had a tender spot which appeared to be over his duodenum. In his history, a periodic remission of symptoms, like that of a duodenal ulcer, was noted. He had been for twelve months under treatment for a duodenal ulcer. One day he got an attack of severe pain which doubled him up, and required

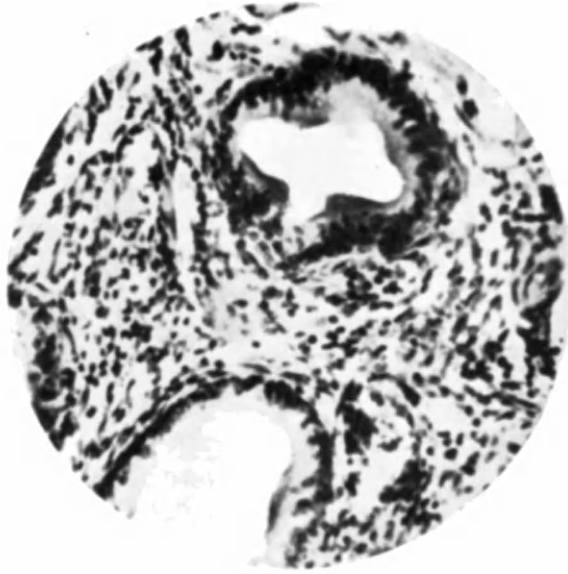a large dose of morphia for its relief. The severity and nature of his attack of pain created a suspicion that he was suffering from gall-stones. At operation the gall-bladder on examination was found to be tightly packed with stones.

ACUTE CHOLECYSTITIS

Suppurating Central Hydatid.—The distinction between central suppurating hydatid and acute cholecystitis in which there is a good deal of epigastric pain and a mild jaundice due to an infection spreading from the gall-bladder perhaps into the common duct, is sometimes very difficult. The following is a typical case-history illustrative of this type of diagnostic difficulty :—

An operation sister had for two years suffered from attacks of severe epigastric pain followed by vomiting. Sometimes the vomiting would ease her pain. In these attacks her temperature was 100°. In one of them, evidence of a pleurisy in the lower and front part of the chest was found. In the belief that her gall-bladder was diseased, a cholecystostomy was performed, and her surgeon was quite satisfied that a chronic cholecystitis was the cause of her trouble. Her attacks continued.

Her surgeon, feeling that the cholecystostomy was inadequate to deal with what he thought was a cholecystitis, performed a cholecystectomy. This operation, too, failed to remove the cause of her trouble, for still her attacks continued.



A



B

Fig. 554.—Microphotographs of a section of the wall of the gall-bladder shown in *Fig. 553*. **A**, High-power; **B**, Low-power.
(*Dr. A. Brennan.*)

When seen she was very ill and had become slightly jaundiced. Her temperature was 103° . She was tender over the epigastric area and over the scars of her previous operation.

Fig. 555 is a radiograph of her liver, in which it will be noticed that, on the right side, the dome is higher than it should be. At operation a central hydatid of the liver was found.

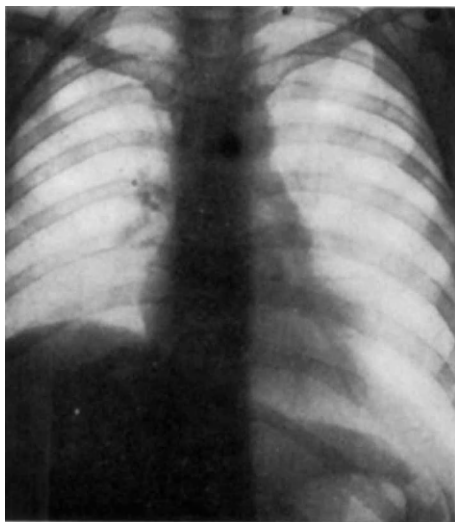


Fig. 555.—Radiograph showing the raised upper surface of the right lobe of the liver from a central hydatid. (From the *Journal of the College of Surgeons of Australasia* and *Medical Journal of Australia*.)

Appendicitis in a High Appendix.—The symptoms of acute cholecystitis are often most accurately mimicked by those of an acute appendicitis in an appendix which has failed to descend and which lies under the gall-bladder. In such a condition the differential diagnosis is exceedingly important, for acute appendicitis situated in the upper part of the abdomen demands immediate operation; it is a very serious condition and may be followed by a fatal peritonitis.

The mistake may arise if, as is the custom in the case of an acute cholecystitis, the surgeon allows the acute condition to subside before operating.

The following case-history is an example of this problem of differential diagnosis:—

A young male patient became ill with acute pain, first in his epigastrium, then over his gall-bladder. He became very sick and on the second day of his illness he had a temperature of 104° and a pulse-rate of 120. His medical attendant, thinking that his condition was due to gall-stones, and that in this condition he had some latitude in regard to an operation, waited

for the attack to subside. When, six days after the onset, I saw the patient, he was very sick indeed, and so rapidly had his symptoms progressed and so sick was he that it was perfectly obvious he had an appendiceal abscess in the region of the gall-bladder and was in a very dangerous condition. Operation confirmed the diagnosis. The patient recovered.

Acute Cholecystitis in a Low Gall-bladder: Diagnosis from Acute Appendicitis.—Where the gall-bladder is in a low situation and becomes inflamed, the pain and tenderness may be in the region of the appendix, and the syndrome of this low cholecystitis may thus simulate that of an appendicitis. An example of this is seen in the following case :—

A young woman complained that occasionally she had epigastric pain after food, and that she suffered from attacks of pain and tenderness over the appendiceal area. Operation disclosed an inflamed gall-bladder situated in the appendiceal area and full of small gall-stones. Her gall-bladder condition might well have been missed at what was regarded as a routine appendiceal operation.

LEFT-SIDED EPIGASTRIC AND LEFT THORACIC PAIN

Anginal Pain.—It has been suggested that where a gall-bladder is highly situated it may cause symptoms like those of angina. It may be that in a high gall-bladder its innervation comes from a segment in the spinal cord higher than usual, and for this reason the pain is higher. In this relation, the following is a very interesting history :—

Gall-stone Disease Mistaken for Angina.—

A female patient, aged 30, had three ‘anginal’ attacks—twice while being driven in a car, and once while sitting quietly in the evening. Each of these attacks occurred after a rather big meal. In one she had felt uncomfortable for some hours previously, but in the other she had had no warning.

In the attacks she would get a sudden pain in the mid-epigastrium, extending outwards across both sides of the sternum. The pain was very severe in the left nipple area and under the upper part of the body of the sternum. It was associated with a very dreadful feeling of impending death. During the severe attacks she had palpitation. Her husband, a doctor, had been present during two of the severe attacks, and noted that she was pulseless, with dilated pupils; he remarked that the “attacks closely resembled angina”. She could not sleep on the left side, as it caused uneasiness and discomfort (often a gall-bladder symptom).

This patient had been under treatment for “angina” and for a vague ill-health. A cholecystographic examination revealed a very large gall-bladder packed with small gall-stones. The diagnosis of gall-stones was a great surprise. Doctors who had investigated her “angina” had not even suspected gall-stones. The gall-bladder was

removed. Ten years later, her husband wrote that the operation had completely cured her, and that she had never had any more of her "anginal" attacks.

Gall-stones Present but not the Cause of Anginal Symptoms.—On the other hand, the surgeon must be careful not to operate on a patient with gall-stones who also has angina. An example of such a case is the following :—

A male patient complained of severe constricting pain which came on over the precordium, the left scapular region, and the left arm. It was preceded by a rumbling of wind and sweating. The attacks of pain commenced suddenly and after about fifteen minutes ended suddenly. He said that he became yellow after the attacks. In the last few days he had several attacks, and after them passed urine the colour of black tea. He had also a slight occasional epigastric pain, lasting only a few minutes. A radiograph showed that he had a gall-bladder packed full of gall-stones. An operation was considered, but the patient died of angina.

CHOLANGITIS

Portal Pyæmia.—Sometimes a portal pyæmia in its earlier stages will be mistaken for an infected gall-bladder or a cholangitis ; especially as, in these conditions, the septic symptoms are sometimes associated with a very mild jaundice and a diffuse tenderness over the liver.

The confusion between an infected gall-bladder and bile-ducts and a portal pyæmia is seen in the following history :—

A patient suddenly developed a pain in the right shoulder extending down his arm. He had a rigor, and his temperature rose to 104° . The rigors continued and his temperature rose still higher, to 105° , and he became diffusely tender over his gall-bladder and liver. It was thought that he had a stone, perhaps in the common duct, and that this had given rise to a cholangitis, or that, as his temperature had risen in a steeple-like way to 105° , and he had had a succession of rigors, it might be a case of liver sepsis. At operation, one large abscess was found in the liver near the gall-bladder. It was a case of portal pyæmia, and the patient died in three months. The origin of the affection could not be discovered.

CHAPTER LXI
CHOLECYSTECTOMY

CHOLECYSTECTOMY is the operation which is most frequently employed for the surgical cure of diseases of the gall-bladder. It is one which, if not meticulously performed, can do more harm than good, and one in which many accidents can happen—accidents fraught with serious consequences. Moreover, it is perhaps one of the most common operations in surgery. For these reasons, a technique which I have found invaluable is given here in detail.

ESSENTIAL PRINCIPLES

The essential principles in performing a cholecystectomy are : (1) Not to handle the liver or the small intestines ; (2) So to expose the gall-bladder that it can be accurately dissected under vision ; (3) To enucleate the gall-bladder along its subserous plane, so that the liver substance will not be exposed, and the gall-bladder bed can be completely covered with the serous layer.

Handling the Liver.—The custom of using the liver as a tractor, in order to bring the gall-bladder for purposes of dissection on to the surface of the abdomen, causes diffuse injury to the liver tissue and, as a result, post-operative sickness, nausea, and anorexia.

Handling the Intestines.—The small intestine should not be handled or exposed. Care in this respect avoids post-operative shock. It also minimizes any disturbance of the delicate motor function of the intestine and thus ensures a smooth post-operative convalescence.

Exposure of the Gall-bladder so that it can be Dissected under Proper Vision.—Most of the unfortunate accidents—and they have been many—are owing to the fact that the operator is unable to see properly in order accurately to dissect the gall-bladder. Thus he is not able to avoid dividing vessels, and therefore cannot prevent the embarrassing bleeding which obscures the anatomical details. The consequence is that reliance is placed more on the sense of touch than on the sense of sight ; and under such circumstances, injuries to the ducts, especially in very diseased conditions of the gall-bladder, are very prone to happen—and do happen.

Enucleation of the Gall-bladder along its Subserous Plane.—Unless the gall-bladder is dissected out of its bed along its subserous

plane, peritoneal tissue will not be available to cover the gall-bladder bed accurately. It is the failure to close over every particle of raw surface resulting from the enucleation of the gall-bladder which causes post-operative symptoms of dyspepsia, or of severe pain and vomiting in relation to meals. In some cases where I have operated for the relief of such distressing symptoms after cholecystectomy, I have found duodenal stenosis resulting from the adhesion of the duodenum to the bare area left after the removal of the gall-bladder—the bare area which had not been properly peritonealized. In other cases I have found the duodenum firmly invaginated and fixed in this bare area; and although a stenosis of the duodenum had not resulted, it was obvious that the dragging of the heavy liver on the duodenum, as well as the constant respiratory movement of this heavy liver, was the cause of the pain and other symptoms which were most unpleasant sequelæ in these cases of cholecystectomy.

General Objective.—The objective of the surgeon in the operation of cholecystectomy should be as follows:—

1. The careful selection of an anæsthetic which will minimize shock or pulmonary complications in patients who are usually old, and who have therefore a poor circulatory reserve; and of an anæsthetic which at the same time does not cause an exaggerated respiratory movement that would embarrass the operator.

2. An incision the main aim of which is the exposure of the cystic and adjacent part of the common duct, the dissection in this region being the most difficult and the most important part of the operation.

3. The adequate protection of the edges of the wound from infection and from trauma, both of which may occur from the manipulation necessary in removing the gall-bladder.

4. The adequate exposure of the gall-bladder, its cystic duct, and the common duct to full view as they lie in the peritoneal cavity—an exposure which involves: (a) spreading the wound wide open; (b) clearing the abdominal cavity in the vicinity of the gall-bladder from the small intestines, the hepatic flexure, and the stomach; (c) pushing the duodenum towards the left and over the spinal column in order to open and expose the angle between the cystic and common ducts, and to make taut the structures at the neck of the gall-bladder, and thus unravel a sometimes tortuous cystic artery and straighten the cystic duct.

ANÆSTHESIA

The choice of anæsthetic can be made from the methods of anæsthesia that follow, any one of which may be selected because

it is the method most suitable to the circumstances connected with the particular patient who is to be operated upon.

Light Ether Vapour Anæsthesia.—This method of anæsthesia, which has been described in Chapter XLVII, p. 463, should be employed for routine cholecystectomy in healthy people. The patient is fully anæsthetized for the making of the incision, insertion of the special frame retractor, and exclusion of the intestines from the operation field. But during the main part of the operation, while the surgeon is operating (with the gentlest manipulations) on the insensitive gall-bladder, the anæsthetist should reduce the amount of anæsthetic to a minimum. Thus, if the anæsthetist works in conjunction with the surgeon, this ether anæsthetic can be given so lightly that operation shock is lessened and pulmonary complications are minimized.

Gas and Oxygen.—The objection to gas and oxygen anæsthesia is that, as it does not relax the abdominal muscles, the intestines crowd round the gall-bladder, and therefore make it difficult to operate in the abdominal cavity. Furthermore, the exaggerated respiratory movement makes dissection of the gall-bladder difficult. The use of the operating frame, in which visceral retraction can be used, overcomes the first objection; and the intratracheal administration of the gas through a nasally introduced catheter considerably lessens the respiratory movement, and obviates the second objection.

High Spinal Anæsthesia.—In patients with bronchitis or emphysema, or other chest conditions, high spinal anæsthesia, after the method either of Kirschner or of Howard Jones, is especially suitable (*see* Chapter XLVII, p. 472).

Local Anæsthesia.—Sometimes, in very old people, cholecystectomy can be performed under local anæsthesia. The abdominal wall is injected as described in Chapter XLVII, p. 467, and the peritoneum round the common duct and the gall-bladder is injected with $\frac{1}{2}$ per cent novocain solution. Diffusion anæsthesia (*see* p. 471) may be used to anæsthetize the peritoneum and mesenteries in the vicinity of the gall-bladder; but mesenteric injection of $\frac{1}{2}$ per cent novocain solution, using Kirschner's high-pressure local anæsthesia apparatus, has a less disturbing effect in very debilitated people.

POSITION OF THE PATIENT

The patient should be placed in a rather high reverse Trendelenburg position. In this position the liver falls somewhat into the abdominal cavity and renders the gall-bladder more accessible;

also one is better able to project the operating-room light on to the area of the cystic duct. *Fig. 556* shows a diagram of the position of the patient and the placing of the operating-room artificial light.

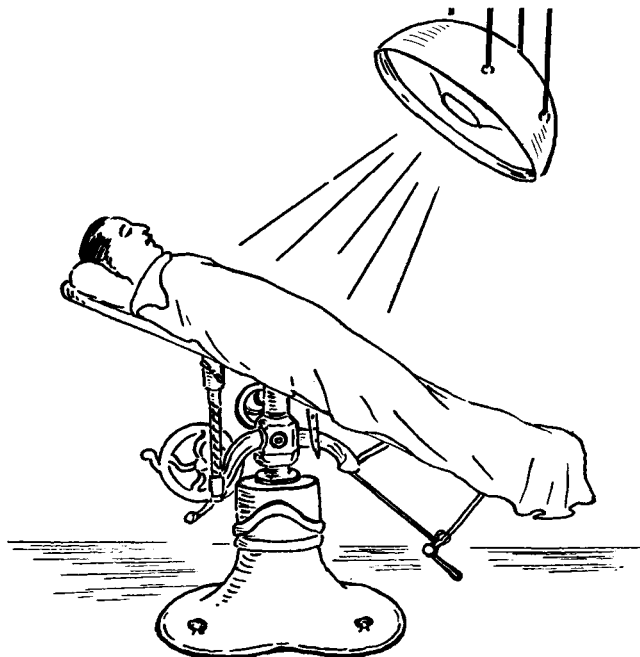


Fig. 556.—Patient in the reverse Trendelenburg position.

THE INCISION

Since cholecystectomy rather than cholecystostomy is the operation of choice, the objective is a perfect exposure of the cystic and the common ducts and their junction—a point on the right side of the gastro-hepatic ligament about $1\frac{1}{2}$ in. below the ensiform cartilage. Therefore the best incision is one made on the right side, slightly paramedian, as high into the epigastric angle as possible, and even carried a little to the left of the midline in its upper part (*Fig. 557*). A Kocher does not expose the ducts so well as a paramedian incision.

In order to obtain the spring-like action of the muscle which retains the

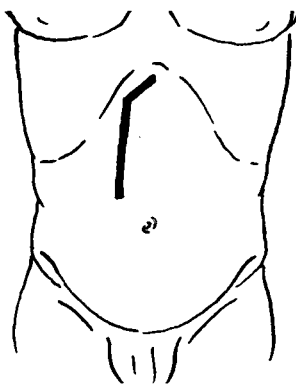


Fig. 557.—The incision.

retractor in position, a somewhat smaller incision than usual—one about 4 in. long—should be made.

The rectus muscle should be split a short distance from its medial edge, in order to provide for a somewhat safer closure of the wound. The reason for this is that sutures cut out very readily from the posterior rectus sheath, the fibres of which run transversely, unless there is a small section of rectus muscle with its longitudinally

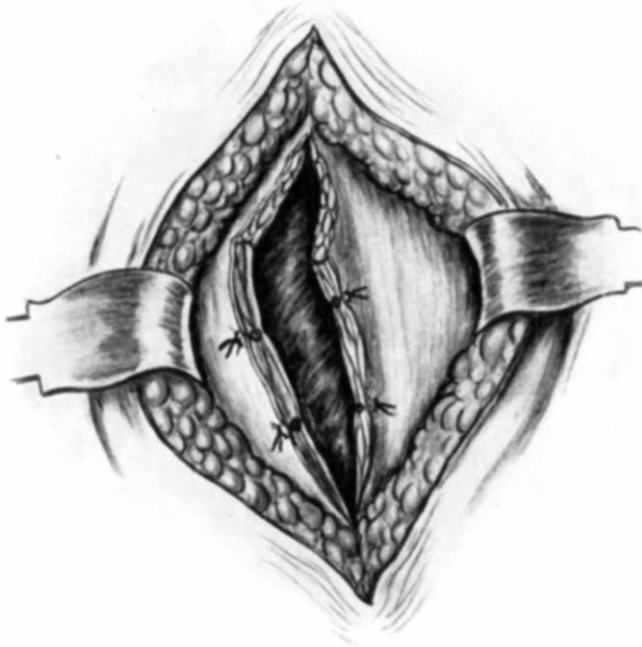


Fig. 558.—X-sutures controlling bleeding arteries in cut rectus muscle.

running fibres left to prevent this cutting out. Bleeding arteries in the muscle, which are sometimes troublesome, are controlled by an X-suture including the sheath as well as the muscle (*Fig. 558*).

A costal incision (*see p. 524*) or a Kocher may be used, but these do not permit such a good exposure of the ducts as the paramedian.

ISOLATION OF THE GALL-BLADDER

The wound should be spread so as to expose the gall-bladder as it lies in its natural position in the abdominal cavity. This is achieved by the use of the four-bladed operating frame and 'mechanical

hands'. The steps of the procedure, and its particular application to gall-bladder operations, are described in detail in Chapter XXXIV, pp. 329-348.

The gall-bladder and its ducts now lie in good view, under a good light, and completely isolated from the mobile viscera, so that if long-handled instruments—knife, dissecting scissors—are used, a very accurate and bloodless dissection can be made, even in the fattest patient.

With such an exposure it is never necessary to drag the liver on to the abdominal wall in order to obtain access to the cystic duct; the gall-bladder is quite accessible in its natural position in the abdominal cavity.

PATHOLOGICAL INVESTIGATION

If the patient has been or is jaundiced, an examination is made of the pancreas for malignancy or for a chronic inflammation; of the common duct for a carcinoma or a stone; of the liver for a hydatid, cirrhosis, or malignancy; and of the spleen for enlargement.

In the absence of a history of jaundice, the examination will be focused on the gall-bladder, especially if the symptoms suggest its involvement rather than that of its ducts. Usually any disease of the gall-bladder is obvious, and any calculi can be felt. If, however, no pathological lesion is manifest—and this is not an unusual occurrence where the diagnosis has been based more on X-ray than on clinical findings—a closer examination of the gall-bladder is made to detect the less obvious forms of cholecystic disease. Will the gall-bladder empty its contents by squeezing it, showing the efficiency of the cystic duct? Is its wall adherent to neighbouring structures? Is it less transparent than normal, thickened, or covered with an accumulation of fat? Is the gland at the neck of the gall-bladder enlarged? What is the colour of bile withdrawn by a hypodermic needle; is it dark green and viscid, giving evidence of stagnation?

If no cholecystic disease is obvious, the question then arises whether the gall-bladder should be removed. If the main pre-operative evidence has been the absence of a cholecystographic shadow rather than definite clinical symptoms and signs, and if there is no disease of the liver which would account for this negative cholecystographic shadow, then the gall-bladder should be removed; for the symptoms may be due to a neuromuscular disturbance, or to some minor grade of chronic cholecystitis. Often in such cases the mucous membrane of the gall-bladder will be found studded with lipoid deposits. If, however, no cholecystic disease is manifest, but

there are signs of disease of the liver, the gall-bladder should not be removed; for the operation in these circumstances may be dangerous, because the diseased liver is probably the cause of both the symptoms and the negative cholecystogram, and much operative interference in such a condition may be followed by a fatal result. In these doubtful cases, however, it is not so much a case of removing an undiseased gall-bladder as of removing the gall-bladder under the impression that it is the cause of the trouble—the real cause remains undiscovered.

DISSECTION OF THE GALL-BLADDER

In cases where the tissue planes are normal, the operation should always be started from the cystic duct, for in this situation, where there is adequate subserous fat, it is always possible to find the correct plane, a subserous one, and it is also easy to tie the arterial supply of the gall-bladder at its source, thus avoiding multiple division of vessels.

Cholecystectomy started from the Cystic Duct.—

Exposure of the Cystic and Common Ducts.—If the pouch of Hartmann is big and distended with bile, and obscures the cystic-common-duct angle, the gall-bladder is partially aspirated of bile through a fine needle in order to lessen the size of the pouch. The

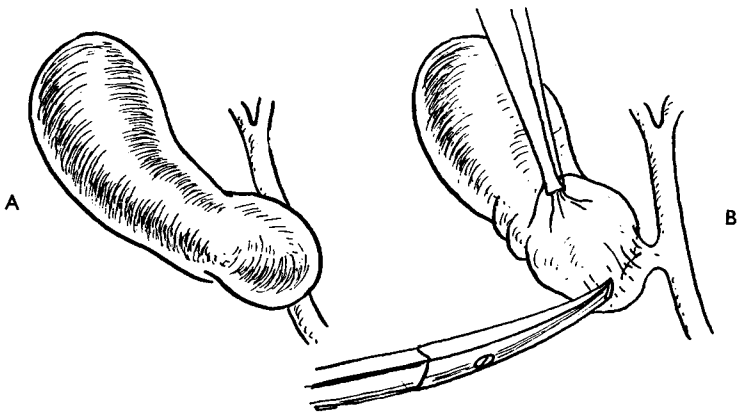


Fig. 559.—A, Pouch of Hartmann distended with bile. B, Dissection after aspiration of bile. This exposes the cystic and common ducts.

overlapping pouch is then easily and safely dissected off the cystic and common ducts. (Fig. 559.)

The enucleation of the cystic duct, and isolation of the adjoining part of the common duct, which is the keystone to the operation, is then begun. The isolation and division of the cord-like cystic duct

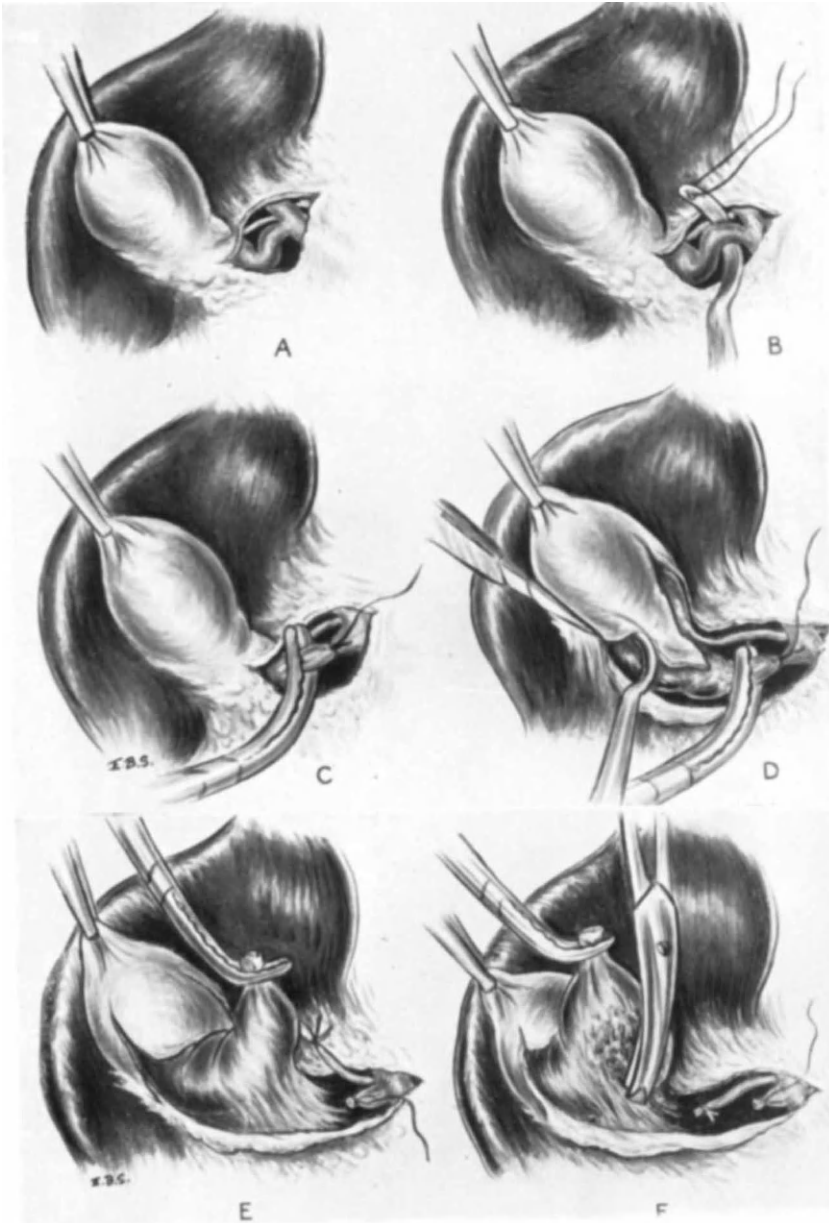


Fig. 560.—Steps in the technique of cholecystectomy. **A**, Incision in peritoneum over the cystic duct and junction of the cystic and common ducts ; **B**, Isolation of cystic duct ; **C**, Cystic duct ligated (one end of ligature left long) and clamp applied to duct on its gall-bladder side ; **D**, Dissection of subperitoneal plane by the blunt dissector ; **E**, Cystic artery ligated some distance from where the cystic duct is divided ; **F**, Gall-bladder dissected from its bed.

at once exposes the proper tissue plane along which the gall-bladder should be dissected from the liver. The division of the cystic duct also facilitates the ligation of the cystic artery. The successive steps in the operation are illustrated in *Fig. 560*.

With a No. 15 Bard-Parker blade (*Fig. 561*) fitted to a long handle, an incision is made in the peritoneum over the cystic duct and continued on to the common duct for about half an inch (*Fig. 560, A*). With 10-in. curved spade-pointed dissecting scissors (*Fig. 562, A*) and a long McCormick dissector (*Fig. 562, B*) the



Fig. 561.—Bard-Parker blade.

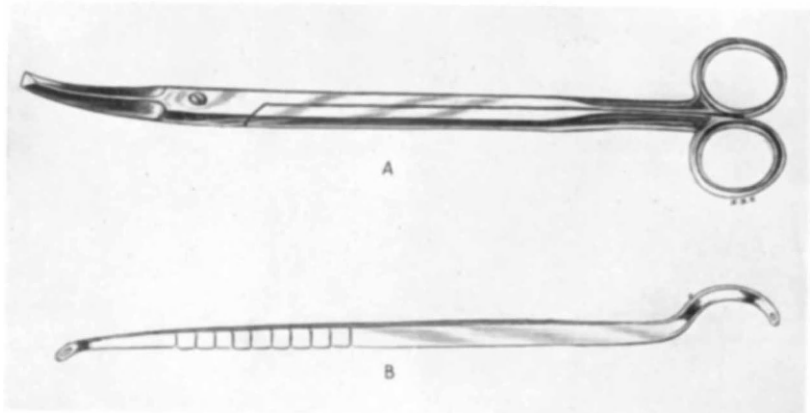


Fig. 562.—Instruments used for cholecystectomy. A, Long dissecting scissors; B, McCormick dissector (long).

cystic duct is isolated and ligated (*Fig. 560, B*). To prevent leakage and also to act as a tractor, a Moynihan clamp is placed on the gall-bladder end of the duct (*Fig. 560, C*). The duct is then divided. The peritoneal incision is now continued on each side of the gall-bladder half an inch from its junction with the liver. It is difficult, however, to divide this peritoneum without injuring the subjacent gall-bladder wall, especially if the gall-bladder is filled with stones or is flaccid. Under such circumstances, the best way of dividing the peritoneum over the gall-bladder and separating peritoneal leaves for covering its bed is shown in *Fig. 560, D*. The peritoneum is raised with the curved point of the McCormick dissector, half-inch by half-inch, each half-inch being divided with the long-handled knife after the peritoneum has been raised. The S-shaped part of the

gall-bladder is now dissected until the cystic artery shows as it divides to enter the gall-bladder well away from the right hepatic duct, at which level the artery is ligated (*Fig. 560, E*).

The gall-bladder is now removed by dissecting along its subserous plane—a continuation of the plane which was found around the cystic duct (*Fig. 560, F*). The fundus is left attached to the liver, and the gall-bladder is temporarily used as a tractor.

Examination of the Common Duct.—At this stage the possibility of a common-duct obstruction should be investigated. If when dissecting and dividing the cystic duct it appears to be dilated, or if

the common duct is obviously dilated, or if there has been a previous history of jaundice—then, in any or all of these circumstances, remove the ligature from the cystic duct and try to introduce a flexible probe through it into the common duct. With the probe in position the common duct is palpated for any small and therefore unobvious stone, a big stone being easily found without the aid of the probe.

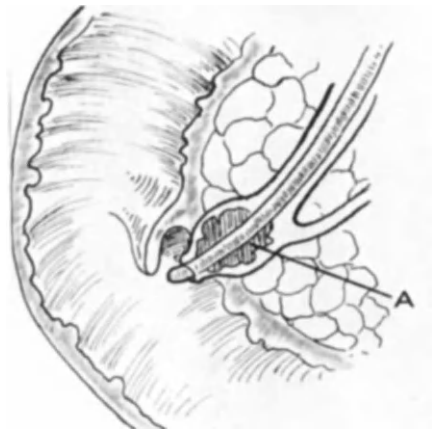


Fig. 563.—Diagrammatic sketch of a small flat stone (A) in the ampulla of Vater, lying against the side of the ampulla and presenting no obstruction to the probe.

The object of employing this method is to avoid opening the common duct unnecessarily. Its success depends on the dilatation of the cystic duct

which occurs if a stone has passed from the gall-bladder through the cystic duct into the common duct. If the probe cannot be passed by the cystic duct, the common duct must be opened, aspirated, and explored. If no stone is found, the opening is closed in two layers, using interrupted fine catgut sutures for the edges of the duct itself and running fine catgut sutures for the peritoneal cut edges.

If the patient has had no jaundice and no stone is palpable, and the cystic duct is quite small, and the stones in the gall-bladder are big ones, then an exploration of the common duct may be unnecessary and meddlesome. It must, however, be remembered that in about 20 per cent of cases of stones in the common duct there is no jaundice, and in these cases a small or impalpable stone is present.

Thus sometimes a small flat stone in the ampulla of Vater may lie against the side of the ampulla and give rise to only a mild jaundice, or none at all. It may be difficult to feel because it is surrounded by inflamed lobules of the head of the pancreas. Furthermore, it may present no obstruction to the probe (*Fig. 563*). In such a case it may be necessary to dislocate the first and second parts

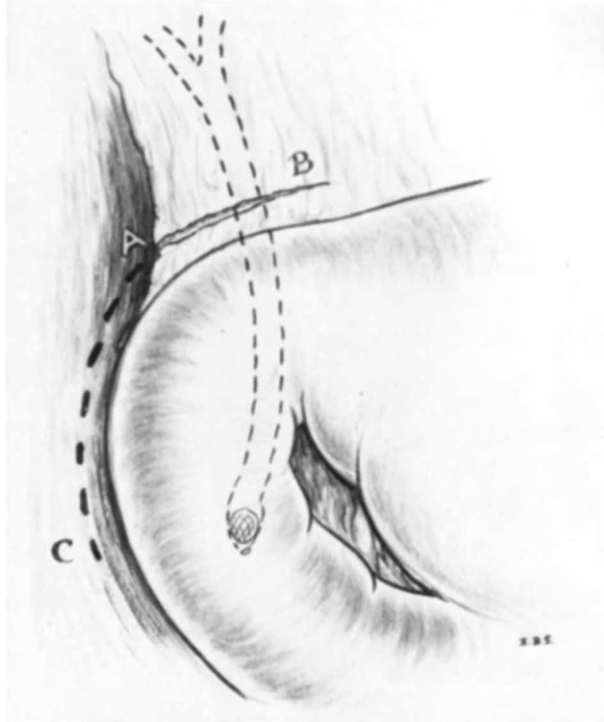


Fig. 564.—Peritoneal incision for dislocating the duodenum. **AB**, Incision over the superior border of the first part: **AC**, Incision over the lateral border of the second part.

of the duodenum in order to examine the duct and the ampulla of Vater more thoroughly with the probe in position, and if a stone is found to remove it by this route.

Dislocation of the Duodenum.—The first part of the duodenum can be dislocated by gently stripping it downwards after dividing the peritoneum along its superior border (*Figs. 564, 565*), care being taken not to injure the subjacent vessels.

If further dislocation is necessary, the incision in the peritoneum can be continued round the lateral side of the second part of the duodenum (after Kocher). The first and second parts of the duodenum

as well as the head of the pancreas can then be dislocated medially and forwards. Thus a very good exposure of the posterior surface of the duodenum and of the ampulla of Vater is obtained and any stone which may be impacted in the latter may be dealt with.

The Toilet of the Bed of the Gall-bladder.—After the investigation of the common duct, the peritoneal edges are sutured over the raw surface made by the removal of the gall-bladder (*Fig. 566*).

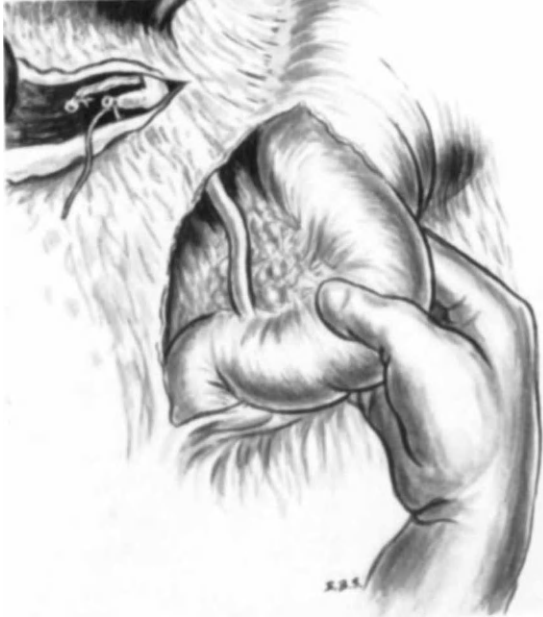

Fig. 565.—Dislocation of the duodenum.

The closure of the peritoneal edges over the cystic duct may be facilitated by threading on a needle one end of the ligature which has been used to tie the cystic duct and passing this end through the upper peritoneal leaf about half an inch from its edge (*Fig. 566, inset*). This little manœuvre buries the duct underneath the upper peritoneal leaf, and prevents its bobbing in and out between the peritoneal edges which, because they are so deeply situated, are being sutured with difficulty.

These peritoneal edges can be sutured very accurately by using a very small curved needle* and two needle-holders—one to insert the

* A small, full-curved Kelly atraumatic needle, with flattened shank, specially made by Messrs. G. F. Merson Ltd., Edinburgh.

needle and the other to pick it up. This detail of technique is of practical importance because it enables these peritoneal edges to be so accurately closed that scarcely any duodenal adhesions to the liver form—a matter of some importance in avoiding post-operative dyspepsia.

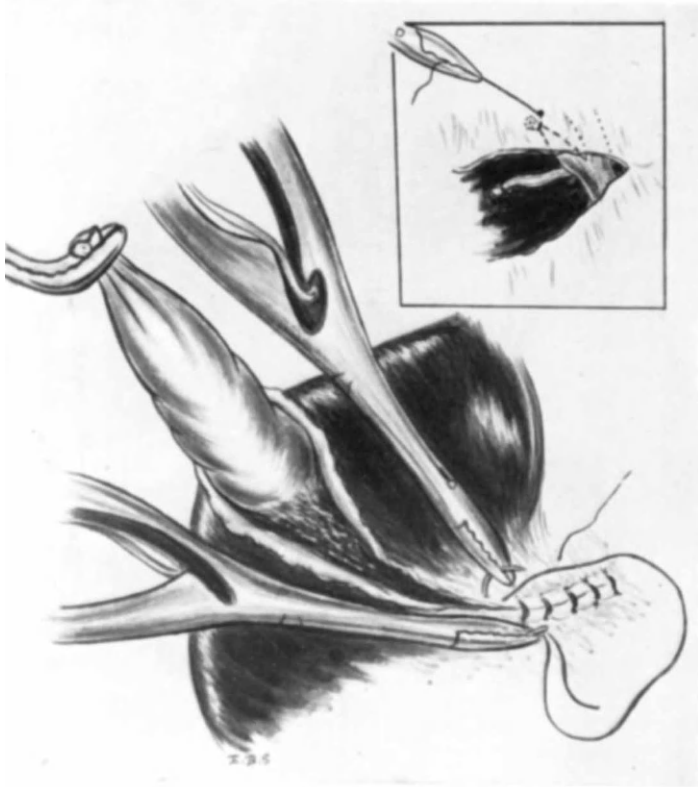


Fig. 566.—Suture of the peritoneal edges over the raw surface of the gall-bladder bed. *Inset:* End of the cystic duct ligature threaded through the upper peritoneal leaf in order to keep the cystic duct out of the way while suturing.

Cholecystectomy Started from the Fundal End.—When all the normal tissue-planes of the gall-bladder have disappeared as the result of inflammatory processes, or when the cystic duct has been ‘taken up’, as often occurs in the passage of a large stone into the common duct from a fibrosed, contracting gall-bladder, the dissection should be from the fundal end, commencing at the medial border of the gall-bladder (*Fig. 567*). At this point there are no big blood-vessels and the gall-bladder can be dissected from below upwards towards its arterial supply.

In fibrous gall-bladders the danger of opening into the liver substance of the bed of the gall-bladder is not great, because there is such a thick wall of fibrous inflammatory tissue that it can be split, leaving a good layer to cover the liver bed.

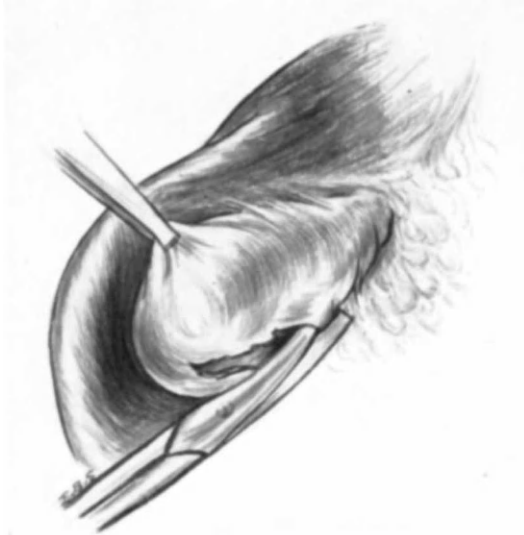

Fig. 567.—Dissection of the gall-bladder from the fundal end.

The gall-bladder should be dissected as far as the common duct, *and part of this latter structure should also be exposed* in order to be quite sure when ligating a shortened and dilated cystic duct that the common duct is not injured.

DRAINAGE

In the majority of cases of cholecystectomy it is safer to drain. There may be a sudden drainage of bile several days after the operation. This may be an indication that the ligature has burst off the cystic duct from an increased pressure in the common duct—a pressure which may have arisen as the result of an obstruction of a small stone in the common duct which has been overlooked. There may be drainage of bile after a cholecystectomy as a result of division of accessory ducts. In two cases, when removing the *fundus* of the gall-bladder, I found an accessory duct running into it. How often we unknowingly sever small accessory ducts, I am not prepared to say. Thus the occasional presence of accessory ducts is another argument for routine drainage.

In my opinion, there is also another useful aspect of drainage after cholecystectomy. There is experimental evidence to show that absorption of tissue juices or poisons from shed blood is a potent factor in causing post-operative thrombosis. Absorption of these tissue juices, which weep from the raw surfaces left after cholecystectomy, may be responsible for mild thrombosis and emboli, and therefore for many pulmonary and other complications. External drainage of these tissue juices prevents, I believe, their absorption into the general circulation, and I am sure it lessens the possibility of post-operative thrombotic phenomena. At any rate, since I have made a comparatively prolonged drainage a routine practice after cholecystectomy operations, I am firmly of the opinion that post-operative troubles have been rare in contrast with the era in which I drained only some of the cases, and then merely for a short period.

AFTER-TREATMENT

In the average case of cholecystectomy—that is, in the average risk—the after-treatment is carried out on the operation table, so to speak. If the liver is not handled, if the gall-bladder is cleanly dissected with sharp instruments, if the small intestines are not touched or handled, if the anæsthesia is very light: in short, if the operation is carried out as I have described, little after-treatment is necessary. The patients are rarely shocked or very sick; they vomit very little; they have only minor alimentary disturbance; and usually their bowels open naturally, or with but a small amount of aperient.

After-treatment in the Bad Case of Cholecystectomy.—Cholelithiasis is frequently found in association with other diseases, such as disease of the liver, circulatory deficiency, metabolic diseases such as gout or diabetes, or obesity. In such circumstances special pre-operative and post-operative treatment will be required, as is described in Chapter XXXVII.

POST-CHOLECYSTECTOMY PAINS

It occasionally happens that, after a cholecystectomy, a patient suffers from attacks of colicky pains, much the same as those which lead to his operation. In some cases, these pains are only of a temporary character and disappear in from a few weeks to a few months (*temporary post-cholecystectomy pains*). In other cases they become permanent (*permanent post-cholecystectomy pains*).

Temporary Post-cholecystectomy Pains.—The transient type of colicky pains which follow cholecystectomy are usually due to a mild obstruction of the common duct caused by gall-stone debris

which may have been massaged into the common duct during the operation, by blood-clots, or by mucus or inflammatory products. As a rule this obstruction clears up during the convalescence and requires little treatment.

Permanent Post-cholecystectomy Pains.—Pains may continue permanently after a cholecystectomy. They may be due to: (a) An incomplete cholecystectomy; (b) A stone in the ducts of the liver or in the common duct which has been missed; (c) A hepatitis or cholangitis; (d) A stricture; or (e) A spasm of the choledocho-duodenal sphincter.

Incomplete cholecystectomy is dealt with on p. 80.

Stone in the common duct which has been overlooked has already been considered on p. 708.

Stricture may follow a cholecystectomy in which the cystic duct is divided too close to the common duct. At operation its existence can be demonstrated by cholangiography, after the method described on p. 723.

Cholangitis gives rise to very definite and recognizable syndromes: to constitutional symptoms such as rigor, to fever, increase in the pulse-rate, and to a mild and variable jaundice.

Spasm of choledocho-duodenal sphincter: Frequently, where operation is undertaken with a view to relieving post-cholecystectomy pains, no apparent cause can be found. The common duct will perhaps be seen to be dilated. In these cases it is likely that the pains are due to a spasm (or an achalasia) of the choledocho-duodenal sphincter—the sphincter of Oddi. It is possible that the cholecystectomy has disorganized the autonomic innervation of this sphincter and has upset its rhythmic emptying action.

It has been found that this spasm is decreased by the administration of papaverine, scopolamine, or amyl nitrite; and that it is increased by morphia (Best¹).

Nygaard² has reported a case of cholecystectomy in a woman, which was followed by post-cholecystectomy colic, in which morphia or opium always brought on a colic, a clinical observation which is compatible with the experimental fact that morphia causes contraction of the sphincter of Oddi.

THE MANAGEMENT OF POST-CHOLECYSTECTOMY PAINS

Prophylaxis.—Preventive treatment is by far the most important part of the management of post-cholecystectomy pain: an experienced surgeon will always leave a clear common duct and will have few post-cholecystectomy troubles. Whether a stone obstructing the

common duct has been removed, or whether the common duct has only been opened and examined because there is a suspicion that it is obstructed, special care must be taken not to overlook any condition that would cause obstruction. In doubtful circumstances, every examination method should be used in order to be sure that this duct is clear. Besides palpation and scooping, the duct should be irrigated with saline and 'vacuum-cleaned' with an aspirator.

It should be remembered that stones in the common duct can slip upwards into dilated liver ducts; and that a small flat stone can be overlooked (*see* p. 709).

It is also surprising to find how often common-duct stones are unexpectedly present; that is, where there are none of the usual manifestations present which indicate exploration of the common duct. For example, in only about 20 per cent of cases of stones in the common duct is jaundice a feature. Lahey, between 1910 and 1926, opened the common duct in 15 per cent of cases and found stones in 8.4 per cent. Now he opens it in 42 per cent of cases and finds stones in 21 per cent.

A further preventive measure, whenever suspicious circumstances make it necessary to open the common duct, is to dilate the sphincter of Oddi (Sir Alexander MacCormick). Probably the basis of this measure is the same as dilatation in cardiospasm.

Operative and Other Treatment.—

Where a Common Duct is Being Drained.—In this case, the first thing to do is to make a cholangiogram; that is, to outline by X rays the common duct after injecting lipiodol through the bile fistula or the drainage tube. An overlooked stone or a stricture may then be seen.

If no obstructing cause is found, then therapy can be instituted through the indwelling drainage tube and the duct washed out with warm olive oil or saline (Best¹). Treatment (described below) with the object of relaxing the sphincter of Oddi may also be carried out.

Where the Common Duct has not been Drained.—Treatment should be instituted to try to relieve a possible dyskinesia of the sphincter of Oddi. According to Best, $\frac{1}{100}$ gr. nitroglycerin should be given by mouth three times on the first day; $\frac{1}{100}$ gr. atropine on the second day; and $\frac{1}{100}$ gr. nitroglycerin three times on the third day.

WHEN TO OPERATE IN A CASE OF ACUTE CHOLECYSTITIS

In an approach to a case of acute cholecystitis, the point of view of a surgeon should be that, unless there are adverse circumstances, he should promptly remove the inflamed gall-bladder in the same way as he would an acutely inflamed appendix. He should not follow

blindly the more or less routine practice of allowing all cases of acute cholecystitis to subside before operating. Some cases will not subside; in about 15 per cent empyema, gangrene, or perforation will occur. The surgeon will then be faced with the difficult problem of removing a disintegrating gall-bladder with extensive and perhaps tough adhesions; or if he exercises discretion in regard to its removal, he will have to carry out a preliminary gall-bladder drainage—thus making a two-stage operation for the patient.

The technical difficulty in the removal of an acutely inflamed and adherent gall-bladder, the danger of injuring adherent neighbouring organs, and the fear of interfering in the upper part of the abdomen with a septic process which is more liable to be disseminated than one in the lower part, are reasons advanced for conservatively treating the attack and postponing operation to a quiescent interval. The operative difficulties and dangers of wounding neighbouring organs are, however, greatly minimized by the refinements in cholecystectomy technique already advocated. The danger of post-operative septic dissemination and its sequent complications is, too, much lessened by adequate, well-arranged, and prolonged drainage.

If an acutely inflamed gall-bladder can be safely resected in the initial stages—and the majority can—the patient is spared much pain, morbidity, and loss of time—a consideration in the wage-earning class.

The adverse circumstances which contra-indicate an emergency operation are:—

1. If the patient is seen at a late stage of the inflammation when adhesions are becoming fibrous and tough.
2. If an acute cholecystitis supervenes on a badly diseased, fibrous, and contracted gall-bladder the result of many previous attacks; that is, if there exists a combination of acute inflammatory adhesions, œdematous walls of adjoining viscera, and old tough adhesions—a combination of circumstances which makes cholecystectomy a dangerous operation.
3. If the acute cholecystitis has occurred in a 'bad risk', a not uncommon occurrence, for gall-stones are often found in old, obese, circulatorily deficient, or otherwise unhealthy persons.

In all such cases it is better surgical strategy to perform the operation when the inflammation has subsided and when pre-operative preparation can be made.

Anyway, in these cases a few days' observation will generally enable a judgement to be formed whether the inflammatory process is going to abate or whether empyema, gangrene, or abscess is likely to occur, and a risky operation has to be faced.

In general, it may be said that, if a patient who is in reasonably good condition has a severe attack of cholecystitis, has not had many previous attacks, and therefore probably has a free-lying gall-bladder, prompt operation is the soundest procedure, and that in such an operation the 'safety first' desideratum hinges mainly round the skill of the cholecystectomist.

REFERENCES

- ¹ BEST, R. R., "The Remaining Common-duct Stone and its Non-operative Management", *Surg. Gynecol. and Obst.*, 1938, June, No. 6, 1041.
- ² NYGAARD, K. K., "On Post-cholecystectomy Colitis", *Acta chir. Scand.*, 1938, **81**, 315.

CHAPTER LXII

ACCIDENTS TO THE BILE-DUCTS IN CHOLECYSTECTOMY

HOW ACCIDENTS HAPPEN IN CHOLECYSTECTOMY

As a rule, accidents which occur in the operation of cholecystectomy are due to the fact that the surgeon does not have a good view of the operation field. As he is unable to see what he is doing, he therefore divides structures which he should not; or, being unable to see accurately to dissect, he uses his fingers, with the result that structures which are friable from inflammation become torn.

There are, however, certain pathological conditions which predispose to injuries of the common duct, such as: (1) Redundancy of the common duct; (2) 'Taking up' of the cystic duct from the passage of large stones; and (3) A fibrous contracted gall-bladder, full of stones and containing no bile.

1. Redundancy of the Common Duct.—In an enteroptotic patient, where the liver is low and the gall-bladder can be drawn right out of the abdomen, and where this traction on the cystic duct makes a loop in a rather long common duct, this structure may be unexpectedly wounded, being divided in the belief that it is the cystic duct, as shown in *Fig. 568*.

A surgeon operating on a gall-bladder, the removal of which appeared to be so easy that he felt he could do it in a few minutes, was horrified to find that, when he had divided what he thought was the cystic duct, he appeared to have divided two cystic ducts. On examination he found that in pulling on the gall-bladder he had folded the common duct into a little loop, and had then divided this loop, thus cutting out a section (*Fig. 568, A-C*).

He telescoped one end into the other and joined the duct up with fine threads of plain catgut, wrapped a cuff of omentum round it, and inserted a drain down to the operation area (*Fig. 568, D, E*). There was a profuse flow of bile for three weeks. The operation was performed on May 14, 1916. She returned home on June 17, 1916, almost five weeks after the operation, and was then well. On January 13, 1917, she developed deep jaundice, which lasted for about three weeks and then gradually cleared up. She had no further trouble, is now quite well, and is 76 years old.

2. The 'Taking-up' of the Cystic Duct.—It is not uncommon to find a large gall-stone impacted in the proximal part of the gall-bladder—that is, in its S-shaped part. If there is a good deal of

fibrosis and contraction of the wall of the gall-bladder, a stone in this position may slowly dilate its way through the cystic duct, which will then shorten in the same way as a cervix shortens and 'takes up' as it becomes dilated by the passage of the child. Thus in many old inflamed gall-bladders with large stones, and especially if one of these large stones has passed into the common duct, the cystic duct is shortened and dilated, and in some cases almost non-existent.

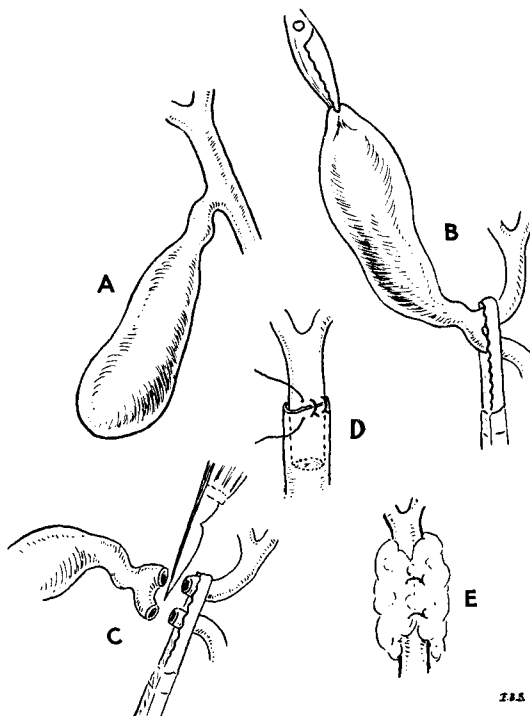


Fig. 568. — A, B, and C show how, in performing a cholecystectomy, the common duct can be injured if it is redundant; D and E show how the injury is repaired.

In such cases it is a not infrequent occurrence for a part of the common duct to be included in the ligature which the surgeon thinks he is placing around the cystic duct, and which he has placed in this position because he has failed to recognize that the cystic duct is almost obliterated (*Fig. 569*).

A ligature so placed usually slips off, and as the opening in the common duct is far back on the abdominal wall the bile runs into the lesser sac, and down into the pelvis, producing a choleperitoneum. No bile, or only a little, may come through the drainage tube.

Since the bile is a natural body fluid it gives rise to very little irritation in the peritoneum, and produces, without many ill-effects or much disturbance, a gradual distension, which at first sight may be mistaken for an intestinal obstruction, because the intestines float in front of the bile, and a superficial examination may show that the distended abdomen is somewhat resonant. Dullness will, however, be found in the flanks.

Case of Choleperitoneum after Cholecystectomy.—The following case-history dramatically illustrates how insidiously and unsuspectedly

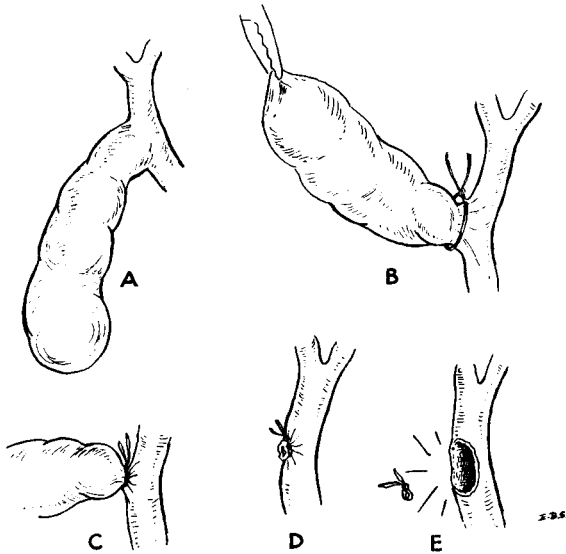


Fig. 569.—Showing how the common duct can be injured by ligation when the cystic duct has been obliterated from the passage of stones.

a choleperitoneum may occur after a cholecystectomy in which the common duct has been injured :—

The patient suffered from attacks of epigastric pain accompanied by shivers and fever, followed by jaundice, and lasting about a week. In between the attacks she would be fairly well.

She was operated on by a surgeon who found that her gall-bladder was diseased. It was hourglass-shaped, with one large stone in the distal segment and another in the proximal segment. The stone in the proximal segment was encysted in the cystic duct which became dilated. There was no stone in the common duct. The surgeon removed the gall-bladder, dissecting it out from the fundal end, tied the cystic duct, and inserted a drainage tube. He removed the tube in twenty-four hours.

On the third day the patient became jaundiced, and her temperature rose to 100° . Seven days later her temperature was 101° , and her pulse was 110. On the tenth day she developed a pain in her right shoulder

and in the right hypochondrium. At this time there was a little bile draining from the opening from which the tube had been removed. Her jaundice had now almost disappeared. Several days later she developed acute pain in the right iliac fossa, which gradually extended to the whole of the lower part of the abdomen and was worse on the left side. Her temperature now was 102°, and her pulse-rate 120. She was at this time—four weeks after her operation—very sick; her leucocyte count was 34,000; her abdomen was distended, somewhat resonant in the middle, with some dullness in the flanks. She had, however, no difficulty with her bowels. She was slightly jaundiced, and had a very dirty tongue.

At a second operation, the abdominal cavity was found to be full of bile. As far as could be ascertained, a dilated and ‘taken-up’ cystic duct must have been amputated too close to the common duct.

Thus it will be seen that in cases of choleperitoneum, even three weeks after the operation, although the abdomen may be very distended, the patient’s bowels may be acting quite well, the pulse-rate may not be very high, the temperature may be only about 100°, and the patient may not appear seriously ill—a state of comparative well-being which could not be present in any other acute abdominal condition with such a degree of distension.

3. A Fibrous Contracted Gall-bladder, full of Stones and Containing no Bile.—A gall-bladder which has been full of gall-stones for a great number of years, and from which the bile has entirely disappeared, may contract into an irregular-shaped lump, and become embedded in the liver in such a way that it lies closely adherent to the common hepatic duct. In such a gall-bladder all the natural planes have disappeared, and the dissection of its proximal part and cystic duct must necessarily be made through almost cartilaginous tissue. It is while the dissection is being made in the region of the common hepatic or right hepatic duct that these structures may be wounded and a slice taken out of them.

The injury to the ducts can be avoided if in such circumstances as these the gall-bladder is first emptied of its stones, so as to have at least a smooth gall-bladder wall along which to make the dissection.

HOW TO RECOGNIZE ACCIDENTS TO THE COMMON DUCT

If injury to the common duct can be recognized at the time of the operation, its repair can be carried out most accurately. As a rule, stricture of the duct does not occur, and generally the patient gets permanently well. If, however, the injury has not been recognized at the time, the sooner it can be determined after operation the more chance there is of successful repair, and of a permanent cure for the patient.

Injury to the common duct which has not been recognized until some time after the operation is in most instances difficult to repair, and, what is more important, the permanent results are nearly always unsatisfactory.

Very often the first indication of injury to the common duct is a discharge of bile from the opening left after the drainage tube is removed—a discharge which does not diminish. At first the surgeon regards this as caused by : (a) The slipping of the ligature from the

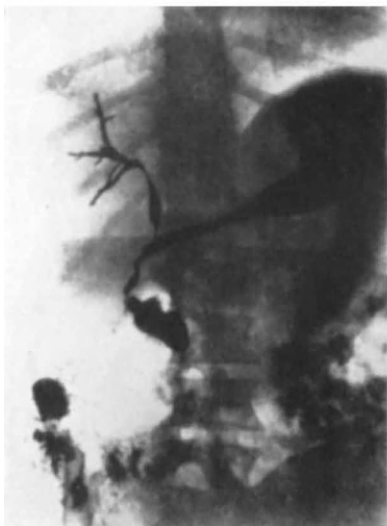

Fig. 570.—Radiograph of a lipiodol injection into a biliary fistula. The common and the hepatic ducts are filled, and the lipiodol is entering the duodenum. (*Hybrinette*.)

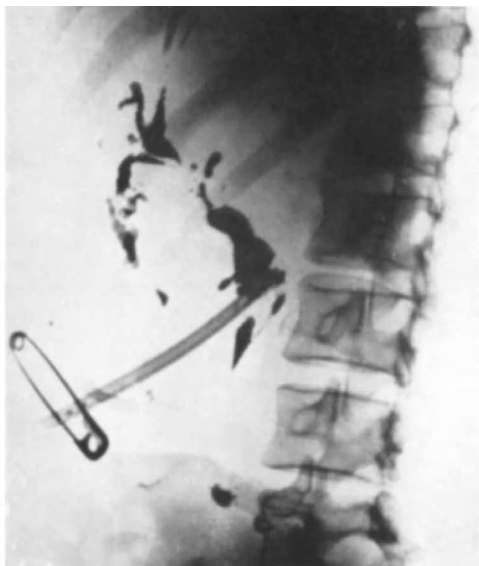

Fig. 571. Radiograph showing a lipiodol injection of the common duct after an operation in which gall-stones and hydatid membrane were removed from the common duct. The duct is still dilated, and bile is seen entering the duodenum, denoting that the ampulla of Vater is patent.

cystic duct because the ligature has not been properly tied ; (b) The bursting open of the cystic duct as the result of increased pressure in the common duct, caused by an overlooked stone in the ampulla of Vater ; or (c) The division of an anomalous bile-duct. As a rule, it does not occur to him that it may be due to an injured common duct. He therefore waits for the discharge of bile to clear up, and thus loses valuable time. A discharge of bile persisting later than the eighth or ninth day after a cholecystectomy demands investigation as to whether there is injury to the common duct. A ligature does not very readily slip off the cystic duct if the common duct is patent,

because the pressure in the biliary system is low. If, however, there is obstruction of the common duct, and the pressure in it rises, the ligature is very likely to be forced off the cystic duct. A persistent discharge of bile, therefore, usually means an obstruction or an injury of the common duct.

At this stage, then, injury must be excluded for the following reasons: If an injury to the common duct is allowed to remain for some time, the proximal part retracts into the portal fissure and becomes fibrosed and contracted; the liver enlarges as a result of biliary obstruction from the strictured duct; and much fibrosis and firm adhesions of neighbouring organs takes place round the sinus. All these conditions make an operation for repair of the duct exceedingly difficult and very often unsatisfactory. The whole secret of repair of the common duct depends upon early recognition of the injury, and this in turn depends upon diagnosing the cause of a persistent discharge of bile after a cholecystectomy.

Diagnosis of the Cause of Discharge of Bile after Cholecystectomy.—A diagnosis can be made by injecting lipiodol into the sinus and thus into the biliary tract. *Fig. 570* is the radiograph of a lipiodol injection into the biliary fistula. The common and hepatic ducts are filled, and the lipiodol is entering the duodenum.

Fig. 571 shows a lipiodol injection of the common duct after an operation in which gall-stones and hydatid membrane were removed from the common duct. The duct is still dilated, and bile is seen entering the duodenum, denoting that the ampulla of Vater is patent.

REPAIR OF WOUNDS OF THE COMMON DUCT

Repair at the Time of the Cholecystectomy.—When the injury to the common duct is recognized at the time of the cholecystectomy, repair is not very difficult, and the result as a rule is good. The cut ends of the common duct may be joined together by fine catgut sutures over a rubber tube led through the ampulla of Vater into the duodenum. This tube may remain in position for years; in fact in one case, recorded by a Russian surgeon, it remained for five years. The lumen of a tube, however, is liable occasionally to become blocked with thickened bile, and this blocking causes more or less severe attacks of jaundice. There is also the danger that infection may spread up along the lumen of the tube to the biliary ducts—that is, that a cholangitis may develop. The circular end-to-end suture, too, is liable to contract and produce constriction. To avoid this the upper cut end can be telescoped into the lower segment of the divided common duct, as shown in *Fig. 572*.

It is better, if possible, to try to preserve the natural sphincter of the lower end of the common duct, for when the common duct opens by a sphincterless opening into the duodenum, infection (cholangitis) is liable to spread into the biliary system. It is therefore advisable, if possible, to unite the severed ends of the common duct, and not to connect the upper cut end of the common duct to the duodenum, although in some cases this must be done.

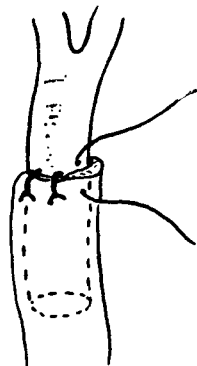


Fig. 572. — Upper cut end of the common duct telescoped into its lower segment.

Anastomosis of the Proximal Cut End of the Common Duct to the Duodenum or Jejunum.

—Where it is not possible to join up the divided ends of the duct because the distal end is atrophied and small, the upper cut end of the common duct must be anastomosed to the duodenum. In this case, the duodenum must be mobilized by dividing the peritoneum over the gastrohepatic ligament at its junction with the first part of the duodenum and along the lateral side of the second part of the duodenum, as shown in *Figs. 564 and 565* (pp. 709, 710). The first part of the duodenum can then be brought upwards. The proximal part of the common duct must now be isolated, and as a rule it is very difficult to find. The best way to approach it is to follow the inferior surface of the liver down to the portal fissure. Usually this part of the common duct is dilated, because there is always a certain amount of stricture of its cut end.

The exposure and isolation of the injured duct is rendered difficult by the enlarged liver which usually accompanies this common-duct injury, and which is also caused by biliary obstruction following the contraction of the divided end. But when this stenosed end has been opened, the bile which is pent up in the liver and causes its enlargement can be aspirated. This manœuvre reduces somewhat the size of the enlarged liver overhanging the portal fissure, and thus makes easier the performance of an anastomosis between the retracted proximal end of the common duct and the duodenum.

Access to the portal fissure for the purpose of repairing the common duct is also improved by using the operating frame. In addition to the usual setting of the retractors of the frame (*see Fig. 248*, p. 347) for the performance of a cholecystectomy, an additional well padded 'mechanical hand' (*Fig. 573, A*) is placed on the lower surface of the liver in order to expose the portal fissure,

and thus enable any anastomosis on the duct to be made unhindered by the large and prolapsing liver.

A small opening is made in the first part of the duodenum, and the cut end of the posterior part of the duct is united by interrupted sutures to the posterior edge of the opening. A tube is then placed in the common duct and led through into the duodenum

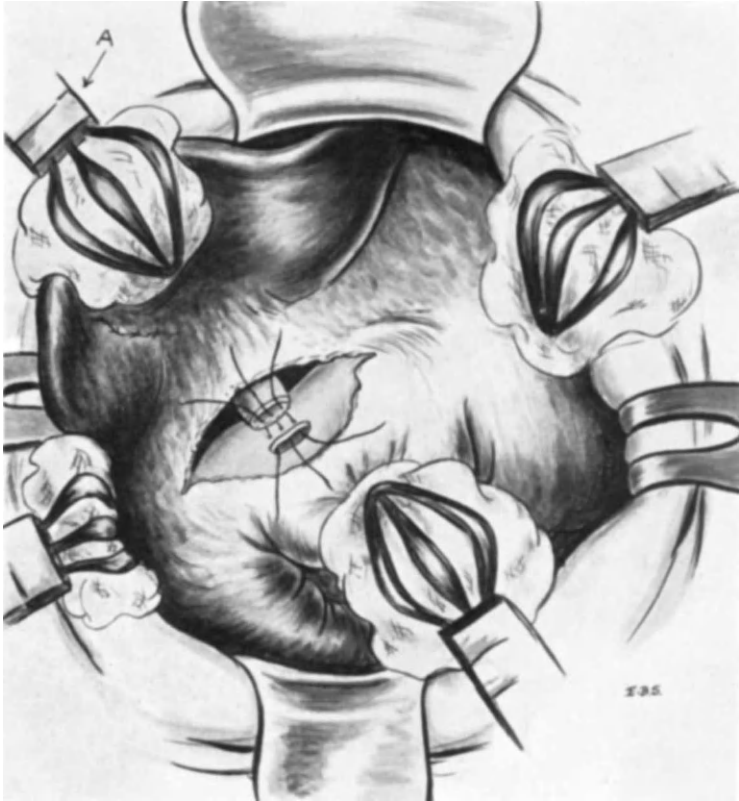


Fig. 573.—Exposure of an injured common duct by operating frame and retractors; and the first stage of the suture of the hepatic duct to the duodenum. A, Additional 'mechanical hand' for the liver.

and the anterior tier of sutures is inserted (*Fig. 574*). A small cuff of 'backwashed' omentum is sutured round the anastomosis. A danger of this operation is that, in a year or two, as a result of the sphincterless opening of the common duct and the consequent entry of duodenal contents, an infection of the biliary ducts—a cholangitis—may develop. A further danger is that, even if the patient should survive this, a stricture of the anastomosis may eventually develop.

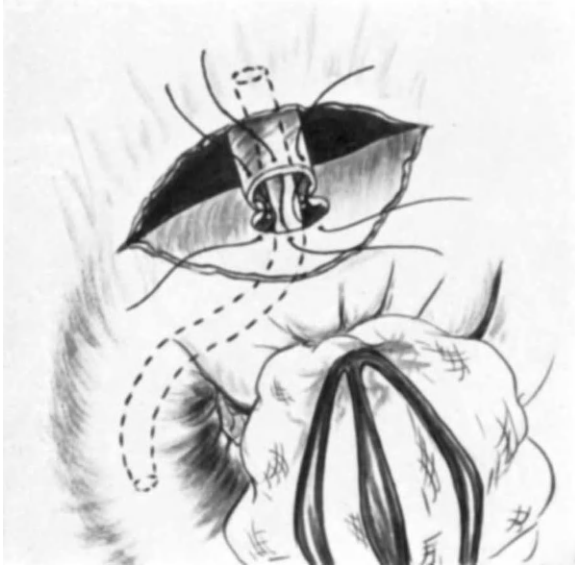


Fig. 574. Tube placed in common duct and led through into duodenum.

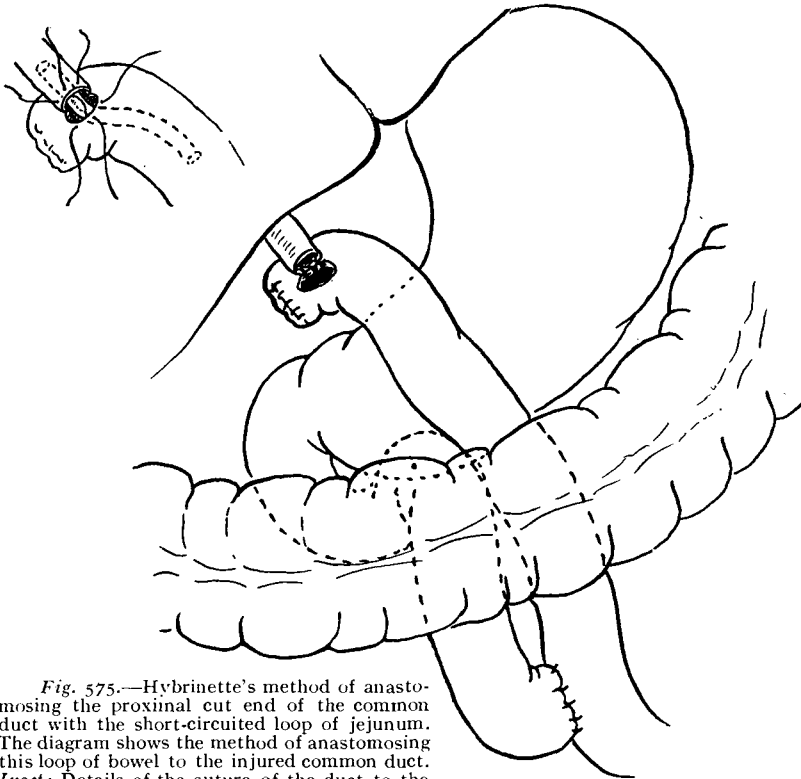


Fig. 575.—Hybrinette's method of anastomosing the proximal cut end of the common duct with the short-circuited loop of jejunum. The diagram shows the method of anastomosing this loop of bowel to the injured common duct. *Inset:* Details of the suture of the duct to the isolated loop of bowel.

This operation of making an anastomosis between the upper cut end of the common duct and the duodenum is so difficult that Hybrinette¹ has suggested a method of anastomosis of the proximal cut end of the common duct with a short-circuited loop of jejunum. He divides the small intestine a short distance below the duodeno-jejunal flexure and brings up the distal loop through a slit in the mesocolon, after which he sutures its cut end to the biliary fistula—to the proximal end of the divided common duct. The free end of the proximal loop he sutures to the jejunum a little lower down (*Fig. 575*).

If the injury to the duct is at its lower end or close to the duodenum, it is an easy matter to make an anastomosis between the common duct and the duodenum.

SOME COMPLICATIONS OF CHOLECYSTOSTOMY AND CHOLECYSTECTOMY

Fistula Discharging Pus after Cholecystostomy.—Not uncommonly a fistula, discharging only pus, remains after the operation of cholecystostomy, which has perhaps been carried out for an acute cholecystitis. As a rule such a fistula is due to the presence of a stone in the cystic duct which had been overlooked, or which could not be removed because of an acute fulminating inflammation of the gall-bladder. For a time the fistula discharges mucus, then muco-pus, and finally pus. In these cases the gall-bladder must be removed. It must not, however, be forgotten that cholecystectomy in such circumstances requires a skilful operator, for the empty, contracted, and fibrosed gall-bladder has lost all semblance to the normal organ, and its dissection is fraught with the danger of injury to the common duct. These fistulæ may persist from the time of the cholecystostomy, or the wound may reopen a few years after the operation and a sinus discharging pus may remain. The following is an example of this type of post-cholecystostomy problem :—

The patient was a short, fat woman, who gave the history that several years ago she had been operated on during an attack of acute cholecystitis. The surgeon who operated did not remove her gall-bladder, but drained it, because its removal involved danger to the patient. Some years after the operation the lower edge of the wound became inflamed, an abscess formed, and finally pus discharged. Since this time a discharging sinus has been present in the wound. Investigation of the wound showed that the sinus was connected with the gall-bladder. In this case a stone was found completely blocking the cystic duct. What had probably occurred was that, in the inflamed state of the gall-bladder, a stone had been overlooked in the ampulla. At first the stone had not completely blocked the cystic duct, and therefore the drainage opening in the gall-bladder had been able

to close because the gall-bladder had not become a completely closed viscus. In later years, probably the stone had become impacted in the cystic duct, leading to an infected mucocele, to an abscess, and finally to an opening of the wound.

Recurrent Symptoms of Disease of the Gall-bladder after Cholecystostomy.—In my experience, most cases of cholecystostomy eventually require a cholecystectomy for well-established cholecystitis or gall-stones. This is true, even if the cholecystostomy has been done on an undiseased gall-bladder. In several cases in which, from careful analysis of the previous history, I am sure there had been no disease of the gall-bladder, I have had to perform a cholecystectomy for definite symptoms of cholecystitis. On examination no stones were found, but the gall-bladder wall was mottled with deposits of lipoid, and presented the appearance of a 'strawberry gall-bladder'. I believe that the fixation of the fundus to the abdominal wall interferes with the emptying of the gall-bladder, and therefore produces a stasis of bile, chronic cholecystitis, and lipoid deposits.

Where, however, a cholecystostomy has been performed and there is definite disease of the gall-bladder—cholecystitis—no drainage will cure the condition, and it is only a matter of time for the cholecystitis, usually accompanied by gall-stones, to recur.

Choledochotomy after Cholecystectomy through a Kocher Incision.—The removal from the common duct of gall-stones which have developed some years after a cholecystectomy for cholelithiasis which was carried out through a Kocher incision, very often presents considerable difficulties.

If the old Kocher incision is reopened, an adequate exposure of the common duct cannot be obtained. On the other hand, if a paramedian incision, which gives the best exposure for the common duct, is made, the division of the adhesions caused by the old incision presents considerable difficulty.

The problem is solved by taking advantage of the use of the operating frame. Retractors fitted to this instrument are inserted in the manner already described. The operating table is tilted laterally to the right (*see Fig. 296, p. 395*), the abdominal wall is lifted away from the liver by the assistant with the aid of the operating frame, and the shadowless light is directed into the cavity thus formed, and on to the adherent area. The surgeon, standing on the left side of the patient and looking down on the adhesions, uses long spade-pointed dissecting scissors to cut the firm adhesions which fix the liver to the Kocher incision. When this has been done, he sutures

the rents in the peritoneum of the anterior abdominal wall (*see Fig. 240*, p. 339).

After all the peritoneal adhesions to the abdominal wall have been divided in the manner described in Chapter XL, the operating table is placed in the normal operating position for a gall-bladder—the reverse Trendelenburg position. The wound is covered with towels, the operating frame inserted, and the ‘mechanical hands’ so placed as to expose the common duct (*see Fig. 247*, p. 346).

In addition to the ‘mechanical hands’ used to expose the gall-bladder, a fourth ‘hand’, padded, is used to draw the liver upwards and so expose the common duct (*see Fig. 573*). The common duct is then opened in the usual way.

REFERENCE

- ¹ HYBRINETTE, S., “Quelques Suggestions de l’Expérience dans le Traitement des Fistules biliaires post-opératoires complètes”, *Acta chir. Scand.*, 1932, 327–36.

CHAPTER LXIII

NON-MALIGNANT AFFECTIONS OF THE PANCREAS

ACUTE PANCREATIC NECROSIS OR ACUTE
PANCREATITIS

It is now recognized that in 50 to 60 per cent of cases of pancreatic necrosis or acute pancreatitis an affection of the gall-bladder or of the biliary tract is the causal agent.

In most severe pancreatic affections necrosis of the pancreatic tissue itself and fat necrosis of the tissue adjacent to it are the dominant pathological anatomical features. The so-called acute hæmorrhagic pancreatitis is a necrosis of the pancreas associated with a hæmorrhagic condition, the necrosis being in most cases the primary condition, and the bleeding and any inflammatory changes a secondary condition. Sometimes, however, the inflammation is the primary condition and the necrosis secondary, but this is rare.

The acute affections of the pancreas may be classified as follows : (1) Acute pancreatic necrosis ; (2) Pancreatosis—a term designating a pancreatic affection with fat necrosis, but without alterations in the parenchyma of the pancreas itself ; (3) Acute pancreatitis.

Some authors regard pancreatosis as the condition which immediately precedes an acute pancreatic necrosis. It corresponds to an œdematous condition of the pancreas, which Archibald (1929) was able to produce experimentally by injections of bile into the pancreatic duct. Pancreatosis as a rule quickly recedes.

In much of the following description of acute pancreatic necrosis I have drawn freely upon the work of Otto Mikkelsen¹ on acute pancreatitis.

In pancreatic necrosis the destruction of pancreatic tissue is caused by activated trypsinogen (trypsin). Activation can be brought about by enterokinase, duodenal juice, bacteria (*B. coli communis*), and bile, especially infected bile.

Experiments have shown that pancreatosis occurs when normal bile in excess, produced by feeding of fat, is forced into the pancreatic duct by closing the sphincter.

Causes of Retrojection of Bile into the Pancreatic Duct.—Bile, either pure or infected, or mixed with pancreatic or duodenal secretions, can be retrojected into the pancreatic duct in the following

ways: (1) By a stone in the common duct; (2) By a spasm of the sphincter of Oddi; (3) By hypotonus of the sphincter of Oddi.

1. *By a Stone in the Common Duct.*—To cause regurgitation of bile into the pancreatic duct effectively, the stone should be small and situated in the papilla, that is, below the opening of the duct of Wirsung. However, experience of a large number of cases (Mikkelsen) shows that this occurs in only about 25 per cent of cases of acute pancreatic necrosis. Generally the stone is found loose in the common duct. Nevertheless, a stone in the common duct is not always the cause of retrojection of bile, for in a proportion of cases of acute pancreatic necrosis no gall-stone is found.

2. *By Spasm of the Sphincter of Oddi.*—It has been suggested that the regurgitation of bile is caused by a spasm of the sphincter of Oddi, that is, by a spasm which occurs as a result of the disharmony of the vegetative nervous system—a spasm similar in nature to that which occurs in the other sphincters of the alimentary canal. The spasm of the sphincter may, as suggested by Oddi, be brought about by mechanical or clinical irritation of the mucous membrane of the duodenum.

3. *By a Hypotonus of the Sphincter of Oddi.*—It is also thought that duodenal juice may enter the duct of Wirsung as a result of hypotonus of the sphincter of Oddi, and that the duodenal juice, perhaps infected, may infect the pancreatic tract and therefore the pancreas in the same way as infected duodenal contents are known to pass up the common duct and infect the ducts of the liver and the gall-bladder.

In favour of the assumption that in many cases it is a spasm of the sphincter of Oddi which causes retrojection, rather than a stone, which would often block both ducts, is the fact pointed out by Mikkelsen that in 70 to 75 per cent of cases there is a common opening of the pancreatic duct and the common bile-duct into the duodenum.

Symptoms.—The two main symptoms of acute pancreatic necrosis are: (1) The quick development of a profound collapse; and (2) Agonizing pain of great severity with extremely sudden onset.

1. *The Collapse.*—The patient is in a cold sweat and the face and extremities are pale and cyanosed; the pulse is small, but better than one would expect with the profound collapse of the patient, and in the beginning it may be slow—a vagus influence. The patient has a tormented and collapsed expression.

2. *The Agonizing Pain.*—Mikkelsen describes the agonizing pain as follows: “The pains are severe, set in at once with their maximum strength, and keep up continuously—there are no remissions as in an

ileus. The pains are situated in the middle or to the left of the epigastrium and radiate to the left, sometimes into the loin, and occasionally into the left shoulder. They are much worse than in a gall-stone colic. The patient himself may volunteer this information, for he is likely to have had a previous attack of gall-stone colic. The severe and sudden pain and the profound collapse are very like the conditions following a perforation of the stomach."

Vomiting of bile-stained fluid is usually associated with the pain; but if the vomiting is fæculent it will be found that the patient is suffering from some other affection, such as intestinal obstruction or peritonitis.

The temperature in the beginning is normal or subnormal.

There is usually some distension towards the upper part of the abdomen which, according to Gobiet, is a very early and a very characteristic sign, and which he thinks is caused by an isolated distension of the transverse colon, perhaps due to irritation of the cœliac plexus.

In the beginning, there is no real *défense musculaire* of the abdomen. If the abdomen is board-like in its hardness, the patient has some trouble other than pancreatic necrosis. A sensitiveness to pressure in the middle and the left side of the epigastrium is characteristic, and is rarely absent in acute cases. There may also be a sensitiveness to pressure under the right costal margin, which suggests a coincident cholecystitis. Sometime a tenderness in the right iliac fossa, caused by an extension of the exudate along the descending colon, can be found. Occasionally a slight accompanying icterus is present.

The early distension of the upper part of the abdomen is soon followed by a distension of the whole of the abdomen, which is partly due to reflex causes, partly to the intense poisoning, and partly to the shock and irritation of the cœliac plexus.

Diagnosis.—In the light of modern treatment, in which immediate operation is deprecated, an exact diagnosis is most important. It should be possible to make an exact diagnosis on the following grounds: (1) A previous history of gall-stones; (2) The typical clinical picture; and (3) The results of the examination for diastase in the urine.

The Diastase Examination.—According to Mikkelsen,¹ the examination for diastase in the urine gives just as reliable results as that for diastase in the blood; hence in practice the examination for diastase in the urine can be relied upon. A diastase number of 150 to 200 is the normal limit, over 200 signifying an affection of the pancreas. A severe acute pancreatic lesion may give a number of 600 to 1000. An increase in the urine diastase only indicates that the pancreas is affected; it does not indicate that the pancreatic affection is the only

lesion. The diastase reaction must therefore be considered in conjunction with the clinical picture. In many cases, of course, the marked *défense musculaire* is an important differentiating sign.

Differential Diagnosis.—The differential diagnosis lies between (1) Cholelithiasis ; (2) Ileus ; (3) Perforated gastric or duodenal ulcer ; (4) Appendicitis ; (5) Angina pectoris ; and (6) Mesenteric thrombosis.

Cholelithiasis : In cholelithiasis the predominance of the symptoms and signs to the right side, the absence of a typical clinical picture of pancreatic necrosis, and the diastase estimate will be deciding factors.

Ileus : The limitation, at any rate in the early stages, of the distension to the upper part of the abdomen, the absence of fæculent vomiting, the absence of remission in the pains, and the diastase estimate are all differentiating factors.

Perforations : Perforated gastric or duodenal ulcer is distinguished from pancreatic necrosis by the intense board-like hardness of the abdomen and by a previous history of gastric trouble.

Angina pectoris : Pancreatic necrosis may be mistaken for angina pectoris. Mikkelsen cites the following example :—

A man, aged 50, began to suffer $1\frac{1}{2}$ years previously from severe pain in the epigastrium. The painful attacks lasted usually for one hour and ended with vomiting. The last attack occurred the day before his admission and was especially bad, and the pain radiated upwards into the chest. Since the attack he had not passed flatus. When he was taken into hospital he was very collapsed and short of breath, and his face had a congested appearance. His abdomen was fat, soft, and not especially tender, and in its upper part somewhat distended. A diagnosis of angina pectoris was made. The following day his abdomen became distended. His tongue was dry and his pulse was 120. He was diffusely tender below the left costal margin, and his diastase number was 600. Since he was very distended, very collapsed, and was continually vomiting, a diagnosis of ileus was made. Operation revealed an acute pancreatic necrosis.

Treatment.—In earlier years the treatment of pancreatic necrosis was as follows : (1) Operation as soon as the diagnosis was made, when the so-called ‘capsule’ of the pancreas was opened for drainage ; (2) At the same time as the above procedure was carried out, if the patient could stand it, any gall-stones were removed and the gall-bladder and common duct drained.

The mortality-rate of this immediate operative treatment in Continental clinics is as follows : Korte (1911), 60 per cent ; Guleke (1924), 52 per cent ; Schmeiden and Sebening (1927), 51·2 per cent ; Kirschner, 70 per cent.

Of later years, however, the tendency has been not to operate immediately, but to wait till the initial shock has somewhat died down.

When operating in the earliest stages the surgeon seeks to drain the biliary duct and cut short that condition of the pancreas which precedes pancreatic necrosis—a condition called by some the ‘œdematous state’ and by others ‘pancreatosis’.

In the acute stage the surgeon seeks, by splitting the ‘capsule’ of the pancreas and by draining the biliary system, to retard the progress of the necrosis, and thus the production of the poisonous substances which cause the profound collapse. He is under the impression that by splitting the ‘capsule’ he relieves the tension in this organ.

Arguments against these operative measures have, however, been advanced by Otto Mikkelsen and others, and are as follows:—

1. That the pancreas has no capsule, that it is only covered by a layer of peritoneum and fine connective tissue, and that therefore there is no basis for incising what is called the ‘capsule’ in order to bring about a ‘decompression’.

2. That interference with the pancreas often causes necrosis of parts of the pancreas, and also brings about fistula formation.

3. That the operation—a shock-producing one—in a patient suffering from a condition which in itself produces profound shock, is very prone to cause a high mortality.

4. That cases in which the biliary system is drained in addition to the operation on the pancreas do not seem to give a better immediate mortality-rate than do those in which the pancreas alone is opened and drained.

5. That in only 50 per cent of cases of pancreatic necrosis are gall-stones found, and therefore the reason for operation which is often given—that the pancreatic necrosis is a complication of gall-stones—does not hold in all cases.

According to these modern observers, it would thus appear that an immediate operative interference in the pancreas itself is not only useless but in many cases is the cause of death. Of recent years the tendency has therefore been to treat cases of pancreatic necrosis without operation—that is, conservatively.

But obviously, if pancreatic necrosis is to be treated conservatively, it is essential that the surgeon should be able to make a correct diagnosis. This has been made possible by a better understanding of the nature of the disease, and by an application of the significance of the diastase test.

H. Wildegans² believes that, with the modern biochemical tests at our disposal, it is possible to make an exact diagnosis in most cases of acute pancreatic necrosis. Since 1933 he has not permitted an

operative interference when a diagnosis of acute pancreatic necrosis could be definitely made. Out of 28 cases, 25 were discharged free from trouble and 3 died (1 from diffuse peritonitis, and 2 from total pancreatic necrosis).

Conservative Treatment.—Mikkelsen's treatment is as follows: Fluid nourishment only is given. The patients are given water, tea, and such fluids as long as the severe symptoms last. Sometimes the fluid must be withheld when the vomiting is too severe. Water is introduced subcutaneously and intravenously, and with it is given 50 g. of glucose in 5 per cent solution, with the requisite amount of insulin. The abundant introduction of fluid dilutes the toxin and keeps up the blood-pressure, and the glucose helps the heart. The heart's action is stimulated by drugs. An attempt is made to bring about normal peristalsis as soon as possible. Bowel wash-outs are given, and 2 c.c. sennatin is given intramuscularly. If this does not cause a bowel action, 1 c.c. of pituoglandol is injected intravenously once or twice daily. Mikkelsen treated conservatively a total of 39 patients with severe acute affections of the pancreas. Among these 39 patients, 20 were extremely ill, their general condition being very poor from shock. Only 3 of these 20 patients died. The remaining 19 patients were also very ill, but not actually shocked; none of them died. The diastase value in these cases was most often 3000 to 4000, and up to 6000, being under 2000 in only 2 of them. Subsequent operation was performed only on patients in whom gall-stones could with certainty be diagnosed; it was not performed until from one to three weeks after the acute symptoms had subsided. Mikkelsen, as the result of conservative treatment, has obtained a mortality-rate of 7.5 per cent.

Illustrative Cases.—An example of the clinical manifestations of pancreatic necrosis or hæmorrhagic pancreatitis is seen in the following case-record:—

A fat old man, who had suffered from attacks of colicky pain in the upper part of the abdomen, probably due to gall-stones, became suddenly ill with an onset of agonizing pain in the upper part of the abdomen. This was associated with great collapse, a subnormal temperature, a pulse of 160, intense hypernæa, rigidity and distension of the upper abdominal region, and dullness in the flanks. He had an agonized expression and could not lie down. He appeared to have a perforation of the stomach or duodenum, or an acute obstruction of the upper part of the small intestine.

At operation the abdominal cavity was found to contain fluid like beef-tea. Areas of fat necrosis studded the peritoneum. The pancreas was very much enlarged, and appeared to be a hæmorrhagic inflammatory mass. A large stone, which could be moved up and down a very dilated common duct, was found. The patient died shortly after the operation.

The following is an example of the clinical manifestations of a less severe type of acute pancreatitis in which sloughing of the pancreas occurred :—

A woman, aged 30, two weeks after pregnancy developed intense pain in the epigastrium and in the neighbourhood of the umbilicus. After some hours it got somewhat better, but gradually spread round to the back in the upper lumbar region. Her pulse went from 90 to about 116, and after taking a drink the pain got very much worse and she vomited. Her bowels were freely opened. She was exquisitely tender all round the upper part of the abdomen and could not lie down. There was evidence of fluid in the abdomen, which was soft.

At operation an enlarged, swollen, non-hæmorrhagic pancreas was found. The patient had no gall-stones.

SUBACUTE PANCREATITIS

There is a less severe type of pancreatic lesion, of which the following is an example :—

A woman, aged 33, became sick on a Monday with a very bad pain just above the umbilicus, and with constant vomiting. On Tuesday she was a little better. On Wednesday the pain became very bad, and vomiting continued. Her temperature was now 102° and pulse 80. The upper part of the abdomen was rigid; her conjunctivæ had a slight icteric tint. She was exquisitely tender over the appendiceal area.

At operation the abdomen was found to be full of fluid, which was slightly bile-stained; the gall-bladder contained stones; the pancreas was large and inflamed; the peritoneum was studded with spots of fat necrosis. There was a large area of fat necrosis in the omentum in the appendiceal area, and this apparently was the cause of the tenderness in that region.

CHRONIC PANCREATIC DISEASE: ASSOCIATION WITH GALL-STONES AND CHOLECYSTITIS

This may be brought about as follows: The anterior surface of the head of the pancreas and the gall-bladder are *in the same lymphatic field*. In consequence of this, a blood-borne infection of the gall-bladder may easily spread by direct lymphatic connexion, and thus cause a chronic pancreatitis. The infection is often confined to the head of the pancreas only. Thus in operations on infected gall-bladders it will frequently be found that the head of the pancreas is hard and nodular.

This type of chronic pancreatitis is interlobular, and must be distinguished from the interacinous type which is found associated with glycosuria.

This interlobular type may cause a mild and variable jaundice—rarely a deep jaundice—some indigestion and wasting, and also tenderness and some pain over the pancreas. A severe degree of jaundice

is not a characteristic of chronic pancreatitis. A small infiltrating carcinoma of the head of the pancreas will quickly infiltrate the common duct, and produce early in the course of the growth a more or less deep jaundice. In the case of a chronic pancreatitis, the enlarging head of the pancreas will not infiltrate the common duct, but will push this structure in front of it. Thus a fairly large inflammatory tumefaction of the head of the pancreas is required to produce even a mild degree of jaundice.

HYDATID OF THE PANCREAS

The following is a case-history of a hydatid cyst lying in front of the pancreas :—

A man, aged 57, had a severe pain in the neighbourhood of the umbilicus, extending laterally on both sides, and also into the middle of the back. After a few days he became slightly jaundiced. Two swellings, which appeared to be hydatid cysts, could be felt in the abdomen : one, in the neighbourhood of the umbilicus, which was tender to touch, and the other on the right side lower down, which was not tender. At operation a suppurating hydatid cyst in front of the pancreas was found.

In the following case the hydatid was situated in the head of the pancreas :—

An old woman had glycosuria and diarrhœa, and for six months had been ill with colicky pains in the middle of the abdomen and with severe vomiting. She had lost $1\frac{1}{2}$ st. in weight, and had become very jaundiced. At operation it was found that she had an old calcified hydatid cyst situated in the head of the pancreas. In this case a cholecystgastrostomy was performed, and she got better.

CYSTIC DISEASE OF THE PANCREAS

A male patient, aged 38, suffered from attacks of intense pain in the epigastrium. The pain radiated through to the back, lasted two or three days, and was only relieved by morphia. He vomited with the attacks, but did not get relief with the vomit. On two occasions he vomited a small quantity of blood. During the attacks he was tender in the epigastrium. The function of his bowels was not disturbed. In the intervals he had no dyspepsia and no disturbance of nutrition. Occasionally a little sugar was found in his urine. He had been ill for $4\frac{1}{2}$ years. Gall-stones were diagnosed and operation was performed. The gall-bladder was found to be normal, but about a tablespoonful of pus and fluid discharged from what was thought to be a pancreatic cyst. Further examination disclosed that there were one large cyst and a great number of small cysts distributed uniformly through the pancreas.

REFERENCES

- ¹ MIKKELSEN, OTTO, "Pancreatitis acuta : schwere Fälle, besonders hinsichtlich ihrer konservativen Behandlung", *Acta chir. Scand.*, 1934, **75**, 373.
- ² WILDEGANS, H., "Abwartende oder primär chirurgische Behandlung der akuten Pankreasnekrose?" *Der Chirurg*, 1936, **8**, Aug. 1, 597.

CHAPTER LXIV

**MALIGNANT CONDITIONS OF THE PANCREAS
AND COMMON BILE-DUCT**

CARCINOMA OF THE COMMON BILE-DUCT

CARCINOMA of the common bile-duct usually produces jaundice at a very early stage of its course. The jaundice is of the unremitting 'black' type, deepens quickly, is not accompanied by any infective symptoms, and is usually associated with an enlarged liver and a dilated gall-bladder. As could be expected, the clinical features of carcinoma of the common duct are almost indistinguishable from those of carcinoma of the pancreas, but in two respects they differ: (1) Carcinoma of the common duct is not associated, at least not early in its course, with so much constitutional disturbance, such as loss of appetite, loss of weight, loss of energy, etc.; and (2) Its onset is not nearly so painless, for the obstruction to the common duct, arising intrinsically as it does, is necessarily rather acute, and this somewhat sudden onset of obstruction causes a certain amount of pain.

Carcinomatous obstruction of the common duct may arise with so much pain that it is often mistaken for gall-stones; indeed, it may be operated upon under this belief, and even at the operation the carcinoma, probably because it is such a small growth, may remain undiscovered.

The following very instructive example is worth quoting in detail, to show how such a mistake can occur; it is only one of the many examples which could be cited:—

A patient, aged 50, became ill with very severe epigastric pain which did not require morphia for its relief. Although the pain did not appear to be as severe as that of gall-stone colic, the surgeon made a definite diagnosis of gall-stones. Two weeks later the patient again suffered from the same sort of pain. In between attacks he had indigestion after every meal—a fullness and an epigastric discomfort. After his second attack of pain a skin irritation developed and he became jaundiced. A cholecystograph showed an enlarged gall-bladder as a faint shadow. Operation was undertaken in the belief that the patient was suffering from gall-stones. A cholecystectomy was performed.

After the operation a discharge of bile continued for ten weeks when, in the belief that the common duct was obstructed, probably from a small

stone overlooked at the time of the operation, the surgeon performed a second operation to relieve this supposed calculous obstruction.

At the second operation he could not demonstrate a stone in the common duct, yet could not pass a probe through the ampulla of Vater. He never thought of the possibility of a carcinoma of the ampulla of Vater, probably because he could not feel a tumour. He made an anastomosis between the common duct and the duodenum. A palpable malignant tumour subsequently developed and the patient died twelve months later.

The combination of the dilated gall-bladder, the absence of gall-stones, and the history of jaundice should have made the surgeon explore the common duct thoroughly at the first operation, especially when the pain associated with the onset was not typical of gall-stones. A biliary discharge for ten weeks indicated without a doubt



Fig. 576.—A, Stasis of contents of duodenum, caused by a carcinoma of the ampulla of Vater.

obstruction of the common duct. Further, the condition could have been proved by lipiodol injection into the common duct and a radiograph of the lipiodol-filled ducts.

In some cases of carcinoma of the ampulla of Vater, where in order to relieve the jaundice an anastomosis between the common duct and the duodenum has been made, the growth may become big enough to cause some obstruction of the duodenum. *Fig. 576* shows a stasis of the duodenum caused by obstruction from a growth in the ampulla of Vater.

Where obstruction of the duodenum thus occurs—that is, in the presence of an anastomosis between the duodenum and the common duct—duodenal contents may be forced up through the common duct into the ducts of the liver. This occurred in the following case:—

A patient, in whom carcinoma of the ampulla of Vater was present in a very chronic form, had a choledochoduodenal anastomosis made. About

two years later he began to vomit large quantities of gastric contents. X rays then showed that, as the result of the spread of the growth, there was some duodenal obstruction, and that as a result of this obstruction duodenal contents had regurgitated into the common duct, and had actually spread up through the bile-ducts into the liver (*Fig. 577*).

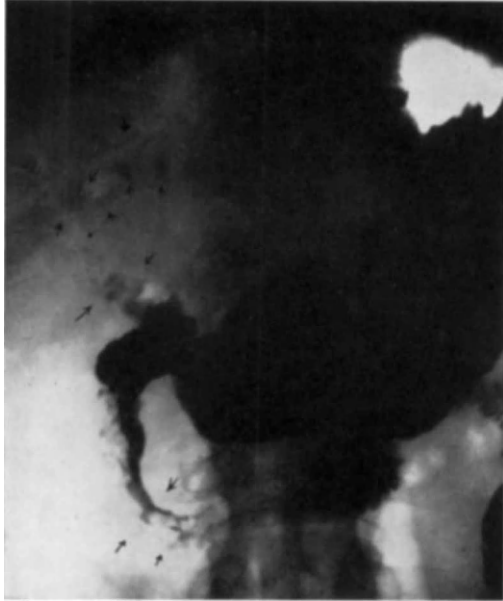

Fig. 577.—Radiograph in a case of carcinoma of the ampulla of Vater, for which choledochoduodenal anastomosis was made. Duodenal contents have regurgitated through the common bile-duct into the liver.

Treatment.—The treatment of carcinoma of the common duct is cholecystogastrostomy if the gall-bladder still remains; but, if cholecystectomy has been performed, then the treatment is anastomosis of the dilated common duct to the first part of the duodenum.

CARCINOMA OF THE PANCREAS

From a clinical point of view, carcinoma of the pancreas can be classified as occurring: (1) In the head of the pancreas; (2) In the body of the pancreas.

I. Carcinoma of the Head of the Pancreas.—Carcinoma of the pancreas is usually of the scirrhus type, and therefore it grows slowly. Tumour formation on palpation of the abdomen is consequently not an obvious feature.

Carcinoma of the head of the pancreas, early in its course, produces a painless, progressive jaundice, without fever, of the 'green'

type. The patient shows a marked constitutional disturbance, losing weight quickly, being unable to work, and having no appetite.

On examination the liver will be found to be enlarged and the gall-bladder dilated. Sometimes, in the early stages of the disease, this enlargement of the gall-bladder manifests itself as only a diffuse lump felt over the region of the gall-bladder. This lump is the dilated gall-bladder lying behind the liver.

If the patient lives long enough, or if a cholecystogastrostomy is performed, a duodenal stenosis, the result of an extension of the growth into the duodenum, may ensue, and the patient may vomit large quantities of gastric contents.

Thus there may be three stages in the course of carcinoma of the head of the pancreas: (a) The carcinoma itself, when the symptoms are due to its effect and to dysfunction of the pancreas from the effects of the growth; (b) Obstructed common duct—jaundice stage; (c) Duodenal stenosis.

Treatment.—In the early stages of the carcinoma, particularly if it is of the invasive type, cholecystogastrostomy should be performed for the relief of the jaundice.

In certain types of carcinomatous growths, deep X-ray therapy will produce considerable regression of the tumour, and it should be employed after the operation. In one case of carcinoma of the head of the pancreas confirmed by biopsy, in which I carried out a cholecystogastrostomy and followed this up by deep X-ray therapy, the patient was alive five years later. In other similar types of cases the patients have lived two, three, and four years. In the majority of cases, however, deep X-ray therapy has had little effect.

2. Carcinoma of the Body of the Pancreas.—Clinically carcinoma of the body of the pancreas comprises two types: (a) A soft proliferating form of growth, which may form a palpable tumour; (b) A hard invasive type of scirrhous growth, which does not give rise to a palpable tumour.

a. The Soft Proliferating Type.—This type of tumour gives rise to symptoms and signs which are almost indistinguishable from those of a carcinoma of the body of the stomach; that is, it gives rise to loss of energy, secondary anæmia, loose stools, and cachexia. As a rule, with this form of carcinoma of the body of the pancreas the patient experiences no pain. Jaundice may occasionally occur if the growth extends to the common duct. Radiography shows a filling defect in the stomach where the tumour pushes up into this organ, and this filling defect is very like that of carcinoma of the body of the stomach.

Carcinoma of the body of the pancreas is very often the cause of a wasting cachectic type of illness, the origin of which is obscure. Its syndrome is usually confused with that of 'silent' carcinoma of the stomach.

b. The Hard Invasive Scirrhus Type.—In the invasive scirrhus type of carcinoma of the body of the pancreas, the symptoms are quite unlike those of the proliferating type, which is painless; the patient not infrequently suffers from agonizing pain coming on in attacks. He does not suffer from the gross ill health, wasting, and cachexia which characterize the proliferating type. The pain is sometimes so severe that it is not relieved even by large doses of morphia. On examination of the abdomen a certain amount of rigidity may be found.

In regard to these differing types of tumours, I recall the histories of two patients who came into my surgery on the same day, both suffering from carcinoma of the body of the pancreas.

One was a very sick man, anæmic, wasted, and cachectic, who had a tumour, easily palpable, in the neighbourhood of the umbilicus. This patient had no pain whatever. The other was a big, rather robust man, who had lost some weight and who complained of continual attacks of agonizing pain. His pain was so great that even the $\frac{1}{2}$ -gr. of morphia which was administered to him did not relieve it.

Operation on the first patient revealed a large soft tumour of the body of the pancreas, while in the second patient there was a firm scirrhus growth in the same situation.

Thus we see that the soft tumour gave rise to no pain, whereas an invasive tumour in the same situation gave rise to great pain.

Late stages of invasive carcinoma of the body of the pancreas may give rise to a curious syndrome, and one very difficult to recognize, as is shown in the following case:—

A man, aged 45, began to suffer from pains in the abdomen, starting in the left side and crossing to the right and downwards to the pubic region. Six months after the onset of these pains he began to vomit at irregular intervals. The vomitus was copious, and appeared to be due to a pyloric stenosis. His appetite diminished, and he became constipated. He lost 3 st. in six months. A tumour could be felt in the left part of the epigastrium, a tumour which appeared to be the spleen.

At operation the veins in the upper part of the abdomen were found to be enormously dilated. The stomach was very dilated and hypertrophied, although the pylorus was patent. The spleen was about three times as large as normal, and was congested. Behind the stomach was found an infiltrating invasive carcinoma of the body of the pancreas, which had spread on to the duodenojejunal flexure and caused almost complete obstruction of the upper part of the jejunum. The carcinoma had also

infiltrated the splenic vein and caused venous obstruction in the spleen, to which was due its increased size. The liver was normal. *Fig. 578* is an operation sketch of this case.

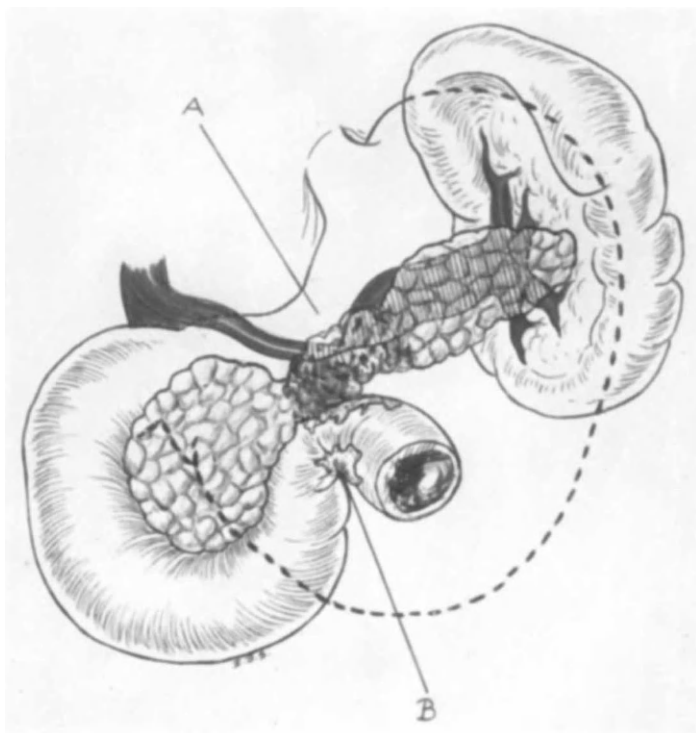


Fig. 578.—Operation sketch of an invasive carcinoma of the middle of the pancreas infiltrating the splenic vein and causing almost complete obstruction of the upper part of the jejunum. **A**, Carcinoma of the pancreas; **B**, Spread of the carcinoma on to the duodenojejunal flexure.

In the treatment of the tumour type of carcinoma of the body of the pancreas, deep X-ray treatment may help.

CHOLECYSTOGASTROSTOMY

Cholecystogastrostomy is indicated in cases where there is obstruction of the common duct by a carcinoma, either in the duct itself, or in the head of the pancreas. The opening between the gall-bladder and the stomach should be made as small as possible. If it is too big, the contents from the stomach may be forced into the gall-bladder, and as a result of this, infection of the ducts—that is, cholangitis—may occur.

Technique.—Cholecystogastrostomy should be carried out as follows :—

1. The gall-bladder is approximated to the stomach at a point as far away from the pylorus as the length of the gall-bladder will permit—the nearer the anastomosis is made to the pylorus the more are

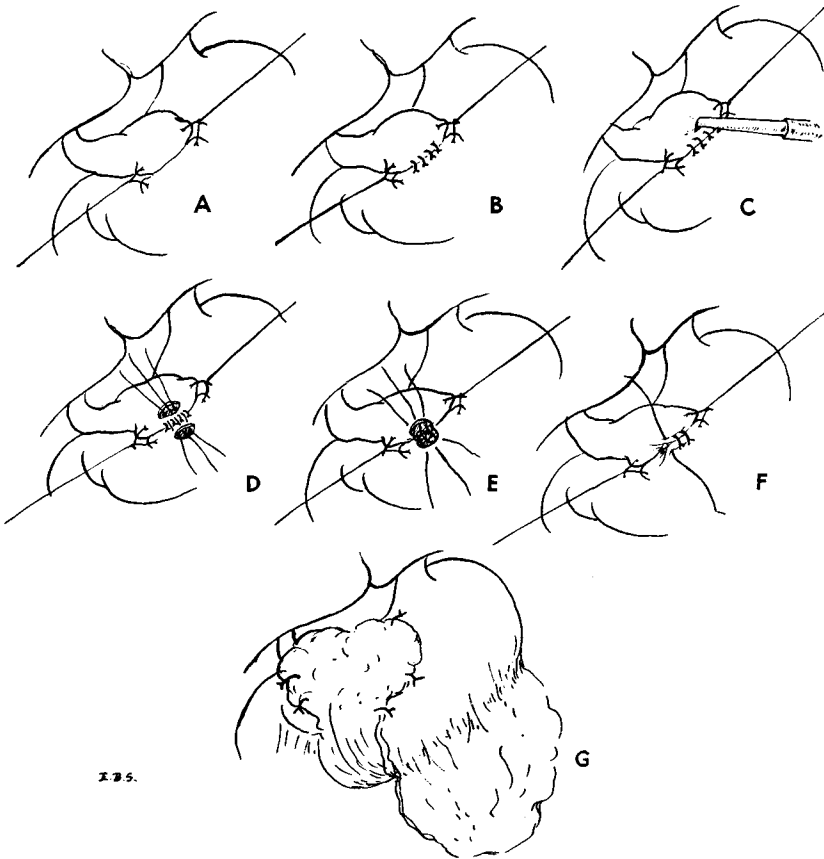


Fig. 579.—A-G, Steps in the technique of cholecystogastrostomy.

gastric contents liable to be forced into the gall-bladder. The fundus of the gall-bladder is attached to this part of the stomach by 'guy-rope' sutures, which are then fixed to the operating frame (*Fig. 579, A*).

2. Four interrupted sutures are now inserted in the seromuscular layer (*Fig. 579, B*).

3. The contents of the gall-bladder are aspirated through an opening at that point on the gall-bladder where the opening will be made for the anastomosis (*Fig. 579, C*).

4. Openings less than half an inch long are now made in the gall-bladder and in the stomach. Three interrupted sutures are introduced (*Fig. 579, D*).

5. The anterior mucous-membrane tier is closed with three interrupted sutures (*Fig. 579, E*), and finally four interrupted sutures are used to close the anterior seromuscular tier (*Fig. 579, F*).

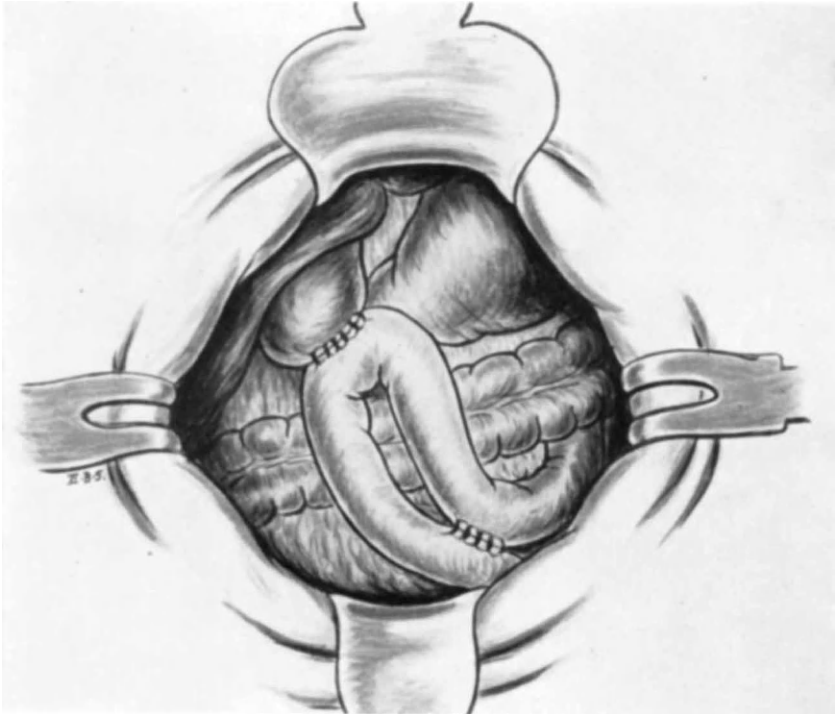


Fig. 580.—Gall-bladder anastomosed to an isolated loop of small intestine, brought up in front of the transverse colon. An entero-anastomosis has been made between the two sides of the loop to render it functionless.

6. The omentum is now 'backwashed' and so tacked on to the stomach and gall-bladder that it closes any opening left between the gall-bladder and the stomach, thus preventing prolapse through it of any intestines (*Fig. 579, G*).

It may sometimes be advisable to suture the gall-bladder to an isolated loop of small intestine. *Fig. 580* shows an operation where the gall-bladder has been anastomosed to such a loop, which has been brought up in front of the transverse colon. An entero-anastomosis is made between the two sides of the loop, so as to render it functionless.

CHOLEDOCHODUODENOSTOMY

The operation of choledochoduodenostomy is specially applicable to a certain type of case—namely, that in which the gall-bladder is removed and an obstruction occurs at the lower end of the common duct, caused by a stone which cannot be removed, by a carcinoma of the pancreas, or by a carcinoma of the ampulla of Vater. The very dilated common duct, where it lies behind the first part of the duodenum, is easily anastomosed.

Fig. 581 shows the technique. On account of the smallness of the anastomosis, interrupted sutures must be used. The stoma

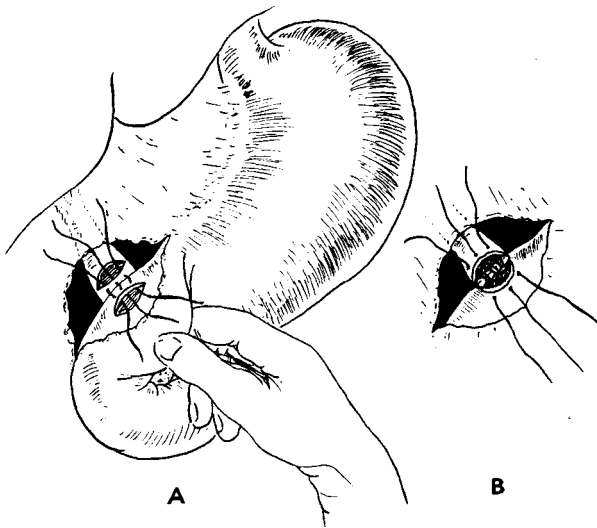


Fig. 581.—Technique of choledochoduodenostomy. **A**, First and second layers of sutures inserted; **B**, First row of anterior sutures.

between the common duct and the duodenum must be made as small as is compatible with the proper emptying of the common duct, and big enough to allow for cicatrizing action. If the stoma is too big, regurgitation of contents occurs into the common duct, and sometimes stagnates there for as long as eight to twelve hours. This stasis predisposes to infection and the occurrence of a cholangitis. The opening should be like a fistula in its action.

Bernhard¹ was able to show after barium meals that in two out of six cases in which an anastomosis had been made between the common duct and the duodenum, the duodenal contents were forced into the common duct and even into the ducts in the liver, as shown in *Fig. 582*. The common duct becomes like a retroduodenal

appendix, and it can be demonstrated that in some cases it remains full of duodenal contents for six to ten hours after the X-ray meal.

This, as has been pointed out, is due sometimes to an obstruction of the duodenum, and at other times to the fact that the opening between the duodenum and the common duct has been made too big. In such cases, if the gastric contents are deficient in hydrochloric acid, infection of the biliary passages may occur. But most cases in which



Fig. 582.—Choledochooduodenostomy. X, Anastomosis between common duct and duodenum. (Bernhard.)

regurgitation of contents into the common duct occurs remain more or less free from trouble for a considerable time.

It will thus be seen that an anastomosis between the duodenum and the common duct should not be lightly made; for example, it should not be made merely because the surgeon finds it difficult to remove an obstructing stone from the ampulla of Vater, for there is the very real danger of the development of a cholangitis: in such circumstances it should be a last resort.

REFERENCE

- ¹ BERNHARD, F., "Das Übertreten von Magen- oder Duodenalinhalt in die Gallenwege nach operativ angelegten Anastomosen, besonders nach der Choledocho-Duodenostomie, im Röntgenbild und seine klinische Bedeutung", *Der Chirurg*, 1934, **6**, June 15, 444-7.

CHAPTER LXV

CONSULTATION ON A CASE OF JAUNDICE

At this stage, when the pathological conditions of the spleen, liver, gall-bladder, and pancreas have been dealt with—all conditions which may cause jaundice—a consultation on a case of jaundice may appropriately be considered. This will involve its diagnosis, the question whether it is of surgical import, and the operative treatment required.

JAUNDICE OF SURGICAL IMPORT

Causes.—The conditions causing jaundice for which operation is necessary are :—

1. Acholuric jaundice.
2. Gall-stone obstruction : (a) 'Ball-valve' stone in the common duct ; (b) Impacted stone in the common duct ; and (c) Stone impacted at the junction of the common and cystic ducts.
3. Carcinoma of the common duct or the ampulla of Vater.
4. Carcinoma or chronic inflammation of the head of the pancreas.
5. Hydatid conditions : (a) Central hydatid of the liver with daughter cysts opening into the common duct ; (b) Hydatid pressing on the common duct to the portal fissure ; (c) Suppurating hydatid of the liver ; and (d) Hydatid of the head of the pancreas.

Elimination of Acholuric Jaundice.—The first consultative step should be to make sure that the case is one of obstructive jaundice, and not one of an acholuric type. Too often this point is forgotten. An enlarged spleen is not noticed, and the attacks of jaundice, associated with pain and fever, are regarded as being due to a stone in the common duct. The absence of bile in the urine and its presence in the stool, and a fragility test of the red cells, will at once show whether the jaundice is of an acholuric nature.

The fact that the possibility of acholuric jaundice does not occur to the surgeon's mind causes mistakes in this respect to be made. Recently I saw a case which had been operated on for "gall-bladder trouble" because the patient had had attacks of jaundice, pain, and fever. The attacks continued, and many years later he was again operated upon, under the assumption that he had a stone in his common duct. It was not until the third operation that it was

discovered that he had an enlarged spleen, and had been suffering from an acholuric jaundice.

In another case, quoted on p. 598, a patient developed jaundice, and had what was obviously a hydatid of the left lobe of the liver. Very naturally it was thought that the hydatid was the cause of the jaundice. At the operation the spleen was found to be enlarged. The jaundice was of splenic origin—acholuric; it was not caused by the hydatid.

Significance of Painful Jaundice.—It may be taken as a general working rule that a jaundice which comes on with more or less severe pain is of surgical import, that it is due to an innocent cause such as gall-stones or hydatid, and that it is curable by operation.

On the other hand, it may be assumed that a jaundice which comes on without pain may be due to medical disease but is nearly always caused by some malignant condition which is not curable by operation, although surgical intervention may be necessary to give temporary relief.

In the jaundice caused by gall-stones the acute pain is due to the sudden obstruction. In the case of a jaundice caused by a carcinoma of the head of the pancreas, little if any pain is produced, because the obstruction occurs slowly.

In the case, however, of a jaundice resulting from the closing of the common duct or the ampulla of Vater by an intrinsic carcinoma, the obstruction occurs fairly quickly on account of the small calibre, and consequently a considerable amount of pain may be produced. Thus a jaundice arising from a carcinoma of the common duct or its ampulla may be mistaken in its early stages for that of a gall-stone in the same situation.

Significance of the Colour of the Jaundice.—Incomplete obstruction gives rise to a 'yellow' jaundice; and as this form of jaundice occurs only in gall-stones and in hydatid disease—both innocent conditions—a 'yellow' jaundice has come to be regarded by the laity as an indication of jaundice due to an innocent cause. It is probably due to the absorption of fairly fresh bile, which consists mostly of bilirubin.

On the other hand, complete obstruction causes a 'black' or a 'green' jaundice, and as this kind of jaundice is nearly always due to malignancy, it has come to be regarded as a cancerous form of jaundice. Biliverdin, the predominating bile-pigment in stale bile, is responsible for the colour.

Significance of a Jaundice Associated with Infective Symptoms.—Fever, rigors, malaise, digestive disturbances, and other

conditions associated with an infection are only seen with a jaundice caused by a 'ball-valve' stone in the common duct and by daughter cysts in the common duct.

Significance of a Jaundice Associated with a Dilated Gall-bladder.—As a general rule, jaundice accompanied by a dilated gall-bladder is due to a malignant cause. A stone big enough to block the common duct must be pushed out of the gall-bladder by fibrotic contraction—that is, pushed out by the fibrosis that follows a continued inflammation of the gall-bladder—for it is too big to be forced out by muscular contraction. Thus, most of the large stones which find their way into the common duct come from gall-bladders that are small and not distensible, and therefore they are impalpable. Furthermore, it requires a complete and permanent obstruction of the common duct to produce dilatation of the gall-bladder, while most obstructions of the common duct by stone are of course not complete, but are of the 'ball-valve' type.

There are, however, cases of common-duct obstruction caused by a large stone, and in which the gall-bladder is dilated, but it is not so dilated as in carcinomatous obstruction.

The absence of a dilated gall-bladder is of considerable diagnostic importance, because in the presence of a complete obstruction of the common duct this feature may be a clue suggesting that the obstruction is caused by an impacted stone and not by a carcinoma.

Important Points in Diagnosis.—If a jaundice arises with acute colicky pain, is remittent, is associated with infective symptoms—rigor, fever, malaise, etc.—and if there is no enlargement of the gall-bladder, then the jaundice is due either to gall-stones or to central hydatid with daughter cysts in the common duct.

If a jaundice comes on without pain, is unremitent, unassociated with infective symptoms, but accompanied by a dilated gall-bladder and an enlarged liver, then the jaundice is usually caused by carcinoma of the head of the pancreas.

But if a jaundice is unremitent, progressive, and 'black'—that is, is the result of a complete obstruction of the common duct—and no gall-bladder can be felt, the important question should always arise as to whether it is not caused by a smooth round stone which has become impacted with almost unnoticeable pain in the ampulla of Vater—a curable condition. A case of this nature is quoted on p. 680.

Even if a jaundice is progressive, is unassociated with infective symptoms, arises without pain, and even though it is 'black' and unremitent and accompanied by an enlarged gall-bladder, it must not be forgotten that the symptoms can be caused by a smooth

round stone encysted at the junction of the cystic and common ducts. Such a condition is not unusual, and is curable (*see* example, p. 666). Close investigation may reveal an obscure previous history of gall-stones or onset of the jaundice with slight pain.

Notwithstanding the fact that a jaundice has arisen painlessly and appears to be the jaundice of complete malignant common-duct obstruction—that is, it is without remissions, there are no infective symptoms, the jaundice is ‘black’ and progressive—the surgeon must still try to discover whether it may not be caused by a surgically curable condition: he must make certain that such a form of jaundice is not caused by a hydatid in the portal fissure or in the head of the pancreas, either of which could give rise to complete obstruction of the common duct and to a painless jaundice. As a rule, it is almost certain that a tumour would be felt if hydatid were the cause; and, of course, the serum reactions for hydatid might be positive.

Conditions which Cause Slight Jaundice.—Very often there are conditions which give rise to a mild jaundice, and which confront the surgeon in regard to the question of operation.

Where the mild jaundice is associated with infective symptoms—fever, etc.—and even though it is painless, it may be due either to a stone or a ‘filter-bed’ of stones (*see* p. 681) in the common duct, or to a suppurating hydatid in the liver, in which latter condition there is an associated infection of the smaller bile-ducts. Such a syndrome may, however, also be caused by a portal pyæmia. A hydatid test will distinguish the hydatid condition; the previous history or a cholecystogram may suggest gall-stones; and some infective origin will be sure to be found for the portal pyæmia.

A mild jaundice is often associated with an infective cholecystitis, but here the symptoms of gall-stones or cholecystitis are generally very obvious, and the jaundice is only secondary to the infective condition of the gall-bladder, probably due to a catarrh of the bile-ducts.

Chronic pancreatitis can cause a mild jaundice. In this case there will be found manifestations of gall-bladder disease.

Jaundice more or less mild may be found associated with an enlarged liver and spleen in splenic affections like polycythæmia (*see* p. 623) and the later stages of splenic anæmia. In these conditions, the surgeon will have to consider the question of splenectomy.

As a rule, jaundice caused by secondary deposits in the liver is not severe. As a considerable quantity of liver substance must be destroyed by the secondaries before jaundice will develop, it will

be found that if the jaundice is any way definite, a lumpy enlargement of the liver can be palpated.

JAUNDICE OF NON-SURGICAL IMPORT

Before coming to a definite conclusion in a consultation on a case of jaundice which is supposed to be of surgical import, the question whether it might have arisen from medical disease ought to be considered.

Jaundice of non-surgical import, due to causes which concern the physician, is generally quite painless in its onset. But in this respect there are exceptions: there are the attacks of jaundice associated with a cirrhotic liver, which have pain over the right side of the lower part of the chest and also a diffuse tenderness over the liver; and there is the jaundice seen in cases of venous congestion coming on rather suddenly in heart failure, especially when it occurs in a liver already fibrous and tough from other causes, in which cases moderate pain is present in the region of the liver and also a diffuse tenderness over the same region—a condition which is frequently mistaken for an inflamed gall-bladder, a suppurating hydatid, or a small stone in the common duct.

A deep jaundice resulting from injections of salvarsan or from a toxic hepatitis is painless in onset, 'yellow', unremitting, not associated with marked constitutional symptoms, and is accompanied by a firm enlarged liver.

A catarrhal jaundice may be of a mild or severe type and may start to get better in a month or two. It may occur in members of the same family.

Sometimes a loose kidney dragging on the duodenum will kink the papilla of the common duct, and thus cause a transient jaundice.

CHAPTER LXVI
**OPERATION-TABLE PROBLEMS IN A CASE
 OF JAUNDICE**

WHEN NO OBVIOUS SURGICAL CAUSE IS FOUND

AT operation in a case of jaundice a cause is usually obvious. An obstruction of the common duct by a gall-stone, a carcinoma, hydatid daughter cysts, or an obstruction of the ampulla of Vater by a malignant or inflammatory condition of the head of the pancreas is, as a rule, easy to recognize.

Sometimes, however, the surgeon can find no obvious surgical cause for the jaundice. At this stage he may be in one of two positions. In the first he may find that he cannot detect any affection of the common duct and that he can pass a probe through its ampulla without encountering obstruction. In the second case, although no lesion may be obvious in the duct, yet he is not able to pass a probe through it into the duodenum.

In the first case the following questions arise :—

1. Is there a stone in the duct too small to be detected by feel or by the probe ; or a stone which has slipped up in a dilated common duct towards the liver ?
2. Is the jaundice due to obstruction from daughter cysts discharged from a central hydatid into the common duct ?
3. Is it a jaundice caused by disease of the liver as a result of one of the causes described on p. 625 ?

In the second case the question which arises is whether the jaundice is caused by the early stage of a scirrhus carcinoma of the ampulla of Vater which will not let the probe pass but is too small to be felt.

A probe can pass a small flat stone which is lying on its edge, but which when it lies flat may obstruct the duct. A stone lying like this and flat against the pancreas cannot be felt (*see Fig. 563, p. 708*).

A probe may fail to pass because it is not in the right axis, or because it is caught in a little pouch, and the failure to pass may be of no significance. On the other hand, it may not pass because the actual orifice may be the subject of a small and impalpable carcinoma.

As a rule, if hydatid daughter cysts are the cause of the jaundice they may not be palpable but they will be found when the duct is opened; they may, however, be the cause and not be in the duct at the time of the operation.

It is in the elucidation of such an operation-table problem and at such a stage of the problem, that cholangiography will help.

Cholangiography.—A method of outlining the common duct by the injection of radiopaque substances—cholangiography—was originated by Mirizzi. At the operation, thorotrast is injected into the common duct—by means of a hypodermic needle if the duct has not been opened, or through a small sutured-in rubber tube if the duct has been opened.

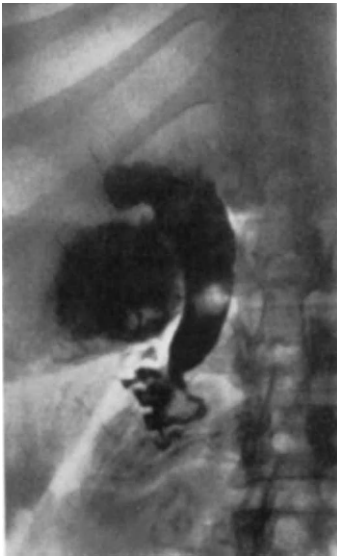


Fig. 583.—Cholangiogram showing a dilated common duct and the negative shadow of a calculus. (*Zopff.*)

A portable X-ray apparatus, so arranged that it does not interfere with the sterility of the operation or the movements of the operator, is used to make the radiograph, which will show: (1) The degree of dilatation of the common duct; (2) The patency of the ampulla of Vater; (3) Any alteration of the contour of the ampulla (indicating malignancy); (4) Any negative shadows (indicating gall-stone or daughter cysts).

Fig. 583 shows a cholangiogram from Kirschner's clinic (*Zopff*), in which is seen a dilated common duct, as well as the negative shadow of a calculus.

The Problem in the Light of Cholangiography.—If now, in this operation problem of an unobvious cause for jaundice, a cholangiogram shows an impatent or partially patent ampulla, or a negative shadow, then the surgeon knows what to do. He will find the stone, or in the case of carcinomatous obstruction he will carry out an internal drainage operation (*see p. 744*).

If the cholangiogram should show nothing abnormal, the surgeon will then be forced back in his search towards the liver—forced to consider central hydatid of the liver (*see p. 632*), or disease of the liver (*see p. 625*) which can produce a deep jaundice.

The liver is then searched for a central hydatid. The assistant, by slowly elevating the operating frame, lifts the thoracic and abdominal wall away from the front of the liver (*see* p. 647). The surgeon, with the left hand behind the liver and the fingers of the right in front, palpates the whole of the liver for any inequalities of density. In the case of a central hydatid the liver may not be enlarged. The normal sharp edges of the liver are, however, usually rounded. An exploring needle attached to *strong* suction may bring out a bit of hydatid membrane on its point—it has to be remembered that the original hydatid cyst will be collapsed and the cavities will contain only daughter cysts. Finally, if still in doubt, a cholangiograph may have to be made by injection of lipiodol into the hepatic ducts by way of the common duct, either at the time of the operation or after. Central hydatid when collapsed is often extremely difficult to find.

In the absence of a central hydatid—and in most countries it is not a common occurrence—the surgeon then considers the question of disease of the liver which will produce a deep jaundice, as in the following case-history:—

A man, aged 60, became deeply jaundiced. He had no pain. His liver felt enlarged and firm and his gall-bladder was thought to be dilated. Although his jaundice had been present for two months, nevertheless his general health was comparatively good.

The operation findings showed no common-duct obstruction, but a somewhat enlarged, round-edged liver, firm as a board, and nutmeg-coloured—the same sort of liver that is found in cases of deep jaundice after arsenical injections.

No cause could ever be found to account for this liver condition; and this case is only an example of many others.

Other causes of jaundice arising from disease of the liver, generally of a lesser degree, are discussed on p. 752.

THE DISTINCTION BETWEEN CARCINOMA AND CHRONIC INFLAMMATION OF THE PANCREAS

In the case of a jaundice in which the head of the pancreas is found enlarged and hard, a diagnostic problem in the pathology of living tissue arises: Is the enlargement due to carcinoma or to chronic inflammation? The following observations will serve as a guide:—

1. Deep jaundice and moderate enlargement of the head of the pancreas indicates carcinoma. Deep jaundice arising from chronic pancreatitis is rare; on the contrary, a very large chronic inflammatory enlargement of the head of the pancreas with little or no jaundice is often seen. Fixation—infiltration—is necessary for the

production of deep obstructive jaundice by a pancreatic tumour. The inflammatory tumour presses on the ampulla; it does not close an ampulla by infiltration as carcinoma does.

2. The obstruction from chronic pancreatitis is usually incomplete and cholangiography will show this.

3. In the absence of disease of the gall-bladder, dilatation of this organ points to complete obstruction—to malignant pancreas. It is only when the gall-bladder is hard and rigid from disease that it does not distend. Consequently, when assessing the significance of the absence of dilatation, eliminate the possibility of chronic cholecystitis.

Non-dilatation of the gall-bladder in chronic pancreatitis may be due either to the fact that it does not cause complete obstruction, or to the fact that the pancreatitis is an extension of an infection from a severely infected and inflamed gall-bladder.

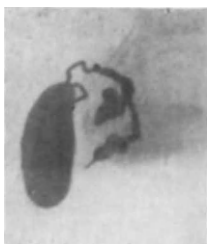

Fig. 584.—Showing the patency of the common duct when tested by cholangiography some time after an external drainage operation.

(From the 'Zentralblatt für Chirurgie'.)

4. A chronic pancreatitis is usually associated with a diseased gall-bladder, for this is its causative origin.

5. A chronic pancreatic tumour is hard but leathery. Features of the patient's illness are sickness and vomiting, just as in carcinoma of the stomach.

Operation where the Nature of the Pancreatic Tumour is in Doubt.—It may be possible that the diagnosis of carcinoma cannot be established. Where the weight of evidence is in favour of chronic pancreatitis, a cholecystogastrostomy should not be made. This operation as a permanency is not without the danger of an ascending cholecystic or hepatic infection. The gall-bladder should preferably be drained by a small external fistula. After three or four weeks the diagnosis can be checked by cholangiography. If the condition is inflammatory, enough resolution will have taken place to permit a free flow of the radiopaque substance into the duodenum.

The fistula will close soon if the duct becomes patent.

Fig. 584 shows the patency of the common duct when tested by cholangiography some time after an external drainage operation.

Where the operation is permanent it is necessary to make a permanent internal fistula into the stomach, duodenum, or intestine. In such circumstances it may be wise to make the fistula into an isolated loop of jejunum (*see* p. 727). The muscular stomach and the duodenum, if the fistula is made into these organs, may force their contents into the bile-passages, and where the internal fistula is to last for a long while this regurgitation may ultimately lead to infection. The functionless loop and the weaker-muscled intestine are less likely to beget regurgitation and hepatic infection than the fistula into the muscular stomach with its wealth of contents. Further, it permits easier natural closure if the natural passage should become patent.

Section II

POST-OPERATIVE COMPLICATIONS

CHAPTER LXVII

**COMPLICATIONS OF THE EARLY
POST-OPERATIVE PERIOD**

DURING the *early* post-operative period—the first five days after operation—the following complications may occur :—

I. Acute circulatory disturbance—shock, collapse, or cardiac failure.

II. Excessive and persistent abdominal pain and vomiting.

III. Post-operative distension, paralytic ileus, and intestinal obstruction.

IV. Pulmonary complications.

The present chapter is devoted to a consideration of the first of these complications.

I. ACUTE CIRCULATORY DISTURBANCE

Any severe abdominal operation is apt to be followed by some degree of acute general circulatory disturbance; but operations in the upper part of the abdomen, especially those of the stomach, are liable to be followed by a considerable degree of that form of circulatory disturbance called shock or collapse. The circulatory mechanism has as a result of the operation been subjected to a severe strain, the effects of which are partly manifested in much the same way as those resulting from very strenuous bodily effort. It is also disturbed by the action of injury on the nervous system, and by the effects of the tissue injury associated with the operation—that is, by products arising from the destruction of tissue.

The reason why this circulatory disturbance is usually more severe in operations in the upper than in the lower part of the abdomen is that organs in this region are more vital, and have not only a richer sympathetic nerve-supply, but also a more profuse supply of lymphatic vessels capable of more rapid absorption—both of them conditions which do not obtain to the same extent in the

lower part of the abdomen. Thus the circulatory disturbance that endangers life more frequently follows operations in the upper abdomen.

This circulatory disturbance is by some writers called shock, by others collapse; most, however, term the acute circulatory disturbance immediately following the operation *shock* (neurogenic cause), and that coming on a day or two later *collapse* (toxic cause).

Causation.—Post-operative circulatory disturbance or shock cannot be attributed to any one cause. It is the combined effect of many interacting factors set in motion by the operative disturbance. It may be closely simulated by a circulatory disturbance arising from cardiac failure. In order that the surgeon may be able to manage a post-operative circulatory disturbance properly, he should be capable of analysing the complex picture often presented in this condition, and he should understand the various mechanisms which produce it, so that he may be able to individualize in the treatment of a case.

In considering this condition of circulatory disturbances following severe operations, it is necessary to distinguish between (1) the patient who has actually—not hypothetically—a normal circulatory mechanism, and (2) the patient who starts out with some crippling of either his cardiac or peripheral circulation.

It will be obvious that a pre-existing circulatory crippling may introduce a large element of cardiac failure into a post-operative circulatory disturbance which might be regarded as a pure post-operative shock or collapse; and that, from a therapeutic standpoint, it is necessary to be able to estimate the extent of this central failure, because the treatment of the condition caused by it is diametrically opposite to that of the peripheral-failure collapse.

I. CASES WITH A NORMAL CIRCULATORY MECHANISM: SHOCK AND COLLAPSE

Shock and collapse may be defined as the dramatic condition caused by some external influence, either psychic or physical, the chief characteristic of which is a more or less profound circulatory disturbance with its incidence on the peripheral vascular mechanism. A somewhat similar condition to post-operative shock and collapse may be induced by such agencies as trauma, toxæmia, anaphylaxis, hæmolysis, and even by psychic disturbances. Shock and collapse, therefore, have many causes all giving rise to a similar clinical picture—a sudden circulatory exhaustion, revealing itself by pallor, sweating, a rapid pulse, a rapidly falling blood-pressure, increased respirations, and apathy.

The conditions which occur in shock and collapse are the same whether these are caused by trauma, severe operation, infection, or by other of the above-mentioned causes.

In these various types of shock and collapse, the initial injury is always found in the walls of the capillaries. Capillary paralysis, capillary dilatation, and increased porosity of the capillary walls follow; and as the result of these changes, plasma passes from the blood-stream into the tissues. Contraction of the small arteries and the arterioles—caused perhaps reflexly—now follows, and the general result is a certain amount of circulatory stasis.

The outcome of all these changes is that less blood reaches the tissues, and therefore less oxygen; poisonous metabolites result from this insufficient oxidation; and these metabolites give rise to further poisoning of the capillary walls with further capillary dilatation.

There follows a decrease in the amount of the circulating blood, and an increase in the amount of blood in the 'blood-depots'—the liver, the spleen, and the abdominal vessels—and thus there is a rapid falling of the blood-pressure.

As a result of these changes, and particularly of the fall in blood-pressure and the decrease in the amount of circulating blood, there is a lessening of the systolic output, and thus an insufficient supply of blood reaches the right heart.

At the same time impulses originating possibly from the contraction of the arteries, possibly through humoral channels, reach the adrenal bodies and adrenaline is poured out. The outpouring of adrenaline causes a compensating increase in blood-pressure, and for a time helps to stem the tide, but as the blood-pressure falls and the amount of circulating blood decreases, a phase of the circulation arises when there is insufficient blood, and therefore an insufficient supply of oxygen, to supply the heart muscle, the vital nerve-centres in the medulla, and the ganglionic centres of the peripheral vascular mechanism.

A stage is thus reached when these centres are exhausted and when they can no longer transmit impulses to raise the blood-pressure, and when therefore a state of collapse exists.

This, then, is the condition we find after severe operations, regardless of its various names and its causation.

The Exciting Causes of Shock and Collapse.—When we come to consider the cause of acute post-operative circulatory disturbance, the same unanimity is not found among the various observers as is found in regard to its manifestations.

There are two main causes of shock; two components, one a quick-acting neurogenic factor, and the other a slow-acting auto-genously produced toxic substance.

The Quick-acting Neurogenic Cause.—This is seen in the shock produced when strangulated bowel is being pressed back into the abdomen, or when a sciatic nerve is being divided. It is also seen in injury to the sympathetic nerve-endings, which produces much neurogenic shock. Neurogenically produced shock comes on immediately—that is, at the time of the operation; it comes on dramatically and requires urgent treatment. It can be brought about psychically: death from shock has followed great terror, and a certain amount of psychically produced shock follows most operations.

The early symptoms and signs of shock—typical of what we, as surgeons, have always understood as shock, and sometimes called *primary shock*—appear during or immediately following the operation.

The Slow-acting Cause.—As the above-described shock symptoms abate, somewhat similar symptoms and signs begin again to appear as the result of a slowly acting cause. They come on slowly after the first eighteen to twenty-four hours. This condition is sometimes referred to as *secondary shock*, or as the erethic phase of shock (Rehn¹), or as chemical shock. It is not shock in the sense that it comes on dramatically and requires immediate treatment. This rather slowly developing phase is regarded by most physiologists as being caused by a second important shock-producing component—a toxic substance arising as a result of the injury to tissue, a toxin which produces capillary injury and paralysis, or perhaps acts through the nerve-muscle endings.

It was at first thought that this toxic substance was histamine, because symptoms similar to those of shock follow from poisoning by this substance. However, it has not been found in the blood in cases of shock—though it must be remembered that it is extremely difficult to isolate. A toxic substance has been found in the blood-stream of experimentally shocked animals, and in the blood-stream in cases of peritonitis. Toxic substances have been isolated from defibrinated blood and also from fresh blood (Freund²) which, when injected into animals, cause the symptoms of fatal shock. König³ has shown that small doses of crushed muscle extract injected intravenously can kill an animal, and he has also isolated from degenerated blood-platelets and from broken-down products of nuclear degeneration a substance which, when injected, produces shock. He has pointed out that both these substances are found in the blood after extensive operations, after serious trauma, and in cases of severe

burns. Injection of any of these poisonous substances will produce a falling blood-pressure, a decrease in the amount of circulatory blood, and an increase in the volume of blood in the lung, the liver, the spleen, and the extremities: in effect, a condition of shock. Switching out the nervous system by anæsthesia does not prevent or lessen the development of shock.

König³ has recently proved that it is not the rapidly falling blood-pressure alone which causes death. He showed that substances which prevent the clotting of blood, injected into animals in which a condition of otherwise fatal shock had been produced, in some peculiar way prevented a fatal result.

Hence we see that shock is a highly complex process which can be caused by injury to sympathetic and sensory nerves, by some circulating toxic product acting on the peripheral vascular system, or by a sudden disturbance in the blood-clotting system.

Prevention of Post-operative Shock.—

Neurogenic Shock.—Neurogenic shock can, to a certain extent, be avoided, and therefore the best post-operative treatment of shock is carried out by the surgeon before operation and at the operation table, when he uses his physiological knowledge, his ingenuity, and his skill to avoid producing psychic or neurogenic shock. A surgeon who is mentally and physically well equipped for the performance of abdominal operations—or indeed of any operation—will produce far less shock than one who is less competent, as, for instance, the ‘occasional’ surgeon.

The Role of Anæsthesia.—Deep, prolonged, and badly given general anæsthesia will produce ‘chemical shock’. Deep general anæsthesia weakens the heart, the tone of the vessels, and the breathing centre. Its action on the muscles also lessens the amount of circulating blood, especially in old people. A happy choice of an anæsthetist who gives a minimum amount of anæsthetic or a careful choice of the general anæsthetic may do much to prevent shock. Nitrous oxide gas, supplemented with ether at certain stages of the operation where relaxation is required, may lead to fewer serious post-operative circulatory effects than if ether alone is given. Local anæsthesia switches off the painful afferent impulses from the brain centres and lessens shock. For example, in certain cases of carcinoma of the stomach, where there is great debility, the use of local anæsthesia will avoid shock and collapse. Spinal anæsthesia (Kirschner) taking in only a section of the body—the belly—reduces shock. Again, morphia, eukodal, and similar drugs short-circuit the psychic centres and lessen shock.

The Role of the Surgeon.—The surgeon unthinkingly produces shock in many ways :—

1. By eventration of the intestines : the exposure allows drying, loss of gas, and causes the pendulum movements to cease ; the dragging of the omentum and intestines on to the abdominal wall causes shock.

2. By blunt dissection. He should use sharp knives, scissors, or the electric knife (the last probably causes the least shock in solid tissues).

3. By performing too big an operation for the patient's strength or collapse resistance ; he should operate in stages in more cases.

4. By emptying large cavities (pus) or obstructed intestinal coils too quickly.

5. By exposing the patient to too great heat or too great cold (patient has lost heat-regulating mechanism).

6. By unnecessary blood-loss.

7. By too much post-operative medication.

8. By large and ill-placed incisions, which do not uncover the 'heart' of the operation area, and which therefore entail much pulling about and bruising of tissues.

9. By operating *at once* (without proper preparation) on those patients whose collapse-resisting power has been lessened in any of the following ways : (a) By exhausting work (doctors and nurses) ; (b) By hunger or exposure to cold ; (c) Following diarrhœa ; (d) By much vomiting ; (e) By long 'bed rest'.

The Prevention of Shock by Anticipating It.—It is sometimes very wise to anticipate the onset of shock where it is likely to arise, and give, during the operation or before the patient leaves the operating table, an intravenous infusion of two pints of Ringer's solution with 8 to 10 per cent of glucose. This infusion ensures that during the critical first twenty-four hours the heart muscle is not placed at a disadvantage because of an inadequate supply of circulating blood through its coronary arteries. Then compensatory action on the part of a heart *well supplied with nourishment* can come into action to combat the effect of the dilatation of the peripheral vessels caused by neurogenic influences ; that is, if the heart is assisted early so as to permit its compensatory action, the peripheral circulatory mechanism—the failure of which has caused circulatory failure or shock—may quickly recover.

Treatment of Shock and Collapse.—The treatment of post-operative shock and collapse in a patient whose circulatory system can

be regarded as healthy, is based on the following principles: (1) The body-heat must be kept at the correct temperature; (2) The blood-vessels must be filled to compensate for the plasma loss and for the decrease in the amount of circulating blood; (3) The peripheral vascular system must be toned up—that is, contraction of the peripheral vessels must be stimulated; (4) The breathing centres must be stimulated.

1. *Regulating the Body-heat.*—The patient's bodily heat is kept up by the use of short-wave diathermy, hot air, or other means. Care is taken that the patient is not overheated.

2. *Restoring the Loss of Circulating Blood.*—In post-operative shock, and even in shock following toxæmia, it is not the myocardium that is affected, but the peripheral vascular system, and the loss of circulating blood caused by this peripheral failure and resulting plasma loss is best restored by a transfusion of blood.

As a substitute for transfusion Krogh recommends salt solution with 6 per cent gum arabic—'gum solution'. Concentrated glucose solution (30 to 40 per cent) is perhaps the next best. Gum solution and strong glucose solution should not be administered in large amounts, for a plethora can result.

Ordinary normal saline solution remains a relatively short time in the circulatory system, and is toxic to the desanguinated heart in shocked subjects; but these drawbacks can in large measure be overcome by employing a continuous-drip infusion of an 8 to 10 per cent glucose solution in a saline (Tyrode's or Ringer's) which is of approximately the same chemical composition as that of the plasma, and which experiment has shown to be non-toxic to the anæmic heart.

The amount of solution which may be given varies according to the condition of the circulation, and may be as much as 2 to 4 litres in a day; the best guide is the amount of urine excreted by the patient.

One of the most important requisites in the treatment of shock by infusions of dextrose or gum and saline solution is that they should be on hand without delay for all emergencies; that is, they ought to be so prepared and kept in special ready-to-use containers that sterility is maintained. These ready-to-use solutions are of special value not only on account of their reliability and absence of reactions, but also because they can be used while waiting for the preparations for a transfusion. Thanks to an enterprising company*

* Drug Houses of Australia Ltd.

the following solutions can be kept in stock ready to use: 5 per cent dextrose in distilled water; gum acacia in normal saline; 5 per cent dextrose in Hartmann's solution; 5 per cent dextrose in Ringer's solution; 10 per cent dextrose in Ringer's solution. They are stored in 1000-mm. vacuum-sealed flasks, which have only to be

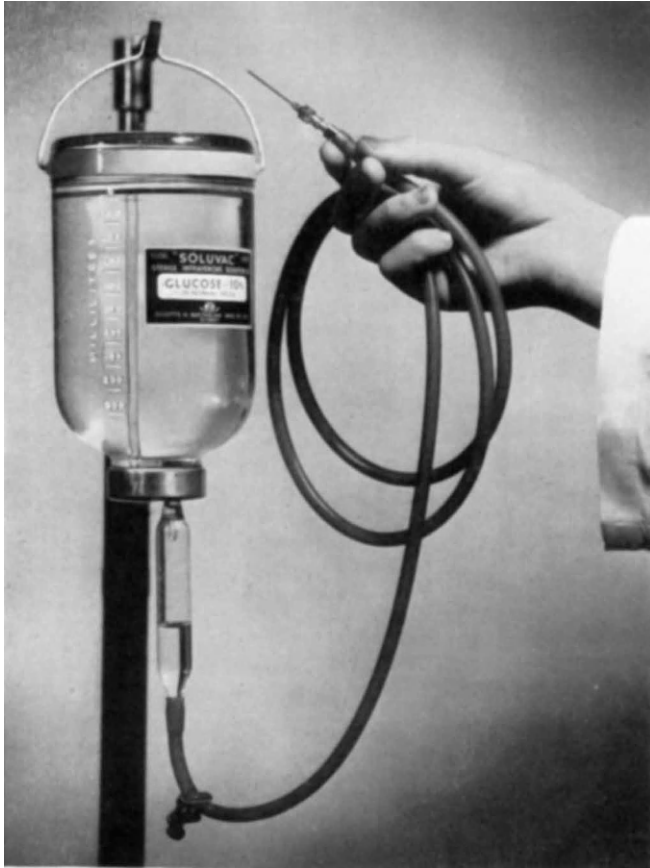

Fig. 585.—The Soluvac container for intravenous solutions ready for use.

inverted and connected to a drip apparatus. *Fig. 585* shows the container ready to be connected to the vein.

Transfusion of blood: As has been stated, of all remedies for shock blood transfusion is the best. In severe cases it may be necessary to give a massive transfusion—two pints or more—which of course may have to be collected from two or three donors. Special precautions are necessary in regard to transfusions in these very bad

cases. There must not be the slightest incompatibility of the donor's blood, and there must be no reaction following the transfusion. At the beginning the transfusion must be given very slowly, in order to allow the body time to adapt itself to the influx of extraneous blood; that is, advantage must be taken of that natural faculty of quick protection which the body possesses.

The donor's blood should be cross-tested against the recipient's, for in these very weak patients the slightest incompatibility may turn the scale against the patient; it is not enough to rely on blood-grouping.

In such debilitated cases a transfusion of blood should be preceded by a saline infusion which is chemically identical with the blood and contains its buffer salts in the proper percentage. The ordinary saline solutions are often toxic to the anæmic heart (Weichardt⁴). The chemical composition of such a solution should be as follows:—

NaCl	8.00 g.	NaH ₂ PO ₄	0.05 g.
CaCl ₂	0.20 g.	NaHCO ₃	1.00 g.
KCl	0.20 g.	H ₂ O	1000 c.c.
MgCl ₂	0.10 g.		

Unfortunately, when this solution is sterilized by heating, a precipitate occurs. It must therefore be sterilized by passing it through a special filter.

The description of a simple method of blood transfusion is appended at the end of this chapter (*see p. 771*).

3. *Toning up the Peripheral Vascular System.*—In shock, however induced, as has been pointed out, it is not the heart muscle which is poisoned, as it is in diphtheria, but the peripheral vascular system. Therefore, in attempting to combat the condition efforts should be made to restore a peripheral vascular efficiency by toning up the arteries, which in turn should ensure that an adequate supply of blood, and therefore of oxygen, will again be delivered to the right heart. Another result of toning up the peripheral vascular system is that the blood-depots—the liver, spleen, etc.—empty, and thus increase the amount of circulating blood.

Adrenaline has been used to tone up the peripheral vessels, but its action has been found to be too evanescent.

Recently, however, synthetic preparations under the names of *sympatol* and *veritol* have been produced. It is claimed that the action of these synthetic preparations is more prolonged than that of ordinary commercial adrenaline, and in addition that *veritol* can be given in larger doses—2 to 4 c.c. It has been shown that in patients

with a peripheral vascular insufficiency, after adequate injections of these synthetic preparations, there is a considerable increase in venous pressure, an emptying of the blood-depots, and an increase of sometimes 50 per cent in the circulating blood. (Oberdisse.⁵)

I have found that continuous-drip intravenous veritol dextrose solution is most efficient in treatment of shock and collapse. From 2 to 4 litres a day of a 5 per cent pure dextrose solution can be given, with the addition of veritol according to the state of the circulation. Twenty drops of this dextrose solution per minute should be given, or more as the condition demands.

The various cardiac remedies can act on the heart only if it is adequately supplied with oxygen. Veritol dextrose solution acts as a satisfactory nourishment for the myocardium, and to some extent can make up for an insufficient supply of oxygen; and it thus enables digitalis or cardiazol to act on the heart muscle even when it is placed at a physiological disadvantage on account of a deficient supply of oxygen.

4. *Stimulating the Breathing Centres.*—Active stimulation of the breathing centres hastens the circulation of the blood, and is therefore important in the treatment of shock. Veritol glucose infusions favourably influence the centres. After the inhalation of carbon dioxide, Brednow⁶ found an increase in the amount of the circulating blood and an expression of stored blood from the blood-depots, and Frimann-Dahl⁷ demonstrated an increase in the rate of the venous stream in the saphenous vein.

The percentage or the amount of CO₂ inhaled should be large enough to produce hyperpnœa.

Carbon dioxide cannot act on a paralysed respiratory centre, such as may accidentally be induced by the administration of evipan and similar intravenous narcotics, or after a badly given general anæsthetic. In cases of this kind it has been recommended that injections of caffeine, coramine, or lobeline should be given. Such treatment is designed to revive an exhausted respiratory centre. When the breathing centre is severely depressed, lobeline should be added to the intravenous sympatol dextrose solution. Used in this way it seems to be more efficacious than if used alone.

2. CASES WITH A CRIPPLED CIRCULATORY MECHANISM

So far we have been concerned with the disturbance of the circulation after operation in a patient who is presumed to have a healthy circulatory system. Shock, however, may occur in a patient whose circulatory mechanism is inadequate *ab initio*.

A study of the literature reveals that between 10 and 15 per cent of post-operative deaths are caused by a circulatory disturbance for which a pre-existing lesion of the heart is mainly responsible. The anæsthetic and the strain of the operation bring to light the weakness in a crippled heart, a weakness which in most cases has been clinically concealed. Even severe heart lesions may not be recognizable by the usual clinical examination. Foged and Torben Geill⁸ studied a series of 428 patients in whom a serious surgical operation was indicated. Of these, 351 were cases in which the heart had been carefully examined clinically in the cardiac clinic and nothing abnormal had been found. In 253 of these cases, electrocardiography and radiography upheld the clinical findings that no heart lesion was present. In the remaining 98, electrocardiography or radiography or both gave an abnormal finding. In the first group the post-operative mortality from heart weakness was 1.1 per cent; in the second group the mortality was 11.8 per cent. Coronary sclerosis and myocardial degeneration were the cardiac lesions indicating a bad operative prognosis.

Every patient, especially if old or fat, who is about to undergo serious abdominal operation, should be cardiographically and radiographically examined. Where examinations show that he has a heart weakness, and where this heart weakness is a coronary sclerosis or a myocardial degeneration, luxurious operations, such as those for gastric and duodenal ulcer, gall-stones, hernias, and the like—operations which are not urgent—should not be performed.

Ewig⁹ has drawn attention to early and almost unrecognizable stages of heart failure which are an important factor in so-called post-operative shock.

A post-operative circulatory disturbance may really be a combination of shock with a certain amount of cardiac failure resulting from a crippled heart, which was apparently normal when not subjected to any special strain.

The diagnosis of how great is the part that peripheral vascular failure and cardiac failure respectively play in a post-operative circulatory disturbance is important, for the principles of treating the cardiac-failure component are diametrically opposed to those underlying the treatment of the peripheral vessel failure which is responsible for true shock.

A crippled heart is present in patients with a mechanically defective but compensated heart. It becomes manifest as a consequence of the strain of the operation in aged patients with apparently normal hearts who have a poor circulatory reserve, for adequate

circulatory reserve is a quality of youth. It is also seen in patients who have been swept by severe 'storms' of toxic or infective disease; in those who are obese and have led sedentary lives; and in those who suffer from arteriosclerosis or from a metabolic or any general disease.

The first manifestation of heart failure is an increase in the action of the heart. The blood-pressure may not be altered; it may even remain relatively high. Cyanosis and dyspnoea may not be present, nor may any symptoms of heart weakness be obvious.

According to Ewig, early manifestations of heart failure are: (1) *Increase in the venous pressure*, which is shown by (a) an increase in the size of the veins in the arms and the neck, and (b) by an enlargement of the liver. (2) *Urinary changes*: (a) urobilinogen appears in the urine—a sign of insufficient circulation in the liver; (b) albumin is found in the urine, the specific gravity of which may increase; (c) the amount of urine may be small during the day, but may increase during the night. At this stage an examination of the heart will show little or nothing. Perhaps it may be noticed that the patient, when talking, cannot utter long sentences with a single breath.

Diagnosis between Peripheral and Cardiac Failure.—As diagnosis in post-operative circulatory failure must primarily be concerned with the question whether there is a cardiac or a peripheral failure or both, it is instructive to compare the manifestations which are caused by peripheral vascular failure—shock or collapse—with those brought about by cardiac failure.

In shock and collapse the blood-pressure is low, the skin is moist, the venous pressure low; the arm and neck veins are collapsed; the liver is impalpable; there is no nocturia, no albumin or urobilinogen in the urine; the cheeks are sunken and the eyes deep-set; the lungs are empty of blood; the patients preserve a horizontal position; there is a decrease in the amount of circulating blood, and a great decrease in the systolic output—all manifestations exactly opposite to those found in heart failure.

In cardiac failure, the blood-pressure is usually not low, the venous pressure is high; the arm and neck veins are distended; the liver may be palpable; there is urobilinogen and albumin in the urine; the cheeks are not sunken as in shock nor the eyes so deep-set; the patients like to sit up; there is an increase in the amount of circulating blood, and not nearly so much decrease in the systolic output as in peripheral-vessel failure (shock).

It must, however, be understood that cardiac failure may in some cases be secondary to a vascular insufficiency, and may be the result

of an insufficient amount of blood offered to the heart by the peripheral circulation, the insufficient supply of blood to the coronary arteries causing a definite injury to the cardiac muscle.

Treatment of the Cardiac-failure Component of Acute Post-operative Circulatory Failure.—

Cardiac Stimulants.—In the hope of increasing the efficiency of the heart, cardiac stimulants may sometimes be given. Caffeine, cardiazol, coramine, digitalin, strophanthin, are drugs of this nature. Caffeine and coramine may be given intravenously if urgently required.

Mechanical Aids to the Circulation.—There are certain natural mechanical aids to maintaining the circulation which can with advantage be used to help one which is failing. These are: (1) abdominal pressure; (2) abdominal respiration; (3) peristalsis; (4) position of the patient. These aids to circulation are more or less lost after a severe operation, and the maintenance of an adequate circulation is thrown entirely on the heart and peripheral-vessel mechanism.

In an operation on the upper part of the abdomen, abdominal respiration is lost partly because of the pain of the wound, and partly because of the position of the wound, which causes reflex inhibition of diaphragmatic movement.

Normally peristalsis causes differences in pressure in the abdomen, which helps to provide a circulation in the abdominal organs. The pendulum movements of the intestines are also an important factor in keeping up a circulation in the splanchnic area. Absolute intestinal immobility is a big disability to an intestinal circulation.

Thus, in post-operative treatment, with a view to helping a cardiac circulatory weakness, the first object is to make the abdominal respiratory movement as deep as possible. An abdominal bandage or rubber corset should firmly encircle the upper part of the abdominal wall, but should not go so far over the ribs that it will interfere with thoracic breathing. A tight-fitting bandage gives the patient a sense of security, and encourages him to breathe freely and deeply. The patient should sit up in bed, and get out of the post-operative crumpled-up position as quickly as possible. Therefore he should be awakened as early as possible by an analeptic drug, such as cardiazol, for the longer he remains unconscious the greater the disablement of the circulation.

Treatment of Venous Congestion.—The venous congestion which follows cardiac insufficiency requires special measures. In cardiac failure combined with shock or obscured in a shock-like clinical picture, the large infusions often used in true shock would perhaps have a fatal result, for in the former condition there is an increase in

the amount of the circulating blood, while in the latter there is a decrease. Venous congestion occurs in those patients who are bordering on cardiac decompensation in their ordinary life, and in whom an increase in the amount of circulating blood is imminent. These patients feel well after the operation until the amount of blood in the quickened circulation is inadequate to maintain the oxygen transport. Sometimes in these cases we may be able to succour the circulation until the venous return mechanism, by the aid of its mechanical helps, again comes into action. A small dextrose infusion may tide the patient over the crisis. It may certainly increase the loading for the heart, but the dextrose in it acts at the same time as a cardiac stimulant. It also causes a slight increase in the blood-pressure, and this has a good effect on the circulation, especially the coronary circulation. Thus the contact between the heart and the periphery may be again partially restored, and the heart is given a chance to increase the venous return into the auricle. Digitalis therapy should then be carried out.

BLOOD TRANSFUSION

(See also p. 765)

Simple Method of Blood Transfusion, Using Whole and Uncitrated Blood.—A method of blood transfusion which uses whole and uncitrated blood, and which can be simply and quickly carried out, is of much value to the abdominal surgeon, who so often has to deal with considerable acute post-operative circulatory disturbances.

The methods of transfusion are legion, but they are all complicated; and they nearly always involve the use of citrate of potash and intricate apparatus if whole blood is used. The methods, too, are often a little slipshod, and are followed by a reaction which may turn the scale in the case of a very sick patient.

NEO-ATHROMBIT APPARATUS.—A technique was evolved whereby whole uncitrated blood could be simply transfused by using an apparatus made of amber. This material, however, proved too costly, and a transfusion apparatus has now been constructed out of an artificial substance which is reduced to the finest powder and then solidified under great pressure. In vessels made of this substance whole blood can be kept for a short time without thrombosis occurring. The substance is called 'neo-athrombit'.

The apparatus is shown in *Fig. 586*. It consists of: (a) A burette for holding the blood, connected on one side by rubber tubing and needle to the vein of the receiver, and on the other side by a screw-on airtight metal cap with a rubber attachment by which

air-pressure can be made in the burette in order to force the blood into the vein; (b) Two beakers, made of neo-athrombit; (c) Two cannulas, the outsides and insides of which are highly polished, for the donor's and receiver's blood. The high internal polish prevents clotting and blocking of the needles.

PRELIMINARY PRECAUTIONS.—The whole object of the method is to be able to give quickly a whole (uncitrated) blood transfusion to a very ill patient with an acute post-operative circulatory failure, without provoking any accompanying reaction which might turn the scale against him in his precarious condition.



Fig. 586.—Neo-athrombit apparatus for blood transfusion.

To this end there are three important precautions: (1) Careful preparation of the apparatus; (2) The blood-grouping should be carefully estimated and donor's and receiver's blood should be *cross-tested*; (3) The transfusion should be preceded by the *biological test*.

1. *Preparation of Apparatus*.—The apparatus is sterilized in pure *soda-free* distilled water by boiling for 10 to 15 minutes. It can also be sterilized in high-pressure steam, when

5 minutes suffices, but on no account must soda be used in the water, because it destroys the apparatus. After boiling, the beaker and burette must be allowed to cool for 20 to 30 minutes, because warm apparatus causes the blood to coagulate. They should be sterilized an hour before the transfusion. Any drops of water which stick to the burette must be dried with a sterile towel, because these also hasten the clotting of blood.

The rubber connexion is rinsed in a paraffin and ether solution composed of paraffin liq. 2 parts, ether 198 parts.

2. *Blood Grouping*.—This should be carried out by a pathologist. If one is not available, it can be carried out by the surgeon, who may use one of the dried test sera, hæmotest or sanguinotest.

3. *Biological Test*.—With a Record syringe, 10 c.c. of the donor's blood is injected into the recipient's veins and three minutes is

allowed to elapse. If a reaction sets in, indicated by redness of the face, restlessness, paleness, irritating cough, cyanosis, collapse, pains in the sacrum and kidney region, then the donor's blood is unsuitable, regardless of the result of the blood grouping, and another donor must be found.

Should, however, these signs not appear, and should some doubt still exist about the compatibility of the donor's blood, then a further test must be made. A further 50 c.c. of the donor's blood is injected and another ten minutes allowed to pass. If no reaction occurs or if no evidence of hæmoglobinuria is to be seen, then this is absolute proof of the compatibility of the blood, and the whole transfusion may be started.

PROCEDURE.—During the time of waiting, in order that clotting may not take place in the needle, a little saline solution will have been slowly injected.

The donor's vein is now punctured with a needle (the lumen of which is polished), and the blood is allowed to flow into one of the beakers. This blood is at once emptied into the burette, the cap replaced on it, and a slight air-pressure made to drive the blood into the vein of the receiver.

Meanwhile the donor's blood is being collected into the second beaker, which in turn is emptied into the container, and so on, until sufficient blood is given. The transfusion should be preceded and followed by a small quantity of Ringer's solution.

This method is simple, quick, and does not give rise to any reaction.

REFERENCES

- ¹ REHN, E., *Arch. f. klin. Chir.*, 1933, No. 177, 360.
- ² FREUND, *Arch. f. exper. Pathol. u. Pharmakol.*, 1920, No. 88, 39; *Zentralb. f. Chir.*, 1935, No. 48, 2867.
- ³ KONIG, W., *Arch. f. klin. Chir.*, 1932, No. 171, 447; *Chirurg*, 1934, **6**, Jan. 15, 43; *Zentralb. f. Chir.*, 1935, No. 48, Nov. 30, 2868.
- ⁴ WEICHARDT, W., "Sterile Infusionsflüssigkeit", *Chirurg*, 1932, **4**, Nov. 1, 839.
- ⁵ OBERDISSE, K., *Verhandl. d. deut. Gesellsch. f. inn. Med.*, 1934, 262-5; *Zentralb. f. Chir.*, 1935, No. 48, 2872.
- ⁶ BREDNOW, *Zeits. f. d. g. exper. Med.*, **73**, 557 (1830); *Zentralb. f. Chir.*, 1932, No. 48, 2872.
- ⁷ FRIMANN-DAHL, *Postoperative Röntgenuntersuchungen*, 1935, Oslo; *Zentralb. f. Chir.*, 1935, No. 48, 2872.
- ⁸ FOGED, JENS, and GEILL, TORBEN, "Die prognostische Bedeutung von präoperativer Elektrokardiographie und Röntgenuntersuchung des Herzens" (verlaufige Untersuchungen), *Acta chir. Scand.*, 1936, **79**, 35-80.
- ⁹ EWIG, W., and KLOTZ, L., "Studien über den postoperativen Shock" *Deut. Zeits. f. Chir.*, 1932, **235**, 681-710.

CHAPTER LXVIII
 COMPLICATIONS OF THE EARLY
 POST-OPERATIVE PERIOD

(continued)

II. EXCESSIVE PAIN AND VOMITING

EXCESSIVE AND PERSISTENT POST-OPERATIVE PAIN

EXCESSIVE pain for forty-eight hours or longer after an operation indicates some complication; it is a warning sign, and indicates that the post-operative course may not be normal. Recurrence of post-operative pain after it has subsided for a short period has much the same significance.

In such circumstances the wound should be inspected. If it is unduly swollen, tense, and tender, there may be either: (1) A deeply situated hæmatoma (the result of inaccurate hæmostasis); (2) The beginning of an infection; or (3) An excessive inflammatory reaction resulting from undue operative trauma.

If no cause for the excessive pain can be found in the wound, it is necessary to be on the watch for some intra-abdominal trouble deep in the operation area, such as some local intraperitoneal bleeding, or an intestinal kink following an intestinal adhesion to the abdominal wound. Such a lesion will soon become manifest by its interference with intestinal function; that is, by the onset of constipation and a beginning distension.

Treatment.—In the treatment of bad post-operative pain, reliance must be placed on the exhibition of morphia. Great relief is also obtained from the continual application of heat—given as radiant heat or as an electric hot bag. The heat helps to restore the pendulum movements of the bowel, and therefore to lessen distension and discomfort (*see* p. 782). It also helps resolution of any areas of inflammation which may be causing a moderate grade of small-intestinal obstruction.

EXCESSIVE AND CONTINUOUS VOMITING

After any operation there is more or less vomiting; but if it is excessive and continues for longer than is usual, it must be

tentatively regarded as pathological, and an attempt must be made to find its cause. Is it the result of an anæsthetic that has been badly administered; or the after-effects of an anæsthetic in a patient with a highly sensitive nervous system? Is it caused by a pre-existing disease, such for example as a renal or hepatic insufficiency—disease which has been latent, but which has been brought to light by the toxic effect of the anæsthetic and the stress of the operation? Or is this persistent vomiting an early sign of a serious post-operative complication, such as an intestinal kink or twist caused by an early lymph adhesion? That it may be due to gastric neurosis in a neurasthenic patient should be the last thought of the surgeon; for too often this diagnosis satisfies the conscience of the surgeon until he discovers, too late, that the persistent vomiting had an organic cause—often a high obstruction of the intestine—which should have been sought for and found earlier in the post-operative period.

General Treatment of Excessive Vomiting.—The general treatment of vomiting in the early post-operative period should be carried out on the definite lines described below.

Prophylaxis.—The following preventive measures will be found to reduce the incidence of post-operative vomiting materially:—

1. Medical examination of the patient before the operation, in order to recognize cases of hepatic and renal insufficiency; and appropriate pre-operative preparation in such cases, including the avoidance of morphia as a pre-narcotic.

2. Choice of the least innocuous form of anæsthesia, such as gas or local anæsthesia.

3. Limitation of the amount of general anæsthetic to be used—an unnecessary amount of anæsthetic is often administered.

4. Insertion of a tube in the rectum for the first forty-eight hours after the operation. The intestines are paralysed from the effects of the operation and the anæsthetic, but the sphincter is uninjured. The paralysed intestines are incapable of overcoming the resistance of the normal sphincter and thereby discharging gas. The insertion of the tube puts the sphincter out of action, gas is discharged, and this naturally lessens distension and the tendency to vomit.

5. An embargo on the use of drastic purgatives. Recovering intestinal function is embarrassed by the administration of purges soon after an operation.

6. The intelligent post-operative use of morphia.

Use of a Rubber Corset.—In order to lessen the pain caused by vomiting, the upper part of the abdomen should be encircled with

a corset made from a split inner tube of a motor tyre. (See Fig. 441, p. 547.)

Intravenous Medication.—As the patient rapidly loses fluid, chlorides, and nourishment, and as a result of this, suffers from dehydration, alkalosis, and nutritional deficiency, he should as early as possible be given intravenous injections of glucose and salt solution.

Treatment of Vomiting due to Hepatic Insufficiency.—In patients with hepatic insufficiency, an operation on the gall-bladder or the stomach may precipitate a failure of liver function. With the vomiting associated with hepatic insufficiency there is often distension, the result of excretion of poisonous autogenous products by the stomach and bowel.

Vomiting on a basis of hepatic insufficiency should be treated by small doses of insulin combined with oral or intravenous administration of glucose.

Management of the more Serious Forms of Post-operative Vomiting.—After a general anaesthesia, as a rule, the patient vomits only gastric contents. If the vomiting becomes excessive, he begins to vomit duodenal contents—bile. If it continues, the vomitus usually becomes dark brown—an indication that the contents of the upper part of the jejunum are being vomited. In such circumstances the surgeon should feel anxious, for this is a serious type of vomiting, and is usually the result of some post-operative complication; it is not just a continuation of the post-anaesthetic vomiting.

In these circumstances for purposes of treatment the surgeon will eliminate or have eliminated the possibility that the vomiting is the result of pre-existing renal, hepatic, or cardiac disease. He will then have cleared the ground for a diagnosis of either: (1) Acute gastro-duodenal ileus; (2) The beginning of a paralytic ileus; or (3) Some mechanical obstructive intestinal condition.

Vomiting caused by Acute Gastroduodenal Ileus.—In persistent vomiting, gastroduodenal ileus should always be the first condition to be excluded, for the possibility of its occurrence is too often forgotten. If the vomiting is frequent and persistent, the vomit copious and consisting mainly of bile, and there is a distension of the upper part of the abdomen, gastroduodenal ileus should be suspected. If, in addition to these symptoms, the stomach tube draws off a large quantity of bile-stained gastric contents, and dissipates the abdominal distension, then a definite diagnosis of gastroduodenal ileus can be made.

The cause of this condition is not known definitely. It has been attributed to the following: (a) Overaction of the sympathetic

innervation of the stomach and duodenum, which gives rise to dilatation of the stomach and duodenum; (b) Toxic action on the plexus of nerve-cells in the wall of the stomach and duodenum, the result of excretion of toxins from some metabolic disturbance following the operation or of the excretion of the administered ether or chloroform by the gastric and duodenal mucous membranes; (c) A pull on the superior mesenteric artery where it passes over the terminal part of the duodenum, caused by the dragging of distended small intestines prolapsing into the pelvis—an arterial pull which is supposed to compress the duodenum against the spine and thus cause a partial duodenal obstruction.

Whatever the cause may be, the treatment should never be operative. The patient should be placed on his face with the lower end of the bed elevated, and the stomach should be washed out repeatedly until it recovers its tone.

The practical points are as follows :—

1. That the duodenal ileus is not, as a rule, discovered until the patient is in a parlous state; therefore the surgeon should always be on the look-out for it.

2. That the patient, as a result of the continual vomiting, very quickly gets into a serious condition from dehydration, from the alkalosis which follows on persistent vomiting, and from the loss of nutriment which he should be taking by the mouth, because rectal therapy is employed to combat these conditions in ignorance of the fact that little absorption takes place from the rectum.

3. That the dehydration, the alkalosis, and the denutrition produced by the vomiting should be treated as *early* as possible by the continuous intravenous administration of 1 per cent saline and 5 per cent glucose.

Management of Vomiting after Gastric Operations.—

Gastric Ileus.—Copious vomiting sometimes follows a partial gastrectomy or other gastric operation. The contents consist of almost pure bile. In such cases, as a result of the extensive operation a gastric ileus may have developed. In these cases an Einhorn tube should be introduced through the nose into the stomach, left in position, and the gastric contents aspirated. As the tone of the stomach improves, advantage can be taken of the tube to introduce nutriment in small quantities, according to the degree of recovery of gastric tone.

Gastric Ileus the Result of Perigastric Inflammation.—A low-grade inflammation or a seropurulent effusion which may develop around the gastric stump after a partial gastrectomy may cause a gastric ileus.

In such a case, as an indwelling Einhorn tube will show, the stomach at first partially empties its contents into the jejunum and then slowly becomes completely paralysed. The evidence of inflammation may not be great : there may be little fever and no tenderness. Here is an example :—

After a partial gastrectomy, a patient started to vomit small quantities of bile-stained contents on the third day. An indwelling Einhorn showed that each successive day less and less contents passed into the jejunum. His temperature ranged from 99° to 100°. He had no tenderness over his epigastrium. At a second operation a seropurulent effusion was found to have become loculated around the stomach. The gastric ileus which the patient had was caused by a perigastric inflammation and needed prompt surgical treatment.

CHAPTER LXIX

COMPLICATIONS OF THE EARLY
POST-OPERATIVE PERIOD*(continued)*III. POST-OPERATIVE DISTENSION: EARLY STAGES OF
PARALYTIC ILEUS AND INTESTINAL OBSTRUCTION

POST-OPERATIVE DISTENSION

THE treatment of post-operative distension involves at the same time the treatment of what may be the beginning of a paralytic ileus or of a post-operative intestinal obstruction. While the diagnosis between these conditions is under review, the treatment of the distension will, of course, be proceeded with.

Causation.—In regard to the early stages of post-operative distension there are two schools of thought. There are those who think that the distension is a partial post-operative intestinal paralysis, and that it is produced by an accumulation of intestinal contents and gas; and there are others who believe that the distension is primarily caused by cessation of the intestinal portal circulation as a result of inhibition of the intestinal movements (principally the pendulum movements), and that the distension is mainly caused by transudation of gas (CO₂) from the static blood into the intestinal lumen.

The assumption that post-operative distension is brought about by a post-operative intestinal paralysis has never been proved. Indeed, there are observations to the contrary. In persistent post-operative distension induced in animals the vasomotor centre has never been found to be exhausted; and in late stages of peritonitis in man a good deal of peristaltic movement still remains.

It has been pointed out by Sjöqvist¹ that there is much evidence to suggest that post-operative distension can be explained in another way. He has shown that in post-operative distension the operation causes a reflex inhibition of all intestinal movements; and of these, the loss of the pendulum movements lessens the efficiency of the circulation of the intestinal wall. These pendulum movements have a peculiar function. They go on day and night, even in the empty intestine. It would seem as if they were comparable to heart-beats,

and were responsible for much of the strength of the intestinal circulation.

Usadel² has shown that the strength of the blood-stream at the portal vein where it enters the liver can be increased if the pendulum movements are increased by rinsing the intestines with hot water. He therefore thinks that the pendulum movements are concerned with the driving strength of the intestinal portal circulation, because they occur when the intestine is empty.

Sjöqvist's conception of post-operative distension, then, is that after an operation the pendulum movements are inhibited, and the strength of the portal circulation in the intestinal wall is thereby practically lost. As a consequence of the weak circulation, he thinks that CO₂ accumulates in the intestinal tissue and transudes into the lumen of the bowel instead of passing into the blood and being excreted by the lung, as it would in a normal portal circulation. Thus he thinks that a disturbance in the circulation of the intestinal tissue disturbs the normal balance of gas excretion, just as such a disturbance in any other tissue would interfere with its gas exchange.

It has been proved that in post-operative intestinal distension the greater part of the gases in the bowel is CO₂. It has also been shown that if excess of CO₂ is pumped into isolated loops of bowel, the CO₂ is rapidly resorbed into the blood and excreted by the lung if the portal circulation is normal; and also that excess of CO₂ is not absorbed in peritonic loops where the portal circulation is at fault.

Post-operative distension, then, according to Sjöqvist's conception, is due to an inhibition of intestinal movements resulting from the operation, followed by a transudation of CO₂ gas into the bowel, which causes distension, and it gives rise to a vicious circle—the distended bowel placing the muscular wall of the intestine at a disability so that it cannot exert its strength to transport intestinal contents.

On the assumption that post-operative distension is primarily caused by intestinal paresis, the principles underlying its treatment have aimed at the removal of gas and bowel contents. The treatment has therefore comprised the use of more or less drastic post-operative purgatives; the use of stimulants like pituitrin, eserine, and prostigmine for the intestinal muscle; and the use of high bowel wash-outs and enemas—all of which might be called 'active' treatment. These methods of treatment have not been satisfactory and have sometimes caused rather than relieved post-operative distension. But on Sjöqvist's hypothesis that the intestinal circulation is primarily at fault, the principles on which treatment should be based

are exactly opposite to those underlying 'active' treatment: no aperients are given before or after the operation, and morphia is freely used till the distension begins to go down and the bowel to discharge gas through the anus. Clinically there is much evidence in favour of this more conservative method of treatment.

Prophylaxis.—The important principle in the treatment of post-operative distension is to prevent it. It is a good working rule that the condition is largely preventable and may be caused by the unskillfulness of the surgeon. He will therefore try to lessen distension by avoiding too much handling and exposure of the intestines; by making an exact toilet of the peritoneum; by being scrupulous in regard to hæmostasis; by taking great care to suture accurately; by taking antiseptic precautions in repairing intestinal and gastric wounds; by screening the small intestine from the wound by means of the omentum; by not leaving air in the peritoneal cavity; and by avoiding drastic pre-operative purgative treatment and too vigorous post-operative treatment.

Treatment.—

Routine Post-operative Treatment.—A flatus tube should be kept in the rectum for the first forty-eight hours after the operation. Aperients and enemas should not be given until the circulation in the bowel wall has returned to normal—that is, until it regains its function—for they embarrass the circulation of the bowel, thereby increasing the amount of gas in it and delaying the return of function. Until the bowel starts to discharge gas naturally, or with a small helping enema, no aperient should be given.

In the treatment of distension two important aids in the restoration of bowel function are: (1) The free administration of morphia; and (2) The application of radiant or other form of heat to the abdomen.

The Use of Morphia.—As morphia is generally regarded as an intestinal paralyant, it is relevant here to discuss its mode of action in post-operative treatment.

Sjöqvist has shown that, in man, morphia stimulates the peristaltic movements, and of these particularly the pendulum movement. He has shown that the action of morphia is different from that of opium, and that this latter drug, probably because of the papaverine that it contains, stills the movements of the intestine. In man, injections of morphia cause a cramp-like contraction of the pyloric and pre-pyloric parts of the stomach, and in the normal bowel increased intestinal movements. He found that intestinal movements were increased when he treated with morphia preparations made of strips

of intestinal muscle taken from resection specimens. According to him, the usual conception that the therapeutic action of morphia paralyzes intestinal movement is erroneous.

Observations made by Plant and Miller³ on patients in whom the intestinal movements could be accurately observed through an extremely thin-walled hernia, showed that the administration of morphia caused an increase of intestinal movements.

Thus the administration of morphia is a rational form of post-operative treatment and minimizes distension; for it stimulates both the pendulum and the peristaltic movements, and therefore hastens the restoration of a normal circulation to the bowel wall, the result of which is reabsorption of CO₂ from the intestinal lumen into the blood and excretion of it by the lung. Morphia, then, in doses of $\frac{1}{6}$ gr., should be freely given for the first three or four days.

The Use of Heat.—Another method of stimulating the pendulum movement of the bowel and therefore of restoring the intestinal circulation of the bowel, is the free application of heat to the abdomen by hot air or short-wave diathermy.

Thus, by avoiding the operative use of aperients, by care in regard to anæsthesia, by gentle and skilful operating, by the free administration of morphia and the use of heat, by avoiding the early use of enemas or high wash-outs, post-operative distension after abdominal operations may be minimized.

Treatment of Post-operative Distension Caused by a Focus of Infection.—It is not uncommon for a post-operative distension to be caused by a focus of infection, such as an area of local adhesive peritonitis or an abscess. The effect of a focus of infection is to paralyse by its toxic action the muscle wall of an adjoining segment of small intestine. Through this parietic segment the intestinal contents do not readily pass. Thus a mechanical intestinal obstruction occurs above this point, with the result that the intestinal wall becomes dilated as in other forms of intestinal obstruction, but shows no signs of peritonitis.

The first principle in the management of such a condition is to find the focus of infection and treat it. Tender spots and local rigidity may indicate its position. Frequently the area is deep amongst the intestines and gives very little indication of its presence. To seek it operatively would be dangerous, because such a procedure would diffuse the infection and cause peritonitis.

In cases where an infective focus is suspected but cannot be located and operatively treated, radiant heat applied to the abdomen

may help the area to resolve and thus permit the paralysed segment to resume its function.

Where an infective focus produces a definite mechanical obstruction, it may be necessary to perform an enterostomy as described on p. 795.

Should the routine treatment of post-operative distension fail to bring relief, then the problem will resolve itself into the treatment of an intractable post-operative distension which may be the early stage of a paralytic ileus or the beginning of a post-operative intestinal obstruction.

EARLY STAGES OF PARALYTIC ILEUS OR OF INTESTINAL OBSTRUCTION

Management of a Case of Post-operative Distension which may Develop into Paralytic Ileus or Intestinal Obstruction.—At this stage—about the fifth or sixth day—the patient should be treated on the following principles: (a) Counteraction of the effects

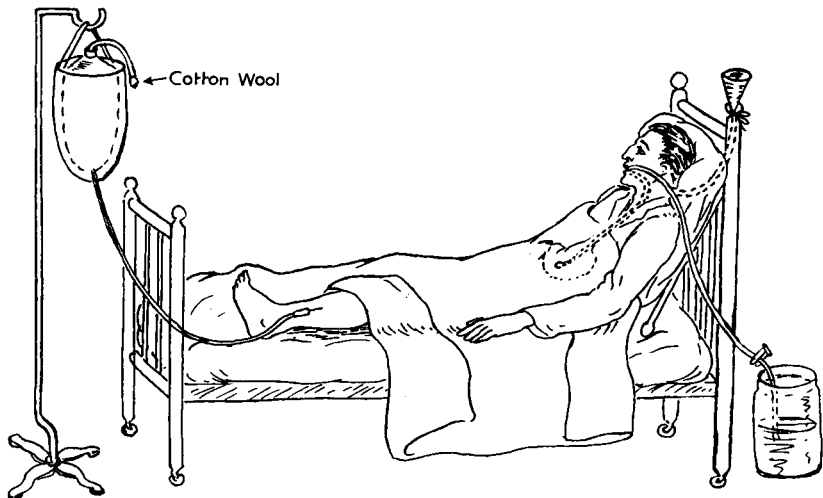


Fig. 587.—Einhorn tube in situ.

of incessant and copious vomiting; (b) Maintenance of the fluid balance in the body; (c) Replacement of the loss of chlorides in order to prevent alkalosis; and (d) Maintenance of the patient's nutrition.

Counteraction of the Effects of Vomiting.—Relief from continual vomiting is obtained by leaving an Einhorn tube in situ in the stomach (Fig. 587). The gastric contents can then be aspirated and

measured, and fluid and nourishment introduced into the stomach as the organ is able to deal with it.

Maintenance of Nutrition and of the Fluid and Chloride Balance.—In a case of paralytic ileus, as a rule it is the alkalosis, the dehydration, and the denutrition from which the patient dies. If these conditions can be combated and the patient's strength maintained until the bowel begins to recover its function, which is usually on about the eighth, ninth, or tenth day, then the patient generally gets better.

In the case of the incipient stage of a post-operative intestinal obstruction, the same principles of treatment hold until a diagnosis is definitely made and an operation performed.

To maintain the fluid balance of the body, the fluid loss from vomiting, from aspiration of gastric contents, and as urine, must be measured and replaced by intravenous continuous-drip saline and glucose—the salt to replace the chlorides, and the glucose for nourishment.

REFERENCES

- ¹ Sjöqvist, O., "Über die Verwendung von Morphin nach Bauchoperationen: Eine pathologisch-physiologische und klinische Studie", *Acta chir. Scand.*, 1936, **78**, 33-70.
- ² Usadel, *Arch. f. Chir.*, 1926, **142**, 423 (*Acta chir. Scand.*, 1939, **78**, 33-70).
- ³ Plant and Miller, *Jour. Pharm. and Exper. Therap.*, 1926, **27**, 361 (*Acta chir. Scand.*, 1936, **78**, 33-70).

CHAPTER LXX
**COMPLICATIONS OF THE EARLY
 POST-OPERATIVE PERIOD**

(continued)

IV. PULMONARY COMPLICATIONS

OPERATIONS in the upper part of the abdominal cavity are particularly prone to develop pulmonary complications. There are many reasons for this: the reflex inhibition of the diaphragmatic movement by a wound in its vicinity; the interference with the function of respiration by the painfulness of the highly situated wound; the situation of the lungs in the same nerve-field—the vagal field—as the organs in the upper part of the abdomen; the rather intimate connexion of the lymphatics in the upper part of the abdominal cavity with those of the lower part of the thoracic cavity; and finally, in addition to these, the chemical effect of an inhaled anæsthetic on the lung as well as the aspiration of any gastric contents which may be vomited during the course of anæsthesia.

These post-operative complications are usually known as post-operative pulmonary inflammation. Sauerbruch¹ points out that in the light of modern clinical experience and from a consideration of experimental results it is necessary that we should alter our conceptions in regard to their nature and cause. All pulmonary complications, he observes, cannot be regarded as the result of a local pulmonary injury, but must be considered rather as a local symptom of a general disease—general bodily disease or cardiac affection.

VARIETIES

The following post-operative pulmonary complications may be briefly mentioned:—

1. Aspiration Pneumonia.—The entrance of blood, stomach or intestinal contents, or foreign bodies into the lung gives rise to this condition, which usually exhibits all the symptoms and signs of a low-grade bronchopneumonia.

2. Infarct Pneumonia.—Infarct pneumonia arises as a small pulmonary embolism which has had its origin in some mildly septic

thrombosis arising in or from the operation area. Around the embolism, which is more or less infected, a spreading thrombosis develops, and finally the pleura becomes involved and a pleuritis forms. The patient complains of sudden pain in the chest which has come on suddenly, and which is made worse by respiration. He has a slight fever. After a few days he spits up a prune-coloured expectoration. As a rule the condition, if not extensive, clears up within a week or two. If the infarct is extensive and becomes infected, a lung abscess—a very serious pulmonary complication—may develop; even a septic empyema may form, and a fatal result ensue.

3. Anæsthesia Pneumonia.—The condition occurs as the result of a chemical irritation of the mucous membrane. It begins usually with a capillary bronchitis. Its frequency and significance are, however, overestimated. True anæsthesia pneumonia occurs only when there is increased sensitiveness of the patient to ether, or in consequence of its unskilful administration.

4. 'Cold' Pneumonia.—This originates from congestive hyperæmia of the lung, which always sets in after cooling of the body. Further, all forms of primary or secondary heart weakness predispose to the occurrence of a pneumonia through reduction of the strength of the circulation, thereby leading to a stasis of the pulmonary circulation.

5. Massive Lung Collapse.—Massive collapse is a special form of post-operative disturbance. It originates through the transfer to a bronchus of a mucous lump or of a blood-clot which interferes with the gas exchange. The air in that part of the lung served by the occluded bronchus becomes absorbed, and circumscribed atelectasis follows. The partial switching out of the lung increases the negative pressure on one side, and for this reason causes a raising of the diaphragm and a displacement of the heart. The movement of the chest wall is stilled and the chest is retracted. Patients generally develop fever and complain of compression and pain in the region of the xiphisternum. The occluded region is dull, and tubular breathing is heard over the affected area. The thickening of the tissue in this region shows radiographically a circumscribed massive shadow. Confusion with pneumonia is quite possible. If the patient coughs up the occluding plug, which sometimes happens, the stagnant secretion is released, the fever disappears, and the respiratory murmur becomes normal in a short time. On the contrary, if the bronchial obstruction persists, a severe pneumonia may develop.

6. Croupous Pneumonia.—A true croupous or 'grippe' pneumonia is only seen occasionally as a post-operative complication, but

it is much more frequent than is generally supposed, and occurs in connexion with operations carried out at the time of the occurrence of a general epidemic.

There is another group of post-operative pulmonary inflammations, following operations in the upper part of the abdomen, which occur as a consequence of disturbances of the motility of the lungs and of the insufficient ventilation of the lungs resulting from this loss of motility. Sauerbruch¹ has shown that after operations on the upper part of the abdomen the breathing is materially altered; the diaphragm assumes a high position; the thorax is in relaxation, that is, in an expiratory position; and the vital capacity of the lung is decreased. This condition of the chest is due to the pain of the wound in the upper part of the abdomen.

It is difficult to understand the significance of the high position of the diaphragm. It is partly a necessary accompaniment of the expiratory position of the thorax, perhaps also of the subdiaphragmatic increase in pressure which occurs when the abdomen is opened. At any rate, the immediate consequence of the switching out of the lower part of the chest, and the limitation of respiratory movement in its upper section, is that the ventilation of the lung is lessened; as a result the circulation of the lower lobe is considerably reduced. Thus the defective breathing and poor pulmonary circulation lay the foundations for the development of a pneumonia.

It is clear that one must blame the pain of the wound for this disturbance of the mechanism of the breathing. It is therefore obviously necessary, if one wishes to lessen the predisposition to a pneumonia in operations in the upper part of the abdomen, to try to make the wound less painful by making it high, strapping it, and by the use of radiant heat.

TREATMENT

Prophylaxis is most important. Patients should not be operated on during epidemics of influenza, or after long train journeys where respiratory infection is likely. They should be examined for any cardiac or pulmonary weakness, and if these conditions are found they should be given suitable pre-operative treatment, and an anæsthetic adapted to the condition should be chosen for them.

A marked congestion pneumonia needs, besides stimulation of the heart, an unloading of the circulation, such as blood-letting and remedies to lessen venous congestion. At all times good treatment depends on the principle of obtaining a rich expectoration. The

breathing should be deepened by relief of pain. Morphia in adequate doses is indispensable. Icoral, coramine, cardiazol, and caffeine are the best of the heart stimulants. In a chronically injured heart, strychnine, digitalis, and other cardiac remedies are indicated.

REFERENCE

- ¹ SAUERBRUCH, F., Official Report of the Meeting of the Berlin Surgical Society, December 10, 1932, *Zentralb. f. Chir.*, 1933, No. 16, April 22, 981.

CHAPTER LXXI
**COMPLICATIONS OF THE MIDDLE
 POST-OPERATIVE PERIOD**

DURING the *middle* post-operative period—beginning about the sixth or seventh day after operation—the complications may be :—

- I. Refractory post-operative distension.
- II. Paralytic ileus.
- III. Intestinal obstruction of a mechanical nature, the result of a kink or twist, or of a local focus of infection.

I. REFRACTORY POST-OPERATIVE DISTENSION

Post-operative distension, vomiting, and constipation may continue into the second week and may not yield to treatment. In this case it is more than likely that it is due to some serious post-operative complication.

The question then arises whether this distension is due to : (1) The early stages of a mechanical small-intestinal obstruction caused by (*a*) a twist, kink, or volvulus of a piece of small intestine, or (*b*) some intra-abdominal local infection which is causing paresis of a segment of small intestine in its vicinity ; or (2) The beginning of a true paralytic ileus.

i. The Possibility of Mechanical Obstruction.—It is at this stage of a post-operative distension that it is of great practical importance, to *eliminate the possibility of a mechanical obstruction*, or at least make an attempt to do so. For if it is the beginning of an intestinal obstruction, and if the patient's life is to be saved, he must be operated upon as early as possible, since operations in the middle stages of this type of obstruction are dangerous, and in the last stages are almost invariably fatal.

In the case of a mechanical obstruction it will nearly always be found that the convalescence has been unsatisfactory. The patient has had a *good deal of pain*, much more than should have been the case. There has been difficulty in getting the bowels opened. The post-operative rigidity of the abdominal wall has not receded. There are indefinitely situated tender spots over the abdominal wall. The patient has progressive constitutional signs—a rising temperature and

pulse-rate, and his general condition is not so good as it should be. In short, it will be obvious that there is some inflammatory or mechanical process going on in the abdomen which is the cause of the obstinate post-operative distension.

Should the surgeon decide that the obstruction is mechanical, he may still elect to temporize and try to relieve the obstruction by appropriate treatment. Such a decision may be wise, and such attempts are often well worth while, for many minor forms of post-operative mechanical obstruction are caused by a local *inflammatory focus* (see p. 782), which may either paralyse an adjoining small segment of bowel—thus causing mechanical obstruction—or produce by its plastic inflammation a temporary angle or kink. These inflammatory foci, given time, and appropriate treatment such as radiant heat, etc., may resolve and thus relieve or partially relieve an obstruction.

2. The Possibility of Paralytic Ileus.—If it is not possible for the surgeon to make a diagnosis of mechanical obstruction, the question arises as to whether the patient is suffering from a true paralytic ileus.

The clinical picture of the beginning of a paralytic ileus is very like that of the usual form of an obstinate post-operative distension: there is very little, if any, pain; there are no tender spots; vomiting comes on slowly; the patient is not very uncomfortable and his general condition is fairly good; he has no rise in temperature and only a very steady rise in pulse-rate.

Distinction of Paralytic Ileus from Mechanical Obstruction Caused by a Focus of Infection.—The clinical picture of paralytic ileus just described is sometimes exceedingly difficult to distinguish from the form of mechanical obstruction produced by a local area of low-grade inflammation paralysing a small section of the small intestine (see p. 782).

Such an inflammatory area may be deep in the abdomen, and may therefore not give rise to local signs, such as tenderness and rigidity, to indicate its presence. Although the obstruction it produces is a mechanical one, and the dilated intestine above the inflammatory area is free from inflammation, nevertheless the obstruction may come on so quietly that very little if any pain may be associated with the obstruction. Thus the clinical picture may be that of a painless distension without local symptoms—a clinical picture almost identical with that of a true paralytic ileus. I have not infrequently seen this type of post-operative distension—really a painless form of mechanical obstruction—develop after an operation

for appendicitis associated with local peritonitis. In this diagnostic dilemma, the presence or the absence of leucocytosis may help in distinguishing between the two conditions.

The distinction is *very important* because an enterostomy made early in the case of mechanical obstruction due to an inflammatory focus is the proper treatment; but an enterostomy in a paralytic ileus is only adding another operation to the one which produced the ileus, and is likely to cause the patient's death.

Use of the Miller-Abbott Tube.—It is in circumstances such as the above, and about this period of a refractory post-operative distension, that the Miller-Abbott^{1,2} tube finds its greatest value, being of use not only for paralytic ileus but for a possible mechanical obstruction.

Fig. 588 shows a photograph of the tube. It consists of about 10 ft. of small tubing marked to show the various levels, with a very small central tube. The outer tube is connected to an Einhorn bucket and is used for aspiration of the intestinal contents. The inner and finer tube is connected to a thin rubber balloon and is used to distend this balloon when the double tube reaches the duodenum.*




Fig. 588.—Miller-Abbott tube.

When practicable, the tube is passed in the fluoroscopic room, where it is possible to see when the tube has reached the duodenum. Where an X-ray outfit is not available, the tube is passed through the patient's nose and down into the stomach. The patient lies on the right side, so that the duodenal bucket will pass into the pylorus, and when this is in the duodenum (ascertained by recognizing contents drawn off as coming from the duodenum), the balloon is inflated with 30 c.c. of air, while constant suction is maintained on the large tube. "As the gas and fluid are sucked out of the gut, the intestinal walls contract, and, regaining their normal propulsive movement, they force the balloon ahead. The suction likewise collapses the

* The tube is made by the Lee Tyre and Rubber Co., Conshohocken, Pennsylvania, U.S.A.

intestine, loop by loop, as the tip of the tube advances until the obstruction is reached, by which time relief of distension and with it relief of pain have occurred."

In a normal individual, the tube will advance along the intestine at the rate of 1 cm. per minute or 2 ft. an hour. A length of 8 to 10 ft. of tubing is generally enough to reach from the pylorus to the cæcum. The tube should be used in conjunction with intravenous saline and glucose therapy.

In one case treated by Dr. John Devine—a case of paralytic ileus following an obstruction—the tube was passed down 8 ft. The distension was completely relieved and the tube was left in until the fourth day. The patient recovered. In other cases where he used it, operation was necessary for the incomplete obstruction, but the relief from the pain, distension, and vomiting was most valuable.

When the tube no longer functions, the balloon should be deflated and the tube may be drawn out with gentle traction. It takes 15 minutes to draw out 10 ft. of tubing.

II. PARALYTIC ILEUS

This condition occurs in various grades of severity. There may be very little reason for it; even the most severe type can occur after only an exploration of the abdomen when none of the abdominal organs has been handled. It does not occur after operations in the upper part of the abdomen as frequently as in the lower part; and in the former it rarely follows gastric operations, but is not uncommon after those on the gall-bladder.

Paralytic ileus can be caused in more than one way. I have seen it after operations on patients with hepatic insufficiency; after a post-operative retroperitoneal infection; after operations where the abdominal contents have scarcely been touched and where it must have been caused by an overaction of the sympathetic supply of the small intestine; and finally, I have seen it follow a trifling operation which was carried out under avertin combined with ether.

The following is a case-history of a patient in whom I feel paralytic ileus was caused by a disturbance of the sympathetic system which perhaps was already diseased:—

A woman, aged 40, suffered from indefinite abdominal symptoms, Her general health was bad. She was subject to attacks of vomiting. In the absence of any definite diagnosis it was decided that her abdomen should be explored. Nothing abnormal was found and none of the abdominal organs was handled. The operation was a trifling one. After the operation vomiting was most troublesome and persistent, and three or four days later her abdomen became distended. Notwithstanding all

sorts of drug treatment and many enemas, only a little flatus was obtained, but no fæces. *She had no pain whatever.* She had no 'deep tender spot' and no areas of rigidity—no sign that there was anything abnormal in the abdominal cavity.

Taken in relation to the amount of distension that she had and the long period in which she had had almost absolute constipation, her general condition was comparatively good. She gradually became worse.

On the eighth day, in the hope that the obstruction might be due to some painless inflammatory obstruction, she was reoperated on. The whole of the small bowel (non-inflamed) was found to be distended as far as the ileocæcal junction; at this point the distension ceased. The colon was normal in appearance. No mechanical obstruction or inflammatory areas could be found. Forty-eight hours after the operation the patient died.

The following case-history is an example of a paralytic ileus which followed an interval appendicectomy under avertin (basal narcotic) and ether.

A man, aged 25, who had had a severe motor accident five weeks previously, and who as a result of the accident had suffered from shock, was operated on for a chronic appendicitis. He was given avertin 0.9 per kilo as a basic narcotic. This did not take effect and he became very excited. Ether was administered. The operation took only a very short time, and an uninflamed appendix was removed through a small incision. The abdomen was not explored.

He vomited a good deal for the first two or three days after the operation and was very uncomfortable, vomiting three times on the third day. The first two days after the operation no flatus was passed; but on the third day a rectal tube delivered a little flatus. He had no tender spots anywhere over his abdomen.

His abdomen began to be distended on the third day, and became more so on the fourth day, when it was very distended, and he was vomiting bile-stained contents, but had no pain. High enemas delivered neither flatus nor fæces. On the fourth and fifth days he was vomiting copiously a black fluid (altered blood); his temperature ranged about 100°, and his pulse-rate was 99-100.

On the morning of the sixth day he vomited large quantities of what were undoubtedly fæcalent contents. He was given a spinal anæsthetic, a rectal tube was purse-stringed into the patulous anus, and a high bowel wash-out was given in the hope that he had a paralytic ileus caused by a sympathetic overaction, and that the release of the abdominal sympathetic fibres, brought about by the spinal anæsthesia, would produce a bowel action. No result whatever was obtained. As he was under spinal anæsthesia a small opening was made in the lower part of the abdominal wall, and the intestines were seen to be distended, not inflamed, but plum-coloured (probably from toxic spoiling). A small enterostomy was then made, but no intestinal contents flowed from the enterostomy tube.

After the operation he continued to vomit large quantities of brown fluid. Some intestinal contents washed out through the enterostomy tube were black and contained altered blood. He continued to vomit large

quantities of fæculent contents and to be tightly distended. He passed neither flatus nor fæces in response to high enemas.

This was the condition up to the ninth day of his illness, when hiccup developed. During the seventh, eighth, and ninth days no fæcal contents came from the enterostomy tube, although a little blood-stained contents could be washed out.

About the end of the ninth day of his illness the enterostomy began to act a little when an enema was given and the distension became slightly less. After each enema, three or four ounces of fæcal fluid passed through the enterostomy tube. From this time onwards some results were obtained with bowel wash-outs and his distension began to decrease. The bowel contents delivered with the enema were also blood-stained. On the twelfth day the enterostomy drained freely.

From the sixth to the thirteenth day of his illness, under the direction of Dr. Ian Wood, an Einhorn tube was left in situ in his stomach, and continuous-drip 5 per cent glucose and 0.9 per cent saline was intravenously administered. The contents of the stomach were aspirated and measured, fluid was introduced, and a table was kept showing the amount introduced, the amount discharged, and the amount of the urine. In this way Dr. Wood kept up the fluid balance in the body.

During the whole time the patient's condition remained good, and after the Einhorn tube was left in situ he was free from vomiting. His main discomfort then was his intense distension.

In this particular case, the question was whether the condition was a true paralytic ileus or some idiosyncrasy on the part of the patient to avertin. That the contents of the stomach and intestine contained altered blood, and that the intestine was plum-coloured, suggested that the whole condition may have been some queer toxic spoiling of the stomach and intestine by avertin. However, the signs and symptoms of the condition were exactly identical with those of a paralytic ileus.

The symptoms, signs, and treatment are given in precise detail, as they may serve as a standard for comparison in other cases.

An interesting coincident observation in this case, and one which showed how the emptying and filling of one segment has a profound influence on the emptying and filling of another, was that when the bowel was recovering its power, the emptying of the rectum and sigmoid by an enema caused (apparently reflexly) emptying of the small intestine from the enterostomy opening.

III. POST-OPERATIVE INTESTINAL OBSTRUCTION OF A MECHANICAL NATURE

As has been pointed out, a paralytic ileus comes on quietly without much pain. No local signs of trouble are found, such as tender spots, or areas of *défense musculaire*. The distension comes on quietly, about the fourth or the fifth day, without any rising

temperature or increase in the pulse-rate. Vomiting also comes on slowly about the same time and gradually increases in frequency, and soon the vomitus begins to show jejunal contents. For the amount of distension, the patient, even on the seventh or eighth day, is not very ill—his general condition is reasonably good.

When, however, an opposite clinical picture is found ; when, as pointed out on p. 789, the convalescence for the first few days after the operation has been stormy ; when there are areas of local disturbance—tender spots and areas of *défense musculaire* ; when the patient's general condition is disturbing ; when he has a slight, perhaps intermittent temperature and a rising pulse-rate ; when he begins to vomit early in his convalescence ; and when he becomes almost completely constipated—then these are circumstances in which the surgeon has to deal with one of two conditions : (1) mechanical obstruction caused by a kink or volvulus ; or (2) a localized focus of infection in the abdominal cavity causing more or less mechanical obstruction.

The Danger of Conservative Treatment.—In most cases of this description the surgeon is encouraged to persist in conservative treatment because enemata deliver some air and fæces, indicating relative constipation. This is due to the fact that the obstruction is either (1) high in the small intestine, (2) incomplete, or (3) due to an inflammatory focus and therefore incomplete.

The facts that there is a possible cause for an obstruction, that there is a localization of symptoms and signs, that there are actually some signs of obstruction and that these are progressive, should be quite sufficient criteria for the surgeon to make up his mind that an operation is urgently necessary ; and, moreover, enable him to make up his mind *early* in the course of the obstruction. To procrastinate generally means death to the patient.

Operative Treatment of Mechanical Obstruction.—A careful preparation of the patient must be undertaken. For twenty-four hours previously, 5 per cent intravenous glucose with 2 per cent saline should be administered by the continuous-drip method ; and just before the operation the stomach should be washed out, and an Einhorn tube left in situ.

The Patient's Condition is so Bad that it will Permit only an Enterostomy or Jejunostomy to be Done.—In such cases an enterostomy ought to be done in preference to a jejunostomy.

The small bowel should be opened as near to the site of the obstruction as possible. The incision should be over the ileocæcal junction, and should be a *small* split-muscle appendiceal incision. By keeping the incision low on the abdominal wall, it is very likely

that the distended loop of small bowel which presents will be fairly close to the obstruction.

The loop is allowed to present through the wound. The air is aspirated from the loop by obliquely inserting one of the needles

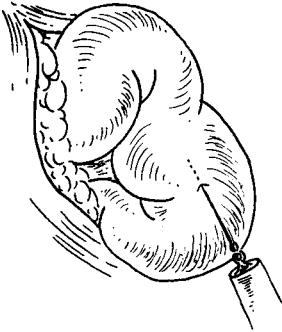


Fig. 589.—Loop of bowel presenting through wound.



Fig. 590.—Loop of bowel aspirated.

used for the local anæsthesia attached to a suction apparatus (*Figs. 589, 590*). If possible the omentum is brought out over the loop. The aspirated loop is closed by a soft intestinal clamp. A rubber tube about the size of a No. 4 catheter should be inserted into the

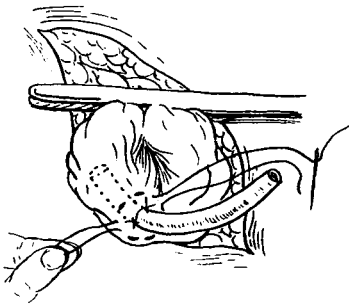


Fig. 591.—Loop closed by soft intestinal clamp; rubber tube inserted through small opening and fixed in position by two fine catgut sutures.

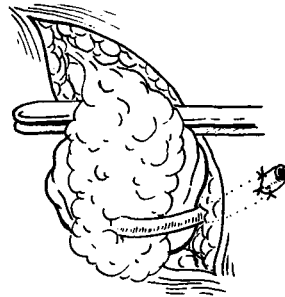


Fig. 592.—Tube involted into intestinal wall by several peritoneal sutures, and brought through a stab-wound in the abdominal wall.

deflated loop through a small opening and fixed there by two fine catgut sutures (*Fig. 591*). The tube should then be involted into the intestinal wall by several peritoneal sutures as shown in *Fig. 592*.

The importance of slow emptying of the distended bowel: The tube is now drawn through an opening in the omentum. Several

interrupted sutures are inserted through the omentum and the intestine and every effort is made to anchor the bowel firmly and accurately to the anterior abdominal wall so that a watertight joint is made. The omentum helps to prevent leaking from the enterostomy in its early stages (it also facilitates early closure of the fistula when the tube is taken out). The whole object of this technique is to enable the surgeon to empty the distended bowel slowly. To empty it rapidly is an important factor in causing collapse and death.

The importance of keeping up the amount of circulating blood as the bowel drains: It must be recognized that if the intestine is drained too rapidly the patient may in his weakened condition die from a sudden loss of fluid, for the absorbing mechanism of the small intestine is probably disabled, and no matter how much fluid he drinks he may not absorb it. Therefore, although the patient may be taking a great quantity of fluid in the twenty-four hours, he may not absorb it into his circulation, and his blood-pressure may sink rapidly and he may die—just simply from intense loss of fluid. Hence, immediately after the patient's enterostomy, if he is losing fluid rapidly, he should receive intravenously 4 to 6 litres a day of 5 per cent glucose in Ringer's solution by the continuous-drip method.

The Patient is Strong enough to Permit a Large Incision and a Search for the Point of Obstruction to be Made.—An operation in which a midline incision is made in the presence of obstruction of the small intestine is exceedingly dangerous, because manipulation of the distended bowel causes much shock, and because the distended intestines make the closing of the abdominal wound difficult. Such an operation should be reserved for the early stages of a suspected case of intestinal obstruction.

In order to obtain what is absolutely essential—complete relaxation—the operation should be carried out under spinal anæsthesia. This is used with the object: (1) of avoiding the prolapse of the distended intestines; (2) of permitting the easy closure of the abdominal wall; (3) of avoiding the paralysing effect of a general anæsthetic on the already partially paralysed bowel; and (4) of obtaining a release action of the intestine by the effect of a temporary paralysis of the sympathetic.

To prevent prolapse of intestines and difficulty in suturing up, the incision should not be midline, and should be of a valvular type. It should also aim at exposing the collapsed part of the small intestine, the part which can be handled without producing shock. For these reasons a large split-muscle incision extending into the rectus sheath (see *Fig. 598*, p. 860) should be made over the right iliac fossa.

In this position it is likely that the collapsed part of the intestine—the part below an obstruction—may be easily found. This collapsed intestine should be found and followed to the site of the obstruction. The manipulation of the distended bowel is thus obviated.

The obstruction can be dealt with according to circumstances, but as a rule its management is simple in these cases of post-operative intestinal obstruction—it may involve no more than unlocking a kink or dividing an adhesion.

REFERENCES

- ¹ ABBOTT, W. O., and MILLER, T. G., "Intubation Studies of the Human Small Intestine—III: A Technique for the Collection of Pure Intestinal Secretion and for the Study of Intestinal Absorption", *Jour. Amer. Med. Assoc.*, 1936, **106**, 16-18.
- ² MILLER, T. G., and ABBOTT, W. O., "Intestinal Intubation: A Practical Technique", *Amer. Jour. Med. Sci.*, 1934, **187**, 595-600; *Surg. Gynecol. and Obst.*, 1938, **66**, April, 691-7.

CHAPTER LXXII

COMPLICATIONS OF THE LATE POST-OPERATIVE PERIOD

IN the late post-operative period—towards the third week—special complications which may arise are :—

- I. Wound sepsis.
- II. Prolapse of the visceral contents.
- III. Post-operative peritonitis in the region of the wound.

I. WOUND SEPSIS**Causes.—**

1. *Injured or Devitalized Tissue.*—The tissue may have been injured by ungentle operative technique, and may have lost part of its local immunity. It then succumbs to an infection late in the convalescence, an infection with which it could easily have dealt if it were not injured. In constitutional diseases, such as gout, diabetes, senility, and so on, and in cases of cancer, the tissues have very little immunity and they cannot withstand even a mild infection. In such a combination, debilitated tissue and low infection bring about wound infection, which usually manifests itself late in the post-operative period.

2. *Infection from Catgut.*—As a rule infection from catgut is mild, and occurs about the tenth to the fourteenth day. It is generally due to the fact that the centre of the catgut strand has not been sterilized by the antiseptic solution with which it has been treated. As the catgut digests, infection occurs when this central part is exposed.

Treatment.—In an infected abdominal wound the peritoneum will deal with the infection much better than will the muscle and other layers of the abdominal wall. Accordingly, where the wound becomes infected it is as a rule only necessary to open it as far as the sutured peritoneum.

Should, however, the peritoneum also become involved, then the very strength of the peritoneum with regard to infection becomes its weakness, for if it fails to subdue the infection, those very physiological properties which give it an enormous power of defence also confer on it a very great absorbability and permit rapid spread of poison.

Wound infection which involves the peritoneum is serious. Such infection is much more dangerous in the upper part of the abdomen than in the lower; for the absorbing power of the peritoneum of the upper abdomen for toxic products is great.

It is therefore wise, with a wound in the upper part of the abdomen where the operation has been undertaken, for example, for perforation, to drain both the peritoneal cavity and the abdominal wound, more from the point of view of draining the peritoneal area in the vicinity of the wound than of draining the abdominal cavity. The omentum can be used to avoid any bad effects of a drainage-tube.

II. PROLAPSE OF THE VISCERAL CONTENTS

This complication occurs when for some reason normal healing of the wound does not take place.

It is especially likely to occur if, in conjunction with some interference of the normal healing, the patient suffers from coughing or vomiting. Thus, in a patient who has been unsuccessfully operated on for cancer of the stomach, who has defective tissue vitality, and who about the second or third week begins to cough or vomit, the wound may burst open and allow the intestines to prolapse.

The same thing may happen in very old people, or in patients operated on for tuberculous disease of the abdomen. It can also occur after an operation for perforated duodenal or gastric ulcer, or even after a gastric or duodenal resection, because the abdominal wound has been infected by gastric or intestinal contents.

In all cases, therefore, where there are reasons to suspect that the repair of the wound may be at fault, special care should be taken to strap the wound, or to provide the patient with a rubber corset, and not to take out the supporting silkworm-gut sutures too early.

III. POST-OPERATIVE PERITONITIS IN THE REGION OF THE WOUND

This can be divided into three main groups, as follows:—

Group I: Cases Infected from the Outside.—These are cases in which the wound became infected between the first and second post-operative periods. This is due to infection from unclean hands, instruments, suture materials, or bad preparation of the patient. With modern surgery it is now rare.

If a peritonitis follows an infected wound, the outlook is good. If on the other hand the peritonitis becomes manifest first and the wound infection follows, then the condition is serious and the outlook bad.

Group II : Cases Infected through the Patient's own Germs.—Such infection occurs in operations for perforation of hollow organs—infected appendix, infected gall-bladder, etc.

Peritonitis from this cause generally occurs when surgeons trust the peritoneum and do not drain the peritoneal cavity in the vicinity of the wound. It is true that in most cases the peritoneum will deal with such an infection, but cases occur in which it will not, especially in patients with defective tissue resistance. The region of the abdominal cavity in the vicinity of such a wound should always be drained. The drain can be removed in a few days; it will not cause any extra adhesions. If any infection does occur about this time, it will soon burst through the track of the tube, which is four days weaker in union than the rest of the abdominal wound. The insertion of the drainage-tube really acts as a safety-valve.

Group III : Infection from Suture Insufficiency.—In this group are comprised those cases in which the trouble occurs in the middle or late post-operative period, and a local peritonitis develops. They are usually due to a suture insufficiency and occur particularly in a resection of the large bowel, or in suture of a perforation, or in partial gastrectomy for late carcinoma. In these cases, either the infection is great, as in the case of the colon; or the resistance of the patient is very low and the infection is mild, as in carcinoma of the stomach. In such circumstances a fistula may form.

In these cases the peritonitis is serious, and the patient generally dies. The remedy is prevention. In the case of carcinoma of the stomach, silk sutures should be used in the outer layer. With the colon, it is a question whether end-to-end anastomosis on a functioning bowel (*see p. 942*) should be used at all. Should infection lead to a suture insufficiency in a partial gastrectomy and a fistula develop, the patient may be saved by aspirating the contents that come from the fistula and feeding them back, either naturally or through a jejunostomy. This is especially useful if the insufficiency is in the stump of the duodenum. Although this procedure is very unpleasant for the patient, if he has any resistance a time will come when the fistula will heal. Patients with fistula may die from an alkalosis and from inanition as a result of the loss of chlorides and nourishment from the fistula.

STAY IN BED

The disadvantage of prolonged rest in bed is as follows: Old patients depend upon function for the efficiency of their circulation. They require muscle movement in order to supply the heart with

an adequate amount of blood—to obtain a proper venous return to the heart—and therefore to enable it to keep up its normal pumping function. Prolonged stay in bed cripples the circulatory mechanism of old people. This crippling takes the form of lowered venous and arterial pressure, and sluggish circulation in certain positions of the body. There is stasis of blood in the lungs and in the extremities. In the extremities this predisposes to thrombosis, which may give rise to embolism, and thus to serious post-operative lung complications. This circulatory depression also interferes with the general well-being of the patient, and the healing of his wounds. It is therefore desirable that old patients particularly should be got out of bed as soon as possible.

Bed Gymnastics.—With a view to keeping up the circulatory mechanism while the patient is in bed and unable to move his muscles freely, bed gymnastics should be carried out. These movements, which consist of movements of the legs and arms and also deep breathing exercises, should be practised under the supervision of a nurse. The patient should be encouraged to lie in any position in bed, and to change his position frequently, and to sit up and move about in the bed carefully. Such exercises improve the venous return in those patients who have a crippled circulation; and they convalesce more quickly and with a lesser incidence of thrombosis.

*CHAPTER LXXIII***REMOTE POST-OPERATIVE COMPLICATIONS**

UNDER this head reference is made to the various problems—remote sequelæ of the operation—which occur from a few weeks to a few months after an operation. Nowadays, when an enormous number of operations is done, the diagnosis and cure of post-operative morbidity is a feature of a surgeon's practice.

The practical surgical problem as a rule is whether the post-operative morbid condition requires an operation. This depends upon whether any one of the following sequelæ is present: adhesions, causing angles or twists or kinks; strangulation under bands; strangulation through openings in the great omentum; strangulation underneath the omentum in a post-operative hernia. Any one of these may interfere with the function of the bowel, cause slight obstruction, and require operation.

From clinical symptoms and signs it is exceedingly difficult to decide if there is any partial or intermittent obstruction of the small intestine. It is also very difficult to decide this by an X-ray examination. The reason is that, as the contents of the small bowel are fluid, the lumen of the bowel can be almost as small as a pen-holder before it gives symptoms or signs of obstruction.

Adhesions, unless they become 'wire-drawn' and therefore painful, do not require operation. The unpedicled adhesion which does not mechanically narrow the lumen of the bowel and is not of the 'wire-drawn' type does not cause pain.

In regard to the many symptoms—such as obstinate constipation, nausea, vomiting, chronic abdominal pain—which may be the result of an operation on the alimentary tract, and all of which may be the consequence of an unskilful and unsurgical operation—Chapter XL, on the treatment of adhesions, should be consulted. Not only will a study of this chapter make clear the unpleasant late effects which follow operations, but it will largely enable the surgeon to avoid these ill results.

CHAPTER LXXIV

**THE STRATEGY OF THE SURGICAL APPROACH
TO A CASE OF SUPPOSED PERFORATION
OF A HOLLOW ORGAN**

THE incidence, the cause, the pathology, and the routine technique in regard to the management of a case of supposed perforation of a hollow organ will, or at least should, be common knowledge for the surgeon who undertakes the responsibility of surgical treatment of such a condition. The application of this knowledge, however, is of as much importance as its possession; in other words, the strategy of the operative approach to a case of perforation has much to do with the success of the operation.

In such finesse preliminary considerations are the following:—

1. Is it actually a case of perforation? There are many acute abdominal emergencies which give rise to similar symptoms and signs.
2. If it is a perforation, is it in the upper or the lower part of the abdominal cavity?
3. In what organ in these parts has the perforation occurred?
4. What pre-operative treatment should be employed to minimize the effects of the perforation and to help the effectiveness of the operation?
5. What form of anæsthesia should be used?
6. What is the operative technique?
7. Should the abdominal cavity be drained?
8. In the case of a perforation of the stomach or duodenum, should the patient have a radical operation to cure the condition which caused the perforation?

Later comes the question: What is to be the post-operative treatment?

I. IS IT ACTUALLY A CASE OF PERFORATION?

Often the surgeon is confronted with a patient suffering from acute abdominal pain and exhibiting the symptoms of severe shock and signs of general abdominal rigidity. In other words, he is faced with a case presenting a not quite convincing clinical picture of

perforation. Thus the first point, of cardinal importance, is an accurate diagnosis.

As a rule no doubt exists in regard to cases in which the perforation is large. Here the patient is stricken down with agonizing pain, the symptoms of shock are profound, the abdomen is "as hard as a board", the abdominal cavity shows evidence of the presence of fluid and air content, and it is clear from the patient's history, the expression of his face, and the way in which he lies in bed, that he is suffering from perforation.

But it is quite another matter with a small perforation, especially if it occurs when the stomach is empty. Here the onset is not so sudden, the shock is not so great, the abdominal wall is not board-like in its rigidity, there is little evidence of air or fluid contents in the abdominal cavity, and the patient's general appearances are compatible with those sometimes seen in acute extra-abdominal conditions such as the onset of a pneumonia, or with those of other acute abdominal emergencies—as, for instance, an acute biliary or renal colic or similar less serious abdominal condition.

The confusion in regard to this type of perforation is seen in the following example :—

A man, aged 60, the father-in-law of a doctor of considerable skill under whose observation he was, became suddenly ill with epigastric pain, some evidence of shock, with no rise in temperature but with a good deal of epigastric rigidity and tenderness. The tenderness and rigidity then began to extend to the right upper part of the abdomen, and the patient's temperature to rise a little, although his pulse-rate had quieted down. Impressed by the right-sided upper abdominal symptoms, the doctor made a diagnosis of gall-stones. In twenty-four hours the whole of the right side of the abdomen had become rigid and tender—especially in the region of the appendix. The patient's temperature was now lower, but his pulse-rate had increased to about 120, and the whole abdomen, when he was seen some hours later, had become rigid. The doctor now thought the case might be one of appendicitis.

On examination the patient was still tender and rigid over the upper and right part of the abdomen ; he had evidence of air in his peritoneal cavity, and he was undoubtedly suffering from a small perforation of the duodenum, which allowed its contents to seep slowly down along the right side.

Had it been a case of appendicitis he would not have had a persistence of the painful and reflex epigastric symptoms in the upper and right parts of the abdomen.

In these cases of small perforations, the finding of air in the peritoneal cavity with the bedside X-ray apparatus is a great help in establishing the diagnosis.

2. IS THE PERFORATION IN THE UPPER OR THE LOWER PART OF THE ABDOMEN?

The surgeon should try to decide on broad grounds whether the perforation has occurred in the upper or the lower part of the abdomen. On this decision will depend the carrying out of one important principle, namely, the placing of the incision over the perforation. An erroneously placed incision may mean the difference between life and death to the patient with a perforation.

It is not always easy to decide whether the perforation is high or low.

A perforation in the lower part of the abdomen usually arises from an appendix, occasionally from a ruptured diverticulum of the sigmoid, and rarely from a typhoidal or tuberculous affection of a Peyer's patch, or from an ovarian cyst or hydatid.

A perforation in the upper part of the abdomen may occur in the stomach, duodenum, gall-bladder, jejunum (jejunal ulcer), or in a hydatid.

In the case of a perforation in the lower part of the abdomen there is generally a definite localization of symptoms and signs during the actual onset of the catastrophe. In the case of the appendix this localization is in the appendiceal area; in a diverticulum it is in the sigmoid region; and in an ovarian cyst in the hypogastrium.

If, however, an appendix is situated in the pelvis it is most important to remember that local manifestations of a perforation may be entirely absent: the general manifestations of peritonitis may usher in the illness.

The clinical picture, too, of a perforation in the lower part of the abdomen is not so catastrophic as is one in the upper part: it is not associated with its acute and agonizing pain, with its intense shock, its board-like rigidity, its rapid progress of symptoms, its profound collapse, or with its rapid change in the patient's appearance.

As a rule, therefore, on general grounds—even in obscure cases where it may be impossible to make a diagnosis of the organ in which the perforation has occurred—one can generally determine whether it is in the upper or lower part of the abdomen, an important diagnosis from the standpoint of the placing of the incision.

3. DETERMINATION OF THE ORGAN AFFECTED

Should it be possible to localize the perforation to the upper or lower part of the abdomen, then an attempt should be made to localize it to the particular organ.

If the perforation is in the upper part of the abdomen, it is necessary to decide whether it is on the lesser curvature of the stomach, in the duodenum, or in the gall-bladder. A previous history indicating gastric or duodenal ulcer or gall-stones (often a previous radiograph) and the early manifestations which are local are a guide to this. A knowledge of the organ involved enables the incision to be aimed directly over the perforation, and thus to be made high in the abdominal wall and therefore small.

A correctly placed incision permits the closure of the perforation without disturbing the surrounding intestinal loops. There are many reasons why an incorrectly placed and therefore large incision militates against a successful issue. The struggle to reach the perforation distributes the spilt contents (not very widely distributed if the operation has been prompt); and also it abrogates the delicate function of the small intestine and adds further to the injury caused by the spilt contents. Moreover, in case of perforation a large wound of the abdominal wall has disadvantages. Such a wound must necessarily become more or less infected by the visceral contents. On this account it may heal unkindly, or it may injure the patient as a result of toxic absorption, or, as the low infection interferes with normal healing, it may burst open if the patient vomits much. All these dangers are greatly minimized if the wound is small.

If the perforation can be localized to the lower abdomen, it is not as a rule difficult to decide whether it is a perforated appendix or diverticulum. Occasionally the distinction may be impossible. In these circumstances it is better to make a split-muscle incision, on each side if necessary, rather than a midline incision.

4. PRE-OPERATIVE TREATMENT

Until a definite diagnosis has been established, morphia should be withheld.

While a case of supposed perforation is under consideration with a view to operation, pre-operative treatment should be instituted in order that no time may be wasted.

An attempt should be made to lessen the spread of the extravasated contents. If the perforation is in the upper part of the abdomen, the patient should be placed on his right side and in a position so that the perforated organ is the lowest part. If the perforation is in the lower part of the abdomen, the patient should be so postured that the pelvis or the affected area is the most dependent part. The proper posturing of the patient while waiting for the operation not only limits the spread of the contents, but also

facilitates their collection into one spot—the region of the lesion—where they can be easily ‘ vacuum-cleaned ’.

While waiting for the operation, efforts should also be made to combat the shock and prepare the patient for the heavy strain on his circulatory system which the post-operative period is bound to entail. With this object in view, morphia should be administered, the patient kept warm (not too warm), and, in serious cases, intravenous administration of fluid, of glucose, and perhaps of whole blood, instituted.

5. CHOICE OF ANÆSTHETIC

In a case of severe perforation, an important point in operative strategy is a wise choice of anæsthetic. In this type of emergency operation, there are two great requirements in an anæsthetic : firstly, that it should give complete relaxation so as to avoid prolapse of intestine, and permit free access to the perforation—sometimes deep in the abdominal cavity ; and secondly, that the anæsthetic should not itself, from its general effects, cause chemical shock in a patient who is already shocked. The form of anæsthesia which, in the opinion of the author, fulfils these requirements is the percaine zonal method of spinal anæsthesia originated by Kirschner, and described on p. 473. This method is particularly valuable in the case of a perforation of the upper part of the abdomen, because the dependent position of the perforation (from the head-down position required while the anæsthetic is being given), combined with the completely relaxed condition of the abdominal wall, permits the ruptured contents to seep back into an accessible position. Furthermore, the method gives rise to little shock.

It is, however, not so satisfactory for a perforation in the lower part of the abdomen, such as an appendiceal or diverticular perforation, where because of the very septic nature of the contents the patient requires all his local tissue immunities—which, in the author’s opinion, are not always conserved by spinal anæsthesia. In these circumstances light ether or nitrous oxide gas supplemented by ether is perhaps the most suitable anæsthetic (*see pp. 463, 464*).

6. OPERATIVE TECHNIQUE

In the operative technique the important points are the placing of the incision, the protection of the abdominal wound, the exposure of the perforation, the suture of the perforation, and the aspiration of the extravasated contents.

Placing of the Incision.—Should it not be possible to localize the perforation to the organ affected, it may be wise to make in the appendiceal area a small ‘test incision’. The character of the extravasated contents then indicates their origin: if bile-coloured they are from the duodenum; if acid-smelling and uncoloured with bile they are from the stomach; if pus-containing and fæcal-smelling they are from the lower abdomen and from a ruptured appendix or diverticulum.

Should the perforation thus be found to be in the upper part of the abdomen, then a paramedian incision (*see Fig. 229, p. 329*) will be made as high as possible, with the upper angular part of the incision extended across the midline. The idea is to get above the perforation so as to look down on it.

The small appendiceal incision can then be utilized for aspirating the pelvis or for inserting a drainage tube.

Protection of the Abdominal Wound.—In the light of the fact that after operations for perforations the abdominal wound often gives trouble, special care should be taken to protect it; for the extravasated contents must be regarded as septic. Before opening the peritoneum, a blunt hook should be inserted in the lower angle of the wound and the abdominal wall elevated so that the peritoneum can be opened without the contents gushing over the edges of the wound. Impermeable wound covers are then clamped on the wound by means of the operating frame before the abdominal wall is lowered (*see p. 332*).

Exposure of the Perforation.—The adequate exposure of the perforation is a first consideration. To attain this, as already pointed out, the first point is a well-placed incision; the second is the use of the operating frame and, in the case of a rather deep duodenal perforation, the employment of ‘mechanical hands’ with filmy scarves, with a view to coffer-dam off the perforation (*see Fig. 247, p. 346*).

Suture of the Perforation.—The suture of the perforation is the next step. No. 0 slightly hardened gut, armed with an atraumatic needle, should be used. One tier of interrupted sutures should be employed, each suture being inserted through uninflamed tissue; and over this a large wad of pedicled omentum should then be applied, using interrupted sutures.

Aspiration of the Extravasated Visceral Contents.—Care should be taken to aspirate the whole of the spilt contents; any solid material left must be wiped out. As the patient is being prepared he should be postured so as to drain these, as far as possible, to one spot—the operation area. In the case of the upper abdomen, this area, together

with the lesser peritoneal cavity, the space at the back of the liver, the right renal fossa, and the pelvis must be carefully 'vacuum-cleaned'; and in the case of the lower abdomen these regions will be aspirated, but above all the pelvis will receive special attention.

7. THE QUESTION OF DRAINAGE

It is, of course, impossible to drain the abdominal cavity. The insertion of a tube through the abdominal wound into the region where any contents may congregate will, however, drain these contents for the first twelve hours, and thus remove pabulum on which organisms may obtain a footing. But, after the first twelve hours, when the drainage tube ceases to function, the abdominal cavity must look after itself: the tissue resistance of the peritoneum must deal with any infection.

There is, however, another function for the drainage tube. It can be used as a safety-valve to anticipate the formation of a secondary abscess, especially if it has not been possible to remove foreign material. Used in this way it acts as a vent. For instance, the tube can be placed *just through* the abdominal wall below the last rib, or deep into the pelvis, or in the right iliac fossa—all places where secondary abscesses develop. Should they develop they will always break, in their early stages, through the vent left in the abdominal wall. A tube or rubber tissue in the pelvis, where it may cause adhesions to the small intestines, can be screened from them with omentum; and the tube in the region around the colon does little harm. Thus a tube used for its vent action can be so disposed that it never gives rise to any ill effects and often it is the means of saving a life.

8. THE QUESTION OF A RADICAL OPERATION

In the case of a perforated duodenal or gastric ulcer, the question will arise whether an additional operation, such as a gastro-enterostomy or a partial gastrectomy, should be combined with the suture of the perforation. In the author's opinion a gastro-enterostomy is rarely justifiable. It may perhaps be necessary if the insertion of the closing sutures has caused a pyloric or duodenal obstruction, which seldom happens; but from the point of view of curing the ulcer (which may be acute or subacute) it is quite unjustifiable.

Partial gastrectomy as a surgical treatment for perforated gastric ulcer is not infrequently employed in many Continental clinics. This is still more unjustifiable. Even if the operation is carried out under local anæsthesia this does not much minimize the risk; and the use

of local anæsthesia in the upper part of an abdomen which has been soiled with septic gastric contents is not sound surgery. Partial gastrectomy as a treatment for perforated gastric or duodenal ulcer should never be considered under any circumstances, except when the operation takes place an hour or two after the perforation.

POST-OPERATIVE TREATMENT

The special requirements in post-operative treatment are :—

1. To deal with acute post-operative circulatory disturbance.
2. To promote the local immunity of the tissues of the abdominal cavity so that they may deal successfully with the infection.
3. To help the wound in the abdominal wall to heal despite the low infection which must be present in it.
4. To watch for any secondary abscesses that may form in the pelvis, or in the subphrenic space, as the result of the extravasation of the contents of the perforated viscus.

The application of hot air or short-wave diathermy to the abdomen considerably helps the local tissue immunity. Radiant heat also helps the healing of the abdominal wound under adverse circumstances.

The management of acute post-operative circulatory disturbance is dealt with in Chapter LXVII.

CHAPTER LXXV

**THE STRATEGY OF THE SURGICAL APPROACH
TO A CASE OF SUPPOSED INTESTINAL
OBSTRUCTION**

WHEN the surgeon is confronted with a supposed case of intestinal obstruction—usually a consultative problem—questions will arise in the following order :—

1. Is it a case of mechanical obstruction? If it is :
2. What is the level of the obstruction?
3. Is there an obstruction of the intestinal circulation?
4. What is the nature of the obstruction?
5. Is it a question of immediate operation or of temporizing treatment?
6. If an immediate operation is necessary, what should be the nature of the pre-operative management?
7. What should be the strategy of an operation?
8. What should be the plan of post-operative treatment—a question of much importance in the treatment of an obstruction?

**THE USUAL CLINICAL PICTURE OF ACUTE
INTESTINAL OBSTRUCTION**

As a preliminary to a consultation on a case of supposed intestinal obstruction, some phases of the usual clinical picture will repay special attention. There are three phases which are of importance in the surgical diagnosis :—

1. The previous clinical history—often most illuminating as to the cause of the obstruction.
2. The actual onset of the obstruction : the first 12 to 24 hours during which local symptoms and signs unclouded by those of intestinal obstruction predominate—manifestations which when carefully analysed are of much value in making a diagnosis as to causation.
3. The established clinical picture when the symptoms and signs are in addition those of obstruction of the intestine.

1. Previous Clinical History.—Information obtained from the previous history is very often good indication of a cause, as in the examples that follow.

a. Previous attacks of gall-stones suggest the possibility of gall-stone obstruction.

b. A previous operation which has been followed by a stormy convalescence—an indication of infective troubles, of errors in technique, or of a post-operative condition which is very likely to lay the foundation of obstruction of the small intestine.

c. A previous history of having had certain types of operation, such as gastro-enterostomy, partial gastrectomy, colectomy, or Gilliam's operation—all operations in which strangulation under or through gaps in the mesenteries is likely to occur.

d. Previous attacks of any inflammatory condition such as appendicitis (especially a pelvic appendicitis), salpingitis, etc.—conditions from which chronic small-intestinal obstruction as a result of bands, angles, or strictures can arise.

e. Previous indications of the presence of abdominal tuberculosis, a potent cause of an apparently causeless obstruction.

2. The Actual Onset of the Obstruction.—It is in this stage that there may be a localization of symptoms of recognizable origin, as for instance :—

a. The changes that take place when strangulation occurs in an external hernia—the onset of pain, of tenderness, of rigidity, of loss of resonance.

b. The local manifestations of an inflammation, which, in the early stages of an obstruction, are found in the left iliac fossa, and which are indications of either a pelvic appendicitis or of an inflammatory diverticular tumour.

c. Local symptoms and signs in the left side of the abdomen which may indicate a volvulus ; that is, local cyst-like tender tumour, associated with rigidity and tenderness.

d. Manifestations in the right lower quadrant which may point to strangulation in relation to a Meckel's diverticulum or to ileocæcal volvulus.

3. The Symptoms and Signs Arising from Obstruction of the Intestine.—The symptoms and signs of intestinal obstruction—the typical manifestations usually given in text-books—are well known and need not be described in detail here. They are: absolute constipation—repeated enemas yield neither fæces nor flatus ; progressive distension unassociated with tenderness or rigidity ; continuous gulping vomiting with a vomitus passing from green to dark-brown in colour and finally becoming stercoraceous ; absence of infective symptoms ; and all the manifestations of collapse—fast pulse-rate, low blood-pressure, and appearance of general exhaustion.

IS IT A CASE OF MECHANICAL OBSTRUCTION?

The first question in a case of supposed intestinal obstruction will be: Is it actually a case of true mechanical obstruction? An apparent intestinal obstruction can occur as a result of the toxic or inflammatory action of some general or local disease.

Toxic Pseudo-obstruction.—When a case of apparent acute intestinal obstruction occurs during the course of a general disease such as uræmia, in the late stages of cirrhosis of the liver, in general infective diseases, or during the course of a local disease not situated in the alimentary system, such as pneumonia or heart failure, then a surgeon must be conservative in making a diagnosis of a mechanical intestinal obstruction. His reasons for such caution will be that the apparent obstruction is a cessation of alimentary-canal function due in the case of renal and hepatic disease almost certainly to a general toxic action on the musculature of the bowel caused by the action of toxins produced in the body; in the case of general infective disease to toxins produced from bacterial growth; in the case of pneumonia to either a toxic action or a spread of the pneumococcal infection to the peritoneum; and in heart disease to intestinal circulatory disturbances with consequent loss of the intestinal movements. Moreover, the surgeon should err on the conservative side, because in such circumstances an exploration of the abdominal cavity is a desperate measure on account of the serious condition of the patient.

Functional Obstruction (Dynamic Ileus).—The question of whether an obstruction is due to paralysis of the intestine as a result of some derangement of the autonomic system—the question of a functional intestinal obstruction (paralytic ileus)—only arises in the case of supposed acute intestinal obstruction following an abdominal operation. This aspect of obstruction and its differential diagnosis from a true intestinal obstruction has already been dealt with on p. 792.

Inflammatory Obstruction.—A type of inflammatory obstruction is found associated with abdominal infection. It may be considered under two categories: the pseudo-inflammatory obstruction of a general peritoneal infection; and the true mechanical obstruction caused by a local inflammatory focus.

Pseudo-inflammatory Obstruction.—This is seen as the result of a general paralysis of the intestinal musculature following in the wake of a general peritonitis. As a moderate grade of general peritonitis may first become obvious by a loss of bowel function—a constipation and a distension of comparatively slow onset—and also as the beginning of this peritonitic condition may not be accompanied by

noticeable signs of infection, this form of obstruction may be difficult to distinguish from a slowly arising true acute intestinal obstruction.

The distinction of these types of pseudo-obstruction from true mechanical obstruction is not as a rule difficult. Apart from perhaps an indefinitely distributed tenderness and some constitutional evidence of an infective condition, it will be found that in an obstruction of the peritonitic type, while the distension is fairly marked, the constipation is only relative and not consistent with the extent of the distension. It is, as it were, an incomplete obstruction with the distension of a complete obstruction. The same is true of the toxic pseudo-obstruction found as a complication of the toxic and infective states mentioned above. In both these conditions encouraging results from repeated enemas rather point to a muscular lesion of the bowel wall—of the detrusor muscle of the intestine—than to a mechanical obstruction. There is, too, in the inflammatory type, generally some evidence of an inflammatory condition which is sufficient to account for this type of obstruction.

True Mechanical Obstruction Caused by an Inflammatory Focus.—The form of pseudo-inflammatory obstruction caused by a beginning peritonitis—the form which is difficult to distinguish from a beginning intestinal obstruction—must be carefully distinguished from that form of true mechanical obstruction which is caused by a local focus of inflammatory disease. This form is seen in the case of an appendiceal abscess, which paralyses the musculature of a small segment of intestine by its local toxic action and thus produces a true mechanical acute intestinal obstruction above the block caused by the segment of paralysed intestinal wall. We have an example of such a form of obstruction in the post-operative mechanical ileus associated with areas of local peritonitis and in the mechanical obstruction found in association with an acute pelvic appendicitis.

Much importance attaches to the recognition of this form of intestinal obstruction, because the principles of its surgical treatment are different from those of an ordinary acute mechanical obstruction; the operative approach which would be successful in the mechanical obstruction would probably kill the patient in the case of the inflammatory obstruction.

A striking illustration of a true inflammatory obstruction caused by a pelvic appendicitis will be found in the case-history given on p. 849.

The surgical strategy in that case was to make a low and lateral operative approach and thus to remove the appendix and drain the abscess without disturbing the obstructed, dilated coils of small

intestine, which were vulnerable to infection. This was accomplished by a T-shaped split-muscle incision immediately above Poupart's ligament (*see Fig. 606*, p. 870), and by a retrograde appendectomy and drainage of the abscess along the appendiceal tract.

If an enterostomy is necessary in these cases of inflammatory obstruction, it should be made through a small incision in the left side.

WHAT IS THE LEVEL OF THE OBSTRUCTION ?

Having settled that the supposed obstruction is an actual one, the next logical question is : What is the level of the obstruction ? If the site of the obstructive lesion can be localized, even to the small or the large intestine, then the diagnosis of the nature of the lesion is half-accomplished.

Though it may not be possible to say at what level the lesion is situated, it is usually possible to say definitely whether it is in the small or large intestine.

How important this second question is at this stage of the consideration of a case of supposed intestinal obstruction will be evident from a study of the following two cases, which have been chosen because they show very distinctly how at first a broad diagnosis in regard to the location of the lesion may influence the operative treatment :—

An Inoperable Large-bowel Obstruction.—

The first case was that of a man, aged 70, an alcoholic suffering from renal disease, who was a very bad risk. He became ill with general abdominal colicky pains, with excessive and continual vomiting, and with complete constipation. His was obviously a case of acute intestinal obstruction. His medical man, finding he had a hard, firm, fixed, slightly tender lump in the left iliac fossa, was quite certain that his obstruction was due to carcinoma of the sigmoid ; and as his urine was " loaded with albumin " and he was a bad risk and his collapse was great, he thought that he could not even take the risk entailed in a palliative operation for the relief of the obstruction.

In the consultation that ensued, four things stood out : (a) the vomiting had started with the onset of his obstruction and had been continuous ever since ; (b) the distension was not very great ; (c) the collapse was profound for the time that the obstruction had existed ; and (d) he could tolerate an enema of 3 pints without inconvenience. These were features characteristic of an obstruction of the small intestine. Therefore, notwithstanding the definite objective finding of a tumour in the region of the sigmoid which appeared to be definitely malignant and the cause of the obstruction, a diagnosis of obstruction of the small intestine was made. As this diagnosis practically presupposed an innocent lesion any risk was now justifiable, and an operation was undertaken. A few minutes sufficed to remove a strangulated bunch of small intestines from a large internal hernial pouch in the left iliac fossa and the patient recovered.

An Apparently Causeless Intestinal Obstruction.—

The second case was that of a woman, aged 80, who became ill with general abdominal colicky pain, intense vomiting, and complete constipation. She was evidently suffering from intestinal obstruction. An examination of the abdomen revealed no obvious causal hernial strangulation. An explorative attack in a very sick woman aged 80 with no definite local objective seemed bad surgical strategy. On further reflection, as the patient's abdomen was almost flat and she had other features inconsistent with a lesion at the level of the large intestine, it must certainly be an obstruction of the small intestine. As obstruction in this region at the patient's age was difficult to explain except by some hernial strangulation; she was re-examined from this point of view, when a more careful examination showed a small—practically impalpable—lipoma-like condition in the inguinal region: a case of Richter's hernia. The simple operation (under local anæsthesia) which followed was easily borne by this very sick and very old woman.

In regard to a diagnosis of the level of the lesion, it can be said that the higher the lesion in the alimentary canal, the earlier, more persistent, and more continuous will be the vomiting; the less the distension; the more profound the collapse in the time; the less complete the constipation; and the bigger the enema that can be tolerated without inconvenience. Conversely, the lower the site of the obstruction, the more will the reverse of these conditions hold.

An obstruction of the upper part of the small intestine may be most misleading. The patient's main complaints are vomiting and abdominal pain. He is not completely constipated, and his abdomen is often rather flat and does not give the impression that he has a complete obstruction. His general condition may not appear to be bad. Thus obstruction in this region is often not recognized until the operation is of no avail.

THE QUESTION OF CIRCULATORY OBSTRUCTION

The question of whether the circulation as well as the lumen of the bowel has become obstructed is of primary importance.

Where this circulation is involved, local symptoms and signs (as in a strangulated hernia) initially dominate the clinical picture, the course of the illness is rapid, the condition of the patient quickly becomes serious, the need for operative relief is extremely urgent, and the prospective operation is a serious one.

But where the circulation is not involved, as in cases of obturation such as arise from a large gall-stone or from a malignant growth, there is a less alarming clinical picture: the local manifestations are absent or are not so obtrusive, the illness is not so rapid and prostrating, and the possibilities in regard to operation are not so serious, except

perhaps in the case of malignant disease, where the lethal effect of late malignant growth must be reckoned with.

In cases in which the circulation and viability of the bowel are in question, as in strangulated hernia, the local signs of pain, tenderness, and swelling may be due to the strangulation of the omentum, which also gives rise to these symptoms and to an inhibition of the function of the alimentary canal. However, whether the circulatory disturbance is in the omentum or the bowel does not matter; for so urgent is the need for surgical intervention in any kind of vascular involvement that the condition must be surgically explored at once lest peritonitis should develop, and a mistake be made which would cost the patient's life.

WHAT IS THE NATURE OF THE OBSTRUCTION ?

The next question is : What is the nature of the obstruction ? When considering this question the surgeon may proceed along the following lines of thought :—

1. The localization of the site of the obstruction will narrow down the diagnosis to either the small or the large intestine : obstruction in the former is usually innocent and in the latter generally malignant.

2. In the previous history, certain incidents, such as operation or repeated operations, generally point to a very likely cause of obstruction of the small intestine. Previous similar attacks over a long period indicate innocent obstruction. A background of unremitting progressive ill health over a comparatively short period suggests a malignant obstruction.

3. In the present history positive findings—local symptoms and signs—will afford a clue to the nature of the obstruction.

4. Finally, the whole diagnosis may be checked up by a consideration of the causes of intestinal obstruction, and of the frequency of occurrence of the various types. In general it will be found that strangulated external hernia is the cause of acute intestinal obstruction in 40 to 50 per cent of cases ; late post-operative complications in 15 to 20 per cent ; early post-operative complications in 12 to 15 per cent ; neoplasm in 9 to 11 per cent ; intussusception in 4 to 5 per cent ; obturation by gall-stone or foreign body in 2 to 4 per cent ; mesenteric thrombosis in 2 per cent ; congenital anomalies in 1 per cent ; and Meckel's diverticulum in 1 per cent. Obstruction due to other causes occurs less often than 1 per cent.

External Hernia.—Intestinal obstruction as a result of external hernia is by far the most common cause of intestinal obstruction. It is most frequent as a result of inguinal hernia, next in frequency

in femoral hernia, then omental hernia, and is only occasionally seen in midline epigastric hernia or other less common hernias.

Intestinal Obstruction during the Early Post-operative Course.

—Acute intestinal obstruction occurring during convalescence from an abdominal operation is dealt with in Chapter LXXI. As there pointed out it may arise as a result of intestinal angles or kinks caused by inflammation; invagination of the intestine into openings in the wound made by gaps in the suture line or by the cutting out of sutures; herniation through the transverse mesocolon after gastro-enterostomy, or through the mesenteric gap often accidentally left after a partial colectomy, or through openings in the broad ligaments after gynæcological operations; strangulation of a loop of bowel under a band of adhesion; a volvulus forming under a band; or of a segment of inflammatorily paralysed bowel.

Intestinal Obstruction during the Late Post-operative Course.

—Intestinal obstruction as a late complication of operation is seen in the strangulation of small intestinal loops under 'wire-drawn' adhesions; in the herniation through the transverse mesocolon after gastro-enterostomy or partial gastrectomy, through a gap in the mesentery after partial colectomy, or through an opening in a broad ligament that sometimes follows a Gilliam's operation; and in the strangulation of intestine in a post-incisional hernia.

Other Causes.—In regard to checking the diagnosis, consideration of the nature of the lesion will then be continued as follows:—

Internal Herniation.—An intestinal obstruction is rarely caused by a strangulation in an internal hernial pouch. Frequently what may appear to be such a strangulation may actually be in an external hernia which has, by forcible measures, been reduced *en masse*.

Volvulus.—Volvulus is seen in the small intestine as a result of congenital anomaly, and is in the neighbourhood of the ileocæcal region when there is undue descent and mobility of this part of the bowel. It is found most frequently in the sigmoid, and generally in those sigmoids which have long mesenteries.

Inflammatory Focus.—Intestinal obstruction may occur as the result of a block caused by a segment of bowel which has been paralysed as a result of an inflammatory focus in the abdomen, e.g., an abscess, or of a cellulitis, e.g. of the sigmoid.

Intussusception.—Obstruction from intussusception is frequently seen in children. It is found in adults as the result of a neoplastic lump in the intestinal wall, e.g. a papillomatous carcinoma of the colon or small intestine. It is also seen in relation to a Meckel's diverticulum which has attached to it a lump of fat.

An obstruction from intussusception is more likely to be acute in children and less acute when it occurs in adults.

Gall-stones.—Intestinal obstruction caused by a gall-stone (obturation) may occur in the upper part of the duodenum, but is usually found in the lower part of the ileum or at the ileocæcal valve. It is recognized by the following facts: There is a previous history of gall-stones; although its signs are those of an obstruction of the small intestine, the effect of the obstruction—the collapse—is not as profound as that of the usual obstruction of the small intestine; and the course of the illness is longer.

Meckel's Diverticulum.—Intestinal obstruction in relation to Meckel's diverticulum occurs as the result of strangulation or of volvulus under the band which is frequently found connecting the diverticulum to the umbilicus. It can also occur as the result of an invagination of the Meckel's diverticulum into the ileum; that is, as a result of an intussusception of this structure.

Neoplasm.—As has already been stated, acute obstruction of the small intestine occurs as a result of a neoplasm in about 1 per cent of cases, but in the large intestine in from 9 to 11 per cent of cases.

THE QUESTION OF IMMEDIATE OPERATION OR OF TEMPORIZING TREATMENT

The question arises as to whether the surgeon should operate at once or should temporize with a view to carrying out radical treatment when the patient has recovered from an obstruction. The answer to this question will depend upon the diagnosis and upon how far the accuracy of this can be depended upon. Temporization may be considered in the following circumstances:—

1. Inflammatory Obstruction.—When inflammation is the cause of the obstruction, e.g., cellulitis of the sigmoid in a diverticular tumour, the surgeon can of course depend upon the regression of the obstruction as the inflammation resolves. Care, however, must be taken that the left-sided local inflammatory symptoms suggestive of an obstruction from diverticulitis or diverticular tumour are not the rising up from the pelvis into the abdomen of a local peritonitis from a pelvic appendicitis. In this case the surgical treatment must be prompt, and the cause—the inflamed appendix—removed.

2. Incomplete Obstruction.—When the obstruction is incomplete temporizing treatment may be instituted with a view to carrying out a radical operation later under better circumstances.

But it must be emphasized that temporizing treatment in regard to cases of acute intestinal obstruction has been the cause of many deaths. This is due to the fact that the equivocal symptoms and signs of obstruction of the upper part of the small intestine are very like those of an incomplete obstruction. They are not at all like the typical text-book picture of intestinal obstruction. A patient comes into hospital with rather an acute onset of colicky pain not well localized, which is associated with a great deal of vomiting, and with constipation. His abdomen is fairly flat. He is comparatively well, has a normal temperature, and not a fast pulse. Enemas give encouraging results. There is very little to indicate that he has a complete obstruction. He is regarded as an incomplete obstruction. He is watched in the wards for two or three days; but finally becomes very ill. He is at once operated on, but the patient, rather unexpectedly, dies: he has had a complete obstruction of the upper part of the small intestine. The resident surgeon or the attendant doctor has had deeply engraved in his mind the typical text-book clinical picture of an intestinal obstruction—a picture of marked distension, complete constipation, and other typical signs.

PRE-OPERATIVE MANAGEMENT OF THE PATIENT

While the patient is under observation, and the question of operation is being considered, time should not be lost, but pre-operative treatment should be at once instituted. This takes the form of intravenous medication—the administration of fluid, glucose, and sodium chloride (*see* p. 764). By this means the fluid that the patient is losing by vomiting is replaced; the glucose keeps up his store of glycogen and therefore his nutrition, and affords him nourishment with which to withstand the operation after the starvation process resulting from the vomiting; the sodium chloride replaces his lost chlorides and prevents any alkalosis.

Much of the success of an operation for intestinal obstruction, and especially of small-intestinal obstruction, is dependent upon an adequate physiological pre-operative preparation of the patient.

THE OPERATIVE APPROACH TO A CASE OF ACUTE INTESTINAL OBSTRUCTION

The plan of the operative approach to a case of intestinal obstruction involves: (1) The choice of an anæsthetic; (2) The planning of the incision; (3) The relief of the obstruction; (4) The surgery of the obstructive lesion.

1. The Choice of an Anæsthetic.—Nothing is so important in the finesse of the operative treatment of a case of intestinal obstruction as the choice of an anæsthetic. If ether is administered there is the disadvantage that the patient may be vomiting and inhale gastric contents ; that it must be deeply given in order to relax the abdominal muscles so that the distended intestines will not prolapse when the wound is made, and such a depth of anæsthesia produces chemical shock. The use of nitrous oxide gas, although causing little shock, does not fulfil the main anæsthetic requirement because it does not relax the abdominal wall. The anæsthetic of choice is percaine zonal spinal anæsthesia—the method of Kirschner. Its advantages are that it can be localized to the abdominal part of the body only, and therefore that it does not cause much fall of blood-pressure ; that there is no danger of inhalation of vomited material ; that the abdominal wall is so relaxed that the intestines are not forced out, and indeed can be left almost undisturbed ; that the wound is easily closed ; and that it has, by its paralysing action on the sympathetic—its release action—a good effect on the emptying function of the intestine. (*See p. 473.*)

2. The Planning of the Incision.—The incision should be made over the site of the obstruction. The object of this is to avoid the shock caused by the evisceration and the handling of distended bowel, and also to obtain easy access for a radical operation.

Should, however, it not be possible to localize the site of the obstruction—a not infrequent occurrence—then this site should be determined by employing only a *small* exploratory incision, of the split-muscle type, made over the appendiceal region. Inspection through this incision will at once indicate broadly where the obstruction is situated. If the lower ileum is collapsed the small intestine is the seat of the obstruction ; if it is distended then the lesion is in the large bowel.

More exact information of the situation and also of the nature of the growth may be obtained if the gloved hand is vaselined and inserted through this small incision (*see p. 947*). The vaselined hand slips through the dilated coils causing very little traumatism. Where the ileum has been found collapsed, the vaselined hand should be directed towards the small intestine ; where distended it should be passed towards the large bowel.

The information sought will be : (1) the nature of the obstruction—whether malignant or otherwise ; (2) the site of the obstruction—information from which it is possible (*a*) to place the incision correctly, (*b*) to design the proper method of bowel drainage

operation which may be necessary for a malignant obstruction ; and (3) the operability (if malignant) of the obstructing factor—information for thought and future use in regard to the correct form of secondary operation.

Thus the information obtained from this small incision will clear up a doubtful situation. It will enable the surgeon, if he finds that immediate radical surgical intervention is necessary and the obstructional factor is inaccessible from the small incision, to place his incision directly over this obstructing element. In this way it will enable him to make the operation easy and to avoid the shock caused by the prolapse and handling of the distended coils.

As a rule, however, the surgeon will find that if the obstruction is in the small intestine he can manage the operation through this incision if it is enlarged.

At any rate, through either incision the surgeon will first seek collapsed bowel and trace it towards the obstruction. This collapsed bowel can be handled without disturbing the disposition of the dilated intestines. Handling collapsed bowel causes very little shock compared with that caused by handling distended bowel.

This small test split-muscle incision over the ileocæcal junction is the keystone of success in many an operation for intestinal obstruction of obscure origin where the patient is critically ill and where a rather badly planned operation would turn the balance against him.

3. The Relief of the Obstruction.—Many causes have been advanced for the quick death which very often follows an operation for acute intestinal obstruction, particularly when it is for obstruction in the upper part of the alimentary canal. Alkalosis, or toxic poisoning from bacteria or from proteolytic products, has been advanced as a cause of the deaths.

As I have watched the conditions which have led up to death in patients after operations for a high intestinal obstruction—patients who up to the operation had been comparatively well—I have been struck by the profound changes, out of proportion to the gravity of the operation, which quickly followed the operative procedure. It seemed to me that they were the result of a rapid decompression of the toxic pent-up fæcal stream. I have noticed that the patient's blood-volume decreases, for his pulse-rate rapidly rises and his blood-pressure rapidly sinks. Notwithstanding the fact that he may swallow large quantities of fluid, little of this appears to be absorbed into his circulation. I feel convinced, therefore, that a potent factor in these deaths is the rapid decompression that follows when the obtruded bowel is opened. The intestine is intensely

distended and its lymphatic vessels are flattened, and therefore it has probably lost much of its absorptive powers. When the obstruction is suddenly relieved it is possible that the lymphatics regain some of their absorptive powers and the patient becomes exposed to the poisoning of an enormous quantity of toxic products which has accumulated in the dammed-up fæcal stream. Following this absorption profound circulatory changes take place which may cause death.

Therefore the main principles in regard to draining the bowel should be: (a) A slow decompression (*see* p. 796); (b) An intravenous flooding of the circulation with fluid, glucose, and chlorides, no reliance being placed on absorption from the bowel.

The relief of obstruction when the lesion is in the large bowel is discussed in Part IV.

4. The Surgery of the Obstructive Lesion.—The first stage of an operation on a severe case of acute intestinal obstruction should be the institution of a continuous intravenous saline and glucose drip, as a precaution against any sudden relief of pent-up intestinal contents which may occur during the operation.

The actual surgery of the lesion will vary according to its position and nature.

In the Small Intestine.—

a. In the case of a strangulated coil special attention will be paid to the circulation and therefore the viability of the bowel, and if this is in doubt or gangrene has occurred, the coil will be resected.

b. In the case of a carcinoma, the affected segment of gut with its mesenteric leaf will be removed; but if the growth is inoperable an entero-anastomosis will be made.

c. An ileocæcal volvulus will be untwisted, and, to prevent a recurrence, the ileocæcal segment will be mobilized, its mesentery split, and a new broad peritoneal attachment given to it.

d. Obstructing bands will be divided.

e. An obstructing gall-stone will be removed by an enterostomy.

f. A tuberculous obstruction may require resection, or an entero-anastomosis may suffice.

In all cases where resection is carried out, an end-to-end or side-to-side anastomosis will be made, and if the obstruction is severe it will be combined with a small controlled enterostomy (*see* p. 795).

In the Large Intestine.—

a. The surgery of obstruction of the proximal and distal colon as a result of carcinoma or inflammatory tumours, is discussed in Part IV.

b. In the case of a volvulus of the sigmoid which has become gangrenous, or even where, from the conformation of the sigmoid and its mesentery, the volvulus is certain to recur, advantage can be taken of the long sigmoid mesentery to carry out, with little danger to the patient, a radical operation on Paul's principle.

POST-OPERATIVE TREATMENT

Not only is pre-operative treatment instrumental in saving lives in the management of a case of intestinal obstruction, but so also is post-operative intravenous medication important in the successful management of a case of intestinal obstruction. Indeed the pre-operative and post-operative treatment are as important as the operation.

The post-operative treatment of a case of intestinal obstruction is described in detail on p. 783 and therefore need not be repeated here.

CHAPTER LXXVI

APPENDICITIS : ANATOMY AND CAUSATION

ANATOMY

THE appendix is a residual organ. Its length varies from five to nine inches. It has in general the structure of the large bowel.

It is richly supplied with lymphoid tissue, which like that of the tonsil is vulnerable to infection. This tissue is most highly developed in youth ; a fact which explains the frequency of the occurrence of appendicitis in the earlier ages. The lymphoid tissue begins to atrophy in later life, when as a result the liability to appendicitis becomes less.

The mesentery contains the appendicular artery, a branch of the ileocolic, which passes behind the ileocolic junction.

Development of the Appendix.—The appendix is particularly prone to developmental errors and therefore to misplacements, and an appendicitis in each of these gives a characteristic clinical picture.

In the development of the proximal part of the colon and the appendix, there are five stages in which developmental errors can occur. These are :—

1. Rotation of the umbilical loop to the subhepatic position ;
2. Descent from the subhepatic position ;
3. Adhesion of the mesentery of the right half of the colon to the posterior abdominal parietes ;
4. Rotation of the right half of the colon towards its mesentery ;
5. Increased development of the anterior and lateral cæcal walls over the posterior and medial wall, thereby giving the appendix its usual position.

In consequence, the appendiceal misplacements commonly found may occur in the following ways :—

1. Adhesion is defective, the mesentery persists, and the colon descends unduly : the appendix is found in the pelvis.
2. Adhesion takes place very early and the cæcum does not descend : the appendix remains in a subhepatic position (*Fig. 593, A*).
3. Adhesion takes place or descent of the appendix is slow, and the cæcum and the appendix in their downward passage may be arrested in various positions : the appendix may become embedded in the perirenal fossa, arrested in a retrocolic, partly retrocolic,

retrocæcal, partly retroperitoneal and partly retrocæcal, subileal, or wholly retroperitoneal position.

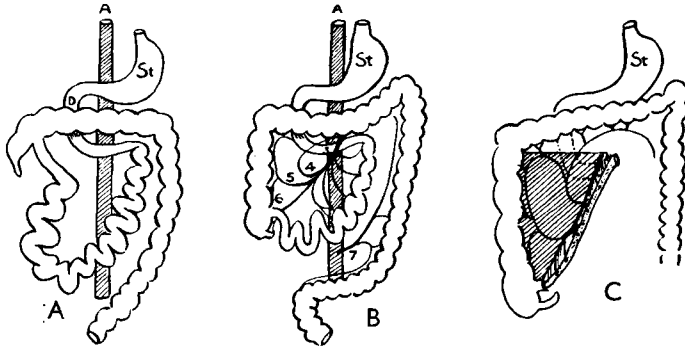


Fig. 593.—Stages in the development of the right colon and appendix. (After Huntington.) A, Rotation of umbilical loop, the ileocæcal junction attaining a subhepatic position. B, Cæcum has descended from the subhepatic area to the right iliac fossa. C, Area (shaded) of peritoneal adhesions which limit the attachment of mesentery and transverse mesocolon and anchor the cæcum and ascending colon.

4. The cæcum fails to rotate towards its mesentery: the appendix is placed at the right level, but is laterally situated.

5. The anterior and lateral cæcal walls fail to develop: the base of the appendix loses its usual relation to the ileocæcal junction,

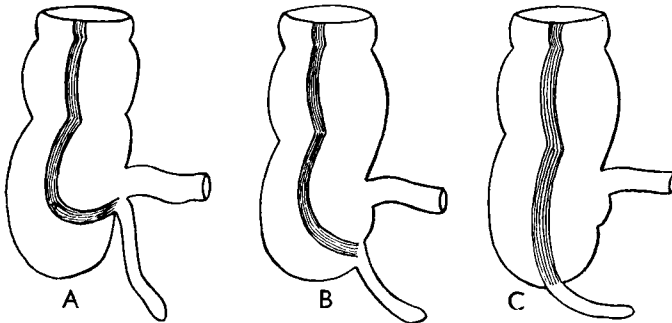


Fig. 594.—Shows the variation in the normal development of anterior and lateral cæcal walls so that the base of the appendix loses its normal relation to the ileocæcal junction. (After Huntington.) A, Preponderance of right cæcal pouch; base of the appendix is directly beneath the ileocæcal entrance. B, Greater development of right cæcal pouch; base of appendix is midway between the apex of the cæcum and the ileocæcal valve. C, Adult differentiation into appendix (distal half) and cæcum (proximal half); base of appendix near lip of cæcum.

and the appendix comes to lie on the terminal part of the cæcum or on its posterior wall (Fig. 594).

The Position of the Appendix.—The appendix may therefore be found in the following positions, each of which gives rise to a form of appendicitis with characteristic manifestations.

1. The usual position, below and to the inner side of the cæcum, occasionally hanging over the pelvic brim, but as a rule just above the brim more or less covered by the terminal ileum (*usual type of appendicitis*).
2. Deep in the pelvis (*pelvic appendicitis*).
3. Retrocæcal (*retrocæcal appendicitis*).
4. Laterocæcal (*appendicitis with renal manifestations*).
5. Extending under the terminal part of the ileum (*appendicitis with umbilical pain and other atypical symptoms*).
6. On the left side—that is, situs inversus (*left-sided appendicitis*).

CAUSATION

Many causes of appendicitis are given, and to discuss them in detail in a work of this description would serve no useful purpose. But regarded from the point of view of diagnosis and operative treatment, it will be of value if the causation of appendicitis is considered on that general pathological basis which underlies the infection of any living tissue. It will therefore be discussed in regard to the following different basic causative factors:—

(1) The infecting organism; (2) Predisposing causes arising as a result of peculiarities of structure or disturbances in the appendix itself; (3) Predisposing causes arising as a result of disturbances in general tissue vitality.

1. The Infecting Organism.—Clinical experience would go to show that the infecting organism arrives or arises enterally, rarely hæmatogenously.

There is no one infecting organism, no specific germ which causes an appendicitis. A germ which is foreign to the intestinal flora, and which is pathological, may arrive enterally and set up an appendicitis. A germ usually present in the bowel and unpathological may, in some peculiar way, become pathological and cause appendicitis. In an appendicitis an organism may be found in pure culture, but as a rule more than one type take part in the infection. The *B. coli communis* is generally a prominent participator, but it may be found in pure culture. The influenza germ, too, may be the sole infecting organism. In most cases, according to Altmeier,¹ *B. melanogenicum* can be isolated, often in symbiosis with an anaerobic streptococcus.

A knowledge of the nature and virulence of the infecting germ is of prime importance to the clinician, for this determines the kind of clinical picture. For instance, some forms of streptococcus are so virulent that they pass through the appendix, leaving toxic and insignificant inflammatory changes, and cause a rapidly spreading

general peritonitis. Others very rapidly cause an acute necrosis of tissue—a gangrene. Others again, though not so virulent, excite little defence reactive phenomena in the peritoneum, and spread by a series of circumscribed (unlocalized by reactive boundaries) areas of local peritonitis in various directions in the abdominal cavity, and there are still other types found, alone or in combination, which have little virulence, and depend for their power to produce an inflammation on local appendiceal predisposing causes arising as a result of peculiarities of tissue structure or disturbances of emptying in the appendix itself; or on a general deficiency of tissue vitality.

An appendiceal infection usually starts in the mucous membrane, and the inflammation which it causes may in a minor proportion of cases remain limited to this structure. In a majority of cases, however, it spreads to the walls of the appendix. It may begin as part of a cæcitis, but unlike the cæcum, in which an inflammation generally remains limited to the mucous membrane, in the appendix it nearly always spreads to all the coats.

2. Predisposing Causes Arising as a Result of Peculiarities of Structure or Disturbances in the Appendix Itself.—The appendix is mostly composed of lymphoid tissue which, like the tonsil, is vulnerable to infection.

Because of the general structure of the appendix—the firm tissue and the long narrow lumen—and the associated action of enteral proteolytic toxins, there is a very definite tendency for an inflammation to end in necrosis rather than resolution. Thus it is not correct to base the conservative treatment of an appendicitis on the assumption that it will follow a similar course to that of an inflammation in other tissue.

Because the appendiceal opening into the cæcum is provided with a valve which may be incompetent, congenitally narrowed, or become œdematous (from cæcal inflammation), the appendiceal contents, which normally empty much more slowly than the cæcum, may become retained, and this retention predisposes the appendix to become infected even by a poorly virulent type of infection.

Further, the appendix is liable to kinks and twists from misplacement, because the cæcum and ascending colon are prone to developmental errors, and the retention of contents so caused predisposes to infection. Thus, as there is often a familial tendency to developmental errors, we see why there may be a familial tendency to appendicitis.

In addition, the emptying capacity of the appendix is often affected by constricting scars, the result of partial necrosis from

previous attacks of acute appendicitis, rendering it liable to a retention infection.

There are, too, the disturbances in the mucous membrane of the appendix caused by the retention of fæcoliths, which by their constant irritating traumatism permit the entrance of an infection to the lymph-follicles.

It is in the last two types of appendiceal obstruction and retention—strictured appendix and retained fæcolith—that an appendiceal perforation (fulminating appendicitis) frequently occurs.

Thus it will be seen what a large role local predisposing conditions play in the causation of an appendicitis; and also how important a part a knowledge of these conditions should play, not only in diagnosis but also in operative treatment.

3. Predisposing Causes Arising as a Result of Disturbances in General Tissue Vitality.—Variations in general tissue vitality, which not only predispose to acute appendicitis but often alter its typical character, are seen in old age and extreme youth; in metabolic diseases, diabetes, gout, arteriosclerosis; and in anæmia or similar conditions. Any of these conditions may be an important though perhaps unsuspected factor in the causation of an appendicitis.

THE CLINICAL INFERENCES

From the way in which appendicitis is caused we may expect the following broad appendiceal clinical pictures: (1) An appendicitis of a virulent infection with stormy onset and course, with rapid local extension, and with profound constitutional symptoms; (2) An appendicitis of an exactly opposite character—one of a lowly virulent infection in lowly resistant tissues, with insidious onset, with a quiet course devoid of reactive phenomena, and with mild constitutional symptoms—the appendicitis of the old, the diabetic, or the arterio-sclerotic; (3) An appendicitis which may be of any grade between these extremes; (4) An appendicitis which is an expression of deficient resistance, when an organism which is a normal inhabitant of the bowel becomes the infecting agent; (5) An emergency appendicitis, when accidents—perforations, gangrene—occur in the appendix with crippling stenosing scars from previous attacks; (6) An appendicitis as an accompaniment, or as a residual infection, in exogenously produced enteral (cæcal) infections from infected food (often seen in camps and holiday resorts).

REFERENCE

- ¹ ALTEMEIER, *Ann. of Surg.*, 1938, April, 517, 634.

CHAPTER LXXVII

THE CLASSIFICATION OF APPENDICITIS

To emphasize distinctions in diagnosis and principles in treatment it is useful to classify the various forms of appendicitis into three groups into which clinically they naturally fall, as follows :—

Group I, based on *the degree of inflammation* (the appendix being situated normally).

Group II, based on *the outstanding effect of a causative factor*—*fulminating appendicitis*—peritonitic, gangrenous, or perforative.

Group III, based on *the situation of the appendicitis*.

The object of this classification is to throw into perspective certain important forms of appendicitis with a view to their early diagnosis and early operation.

Group I: **APPENDICITIS CLASSIFIED ON THE BASIS OF THE DEGREE OF INFLAMMATION**

In this group the appendix is in the normal position. There are three distinct grades: (1) Acute appendicitis; (2) Chronic appendicitis; (3) Very chronic proliferative or plastic appendicitis.

I. ACUTE APPENDICITIS

Under the title of acute appendicitis is included that form of the disease which is usually seen in practice. It is the one found in the average normal healthy person, in whom the appendix is in the normal position, and when the infecting germ is not of especially high virulence.

Causation of Deaths from Acute Appendicitis.—Acute appendicitis is responsible every year, in every country, for a surprisingly large number of deaths—many of which could have been prevented: in Australia (1936), 554 deaths¹; in England and Wales (1936), 2869 deaths²; in Scotland (1936), 433 deaths; in Switzerland, 500 deaths; in the United States of America (1936), 16,480 deaths.³

The causes of many of these deaths will fall into one of the following categories :—

a. The patient does not report to the medical man in the early stages of the illness.

b. The patient does report the illness to a medical man, but it is an appendicitis in an appendix in an abnormal position, or of an abnormal type giving rise to equivocal symptoms, and is not recognized in its early stages.

c. The patient is lacking in general resistance; and because of this there are poor reactive phenomena—fever, pain, reflex manifestations—so that the disease is not recognized in its early stages.

d. The infecting germ is of high virulence and no reactive phenomena on the part of the body can limit it, so that a general peritonitis develops; or the virulence is of such a peculiar nature that it does not excite protective reactive phenomena, and the infection spreads in the peritoneal cavity.

e. The type of appendicitis is perforative or gangrenous; and the symptomatic quietude—the *rémission trompeuse* (see p. 845)—immediately following the stage of gangrene or perforation misleads the patient, his family, or his family doctor.

The Early Diagnosis of Acute Appendicitis.—From the point of view of successful surgical treatment of acute appendicitis, its early diagnosis is most important. As a rule the usual clinical manifestations of acute appendicitis are now so well known that, if the inflamed appendix is in its normal position, no difficulty is experienced in making an early diagnosis. But in the acute appendicitis which occurs in the abnormally situated appendix, when the clinical manifestations are generally anomalous, considerable difficulty is experienced in recognizing the condition in its early stages and a diagnosis is often made late. Anomalous forms of acute appendicitis, too, are most difficult to recognize in their early stages, and are the cause of many failures to make a prompt diagnosis.

Thus it will be not only of practical diagnostic but of therapeutic value to deal with the usual manifestations of acute appendicitis in a routine way, and to throw the emphasis of the discussion on to the unusual features of the anomalous acute forms.

The Usual Clinical Manifestations of Acute Appendicitis (the appendix being in the normal position).—Sudden onset of more or less severe abdominal pain is the striking characteristic of most cases. Sometimes the attack occurs on the immediate background of some ill health—a failure of appetite, a feeling of not being well, a dyspepsia, and a constipation. But it is more characteristic of appendiceal pain that it arises on a background of perfect health.

An onset of sickness or vomiting definitely preceding pain usually indicates an affection other than acute appendicitis.

The pain may be situated at first in the epigastrium, but usually it soon localizes in the right iliac fossa. This sequence of epigastric pain and right iliac fossa pain is indicative of appendicitis. Pain may also be present in the region of the umbilicus—probably referred from the small intestine as the result of the spread of the inflammation to the lower end of the ileum.

The pain may be recognized as arising from a visceral rather than a skeletal lesion by the fact that it is associated with nausea, vomiting, sweating, and a rising pulse-rate; that is, it is accompanied by manifestations of *peritonism*.

In some cases the pain may be entirely epigastric. I have seen a patient with a gangrenous appendix who complained of only a severe attack of epigastric pain, and who, on account of this, was regarded as suffering from an acute gastric affection.

In children, diffuse umbilical pain may be the sole painful manifestation of an appendicitis, and on account of this appendicitis in children sometimes remains unrecognized.

An onset with *agonizing pain* is of significance. It means, as a rule, that the patient has a *severe attack of appendicitis*. *Sudden relief* from such a pain does not mean that the inflammation is subsiding: severe pain means severe inflammation, a condition which could not get better in a few hours; and sudden relief is usually a danger sign indicating either the onset of gangrene or the occurrence of a perforation.

Sudden relief, however, may be due to the emptying of an intra-appendiceal accumulation of retained secretion or pus through the appendiceal lumen into the cæcum.

Early in an attack of appendicitis the bowels become constipated, the tongue furred, and the breath emits the easily recognizable characteristic odour of an infective bowel condition; but an appendicitis can occur without any of these manifestations.

With the above clinical manifestations are associated more or less severe *constitutional symptoms* and signs—evidences of fever, as rise in temperature and increase in the pulse-rate, together with evidence of toxic absorptions, and of disturbance of the secretory processes.

A *leucocytosis* is usually present, and is of value in distinguishing the onset of some forms of acute appendicitis from that of typhoid fever.

Localized tenderness is a most reliable sign of appendicitis. The persistence of a 'deep tender spot', even after the other symptoms have disappeared, is also characteristic.

Acute Appendicitis Occuring as a Residual Affection in Acute Colitis.—An acute appendicitis may come on during the course of acute colitis resulting from a food infection, often seen in holiday resorts in hot weather. In such a case, the acute appendicitis is a residual infection. It comes on about the third or fourth day after the onset of the colitis, just when the colitis is clearing up and the attending medical man is not on the alert. Because it occurs on the background of a clinical picture of colitis, and since the onset of the patient's illness is with diarrhœa, it is liable to remain unrecognized. Further, the onset of the appendicitis in a clinical picture of general abdominal pain and tenderness is not noticed. For example :—

A woman, aged 45, who had been swallowing pus from a tooth extraction which had become septic, became ill with diarrhœa, general abdominal tenderness, and colicky pains. About the third or fourth day the symptoms began to clear up, but her tongue then became much more furred and her tenderness became localized to the right side. About the sixth day it was obvious that she had an acute appendicitis.

Operation disclosed that she had had a colitis and an acute appendicitis.

The acute appendicitis had developed as the colitis was improving, possibly a residual infection in the vulnerable lymphatic tissue of the appendix.

Mild Types of Acute Appendicitis.—The clinical picture of acute appendicitis above described is that of the usual type in which an infection commencing in the mucous membrane rapidly involves the whole wall of the appendix—an appendiceal phlegmon. There is, however, a small proportion of cases in which the inflammation never spreads beyond the mucous membrane, that is, there is a mild form of acute appendicitis. In these cases the pain may cease when the inflammatory secretion empties into the cœcum. There is little tenderness or rigidity because the peritoneal layer of the appendix is unaffected. Such cases usually resolve.

Termination of Acute Appendicitis.—The course of acute appendicitis is broadly that of an ordinary inflammation ; and it may proceed in any one of the following ways :—

- a. It may begin to resolve on the fourth or fifth day.
- b. If it does not resolve it may go on to abscess formation.
- c. If the germ is virile or the patient's resistance is low, the infection, without becoming in any way localized by reactive processes, may spread through the appendix to the peritoneum and cause either a circumscribed or a general peritonitis. This becomes obvious by the extension of rigidity and tenderness, the onset of distension, the onset and progress of a constipation—not always complete—the onset

of nausea and vomiting, the rapid deterioration of the patient's well-being, and the onset of symptoms and signs of a collapse.

d. The inflammation may end in necrosis—gangrene (rather a special tendency because of the anatomical structure of the appendix).

Mistakes in Diagnosis.—There are many unjustifiable mistakes made in regard to the diagnosis of acute appendicitis which need not be considered. But there are also mistakes made in regard to conditions which give a severe appendicitis-like pain and sometimes lead to an operation for acute appendicitis, in which the appendix is innocent, and these are considered below :—

a. Stone in the Lower Part of the Right Ureter.—

A famous cricketer was operated on for symptoms similar to those of acute appendicitis—attacks of acute pain in the appendiceal region. His symptoms recurred. He was reoperated on for ‘ adhesions ’. It was then noticed that every time he batted his attack of pain came on with also some pain at the tip of the penis and a desire to micturate—presumably the result of a violent movement.

A radiograph showed that he had a small irregular stone (radiographically demonstrated with some difficulty) in the lower part of his ureter.

b. Lumps of Lymph from a Tuberculous Kidney passing down the Right Ureter (tuberculous kidney—bladder and ureters not involved).—

A nurse was operated on by a surgeon for symptoms similar (as he thought) to those of acute appendicitis. Her symptoms recurred. He then operated on her for a supposed salpingitis. Her symptoms again recurred. Then one day she brought to him a specimen of urine which was like milk : she had a tuberculous right kidney, and the pain was due to passage of lymph masses down the ureter.

c. Obstruction of the Distal Colon by a Malignant Growth.—Frequently a symptom of obstruction of the sigmoid is rather acute pain over the cæcal region (*see* p. 907).

d. Early Carcinoma of the Ileocæcal Valve.—Carcinomatous obstruction at the ileocæcal valve often gives rise to severe right-sided pain which can be mistaken for that of appendicitis (*see* p. 892).

e. Painful Ovulation of the Right Ovary.—Pathological anatomical disturbance in the right ovary causing painful ovulation may lead to a mistaken diagnosis of acute appendicitis.

f. Salpingitis and Tubal Pregnancy in the Female.—These conditions are frequently confused with acute appendicitis.

g. Meckel's Diverticulum.—

A patient was operated on for supposed acute appendicitis. His symptoms recurred. Reoperation showed that he had a Meckel's diverticulum to which a wad of fat was attached ; and that this had become intussuscepted and was travelling up and down the terminal part of the ileum, giving rise to acute right-sided abdominal pain.

h. Intermittent Torsion at the Ileocæcal Junction.—I have seen cases which have been operated on for a supposed acute appendicitis where a partial volvulus at the ileocæcal junction (unrecognized at the operation) was the cause of the severe right-sided pain.

i. Diverticulitis.—Cases occur in which a long sigmoid with acutely inflamed diverticula lies on the right side and causes a symptom-complex clinically indistinguishable from acute appendicitis (see p. 921).

j. A Low Right Kidney.—In the female a low right kidney with intermittent attacks of hydronephrosis gives acute pain and tenderness in the lower right quadrant.

k. Twisted Omentum.—

A patient developed a sudden severe pain in the lower right quadrant of the abdomen. He had a tender spot and an area of rigidity below and to the left of the appendiceal region. At operation an area of twisted and hæmorrhagic omentum was found under the tender spot.

l. Acute Ileocæcal Lymphadenitis.—

A boy of 12 developed severe pain in the vicinity of the umbilicus. His temperature was 103°, and pulse-rate 100. He had no disturbance of his bowel function. His tongue was not dirty. He had a tender spot above and to the right of the umbilicus. During the previous year he had had several attacks of abdominal pain lasting for a day or two. Except for the rather high position of the local 'deep tender spot', he presented a typical picture of acute appendicitis.

At operation very large lymph-glands in the mesentery of the small intestine and in the vicinity of the appendix were found. The appendix was not obviously inflamed. Microscopical examination did not reveal any evidence of tuberculous infection.

m. Abscess around a Cæcal Carcinoma.—The abscess occasionally found round a cæcal carcinoma is only distinguished from that seen in the vicinity of a chronic plastic appendicitis by differences in the clinical history and radiographic appearances.

n. Acute Colitis.—Acute colitis causing abdominal pain and diffuse right-sided tenderness may be mistaken for an acute appendicitis. This mistake, however, is not so important as the opposite mistake when the symptoms of acute colitis conceal those of an acute appendicitis. For example :—

A hospital surgeon accustomed to operating on cases of appendicitis became ill with a severe attack of diarrhœa. There was a diffuse, not severe, abdominal pain situated more on the right than on the left side of the abdomen, and he sweated profusely. He had little tenderness and only a slight fever. Nothing would persuade him that he had an acute appendicitis; but he had a retrocæcal appendicitis at least five days old.

Other similar mistakes in diagnosis may be made in cases of an inflamed lowly situated gall-bladder, twisted or suppurating ovarian cyst, root pains from an osteo-arthritic spine, tuberculous peritonitis, typhoid fever, pneumococcal peritonitis, regional ileitis.

2. CHRONIC APPENDICITIS

In most cases what is called chronic appendicitis is really not the result of an inflammation but that of a mechanical disturbance associated with the retention of a fæcolith or following the obstruction of the appendiceal outlet and the emptying of the appendiceal content—an obstruction which is usually caused by a healed and contracted scar, the sequel of necrosis and loss of substance from a previous acute appendiceal lesion.

But there is also a definite chronic appendicitis—a chronic smouldering inflammation of the lymph-tissue of the appendix—manifestations of which are some nagging pain and a ‘deep tender spot’ over the appendiceal area; that is, there are indications of a true chronic appendicitis.

There is, too, a chronic appendicitis associated with a low-grade cæcitis (from stasis and other causes), in which the appendix participates as a result of incompetence or œdema of the valve guarding the entrance to the appendiceal lumen.

3. PROLIFERATIVE OR PLASTIC CHRONIC APPENDICITIS (‘*Chronic Appendicitic Tumour*’)

There is an extremely chronic form of appendicitis in which the infection produces proliferative changes, and these in turn produce a tumour almost like that seen in chronic inflammatory diverticular tumour, or in the ‘ulcer tumour’ occasionally observed in association with chronic gastric ulcer (*see also* p. 895).

The practical importance of recognizing this type lies in the fact that it is not infrequently mistaken for a carcinoma of the cæcum.

These cases of ‘chronic appendicitic tumour’ are often seen in old people, where an inflammation of low grade—possible in the enfeebled tissues of the aged—occurs in an appendix which has become invaginated into the wall of the cæcum. In such cases a tumour of the size and appearance of a well-advanced carcinoma of the cæcum is the result. The tumour formation is the main feature; and the mass feels hard, irregular, and fixed, and just like a carcinoma of the cæcum. This malignant-like appendiceal tumour is usually encountered at operation, when it is regarded as an inoperable carcinoma

of the cæcum because it is large, hard, irregular, and firmly bound to the posterior abdominal wall.

The mild constitutional symptoms caused by these tumours—slight rise in temperature and some loss of health—usually pass unnoticed. The tumours usually exhibit little tenderness.

Occasionally these slowly developing 'chronic appendicitic tumours' invade the abdominal wall, the muscle layers of which become fused together into a more or less homogeneous mass. Incision may show small points of pus distributed through the tumour. Even after wide incision the tumour clears up very slowly, and it may be three or four months before resolution takes place. In such a condition the removal of the appendix is of course impossible.

The following are illustrative cases :—

A man, aged 60, was well until six months before admission to hospital when he became sick and began to feel a pain in the region of the right iliac fossa. This pain became worse and he began fairly rapidly to lose health. He became cachectic, his tongue became dirty, and his bowels constipated—all manifestations of a progressive malignancy. A few days before admission to hospital he became worse and had a temperature of 103°. When examined, a large firm tumour in the region of the appendix could be felt. This mass was thought to be a carcinoma of the cæcum associated with some surrounding inflammation.

At operation, a carcinoma-like mass was found. The surgeon did not attempt to remove it because he regarded it as inoperable carcinoma of the cæcum.

On further examination, however, it was noticed that, although the tumour was fairly large, the radiographic appearance of the barium-filled cæcum did not show anything like the deformation of the cæcal wall that should have been caused by a carcinoma of the size and with the invasive properties that the clinical examination would indicate. Consequently, notwithstanding the hopeless outlook that had been given, another operation was undertaken, when an appendix embedded in the mass and lying paracolically was with great difficulty removed.

A woman, aged 67, complained of moderate pain in the right iliac fossa. The pain was followed by constipation, and soreness over the appendiceal region. She also complained of nausea and anorexia.

Examination showed that she had a firm hard tumour which felt exactly like a carcinoma. No filling defect showed in the radiograph of the cæcum. At the operation, through the middle of the ascending colon could be felt a hard mass which was apparently in the posterior abdominal wall, and with which a little œdema was associated. It appeared to be almost certainly a carcinoma. However, the peritoneum was divided on the lateral side of the cæcum and the whole cæcum and ascending colon delivered. It was then found that the tumour was caused by a very chronically inflamed appendix round which great proliferation of cellular tissue had taken place, the appendix being deeply embedded in the posterior wall of the cæcum. The appendix was removed.

Group II: APPENDICITIS CLASSIFIED ON THE BASIS OF THE OUTSTANDING EFFECT OF A CAUSATIVE FACTOR

FULMINATING APPENDICITIS

A fulminating appendicitis, as its name implies, is a form of appendicitis so acute that it is of a catastrophic nature—it is an *acute abdominal emergency*.

It may arise as the result of the extreme effects of one or other of the main causative factors, and therefore occurs in one of the following ways:—

1. As a result of the intense virulence of the germ, causing either (*a*) rapidly spreading general peritonitis, or (*b*) death of tissue—a gangrenous appendicitis.

2. As a result of (*a*) disturbance in general tissue resistance, such as occurs in the senile, alcoholic, diabetic, or gouty subject, or in the anæmic, overworked, or ill-nourished patient; or (*b*) as a result of a disturbance of tissue nutrition in the appendix itself following deficient arterial blood-supply—in all these conditions even an average type of infection may cause a gangrenous appendicitis.

3. As a result of defective emptying of the appendix and retention of secretion due to stricture or following ulceration caused by a retained fæcolith—in these circumstances the addition of infection may cause a perforative appendicitis.

Rapidly Spreading General Peritonitis.—In some cases (happily rather rare), whether resulting from the extreme virulence of the organism (streptococcus), from the patient's poor resistance, or from an unfortunate combination of both, an infection may spread through the appendix, leaving very little inflammatory trace, and cause a peritonitis that spreads from hour to hour—a fulminating peritonitis—and finally becomes generalized.

The clinical picture is that of a rapid onset of profound collapse and of evidence of a rapidly spreading inflammatory process in the abdominal cavity—a picture only too easy to recognize, but one the cause of which is less easy to diagnose, because distinguishing localizing signs of its appendiceal cause may be indefinite and evanescent.

Gangrenous Appendicitis.—As a rule a gangrenous appendicitis comes on with very severe pain—with a stormy onset. The pain may be situated first in the epigastrium and then in the right iliac fossa.

The patient has all the symptoms of acute peritonism: he vomits, he becomes shocked and sweats, and his pulse-rate rises. His temperature may or may not increase.

After twelve to eighteen hours he experiences a period of great relief—his pain disappears, his fever abates, his pulse-rate becomes slower, but his tongue may remain furred. The patient now feels quite comfortable, but he looks pale and very ill. There is little evidence now of the presence of an acute appendicitis: perhaps only a slight rigidity and the least tenderness.

This is the 'silent' but dangerous interval, the period during which gangrene is taking place—the *rémission trompeuse*.

Very soon the whole picture rapidly changes—the pulse-rate rises quickly, the temperature also rises momentarily, only to fall later, and thenceforward there is the ever-increasing ominous divergence between the pulse and temperature curves.

The abdomen now becomes generally rigid, but does not become board-like. At first the rigidity is more on the right side than on the left and more in the lower part of the abdomen than the upper: there is, as it were, a definite march of the rigidity—a very informative sign. This is the period of a developing peritonitis.

The patient begins to vomit incessantly, and soon the vomiting and the vomitus are characteristic of peritonitis.

Enemas elicit no fæces, but perhaps a little flatus; that is, the patient is not absolutely constipated, at any rate during the middle stages of the condition.

The diagnosis is made on the stormy onset with great pain, the sudden relief, the rapidly generalizing rigidity, and the quickly developing collapse.

But gangrenous appendicitis does not always begin with the stormy onset which is usually seen in the patient with a more or less normal resistance, in whom as a rule the main cause of the gangrene is a virulent infection: it may arise insidiously. There is a type of gangrenous appendicitis in which the main cause of the gangrene is presumably the predominance of some defective tissue resistance. Such a gangrenous appendicitis is seen sometimes in the diabetic, the alcoholic, or the arteriosclerotic subject. In such cases, the onset is so mild that not only a gangrenous but even an acute appendicitis is not recognized. For example:—

A man, aged 60, who for years had drunk whisky to great excess, and who was obviously an unhealthy person, became sick at four o'clock on Friday with a mild pain in the lower part of the abdomen. His doctor thought he might possibly have appendicitis; he was not sure.

I saw him at four o'clock on Saturday and then he had no pain and no tenderness. His abdomen was so soft that I could sink my hand into it down to the posterior abdominal wall. His pulse-rate was 70 and his temperature normal, but his tongue was very furred. I felt quite certain

that anyway he had not an appendicitis severe enough to need operation, especially in such a bad subject.

By four o'clock on Sunday he had a well-established peritonitis.

Operation showed a wholly gangrenous appendix. The patient died.

I have seen the same kind of comparatively quiet onset of gangrenous appendicitis in diabetic subjects and in arteriosclerotics.

Acute Perforative Appendicitis.—In a case of acute perforative appendicitis, the patient is likely to have had previous attacks of appendicitis; for this type of appendicitis is frequently seen in the strictured appendix, with retained secretion, which results from previous inflammatory attacks, or where a retained fæcolith ulcerates its way through a dilated and thin-walled appendix.

In the perforative form of appendicitis an onset with intense pain is an outstanding feature—the inflammation in the strictured appendix with pent-up contents causes great tension and therefore intense pain. This tension gives rise to a high fever, and the patient may register a temperature of 104° . Then the perforation occurs and the patient experiences intense relief. Now follows a period of comfort—the 'silent' but dangerous interval similar to that in gangrenous appendicitis—the *rémission trompeuse*. This interval is followed by the symptoms and signs of an oncoming general peritonitis, when the temperature falls, the pulse-rate increases, the patient begins to vomit frequently, the bowels become obstinately constipated, and the abdomen begins to distend and to become generally tender and rigid.

Where the perforation occurs in a normally situated appendix it may at first sight be difficult to decide whether the perforation is in the upper or lower part of the abdomen—important knowledge from the point of view of treatment. As a rule, however, if the actual onset is studied, there will be found a very definite localization of symptoms and signs in the right lower quadrant of the abdomen.

Where, however, the perforation occurs in a pelvically situated appendix, these localizing manifestations are absent, and the symptoms and signs are those of an intestinal obstruction or a spreading peritonitis of unknown origin, which, unfortunately, only too often is surgically attacked—usually with dire results—in the belief that it is a case of true mechanical intestinal obstruction (*see p. 849*).

Group III : APPENDICITIS CLASSIFIED ON THE BASIS OF ITS SITUATION

As was pointed out in the previous chapter, the appendix, owing to developmental errors, may be anomalously placed. The clinical picture of an acute appendicitis in these anomalous situations is

different from that of an appendicitis in the normal position; and therefore an inflammation of an appendix situated in an abnormal position is frequently the cause of symptoms which are often not recognized as those arising from an acute appendicitis until a late stage of the disease, when operation may not avail. Consequently, appendicitis may with advantage be classified according to its abnormal situation as follows: (1) Pelvic appendicitis; (2) Subhepatic appendicitis; (3) Retrocæcal and retroperitoneal appendicitis; (4) Left-sided appendicitis; (5) Subileal appendicitis; (6) Appendicitis in a femoral hernia.

I. Pelvic Appendicitis.—Pelvic appendicitis is an acute inflammation of an appendix which has descended to and lies on the floor of the pelvis.

Looking back over my own experience in regard to acute appendicitis, one fact stands out, and that is the number of deaths which have been caused by pelvic appendicitis.

The deaths which occur in an appendicitis in this position are caused in two ways. In the first, the pelvic appendicitis, because of its anomalous symptoms, is frequently not recognized till late in its course. In the second, the operation for the removal of the appendix is a difficult one in this situation, and a surgeon unversed in the art of dealing with such an appendix not only endangers the patient by his strenuous efforts to remove it (often unavailing), but spreads the infection.

Some general characteristics of a pelvic appendicitis (not always constant) are the following: (*a*) Its 'silent' onset; (*b*) Its protean syndromes; (*c*) The absence of tender points; (*d*) The absence of reflex abdominal signs; (*e*) The presence of bladder and rectal symptoms—frequency of micturition and tenesmus; (*f*) The occasional onset with left-sided symptoms and signs; (*g*) The not infrequent onset with all the manifestations of a true mechanical intestinal obstruction.

In order to emphasize the surgical importance of the phases of pelvic appendicitis, I shall relate a series of histories—nearly every one of which has been more or less of a catastrophe.

Indefinite Abdominal Pain.—So indefinite may be the pain of a pelvic appendicitis that its appendiceal origin may not be recognized.

A doctor became ill with an indefinite, unlocalizable, not severe abdominal pain. Pressure on his hypogastrium elicited epigastric pain. He had no other indication of an appendicitis. A delayed operation showed that he had a severe pelvic appendicitis. His convalescence was stormy.

'*Silent*' *Pelvic Abscess*.—A pelvic appendicitis with a sequential abscess may arise so quietly that no attention whatever is attracted to the local condition.

A woman, aged 22, had been in a medical ward for three weeks. She suffered from very bad headaches, and ran a high temperature; that is, she had a septic condition for which no local focus could be found. She had had no pain. Her abdomen appeared perfectly normal and soft and disclosed no tender point. No one thought of examining the pelvis. A pelvic examination disclosed the fact that she had a large pelvic abscess. Operation showed that it was the result of a pelvic appendicitis.

Symptoms of a Septic Nature without any Other Symptoms of an Appendicitis.—A pelvic appendicitis not infrequently turns out to be the source of a septic focus which has been the object of a long search.

A nurse, aged 45, complained that she had suffered for twelve months from what she called "septic attacks". An attack would last for two or three days, and during this period, her temperature would rise, she would get a headache, and sometimes she would have a slight shiver.

She had been much investigated with the idea of finding her septic focus, and her symptoms were regarded as being caused by a gall-bladder infection.

Operation revealed a very long appendix, with a large walnut-sized bulbous tip which lay in the pouch of Douglas, and which contained a pocket of pus. The pus in the appendix apparently emptied periodically through the appendiceal lumen into the cæcum.

Pelvic Appendicitis Giving Rise to Left-sided Symptoms.—It is most important to recognize that a pelvic appendicitis (perhaps more frequent in women because of the frequency of enteroptosis) can cause only left-sided symptoms. The importance of this lies in the fact that these symptoms, on the assumption that they are caused by a diverticulitis or a salpingitis, are not seriously regarded, or, as in the following case, are not recognized as of appendiceal origin:—

A woman, aged 58, became ill with severe pain in the left iliac fossa. She did not vomit or sweat. Her temperature was 100.8° and her pulse-rate 115. Her tongue was very dirty. The abdomen was so soft and flat that the posterior abdominal wall could be easily felt. There was definite tenderness in the left groin but no tenderness whatever over the appendiceal region. On vaginal examination, she was tender in the left fornix. In eight hours her tongue became more furred, the pulse-rate increased to 120, the abdomen became slightly fuller, and the tenderness extended somewhat to the right, but there was still no tenderness over the appendiceal region.

Twelve months previously she had had a somewhat similar illness, when she was confined to bed for six weeks. She was so sick that she nearly died. At that time she was tender on the left side, had a considerable amount of distension, and her temperature ranged from 102° to 103° for many weeks. At the height of her illness she discharged a large quantity

He had normal bowel movements. On the eighth day of his illness he was still vomiting but had no pain. His bowels, however, were now beginning to become constipated and still the surgeon never thought of appendicitis—probably because of the absence of pain. But a rectal examination revealed an inflamed tender mass in the pelvis—a pelvic appendiceal abscess. From this time on the patient's abdomen became rapidly distended, and, previously free from any tenderness, it now exhibited tenderness in the *right iliac fossa*, but only slight and only on deep pressure.

The patient's temperature, which had been 99° on the seventh and eighth days, now dropped to 95° and 96°.

Operation, undertaken far too late, revealed a pelvic appendicitis with a pelvic abscess. The patient died.

In this case the continuous vomiting, the absence of noticeable pain or tender points, and the almost normal function of the bowel in the early part of disease were the misleading features.

Pelvic Appendicitis Causing Chronic Intestinal Obstruction.—An acute pelvic appendicitis can, as has been pointed out, occur so anomalously that it is not diagnosed. Then as it becomes partially cured by natural processes it may, as a result of the curative contractive processes, set up the symptoms of a chronic intestinal obstruction, which are very naturally mistaken for those of an obstruction by carcinoma.

A man, aged 56, had been sick for eighteen months, complaining of attacks of pain which would come on quite suddenly at irregular intervals. The pains would extend across the abdomen about the level of the umbilicus and sometimes down to the left side.

During the attacks he had no fever or rise in pulse-rate; but they were so severe that each time he required hospital treatment, when enemas and other measures for intestinal obstruction relieved him. At no time was he ever tender over the appendiceal region. One significant fact, however, was that at the onset of each attack his tongue became very furred and remained so for a week or longer.

His condition was eventually diagnosed as chronic intestinal obstruction, of probably malignant origin. Operation revealed a long chronically inflamed appendix lying on the floor of the pelvis, with perforation around which a chronic abscess encapsulated by adherent loops of small intestine had formed.

Pelvic Appendicitis Simulating Carcinoma of the Sigmoid.—Occasionally a pelvic abscess, 'silent' in its early stages, may first attract attention by pain and tenderness on the left side as the pus rises into the abdomen in the region of the sigmoid. When such an acute condition subsides somewhat, a tumour may form in the sigmoid region and may be mistaken for an inoperable carcinoma of the sigmoid. The following case-history is an instructive example of such a mistake.

A very ill-looking man, aged 50, presented himself with a letter from a doctor. In the letter the doctor wrote : " This patient has a large, hard, irregular, fixed tumour situated in the region of his sigmoid colon. . . . He has lost a lot of weight and has become very constipated. . . . I feel sure he has an inoperable carcinoma of his sigmoid. . . . I have told him that I think operation is inadvisable, but that I would like your opinion " .

In going over his history, I noticed that three months previously he had suffered from a very severe abdominal pain which made it necessary for him to stop work for the day. Feeling better next morning he had gone to work. Up to this time he had been perfectly well. This, he said, was the onset of his trouble, and from this on he had steadily " gone downhill " .

I had no doubt in my own mind that the tumour that could be felt in his sigmoid was a carcinoma of the sigmoid and inoperable ; but feeling there might be an inflammatory element, with much diffidence I suggested an operation.

I found a most interesting condition. After a difficult dissection I uncovered an inflammation of the last inch of his appendix, which was situated deep in the pelvis. A small abscess had formed round this and pus had spread into the retroperitoneal plane and passed up in a plane posterior to the sigmoid. The malignant-like tumour felt in the sigmoid region was a chronic abscess cavity with walls nearly half an inch thick, situated behind the sigmoid colon and containing about a tablespoonful of pus.

Pelvic Appendicitis [Causing Symptoms of Chronic Intestinal Obstruction and a Carcinoma-like Tumour of the Cæcum.—Not only can a chronic pelvic appendicitis give rise to a malignant-like tumour of the sigmoid, but it can cause a similar pseudo-malignant tumour of the cæcum, as for example :—

A man, aged 50, had been complaining for three months of colicky pains associated with distension and severe constipation.

He had had no rise in temperature or increase in pulse-rate ; but he had lost weight, health, and strength, and had a general cachectic appearance suggestive of malignancy. Clinical examination revealed the fact that he had a hard, irregular, nodular tumour in the right iliac fossa.

Radiographic examination revealed gross obstruction of the last part of the small intestine.

A diagnosis of ileocæcal carcinoma was accordingly made.

At operation a pelvic appendicitis, which, becoming chronic, had formed a hard inflammatory tumour extending up into the ileocæcal region, was found to be the cause of the obstruction.

Chronic Perforative Pelvic Appendicitis Causing Diverticular-like Tumour.—An acute perforative pelvic appendicitis eventually settling down into a subacute or chronic condition can produce an obstructive inflammatory tumour which is indistinguishable from a chronic obstructive diverticular tumour.

A woman, aged 65, fat, pale, and sick-looking, with a blood-pressure of 180 mm. Hg, had been ill for six months.

Her illness started with an attack of pain in the left iliac region. She had had many of these attacks; the last had occurred three weeks ago and had been so severe that she had consulted a doctor. In these attacks the pain in the left iliac fossa came on suddenly and was accompanied by vomiting. Her temperature fluctuated between 101° and 99° . She became constipated and had to have enemas. Some frequency of micturition developed. She was very tender over the left lower part of the abdomen. Her leucocytes varied between 10,000 and 16,000. She had a ballooned rectum and a mass could be felt with the tip of the finger. This mass appeared to be something around the lower part of the sigmoid, but not in it.

A barium clysma showed a very indefinite filling defect, which was diagnosed by the radiologist as undoubtedly a diverticular tumour or carcinoma—probably the former.

At operation it was found that the cæcum was ptosed and extended over to the left side and lay alongside the terminal part of the sigmoid, to which it adhered. A fairly large, firm tumour occupied the lower part of the sigmoid. This was seen to be an inflammatory condition—a perisigmoiditis. On separating the firmly attached cæcum from the sigmoid, there was found an old, very much inflamed appendix, which had perforated at its base and liberated a fæcolith around which there was about half a drachm of pus. The tumour was therefore a pelvic inflammatory appendiceal tumour.

Her doctor, a most excellent diagnostician, said after the operation: "The possibility of appendicitis being the cause of the patient's trouble never even entered my mind."

Pelvic Appendicitis in a Female Child Simulating Pneumococcal Peritonitis.—Cases of acute pelvic appendicitis sometimes occur in female children, and when they do they are not infrequently mistaken for pneumococcal peritonitis and the true nature of the condition is not recognized till operation is of no avail.

2. Subhepatic Appendicitis.

Acute Subhepatic Appendicitis.—An acute appendicitis in the undescended appendix—subhepatic appendicitis—presents a serious problem. The following case is an example:—

A man, aged about 35, was seized with acute pain over the region of the gall-bladder. His temperature and pulse-rate rose. He vomited a good deal, and in three days he had become very ill. His tongue was very furred. The diagnosis made by his doctor was 'gall-stones'. Basing his treatment on the fact that an acute cholecystitis usually mends, the doctor advised no operation. The patient became very ill.

Operation revealed suppurative subhepatic appendicitis.

Chronic Subhepatic Appendicitis.—The symptoms of chronic or subacute appendicitis in the subhepatic situation may be confused with those of cholecystitis or with some renal condition. The following case-history is an illustration of such a happening.

A patient had been ill for years, suffering from agonizing attacks of pain situated in the right hypochondrium and in the vicinity of the umbilicus, and lasting two or three days.

Associated with this pain was a hyperæsthesia so acute that the abdomen in the region where the pain was felt could not be touched.

Attacks of vomiting, nausea, and retching followed the onset of the pain. The patient had had two severe attacks of hæmaturia, and these were associated with similar attacks of vomiting and pain. He was tender

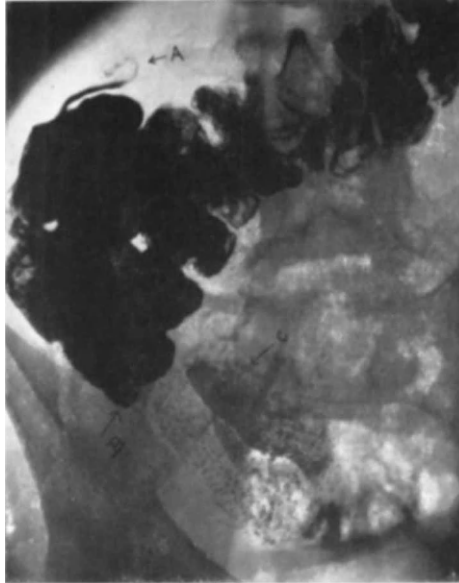

Fig. 596.—Radiograph of colon and appendix. **A**, Appendix (subsequently found to be diseased) situated over the right kidney; **B**, Middle of ascending colon prolapsed so that it might be mistaken for a cæcum in the normal position; **C**, Some retention of barium meal in the terminal part of the ileum.

(*a*) over McBurney's point, (*b*) in the right part of the epigastrium, and (*c*) anteriorly over the lower pole of the right kidney.

His kidney had been explored in the belief that his hæmaturia and pain were caused by a renal lesion, but no renal abnormality had been found.

A radiograph (*Fig. 596*) showed an appendix in a subhepatic position.

With the localization of the appendix to the subhepatic position, the whole diagnosis became clear. Operation disclosed a diseased appendix with subacute inflammation.

3. Retrocæcal or Retroperitoneal Appendicitis.—Retrocæcal or retroperitoneal appendicitis presents its own peculiar diagnostic difficulties. Generally there is some form of obscure abdominal pain. It may be in the right loin or in the vicinity of the gall-bladder, with disease of which organ it is often confused.

Cholecystography does not help, because it may exonerate or incriminate the gall-bladder. An attempt to localize the appendix by X rays may fail because it is retroperitoneal. Taken in conjunction with the anomalous symptoms this itself may be evidence that there is a retroperitoneal appendix present. There may be no abdominal tender point and no reflex rigidity, especially in fat people. There may, however, be a tender point in the loin.

In such circumstances if a retrocæcal abscess forms, the patient may be regarded as suffering from typhoid fever.

I once saw, in consultation, a bookmaker, a very fat man, who complained of diarrhœa. He had a temperature of 101.8° , a pulse of 70, but no tender point. His case had been clinically diagnosed as enteric fever. A delayed operation showed that he had a retrocæcal appendicitis with abscess formation. The patient died.

A retrocæcal appendicitis may cause a perinephric abscess, as in the following example :—

A man had the signs of a perinephric abscess. He had no symptoms of appendicitis or appendiceal tender point, and no symptoms of renal disease. When the abscess was opened the pus was found to be infected with *B. coli communis*. An appendiceal cause was suspected, and at a subsequent operation the inflamed bulbous tip of a long retrocæcal appendix was found to have penetrated the retroperitoneal tissue and the perinephric fascia where it connected to the abscess cavity.

In this patient there was not the slightest abdominal symptom to suggest that he had an appendicitis.

Retroperitoneal Cellulitis.—As has been just pointed out, the infected bulbous tip of the appendix can penetrate into the retroperitoneal space and infect the perinephric space. In the same way a retrocæcal or retrocolic or even a lateral cæcal inflamed appendix—usually by its tip—can infect the retroperitoneal plane of fascia and thus cause a retroperitoneal cellulitis—a very dangerous and treacherous condition. Here is an example :—

A patient fell ill with appendicitis. At operation his appendix was found to be retrocæcal, with a bulbous infected end which penetrated through the peritoneum into the retroperitoneal tissues.

The appendix was removed, but no drainage was instituted.

About ten days later the patient began to vomit. Gradually this got worse, and it was obvious from the large quantity which he vomited and other indications that he had a gastroduodenal ileus. He had no rise in temperature or pulse-rate.

Eventually the patient died, and the post-mortem examination revealed a sheet of retroperitoneal cellulitis extending to the duodenum, where it caused a complete duodenal paralysis ; and this inflammatory obstruction was the cause of his gastroduodenal dilatation.

In all such cases as this, where the retroperitoneal plane is infected, it is not wise to trust its power to deal with infection in the same way as is done with the peritoneum, for the local immunity powers of the retroperitoneal plane of tissue are peculiarly low. A tube should be inserted into the loin from the infected peritoneal perforation.

4. Left-sided Appendicitis.—The importance of discussing the question of an appendicitis that gives rise to left-sided symptoms lies in the fact that as a rule evidence of an inflammatory focus in the left lower quadrant of the abdomen is regarded as being caused by a diverticulitis—a condition that does not call for immediate operation.

As we have seen, a pelvic appendicitis can cause left-sided symptoms. A very long appendix extending to the left side can do the same. Rarely are they caused by an appendix situated on the left side.

5. Subileal Appendicitis.—Where an appendix extends upwards and medially and lies deep to the mesentery of the small bowel, if and where such an appendix becomes inflamed it may give rise to anomalous symptoms.

A man, aged 21, became ill with abdominal pain, nausea, anorexia, furred tongue, and temperature of 100°. When seen two days later he was distended but had no tender points. Operation disclosed a long appendix lying under the meso-ileum.

Patients with acute appendicitis in this region may die as a result of intestinal obstruction.

6. Acute Appendicitis in a Femoral Hernia.—It should not be forgotten that an appendix can be present in a femoral or inguinal hernia and that it may become inflamed.

A woman, aged 25, suddenly developed pains all over the abdomen, but they seemed to be worse round the middle of the abdomen. She had a small tender lump over the region of the femoral canal. She was not vomiting, had no rise of temperature or increase of pulse-rate, and had no pain over the femoral canal, but there was a little tender lump which felt like a gland, and was not obvious on the surface.

At operation it was found that there was a femoral hernia in which the terminal inch of the appendix was incarcerated. The terminal part of the appendix was acutely inflamed, but was not gangrenous. (The appendix was removed through the femoral opening.)

REFERENCES

¹ *The Official Commonwealth Year Book for 1937.*

² *The Registrar-General's Statistical Review of England and Wales for the Year 1936.*

³ Mortality Statistics, United States Department of Commerce, Bureau of Census for 1937.

CHAPTER LXXVIII

THE TREATMENT OF APPENDICITIS

The Clinical Recognition of the Stage of an Acute Appendicitis—the Question of Conservative or Operative Treatment.—

It is not enough to make a diagnosis of an acute appendicitis. In order to determine the treatment—conservative or operative—it is necessary to know the stage of the pathological process—whether the inflammation has remained limited to the mucous membrane; whether it has involved the peritoneum; whether it is progressing or receding; whether necrosis of tissue or perforation has taken place; whether the patient is dealing with the type of virulence of the infecting organism; whether the patient's resistance can be depended upon during conservative treatment. All these questions can as a rule be answered by a careful interpretation of the clinical symptoms and signs.

The truth is that a surgeon who has a large experience of the 'living pathology' of acute appendicitis can select the case that will get better with conservative treatment. But the surgeon not so experienced will include in his conservative treatment patients who have developed necrotic, perforated, and other unfavourable conditions—patients who will die, or because of slow absorption of necrotic processes develop thrombotic or embolic phenomena and take months to get better.

In the aggregate, many lives will be lost by leaning towards conservative treatment. A surgeon needs to be a good surgical pathologist to treat a patient conservatively.

OPERATION IN ACUTE APPENDICITIS

The Question of Immediate Operation.—In every case of acute appendicitis, the question of immediate operation should be considered, no matter what the day of the illness. In patients with acute appendicitis seen before the fifth day, the appendix should be removed at once. After the fifth day the question of conservative treatment should be considered; but even after this lapse of time a skilful appendicectomy can in most cases remove the appendix without unduly disturbing nature's barriers. If an inflamed appendix can be removed an enormous advance has been made in the chances

of the patient's recovery, for it often consists of dead or half-dead tissue or has become perforated, and it is therefore a focus of intense infection and of continual reinfection.

Thus in bad cases, no matter what the day of the illness, an incision should be made over the region of the appendix. It may be that a gangrenous appendix can be practically lifted out of an abscess; that a skilled surgeon can juggle out an appendix without disturbing or soiling loops of intestine (an important principle); that if the appendix cannot be removed an abscess can be drained; or that, failing the performance of any of these things, at any rate a tube can be inserted in the pelvis so that any scattered abscess formation may break into the drainage track thus made.

Of course, in a case which is obviously subsiding after the fifth day, it is much better to adopt the expectant method of treatment. But, as a rule, in the case of bad appendicitis which is not subsiding on the fifth or sixth day, it is better to have an opening in the abdominal wall.

Principles of the Operation.—The practical points in an operation for an acute appendicitis are as follows:—

1. *The Incision should be Made Exactly over the Base of the Inflamed Appendix.*—The reason is, that the base is usually the most undiseased part of an inflamed appendix. To this end, therefore, the incision should be made low in the case of a woman, who probably has a low cæcum; high in the case of a child, who probably has a high cæcum; more to the midline where the symptoms (umbilical referred pain, etc.) show that the small intestine is obviously involved and the appendix is probably in a subileal position; and more towards the lateral part of the abdomen where clinical manifestations indicate that the appendix is more lateral than is normal.

2. *A Gridiron Incision should be Made.*—Because (a) it can be easily and loosely closed and therefore made somewhat valvular for the purpose of drainage; (b) it can be extended widely and can be made into a very large incision without dividing any muscle- or nerve-fibres; (c) it can be placed laterally and therefore directly over the base of the appendix.

3. *The Resection of the Appendix should be Begun at the Base.*—Because (a) the main blood-supply is secured early in the operation, and the appendix is, as it were, then untethered; (b) the base is the least inflamed part and therefore the one place in which the true peritoneal plane of an inflamed appendix can be accurately determined, and when this is faithfully followed, it sometimes makes possible the resection of an inflamed appendix that appears almost unresectable.

4. *The Small Intestine should not be Disturbed.*—To this end packs should be sparingly used and the omentum should be employed to screen the small intestine from the field of the operation.

5. *The Abdominal Cavity (and the Abdominal Wound) should as a Routine be Drained.*—In severe cases I am sure that more lives will be saved by following this principle rather than the trust-the-peritoneum principle.

Routine drainage is instituted, not so much with the object of draining the abdominal cavity (which cannot be done for any length of time), but (*a*) with the object of letting out inflammatory products and weeping tissue-juice from raw surfaces, both of which form good pabulum for the culture of organisms; (*b*) because in an acute appendicitis the abdominal wall must be drained, otherwise it becomes infected; (*c*) because any residual abscess which may form as a result of infection of peritoneal exudation will always break into the drainage track—a weak spot in the tissue make-up—even up to several days after the drainage tube has been removed; and (*d*) because by giving exit to infected tissue products it lessens their absorption and therefore the incidence of thrombosis and pulmonary complications.

The drainage tube (or rubber tissue) should, however, always be excluded from the area of the small intestine by the omentum; and where possible it can be taken out in forty-eight hours. Used in this way drainage will rarely cause any damage: it will not cause adhesions of the small intestine (because of the screening), which are the ones that matter; and even should any adhesions arise they will be beneficent because of the transience of the drainage.

Thus routine drainage, cleverly arranged, will in the aggregate in my opinion save lives in the operative treatment of appendicitis; and this is especially true in the case of operation for acute appendicitis in the hands of the junior surgeon, into whose surgical care many cases of acute appendicitis fall.

It requires a good deal of knowledge of 'living pathology' and considerable judgement to decide in a case of acute appendicitis when not to drain: many factors—the type of infection, questions of the patient's resistance, of hæmostasis, of infected peritoneal exudate, of soiling of the abdominal wall, and of retroperitoneal involvement—all have to be taken into account.

Routine Technique.—The following is a routine technique in operation for an acute appendicitis in a normally situated appendix:—

The Incision.—The incision is illustrated in *Figs. 597, 598*. It should be based on the McBurney principle. Its centre should be situated over the ileocæcal junction or the base of the appendix,

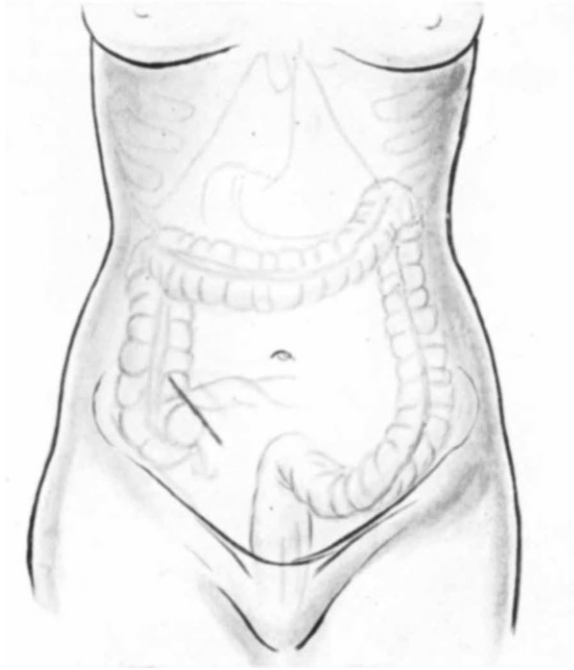


Fig. 597.—The usual site of the incision for an appendicitis in which the appendix is in the normal position. It should be made higher or lower, according to the situation of the appendix.

Impermeable towels should be clamped on the wound with the operating frame. Towel clips should not be used to fix the towels to the skin. Trinca¹ reports two cases in which gas gangrene developed in the abdominal wall as the result of infection through towel clips.

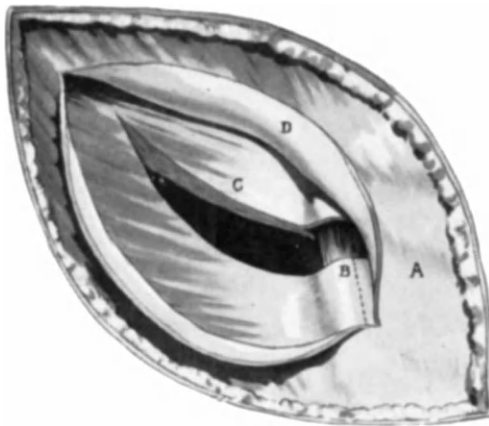


Fig. 598.—Drawing showing the McBurney split-muscle incision, and a method of enlarging by making a continuation of the separation of the fibres of the internal oblique and transversalis into the external sheath of the rectus and a vertical incision downwards from this. **A**, Sheath of rectus muscle; **B**, Vertical incision in rectus sheath; **C**, Tendon of internal oblique and transversalis; **D**, Reflected external oblique.

Finding the Appendix.—In acute appendicitis it should be a rule that the appendix itself should never be sought; for its terminal part, nearly always very inflamed, full of pus, and thin-walled, ruptures on the slightest touch. Further, the protective lymph barriers which usually surround this terminal inflamed part are broken down if the appendix is rooted out end first.

The base of the appendix, always the least diseased part, should as a routine be sought for. To find it, search should be made for

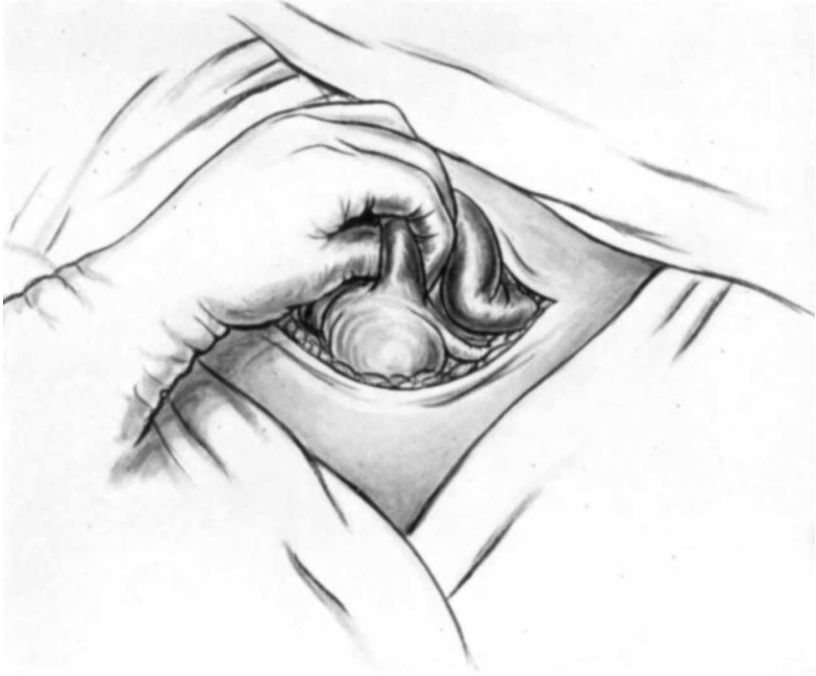


Fig. 599.—Showing how the ileocaecal junction is found, and how this serves as a guide to find the base of the appendix, which, as a rule, is in a constant situation in regard to it.

the ileocaecal junction, which bears a constant relation to the base of the appendix. This is found by passing the left first finger lateral to the caecum and down into the pelvis until it can feel the internal iliac artery beating. From the artery the finger comes up medially on the posterior wall of the pelvis and over its brim until it encounters the mesentery of the terminal part of the ileum. The forefinger and the thumb now bring up the ileocaecal junction. The base of the appendix, except in a few rare circumstances, is found an inch downwards and an inch backwards from this point (*Fig. 599*).

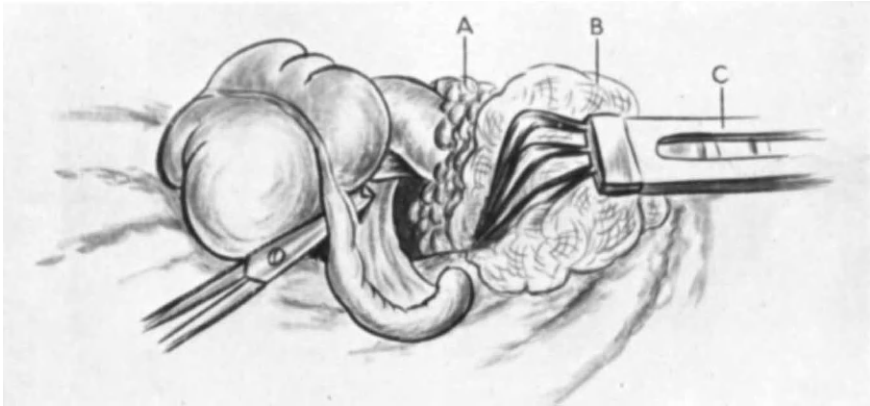

Fig. 600.—An opening made with the curved scissors in order to begin the division of the mesentery by clamping, tying, and cutting the vessels in steps. The ileum is covered with omentum (A) and soft scarf (B), and held out of the way by a 'mechanical hand' (C).

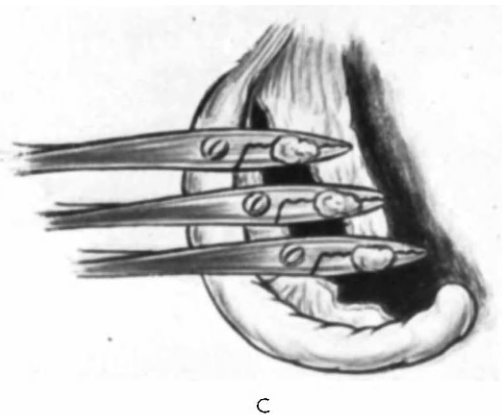
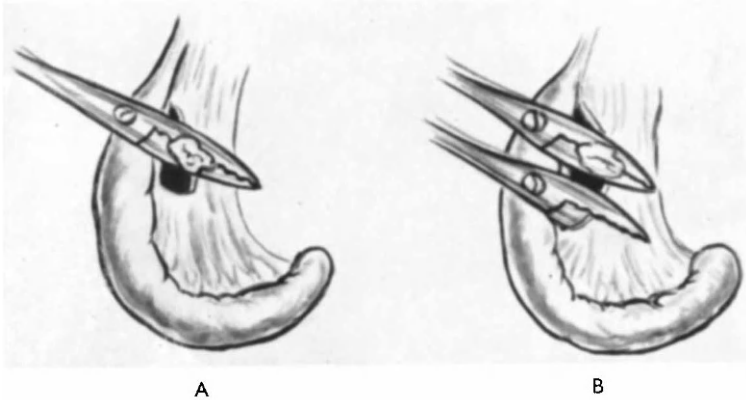


Fig. 601.—Ligation of the appendiceal mesentery from within out—a method which makes the surgeon expert in retrograde removal of the appendix—in piecemeal fashion from the base of the appendix towards the mesenteric free margin.

Protection of the Small Intestine.—In all cases, in order to protect the ileum from soiling, before any resection is started the omentum should be brought down and folded over the terminal part of the ileum, and with this structure held medially by a scarf and ‘mechanical hand’, as shown in *Fig. 600*.

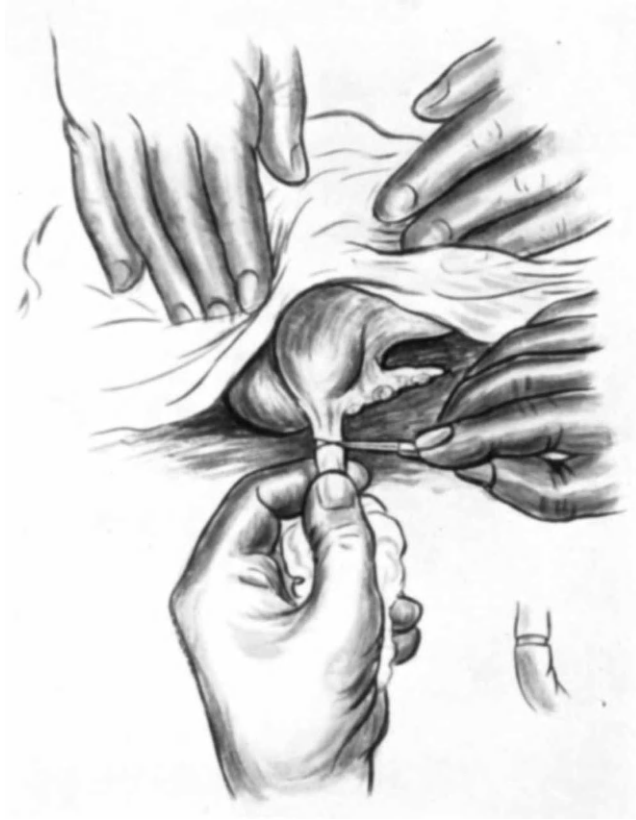

Fig. 602.—Division of the peritoneum around the base of the appendix. (*MacCormick.*)

Removal of Appendix.—If the appendix is not adherent, the mesentery is clamped and divided either *en bloc* or piecemeal from the base of the appendix to the free margin of the mesenteric border, as shown in *Fig. 601*. Where the mesentery is very fatty, it should be double-clamped.

The peritoneum around the base of the appendix is divided as shown in *Fig. 602*.

The appendix is crushed at the level of this division. The clamped vessels of the appendiceal mesentery are ligated. The base of the appendix is tied with catgut. (See *Fig. 604.*)

A No. 1 or No. 0 catgut purse-string suture on an atraumatic round straight needle is then inserted and held by the assistant as

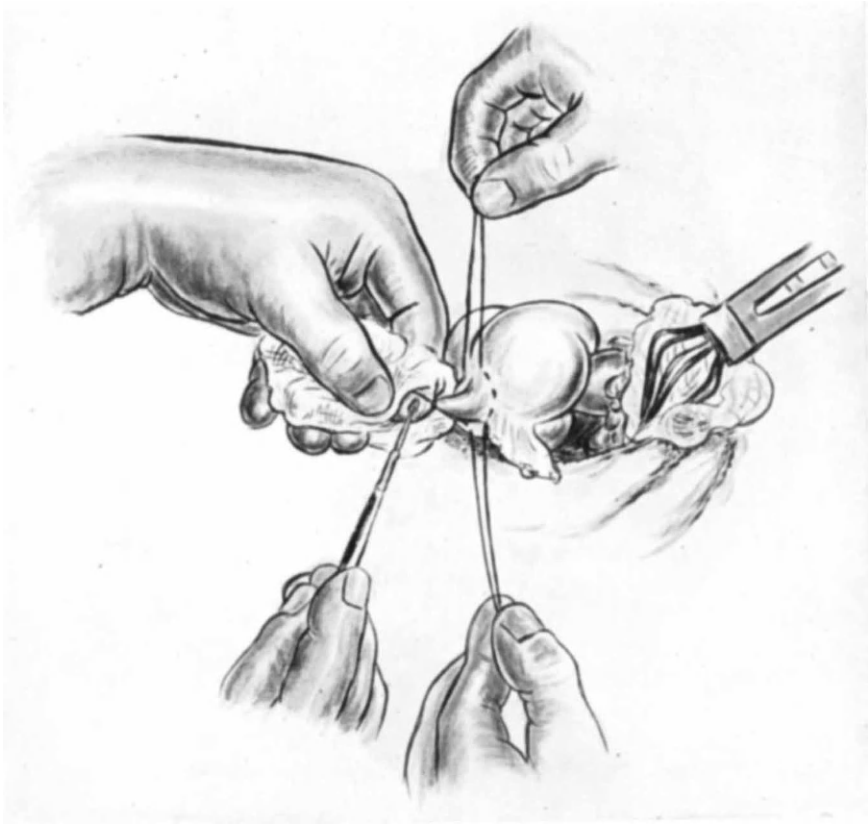


Fig. 603.—Purse-string suture inserted and held by assistant. Appendix having been amputated the mucous membrane is scooped out (*MacCormick*) and a wad of gauze used to prevent soiling while the mucous membrane is being removed.

shown in *Fig. 603.* The appendix is amputated as shown in *Figs. 603, 604,* a wad of gauze being used to prevent soiling.

In this method the mucous membrane of the stump is scraped out (after Sir Alexander MacCormick), with the object of removing as much of the germ-bearing layer as possible from the stump. It is then invaginated as shown in *Fig. 605.*

The advantages of this method as a routine one are that one bowel coat is left internal to the infected stump and three external to it ; that the base of the appendix is ligated, and therefore no bleeding into the bowel can occur ; and that the base quickly sloughs off, so that any infection of the stump must break into the lumen rather than into the peritoneal cavity.

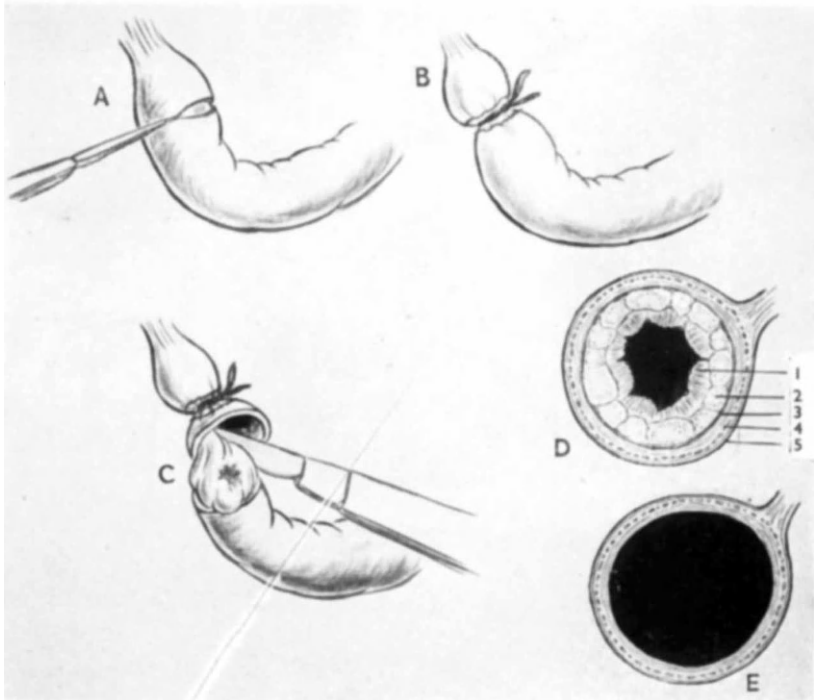


Fig. 604.—Amputation of the appendix: A, The peritoneum is incised (see Fig. 602); B, The appendix is crushed along the line of incision and tied at this point with gut; C, The appendix is amputated (see Fig. 603) and the mucous membrane and lymphoid tissue scooped out with the knife, leaving a small butt of the appendix consisting only of serosa and muscle-layer; D, Shows various layers in cross-section of appendix (1, Mucous membrane; 2, Lymphoid tissue; 3, Circular muscle; 4, Longitudinal muscle; 5, Peritoneum); E, Showing the layer left in the excavated stump.

Retrograde Removal of the Appendix.—Should, however, the appendix be firmly bound down by inflammatory adhesions, or have no mesentery, or be embedded in the wall of the cæcum, it should be removed base first. The base, after being isolated, is divided between two strong forceps with a diathermy knife, and the divided ends are cauterized with the coagulating diathermy current. The distal cut end of the appendix is then held up, and the blood-supply

caught as it is put on the stretch, by the application of successive Spencer Wells forceps. (See Fig. 608.)

As each vessel is divided, the appendix becomes untethered as it were, and by the time the middle of the appendix is reached, nearly the whole of the blood-supply is divided, when the rest of the appendix—often in an inaccessible position—can be dissected under vision or lifted out without clamping any more vessels.

The base of the appendix is invaginated in the usual way.

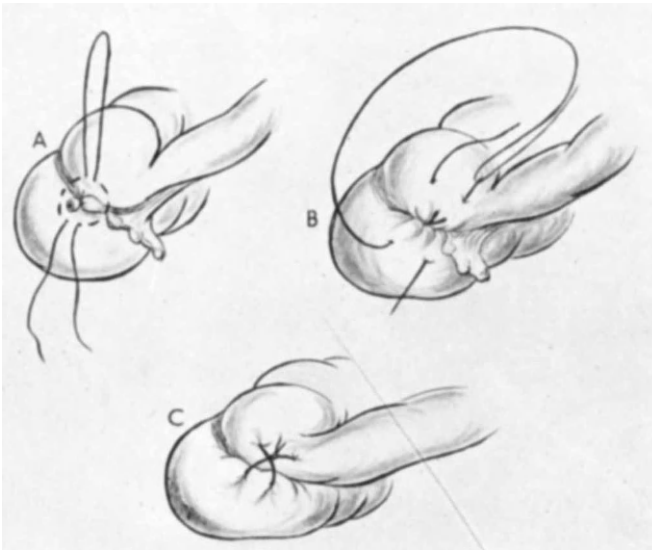


Fig. 605.—The insertion of a purse-string suture (A) and a covering X-suture (B) to fold in the raw mesenteric surfaces; C, The X-suture tied, leaving no raw mesenteric surface visible.

In the Case of an Appendiceal Abscess.—Should an abscess have formed it must communicate with the appendix in some part of its course. Thus as the appendix is slowly brought out of the wound base first, by a retrograde sequential division of its mesenteric vessels, there will come a time when the abscess will open into the track from which the appendix is being removed. This, of course, is the proper route along which to approach an appendiceal abscess; that is, through the 'tunnel' made by removal of the appendix, and therefore as far as possible from the easily infected small intestine. It is the handling and soiling of the small intestine in bad cases of acute appendicitis which produces post-operative ileus. A skilful surgeon should be able to lift out an inflamed appendix without

disturbing the loops of small intestine ; and surgeons skilful in this respect get very little post-operative ileus.

The Removal of Peritoneal Exudate.—When the appendiceal inflammatory process reaches the peritoneal surface of the appendix, it produces reactive processes in the neighbouring peritoneal surfaces of the abdominal cavity. This fluid, which is highly albuminous, is in its early stages a response to toxic action from the infective process rather than to the process itself ; in its later stages the extent of its infection depends on the stage of inflammatory spread.

The situation of this exudate depends on the position of the appendix. If this organ is situated below the brim of the pelvis, the exudate will be found in the pelvis ; if it lies above the brim and towards the renal fossa, the fluid will collect in this region and towards the subphrenic region ; if the appendix lies in a sub-ileal position, then the exudate collects in this region.

The removal of this exudate, which is a good culture material for organisms, is highly important.

After the appendix has been removed, the abdominal watersheds should be explored for the presence of exudate. The exploration should be made by a lateral approach (along lateral side of cæcum or ascending colon), and down into the pelvis, using a swab on a holder and protecting the small intestine with a long spade-like retractor.

If exudate is present it should be aspirated. The operating table should be tilted laterally for some minutes, or head down or feet down according to the need, in order to allow any fluid to gravitate into a position where it can be reached with the aspirating tube.

Where the Exudate is Highly Infective.—In a gangrenous, perforative, or highly virulent rapidly spreading appendicitis, the exudate is, of course, very infective. Its spread is somewhat limited to the appendiceal area by the protective immobility of the abdominal wall. Accordingly, the object in dealing with this highly infective exudate is not only to remove it but to prevent its further spread, which of course is imminent when this protective immobility is removed by the anæsthetic.

To attain this end the patient should be so postured early in the operation by positioning the operation table as to encourage the movement of exudate towards the appendiceal and pelvic area. In these positions it can be aspirated without plunging the aspirating tube between coils of small intestine.

Search for Fæcolith.—In an operation for a perforative appendicitis, a search should always be made for a fæcolith. Often in the

excitement of the operation this precaution is forgotten, and the result is a drainage wound that will not close—a fistula.

Closure of the Wound.—In a case of acute appendicitis the abdominal wound should be closed with much care. It must be assumed that it has become infected. Plain—not chronic—catgut (No. 0 for the peritoneum and No. 3 for the muscles) should be used. Unless the muscles and aponeurosis are loosely approximated, necrosis of these tissues is very liable to occur. The sutures, always interrupted, should be inserted so loosely that when the tissues swell, as they always do as the result of inflammation following infection, the edges of the wound are approximated. Very fine, coapting, interrupted sutures taking a small bite may be employed to hold the loose wound together for twenty-four hours.

In severe infections drainage of the wound should always be instituted, even if the peritoneal cavity is not drained.

Post-operative Treatment.—A minimum of after-treatment should be the aim. Well-meaning, anxious, and meddling post-operative treatment has turned the scale against many a case of severe appendicitis.

Distension and loss of bowel function are the result of paresis of bowel muscle by toxic action by an inflammatory spread, as well as being due to the effects of the operation causing cessation of bowel movements.

The removal of the toxic and infective action is accomplished when the appendix—the source of the infection—is removed, and time must be allowed not only for the normal muscle movements to recover but also for the bowel wall to recover at least partial function as a result of the elimination of the muscle poisoning and the recession of the inflammation. Measures with a view to relieving the distension and constipation before the bowel muscle has recovered only increase the mechanical disability and retard the recovery of the muscle walls.

The post-operative treatment should aim at (1) rest to the bowel and restoration of its movements; (2) treatment of the inflammation; and (3) maintenance of the patient's strength. The bowel is rested by abstention from administration of purgatives and enemas, and its movements are encouraged by the use of morphia. The inflammation (in the abdominal wound as well as the abdominal cavity) is treated with radiant heat or short-wave diathermy. The patient's strength is maintained by intravenous nutrition, which if employed early has not only a good effect on the patient's general well-being and on the quick excretion of toxins, but also on his local condition—on the recovery of his bowel. (*See p. 784.*)

For the first twenty-four hours a flatus tube should be inserted. The wound should be free of dressings so that it may have the full benefit of the radiant heat. The right lateral or Fowler's position should be employed.

OPERATION FOR ACUTE PELVIC APPENDICITIS WITH OR WITHOUT SYMPTOMS OF INTESTINAL OBSTRUCTION

An operation for an acute pelvic appendicitis requires a different operative approach from that of an appendicitis in the normal situation. It presents difficulties depending upon the complications of the pelvic appendicitis.

The operative management depends largely on whether the acute pelvic appendicitis is caused by: (1) A long appendix with the cæcum in the normal position when the tissues of this organ (as a rule) and the base of the appendix are reasonably sound; or (2) An appendix which, with the cæcum, has prolapsed into the pelvis.

Cæcum in Normal Position and Appendix Extending into Pelvis.—The chief operative difficulties in such cases are:—

1. The removal, without rupture, of a long, bound-down, inaccessibly situated pelvic appendix, in which gangrene may have taken place, or in which the terminal part may be paper-thin and distended with pus.

2. The removal of an appendix as above described (in itself a surgical feat requiring some skill) in the presence of the surgical difficulties caused by the complication of an acute intestinal obstruction.

The Incision.—A split-muscle incision, made *as low as possible*, should be employed (*see Figs. 597, 598*).

A paramedian incision, which might be the correct procedure in an operation for an intestinal obstruction of mechanical causation, is (in my experience) a *fatal error* in a case of acute pelvic appendicitis complicated by an intestinal obstruction. An incision in this situation allows the coils of small intestine, mechanically dilated but usually uninfected, to prolapse into the appendiceal infected area and become soiled. It also makes it almost impossible to protect these coils from soiling, as the laterally situated appendix must be approached through centrally situated small-intestinal coils. Furthermore, the suture of a midline incision in the case of a distended abdomen is often very difficult, and the wound, necessarily soiled, behaves badly when it becomes infected: as it must be firmly sutured it is more likely to break open than a split-muscle incision which can be loosely approximated, and therefore stands infection better.

These objections also hold against the employment of a midline incision for an uncomplicated acute pelvic appendicitis.

A split-muscle incision is therefore made, placing it as low as possible. When dividing the oblique and transversalis tendon it should be split as far as possible into the outer sheath of the rectus, as shown in *Fig. 606*, and the muscle-fibres should also be separated as far laterally as possible. If a still larger incision is required, the rectus sheath should be divided vertically (*Fig. 606, A, B*). Thus a very large incision—as large as a subumbilical midline incision—is

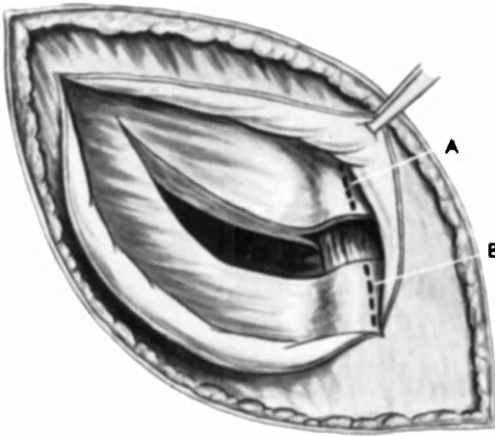


Fig. 606.—Drawing showing how the split-muscle incision is enlarged by incisions in the rectus sheath, indicated by the dotted lines A, B.

obtained, which can be loosely sutured, and in which no nerves have been divided.

The edges of the wound should be covered with impermeable wound covers which should be clamped on to the edges of the wound with the four-bladed operating frame, using small retractors.

The wound should be opened to its widest extent with only the muscle pressure—that is, respiratory muscle pressure

—the frame being fixed in during a negative phase of respiration (*Fig. 607*).

Deflation of the Cæcum.—If the cæcum is so distended (as a result of the obstruction) that it will interfere seriously with manipulations, a hypodermic needle should be inserted obliquely into its anterior wall, attached to a suction pump, and the cæcum and adjacent small intestine deflated. With patient suction—which takes time owing to the smallness of the needle—the reduction in size will be considerable, because the contents are mostly air. In this way operative manœuvres in relation to the deeply situated appendix are rendered much easier.

One X-suture should be inserted over the needle puncture.

Excision of the Appendix.—The steps for the excision of the appendix are as follows:—

Find the terminal part of the meso-ileum by the manœuvre previously described—that is, by sweeping the finger upwards from

the pulsation of the internal iliac artery (*see Fig. 599*). Trace the terminal part of the ileum to the ileocæcal valve. On the collapsed

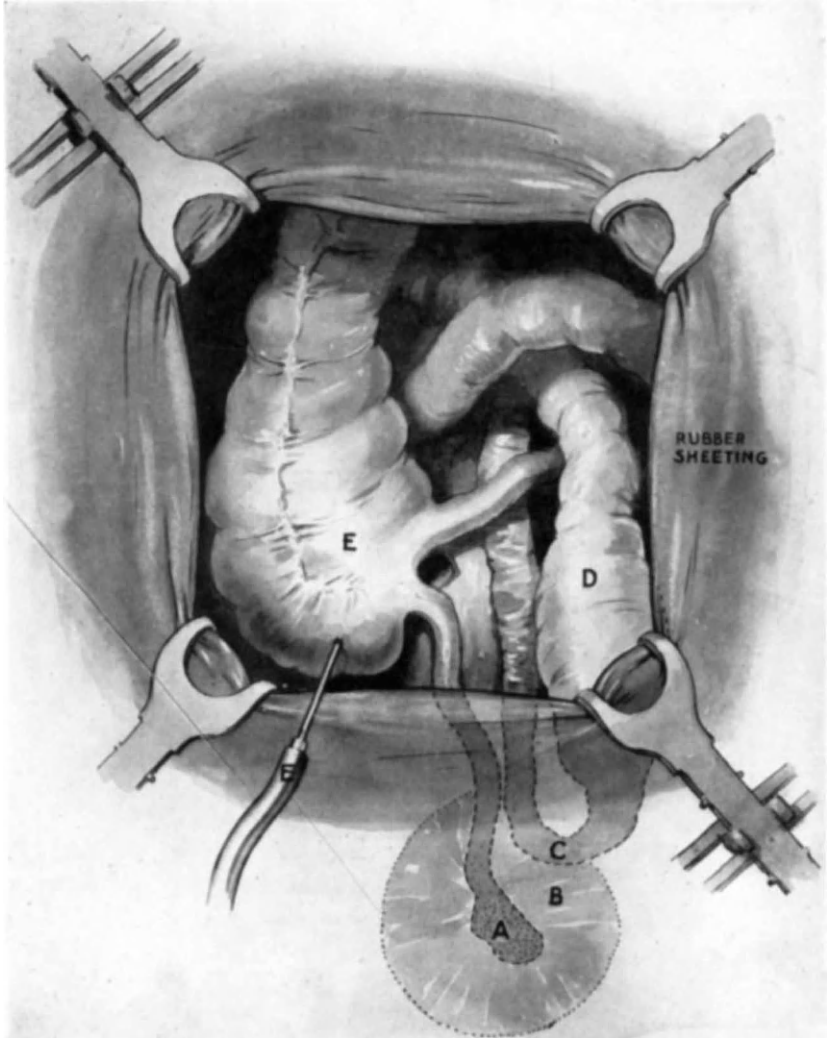


Fig. 607.—Operation on a pelvic appendiceal abscess with intestinal obstruction. **A**, Infected appendix (dotted in); **B**, Abscess (shadowed in); **C**, Paralysed segment of small intestine; **D**, Obstructed small intestine; **E**, Dilated cæcum; **F**, Hypodermic needle attached to air pump deflating cæcum. (Diagrammatic.)

cæcum identify the base of the appendix by its relation to the ileocæcal junction. With a diathermy knife divide the base of the appendix between two clamps and invaginate the appendiceal stump.

In order to expose a wide operation area and so display the arteries of the appendix, cover the cæcum with several layers of scarf, and by means of a 'mechanical hand' push it out of the operation area and into the abdominal cavity (*Fig. 608, A*).

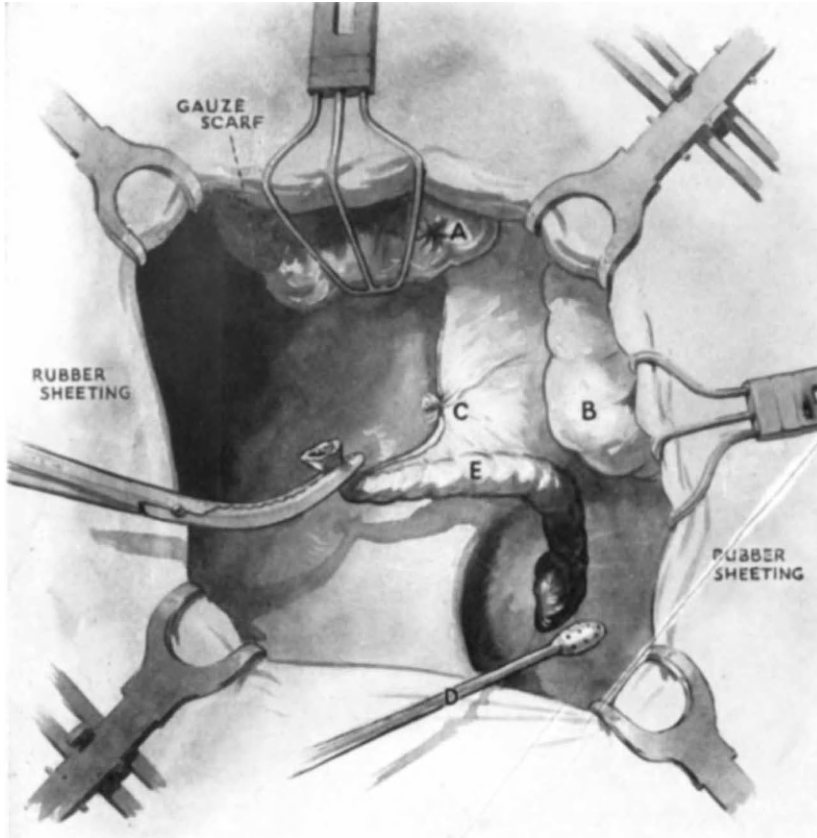


Fig. 608.—Showing exposure in case of pelvic appendicitis associated with intestinal obstruction. The wound is widely but gently held open by the operating frame. The edges of the wound have impermeable covers so clamped on that they cannot be disarranged (thus avoiding soiling with the infection). The figure also shows the base of the appendix divided between clamps and invaginated. **A**, Deflated cæcum covered with gauze and held out of operation area with 'mechanical hand' (blade flexed at an acute angle); **B**, Small intestines covered first with omentum and then with a scarf and excluded from operation area with 'mechanical hand'; **C**, Arterial twigs in mesentery clamped, cut, and tied so as to make the appendix come up to the operator; **D**, Aspirator for perforating the abscess and rapidly and completely removing the pus; **E**, Pelvic appendix.

Use the omentum to cover and thus protect the small intestine, and with a small soft scarf and mechanical hand displace it from the infected appendiceal area.

With the Spencer Wells forceps which hold the divided (and sterile) appendiceal cut end, firmly lift the appendix vertically so as to stretch the mesentery and display its entering arteries; and then clamp and snip these one by one (*Fig. 608, C*).

As each arterial twig is divided the appendix can be lifted higher and higher, till finally it can be lifted out altogether without ever having been touched, and therefore with its dilated fragile infected terminal part intact.

With this method the calamity of a gangrenous pelvic appendix being ruptured by being 'rooted' out end first should never occur.

Appendix and Cæcum Prolapsed into the Pelvis.—In this case, the cæcal wall and the base of the appendix are as deeply inflamed as the rest of the appendix. There will therefore be little sound tissue for the performance of appendicectomy. Further, in this case the appendix cannot be removed as described above, but the cæcum must be delivered and therefore protective reactionary barriers broken down. The cæcal wall, too, will be found too friable to hold sutures. In this case it is better to drain if the appendicitis is at all well advanced.

The following is an instructive case in this respect:—

A boy of 20 became sick with a pain "as if his bowels wanted to act". Next day, the pain was in the left iliac fossa. His temperature was 100° and his pulse 80. He did not vomit. On the following day he had, and continued to have, rather severe pain at the end of passing water, and was tender over the bladder. He had a continual feeling of tenesmus and passed mucus. His tongue was dirty, but he looked well. On the seventh day of the illness, his abdomen was rather distended. He still complained of all the symptoms described above, his temperature was 100°, his pulse 90, he was tender on examination rectally, where a definite resistance could be felt. He was not tender on the right side—or in the appendiceal area. He had been attended by a medical man for a week without a diagnosis being made, and then pelvic appendicitis and pelvic abscess was diagnosed.

OPERATION.—An appendiceal abscess deep in the pelvis was found. The cæcum had prolapsed into the floor of the pelvis. The surgeon thought that the appendix could be easily removed. He had to deliver the inflamed and bound-down cæcum. When the appendix was removed, the cæcal walls were so friable that they would scarcely hold stitches.

The patient subsequently developed peritonitis and died.

The one thing that should not have been done in this case was an appendicectomy. Drainage should have been instituted, even if the inflammatory condition had been in an earlier stage.

In the Case of an Abscess.—If in a case of pelvic appendicitis an abscess is present, it will present along the appendiceal track as the appendix is being removed base first. In order to avoid soiling of

the perhaps uninfected small intestines, the pus should not be allowed to rupture, but be sucked out—‘ vacuum-cleaned ’—with an aspirator.

If, however, a large pelvic appendiceal abscess in relation to a pelvic appendicitis occurs in a female, it should be approached vaginally rather than abdominally, and should be opened through the posterior fornix, or through the anterior fornix. The appendix can then be removed at a later date.

If such a large pelvic appendiceal abscess forms in a male, and if it can be distinctly felt in a rectal examination, it should be opened through the rectum. The patient is placed in the knee-chest position, and an ordinary vaginal speculum is inserted into the rectum. The speculum is elevated with the left hand, when the anterior wall of the rectum falls forward and the abscess can be palpated and opened under good vision. The appendix can then be removed when the inflammation has subsided.

A pelvic appendiceal abscess in a male which is not frankly ‘ pointing ’ into the rectum may be more safely drained by making a small incision above Poupart’s ligament and tunnelling down along the lateral wall of the true pelvis.

The Question of Drainage.—A rubber tube or rubber dam drain should be introduced into the pelvis from the outer angle of the abdominal incision. In the case of a female, a tube should also be passed from the abscess cavity into the vagina. This manœuvre is carried out in the following way: Use the left hand in the vagina to find the posterior lip of the cervix and with it hold a swab on a holder against the posterior fornix; with the right hand push the cutting spade-point of the long spade-pointed scissors from above on to the swab, and through the opening thus made lead a tube from the pelvis into the vagina.

The *full length* of the long ‘ drainage track ’ is kept open from ten to fifteen days by using the same length drainage tube but of smaller and smaller calibre, till finally a No. 6 soft rubber catheter is employed. It will often be found that small secondary abscesses will ultimately find their way to and break into this drainage track—even, sometimes, days after the last tube is removed.

OPERATION FOR SUBHEPATIC APPENDICITIS

Acute Suppurative Subhepatic Appendicitis.—For suppuration in a subhepatic appendicitis, a split-muscle opening similar to a McBurney should be made. The valvular character of this opening is of advantage in the management of the suppuration. The abscess should be drained, and the appendix removed later.

Chronic Subhepatic Appendicitis.—The only possible incision for this type of anomalous chronic appendicitis is an upper paramedian incision.

The four-bladed self-retaining operating frame with its wound covers should be used.

By means of this operating frame the assistant can gently and slowly lift the abdominal wall so as to display the peritoneum lateral to the cæcum and colon, along which an incision should be made. The cæcum and the ascending colon, thus freed, and with these organs the base of the appendix, should be drawn towards the midline, where the appendix can be excised in comfort and in the usual way. The cæcum and ascending colon are then replaced and the divided peritoneum closed with a few peritoneal sutures.

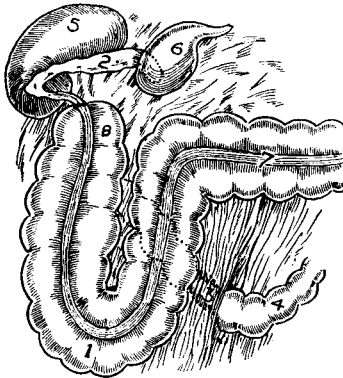


Fig. 609.—Diagrammatic representation of a condition which may be found at operation in a case of chronic subhepatic appendicitis. 1, Middle of ascending colon prolapsed and occupying the position of the normal cæcum; 2, Subhepatic appendix; 3, Terminal 3 in. of ileum which is retroperitoneal (dotted in). 4, Ileum slightly dilated proximal to retroperitoneal segment; 5, Kidney; 6, Gall-bladder; 7, Transverse colon; 8, Cæcum.

Subhepatic chronic appendicitis can, however, present other operative difficulties. In the early or excessive adhesion which is often the cause of the non-descent of the appendix, the last two or three inches of the terminal part of the ileum may sometimes be found in a retroperitoneal position behind the cæcum (as shown in *Fig. 609*). This ileal segment on account of its retroperitoneal situation tends to become narrowed and thus to give rise to a mild chronic intestinal obstruction with colicky pain. It may therefore happen that, at the same time as the performance of the appendicectomy, some peritoneal plastic work on the terminal ileum may require the surgeon's attention.

OPERATION FOR RETROCÆCAL OR RETROPERITONEAL APPENDICITIS

In retrocæcal or retroperitoneal appendicitis, a split-muscle McBurney incision is again the most suitable, enlarged as described on p. 870.

The wound of the incision is covered with impermeable wound covers and the four-bladed operating frame with special small blades inserted.

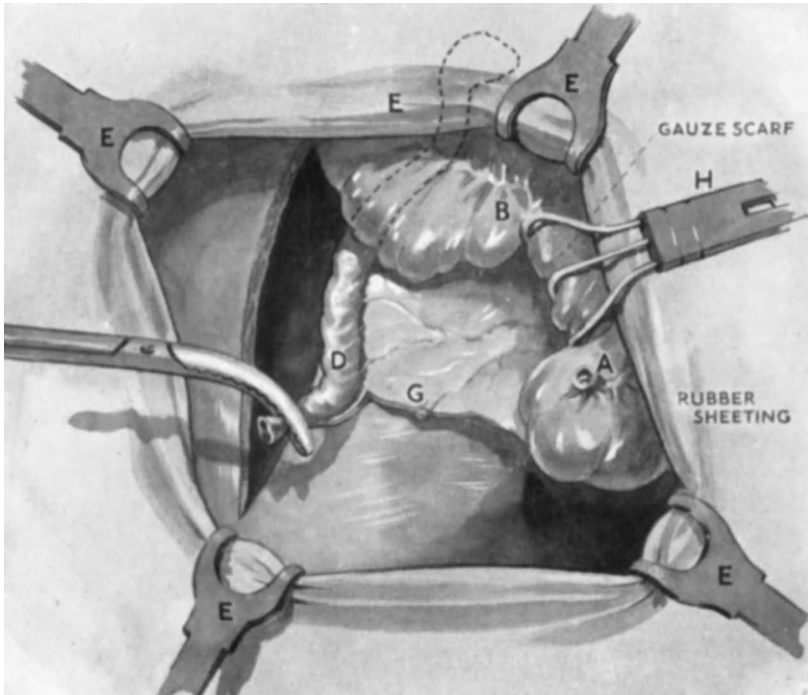


Fig. 610.—Operation for retrocæcal appendicitis. **A**, Base of appendix is divided and butt invaginated so that cæcum **B**, covered with a scarf, can be pushed into the abdomen with a 'mechanical hand'. **C**, Arterial twigs snipped and tied. **D**, Appendix (retrocæcal). **E**, The abdominal wall is lifted up with the retractor so that the terminal part of the appendix (dotted in) is removed under good vision.

A little search reveals the base of the appendix, which is divided with the diathermy knife and then invaginated as shown in *Fig. 610*.

The cæcum is covered with a scarf, and with a 'mechanical hand' pushed back out of the operation area into the abdominal cavity. By lifting up the hæmostat on the divided end of the appendix and at the same time elevating the abdominal wall by means of the operating frame with the patient in reverse Trendelenburg position, it is possible to dissect the appendix under sight from base to apex almost as far up as the liver.

Fig. 611 shows the method of drainage—lumbar stab—to prevent the spread of inflammation—retroperitoneal cellulitis—where the infected appendix has opened into the retroperitoneal tissue.

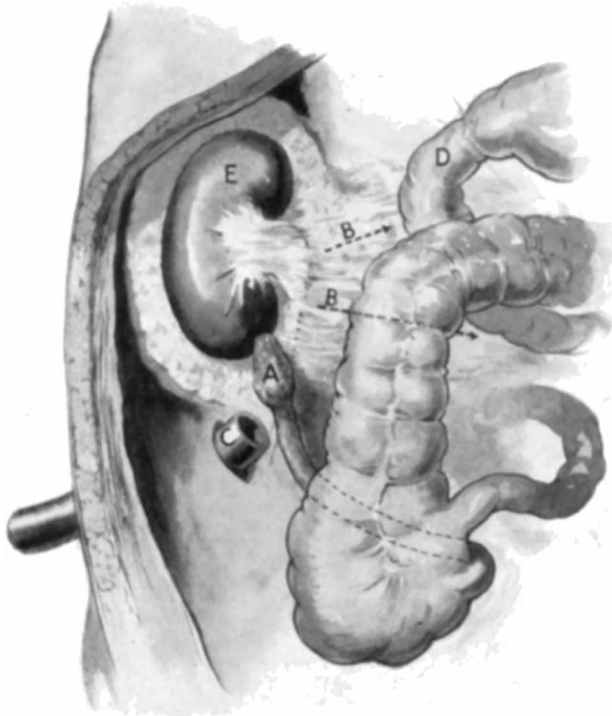


Fig. 611.—Showing method of drainage—stab wound in loin—in a retro-cæcal appendicitis. A, Infected terminal end of infected appendix; B B, Direction of spread of retroperitoneal cellulitis if it occurs; C, Drainage tube; D, Duodenum; E, Kidney. (Diagrammatic.)

APPENDICECTOMY THROUGH THE INTERNAL ABDOMINAL RING WHEN DOING AN INGUINAL HERNIA

It is often quite easy when operating for inguinal hernia to deliver the appendix through the internal abdominal ring, bring it up, and amputate it. Two small retractors should be placed in the internal abdominal ring and the ring fully opened so that the appendix can be picked up with a long dissecting forceps and brought up to the ring.

APPENDICECTOMY THROUGH A SMALL INCISION

Frequently the appendix can be removed through a small incision, especially if the surgeon is accustomed to divide the vessels

from the base of the appendix towards its apex. It can also be removed through a very small incision ancillary to the upper abdominal incision by employing the operating frame (*see* p. 438).

FISTULA AFTER OPERATION FOR ACUTE APPENDICITIS

Causation.—The causes of fistula after operation for acute appendicitis are as follows :—

1. The appendix was tuberculous, a condition that is often not recognized by the operator, and the appendiceal stump because of the tuberculous lesion does not heal and bursts open.

2. The appendix (in a perforative acute appendicitis) was removed but a fæcolith loose in the peritoneal cavity was overlooked.

3. An appendiceal abscess involved the salpinx and a fistula persists till the infected tube is removed.

4. The appendix, where the operation has been performed for appendiceal abscess, has been only partly removed, and the fistula comes from the part where the appendix has broken off.

5. An opening has accidentally been made in the cæcum or sigmoid.

6. A foreign body is present in the wound—silkworm-gut, chromicized gut, a tag of gauze, or a necrosed bit of tissue ; or in the abdominal cavity—a piece of tube or other foreign body.

THE MANAGEMENT OF THE COMPLICATIONS OF ACUTE APPENDICITIS

The complications are wound infection, fæcal fistula, post-operative ileus, thrombotic phenomena and their sequel embolism, and peritoneal abscess—pelvic and subphrenic.

With the exception of subphrenic abscess, most of these have been dealt with elsewhere and need not be again discussed.

The most important treatment of the majority of the complications of appendicitis is prophylactic—that is, to foresee them and forestall their development. This, of course, applies to those complications like pelvic and subphrenic abscess and post-operative ileus which to a considerable extent are preventable by a wisely planned operation. It also applies to the thrombotic complications which are prone to follow unskilful operating and lack of drainage.

The next most important point in treatment is to recognize early ileus and intraperitoneal abscess (*see* pp. 789, 790).

Subphrenic Abscess.—A needle should not be used to search for a subphrenic abscess. Slight cyanosis, fixation of the diaphragm (as seen by X rays), evidence of less air entering the right base, are

manifestations of the condition. A subphrenic abscess should be opened if possible from the peritoneal cavity below the last rib or through the lower part of the diaphragm, the 10th or 11th rib being resected and the pleura pushed up, so as to avoid opening it. The abscess should never be approached transpleurally. It will be found that a large flexible aspirating tube will reach a long way up behind the liver from an infracostal incision or through the space made after removal of the 12th rib.

ACUTE APPENDICITIS IN THE AGED

Usually acute appendicitis in the aged occurs in a crippled appendix, which may be atrophied from age, strictured and dilated from disease, fibrous, disabled from a contained fæcolith, or arterially deficient from arteriosclerosis.

The condition presents a different clinical picture from that of other age periods, and experienced practitioners often do not recognize it in its early or even in its late stages.

In the young we find the manifestations of high reaction, but in the aged the reverse—sometimes even an entire absence of reaction. The natural defensive processes are greatly deteriorated; the local immunity of the body-cells is much lessened.

The aged patient is often the subject of a fulminating form of acute appendicitis—a perforative or gangrenous type (*see* p. 844); nearly half of the cases in patients over 60 are perforated. He has also to contend with the poor healing power of his aged tissues, and the predisposition inherent in such tissues to pathological accidents, such as thrombosis with its attendant chain of dangers, lung emboli, pneumonia, etc.

The one remedy, therefore, for acute appendicitis in the aged is early operation. But this is the one thing that the aged patient does not get, because as there is an absence of reactive symptomatic manifestation in the early or middle stages his condition is not diagnosed.

The aged acute appendicitic patient usually complains of a general illness and perhaps of mild indefinite abdominal pains for the first few days. There is little evidence of inflammation in his abdomen—perhaps a little tenderness, a little *défense musculaire*. He has no nausea and does not vomit. His temperature and pulse-rate are normal (in more than half of the cases). Rarely has he a leucocytosis. There is little disturbance of bowel function. No suspicion arises that he is suffering from appendicitis. On account of his age the course of the disease may be rapid.

In the aged, too, the onset and 'march' of a peritonitis as an extension of an appendicitis is different from that of the earlier age periods. The early stormy signs of the peritonitis in the young fail, as also do the vomiting, the tense belly wall, the distension, the almost absolute constipation, and the restlessness. Notwithstanding the seriousness of the local lesion the patient's general condition appears relatively good. It looks almost as if he is going to get better. Then follows a sudden worsening and a quick death. Often death comes as the result of one of the complications of acute appendicitis, such as thrombosis and embolism—accidents which are so prone to occur in the old person.

Many cases of acute appendicitis in old people are admitted in a dying condition.

Operative Management.—In these cases operative strategy is important: early operation, a split-muscle incision, spinal or gas anæsthesia, a quick operation, cardiac treatment in addition to the usual post-operative treatment (*see* p. 784), bed gymnastics, thyroid therapy as a prophylaxis against thrombosis.

These patients die of embolism, heart failure, lung injury, and peritonitis.

The death-rate in operations for acute appendicitis in the aged in a large series may be as high as 30 to 35 per cent.

ACUTE APPENDICITIS IN THE YOUNG

Like acute appendicitis in the aged, acute appendicitis in the young is attended with a rather high mortality. Maes, Boyce, and McFetridge,² in a series of cases of acute appendicitis in 250 children, reported a mortality of 7.6 per cent. Farr writes that it is nearer 10 per cent.

There are many factors which are responsible for this high mortality-rate, some of which are as follows:—

1. Many parents administer castor oil to their children for most illnesses, thus causing serious delay in diagnosis and disseminating the infection if the illness is the beginning of an acute appendicitis.
2. A diagnosis is not always promptly made, because it is difficult to get a satisfactory history in young children, and because the onset of an acute appendicitis in children is often atypical as a result of developmental appendiceal displacements (*see* p. 831).
3. In children the appendix contains a large amount of lymphoid tissue, which is very liable to infection, and in which because of its rather poor local immunity an infection runs an unfavourable course.

4. In children the great omentum is not well developed: it is diminutive, and is therefore not so effective in providing local protective immunity as it is in adults; in consequence its localizing power is poor.

Acute appendicitis in children frequently follows a gastrointestinal affection, and is therefore probably more often a result of intestinal infection than in the case of adults.

A most important feature in acute appendicitis in children is the rapidity with which it progresses: a perforation can occur in twelve hours.³ This rapid progress is due to the large amount of lymph tissue, the vulnerability to infection of the child's tissue, its low powers of general resistance, and the defective localizing power of its omentum. In appendicitis in children, gangrene, perforation, and abscess formation occur in a large percentage of cases—73 per cent.²

In a question of appendicitis in a child, a rectal examination should always be made, because the finger can reach much higher than in an adult and therefore more information can be obtained.

Deaver and Parsons³ point out that a factor which makes an acute appendicitis in a child a more serious condition than in an adult is that the vitality of the cellular tissues is more dependent on the surrounding fluid medium; that is, the tissues are more dependent on the integrity of the composition of the plasma and intercellular fluid. The main constituents of intercellular fluid are water, soda, and chlorides. In a child the normal balance of these constituents is very easily upset, when the vitality of the cell is at once affected. This disturbance of balance is brought about in the following way. The secretory and motor functions of the alimentary canal are disturbed by an infection involving the alimentary system, such as acute appendicitis, and the child early refuses food and soon fluid. Thus he quickly becomes dehydrated (clinically seen by a high concentration of urine and an increase in the amount of hæmoglobin and the number of red cells). As the child has a higher metabolism than an adult, he requires more nourishment, and in the absence of food soon begins to live on his own tissues and quickly to use up his glycogen. His fats are dependent for oxidation on carbohydrates, i.e., on glycogen, so that, as the glycogen becomes depleted, the fats are oxidized without the aid of carbohydrates; and as a result, incomplete oxidation takes place, ketone bodies being formed. The child is now in a condition of acidosis, and his urine will contain acetone and also exhibit evidence of dehydration.

The remedy at this stage is water-and-salt solution. The sodium base of the salt solution makes up for that which has been lost in combination with the ketone bodies, for it is only in such a combination that they can be excreted.

In addition to dehydration and ketosis, an alkalosis can develop. As the child starts to vomit, he begins to lose chlorides continually, and therefore the *pH* of his plasma decreases, in consequence of which an alkalosis develops.

Thus the management of the child's pre-operative condition—and post-operative too—is as follows:—

1. Replacement of fluid by water (the urine must be kept at about S.G. 1·015).
2. Replacement of chloride by salt (suppression of urine indicates too much chloride).
3. Replacement of protein and blood by blood transfusion.
4. Replacement of glycogen by glucose (sugar in the urine indicates too much glucose).

Principles of Operation for Appendicitis in the Young.—

1. A McBurney incision should always be employed, for the same reasons as are given for its use in appendicitis in an adult. (*See* p. 860.)

2. The appendix should always be removed, if possible, for when perforation occurs, as it so often does, this is the only way to prevent fæcal and septic material from continually pouring into the peritoneal cavity. In cases where the appendix has become perforated and is not removed, the patients generally die.

3. Where there is any doubt whatever as to the need of drainage, it should be employed (*see* p. 859). Drains should be of the glove-rubber type; they should be placed lateral to the cæcum, and should if possible be screened from the small intestine by the omentum. Drains should be left in till about the ninth or tenth day. After the fourth day the tube should be shortened a little each day.

If the peritoneum is not drained, at least the wound should be.

4. Light ether is the best anæsthetic, because, if properly given, it enables the appendix to be removed without any disturbance of the small intestines. The danger of nitrous oxide is that the small intestines are forced into the septic appendiceal area.

5. When an abscess is palpable, it may be possible to approach it extraperitoneally, and the incision should be made to the outer side of the abscess. The appendix should not be removed unless it presents and can be easily dealt with.

INTUSSUSCEPTION OF THE NORMAL APPENDIX

Intussusception of the normal appendix can occur. Such an occurrence is, however, rare. The manifestations are those of colicky pain referred to the umbilicus, localizing finally over the cæcum, and cæcal tenderness—a clinical picture of a subacute appendicitic attack. (*Fig. 612.*)

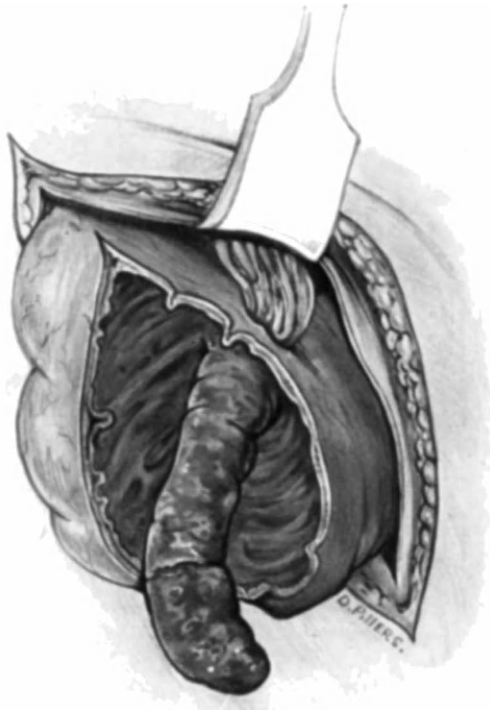


Fig. 612.—Intussusception of the normal appendix into the cæcum.* (By kind permission of Mr. G. T. Mowat and the 'British Journal of Surgery'.)

CARCINOID TUMOURS OF THE APPENDIX

Carcinoid tumours are found anywhere in the alimentary canal, but they occur most frequently in the appendix, where they are found, according to Dick and Illingworth, in 0·4 per cent of appendicular lesions.

They are thought to arise from cells of endodermal origin (chromaffin tissue) which are more liberally distributed in the region

of the lower part of the ileum and the appendix than anywhere else in the alimentary canal.

These tumours begin as a small yellow nodule or as an annular thickening anywhere in the submucous layer of the appendix. Their growth very soon closes the lumen of the viscus. Thus they usually become obvious as an obstructive appendicitis (*Fig. 613*), or as a mucocele—a tumour.

As malignant tumours, their main feature is their benignity. Only rarely

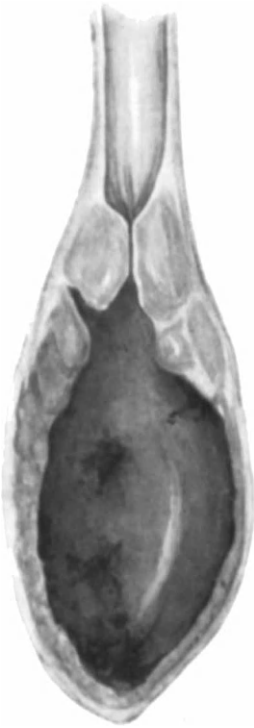

Fig. 613.—Carcinoid tumour in an early stage which caused an acute obstructive appendicitis.⁵ (By kind permission of Mr. Thomas Moore and the 'British Journal of Surgery'.)

do they form metastases in the glands and peritoneum.

Clinically they are never diagnosed. They come before the surgeon under the guise of an acute or subacute appendicitis; or as a mucocele when operating for a chronic appendicitis.

REFERENCES

- ¹ TRINCA, A. J., "Some Points in the Treatment of Appendicitis," *Med. Jour. of Australia*, 1935, Sept. 7, 308.
- ² MAES, BOYES, AND MCFETRIDGE, *Surg. Gynecol. and Obst.*, 1938, **65**, June.
- ³ DEEVER AND PARSONS, *Ibid.*.
- ⁴ MOWAT, G. T., "A Case of Intussusception of the Normal Appendix into the Cæcum", *Brit. Jour. Surg.*, 1938, Oct., 445.
- ⁵ MOORE, THOMAS, "Carcinoid Tumours of the Appendix", *Ibid.*, 310.

CHAPTER LXXIX

**ILEOCÆCAL MESENTERIC LYMPHADENITIS
AND REGIONAL ILEITIS****ILEOCÆCAL MESENTERIC LYMPHADENITIS**

A RECURRING ileocæcal adenitis of non-tuberculous origin is found occasionally in children from the age of about ten to sixteen. It can simulate surgical affections of the abdomen. It is not as a rule diagnosed, and is usually discovered at operation on a patient who is supposed to be suffering from acute appendicitis. The condition is often accompanied by a respiratory affection.

The glands which drain the lower part of the ileum, the cæcum, and the ascending colon—the glands in the ileocæcal angle—are the ones which are involved. Rarely these glands may be part of a more general abdominal lymphadenitis. According to Porrier, in his text-book of topographical anatomy, these lymph-glands are often found swollen in inflammatory conditions of the appendix.

The glands are dark red, enlarged, soft, and easily isolated, with no evidence of caseation or calcification. In a few rare cases, suppuration or even peritonitis may supervene. X-ray evidence of calcification, when present, indicates a tuberculous origin.

The nature of the infecting germ has not been determined.

In a few cases the appendix shows signs of inflammation, but in the great majority it presents no evidence of disease. The attacks are in many cases preceded by infective conditions such as tonsillitis; or by toxæmic symptoms—probably evidence of a hidden infection. The origin of the infection is probably the lower part of the ileum, the cæcum, or the appendix—the regions from which the glands receive their lymph drainage.

In the cases where I have operated on and removed the appendix, the condition has not recurred; and I have regarded this as evidence that the infection may have entered through this organ in the same way as it reaches the glands of the neck by way of the tonsil while leaving little trace in this structure.

Brown¹ describes chronic, subacute, and acute cases in 17·3 per cent of operations for acute appendicitis in children, and has studied

the disease in 23 cases, most of which he has followed over a period of years.

Although at first sight the clinical picture of ileocæcal mesenteric adenitis is that of an acute or subacute appendicitis, on closer examination there are distinctive differences. The tongue is not very furred, and the breath has not the smell characteristic of an appendiceal affection. The bowel function is not much disturbed. The pains are more generalized. The tenderness is diffuse and its main incidence is above and to the left of the appendiceal area. For the amount of tenderness, there is little *défense musculaire*—a fact which is significant of a retroperitoneal inflammatory affection. Occasionally the glands can be felt.

A knowledge of ileocæcal adenitis and its association with acute or subacute appendicitis is necessary to the appendicectomist.

REGIONAL ILEITIS

The following case-history is an example of an early stage of regional ileitis :—

A boy, aged 14, complained that for the past week he had a severe constant pain in the region of the umbilicus and towards the right side. His tongue had become furred. He found it more comfortable to walk with a stoop. His bowels had been regular. He was diffusely tender below and to the right of the umbilicus. His abdomen seemed rather full and his abdominal wall, in the lower part, was a little tender. He had no rise in temperature or increase in pulse-rate. There was a history of an accident three years previously, which was followed by pain in the region now affected.

At operation, the following condition was found :

1. Great enlargement of the ileocæcal mesenteric nodes—some as large as a walnut—the enlargement being obviously of inflammatory origin.
2. Beginning abruptly about six inches from the ileocæcal junction, a terminal ileitis, the intestine being intensely congested, almost plum-red, with thickened walls, so that it felt almost like a partially filled sausage.
3. A mild chronic inflammatory condition of the cæcal wall, with very little thickening.
4. A rather long, slightly twisted appendix, with a congestion of its walls of much the same extent as that of the cæcum.

This condition is an early example of what Crohn,² in 1932, described under the title of "Terminal Ileitis", "a disease of the terminal ileum affecting mainly young adults, characterized by a subacute or chronic necrotizing and cicatrizing inflammation. The ulceration of the mucosa is accompanied by a disproportionate connective-tissue reaction of the remaining wall of the intestine, a process which frequently leads to stenosis of the lumen of the

CHAPTER LXXX
**THE DIAGNOSIS OF DISEASES OF THE
 PROXIMAL COLON**

FOR clinical purposes, the colon may be divided into : (1) Proximal colon—cæcum, ascending colon, and hepatic flexure ; and (2) Distal colon—transverse colon, splenic flexure, descending and sigmoid colon.

In the diagnosis of diseases of the proximal colon, the first practical consideration, not only from the patient's but also from the surgeon's point of view, is the question of malignant disease. Therefore, as a matter of actual practice, it will be found that diagnosis in either the proximal or distal colon builds itself round the question of the presence or absence of carcinoma. Failure to diagnose an innocent condition may not carry with it any evil consequences for the patient ; but failure to recognize a malignant condition in its early stages is fraught with ill effects for him because, at this stage, it is in most cases curable by operation, for malignancy of the colon is usually relatively beneficent as compared with that of the stomach.

The Approach to the Surgical Diagnosis.—The approach to the surgical diagnosis of diseases of the proximal colon will therefore be : (1) A consideration of *malignant diseases* ; (2) A discussion of *innocent surgical conditions* which must be taken into account when making a diagnosis in regard to malignancy.

THE DIAGNOSIS OF MALIGNANCY

Greater clinical diagnostic accuracy will be obtained if malignant conditions in the proximal colon are regarded from the standpoint of : (1) The pathological types of malignancy ; (2) The usual clinical picture ; (3) A study of those unusual onsets and equivocal syndromes which are not usually recognized in their early stages.

I. THE PATHOLOGICAL TYPES OF MALIGNANCY

To the practising surgeon it appears as if two widely diverse distinct pathological types of malignancy are met with in both the proximal and the distal colon :—

a. A *proliferative, papillomatous type*, in which tumour formation is the main tendency and invasion a comparatively minor feature.

b. A *highly invasive type*, in which scarcely any proliferative tumour formation takes place, but in which invasion, and therefore contraction and obstruction, is the dominant feature of the growth.

The proliferative type, although it ulcerates and bleeds and causes gross ill health, is, from the point of view of local spread, not highly malignant, even though it may be a large tumour. The invasive type is, naturally, highly malignant.

It would also appear that between these two very outstanding types are found combinations and degrees of the proliferative and invasive tendencies.

Malignant Types seen in the Proximal Colon.—In carcinoma of the proximal colon, one finds clinically four distinct pathological entities, each of which gives rise to a distinctive clinical syndrome—at any rate in its early stages. These types are as follows :—

a. A proliferative tumour type of carcinoma, usually found in the cæcum.

b. An invasive type of carcinoma, seen in the ileocæcal valve.

c. A partly invasive and partly proliferative type (a common form), generally found in the ascending colon or the hepatic flexure.

d. An almost purely papillomatous type of carcinoma (a rare form) with practically no invasive tendency.

In general, these distinctive pathological types have a distinctive onset or cause a significant syndrome.

In the first, the early symptoms are those of bleeding and ulceration, constitutional ill health and profound anæmia; in the second, those of obstruction; in the third, those of colitis, ulceration, and perhaps of some obstruction; and in the fourth, early, a complete latency of symptoms, and, late, perhaps those of colicky pain, the result of a certain amount of intussusception of the tumour.

The Position of Papillomata in the Scale of Malignancy.—

In relation to the above types of malignancy, the place of multiple papillomata in the scale of malignancy should be considered. The multiple, so-called ‘innocent’ papillomata should be regarded as malignant—but as the most beneficent stage of a malignancy. Clinically they appear to be of the same nature as the ‘innocent’ papilloma of the bladder which so soon takes on malignant characters. I have seen first one of these colon papillomata, and then later another, and finally a third, become malignant—all primary malignancies. It is interesting to notice that these papillomata of the colon, like papillomata of the bladder, show a marked tendency to transplant. This

tendency to transplant is, too, seen rather frequently in the papillomatous type of carcinoma—a factor which must be considered in its surgical treatment.

2. THE USUAL CLINICAL PICTURE OF PROXIMAL-COLON MALIGNANCY

The typical proximal-colon malignancy can easily be recognized :—

The patient has been, without respite, slowly losing health and strength and becoming anæmic.

His general appearance gradually alters and he begins to look sick.

His bowels, which have always been regular, begin to lose this regularity, and he has to take a little medicine, probably for the first time in his life.

He occasionally has diarrhœa, for which no cause can be found.

He may have noticed blood in his stools.

He complains of a discomfort or fullness immediately after meals, gets some relief, and then some slight recurrence of the discomfort some hours after meals.

When this patient consults his doctor, a tumour can usually be felt on the right side of the abdomen; and a radiograph shows a definite deformation of the colonic walls with some filling defect.

This is the picture of carcinoma of the proximal colon seen in the majority of cases; but it is a picture of a *late stage* when surgical treatment may not be effective.

It is, however, the unusual onset and equivocal syndromes of malignant disease in this region which will repay study by enabling an earlier diagnosis to be made.

3. UNUSUAL ONSETS AND EQUIVOCAL SYNDROMES OF PROXIMAL-COLON MALIGNANCY

The Syndrome of the Proliferative Type of Carcinoma.—

A characteristic malignancy of the cæcum, and one which often gives rise to a confusing syndrome, is a large, ulcerating, bleeding growth—a proliferative type of carcinoma.

The patient may come under notice because he is thought to have a carcinoma of the body of the stomach, or because it is thought that his is a case of pernicious anæmia. He has perhaps a slight dyspepsia coming on a few hours after meals; has been losing some weight and getting very pale; has been rapidly losing energy and strength; has a slight disturbance of the function of his bowels. In the belief that he has a gastric carcinoma a radiographic examination of his stomach may have been made, when no cause for his trouble was found.

Examination may reveal a palpable tumour, but it is curious that in some cases no tumour is felt.

The patient may have attacks of diarrhœa, and blood will usually be found in his stools.

In these cases, a diagnosis may not be made, because the cæcum has not been carefully examined; the radiologist, being satisfied that he has relieved the patient when he has not found a carcinoma of the stomach, does not meticulously X-ray the cæcum.

The diagnosis, of course, rests on the finding of occult blood and of a filling defect in the cæcum, which may require 'dosed compression' after the method of Berg to demonstrate.

The Syndrome of the Invasive Type of Malignancy.—In the form of malignancy which usually occurs in the ileocæcal valve is seen the invasive type of malignancy. The patient may be operated on because it is thought that he has an appendicitis. He complains of colicky pains in the appendiceal region; has slight distension; no constitutional signs—rise of temperature or pulse-rate—indicating an inflammation; has perhaps a diffuse and slight tenderness in the right iliac fossa; but has no palpable tumour as the growth is highly invasive.

Even when such a case comes to operation as a supposed chronic appendicitis, the invasive scirrhous growth may pass unrecognized, as is seen in the following case-history:—

A patient complained of the symptoms above described. A diagnosis of chronic appendicitis was made and the appendix, which was obviously not diseased, was removed. Some few months later the patient was readmitted to hospital with acute intestinal obstruction, the cause of which was a scirrhous carcinoma of the ileocæcal valve. The extent of the growth showed that it must have been there at the time of the appendiceal operation, must therefore have been the cause of the symptoms which led to the diagnosis of appendicitis, and must have been missed by the surgeon.

The Syndrome of the Proliferating and Invading Type of Carcinoma.—The type of carcinoma which occurs in the ascending colon is as a rule of the kind that is both proliferating and invading, and it gives the syndrome usually seen (p. 891).

The early symptoms usually start with a mild dyspepsia, coming on about two or three hours after a meal; with a slight irregularity in the function of the bowel, where this function has always been regular; with attacks of unexplainable diarrhœa; and with a slight but *progressive* failure of health.

Obstructive symptoms are only seen late in the course of the disease; and tumour formation is not a prominent feature in the early stages.

A barium enema or a barium enema followed by injections of air should show very distinct evidences of this type of carcinoma, because of its invasion of the colonic wall, which causes considerable contraction and therefore disturbance of the contours of these walls—disturbances of contour which show up very clearly in a properly made radiograph.

When this form of carcinoma occurs at the hepatic flexure and begins to cause obstruction, the symptoms and signs may be equivocal and like those of appendicitis; that is, pain and a *diffuse tenderness* in the right iliac fossa. For example:—

A man, aged 50, complained of symptoms similar to those of appendicitis. His temperature was 100° and his pulse-rate 90 (due in this case to the ulcerating growth). He was diffusely tender over the appendiceal area. A radiograph showed a long and greatly dilated appendix (nine inches long and nearly half an inch in diameter). A diagnosis of appendicitis was made and the appendix removed. A short time later it was discovered he had a growth at his hepatic flexure causing obstruction: it was the symptoms of the obstructive dilatation of the cæcum and the appendix which had caused the appendicitis-like clinical picture.

The Syndrome of the Papillomatous Type.—The truly papillomatous type is extremely difficult to recognize in its early stages.

It is not invasive and therefore produces little disturbances of the contours of the bowel, so that it is not easily detected by X rays. Thus the filling defect that it causes may in a routine examination pass unnoticed because it is so like that which can be caused by a faecal mass.

It does not ulcerate or bleed, and therefore does not shed blood or pus into the fæces.

It is not readily palpable.

When it grows to a fair size it begins to give rise to symptoms; and these are colicky pains (perhaps caused by attempts of the bowel to expel the lump in its wall), generally in the left side of the abdomen.

The following is an example of this form of colonic growth:—

A patient complained of mild colicky pains over the region of the sigmoid. He showed no constitutional disturbance and no alteration in the function of his bowel. He had been attending doctors for eighteen months and had been X-rayed many times without obtaining a diagnosis.

A barium enema followed by injection of air showed that he had a papilloma-like carcinoma at the beginning of the transverse colon. Some intussusception had apparently taken place towards the sigmoid, and this was probably the cause of the left lower abdominal pain.

Summary of Clinical Onsets.—The clinical onsets of malignant disease of the proximal colon may be summarized as follows :—

- a. A palpable *right-sided abdominal tumour*.
- b. '*Appendicitic*', appendiceal symptoms and signs.
- c. '*Dyspeptic*', the dyspepsia being investigated in the belief that it is caused by a carcinomatous stomach.
- d. *A profound anæmia* and ill-health.
- e. *Left-sided pain*.
- f. The symptoms of *chronic intestinal obstruction*.
- g. The symptoms of *acute intestinal obstruction*.
- h. Unexplained attacks of *diarrhœa*.
- i. *A latency of symptoms*, the first manifestation being the finding by the patient of dark-brownish blood in his fæces.

The Radiographic Onsets.—The radiographic onset of malignant disease of the proximal colon may be :—

- a. Evidence of chronic intestinal obstruction : signs of '*pooling*' in the small intestine, shown by the presence of *rests* of barium ; an intestinal *ladder pattern*, seen with a plain radiograph.
- b. Disturbance of contour of the colonic walls—*deformation of the colonic wall*.
- c. The presence of a *filling defect*.
- d. In the case of ileocæcal carcinoma, it may be possible to demonstrate the *obstruction* by giving the patient a barium enema, putting him on his left side, and photographing the ileocæcal valve under compression in various positions (the left-sided position is used to facilitate the passage of the barium through the ileocæcal valve).

THE DIAGNOSIS OF INNOCENT CONDITIONS

Having dealt with the diagnosis of malignant conditions of the proximal colon, the ground has been cleared for the discussion of the diagnosis of those of an innocent nature which exist in this region, or are associated with it, and which, from a practical point of view, will show up more usefully on the background of the diagnosis of proximal-colon malignancy which has just been considered.

The diagnosis of these innocent conditions will therefore be dealt with mainly along the lines of the clinical pictures caused by malignant growth of the proximal colon—a further clinical effort to solve an important practical problem, namely, the early recognition of malignant colonic disease.

Innocent conditions of or related to the proximal colon are considered under the following headings : (1) Right-sided abdominal tumour ; (2) Right-sided abdominal pain ; (3) Progressive anæmia

and ill health; (4) Unexplainable attacks of diarrhœa; (5) Blood in the fœces coming from the colon (proved by sigmoidoscopic examination).

1. Right-sided Abdominal Tumour.—

Chronic Proliferative Appendicitis.—A chronic proliferative appendicitis can cause a tumour, which can be as large as an orange, is not tender, infiltrates the tissues surrounding the colon and the abdominal wall, is hard and fixed like a carcinoma, and which may be in existence from three to five months (*see* p. 842). A tumour of this nature is not uncommon, and has been the cause of many serious mistakes, that is, unnecessary partial colectomies.

An example of such an inflammatory tumour is the following :—

A man, aged 55, was operated on by a good surgeon in a country town for a tumour of the right side of the abdomen situated in the vicinity of the cæcum. The surgeon found a large, hard, infiltrating tumour, which he diagnosed as undoubtedly carcinoma. He decided that it was too adherent to remove and gave the patient a diagnosis of inoperable carcinoma. It was possible to demonstrate that it was a chronic inflammatory, proliferative appendiceal tumour, and to remove the offending appendix (in the circumstances a feat of considerable difficulty).

The X-ray appearance in these chronic inflammatory appendiceal tumours is different from that of a malignancy in that it does not show anything like the extensive typical deformation of the cæcal wall that is found in a carcinomatous tumour of the proportions indicated by palpation.

Chronic Retrocæcal Appendiceal Abscess.—It is not uncommon for a *very chronic abscess* to form round a retrocæcally situated appendix, and constitute a hard, firm tumour.

In the case of such an abscess, which may exist for many months, the walls become very thick and hard and lose their inflammatory sensitiveness; and the abscess itself pushing the cæcum forward forms a hard firm fixed tumour, which being insensitive is, clinically, very like a malignant tumour.

Ileocæcal Tuberculosis.—An ileocæcal tuberculosis is not difficult to recognize: there are signs and symptoms of a disturbance of the small and large intestine—diarrhœa, etc.; the constitutional disturbances which go with an infection of the tuberculous type; and signs of tuberculosis in other parts of the body.

Ileocæcal Tuberculous Adenitis.—Tuberculous glands in the region of the ileocæcal junction can form an almost insensitive tumour giving rise to only mild constitutional symptoms.

Hydatid of the Abdominal Wall.—A hydatid of the right side of the abdominal wall will often give the impression to the palpating

hand that it is situated in the abdominal cavity and possibly in the proximal colon.

Desmoid Tumour.—A hard, insensitive, infiltrating tumour may be found over the cæcum in the scar of an appendiceal operation. Such a tumour—a desmoid—is very similar to a carcinoma of the cæcum.

Chronic Abscess in an Appendiceal Scar.—Occasionally a chronic abscess forms in an old appendiceal scar around a fragment of silk-worm gut or silk which has unintentionally been left in the wound. Such an abscess is confused with carcinoma of the cæcum.

Renal Tumours.—Enlargements of the kidney are distinguished clinically by the fact that they give rise to renal symptoms, liberate pathological products into the urine, and usually (if they involve the ureter) cause irritation of the bladder—frequency of micturition, and other symptoms. They are distinguished radiographically by the fact that they are nearly always recognizable by the various modifications of pyelography (intravenous and retrograde), and by the relation of the palpable tumour to the pyelographic shadow, or the disposition of the pyelographic shadow when the tumour is displaced.

It must, however, be remembered that in some cases renal tumours do not open into or deform the pelvis of the kidney, and therefore do not give rise to renal symptoms or permit pyelographic recognition.

Gall-bladder Tumour.—A tumour can be caused by a stone quietly becoming impacted in the cystic duct. It can arise without pain and jaundice, and extend down so that it lies over the proximal colon. It may not be tender.

2. Right-sided Abdominal Pain.—Innocent disease of the proximal colon which may cause right-sided abdominal pain may be catalogued as follows:—

- a. Chronic and subacute appendicitis.
- b. Reflected pressure from an obstruction of the sigmoid (innocent or malignant) (*see* p. 907).
- c. 'Painful cæcum', the result of stasis, ptosis, chronic volvulus at the ileocæcal junction, ileal kinks, and developmental defects in this region.
- d. Diverticulum of the cæcum (with peridiverticulitis).

A patient had a hard firm tumour in the region of the cæcum. It was tender. A radiograph showed that he had a large diverticulum of the cæcum in this region. Operation showed that the tumour was a normal kidney ectopically situated. The tenderness was due to the inflammation of the diverticulum which lay over the displaced kidney.

Conditions associated closely with the proximal colon which may cause right-sided pain are: (a) Ureteral obstruction; (b) Pelvo-ureteral obstruction in the kidney; (c) Chronic gall-bladder conditions; (d) Ileocæcal adenitis.

3. Progressive Anæmia and Ill Health.—Affections which give rise to progressive anæmia and ill health, and which must be considered in relation to a cæcal malignancy, are carcinoma of the fundus of the stomach and of the body of the pancreas, and the various forms of anæmia, particularly pernicious.

4. Unexplainable Attacks of Diarrhœa.—As has been pointed out, attacks of diarrhœa persisting over a period of two or three months may be the first indication of a growth in the proximal colon, but unexplainable attacks of diarrhœa may be the beginning of an ulcerative colitis.

Ulcerative Colitis.—Clinically it should be possible to distinguish between diarrhœa from this innocent cause and that from a malignant cause. In the former the fæces contain much pus and mucus and little blood; the patient complains of tenesmus; the sigmoidoscope reveals the pathological characteristics of ulcerative colitis in the mucous membrane, and a barium clysma demonstrates the absence of haustral formation in the colon. In the latter the fæces contain much blood and little pus and the patient suffers from a considerable constitutional disturbance and a rapid general deterioration. A radiograph may show positive evidence of a malignancy.

5. Blood in the Fæces Coming from the Colon.—Blood in the fæces coming from the colon (proved by the sigmoidoscope), as has been pointed out, at once raises the question of malignancy. It may also come from multiple papillomata of the proximal colon (and from the distal colon, too). However, this so-called innocent tumour, usually regarded with equanimity, should be regarded as a pre-malignant condition, if not as an actual 'beneficent' malignant one.

Therefore blood in the fæces unassociated with a gross amount of pus cannot be taken as indicative of any innocent disease: it must, provisionally, be regarded as strong circumstantial evidence of a malignant growth.

CHAPTER LXXXI

PRINCIPLES UNDERLYING OPERATION FOR CARCINOMA OF THE PROXIMAL COLON

THERE are two main types of malignant disease which must be considered in relation to the principles governing operation on malignant disease of the colon : the proliferative and the invasive.

AN OPERATION FOR CARCINOMA OF THE PROXIMAL COLON IN VERY ILL CASES

In the *proliferative* type of malignancy, already described, a large tumour, which bleeds and ulcerates, forms. The patient becomes exceedingly sick and ill, and has practically no healing power in his colonic wall.

Although the effects of the ulceration and bleeding of this type of tumour are profound, and although because of its size the tumour appears inoperable, nevertheless, the malignancy is not as bad as it looks ; for usually it is not very invasive and therefore it is only locally malignant.

An operation that removes the tumour generally cures the patient.

It is in cases such as these that I think the following procedure will enable a curative operation to be carried through with safety ; whereas an ileo-sigmoidectomy carried out on the orthodox lines may kill the patient—a patient who is probably curable.

PRINCIPLES OF THE OPERATION

The principles on which the procedure is based are :—

1. The ulcerating and infected tumour, the cause of the anæmia and ill health, is resected at a first operation stage.
2. The principle of Paul is utilized to establish bowel continuity.
3. The spur is crushed at the time of the operation and the bowel ends are sutured round the enterotome with the exception of a small opening in the ileal end, which serves as an enterostomy for the emptying of the bowel until the enterotome makes a connexion between the two intestinal segments.
4. The small enterostomy and colostomy left are, with the aid of local anæsthesia, subsequently closed.

Technique of the Operation.—The steps of the operation in their order are as follows :—

1. Through a paramedian incision the ileocolic segment—the terminal part of the ileum, the cæcum, ascending colon, and hepatic flexure—is mobilized in the usual way, but mobilized *very extensively* (Fig. 615).

2. A *four-inch* section of the ileum is sutured to the transverse colon.

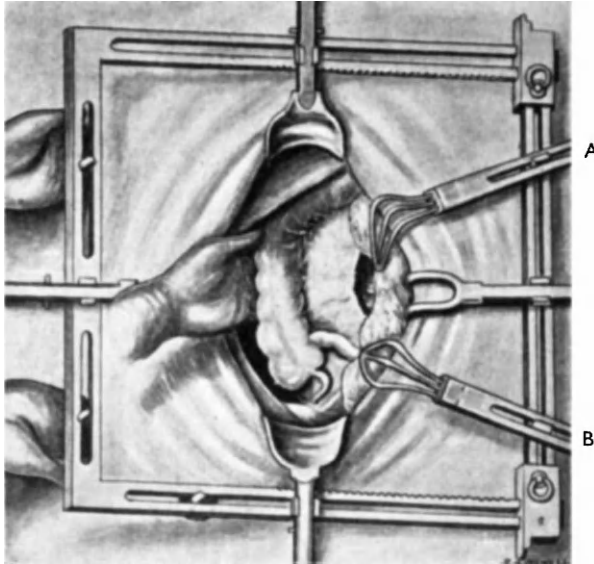


Fig. 615.—Retractor locked in wound and firmly clamping on protective towels. Mechanical hands (A, B) incarcerate the small intestine, covered with gauze veils. With two hands the assistant lifts the side of the retractor and so lifts the abdominal wall away from the ascending colon. This exposes to view the peritoneum lateral to the colon, which is incised. The colon stripped up by the surgeon's left hand is brought to the midline. (Figs. 615, 616 from 'The Lancet'.)

3. The mesenteric leaf (with any contained glands), pertaining to the segments of bowel to be removed, is resected (made possible by the extensive mobilization).

4. Any peritoneal defects in the abdominal cavity are closed.

5. The parietal peritoneum is meticulously sutured around the neck of the loop of bowel to be removed.

6. The segments are amputated, leaving some redundancy of the ends (Fig. 616).

7. The enterotome (a very long one) is applied (Fig. 644, p. 957).

8. The ends of the bowel are closed.

9. As soon as the anastomosis is established, the small openings in the bowel are closed. (If this is done very early after the operation and before much inflammatory thickening in the bowel sets in, the bowel wall turns in easily and is therefore readily sutured.)

10. Any fistulæ that remain are subsequently closed under local anæsthesia.

11. Months later, when the patient is well, with the object of avoiding a hernia the closed bowel ends can be sunk under the muscles, and these latter coapted.

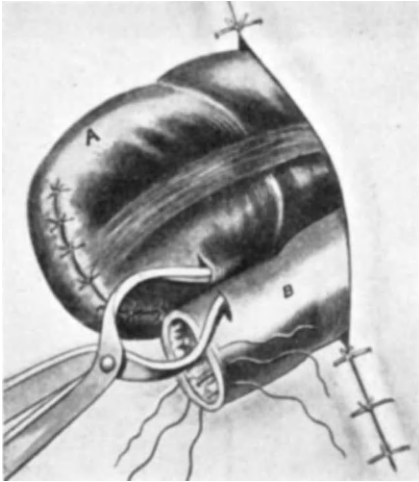


Fig. 616.—Ileocolotomy. A, Protruding end of transverse colon closed with sutures. B, End of ileum partially closed. The blades of the clamp are shown inserted into two small openings made near the ends of the bowel. Subsequent experience has shown that this is not an advantage; it is better to bring the enterotome blades out through the corners of the cut ends.

The following is a case-history which shows the practical value of this operation :—

A man, aged 54, suffering from a very large ileocæcal carcinoma was so emaciated and enfeebled that I scarcely entertained the thought of exploring the abdomen. The anæsthetist gave as his opinion that he would probably not tolerate an anæsthetic even for exploration. To my surprise, at an exploration I found that the growth was operable. Ten minutes sufficed to strip up the diseased segment of colon from the posterior abdominal wall and fix it as a loop through the loosely sutured abdominal wound. The remainder of the operation—the reconstitution of the continuity of the bowel—was

done in the patient's bed without even local anæsthesia. This man left the hospital in seven weeks with a completely healed wound. He is now, ten years later, well.

This operation is of value in another group of cases—at any rate in the hands of the average surgeon, that is, in cases where a long tedious dissection to free an extensive growth is necessary, and where therefore an added ileocolonic anastomosis would turn the scale against the recovery of the patient.

The following case-history is an illustration of the application of this procedure :—

Twelve months previous to admission to hospital, a patient had been operated on for a carcinoma of the hepatic flexure of the colon. The

growth was considered inoperable. As the patient had remained in fair health I was asked to make a special attempt to remove it. I spent over two hours on a very extensive careful dissection. Time, of course, was necessary, and that was all required for the dissection; no time could be spared for an anastomosis. Therefore, after the diseased segment was removed, the ends of the bowel were left in the way described above. The operation was subsequently completed in bed.

THE STANDARD OPERATION FOR CARCINOMA OF THE PROXIMAL COLON (ILEOCOLECTOMY)

The standard operation of ileocelectomy as given in text-books is suitable for the *invasive* type of carcinoma in which a wide block dissection is necessary, and in which the tissues of the patient have still a fair reparative function.

The principles on which it is based are sound: ligature of the arterial supply and resection of the terminal part of the ileum, and the cæcum and ascending colon; and the construction of a lateral anastomosis between the ileum and the transverse colon.

The operative mortality, however, of this type of operation in average hands is surprisingly high. Investigations have convinced me that the mortality-rate is sometimes as high as 35 per cent. On the other hand, inquiries indicate that the mortality-rate in the hands of a skilful surgeon is much lower.

The reason for this difference is probably that the skilful surgeon, when making the anastomosis, understands better the principles on which the operation should be based, and especially how to avoid contamination from septic bowel contents.

The principles underlying the performance of ileocelectomy should be:—

1. The placing of the incision so that it fully exposes the vascular pedicle of proximal colon.
2. The taking of special precautions to avoid peritoneal soiling by the grossly septic contents of the bowel segments.
3. The taking of special care to prevent soiling of the abdominal wall.
4. The drainage of the small intestine, which is very often the subject of chronic obstruction.
5. The implantation of the ileocolic anastomosis in an 'omental nest'.
6. Adequate drainage of the *region* of the anastomosis.
7. Meticulous closure of the peritoneal defects on the posterior abdominal wall.

1. The Incision.—Ileocelectomy should be performed through a paramedian incision, one which has for its centre the root of the

ileocolic artery, for this is the critical part of the operation area—the part where the greatest difficulties (dissection of glands and arteries) may be encountered.

If the operation frame (*see* p. 899) is used the lateral side of the proximal colon can be exposed to view, incised (there are no vessels in this position), and the ileocolic segment stripped to the midline.

2. To Prevent Soiling of the Peritoneum.—The art of avoiding soiling of the peritoneum when making the anastomosis is a large factor in the safety of the operation. Refinements in this respect are :—

a. By means of ‘guy-rope’ sutures to elevate the anterior intestinal wall away from the posterior.

b. When opening the bowel segments to incise to the seromuscular layer first, leaving the mucous membrane intact.

c. To incise the mucous membrane with the diathermy knife so as to avoid moving it and therefore touching intestinal contents.

d. To stop any bleeding vessels by pinching them with the dissecting forceps to which is contacted the coagulating diathermy current.

e. To leave the mucous membrane edges unsutured, coapting only the seromuscular edges (using an atraumatic needle with the finest catgut) by *interrupted sutures*, each suture being held up by a forceps so that the mucous membrane drops away and allows the succeeding suture to be inserted without touching the mucous membrane.

f. When the whole row of sutures is inserted, to lay a wet pad soaked in 1-500 acriflavine solution over them for ten minutes.

A skilful surgeon can insert the sutures without touching the septic contents and without allowing the sutures to touch soiled intestinal mucosa—a manœuvre that means a great deal in the avoidance of soiling the peritoneum.

3. To Prevent Soiling of the Abdominal Wall.—Before the bowel segment is touched the edges of the wound in the abdominal wall must be covered, without the possibility of disarrangement, with impermeable material. The only method that I know for avoiding disarrangement is the use of the operating frame, as illustrated on pp. 331-335. This instrument clamps a cover to the wound as far as the peritoneum, so that it is almost impossible to disturb the wound covers and therefore to contaminate the wound with intestinal contents. The impermeable wound covers are best made by a sheet of cellophane between layers of gauze.

4. Drainage of the Small Intestine.—A small enterostomy should be made. In making this a No. 12 or 14 rubber catheter should be

used ; the catheter passed through omentum laid between the parietal peritoneum and that part of the small intestine which is anchored to the abdominal wall to form the enterostomy (*see* p. 796) ; and the parietal sutured to the visceral peritoneum around the opening in the bowel. The tube is passed through an omental screen in order to facilitate the closure of the enterostomy when the tube is removed.

5. Implantation of the Anastomosis in an 'Omental Nest'.

—When made, the anastomosis can be loosely wrapped round with omentum so that it lies almost completely enclosed in an omental sac.

6. Adequate Drainage.—One part of the above-mentioned omental sac is left open and connected externally by rubber tissue through an opening left in the abdominal wound. Thus any exudate or leaking bowel content will eventually find its way to the surface, while at the same time the tissue (a foreign body) is not close enough to the anastomosis to interfere with its healing. The tube should, however, be left in a few days longer than necessary so that there will be a potential weak spot in the wound which will automatically break down and allow drainage if, subsequent to its removal, anything should go wrong with the anastomosis.

7. Closure of Peritoneal Defects in the Posterior Abdominal Wall.—Infection of the retroperitoneal plane of tissue is a fruitful source of trouble in ileocelectomy ; for, as pointed out on p. 380, it is most vulnerable to infection. To avoid this source of trouble, peritoneal defects must be meticulously closed, or if this is impossible, the bare space should be drained through the loin.

**ILEO-TRANSVERSE-COLOSTOMY AS A FIRST-STAGE
OPERATION WHERE THE PATIENT'S GENERAL
CONDITION IS BAD**

Where, as a result of the growth, the patient's general condition is too bad to permit removal, ileo-transverse-colostomy may be carried out as a first-stage operation. As a palliative operation it is not a very good one, for it exposes the patient to all the risks of a colonic anastomosis made in the presence of tissues metabolically profoundly altered by the cancerous toxins of a late growth. In such circumstances, tissue repair of the septic bowel segments is most precarious. Further, by the time the second-stage operation can be approached with any degree of safety, a growth which could cause such ill health, and which because of size is growing much faster than a smaller growth, will have spread beyond the bounds of removal.

In such a case, it is much better rapidly to resect the growth as described and restore continuity on Paul's principle (*see* p. 898)—that is, to aim at saving the life of the individual regardless of the inconvenience that a temporary enterostomy may cause him.

**ILEO-TRANSVERSE-COLOSTOMY AS A FIRST-STAGE
OPERATION WHERE THE GROWTH IS
ASSOCIATED WITH OBSTRUCTION**

Ileo-transverse-colostomy as a first-stage operation where a growth of the proximal colon is associated with gross obstruction, where, for instance, there is a growth in the ileocæcal valve of the sclerosing type, is based on sound principles.

In this case the patient should be prepared beforehand with intravenous injections of salt solution with a view to combating the alkalosis. He should also have the post-operative treatment usually employed after operation for acute obstruction in a small intestine, that is, continuous intravenous infusion of fluid containing the normal salts of the blood, with a small excess of sodium chloride, and with 5 per cent of glucose.

The growth will then be resected when the patient has recovered from the intestinal obstruction.

CHAPTER LXXXII

**DIAGNOSIS OF DISEASES OF THE DISTAL COLON
AND RECTUM (UPPER PART)**

THE diagnosis of diseases of the distal colon and rectum (upper part) is best considered as a single problem, because the symptoms and signs of affections of the lower end of the sigmoid and the upper end of the rectum must necessarily be of a somewhat similar nature.

As in diagnosis of disease of the proximal colon, so in that of the distal colon and rectum, the first and the most important practical consideration is the question of a malignant condition—ot at least of its exclusion; and a discussion of the diagnosis of the innocent diseases of the distal colon and rectum is of importance in regard to their similarity or otherwise to the syndromes of malignant disease.

Thus such a discussion should serve as a further aid in clarifying a diagnosis in regard to malignancies in this region which are a frequent and serious problem, and which are not diagnosed in their early stages although they give rise to recognizable syndromes.

DIAGNOSIS OF MALIGNANCY

The diagnosis in the distal colon and rectum may be considered in relation to: (1) The pathological types of growth; (2) The usual clinical picture; (3) A study of the unusual onsets and equivocal syndromes.

1. TYPES OF GROWTH

The pathological types of growth are much the same as in the proximal colon; but unlike the latter growths, the proliferative type is not usually seen in the distal colon—it is the exception. The invasive type with more or less tumour formation, and with more or less obstruction, is the one most frequently found.

2. THE USUAL CLINICAL PICTURE OF CARCINOMA OF THE
DISTAL COLON OR RECTUM (UPPER PART)

In many cases, the diagnosis of a carcinoma of the distal colon or upper part of the rectum is obvious. The patient has had a definite onset of ill health, and of an unhealthy appearance, both of

which are progressive. His bowel function has become irregular. He has manifestations of a chronic obstruction—mild distension, colicky pains, borborygmi, all relieved by enemas and passage of flatus. He may complain of *tenesmus*—frequent desire to defæcate, with very little result, except perhaps a little pus and mucus. The fæces, taken from high up in the rectum with the sigmoidoscope, to obviate any focus of lower rectal or anal canal bleeding, may show *much* blood and perhaps a little pus. A tumour may be felt abdominally or rectally. Barium enemas may show deformation of the wall of the sigmoid or a filling defect.

Such a clinical picture—not an uncommon one—is obviously a malignant growth and does not require discussion. It is usually caused by a growth in which tumour formation and invasion are equally represented.

The symptoms and signs, too, of growths in that part of the rectum which can be reached with the fingers are so definite and well known and so easy to recognize that the diagnosis of this condition in this region does not need detailed consideration.

The diagnosis of a malignancy of the distal colon, however, is usually less simple than above described; for onsets less characteristic of malignant disease in this region are not nearly so easy to recognize.

3. STUDY OF THE UNUSUAL ONSETS AND EQUIVOCAL SYNDROMES

The Latency of a Malignancy.—It is well known that, except for a little almost unnoticeable progressive deterioration of health, in many cases there may be no manifestations whatever to indicate the presence of a carcinoma.

Blood in the Fæces.—The finding of blood in the fæces by the patient may be the first indication of the proliferative type of growth. It is in this bleeding type that a tumour—a proliferative growth—should be palpable in the left iliac fossa; but it cannot always be felt. As a rule, in the early stage of such a growth there is little obstruction and therefore little disturbance of the bowel function. For example:—

A doctor noticed that, over a period of a month, when he used the toilet paper after stooling, the fæces on it showed an admixture of bright blood. His bowels were regular and his health was good.

A radiograph showed no invasive contraction of the colonic wall but a very definite filling defect in the lower sigmoid—one so limited and sharp-edged that it was regarded as being due to a papilloma. Operation disclosed a carcinoma of the sigmoid of the papillomatous proliferative type.

Onset with Dyspepsia.—Not infrequently the advent of an obstructive distal-colon carcinoma is marked by a dyspepsia. This carcinoma interferes with emptying of the colon; and thus, as pointed out on p. 89, reflexly disturbs the emptying of the gastric segment, thereby causing a fullness and discomfort after meals—a mild painless dyspepsia.

Onset of Acute Intestinal Obstruction.—The first sign of a distal-colon carcinoma may be the sudden onset of an acute intestinal obstruction of the large-bowel type—complete constipation and great distension. This is seen in the growth which is almost entirely invasive and contractive, in which there is almost an entire absence of tumour formation. In this type bleeding does not usually occur, and cancerous cachexia and ill health are in its early stages not seen; and therefore its early symptoms may not attract the patient's attention.

Onset with Chronic Obstruction.—The first evidence of a malignancy may, however, be a chronic obstructive syndrome: dyspepsia, indefinitely localized; colicky pains; progressive chronic constipation; mild distensions.

Onset with Right-sided Symptoms.—In the invasive type of growth, where obstruction is a marked feature, the patient may be sent into hospital because he complains of symptoms like those of appendicitis—*diffuse* pain and *diffuse* tenderness over the right lower quadrant of the abdomen.

I have operated on several cases of carcinoma of the sigmoid in which the patients have had an operation for a supposed appendicitis a few months previously (the cæcal pain of an obstructed sigmoid).

The basis of right-sided symptoms in obstructive carcinoma of the sigmoid is probably due to the fact that the action of intracolonic pressure in its early stages is most effective—and therefore painful—on the thin-walled cæcum. Dr. Crawford Mollison (personal communication) has seen sudden death occur as the result of a ruptured cæcum in a case of obstructive carcinoma of the sigmoid.

Accordingly, when in an appendiceal operation on a patient in the cancer age the appendix is found undiseased, the surgeon should never fail to explore the sigmoid.

Onset with Hæmorrhoids.—Not infrequently the first manifestation of carcinoma of the lower part of the sigmoid is a rather sharp onset of hæmorrhoids which gradually get worse. Many cases of sigmoid carcinoma which come to operation have had an operation for hæmorrhoids a few months previously.

Onset with Urinary Symptoms.—Frequency of micturition and dysuria (without much evidence of inflammatory disturbance—

pus, etc.) may be the earliest symptoms of an extensively infiltrating carcinoma of the lower end of the distal colon or the upper part of the rectum. A young man was sent to a urologist (Dr. H. Mortenson) because he had frequency of micturition, dysuria, and some disability in regard to the urinary stream, but no pyuria. The urologist found that he had a stricture of the left ureter. I saw the patient in consultation to confirm the fact that he had an almost entirely invasive, widely infiltrating carcinoma of the upper part of the rectum, which had first manifested itself by urinary symptoms.

Onset with Frequency of Defæcation.—Often the earliest manifestation of carcinoma of the lower sigmoid or upper part of the rectum is a frequent desire to defæcate (analogous to frequency of urination). The lump in the wall of the bowel probably acts in the same way as a lump of fæces in giving rise to an afferent impulse which affects the defæcatory reflex arc. It is the repeated efforts of the patient to defæcate when the rectum is empty that causes a discharge of pus and blood from the ulcerating growth—the spurious diarrhœa of the text-books.

Tumour of the Left Iliac Fossa.—Occasionally a tumour of the left iliac fossa, discovered on making a routine examination, is the only manifestation of a malignancy of the colon. This tumour may not be the growth itself, but hard fæces accumulated above an obstructive carcinoma.

Carcinoma of the Distal Colon with Signs and Symptoms of a Rectal Carcinoma.—Not infrequently a patient will complain of constipation, of tenesmus, of the presence of mucus and blood, and when he is examined what appears to be a definite carcinoma of the rectum itself is found almost presenting at the anus. No question in regard to the situation of the growth occurs. The surgeon proceeds to operate from the perineum and, when the operation is almost finished, finds that there is no carcinoma in the rectum but that the growth is situated perhaps in the middle of the sigmoid.

What has happened is that a lumpy proliferative carcinoma of the sigmoid has been the peristaltic stimulus to cause an intussusception so that the growth itself almost presents at the anus and therefore gives the impression of a carcinoma of the lower part of the rectum.

To know that a carcinoma of the sigmoid can present at the lower part of the rectum is important because of the fact that it causes grave mistakes to be made in regard to the proper approach to a carcinomatous growth. It is approached from the perineum and not from the abdomen, often with serious consequences to the patient.

CRITERIA FOR THE DIAGNOSIS OF CARCINOMA OF THE DISTAL COLON

1. The onset of progressive ill-health associated with local symptoms and signs which indicate an affection of the distal colon.
2. The onset of an unexplainable dyspepsia.
3. Indications of a mild large-bowel obstruction.
4. The presence of occult or visible blood in fæces obtained by the sigmoidoscope from the lower end of the sigmoid.
5. X-ray findings: signs of a 'filling defect', and of invasive deformation of the colonic wall.
6. A sigmoidoscopic examination, the field of which is limited because it cannot reach the growth.
7. A bimanual examination. This examination, made on a proper operation table with the patient in the lithotomy position, the body flexed acutely on the thighs, is more likely to reveal a tumour, or an unnatural sense of resistance, than the ordinary method of trying to palpate the tumour from the abdominal wall only.

DIAGNOSIS OF INNOCENT CONDITIONS OF THE
DISTAL COLON AND RECTUM

As indicated, the manifestations of these will be considered in relation to the various phases of malignant disease.

INNOCENT CONDITIONS CONSIDERED IN RELATION TO
FREQUENT DEFÆCATION—TENESMUS

Ulcerative Colitis.—In relation to frequent defæcation, tenesmus, and diarrhœa with pus and blood in the stools—typical manifestations of a carcinoma of the lower end of the sigmoid—ulcerative colitis must always be regarded as a consideration; for it is not uncommon for this condition to be confused with carcinoma of the lower end of the distal colon.

Ulcerative colitis, however, is easily recognized. A sigmoidoscopic examination will reveal a swollen, œdematous-looking mucous membrane, which bleeds easily, and which may be studded with little patches of lymph or points of ulceration. A radiograph will show the characteristic loss of haustration.

INNOCENT CONDITIONS CONSIDERED IN RELATION TO BLOOD
FOUND IN THE FÆCES

Multiple Papillomata of the Colon and Rectum.—In relation to blood found in the fæces (without pus) and proved to be coming from the colon, when it does not arise from a carcinoma, it is more

likely to be caused by single or multiple papillomata of the colon than by any other innocent condition. Papillomata of the colon, however, should be regarded as the first stage of a 'beneficent' malignancy.

From this point of view, therefore, one must regard blood in the fæces (coming from the distal colon) as in most cases an indication for operation.

The *X-ray diagnosis* of multiple papillomata depends upon the fact that they give rise to multiple filling defects. In the case in which the papilloma is single, it is difficult to distinguish radiographically from the papillomatous type of carcinoma.

INNOCENT CONDITIONS CONSIDERED IN RELATION TO OBSTRUCTIVE MANIFESTATIONS

Innocent conditions of or around the distal colon or upper part of the rectum which give rise to obstruction either chronic or acute, and which may be confused with invasive obstructive carcinoma, are as follows: (1) Diverticulitis; (2) Acute or chronic pelvic appendicitis, involving the distal colon; (3) Endometrioma.

Diverticulitis.—So frequently do diverticulitis and its complications, abscess and chronic inflammatory tumour, cause both chronic and acute obstruction, and so frequently are these grades of obstruction regarded as being caused by a malignant condition, that this condition is considered separately and at some length in Chapter LXXXIV.

Acute Pelvic Appendicitis.—An acute inflammation, or abscess arising in a pelvicly situated appendix, may cause paralysis of a segment of the small or large intestine or of both and thus cause mechanical *acute intestinal obstruction* (see p. 849).

Because, perhaps, absorption in the pelvic lymphatics is slow, the inflammatory condition does not give rise to the usual constitutional signs which denote an inflammatory process, namely, rise in temperature, increase of the pulse-rate, etc. And because the inflammatory area is remote from the abdominal wall parietal peritoneum, abdominal tenderness may be absent. The consequence is that, as a result of the absence of the usual inflammatory manifestations, the obstruction, *in its early stages*, may be regarded as being due to a malignant distal colon.

The importance of recognizing the cause of the obstruction is that the operative approach to an acute obstruction caused by a malignancy is very likely to bring about the death of a patient in whom this obstruction was the result of an acutely inflamed pelvic appendix (see p. 849).

Chronic Pelvic Appendicitis.—Not only can a pelvic appendicitis give rise to an acute obstruction, but also it can cause a *chronic intestinal obstruction* which is clinically almost indistinguishable from that caused by a scirrhus carcinoma of the sigmoid. For example:—

Over a period of two years, a patient, aged 55, complained of attacks of what his doctor called “intestinal obstruction”. During these attacks, his tongue would be covered with fur; he would suffer very acute abdominal pain which he could not localize, but which seemed to him to be somewhere in the vicinity of the central part of the abdomen; his bowels would become almost completely constipated, and his abdomen somewhat distended. He would have no increase in temperature and no rise in the pulse-rate. Each attack generally lasted a week, sometimes a little more, and towards the end he would get great relief from an enema. During the attacks he would have to go into hospital, but between them he felt quite well and looked healthy, his main trouble being some difficulty in getting his bowels open. At operation a chronic recurring pelvic appendicitis with much surrounding fibrosis was found to be the cause of the obstruction.

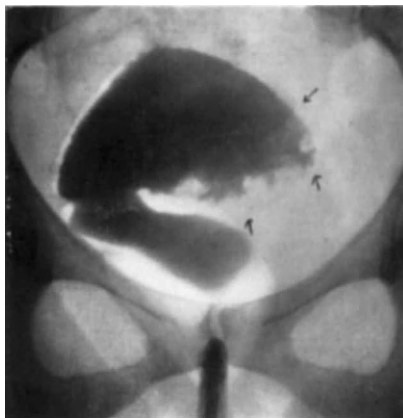This patient was thought to have a chronic intestinal obstruction caused by a carcinoma of the colon.

Endometrioma.—Endometrioma may cause a chronic obstruction. For example:—

A woman, aged 35, was operated on by a country surgeon because she had pain and tenderness over the right side (*see p. 907*). He found that the appendix was not diseased. He explored the abdomen and was most disturbed to find what he regarded as a hard carcinomatous tumour obstructing the lower part of the sigmoid. Operation showed

Fig. 617.—Filling defect (indicated by arrows), the result of an endometrioma causing obstruction of the sigmoid.

that it was an endometrioma. *Fig. 617* is from a radiograph showing the filling defect which it caused. The right-sided pain and tenderness were caused by the early sigmoid obstruction.



INNOCENT CONDITIONS CONSIDERED IN RELATION TO TUMOUR OF THE LEFT ILIAC FOSSA (A SIGN OF MALIGNANCY)

A hard firm tumour situated in the left iliac fossa, and almost indistinguishable from that caused by carcinoma, may arise as a

manifestation of innocent disease of the distal colon. Such a tumour can be caused by: (1) Proliferative inflammatory tumours; (2) Parasitic conditions, such as hydatid; (3) Fæcal lumps; (4) Disease outside the colon, as inflammatory and innocent neoplastic tumours of the uterus and Fallopian tubes.

Proliferative Inflammatory Tumours.—The fundamental clinical distinction between a malignant and an inflammatory diverticular tumour, which should be evidence of inflammation, pain, and tenderness, does not hold; for carcinoma of the sigmoid may be surrounded by inflammation or even an abscess and be tender, while an inflammatory tumour in this region, such as an inflammatory diverticular tumour, may be so chronic that it exhibits no tenderness to the palpating hand. Proliferative inflammatory tumours are: (1) Inflammatory diverticular tumours; and (2) Chronic inflammatory left-sided appendiceal tumour.

1. *Inflammatory Diverticular Tumours.*—Diverticulitis often gives rise to a tumour in the left iliac fossa which to the palpating hand, or when exposed at the operation, is indistinguishable from that of carcinoma. The clinical symptoms, too, of both conditions are almost indistinguishable. This inflammatory tumour is more often than in other innocent conditions confused with carcinoma of the distal colon. It will therefore be more convenient to consider its clinical manifestations at length in Chapter LXXXIV.

2. *Chronic Inflammatory Left-sided Appendiceal Tumour.*—The condition can best be exemplified by an actual case:—

A man, aged 45, was sent to me by his doctor with a note to say that he had had for three months a hard, irregular, fixed tumour in his left iliac fossa, which, he wrote, he felt sure was an inoperable carcinoma of the sigmoid. Examination disclosed that the tumour was present as described by the doctor. It was hard, irregular, fixed, and not tender. I felt certain that it was malignant. On going into the patient's history carefully, I found that he was perfectly well till four months previously, when he had had an attack of abdominal pain which made him stop his work for two days. Feeling that the sudden onset might possibly indicate some inflammatory onset and relieve him from condemnation to death from a malignancy, I suggested operation. His relatives interfered and said that they preferred him to "die a natural death".

Eventually I operated on him, and to my surprise found situated behind the sigmoid a small abscess with hard fibrosed walls, almost half an inch thick.

Investigation showed that the patient had had an acute pelvic appendicitis which had given very little indication of its presence. A chronic suppuration in the pelvis had followed, and this had extended upwards in the retroperitoneal plane to behind the upper part of the sigmoid where it had localized as a chronic abscess that could be felt as a hard irregular non-tender tumour.

Hydatid.—A smooth, round, firm, non-tender, *very mobile* tumour palpable in the left iliac fossa is likely to be a hydatid. In one case of hydatid of the left iliac fossa it could be moved about a circle of six inches in diameter.

A hydatid tumour, too, may be found encysted between the bladder and rectum in the male, or the uterus and the rectum in the female. Hydatid in this position follows an operation for hydatid in the abdomen, when scolices escape and drop into the pouch of Douglas or rectovesical space.

Such a tumour must be dissected out, a feat which requires considerable skill. It can, however, be dealt with in the usual way by the removal of the cysts and drainage of the cavity which is left.

Fæcal Lumps.—Hard lumps of fæces may sometimes simulate a tumour ; but it must not be forgotten that an accumulation of fæcal lumps can occur above a malignant obstruction, as is shown in the following case :—

A man, aged 50, complained of constipation which had become evident for the first time in his life. He had passed a little blood in his fæces. Examination disclosed a large lump, in the left iliac fossa, which was obviously impacted fæces. He was told that he was suffering from constipation and that an enema would cure him. Examination subsequent to the enema showed that the lump had entirely disappeared and all anxiety in regard to a possible malignancy was allayed.

Three months later it was obvious that he had a carcinoma of the lower end of the sigmoid : the lump previously felt was the accumulation of fæcal lumps above a carcinomatous obstruction.

Inflammatory Conditions of the Fallopian Tubes and Myomatous Tumours and Ovarian Conditions.—These are, as a rule, so obvious that they present no special diagnostic difficulties.

CHAPTER LXXXIII

SURGICAL TREATMENT OF INNOCENT DISEASES
OF THE DISTAL COLON

Multiple or Single Papillomata.—The surgical treatment of multiple papillomata of the proximal and distal colon and the rectum presents a very difficult problem. As this is practically a malignant condition, resection of the whole colon is the only sound method of treatment—rather a drastic procedure. Even when I have resected the greater part of the distal colon for multiple papillomata, one of which had become malignant, in the years that followed a malignancy developed in a papilloma left in the hepatic flexure.

If resection of the whole colon must be considered, then it is best carried out by making as a first stage an ileo-sigmoidoscopy as close as possible to the rectosigmoid junction. The colon can then be removed at a second stage.

For a papilloma of the lateral or posterior wall of the rectum an operation may be carried out by splitting the posterior rectal wall throughout its whole length, and locally excising papillomata, together with that portion of the bowel wall on which they are situated. The sliced rectum is then sutured as far as the sphincter. In this region the mucous membrane only is sutured, the sphincter being allowed to unite by granulation. In about two or three months the sphincter heals and the patient becomes continent.

In the meantime the ununited sphincter has permitted repair of the sliced rectal wall.

I have used this method for the local resection of papillomata of the rectum with success, an example of which is the following case :—

A man was referred to me for operation for carcinoma of the rectum. Examination revealed the fact that he had, on the posterior wall of the rectum, a large local papilloma which bled freely. At the operation, after removal of the coccyx, I divided the rectal wall by a vertical incision posteriorly, thus opening up and displaying the whole rectum. I removed the papilloma with a portion of the subjacent rectal wall, sutured the defect thus caused, closed the rectal wall as far as the sphincter, uniting the mucous membrane subjacent to the sphincter, but leaving the sphincter unsutured. In three months the rectum had completely healed and the

patient was continent. Ten years later he was still alive and well. Microscopical examination of the papilloma showed that the superficial part of the growth showed signs that it had become malignant.

Resection of such papillomata with the underlying mucous membrane (that is, resection through the anal orifice) does not cure the condition, even if the resection is followed by the use of radium. One patient treated in this way had a recurrence in the scar eight years later.

Ulcerative Colitis.—In the late stages of ulcerative colitis, when the walls of the colon are rigid, opaque, and very much thickened, no treatment is of much avail.

In the early or middle stages, however, I have seen some improvement after the various forms of vaccine treatment. An autogenous vaccine of a streptodiplococcus (Bargen), isolated from the fæces of the patient, the growth of which is not inhibited by the patient's blood, has given some improvement and minimized the recurrences.

Appendicostomy.—I have tried all the various forms of colostomy and enterostomy, with little avail. But curiously enough, and contrary to the experience of others, I have been able to give to patients great benefit by a carefully made and permanent appendicostomy.

This method of using an appendicostomy has greatly helped a number of patients with severe ulcerative colitis and enabled others to earn their living.

The principles of its use are that the appendicostomy must be permanent; that the patient must be trained to attend to it himself; and that it must be used by him, not only to keep his colon comparatively empty, but also for the instillation or infusion of remedies. Weak solutions of tannic acid as well as injections of cod-liver oil have been attended with much benefit.

The patient washes out the colon each day with a large quantity of saline.

To make the appendicostomy, the mucous membrane of the base of the appendix (dilated) is coapted to the skin to form a small fistula. This is kept closed by an indwelling No. 14 catheter (closed with a spigot). The catheter is only removed in order to replace it by another.

This fistula, if properly managed, never leaks fæces or give rise to a bad smell. These permanent tubes are indwelling and the patients wear them for years; and very often they have found so much benefit from them that when I wanted to do away with the use of the tube and close the fistula, the patients would not allow me to do so.

Patients that I have treated in this way have been very much benefited. Examples are as follows :—

A woman had been six months in bed, suffering from intense diarrhæa—she had been passing up to twenty motions a day. She was terribly emaciated and was completely bedridden. All the usual measures had been tried. She was so ill that she had to be transfused before she could be operated on. An appendicostomy was done and she was treated as I have described. In six months she appeared to be well and gained many stone in weight. By the use of the tube, she avoids, or at least minimizes, recurrences and is able to work.

A girl, aged 25, a typist, had been ill for years with all the symptoms of ulcerative colitis. She had had to give up her work and had been an invalid for one year. An appendicostomy was done and she was taught how to manage it. She has now been back at work nearly four years. She still wears the tube.

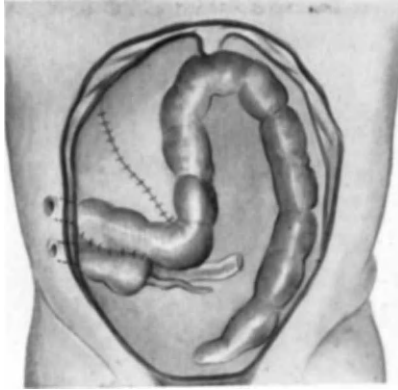

Fig. 618.—Surgical treatment of ulcerative colitis. Suture of cæcum to upper part of ascending colon and hepatic flexure, so as to make a disconnecting artificial anus a little above the cæcum.

Although this method of treatment may not cure bad cases, it minimizes the acute recurrences and enables the patient to earn his living, and so ameliorates the conditions without imposing any disability as the result of a permanent stoma.

The appendicostomy also appears to give the patient such control of his colon that he can keep it empty, and therefore lessen those conditions which favour bacterial development and a resulting colonic inflammation.

Exclusion of the Distal and the Greater Part of the Proximal Colon.
—In the surgical treatment of ulcerative colitis, I have taken advantage of the fact that in most cases the cæcum is the least affected part, and in others that it is scarcely affected at all ; and I have completely excluded the distal and the greater part of the proximal colon.

The exclusion is accomplished in the following way :—

1. The hepatic flexure is extensively mobilized.
2. The proximal colon is doubled on itself.
3. The cæcum and first part of the ascending colon is sutured to the upper part of the ascending colon and hepatic flexure, as shown in *Fig. 618*.
4. The proximal colon is then completely disconnected at the apex of the loop, in the manner described on p. 948.

The disconnecting anus is made as small as possible by closing the skin round it and suturing the mucous membrane to the skin.

The object of making it so small is to enable the patient to keep it plugged with the tube in the same way as an appendicostomy wound.

The excluded colon is washed clear of fæces, treated from time to time with instillations of cod-liver oil, and allowed to lie functionless.

The results in a small number of cases so far are good, and the method is on its trial. All that can be said about it is that it is based on reasonably sound principles.

The control of the anus in this position is not so satisfactory as with the similar type of artificial anus in the transverse colon.

CHAPTER LXXXIV

THE DIAGNOSIS OF DIVERTICULOSIS
AND DIVERTICULITIS

DIVERTICULA are found in all parts of the alimentary canal—the œsophagus, stomach, duodenum, and the small and large intestines. They are, however, commonly seen in the large bowel, and particularly in the sigmoid, where they may be very numerous. They are found in the later periods of life, when the supporting connective tissue is naturally becoming weaker. It is with diverticula of the colon that the matter in this and the succeeding chapter deals.

Diverticula may be congenital or acquired. The wall of the congenital diverticulum is made up of all three coats of the bowel; that of the acquired of a mucous coat and a serous coat—the muscular coat being missing.

Diverticula are found most frequently in the distal part of the sigmoid. They are pulsion diverticula, that is, due to increased pressure in the lumen of the bowel. They occur in the fat-laden gut, in which the musculature is weakened by gaps of fat; and often appear to originate in those spots in the bowel where arteries to the mucous membrane have perforated the muscle coat of the wall of the bowel, and where therefore there must exist a congenital deficiency—a starting-point for the diverticular formation.

Diverticula may be found uniformly spread throughout the colon; and in this case the condition is called *diverticulosis*.

On account of fæcal retention, inflammation is very likely to occur in the wall of a diverticulum and thus give rise to a *diverticulitis*.

If the inflammation in the diverticulum extends to the surrounding tissue it is called *peridiverticulitis*.

Where there are many diverticula aggregated, as often occurs in the sigmoid, and where these become inflamed (diverticulitis) and this inflammation spreads to the surrounding tissue (peridiverticulitis), a chronic inflammatory tumour may form. The grade of infection is low and often its effect is more in the nature of a tissue proliferation, so that a large, hard, not very tender tumour is the result—a *diverticular tumour*.

of a filling defect, a partial obstruction, which corresponded to a palpable thickening. Diverticula could be seen. The weight of X-ray evidence, therefore, suggested an inflammatory mass around the bowel, possibly arising from diverticulitis. Incision revealed an abscess.

A fistula discharging air and a very small quantity of fæces persisted for four months. (*Fig. 619.*)

Distinction from Appendicitis.—The interest to the surgeon of these types of diverticulitis is not only their recognition as such, but also their distinction from an appendicitis which has given rise to left-sided manifestations of inflammation. Such appendiceal manifestations may be brought about by: (*a*) An inflammation of an appendix anomalously situated on the left side; (*b*) An inflammation of a long, pelvicly situated appendix, which extends over to the left side; or (*c*) An extension up the left side (often the first abdominal sign) of an abscess resulting from a pelvic appendicitis (*see p. 848*).

4. INFLAMMATORY SYMPTOMS AND SIGNS IN THE RIGHT ILIAC FOSSA

Sometimes the symptoms of a diverticulitis are those of an appendicitis, that is, pain and tenderness more on the right side than on the left. In this case they are due to the fact that a circumscribed peritonitis has arisen from a diverticulitis of one or more diverticula in an elongated sigmoid which lies over towards the right side. For example:—

A fat patient was operated on for a supposed acute appendicitis, the right-sided symptoms of which were not quite typical, and the tenderness from which was not exactly localized. The appendix was found to be normal, but lying towards the right side was the sigmoid with a few inflamed diverticula.

Rarely a circumscribed low-grade peritonitis may spread up from a diverticulitis deep in the pelvis on the right side and create the suspicion of an appendicitis.

An abscess may form on the right side with very little pain and tenderness and with nothing to indicate that it has arisen from a diverticulitis. The following case-history illustrates this fact, and also how an abscess can form (in this case not quietly) on the right side without there being any left-sided symptoms.

A very fat male patient was operated on for acute appendicitis. He was quite well for five years after the operation, when he started to develop some pains over the appendiceal area. Sometimes these pains would be violent, but as a rule they would not last long. One day the pain suddenly became very violent somewhere about the umbilicus. His temperature was 100°, and he had some difficulty in getting his bowels open. Gradually he became distended and his bowels became more difficult to open.

On examination there was a good deal of rigidity and distension, and he had what would have been considered an appendiceal abscess were it not known that the appendix had been removed.

X-rays revealed a widespread diverticulitis. Operation disclosed (in the region of the appendix) a large abscess which had spread up from the pelvis.

5. INFLAMMATORY SYMPTOMS AND SIGNS IN THE HYPOGASTRIUM

Diverticulitis may become apparent as a median hypogastric inflammatory condition with a certain amount of tumour formation, in which the inflammation is so chronic and circumscribed that it may be—and as a matter of fact has been—mistaken for an *ovarian tumour*.

6. INFLAMMATORY PELVIC SYNDROME REGARDED AS OF GYNÆCOLOGICAL SIGNIFICANCE

An ill-defined pelvic inflammatory syndrome without bowel symptoms may arise from a diverticulitis. The condition may resemble a pelvic peritonitis of tubal origin. As the adhesions may be rather generalized and the diverticula not obvious in a collapsed sigmoid, an operating gynæcologist may fail to discover the true origin of the peritonitis. The importance of this pelvic syndrome (as also of the inflammatory syndromes (3), (4), and (5) described above) is that, although diverticulitis is not uncommon and frequently causes symptoms and signs clinically indistinguishable from inflammatory disease of uterine or adnexal origin, it receives comparatively little attention in gynæcological literature.

7. GENERAL PERITONITIC CONDITIONS

A *severe peritonitis* may follow a fairly large perforation of a diverticulum. It is not uncommon for a case of an acute abdominal emergency to come into hospital after having had an onset of acute abdominal pain, which has arisen in the left lower part of the abdomen, and which has been followed by an onset of shock, of vomiting, and of general abdominal pains. When admitted to hospital, the patient presents all the symptoms and signs of a rapidly spreading peritonitis. The clue to the diagnosis is the onset of a pain in the left lower part of the abdomen; and a further clue may be that, in these days of frequent X-ray examinations, there may be some X-ray evidence that the patient has had a diverticulitis. A peritonitis of this degree is nearly always the result of a fairly large perforation of a diverticulum. In passing, it should be noted that the operative outlook in these cases is exceedingly bad.

A *less severe peritonitis* may follow a pin-point perforation, run a course of about ten days, and simulate an incomplete intestinal obstruction.

8. ABDOMINAL CATASTROPHES

A dramatic abdominal catastrophe may be the first indication of a diverticulosis or diverticulitis.

Acute Abdominal Crisis Following Defæcation.—Very occasionally perforation of a diverticulum may follow a forcible act of defæcation, and when this happens the results are dramatic and terrible. The following case-history is an example of such an occurrence :—

A man, accustomed to go to stool every morning at a certain time, during a forcible act of defæcation and following a considerable amount of straining, was seized with the most agonizing abdominal pain that I have ever seen. His pain was followed by violent vomiting. He quickly became acutely shocked, and his abdomen became generally rigid—of a board-like nature—with general abdominal tenderness.

At operation (two hours later) it was found that he had passed the whole of a formed stool into his abdominal cavity.

Death quickly followed the operation.

Acute Abdominal Crisis Following Administration of an Enema.—Quite rarely one of these large perforations may follow the administration of an enema. For example :—

A woman came into hospital with the symptoms of intestinal obstruction. She had tenderness over the left iliac fossa, had had a certain amount of pain in the left iliac fossa, was not very distended, and had a perfectly soft abdomen. A diagnosis of diverticulitis was made.

Knowing that the obstruction from a diverticulitis is of an inflammatory nature and usually only a relative one, the surgeon ordered an enema. Immediately afterwards the patient was seized with the most violent agonizing pains. She could not return the enema, her abdomen became as hard as a board, and she suffered from intense shock. She died three hours later.

General Peritonitis Following Exploration of the Abdomen.—A pedicled diverticulum may be torn off during an exploration of the abdomen, and the low-grade peritonitis that follows the pin-point perforation is apt to puzzle a surgeon. This difficulty is seen in the following case :—

A surgeon, operating on a case of chronic appendicitis, inserted his hand through the split-muscle appendiceal incision and examined the rest of the abdomen. He was surprised to find that he brought out on his hand what seemed to be a small pill, but he took no further notice of this finding. He was, however, disturbed to find that on the fourth day his patient seemed to be very sick with a temperature of about 99°, and a rising pulse-rate. On examination, he found that the patient's abdomen

was distended, with a certain amount of general tenderness. Very soon the patient began to vomit, and about the tenth day died of what appeared to be a general peritonitis, which had slowly developed.

In this case, the surgeon, in exploring the abdomen, had torn off a slenderly pedicled diverticulum containing a small fæcolith, which was what he brought out from the abdominal cavity.

The slowly developing peritonitis arose from the small pin-point perforation which the avulsion of the diverticulum caused.

9. ACUTE INTESTINAL OBSTRUCTION (LARGE-BOWEL TYPE)

An *inflammatory diverticular tumour* of the sigmoid may give rise to acute intestinal obstruction. When this happens the obstruction is of the large-bowel type; that is, the bowel function completely ceases—enemas give neither fæces nor air—the abdomen becomes very distended, and in the late stages of the illness (five to six days) the patient begins to vomit.

With these symptoms of intestinal obstruction there may be some tenderness in the left iliac fossa indicating the inflammatory origin of the obstruction. There may be some constitutional signs such as rise in temperature and pulse-rate—symptoms which also suggest that the obstruction may be inflammatory. It should, however, be remembered that in some cases there may be no manifestations whatever of an inflammatory lesion.

If the patient has been examined previously, the cause of the trouble may be obvious, for a radiograph may have shown that the patient has a diverticulitis. In most cases, however, a previous X-ray examination has not been made.

As in malignancy, such cases of diverticulitis occur in people over 40, so that the natural diagnosis is one of malignant obstruction; especially, too, as malignancy is the most frequent cause of obstruction in the sigmoid. Not alone is this the diagnosis which is usually made clinically, but it is the one which is usually made operatively as well. The reason for this is that the diverticular tumour is so stony hard, so irregular, so large, and infiltrates the surrounding structures so widely, that it has all the macroscopical appearance of a carcinoma.

Such a tumour may have glands associated with it, which, because they are firm, also suggest a malignancy. Close observation, however, will show an absence of surrounding peripheral nodules (malignant), or some œdema in the vicinity of the edges of the growth—a condition which is not seen in a malignancy.

Further, the fact that it is so large and yet the patient is in fair health and does not look cachectic, and further still, that

If the material examined contains more urea than is present in the patient's blood it is certain evidence of admixture with urine.

When only a drop or two of material is available for analysis the *urease test* will show whether or not urine is present. The ferment urease acts on urea, producing alkalinity due to ammonium carbonate. To carry out the test, add a few drops of phenol red to the material and then adjust the reaction till the fluid is just not red. Add urease and if urea is present the fluid will turn red in a few minutes.

2. *Recognition of Faecal Contamination.*—When faecal matter comes away with the urine in any considerable quantity there is no difficulty in recognizing it, but when it is small in amount, and mixed with the products of cystitis, it is not so easily identified. In these cases microscopical examination of the centrifuged deposit will generally clinch the diagnosis. The finding of faecal debris and particles of undigested muscle and starch is sure evidence of the existence of a fistula between the intestine and urinary tract. If any doubt remains, the best plan is to carry out a bacteriological examination for the presence of spore-bearing anaerobic bacteria. These are always present in the intestine and almost never in the urinary tract (only in association with gas-gangrene infections). To carry out the test, a few cubic centimetres of urine is heated at 60° C. for half an hour to kill off non-sporing bacteria, and then 1 c.c. is added to melted glucose agar in a deep glucose agar tube so as to provide an anaerobic culture. The tube is incubated overnight, and the presence of spore-bearing anaerobic bacteria is shown next day by the large quantities of gas formed within the medium.

13. EQUIVOCAL MALIGNANT TUMOUR OF THE SIGMOID FOUND DURING EXPLORATION OF THE ABDOMEN

We next consider the equivocal malignant tumour of the sigmoid (generally found during an exploratory operation), which may either be a very chronic inflammatory diverticular or a malignant tumour—in many cases it is impossible to say which. Here is an example :—

A woman, aged 60, was operatively explored because she had suffered from chronic colicky pains for six months and had become constipated. At the operation a large tumour of the sigmoid was found. The tumour was firmly adherent and inoperable. The question of its being a diverticular tumour was mooted and carefully considered. It was definitely decided that it was malignant and that it could not possibly be inflammatory.

The patient was sent for deep X-ray therapy with the hope that this treatment might reduce the tumour to enable it to be removed. Accordingly, four months after the first operation, an attempt was made to remove the tumour. With great difficulty, and with misgivings that resection should have never been attempted in such an adherent 'malignant tumour', it was resected. The whole sigmoid was removed and an artificial anus made. (The transverse colon was eventually connected to the rectum and continence was restored.)

The surprise came when the pathologist's report on the operation specimen was diverticulitis.

DISTINCTIONS BETWEEN DIVERTICULAR AND MALIGNANT TUMOURS

DIVERTICULAR TUMOUR	MALIGNANT TUMOUR
<i>Living Pathology as seen at Operation.</i> — Generally large, extends longitudinally (along colonic wall) and involves large area of sigmoid	Generally small, extends transversely (by circular lymphatics) and involves a small area of the sigmoid
Large tumour necessary to produce complete obstruction	Small tumour (because of invasive and contractive nature) can cause complete obstruction
The constitutional symptoms are inconsistent with the large size of the tumour and its extensive adhesions; that is, for the large tumour, they are comparatively mild	A comparatively small tumour may produce marked constitutional disturbance
Hard—but not 'stony-hard'—(and often with soft spots) Glands firm	'Stony-hard' and nodular Glands hard
Evidences of an œdema in the periphery of the tumour or of a cellulitis of the sigmoid	Evidences of sago-grain permeation in the area surrounding the tumour
Tough leathery adhesions to surrounding structures	Brittle rigid adhesions to pelvic contents
<i>Clinical—the Significance of the History.</i> — Evidence of an infective origin	No evidence of infection (except perhaps late)
Comparative absence of tenesmus, frequent desire to defæcate, and of passage of pus or blood	Tenesmus, frequent desire to defæcate, and a discharge of pus and blood are outstanding features
<i>Sigmoidoscopic.</i> — No pus, no bleeding, no ulcerating surface. Openings of diverticula cannot be seen (Care necessary because use of air inflation for passing sigmoidoscope may rupture a diverticulum) May be signs of constriction outside the mucous membrane	Ulcerating surface, pus, blood, possibly a tumour, and a definite constriction seen
<i>X-ray Appearances.</i> — 1. A rather long filling defect—a uniform constriction with spikelets arising from its edges, and with the isthmus showing a uniform barium density 2. Outlying diverticula (Occasionally diverticula may not show because they are filled with inspissated fæcal content)	1. A rather short, not uniform, constriction, with a variability in denseness of the edges of the 'defect' and of the isthmus shadow, and an irregularity of contour of this shadow

14. CARCINOMA DEVELOPING ON DIVERTICULITIS

Frequency.—The author believes from his experience that carcinoma develops on diverticulitis in about the same proportion of cases as it supervenes on chronic gastric ulcer. He has rarely seen diverticulitis accompanying cases of a sigmoid carcinoma; and in a fairly large experience of diverticulitis, he has only seen three cases in which a carcinoma has appeared to develop on a pre-existing diverticulitis.

Indications of the Onset of Carcinoma.—In an established case of diverticulitis, the onset of severe tenesmus, frequent desire to defæcate with little result, mild fæcal incontinence, and the passage of blood and pus indicate carcinomatous degeneration. An X-ray filling defect (seen in a barium clysm) will show a characteristic variation in the density of the barium shadow at its edges and in the isthmus, and also a characteristic irregularity of contour.

CHAPTER LXXXV

**THE TREATMENT OF DIVERTICULOSIS
AND DIVERTICULITIS**

FROM the discussion on diverticulosis and diverticulitis in the previous chapter—covering as it does a considerable surgical experience—it will be obvious that the surgery of diverticulitis is an important phase of the surgery of the alimentary canal.

Out of this discussion three facts have emerged: (1) A diverticular condition, because of the protean character of its manifestations, often remains unrecognized; (2) Obstruction is often caused by an exacerbation of an associated inflammation; and (3) Many fatal abdominal catastrophes follow in the wake of diverticulosis or diverticulitis.

The salient points from the standpoint of surgical treatment which arise out of this discussion are as follows:—

1. The more frequent employment of medical treatment (not immediate operation) in the case of threatened obstruction, which, as pointed out, may be due to exacerbation of an associated inflammation.

2. In the light of the fact that improved methods of surgical operation for diverticular lesions (operation on the defunctioned colon, *see* p. 943) are now possible, the question whether diverticulitis should not be more often treated by radical surgical operation, in order to avoid the catastrophes described in Chapter LXXXIV.

Medical Treatment.—The following principles should guide medical treatment:—

1. Measures to prevent an increase in pressure in the lumen of the bowel, such as the administration of paraffin, the use of special diet, the employment of oil or glycerin enemas as mechanical aids to defæcation, the avoiding of straining at stool and of the giving of large enemas under pressure with Higginson's syringe.

2. Measures which lessen adventitious infection of the colonic contents: avoidance of infected food and of diets which predispose to food infection.

3. Prompt treatment of any complicating inflammation, on the lines of the treatment of any inflammation.

4. The reduction of obesity and the improvement of the general muscle tone by exercise.

Surgical Treatment.—The treatment of diverticulitis by surgical measures may be considered under three heads:—

1. The management of uncomplicated diverticulosis and diverticulitis.

2. The management of the various complications of diverticulosis and diverticulitis.

3. The treatment of a proliferative chronic inflammatory diverticular tumour, which involves part or the whole of the sigmoid, and which has irreparably destroyed its function.

1. THE MANAGEMENT OF UNCOMPLICATED DIVERTICULOSIS AND DIVERTICULITIS

Diverticula with long slender pedicles are dangerous and are liable to break off and cause pin-point perforations, and therefore this is the type of diverticulum that gives rise to local abscess formation, and to the various grades of peritonitis.

In cases where they are not too numerous, they should be removed by ligation and over-suture; and removed much more frequently than is the present custom: the potential danger that these diverticula may cause death should be recognized.

Usually, however, they are too numerous to remove in this way. But where they are numerous and localized to the sigmoid, the question of their radical removal, on the safer lines to be subsequently indicated, should at least be considered.

2. THE MANAGEMENT OF THE VARIOUS COMPLICATIONS OF DIVERTICULOSIS AND DIVERTICULITIS

Chronic Mild Localized Peritonitis.—As a rule, a chronic localized peritonitis is an extension from an actual diverticulitis or from the cellulitis of the colonic wall; it is usually not the result of a perforation of a diverticulum, though it may be. Therefore it is usually amenable to medical treatment: that is, reduction of the bowel function to a minimum, and the recognized treatment of an inflammation.

Abscess Formation.—In the case of abscess formation, however, it will be found that a small perforation, or the presence of a fæcolith following a rupture of a slender pedicle, has a causal relation, for usually when the abscess is opened, gas and fæces are discharged.

The treatment of such an abscess is, of course, prompt drainage; but the problem is not always solved by this simple surgery.

Frequently there are smaller and unnoticeable abscesses among the coils of the intestines ; and further there is the opening in the bowel—an opening deep in the abdominal cavity, which is a continual source of reinfection. Therefore, in serious cases of multiple abscess formation, I do not hesitate completely to disconnect the large bowel at the hepatic flexure or transverse colon, that is, to defunction the distal colon, as described in Chapter LXXXVI. The excluded segment of distal colon is then cleared of fæces and treated, and finally left dormant and resting, for the opening to close and the inflammation to subside. In the end, this treatment, though tedious, saves much morbidity and eventually many deaths.

As a result of this defunctioning measure it is remarkable how quickly the abscess conditions will clear up and the opening in the bowel will close. It is the fæcal stream that prevents healing (*see* p. 1019). This defunctioning measure has also this advantage : if the distal colon is defunctioned long enough, the recurrences which usually follow abscess formation do not readily take place.

The restitution of bowel function, when the inflammation has subsided and the intestine has healed, is a simple measure. (*See* p. 955.)

General Peritonitis.—Where *general peritonitis of sudden onset* arises as a complication of a diverticulitis it is usually the result of a fairly large perforation. Such a condition is serious and the patients generally die, no matter what operation is performed.

In these cases drainage and prompt and complete disconnexion of the distal colon (as described on p. 948) is the only hope.

Where a *general peritonitis of slow onset* arises, it is usually the result of a pin-point perforation and there may be some hope for the patient. In such a case, adequate drainage, exclusion of the distal colon, energetic treatment of the inflammation and of the patient's general condition, are the principles which should guide surgical therapy.

3. ACUTE INTESTINAL OBSTRUCTION

Here there are usually three cardinal factors to consider :—

a. A mechanical obstructing factor made up of chronic inflammatory proliferative and scar tissue, resulting from irritative and destructive inflammatory processes.

b. A florid inflammatory factor, which superadded to (*a*) may be the immediate cause of the obstruction.

c. The toxic effects on the body generally from the obstructed and pent-up fæcal stream, and from an alkalosis caused by vomiting (if the obstruction should reach that stage).

This method, too, is of very little use in the inflammatory conditions of the sigmoid; that is, in conditions such as large inflammatory diverticular tumour of the sigmoid, in which a large part of the sigmoid is involved, and in which the mesentery and bowel are rigid and contracted.

For the other standard operations on the distal colon a surgical text-book must be consulted.

OPERATION ON A DEFUNCTED DISTAL COLON

In the surgery of the distal colon, the principle of carrying out operations and allowing the wound in the bowel to heal in a distal colon which has been *completely* defunctioned will considerably improve the operative results.

Operation on this principle will enable the surgeon to perform with success operations on the distal colon such as the various forms of sutured anastomosis, and anastomosis of the sigmoid to the rectum—an operation which he would never dare to attempt in the functioning distal colon. It will also permit the surgeon to save the continence of many patients whom otherwise, with the ordinary methods of operating, he would have left with an artificial anus.

Meaning of Defunctioned Colon.—By defunctioned distal colon is meant one that has been *completely* disconnected from the alimentary canal, so that it cannot be soiled in any way by even the smallest quantity of fæces; one from which the fæcal contents have been washed out; and one which has been allowed to remain functionless until such time as the bacterial content has been considerably reduced—on the principle that if a segment of bowel is completely isolated experimentally and thus deprived of its function, in the process of time it will lose much of its bacterial content.

This process of debacterialization, brought about by the defunctioning of the distal colon and by the lapse of time, can be hastened by daily lavage of the excluded segment with saline, or with weak antiseptic solution.

Advantages of Operation on Defunctioned Distal Colon.—The two important points of this method of operating are: (1) The operation is carried out under favourable conditions—that is, absence of septic fæces; functionless, collapsed, and retracted colonic walls; and low bacterial content. (2) The wound in the intestine is allowed to heal under such conditions. Of these two points, the healing of a wound in a bowel devoid of content and without function is much the more important.

It has also another advantage : Occasionally, after defunctioning the distal colon for a time, it will be found that some growths, which appeared to be inoperable, lose their adhesions to surrounding structures and become operable. This change is owing to the fact that many cases of carcinoma of the colon are associated with a good deal of inflammation, which clears up after a period of defunctioning and preparatory treatment.

Furthermore, arising out of this method of operating is what might be regarded as an advance in the surgery of the colon, namely, that the disconnexion (made by a disconnecting artificial anus) to defunction the distal colon—a disconnexion made at the hepatic flexure or in the proximal part of the transverse colon—can be made more or less continently ; that is, the patient need not be soiled with the fæcal contents—the semifluid contents of the cæcum and ascending colon can, as a rule, be ‘ corked ’ into this segment of bowel as if they were corked in a bottle (*see* p. 947). The contents of the cæcum can then be emptied or evacuated by a wash-out every twenty-four hours. If the anus is properly constructed there is very little soiling of the abdomen, rarely an irritation of the skin, and never any smell.

This method of operating on an excluded distal colon is therefore one that can be used as a routine for carcinoma of any type and in any situation. It is possible to carry out with reasonable safety sutured end-to-end or side-to-side anastomoses in old and debilitated cancerous patients ; to remove almost the whole of the sigmoid in inflammatory diverticular tumour, and eventually to join the upper part of the sigmoid to the upper part of the rectum ; to remove carcinomas of the lower end of the sigmoid, and anastomose the middle of the sigmoid to the divided rectum ; to remove inflammatory diverticular tumours of the sigmoid which, by the ordinary methods of operating, would be quite irremovable ; to remove a series of innocent adenomas of the sigmoid by slitting it longitudinally, dissecting them out of the mucous membrane, and then closing the lumen of the bowel ; and to cure rectovesical fistula arising as a result of diverticulitis of the sigmoid.

Indications for Operation.—In the surgery of the distal colon there are two main fields :—

1. The surgery of malignant conditions, the most important of which is carcinoma of the sigmoid.
2. The surgery of innocent affections, which comprise inflammatory diverticular tumours with their complications (rectovesical fistulæ, abscesses, etc.), single or multiple adenomata of the sigmoid,

This incision is preferably made very small, because through it the disconnecting anus is going to be made, and therefore it may become infected; and in the presence of infection, a small wound is more manageable and less dangerous to the patient than a large one. Exploration of the whole abdomen through this small opening can be most effectively carried out by vaselining the gloved hand. (*Fig. 632*).

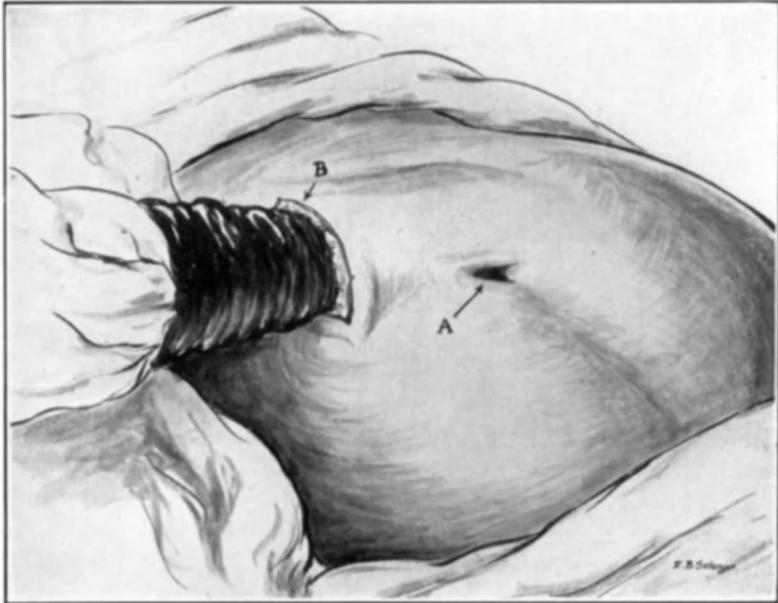

Fig. 632.—Drawing from a photograph of an exploration of the abdominal cavity being made through the small incision, with a vaselined gloved hand. The drawing shows the operation viewed from the end of the table. A, Umbilicus; B, Gloved hand inserted into the small exploratory incision through which the disconnecting anus will be made.

The lubricated gloved hand slips readily through the small incision; the omentum or intestines do not cling to it; and thus an exact and reliable exploration of the growth, the liver, and the whole abdomen can be made. With this simple aid it is surprising to experience for the first time the comfort and ease with which an exploration, usually difficult under such circumstances, can be carried out.

The main object of the exploration is to make an examination of the growth and of any glandular involvement with a view to its operability, and to ascertain if there is any metastatic spread of the growth which would prohibit its radical removal.

2. *Construction of a Disconnecting Anus.*—See Chapter LXXXVII.

CHAPTER LXXXVII

THE TECHNIQUE AND MANAGEMENT OF THE
DISCONNECTING ANUS**Requirements in the Construction of a Disconnecting Anus.—**

In regard to the disconnecting anus, there are five requirements: (1) That it should completely disconnect; (2) That it should be more or less continent; (3) That it should be capable of being easily closed; (4) That the opening into the distal colon should be a fistula-like one so that it will closely fit an irrigation tube; (5) That it should be situated well away from the area of the operation.

Of these requirements, (1) is obtained by dividing the bowel and implanting the divided ends into separate openings in the abdominal wall; (2) by making a small fistula-like anus at the beginning of the transverse colon, with an opening so small that it can be easily occluded; (3) by combining the small fistula-like anus with a very long spur; (4) by constricting the divided distal end by suturing the skin around it; and (5) by making the disconnexion in the upper right part of the abdomen at either the proximal part of the transverse colon or at the hepatic flexure.

THE STEPS IN THE TECHNIQUE

1. An incision (already described on p. 946, and used for exploratory purposes)—2 in. long in the upper part of the right rectus.

2. Formation of a long spur—if the transverse colon is long, its proximal part is drawn out of the abdominal wound, and a tube passed through the apex of the loop as shown in *Fig.* 633.

The loop is stretched to its full extent, and its limbs are connected together by a running suture (or by two running sutures), so as to make a broad contact and thus avoid a loop of small bowel being caught in the subsequent crushing. The object is to make as long a spur as possible: it should be three or four inches long (*Fig.* 634).

If the transverse colon is short, the long spur is made by suturing the proximal part of the transverse colon to the ascending colon, the apex of the loop then being the hepatic flexure.

3. The parietal peritoneum is sutured round the neck of the loop (*Fig. 635*).

4. Buttonhole openings (through only part of the abdominal wall) are made 1 in. on each side of the incision. Through these openings Kocher clamps are applied to the bowel (*see Fig. 635*), which is then divided between them with a diathermy knife, and the cut ends, after being coagulated with the diathermy current, are drawn by these forceps into the buttonhole openings. (*Fig. 636.*)

The skin edges are now sutured around the bowel ends, so as to make a pair of tiny fistulæ. It only requires a very small opening to allow complete egress of the semifluid contents of the ascending colon. In these small fistulæ, in order to avoid stricture, and for control purposes, care must be taken to see that the mucous membrane edge accurately joins the skin edge (adjusted with a few sutures after the clamps are taken off).

In order that there should not be the slightest intestinal obstruction, the proximal Kocher clamp is taken off after twelve hours, but to keep the bowel ends in proper position, the distal one is left on for several days. *Fig. 637* shows the two clamps in position on the abdomen.

Fig. 638 is a drawing showing the finished disconnecting anus.

Rarely, in a case of acute intestinal obstruction, the bowel is so intensely distended that it is impossible to make a spur. In these circumstances a cæcostomy should be made, and when the bowel regains its normal size a disconnecting anus can then be made.

Management of the Disconnecting Anus.—*Fig. 639* is a photograph which shows how small these colostomy openings can be, and yet function properly.

This artificial anus is controlled by inserting into it a corked rubber tube which has a calibre large enough to fit firmly into the opening, and to which a large flange of sponge rubber is fixed. *Fig. 640* is a photograph showing the use of this tube.

The patient can either once or twice in the twenty-four hours, according to his necessity, attach a funnel-and-tube wash-out apparatus to this tube, and wash out his cæcum and ascending colon, and then recork it; or he can remove the corked tube, lean over a basin, completely empty the contents of his cæcum and ascending colon, clean himself, and reinsert the corked tube. He will then, if the anus is correctly made, remain clean for twenty-four hours—that is, until he next attends to his anus. It may require a little time and some adjustments of the anus (under local anæsthesia) before control is obtained.

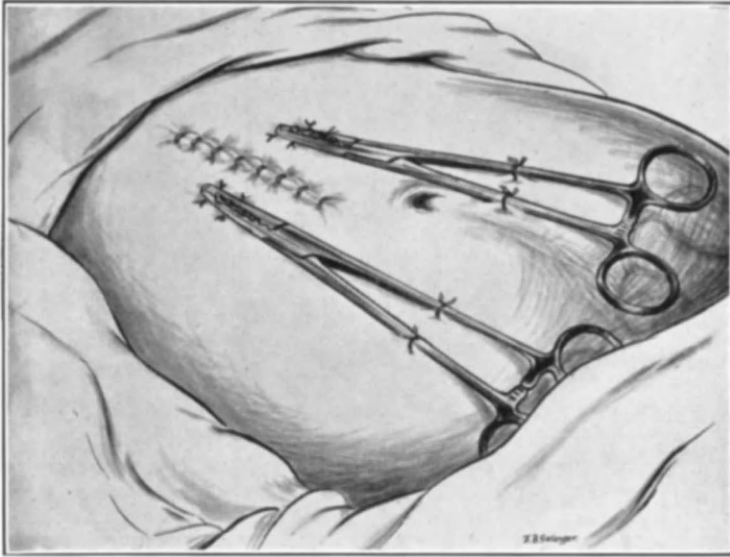


Fig. 637.—Kocher clamps in position on the abdomen.

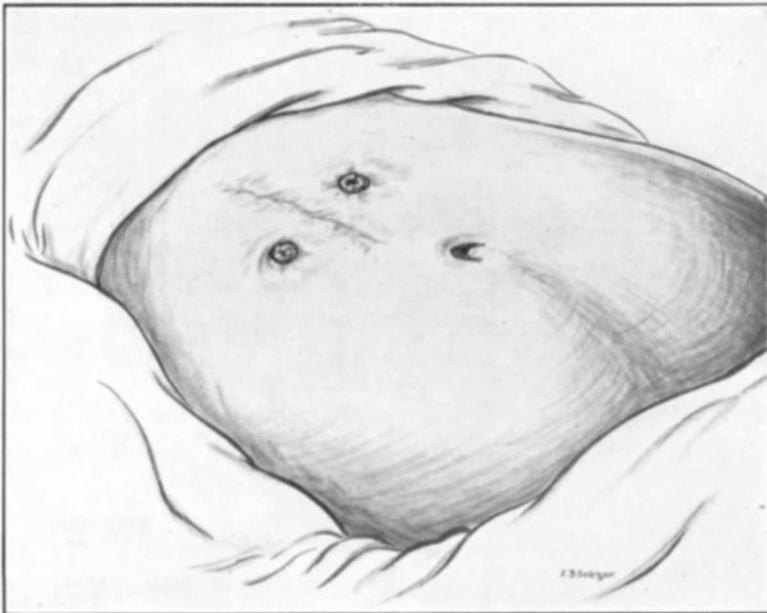


Fig. 638.—Showing the completed disconnecting anus.

of fæces, especially after a barium meal. In some cases it has been necessary to insert a stomach tube into the opening in the distal colon and purse-string it into the artificial anus, in order to make it watertight and thus get sufficient pressure of fluid in the excluded segment of the colon to wash out fæcal lumps.

Reconnexion of the Colonic Segments in the Disconnecting Anus.—The restoration of function in the small disconnecting anus is very simple.

A very long enterotome with a narrow, almost cutting, and a generously bevelled edge is used to crush the spur (*Fig. 642*).

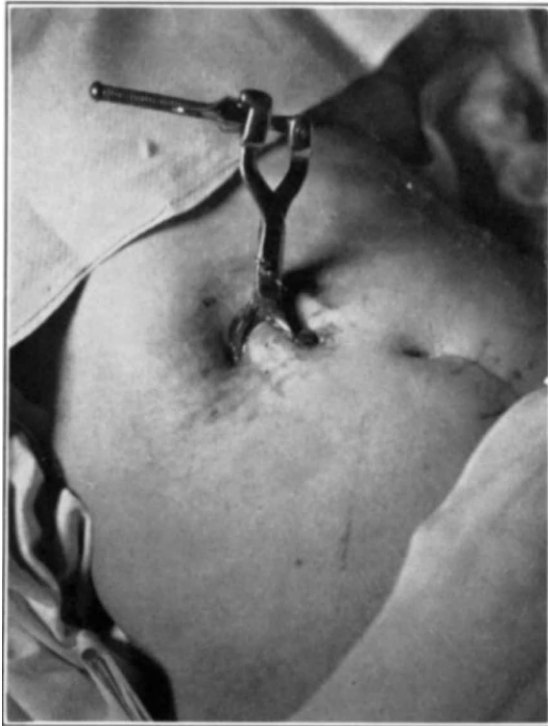

Fig. 642.—The enterotome in position.

The length of the clamp makes a very long opening in the spur, which has for this purpose been made long; the generously bevelled edges produce a graduated pressure, and thus make a wide area of contact and therefore a safe anastomosis between the two limbs; the narrow crushing—almost cutting—edge cuts quickly through the spur.

Fig. 643 shows the enterotome. The blades are vaselined before use, introduced separately, and then connected up with the screw.

Fig. 644 is a diagram showing the enterotome applied.

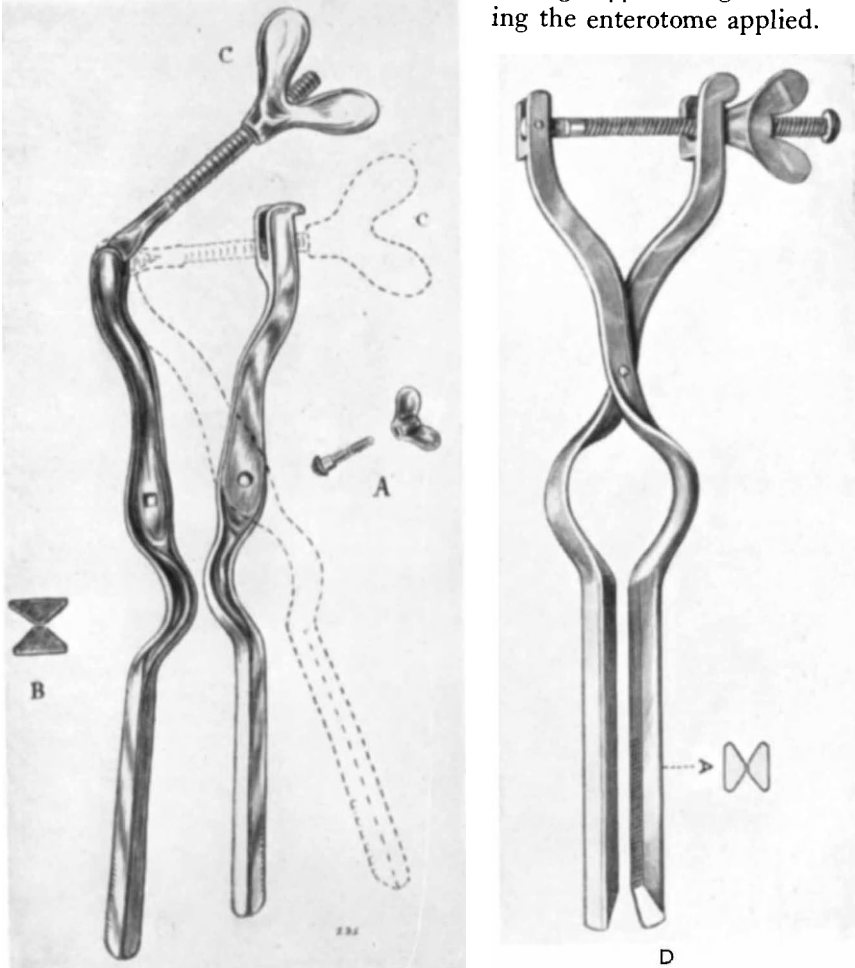


Fig. 643.—An illustration of the enterotome with its blades disconnected. A, Screw which connects the blades; B, Cross-section of the blades, also shown at A in illustration D; C, Large winged nut which draws the blades tightly together after they have been placed in position on the spur and connected; D, Enterotome assembled.

Through the deep anastomosis formed by this long enterotome, most of the fæcal contents pass, rather than up through the fistula-like anus. The consequence is that except for a small fistulous opening, which may discharge a little fæces or perhaps only air,

The Period of Defunctioning Necessary before a Sutured Anastomosis should be Carried Out.—The longer the distal colon has been defunctioned, the lower the bacterial content, the better the local condition, and therefore the safer the operation.

In innocent conditions, such as a diverticular tumour or the complications arising from it, operation may be delayed even for twelve

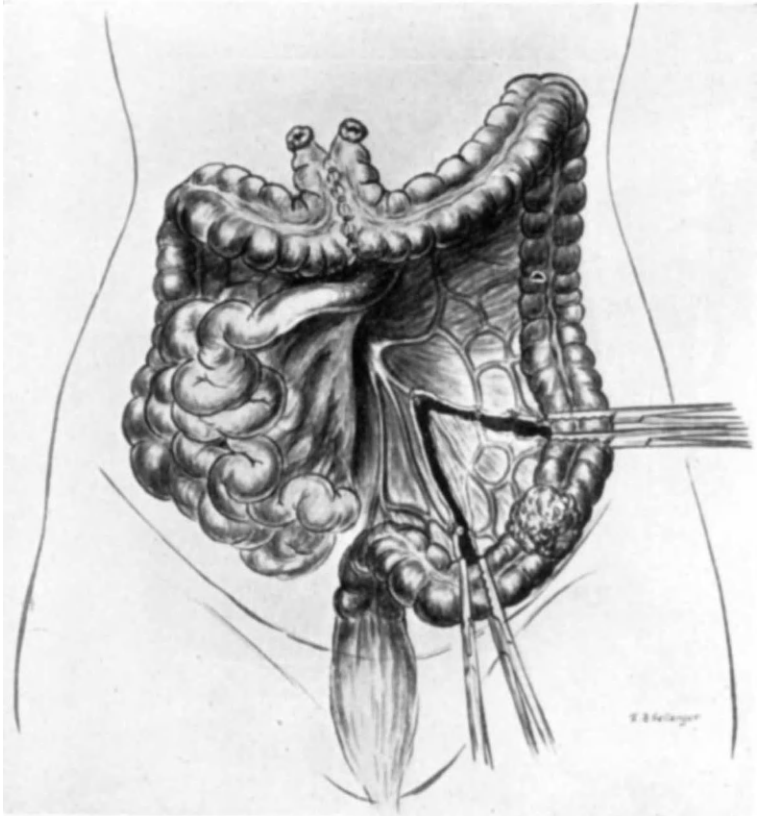


Fig. 646.—Resection and sutured anastomosis in a defunctioned distal colon. Showing the resection of the segment containing the growth. (*Figs. 646–654 from 'Surgery'.*)

months, but as a rule such a long period is not necessary. In such inflammatory conditions long defunctioning is sound treatment, because areas of inflammation spreading from the tumour to all the organs in its neighbourhood slowly disappear.

A prolonged defunctioning of the distal colon enables the surgeon not only to remove inflammatory tumours which previously were

inoperable, but also to avoid the removal of bowel which is inflamed but otherwise healthy. In one patient in whom I had unsuccessfully made two attempts to remove an inflammatory diverticular tumour in a defunctioned distal colon, I was able, on making a third attempt, after the bowel had been defunctioned for a considerable time, to remove the tumour. In another patient who developed acute intestinal obstruction as the result of an inflammatory diverticular tumour in the sigmoid, the diverticular condition completely cleared up after

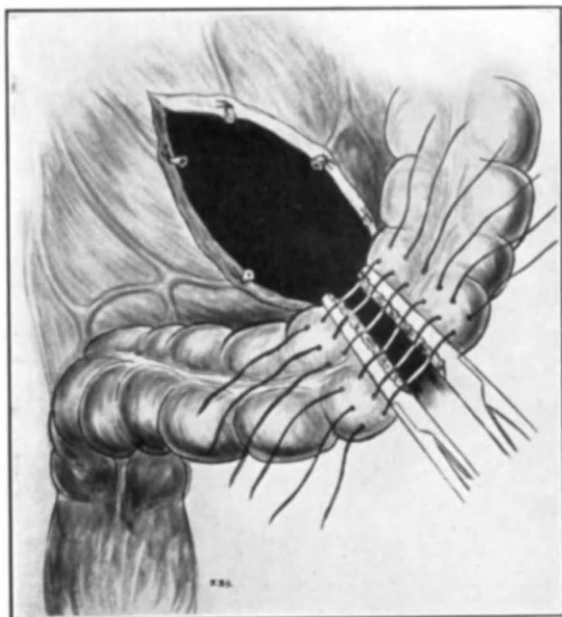


Fig. 647.—Resection and sutured anastomosis in a defunctioned distal colon, showing the interrupted sutures around the cut bowel ends, which have been approximated by the forceps.

the distal colon had been defunctioned for twelve months, and normal function was restored.

Thus, in innocent affections, the longer the distal colon is defunctioned, the safer and more successful is the operation.

In malignant conditions the bowel should not be defunctioned for more than two or three weeks. In bad cases, however, the growth can be removed and the *reconstitution of the continuity of the colon* carried out in a bowel in which a long period of defunctioning has been allowed (*see p. 945*).

Technique.—In the defunctioned distal colon, a really *aseptic anastomosis* can be made. This is made possible by the fact that, as

the excluded segment is functionless and time is not a consideration, the lumina of the divided ends of the colon can be aseptically sealed by diathermic coagulation. The technique used in making this aseptic anastomosis is illustrated in *Figs. 646 and 647*.

The segment of bowel containing the growth is isolated with the aid of the diathermy knife and Kocher clamps and removed, together with the corresponding part of mesenteric leaf. The Kocher clamps closing the proximal and distal segments are contacted with the diathermy current, in order to seal that piece of bowel which lies within the grasp of the clamp. The clamps are approximated as shown in *Fig. 647*, and interrupted sutures, taking in a big bite of the seromuscular layer, are placed around the whole circumference of the bowel ends. These sutures are tied so gently that the sealed ends of the bowel are not opened. The rent in the mesentery is closed in the usual way. The segment of bowel containing the anastomosis should be embedded in a little pocket of omentum for additional safety. A drainage tube is inserted down to the anastomosis.

2. SIGMOIDOTOMY FOR REMOVAL OF SINGLE AND MULTIPLE ADENOMATA

In cases where there have been large single or multiple adenomata, I have not hesitated after defunctioning the colon to slit the sigmoid up widely and remove the adenomata. It is a comfort to feel that, because the operation has been carried out on the defunctioned colon, there is very little danger of a suture insufficiency in the extensively sutured sigmoid.

3. RECTOSIGMOID RESECTION WITH SUTURED ANASTOMOSIS

It is in growths in the lower third of the sigmoid that this method of making an anastomosis in a defunctioned colon is so valuable.

In this situation none of the safer operation methods based on the principle of Paul can be satisfactorily carried out, because they do not permit an adequate resection of the mesenteric leaf, nor do they allow sufficient removal of the bowel on the rectal side of the growth. But where a rectosigmoid resection with a sutured anastomosis is carried out on a defunctioned bowel, the proper amount of the sigmoid with the corresponding part of the mesenteric leaf and the upper part of the rectum can be resected, and with every prospect of success and very little danger the sigmoid can be anastomosed to the divided rectum. Moreover, when the repair of this

rectosigmoid anastomosis takes place in a defunctioned colon, the incomplete peritonealization of the rectum does not mar the eventual successful healing of the anastomosis.

A sutured rectosigmoid anastomosis is particularly applicable after rectosigmoid resection for an innocent diverticular tumour where the circulation of the rectum is not endangered.

Technique.—*Box clamps* are used to seal the cut ends when the sigmoid is divided. *Fig. 648* is an illustration of a box clamp and

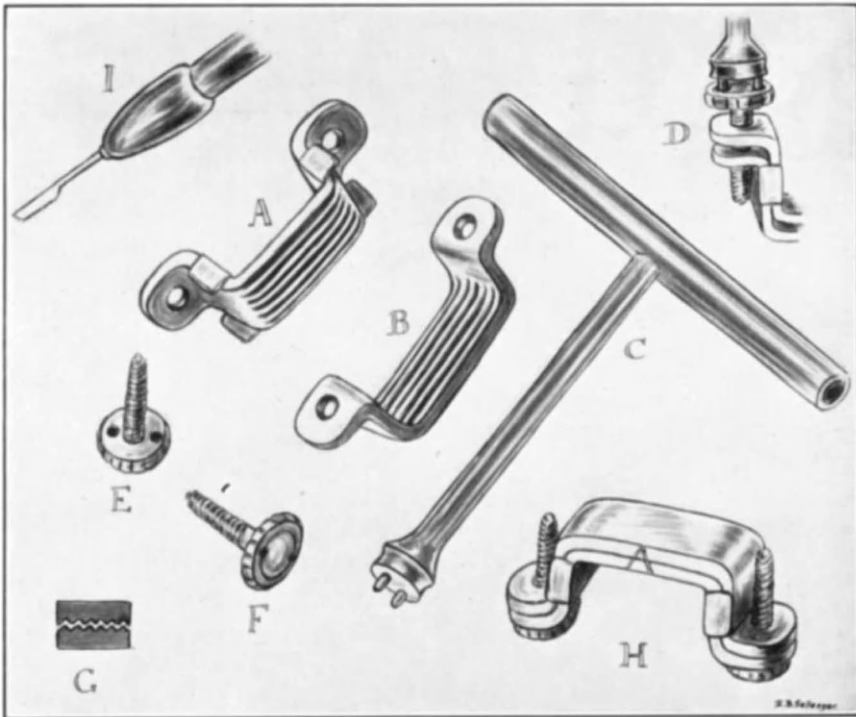


Fig. 648.—The box clamp for aseptically closing the divided ends of the colon. A, B, The two sections of the clamp; C, The key, which is inserted into the screws E, F, to bring the two sections of the clamp together; D, The key in action; G, A sectional drawing showing the serrations on the gripping surfaces of the two sides of the clamp; H, The clamp assembled; I, The diathermy knife used to divide the bowel and coagulate its cut edges.

its constituent parts. The clamps are nearly three-quarters of an inch wide, and have deep serrations. They are applied under great pressure obtained by the use of a key (*Fig. 648, C*), which produces a very powerful, firm grip on the cut segment. Owing to the great pressure, the broad serrated grip, and the coagulation of the gripped tissues by means of the diathermy current, leakage is impossible and

rectosigmoid segment (*Fig. 650*). A clamp is not applied to the rectal stump because the tissue of its cut edges must not be crushed. The use of a clamp is unnecessary, as the rectum can be cleaned and disinfected through the anus.

In the case of a woman the tubes should be removed, because even the presence of slight infection (a mild sepsis occasionally occurs

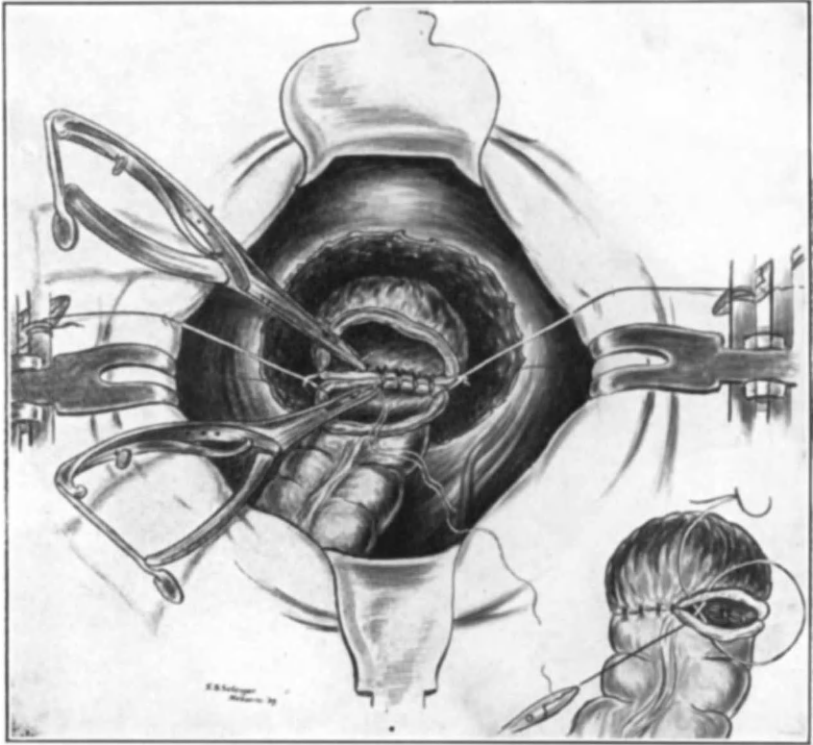


Fig. 651.—Diagrammatic representation of sutures being inserted from the mucous membrane inside the bowel, so as to join the posterior wall of the divided end of the sigmoid to that of the divided end of the rectum. It also shows the use of the two needle-holders, which enable the suturing to be done in the depths of the pelvis; and how the anastomosis is 'guy-roped' to the frame, so that in such a deep wound the ends are kept in accurate position and exact suturing is made possible. *Inset:* Figure-of-8 sutures being used to coapt a small section of the anterior edges of the rectum and colon segments.

round the cut edge of the rectum) may give rise to tubo-ovarian abscesses.

The Anastomosis.—The lower end of the sigmoid is now anastomosed to the stump of the rectum in the following way: The cut end of the sigmoid is examined, to make sure that it is properly vascularized. It is brought down to the rectal stump, placed in

correct apposition to it, and secured in this position by 'guy-rope' sutures, which, besides fixing the segments together, are used to anchor them to the operating frame (*Fig. 651*).

As the bowel segments are empty and clean, interrupted sutures of fine, slightly hardened gut, taking a bite of about one-third of an inch, are inserted from their lumina. These sutures are used to join the posterior and lateral walls, until it is impossible to insert any more. When this point has been reached, a few figure-of-8 sutures are inserted from the external surface of the bowel in order to complete the anastomosis (*Fig. 651*, inset).

Only one layer of sutures is used. The sutures are inserted from the lumen of the bowel, because on account of the cramped position it is most difficult to place the posterior layer of sutures in position from the external surface.

A long needle-holder is used to insert the sutures, and another one in the left hand serves to pick them up. By employing this double needle-holder device, it is surprising to see how deep down in the pelvis an anastomosis can be made.

The pelvic peritoneum is sutured over the anastomosis.

Drainage.—Adequate and prolonged drainage is important. A tube is introduced through the abdominal wound down to the anastomosis; and where conditions relating to union are specially bad, as in resection for vesicosigmoid fistula (*see p. 940*), the coccyx should be removed and another tube inserted up to the anastomosis through the opening thus made.

In order to prevent accumulation of secretion in the rectum, the sphincter is divided posteriorly (without dividing the mucous membrane), or if this is not done an indwelling rectal tube is used.

About six or seven days after the operation it will often be found that, if saline is injected through the anus, some of it will come out of the abdominal tube. This is owing to the fact that a leak has developed in the anastomosis. The drainage tube (or a smaller one) is therefore left in position till such time as fluid injected through the rectum shows that the anastomosis has healed.

About two weeks after healing is complete the spur of the artificial anus is crushed; and the fistulæ closed later under local anæsthesia.

Vaginal Drainage in the Female.—Instead of passing the long drainage tube from the abdominal wound through a coccygeal opening, as in *Fig. 630*, p. 941, it may be passed through an omental screen and an opening in the pouch of Douglas into the vagina. In this way the anastomosis can be disconnected from the main part of the abdomen and connected externally through the vagina. If

anything should go wrong with the circulation of the stump (often better than anatomical dissections would lead us to believe). It is also a safeguard in the precarious healing which usually occurs in rectal wounds.

Thus in this technique it is particularly important that drainage should be established perineally by removal of the coccyx as well as abdominally through the wound.

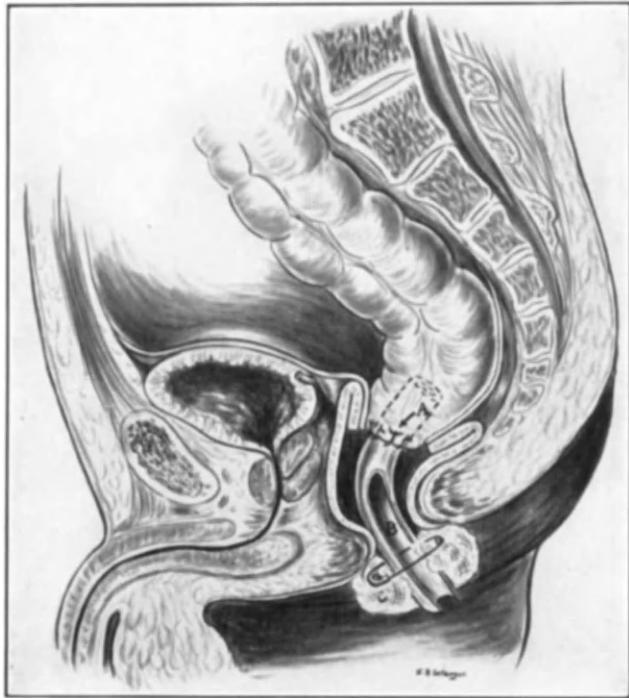

Fig. 654.—Showing diagrammatically the cut end of the sigmoid telescoped into the rectal pouch. A few sutures connect the peritoneum of both parts, so that, as the sigmoid is drawn down, peritoneal surface becomes applied to peritoneal surface. **A**, Ring of skin around artificial anus sutured to rubber tube; **B**, A slotted tube fixed in position with a safety-pin, used to keep the anastomosis in position and drain the rectal pouch; **C**, Gauze and safety-pin preventing the tube from going up.

As the sigmoid is functionless and the rectum patulous from the division of the sphincter ani, there is no more danger from this telescopic operation than from drawing the sigmoid on to the surface of the abdominal wall to make an ordinary abdominal artificial anus.

A difficulty, however, in this method is that sometimes it is not easy to make the opening in the rectal pouch, because the bladder falls over and adheres to the rectal stump.

The method is particularly applicable to *bad* cases of carcinoma of the lower end of the sigmoid, for the making of the telescopic anastomosis can be delayed for six or twelve months, when the patient will have greatly improved in health as a result of the removal of the malignant growth, and the circulation of the rectal stump, which is sometimes disturbed in these cases, will have improved.

CASE-HISTORIES

The following case-histories are cited to show the practical application of the sutured and telescopic rectosigmoid anastomoses in the defunctioned or excluded colon :—

Sutured Rectosigmoid Anastomosis.—

Case 1.—An old and very debilitated man. Carcinoma of the lower end of the sigmoid, acute intestinal obstruction, and a late stage of diabetes.

Stage 1 : Disconnecting anus in the proximal transverse colon.

Stage 2 : Rectosigmoid resection with closure of the rectal stump, and implantation of lower cut end of sigmoid into loin.

Stage 3 : Six months later—resection of sigmoid mucous-fistula (artificial anus) and anastomosis by suture of lower end of sigmoid with rectal stump.

Recovery : lived three years.

Case 2.—Female, aged 50. Diverticular tumour, intestinal obstruction.

Stage 1 : Disconnecting anus in the distal part of the transverse colon, and exploration of the abdomen. Large adherent mass filling the whole of the pelvis. Regarded as inoperable carcinoma of the sigmoid.

Stage 2 : Three months later, at a second operation, further scrutiny of the mass now gave the impression that it might be an inflammatory diverticular tumour, and not a carcinoma, as at first thought. It was, however, still irremovable.

Stage 3 : Six months later, at a third operation, it was found that as the result of six months' defunctioning of the disal colon, the tumour of the sigmoid had become so much smaller and less adherent that it now appeared possible to remove it ; and the whole of the lower two-thirds of the sigmoid, which was involved in the tumour-mass and widely adherent to adjacent structures, was removed. The severed end of the sigmoid was anastomosed to the upper part of the rectum. *Fig. 655* is a radiograph made six months after the operation of a barium clysma in this patient.

Telescopic Rectosigmoid Anastomosis.—

Case 3.—A very fat man, aged 56, a hotelkeeper, developed acute intestinal obstruction. He was operated upon in the country, and what was thought to be an inoperable carcinoma of the sigmoid was found.

In order to relieve the obstruction, an artificial anus was made in the upper end of the sigmoid.

When examined it was thought that the tumour was inflammatory, and that it was the result of an extensive diverticulitis.

At a second operation the whole of the sigmoid, including the portion bearing the artificial anus was removed. It was impossible to approximate

the divided ends of the bowel and therefore to make an anastomosis; consequently it was necessary to close the divided rectum by suturing the muscle-layer and the peritoneum separately (*see Fig. 652*); and also to

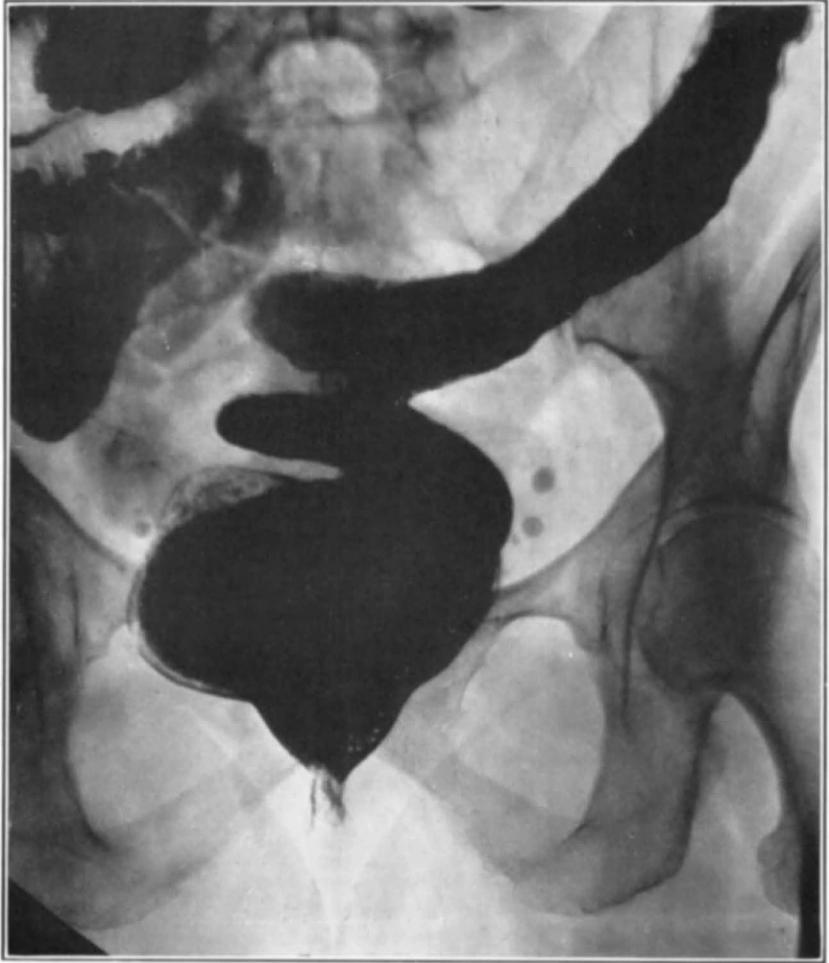

Fig. 655.—Radiograph of a case in which a diverticular tumour involving most of the sigmoid was removed, and the divided end of the sigmoid anastomosed to the upper part of the rectum. (*From the 'British Journal of Surgery'.*)

implant the distal cut end of the beginning of the sigmoid into the loin, where it would function as an artificial anus.

Four years later, at the request of the patient—who could not any longer tolerate the artificial anus—it was decided to make an attempt to unite the descending colon to the rectum. The radiograph (*Fig. 656*), shows the level of the division of the sigmoid—almost at its beginning—and the smallness of the rectal stump.

After making a disconnecting anus and preparing the distal colon, the sigmoid was joined to the rectal stump by a telescopic anastomosis made in the way already shown (*Fig. 654*).

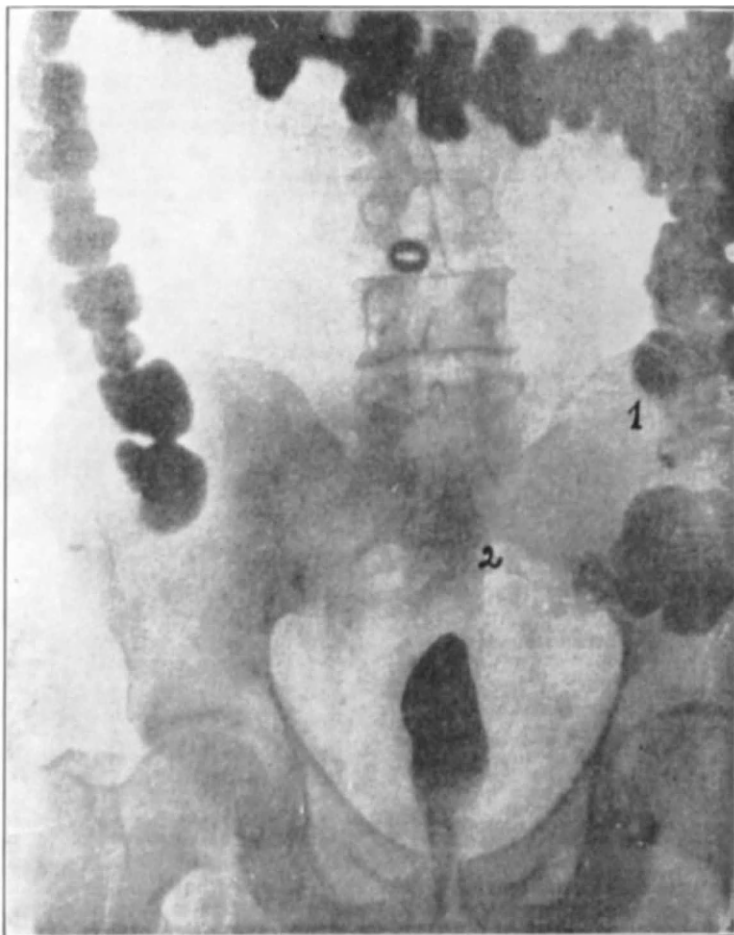


Fig. 656.—Showing radiograph of the descending colon and the rectal stump when, after four years, the distal end of the descending colon had elongated a little from the increased function imposed on it. Note the smallness of the rectal stump. 1, The lower end of the descending colon; 2, Stump of rectum. (*From 'Australian and New Zealand Journal of Surgery'.*),

The following were the detailed steps of the operation :—

1. The abdomen was opened by a median subumbilical incision.
2. An incision was so made round the artificial anus that a substantial ring of skin was left attached to the mucous membrane; the anus was then disconnected from the abdominal wall and the descending colon extensively mobilized.

3. A rubber tube 2.5 cm. (1 in.) in diameter, cut as shown in *Fig. 654*, was now sutured to the ring of skin which had been left attached to the artificial anus for this purpose.

4. A sponge-holder with a swab on the end was next introduced through the anus into the rectum and pressed against its upper blind end.

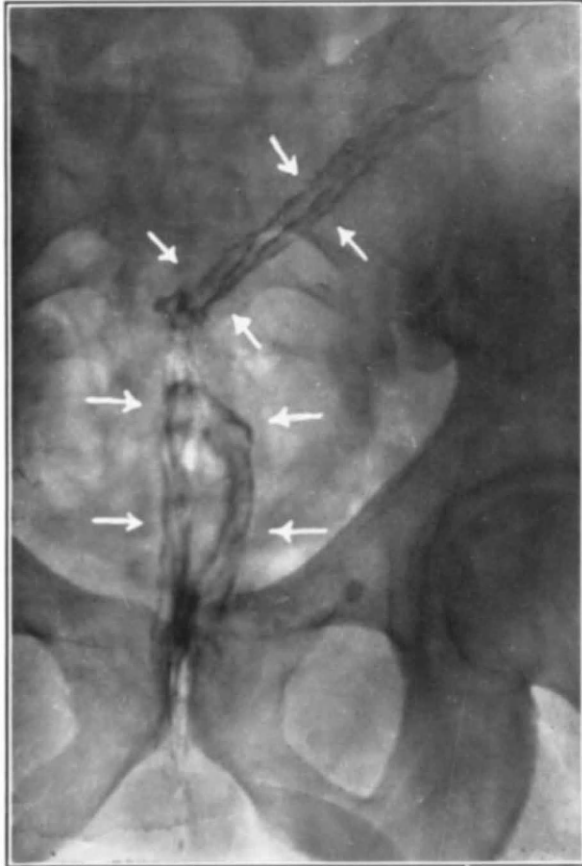


Fig. 657.—Radiograph of the rectum made after a barium clyisma followed by injection of air. It was taken four years after the telescopic operation. Note the straight tube-like rectocolic segment. (*From the 'British Journal of Surgery'.*)

An incision 3.75 cm. ($1\frac{1}{2}$ in.) long was made through the rectal wall. The forceps were now made to grip the end of the tube and draw it, with the attached bowel, through into the rectum.

5. The rectal stump had contracted from disuse, and, as the patient was very fat, a tunnel had therefore to be made posterior to the bladder before the rectum could be incised. Consequently, when the bowel was drawn through this tunnel, there was no space whatever to permit the manipulations required for the insertion of sutures in order to unite the cut edge of the rectal wall to that of the colon. Union of the bowel

ends was then attained as follows: The obliquely cut part of the tube was drawn down through the anus and kept in this position by means of gauze and a very large safety-pin inserted as shown in *Fig. 654*. The sphincter, grasping the obliquely cut part of the tube, prevented the tube from moving downwards; the safety-pin prevented it from going upwards. The bowel ends were therefore held in the position in which they were placed. The slotted part of the tube drained any contents which might have accumulated in the rectal cavity. A drainage tube was introduced abdominally down to the junction of the colon with the rectum.

The convalescence of the patient was uneventful. Four weeks after the operation, when it was found that the anastomosis was firmly healed, a little local anæsthetic was injected into the small strip of skin between the bowel ends, and the spur of the midcolic anus was crushed. The artificial anus then closed naturally in a very short time. Four years later a radiograph (*Fig. 657*) showed that this patient was functioning perfectly, and that no contraction had taken place at the telescopic union.

Case 4.—A woman, aged 55. Carcinoma of lower end of sigmoid.

Stage 1: Disconnecting anus made at the proximal part of the transverse colon, when an exploration revealed a carcinoma situated close to the lower end of the sigmoid.

Stage 2: Three weeks later—resection of the lower end of the sigmoid and the upper part of the rectum; closure of the rectum, implantation of the cut end of the sigmoid into the abdominal wall.

Stage 3: Many months later when the patient was in good health—mobilization of the upper part of the sigmoid and the descending colon, and the making of a telescopic anastomosis with the rectal pouch, the sphincter ani of which was divided.

This patient is now well. Function normal for sixteen months.

5. RESECTION OF CARCINOMA OF THE DESCENDING COLON OR SPLENIC FLEXURE

The following is a method of resecting a carcinoma of the descending colon and its peritoneal leaf with the glands contained therein; and also of restoring the continuity of the bowel.

The operation steps are:—

a. The distal colon is exposed. The peritoneum lateral to the sigmoid, the descending colon, the splenic flexure, and the proximal part of the transverse colon is incised by lifting the operating frame and displacing the intestines medially to create a space so that this incision can be made.

b. The sigmoid, the descending colon, the splenic flexure, and the distal part of the transverse colon are in turn mobilized, and with these parts of the bowel is lifted the peritoneal leaf (with glands) of the posterior abdominal wall opposite to the descending colon.

c. The box clamps are applied to the upper third of the sigmoid and the bowel is divided between them. The mesentery and vessels of the upper part of the sigmoid mesentery are divided, also the

peritoneal leaf opposite the descending colon and its vessels, and finally the peritoneal leaf and vessels (area supplied by the left colic) of the distal part of the transverse colon.

d. The isolated segment consisting of the upper third of the sigmoid colon, the descending colon, the splenic flexure, and the distal half of the transverse colon is drawn out through the upper angle of the wound where the parietal peritoneum is sutured to it.

e. The sigmoid (which has been previously mobilized) is now, with its box clamp and its peritoneal leaf, drawn upwards towards the kidney, so that its mesenteric leaf will cover the extensive bare space on the posterior abdominal wall left by the removal of the peritoneal leaf pertaining to the descending colon.

So as to anchor the sigmoid and its leaf in proper position, the box clamp is drawn through and fixed in a stab wound just below the last rib.

Omentum is used to cover what little bare space is not covered in the above way, and the wound in the abdominal wall is closed.

f. The segment of bowel containing the growth is amputated after the wound is closed.

The implanted cut end of the transverse colon functions as an artificial anus, and the box-clamped end of the sigmoid lying in the stab-wound finally closes.

Many months later, when the patient is very much better, and when the possibility of any metastasis has passed, either of the following methods may be employed to restore continuity of the bowel : (1) Where the remaining parts of the sigmoid and transverse colon, after mobilization, can be approximated, a colonic end-to-end anastomosis can be made under the protection of a disconnecting anus at the hepatic flexure. (2) Where the colonic segments cannot be approximated, the ileum is divided at its lower end, the proximal end is anastomosed to the sigmoid colon, and the distal end implanted into the abdominal wall to make a mucous fistula. The patient's condition then is this : He has two mucous fistulæ, which give little trouble, but he is continent ; and he has had a very wide removal of a carcinoma in a situation which is difficult to deal with surgically, and also a resection of all the glands and the mesentery related to this growth.

CHAPTER LXXXIX

THE SURGERY OF MALIGNANT DISEASE OF THE
RECTUM

PATHOLOGICAL TYPES

GENERALIZING broadly, and from a clinical point of view, carcinoma of the rectum may be divided into two main types :—

1. *An invasive malignant type*, in which the expectation of life is very poor, no matter how ruthless or extensive the operation may be—that is, carcinoma in the young, and carcinoma which shows a definite tendency to metastasize early and to infiltrate widely.

2. *A more benign and less invasive type*, in which the expectation of life is good—that is, the carcinoma which tends to remain local and not to metastasize in the early stages, and which, according to Dukes¹ and to Westhues² occurs in 45 to 50 per cent of cases.

STANDARD OPERATION METHODS

The standard operations for carcinoma of the rectum are the abdomino-perineal (the Miles operation) and the perineal.

The abdomino-perineal operation, in which the sigmoid, its mesentery, the rectum, and the anal canal are removed, is conceived on sound lines, and will probably remain the operation of choice in selected cases.

It has, however, certain disadvantages. It is primarily an abdominal dissection of the rectum, and is therefore an operation which is attended with a good deal of shock. It leaves the patient incontinent. It is, moreover, carried out on the functioning rectum, in which operation is more dangerous and difficult; and it is an operation which in the hands of an average surgeon has a high mortality-rate—good surgeons admit a mortality-rate of 20 to 30 per cent.

This operation may certainly be the proper one for all lowly-situated and all unfavourable types of rectal growth; but it is doubtful if it should be employed for all rectal carcinomas, many forms of which are relatively benign.

The perineal operation, which is more limited in its scope, is less dangerous. It is more suitable for the second class of rectal

carcinoma, the less invasive type (if the surgeon can be sure of his ground), especially in its early stages. Of this class, if the surgeon can recognize them, there are rectal carcinomas in which the expectation of life is extremely good ; for we have all seen patients with rectal carcinoma who, with the help of a colostomy, have lived six, seven, or eight years. In such cases, an extensive radical operation is certainly quite unnecessary, and a more conservative operation will always suffice.

Thus in relation to the operative treatment of carcinoma of the rectum there are two schools of thought :—

The *first*, basing its principles on an extensive spread of the carcinoma, makes the operative approach from the abdomen and carries out an abdomino-perineal type of operation.

The *second*, regarding the spread of the carcinoma as not always a wide one, and regarding, too, a wide spread as an inoperable case, carries out the operative approach from the perineum.

The surgeon may, therefore, take advantage of the peculiar pathology of carcinoma of the rectum and select the type of operation which will suit the particular circumstances, when it will be found that it will not always be necessary to perform extensive operations that sacrifice the sphincter.

Lower Sigmoid Growths.—Carcinoma of the lower part of the sigmoid which involves removal of part of the rectum is usually dealt with (1) by a Miles operation, which sacrifices the whole rectum, or (2) by rectosigmoid resection with closure of the lower end of the bowel and implantation of its upper end to form an artificial anus.

THE AUTHOR'S METHODS

My own views^{3,4} in regard to all operations for carcinoma of the rectum are that (a) I like to approach them in a defunctioned rectum (*see* p. 980); and (b) according to the position and to the more or less invasive character of the growth, I like to approach an operation for a carcinoma of the rectum (and the lower end of the sigmoid) along one of the following lines: (1) An abdominal rectosigmoid resection and anastomosis; (2) A limited perineal operation; (3) A perineo-abdominal rectosigmoid mobilization, permitting a conservative operation (preservation of sphincter) if circumstances permit, and if they do not, a radical operation.

1. The Abdominal Rectosigmoid Resection and Anastomosis.—Where the growth is in the *lower end of the sigmoid* and its resection also involves the removal of the upper part of the rectum, I approach the operation from the abdomen; isolate and resect the

diseased segment, dissecting the upper part of the rectum from above; and anastomose the divided sigmoid to the rectal stump.

2. The Limited Perineal Operation.—If the patient is old and weak, I carry out a limited perineal operation as described on p. 1012—the least dangerous operation for an old and feeble person.

3. The Perineo-abdominal Method (Radical or Conservative).—In most cases of carcinoma of the rectum (even where the growth is low in the rectum and I know I shall have to sacrifice the sphincter), I approach the operation from the perineum.

I employ a preliminary defunctioning operation which enables me: (*a*) To determine the operability from the point of view of an abdominal spreading; (*b*) To operate on an empty and clean rectum; (*c*) To begin the dissection from below, where, if I find that the growth is inoperable, I can retreat early in the operation and before I cut any important vascular connexions; and (*d*) To finish the dissection abdominally so that I avoid the difficulty and delay which occur in the abdomino-perineal approach of incarcerating the divided sigmoid (often dilated and hypertrophied) under the pelvic peritoneum.

In those cases where the growth is high in the rectum, and where in consequence it is unlikely that the neighbourhood of the sphincter will be involved, I spare the sphincter and begin the isolation of the rectum at its junction with the anal canal, isolating the rectum and the sigmoid with its mesentery without dividing any vascular connexions; and I deliver this whole vascularized recto-sigmoid segment abdominally. Having preserved the anal canal and the vessels, I am in a position to judge whether I should carry out a *conservative* or a *radical* operation; that is, I am in a position to study the metastatic spread in the mesentery and the extent of the infiltration of the rectal wall, and to see the length and therefore estimate the extensibility of the sigmoid. If I feel that I can elongate the sigmoid so as to make it reach the sphincter and still remove enough sigmoid and mesentery to eradicate the disease completely (not a frequent occurrence), I perform a *conservative* operation: I divide the inferior mesenteric artery in the proper spot, return the elongated sigmoid stump through the anal canal and sphincter, and amputate that segment of bowel which protrudes beyond the anus.

If on the other hand I find, for one reason or another, that I cannot carry out the conservative operation, I perform the radical operation to be described subsequently: I amputate the sigmoid as high up as possible, and the whole of its mesentery, and make an abdominal anus.

Thus at the penultimate of the operation, when I have inspected the type and extent of the malignant disease, and when I am in a position to make a sound judgement, I can decide whether the operation shall be conservative or radical.

REFERENCES

- ¹ GABRIEL, W. B., DUKES, CUTHBERT, and BUSSEY, H. J. R., "Lymphatic Spread in Cancer of the Rectum", *Brit. Jour. Surg.*, 1935, **23**, Oct., 395.
- ² WESTHUES, H., *Arch. f. klin. Chir.*, 1930, **161**, 582.
- ³ DEVINE, H. B., *Brit. Med. Jour.*, 1935, **2**, 1245.
- ⁴ DEVINE, H. B., *Med. Press and Circ.*, 1935, **190**, No. 5022.

CHAPTER XC

OPERATION ON THE DEFUNCTIONED RECTUM

THE principle of the method of operating on a defunctioned distal colon (*see* p. 943) can with equal value be extended to operations on the rectum: operations can be carried out more safely and easily on the defunctioned rectum, and in particular those dangerous operations in which it is necessary to unite the rectum to the sigmoid.

In the surgery of the rectum, operations for *carcinomatous growths* are the most important problem, for these growths are of frequent occurrence, being rather more than one-third of the carcinomatous growths of the whole alimentary canal. And operation for carcinoma of the rectum is well worth while, for, although the operation is difficult and serious and the patient runs a high operative risk, nevertheless, if he recovers he may in quite a majority of cases enjoy a considerable length of life, because, as pointed out, about 50 per cent of cases of carcinoma of the rectum are of a moderate type of malignancy.

In the surgery of the rectum, too, a problem almost as exacting as that of carcinomatous growths is the surgery of *inflammatory diverticular tumour of the sigmoid*, for, in such cases, the whole sigmoid colon may be involved.

THE UNFAVOURABLE CONDITIONS PECULIAR TO THE RECTUM

The conditions peculiar to the rectum which are adverse to operations on it and involve special difficulties are as follows:—

1. Its septic contents.
2. The powerful muscular movements which take place in its walls when it is discharging fæcal contents.
3. Its equipment with a sphincteric apparatus, which, because of its muscular obstruction in the functioning rectum, will never allow a wound proximal to it in the rectal wall to heal.
4. Its inaccessible situation; it is encased in the bony pelvis, and is therefore difficult of access for the manipulations required for its resection.

**OPERATIVE APPROACHES FOR CARCINOMA OF THE LOWER
END OF THE SIGMOID, THE RECTOSIGMOID
JUNCTION, OR THE RECTUM**

These are : (a) The abdominal rectosigmoid resection ; (b) The perineo-abdominal resection (radical or conservative).

The Abdominal Rectosigmoid Resection.—In the past, it was my custom to deal with cases of carcinoma of the lower end of the sigmoid or of the rectosigmoid junction by one of the two methods indicated on p. 978. In some cases, dependent on circumstances, I performed a radical Miles operation. In others I resected a segment containing the growth and including the lower half of the sigmoid and the upper part of the rectum. I then closed the rectal stump, covered it with peritoneum, and implanted the cut end of the sigmoid into the abdominal wall as an artificial anus. I also employed this latter method for inflammatory diverticular tumour of the lower end of the sigmoid. In all cases I made the patient incontinent. I never attempted to anastomose the sigmoid to the rectum, for I knew that operations on the rectum in the presence of a functioning bowel were usually unsuccessful, primary union of an anastomosis always failing, and the resultant infection leading to fatal results.

Nowadays, since I find that I can with comparative safety carry out these rectosigmoid anastomoses if I make them and allow them to heal in a properly defunctioned and prepared distal colon and rectum, I have no hesitation in anastomosing the sigmoid to the rectum.

Thus, being able with some degree of success to join the divided end of the sigmoid to the rectal stump in the defunctioned distal colon, it is often possible to remove growths of the lower or lowest part of the sigmoid and, without sacrificing the efficiency of the operation, preserve continence for the patient.

This method is eminently suitable for diverticular tumours which involve the whole sigmoid, in which the blood-supply of the rectum is not necessarily interfered with.

The steps in the technique of a sutured abdominal recto-sigmoid resection are described on p. 961 et seq.

The Perineo-abdominal Method of Resection of the Rectum (Radical or Conservative).—A perineo-abdominal method of resection, which can be either radical or conservative, should be employed when dealing with those carcinomatous growths of the rectum which, judged from the standpoint of the usual examination, require a radical operation, but which, in a small proportion of

cases, when examined at the time of the operation, are found to be favourable for a conservative operation; that is, for an operation which preserves the patient's continence.

The Principles of the Perineo-abdominal Resection.—The main principles involved in this operation are as follows:—

1. The abdominal spread of the carcinoma is reviewed at a preliminary operation (a defunctioning operation); that is, the operability of the growth from the abdominal side is ascertained.

2. The operation is carried out on a defunctioned and prepared rectosigmoid.

3. The perineal and the abdominal parts of the operation are carried out simultaneously by the co-operation of the surgeon and the assistant surgeon (after the method of Kirschner).

4. In order to avoid the shock caused by abdominal dissection, the dissection of the rectum is begun and practically completed from the perineum, the mobilized rectosigmoid segment being merely delivered abdominally.

5. The rectum is isolated without interfering with its superior hæmorrhoidal blood-supply, and the rectosigmoid segment is delivered on to the abdominal wall with its blood-supply intact.

6. If the conditions are such that a conservative operation cannot be carried out, the whole of the sigmoid and its mesentery are removed with the rectum—that is, the operation is made a *very radical* one.

7. If the conditions are such that a conservative operation can be carried out, the ligation of the inferior mesenteric artery is made abdominally; that is, made in a position (unlike ligation from the perineum) where it can be carried out with accuracy in regard to the elective site of ligation and to injury of the anastomotic points.

THE TECHNIQUE OF THE PERINEO-ABDOMINAL OPERATION

The technique of the radical or conservative perineo-abdominal operation is as follows:—

Preliminary Exploratory and Defunctioning Operation.—At a preliminary operation the abdomen is explored and the distal colon defunctioned; then, for a period of three weeks, the defunctioned colon is prepared in the manner already described (Chapter LXXXVI).

Position of the Patient.—The position recommended, in order to permit of the abdominal and perineal dissection going on simultaneously, is as described in the following paragraphs.

The Question of a Radical or a Conservative Operation.—

Finishing with a Radical Operation.—If it has been found necessary to remove the anal canal there can be no question of a conservative operation, and a radical one is carried out: the inferior mesenteric artery is ligated, and the whole of the sigmoid and all its mesentery is amputated, its divided end being implanted into the anterior abdominal wall. In these circumstances the transverse colic anus may be allowed to continue to function; and it will be found that in many instances it is more controllable than a sigmoid anus. But if circumstances require, the transverse colic anus, with the aid of a little local anæsthesia, can easily be closed, when the sigmoid anus will function.

Thus in invasive malignancy with metastasis in the glands the whole of the sigmoid mesentery is removed (as it should be), a desideratum which is difficult to attain in an abdomino-perineal approach because it is often impossible to incarcerate the whole sigmoid (frequently dilated) under the peritoneum.

Finishing with a Conservative Operation.—If, however, the anal canal has not been removed, the question now arises whether the extent of the disease and the anatomical conditions permit the performance of a conservative operation. The surgeon carefully examines the extent of the disease: he examines the growth in the rectal wall itself to see if it has penetrated through the muscular coat; he examines any glandular metastases in the mesentery and their extent.

If the growth is one of those invasive types of carcinoma of the rectum in which the metastatic spread in the mesentery of the sigmoid is definite, no conservative operation should be attempted, but the rectum with the sigmoid and its mesentery should be removed in the manner described.

If, on the other hand, the local lesion is not very invasive—that is, if it is not extensive, or has not penetrated the muscular walls; if no metastatic glandular spread is obvious; if there are only a few glands in the lower part of the mesentery, and these, as is often the case, are of doubtful malignancy—then the surgeon will consider the question of carrying out a conservative operation. He will follow this examination by an anatomical examination of the sigmoid, in order to see whether it will be long enough, when it is straightened by division of its mesentery and of its vessels at the correct places, to be passed through the anal canal and to extend a little beyond its lower margin; that is, long enough to fashion a new anal canal and thus preserve continence for the patient.

A Direct Circulation for the New Anal Canal.—If the malignant condition is such that a conservative operation can be carried out, and if the sigmoid is long enough when elongated to reach the anus, as in the case illustrated in *Fig. 678*, the next step is to provide for a circulation to that part of the sigmoid—probably the middle—which is to form the anal canal.

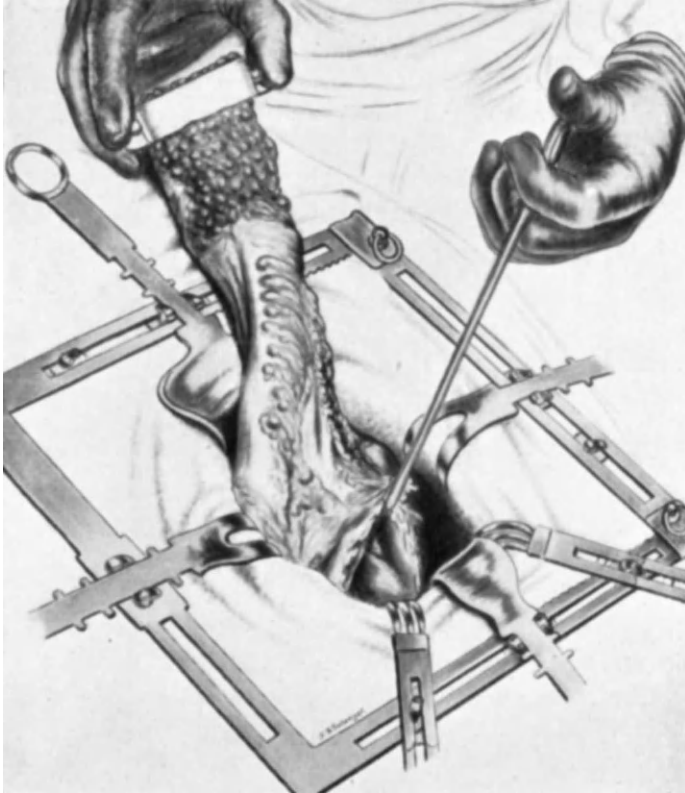


Fig. 678.—Showing the inferior mesenteric artery divided below the origin of the first sigmoid artery. This division allows still further elongation of the rectocolic segment, so that when the rectum and sigmoid are brought down to the anal canal, a segment adequate for the removal of the disease can be excised. (*From the 'British Journal of Surgery'.*)

In a particular case the sigmoid may be big and the first sigmoid artery long, and then the inferior mesenteric artery can be divided below the first sigmoid artery. This long sigmoid artery will reach to the anal canal, so that the part of the sigmoid which is to form the new anal canal will have a direct circulation from the first sigmoid artery, and the circulation of the anal canal will never be in doubt.

operation for carcinoma of the rectum. The abdominal anus now becomes a permanency, and serves just as well as an inguinal anus, or even better. The patient, therefore, is practically no worse off because a conservative operation has been attempted.

An Indirect Circulation for that Part of the Sigmoid which is to form the New Anal Canal.—Of all requirements for a successful

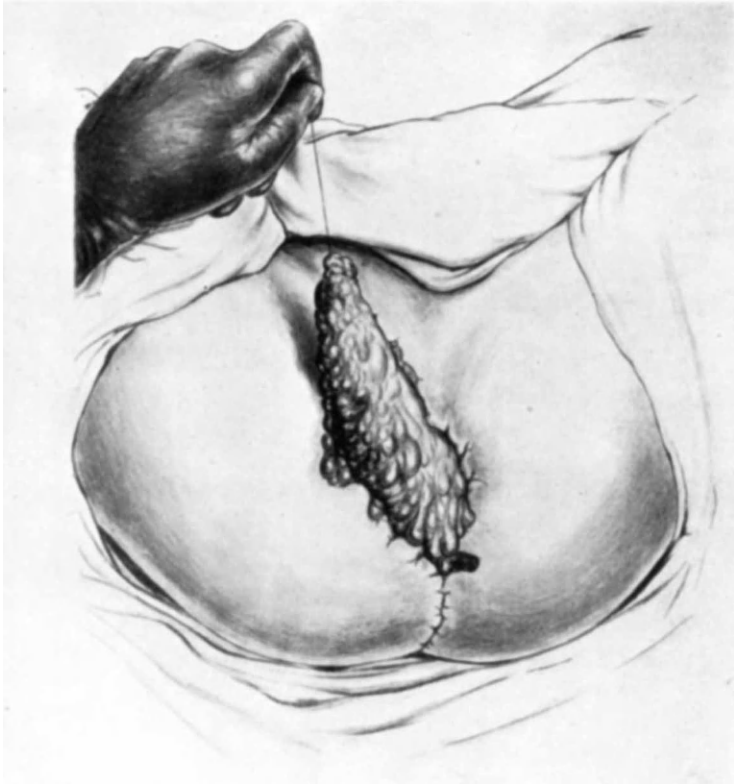

Fig. 681.—Showing the short piece of rectosigmoid segment left protruding beyond the anal canal after the diseased portion has been amputated (here shown too long).

conservative operation, the most difficult one to fulfil is the provision of an adequate circulation for that part of the sigmoid which is to form the new anal canal. In only a few cases, in which the sigmoid and its arteries are specially long, can a direct circulation be provided, as in the case described above. In other cases it is necessary to depend on an indirect circulation, and in the perineo-abdominal operation (conservative), where this circulation can be

determined abdominally, and therefore precisely, the chances of getting an adequate circulation for the anal sigmoid segment are quite good—a long way better, at any rate, than if the ligation were made from the perineum.

Thus if the sigmoid arteries are short and for this reason it becomes necessary to rely on a collateral circulation, the division of the inferior mesenteric artery abdominally can be made at different levels according to the manner in which the sigmoid arteries arise from the inferior mesenteric artery.

Where they arise in a bunch, or where the first sigmoid comes off the left colic (as it does in eleven out of twenty cases, according to Hamilton Drummond¹), the ligature will have to be placed below the left colic. The collateral circulation will then depend on the richness of the anastomosis between the left colic and the first sigmoid, or on that from the first sigmoid loop when this arises from the left colic.

Where, however, the sigmoid* arteries arise separately from the inferior mesenteric, the ligature should be applied between the first sigmoid and the left colic artery.

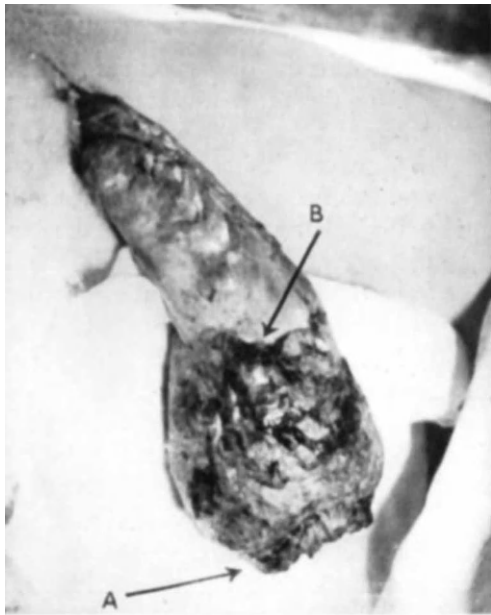
Author's Views in Regard to a Collateral Circulation for the New Anal Canal.—Personally, I have been always afraid to rely very much on a collateral circulation. However, in regard to this collateral circulation, I have recently made several operative observations which have given me more confidence in its adequacy. I have learnt from these observations how a collateral circulation will behave in the live body, and I have therefore more confidence in its efficiency than I had previously. This factor, taken in conjunction with the knowledge that, as I now operate on a defunctioned distal colon and rectum, I am in a position to retreat if gangrene of the rectal stump occurs, makes me feel that I shall, in the future, take more advantage of this collateral circulation in order to carry out a conservative operation which, in its radical quality, may be almost equivalent to that of the standard radical operation.

With regard to this collateral circulation, my conclusions are based on the following observations, made on living patients, and for this reason of considerable value. In the case of a woman, after making an abdominal incision I tied and divided the inferior mesenteric artery distal to the left colic, leaving the sigmoid and rectum in position. Three weeks later, I mobilized the sigmoid and rectum from the perineum, with a view to their removal, and found them both highly vascularized: an adequate rectal and lower sigmoid circulation had taken place following the division of the inferior mesenteric artery, probably because the lapse of time had

determined an adequate circulation much in the same way as, given sufficient time, an adequate circulation can be determined in a tube-pedicle skin graft.

In the case of three other patients, I operated from the perineum ; I mobilized the rectum and lower part of the sigmoid, isolating the rectosigmoid segment with its mesentery, and with its superior hæmorrhoidal blood-supply intact, and then delivered the whole segment through the abdominal incision on to the anterior abdominal wall. Instead of at once amputating this rectosigmoid segment to make a radical operation, I allowed it to remain on the abdominal

Fig. 682.—The same segment as shown in *Fig. 677*, taken ten days after operation. **A**, Mark where the box clamp was applied ; **B**, Junction of the rectum with the peritoneum-covered sigmoid. The whole of the segment has shrunk very much longitudinally, but it is alive to its lowest part, that is, to the lower end of the rectum, where it was divided at the anorectal junction.



wall in dressings ; but I divided the inferior mesenteric distal to the origin of the left colic in one case, and distal to the origin of the first sigmoid in the others.

Thus this rectosigmoid segment could be vascularized through a collateral circulation only—through the left colic to the first and second sigmoid arteries, or through the anastomoses of the first and second sigmoid arteries. In all cases these isolated rectosigmoid segments, the longest one measuring 22 in., were allowed to lie in dressings for a week on the abdominal wall. *Fig. 677* is a photograph of the 22-in. segment taken immediately after the operation, and *Fig. 682* is from a photograph of the same segment taken ten days after the operation. In this case the whole segment remained

completely vascularized. In the others only a small amount of gangrene occurred at the lower ends of the segments.

As it is necessary in conservative rectal operations for only a very limited extent of the sigmoid to be dependent on a collateral circulation, the above observations, in which nearly the whole of the rectum was nourished by a collateral circulation, are quoted to show that by careful 'determination' it is possible to establish an adequate collateral circulation to the stump of the sigmoid in cases where the conditions permit the performance of the conservative operation.

THE RELATIVE MERITS OF THE PERINEAL AND THE ABDOMINO-PERINEAL OPERATIONS

As has already been pointed out, there is some difference of opinion as to the most advantageous surgical treatment of carcinoma of the rectum.

The radical abdomino-perineal operation, based on sound principles, has been regarded during the last ten or more years as the routine surgical treatment. With the lapse of time, however, it has been found that in average hands the mortality is high, and that the successful operative results obtained by masters of the art of rectal surgery cannot be reached by even good general surgeons, and still less by the 'occasional' surgeon. Miles^{2,3} reports a death-rate of 10 per cent. Joll (personal communication) states that his mortality-rate is 20 per cent. Kirschner, carrying out the abdomino-perineal method by synchronous operation, gives an operative death-rate of 30 per cent.

On the other hand, the somewhat supplanted perineal operation, regarded as not founded on ideal lines, is recognized as giving a much lower mortality-rate. Yet it is surprising to find that when, after a considerable lapse of time, the end-results of more limited perineal operations carried out in the earlier years of rectal surgery have been investigated, they have been found to be unexpectedly good.

Lockhart-Mummery gives his five-year survival-rate as 52 per cent in a total of 142 operation survivals.

Gabriel, Dukes, and Bussey⁴ investigated the follow-up records at St. Mark's Hospital, London. They found that in *Group A* cancer of the rectum, those cases where the growth was removed by perineal excision before there was time for growth extension to the perirectal tissues, 91 per cent of the operation survivals were alive after five years; in *Group B*, cases where the growth had extended by direct spread to the perirectal tissues but had not caused deposits in the glands, 54 per cent of patients survived for five or more years; and

made me shift my ground to the perineo-abdominal type of operation which I have described.

Thus, a possibility of ultimate success in conservative or in perineal operations is, of course, based on the pathological fact that in a considerable number of cases carcinoma of the rectum remains local; and that once carcinomatous metastases have spread to the glands of the mesentery of the sigmoid it is doubtful whether the radical operation completely removes this mesenteric spread; and indeed, whether in some of these cases it benefits the patient any more than by removing the local growth and thus giving him a temporary respite, often only the length of time of the natural course of the disease—three years.

Table I.—RECTAL CARCINOMA: RESULTS OF TWELVE OPERATIONS BY AN EXTENDED PERINEAL METHOD

SEX	AGE	STAGE OF DISEASE	CONTIN- ENCE	DURATION OF LIFE AFTER OPERATION
F.	49		+	5 years. Local recurrence
M.	55		+	12 years
F.	42	Had been considered inoperable	+	15 years
F.	60		+	10 years
F.	45		—	18 years. Had syphilis as well as carcinoma of the rectum. Gangrene of stump occurred. Second operation to make abdominal anus
F.	50	Had been considered inoperable	+ (?)	12 years. Continent anus, then stricture occurred. Second operation to make abdominal anus
M.	50	Very late	+	2 years. Fixation to prostate and bladder. Died of local recurrence
F.			+	1 year. Local recurrence. Had abdominal anus made
M.	55	Late	+	2 years. Later developed urinary fistula
M.	66	Very late	—	5 days
M.	77	Very debilitated	—	6 days. Pneumonia
M.	48	Late	—	5 weeks. Cystitis. Low sepsis in pelvis. Good deal of cancer toxæmia beforehand

TWO-STAGE PERINEAL OPERATION

The simplest method of operation for resection of the rectum is undoubtedly that one in which at a first-stage operation an abdominal anus and an abdominal exploratory operation are made, and at a second-stage operation the rectum is resected from the perineum, the segment of sigmoid colon left below the abdominal anus being closed at its lower end, so as to form a blind pouch.

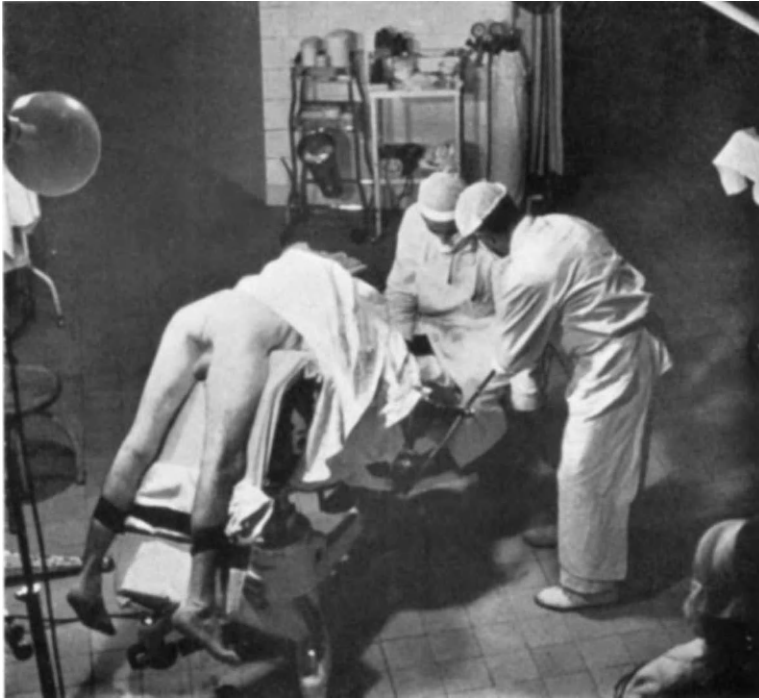

Fig. 684.—Usual position of patient for the two-stage perineal operation.

The patient should be operated on in the face-down position, with the thighs flexed (*Fig. 684*). The lateral position may also be employed.

A diathermy knife connected to a hand-operated switch should be used for the dissection: it makes a quicker dissection and a cleaner cut, and therefore lessens shock; it seals the lymphatics for a few days and prevents the absorption of toxic tissue products from the big wound, which is probably the cause of the collapse that often sets in two or three days after an operation of this type.

Nitrous oxide, or spinal anæsthesia according to the method of Howard-Jones or Kirschner's most recent method (*see* Chapter XLVII), should be used for very bad cases, or for those with pulmonary trouble.

The operation has a low mortality-rate, and is therefore suitable for bad risks. Its disadvantage is that it is sometimes followed by a sacral fistula.

In England, Lockhart-Mummery's name is associated with this operation. His results, for which I am indebted to Mr. O. V. Lloyd-Davies, are shown in *Tables II* and *III*.

Table II.—RESULTS OF PERINEAL EXCISION ON A FIVE-YEAR BASIS
(*St. Mark's Hospital, London*)

CLASSIFICATION OF GROWTH	OPERATION SURVIVALS	UNTRACED AND DIED OF OTHER CAUSES	ALIVE AT 5 YEARS	5-YEAR SURVIVALS
Group A ..	30	2	26	per cent
Group B ..	50	7	28	93
Group C ..	62	5	13	65
Total ..	142	14	67	23

Table III.—OPERATION MORTALITY AFTER PERINEAL EXCISION OF THE RECTUM
(*St. Mark's Hospital, London*)

CLASSIFICATION OF GROWTH	SUBMITTED TO OPERATION	DIED FROM OPERATION	OPERATION MORTALITY
Group A ..	46	0	per cent
Group B ..	100	5	0·0
Group C ..	140	15	5·0
Total ..	286	20	10·7

IMPROVED METHOD OF CLOSING THE CUT END OF THE SIGMOID

In the high sacral operation described in this chapter the cut end of the sigmoid can be most effectively closed by the displaceable crushing and suturing instrument devised by Professor von Seeman.

The clamping blades of this instrument can be moved through a range of 180° into any desired position. It can therefore be used high up in the pelvis in a confined space, and it is accordingly

most useful for closing the cut end of the sigmoid in this operation. The illustration (*Fig. 685*) shows its use in amputation of the diseased rectal segment.

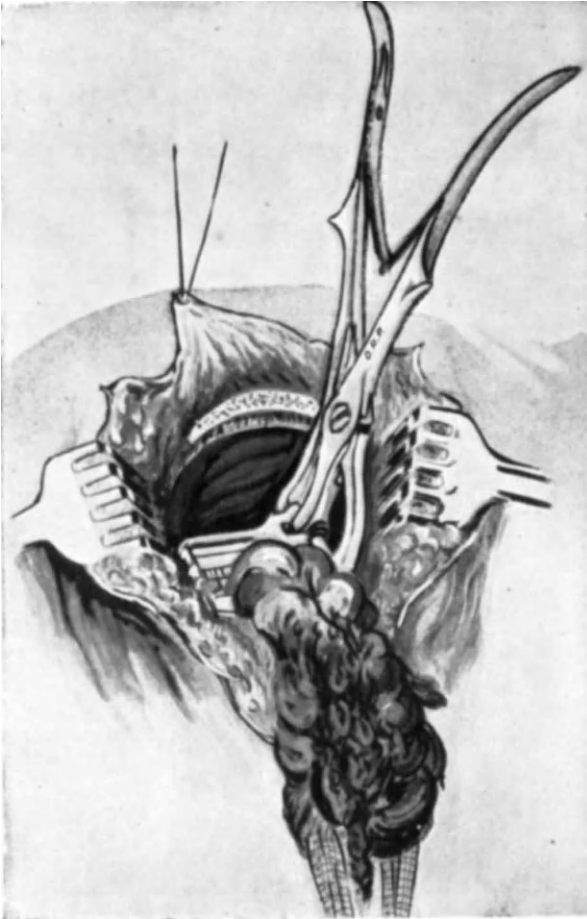


Fig. 685.—Von Seeman's crushing and suturing instrument in use.

REFERENCES

- ¹ DRUMMOND, HAMILTON, *Brit. Jour. Surg.*, 1914, 1, 677.
- ² MILES, W. ERNEST, "Rectum and Anus", *Post-graduate Surgery* (Ed. R. Maingot), 1936, 1, pt. iii, 1408. London: Medical Publications Ltd.
- ³ MILES, W. ERNEST, *Ibid.*, 1472.
- ⁴ GABRIEL, W. B., DUKES, CUTHBERT, and BUSSEY, H. J. R., "Lymphatic Spread in Cancer of the Rectum", *Brit. Jour. Surg.*, 1935, 23, Oct., 395.
- ⁵ WESTHUES, H., *Arch. f. klin. Chir.*, 1930, 161, 582.

CHAPTER XCII
OPERATION ON THE FUNCTIONING RECTUM

ABDOMINO-PERINEAL RADICAL OPERATION

IN performing this operation—the Miles type—it is an advantage, as recommended by Kirschner, for an abdominal and a perineal operator to operate simultaneously. In this case the general steps of the operation, as I perform it, are:—

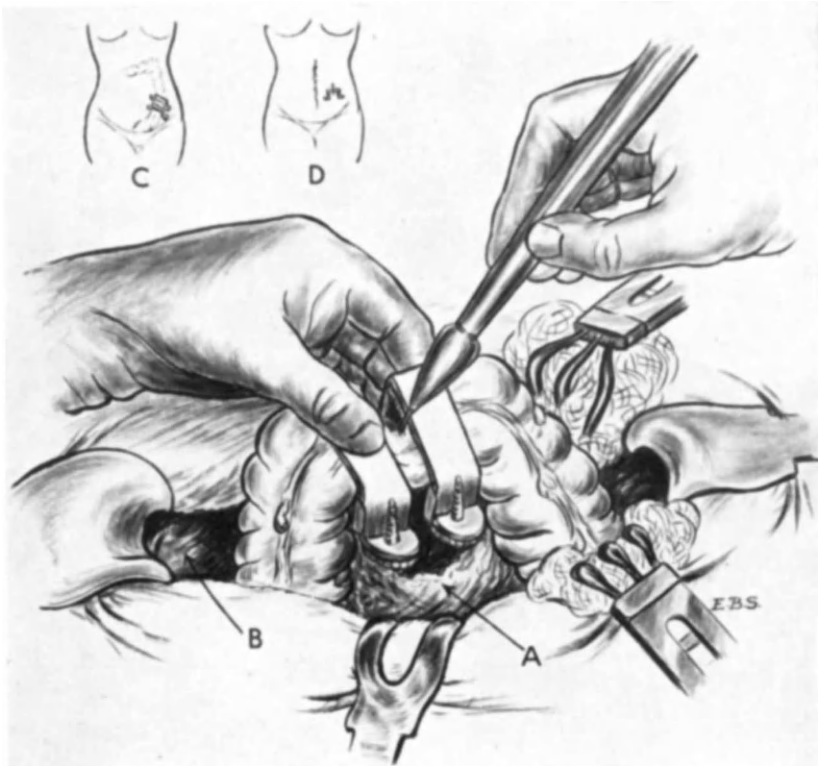


Fig. 686.—The sigmoid being divided between clamps, using a diathermy knife. *A*, Mesentery of the sigmoid; *B*, Peritoneum of the parietal wall. *Inset*: *C* shows the two box clamps between which the sigmoid is divided; *D* shows the box clamp, on the proximal cut-end, pulled through a stab wound to make an artificial anus.

1. The position described and illustrated on p. 991 is the best one for the simultaneous procedure.

2. The abdomen is opened through a sub-umbilical midline incision, and the author's operation frame with impermeable wound covers inserted into the wound (see *Fig. 674*. p. 998).

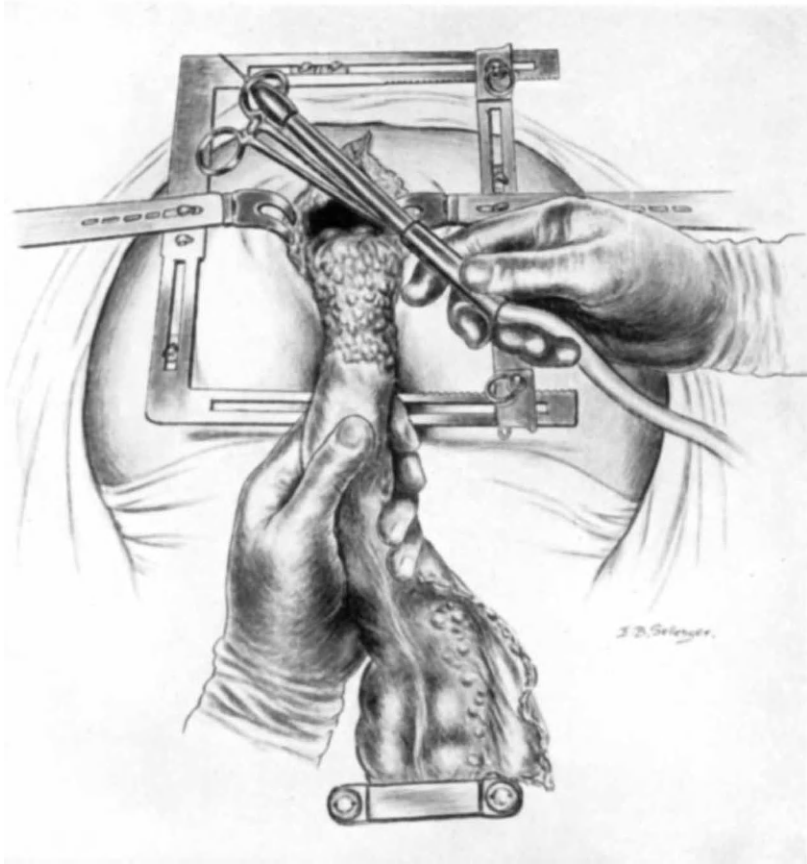


Fig. 687.—Perineal part of abdomino-perineal operation on the functioning rectum. Pressure on the sigmoid segment everts the plane of the anterior rectal wall and displays it for dissection from above downward.

3. By means of the 'mechanical hands' the small intestines are locked away from the area of the operation into the abdominal cavity.

4. Box clamps are placed on the sigmoid at the proposed line of division, and this structure is divided between the clamps with

a diathermy knife ; the divided ends of the bowel are then sterilized by contact with the coagulating current (*Fig. 686*).

5. The peritoneal attachments, the mesentery, and the inferior mesenteric artery are divided.

6. The rectosigmoid segment is isolated by driving the hand down behind the rectum to the base of the coccyx, through a natural tissue-plane which opens easily.

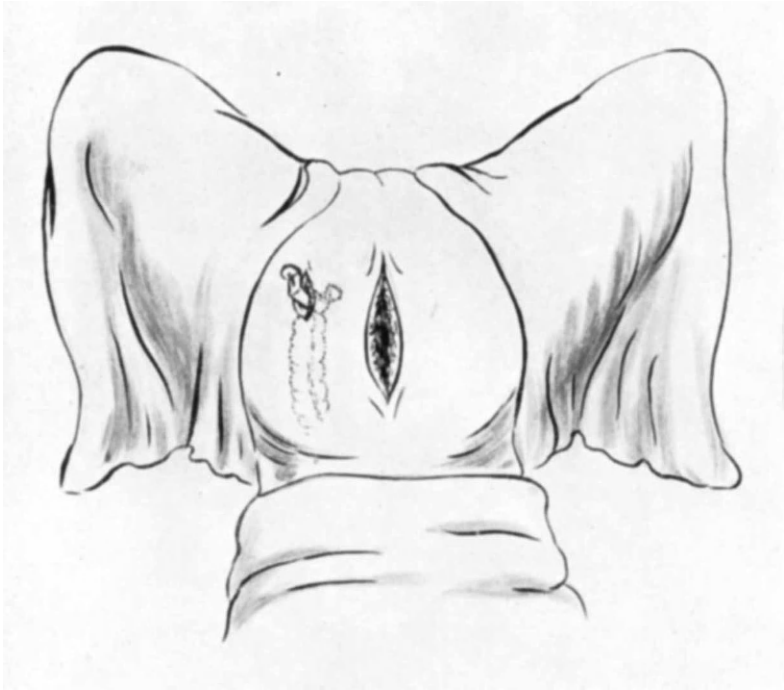


Fig. 688.—The box clamp being drawn endways through the stab incision in the left iliac fossa to make an artificial anus. (View from head end of operation table.)

7. Meanwhile the perineal operator has isolated the anal canal and closed it with a box clamp (*see p. 994*), removed the coccyx, and with the spade-pointed dissecting scissors isolated the anal canal and posterior and lateral planes of the rectum.

8. At this stage the abdominal operator passes the box clamp, through the opening made posteriorly to the rectum, to the perineal operator. The latter draws the clamp (with the sigmoid) through this cavity and then forcibly downwards, and thus everts and reveals the plane of cleavage of the anterior rectal wall—a plane which can

then be readily followed and dissected under sight and from above downwards, which makes an easy and therefore an accurate dissection. (*Fig. 687.*)

9. To make the artificial anus, the abdominal operator makes a stab wound in the left iliac fossa. He then draws the box clamp, which clamps the proximal end of the divided sigmoid, endways through it. (*Fig. 688.*)

10. The abdominal operator now closes with sutures the gap in the pelvic peritoneum and the wound of the abdominal wall.

11. In the meantime the perineal operator, swabbing out the wound with the three-dye mixture described on p. 986, and inserting a sheet of sterilized cellophane into the wound and packing the wound with gauze on this tissue (cellophane is better than rubber or oiled silk), has attended to the perineal wound.

Carried out in this manner the time of the operation is much shortened.

This method, too, by avoiding much abdominal dissection, lessening movement during the operation, and avoiding the difficulty of incarcerating an air-filled rectum under a sutured peritoneum, reduces the shock and therefore the mortality-rate of this operation.

CHAPTER XCIII

GROSS ISCHIORECTAL SEPSIS. INJURIES TO THE
RECTUM

ISCHIORECTAL SEPSIS

IN some debilitated patients, neglected ischio-rectal suppuration spreads widely in the soft tissues and burrows into the rectum and eventually presents to the surgeon an almost insuperable surgical problem, not only to obtain healing of the cavities left after the opening of the abscesses, but also to close the resulting fistulæ in the presence of the functioning bowel and the obstructing sphincter.

A somewhat similar problem exists in connexion with the vesico-rectal fistulæ sometimes left after prostatectomy. The following case-history exemplifies the principles involved and the method adopted in dealing with such problems.

A man, aged 58, became ill with a bilateral ischio-rectal suppuration and cellulitis. When the abscesses were incised the amount of pus was very great, the tissue destruction extensive, the openings into the rectum multiple, and the cavities left round the rectum, after an adequate opening, enormous. The anus was surrounded, as it were, by a moat.

For eight months there was no repair reaction in the large wound, which remained wide open *in statu quo*.

The patient was bedridden and a very sick man ; and it was thought that it was his general condition and resulting loss of tissue resistance which prevented the wound from healing.

At this stage (coming under my care) the distal colon was completely excluded and prepared as described in Chapter LXXXVII.

In a fortnight the appearance of the wound had completely changed : it had become clean and healthy-looking and had begun to heal. It was not, therefore, in this case, the enfeeblement of the patient's tissues that caused the lack of healing for eight months, but the effect on the wound of the septic fæcal stream, which inhibited repair.

In a short time the wound had so contracted that its encompassing walls could be dissected away, the openings in the rectum and anal canal closed, and the whole cavity obliterated by buried catgut sutures and the sutured area reticulated with a system of small ' agricultural ' rubber-tube drains.

These drains were left in till most of the tissues were united, then they were slowly taken out, after which the repair of the cavities became complete.

Observation on this case (and on others) has convinced me that most of the 'inoperable' fistulæ in connexion with the rectum can be closed if the distal colon is excluded for a long enough time; that is, if the effect of gross fæcal contamination is eliminated.

INJURIES TO THE RECTUM

Principles Involved when dealing with Rectal Injuries.—

Two concrete instances of injury to the rectum, each involving surgical treatment on different principles, are here described, with a view to showing that the treatment of wounds of the rectum is always an individual problem, the solution of which depends on the circumstances.

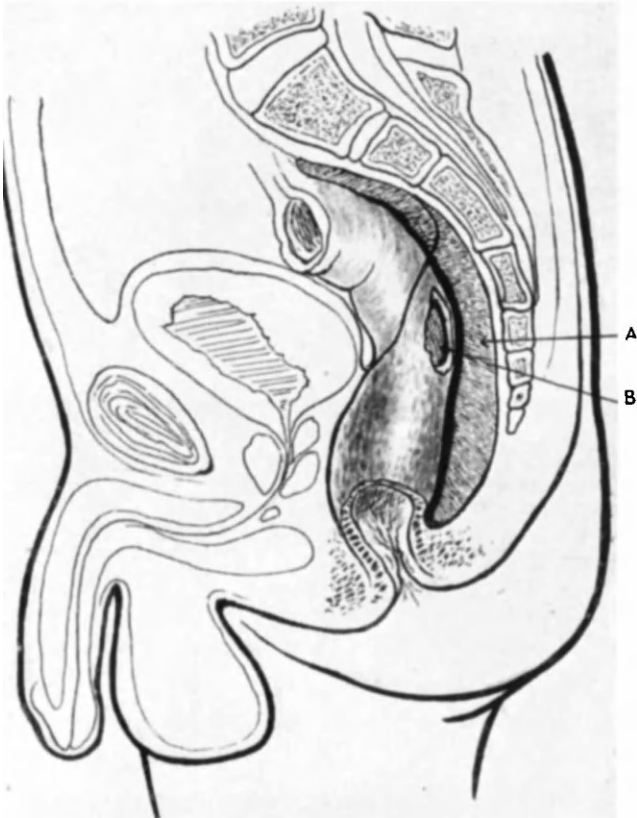


Fig. 689.—Diagram of injury to the rectum by explosive bullet. **A**, Chronic abscess cavity; **B**, Hole in rectum made by bullet.

Explosive Bullet piercing the Ampulla of the Rectum.—

A boy in a stooping position was shot in the left iliac fossa with an explosive bullet. Fæces subsequently issued from the point of entry. X rays showed that the bullet was embedded in the middle of the sacrum.

The patient became very ill, with all the signs of sepsis in the abdominal cavity. After an illness of many weeks' duration he was sent into hospital.

At an operation the coccyx was removed and a large hole the size of a small plum was found in the middle of the posterior wall of the rectum. It was also seen that a large chronic abscess had formed between the rectum and the sacrum, opening on the one hand into the rectum (*Fig. 689*), and on the other through the abdominal fistula. The walls of the rectum were almost one-third of an inch thick and were rigid, and because of this it was of course impossible to suture the large hole in the rectum.

The opening was eventually closed as follows: The rectal wall and anal canal were slit posteriorly throughout their whole length. After the lapse of a period of time to allow a regression of the florid inflammatory element in the rectal wall, a beginning was made to unite the cut edges. The sliced rectum and subsequently the divided anal canal were closed under local anæsthesia in sections of one inch at a time, until finally the region of the sphincter was reached, when this muscle was allowed to unite by second intention. The patient eventually became quite continent and has occupied a responsible position for many years.

In the above case, to effect closure in the functioning rectum took a long time—a considerable disadvantage. In the light of subsequent experience, the more correct surgical treatment would have been to disconnect the distal colon at the transverse colon, that is, exclude it as described on p. 948, clear this excluded viscus of fæces, then close the opening in one or two stages, and finally reconnect the segments of colon when the rectal wound had completely healed.

This case, however, shows one principle which may be followed when dealing with extensive wounds of the sphinctered rectum with a badly diseased rectal wall.

Perforation of the Rectum into the Peritoneal Cavity.—

A boy, vaulting with a broomstick, accidentally let it go and came buttock downwards on its point, which passed up through his anus, through the upper part of the rectum, and into the peritoneal cavity (*Fig. 690*).

Examination revealed the fact that the rectal cavity was full of coils of small intestine.

Operation: Laparotomy; withdrawal of the coils of small intestine; closure of the wound in the rectal wall; closure of the peritoneal layer by extensive mobilization and imbrication; and finally, the insertion of a finger-sized drainage tube through the abdominal wound to the sutured rent.

The patient recovered from the operation, became well, and his bowels functioned naturally until the ninth day when, unexpectedly, he passed a fully formed motion through and around the drainage tube. Apparently

the rectal-wall wound had completely broken down (so I thought). However, from that day on, no more fæces passed from the wound, the bowels functioned, and all the wounds were healed in four weeks.

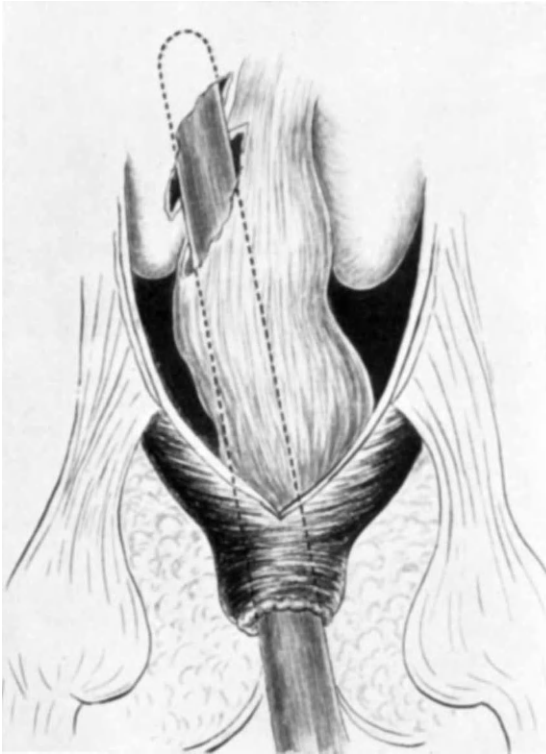

Fig. 690.—Diagram illustrating the way in which injury to the rectum by a penetrating broomstick occurred.

The imbricated peritoneum had saved the situation. Had I drained perineally, as I was tempted to do—drained with gravity, not against it—I am sure a chronic fistula would have formed; but I mistrusted the healing properties of the rectal wall and the perineal tissues, and trusted those of a double peritoneal layer.

Thus this case shows another principle of surgical treatment in the management of wounds in the upper part of the rectum.

INDEX

	PAGE		PAGE
A BAISSEMENT of rectum (<i>Fig.</i> 683)	1009	Abdominal operations, suture material for	358
Abdominal adhesions to anterior wall, general considerations (<i>Figs.</i> 293-296)	392	— — upper, anatomical features in (<i>Fig.</i> 288)	380-385
— — — in upper region operations (<i>Figs.</i> 238, 239)	335	— — — Devine operating frame in (<i>Figs.</i> 223-250)	325
— — — dyspepsia due to	198-200	— — — general principles (<i>Figs.</i> 222-349)	324-349
— — — method of dealing with, in jejunal ulcer operations (<i>Fig.</i> 458)	564	— — — incisions in, general principles <i>re</i> (<i>Figs.</i> 289-291)	386-389
— — — of omentum to anterior abdominal wall	396	— — — posture in	349
— — — surgery of (<i>Figs.</i> 292-301)	390-402	— — — organs adhering to abdominal wall (<i>Figs.</i> 297-299)	397
— — — treatment of particular forms (<i>Figs.</i> 297-301)	396	— — — perforation of (<i>see</i> Perforation of Hollow Organ)	
— — — cavity, absorption of fluids in	382	— — — pain, right-sided, diagnosis of	896
— — — method of exploration of (<i>Fig.</i> 254)	353	— — — pressure in post-operative cardiac failure	770
— — — scissors dissection in (<i>Figs.</i> 251, 252)	351	— — — respiration in post-operative cardiac failure	770
— — — surgical handicraft in (<i>Figs.</i> 251-287)	350-368	— — — surgery, surgeon's equipment (<i>Figs.</i> 220, 221)	317, 323
— — — technique of entering, in jejunal ulcer operations (<i>Fig.</i> 457)	563	— — — viscera, nerve-supply of (<i>Fig.</i> 26)	54, 383
— — — corset for post-operative use (<i>Fig.</i> 441)	547	— — — wall, adhesions to (<i>see</i> Abdominal Adhesions)	
— — — — in vomiting	775	— — — avoidance of soiling of, in ileocectomy	902
— — — — crises in diverticulitis	923	— — — — hydatid of, diagnosis of	895
— — — — regional ileitis	888	— — — — nerves of (<i>Fig.</i> 289)	386
— — — — dissecting scissors (<i>Figs.</i> 251, 252)	351	— — — — postural tone of (<i>Figs.</i> 290, 291)	386
— — — — dissection with diathermy knife	353	— — — — tumours of (<i>Figs.</i> 302, 303)	403-405
— — — — distension, post-operative (<i>see</i> Distension, Post-operative)		— — — — wounds, closure of (<i>Figs.</i> 435-441)	541-547
— — — — emergencies involving upper or lower abdomen	805-828	— — — — — ligatures and sutures for	541
— — — — exploration in intestinal obstruction	825	— — — — — technique (<i>Figs.</i> 435-441)	543
— — — — isolation of gall-bladder	341	— — — — — protection of, in closure of perforation	812
— — — — operation on defunctioned distal colon (<i>Fig.</i> 632)	946	— — — — — tumour in scar of	404
— — — — preparatory to gastro-entrostomy (<i>Figs.</i> 309-312)	435	Abdomino-perineal operation for cancer of rectum	976
— — — — lymphatic fields in surgery	382	— — — and perineal resections of rectum compared	1008
— — — — lymph-glands, examination of, in reflex dyspepsia	411	— — — resection of rectum, technique (<i>Figs.</i> 686-688)	1015-1018
— — — — operations (<i>see also</i> Dyspepsia, Surgical)		Abscess, appendiceal, chronic retrocaecal, diagnosis of	895
— — — — general considerations of patient's risk	373-379	— — — — operative technique	866
— — — — — hæmatemesis after	295	— — — — in appendiceal scar, diagnosis of	896
— — — — — hæmostasis in (<i>Fig.</i> 273)	362	— — — — around caecal carcinoma simulating appendicitis	841
— — — — — instruments and tray for (<i>Fig.</i> 255-266)	355	— — — — formation in diverticulitis, treatment of	933
— — — — — lower, surgery of (<i>Figs.</i> 593-690)	829-1022	— — — — following perforation of hollow organ	813
— — — — — method of handling intestines and stomach (<i>Fig.</i> 253)	352	— — — — in gastric carcinoma	237
— — — — — routine suture technique (<i>Figs.</i> 268-272)	358	— — — — in left iliac fossa in diverticulitis (<i>Fig.</i> 619)	920
		— — — — pelvic, in appendicitis	873
		— — — — perinephric, due to retrocaecal appendicitis	855

	PAGE		PAGE
Abscess, subphrenic	878	Anæsthesia, spinal (<i>see</i> Spinal Anæsthesia)	
— — after splenectomy in ruptured spleen	609	Anæsthetic apparatus for abdominal operations	323
— tropical, of liver	624	Anal canal in conservative perineo-abdominal resection of rectum (<i>Fig.</i> 682)	1002, 1005
Achalasia of cardia (<i>Figs.</i> 4-8)	11, 55	Anaphylactic shock due to aspiration of hydatid cyst	628
— — dysphagia due to, treatment (<i>Fig.</i> 9-12)	19	Anatomical features in surgery of upper abdomen (<i>Fig.</i> 288)	380-385
— — transient	17	Angina pectoris, diagnosis from acute pancreatic necrosis	733
Acholic jaundice, diagnosis of	748	— — gall-bladder symptoms simulating	697
— — — from gall-bladder syndrome	683	Antecolic gastro-entero-anastomosis in partial gastric exclusion (<i>Figs.</i> 452, 453)	557
— — spleen and (<i>Figs.</i> 493, 494)	597	— — method in gastro-entero-anastomosis (<i>Fig.</i> 376)	493, 495
— — splenectomy in	609	Antral gastritis, examination for, in reflex dyspepsia	411
Acid eructations in dyspepsia	25	— — filling defect due to (<i>Fig.</i> 186)	276
Acidic duodenal ulcer	48	Anus (<i>see also</i> Rectum)	
— theory of causation of peptic ulcer (<i>Figs.</i> 58-64)	108	— — disconnecting, incision for (<i>Fig.</i> 631)	946
Acidity of gastric juice in jejunal ulcer formation	178 et seq.	— — reconnection of colonic segments (<i>Figs.</i> 642-645)	955
Adenitis, ileocæcal tuberculous, diagnosis of	895	— — technique and management of (<i>Figs.</i> 633-645)	948-957
Adenomata of sigmoid colon, removal of	961	Aponeurosis, suture of, in abdominal operations (<i>Figs.</i> 437-439)	546
Adhesions, abdominal (<i>see</i> Abdominal Adhesions)		Appendiceal abscess, chronic retro-cæcal, diagnosis of	895
Adrenaline in post-operative shock	766	— — operative technique	866
Adrenals in shock	760	— — dyspepsia, reflex (<i>Figs.</i> 40, 41)	84
Age incidence of gastric carcinoma	209	— — scar, chronic abscess in, diagnosis of	896
Albolene in preparation of catgut suture material	543	Appendicectomy, complications of	878
Albuminuria in heart failure	769	— — fistula formation after	878
Alcoholism, operability and	373	— — in gastro-enterostomy (<i>Figs.</i> 310-312)	436
Alimentary canal, gross dilatations and spasms of (<i>Figs.</i> 25-31)	52-67	— — ileocæcal mesenteric lymphadenitis	885
— — nerve control of	384	— — through internal abdominal ring during operation for inguinal hernia	877
Allis's forceps (<i>Fig.</i> 260)	356	— — small incision	877
<i>Ambæa dysentericæ</i> , liver abscess due to	624	Appendicitic tumour	842
Ampulla of Vater, carcinoma of (<i>Figs.</i> 576, 577)	739	— — diagnosis of	895, 912
— — — diagnosis from gall-stone in common duct	684, 686	Appendicitis, acute	836
— — — dyspepsia of	408	— — — causation of deaths from	836
— — — stone in, duct not obstructed by (<i>Fig.</i> 563)	708	— — — clinical manifestations	837
— — — impacted in (<i>Fig.</i> 544)	679	— — — differential diagnosis	840
Anæmia in diagnosis of abdominal conditions	897	— — — early diagnosis of	837
— hæmatemesis in	295	— — — following colitis	839
— von Jaksch's, spleen and	604	— — — mild types	839
— — splenectomy in	611	— — — operation in (<i>Figs.</i> 597-605)	857
— — pernicious, atrophic gastritis in (<i>Fig.</i> 51)	97	— — — post-operative treatment	868
— — spleen and	600	— — — principles of	858
— — splenic	596	— — — routine technique (<i>Figs.</i> 597-605)	859
— — — bleeding from operation in	294	— — — perforative	846
— — — hepatomegaly in	623	— — — question of immediate operation in	857
— — — splenectomy in	609	— — — termination of	839
Anæmic type of clinical picture in 'silent' gastric carcinoma	232	— — in the aged	879
Anæsthesia in appendicectomy in children	882	— — anatomy of (<i>Figs.</i> 593, 594)	831
— — cholecystectomy	700	— — causation of	833
— — in closure of perforated abdominal organ	811	— — — clinical inferences from	835
— — for gastro-enterostomy	434	— — — chronic	842
— — in intestinal obstruction	825	— — — regional ileitis simulating	888
— — local, (<i>see</i> Local Anæsthesia)		— — — classification of (<i>Figs.</i> 595, 596)	836-856
— — for operations for jejunal ulcer	563	— — — determining line of treatment	857
— — partial gastrectomy (<i>Figs.</i> 336-345)	403-474		
— — pneumonia post-operatively in surgical dyspepsia	786		
— — in production of shock	762		

	PAGE		PAGE
Appendicitis, diagnosis from diverticulitis	921	Bed, disadvantages of prolonged rest in gymnastics	801 802
— effect of causative factor as basis of classification	844	Beneficial abdominal adhesions	390
— in a femoral hernia	856	Bile discharging after cholecystectomy — origin of	722 653
— fulminating	844	— retrojection of, into pancreatic duct, causes of	730
— gangrenous	844	— — — — by stone blocking exit to duodenum (<i>Fig.</i> 546)	681
— inflammation as basis of classification	836	— stasis, cholecystitis due to	658
— left-sided	856	Bile-ducts (<i>see also</i> Gall-bladder)	
— pelvic (<i>see</i> Pelvic Appendicitis)		— accidents to, in cholecystectomy (<i>Figs.</i> 568-575)	718-729
— proliferative (plastic) chronic	842	— common, carcinoma of (<i>Figs.</i> 576, 577)	738
— — — diagnosis of	895, 912	— — — diagnosis from gall-stone	684
— retrocaecal (retroperitoneal)	854	— — — examination of, in cholecystectomy (<i>Fig.</i> 563)	708
— — — cellulitis and	380	— — — gall-stone in, after cholecystectomy	714, 715
— — — operation for (<i>Figs.</i> 610, 611)	875	— — — differential diagnosis (<i>Figs.</i> 543-546)	678-682
— simulating acute cholecystitis	696, 697	— — — hydatid of liver associated with (<i>Fig.</i> 516)	636
— situation as basis of classification (<i>Figs.</i> 595, 596)	846	— — — simulating	633, 634
— subhepatic (<i>Figs.</i> 596, 609)	853, 874	— — — at junction with cystic duct (<i>Fig.</i> 538)	666
— subileal	856	— — — retrojection of bile into pancreas due to	731
— treatment of (<i>Figs.</i> 597-613)	857-884	— — — ileus of	60
— in the young	880	— — — injury to, in cholecystectomy, recognition of	721
Appendicostomy in ulcerative colitis	915	— — — redundancy of, cholecystectomy and (<i>Fig.</i> 568)	718
Appendix, adhesions in vicinity of, dyspepsia due to	199	— — — repair of wounds of (<i>Figs.</i> 572-575)	723
— carcinoid tumours of (<i>Fig.</i> 613)	883	— — — stricture of, after cholecystectomy	714
— development of (<i>Figs.</i> 593, 594)	831	— cystic, gall-stone blocking (<i>Figs.</i> 536, 537)	663
— examination of, in reflex dyspepsia	408	— — — 'taking-up' of, cholecystectomy and (<i>Fig.</i> 569)	718
— normal, intussusception of (<i>Fig.</i> 612)	883	— examination of, in reflex dyspepsia	408
— variations in position of	832	— pancreatic, retrojection of bile into, causes of	730
Aspiration of extravasated visceral contents in perforation	812	— rupture of hydatid into	629
— gastric intestinal contents in gastric resection	453, 625	Bile-pigment gall-stones	659
— liver abscess	625	Bilroth I gastro-entero-anastomosis, illustrative cases (<i>Figs.</i> 409-411)	518
— pneumonia post-operatively in surgical dyspepsia	785	— — — method of making	495
— of stomach in gastric resection (<i>Figs.</i> 329, 330)	453	— — — technique (<i>Figs.</i> 403-411)	514
— — — partial gastrectomy (<i>Fig.</i> 350)	478	Bilroth II gastro-entero-anastomosis, method of making (<i>Fig.</i> 375)	494
— in vomiting due to gastric ileus	777	— — — in partial gastric exclusion (<i>Fig.</i> 451)	554
Atrophic gastritis, gastroscopic appearances (<i>Fig.</i> 214)	310	— — — suture technique (<i>Figs.</i> 394-402)	507
— — — in pernicious anaemia (<i>Fig.</i> 51)	97	— method of partial gastrectomy where gastric musculature is weak (<i>Fig.</i> 335)	462
Atropine in dyskinesia of sphincter of Oddi	715	Binokel, stereoscopic, for viewing radiographs (<i>Fig.</i> 158)	244
— to lessen flow of saliva in gastroscopy	302	'Black' jaundice in gall-bladder syndrome	685, 686
— premedication in gas and oxygen anaesthesia in partial gastrectomy	464	— — — significance of	749
Autotransfusion of blood in rupture of spleen	608	Bladder, ileus of	59
Avertin premedication in gas and oxygen anaesthesia in partial gastrectomy	465	— spasm of (irritable bladder)	65
<i>BACILLUS coli communis</i> in appendicitis	833	— symptoms in diverticulitis (<i>Fig.</i> 621)	927
— <i>melanogenicum</i> in appendicitis	833	Blood, autotransfusion of, in rupture of spleen	608
Bacteriology of appendicitis	833	— in faeces (<i>see</i> Melæna)	
Balfour's antecolic gastro-entero-anastomosis in partial gastric exclusion (<i>Figs.</i> 452, 453)	557	— transfusion in appendicitis in young	822
'Ball-valve' stone in common duct (<i>Fig.</i> 543)	678	— — — hæmatemesis	299
Bard-Parker blade for cholecystectomy (<i>Fig.</i> 562)	707		
Barrel for carrying silk (<i>Fig.</i> 258)	356		
Bartlett's method of preparing catgut suture material	542		

	PAGE		PAGE
Blood transfusion by Neo-athrombit apparatus (<i>Fig.</i> 586)	771	Cancer of pancreas, reflex dyspepsia due to (<i>Fig.</i> 39)	83
— — in post-operative shock, (<i>Fig.</i> 586)	764, 765, 771	— en plaque, radiography in	270
— — splenectomy	620	— of proximal colon (<i>see</i> Colon, Proximal)	
Body-heat, restoration of, in post-operative shock	764	— rectum (<i>see</i> Rectum)	
Bone changes in acholuric jaundice (<i>Figs.</i> 493, 494)	598	— sigmoid colon (<i>see</i> Colon, Sigmoid)	
Box clamp for use in rectosigmoid resection (<i>Figs.</i> 648, 662)	985	— spleen	606
Breathing, abdominal, in post-operative cardiac failure	770	— stomach (<i>see</i> Stomach)	
— centres, stimulation of, in post-operative shock	767	Carcinoid tumours of appendix (<i>Fig.</i> 613)	883
Bromsulphalein test of liver function	674	Carcinomatous degeneration in gastric ulcer (<i>Figs.</i> 79-84)	145
— — — — in cholecystography	375	Cardia, achalasia of (<i>Figs.</i> 4-8)	II, 35
Bronchus, rupture of hydatid into	646	— — dysphagia due to, treatment (<i>Figs.</i> 9-12)	19
Brood capsules in hydatidosis	627	— — transient	17
Bullet wound of rectum (<i>Fig.</i> 689)	1021	Cardiac (<i>see also</i> Heart)	
		— cases, shock after upper abdominal operations in	768
CACHEXIA in diagnosis of abdominal conditions	897	— stimulants	770
Cæcal symptoms in cancer of distal colon	907	Cardiazol as cardiac stimulant	378, 770
Cæcostomy in operations on functioning distal colon	942	Cardiospasm (<i>Figs.</i> 4-8)	II, 55
Cæcum, carcinoma of, abscess around, simulating appendicitis	841	— dysphagia due to, treatment (<i>Figs.</i> 9-12)	19
— deflation of, in pelvic appendicec-tomy	870	— — — — —	17
— 'painful'	896	Castle's 'intrinsic factor', gastrectomy and	460
— prolapsed into pelvis in appendicitis	873	Catarrhal jaundice	752
Caffeine as cardiac stimulant	770	Catgut sutures in abdominal surgery	542
— in post-operative shock	767	— — causing wound sepsis in surgical dyspepsia	799
Calcified hydatid of liver (<i>Figs.</i> 531-534)	650	Cellulitis of colonic wall in diverticu-litis	919
Calculus in common duct (<i>see</i> Bile-duct)		— retroperitoneal	380
— at pelvo-ureteric junction, removal of (<i>Figs.</i> 304, 305)	409	— — due to retrocæcal appendicitis	855
— ureteric, simulating appendicitis	840	— of sigmoid in diverticulitis, intestinal obstruction due to (<i>Fig.</i> 620)	925
Cancer of ampulla of Vater, diagnosis from gall-stone in common duct	684, 686	Chemical shock	761, 762
— cæcum, abscess around, simulating appendicitis	841	Cholæmia, acute, hæmatemesis in	296
— common bile-duct (<i>Figs.</i> 576, 577)	738	Cholangiography after operation in doubtful tumour of pancreas (<i>Fig.</i> 584)	756
— — — — diagnosis from gall-stone	684	— in obscure jaundice (<i>Fig.</i> 583)	754
— descending colon or splenic flexure, resection of	974	Cholangitis after cholecystectomy	714
— developing on diverticulitis	931	— diagnosis from portal pyæmia	698
— — jejunal ulcer	190	Cholecystectomy (<i>Figs.</i> 556-567)	699-717
— differential diagnosis from penetrating gastric ulcers (<i>Figs.</i> 75-78)	134	— accidents to bile-ducts in (<i>Figs.</i> 568-575)	718-729
— of distal colon, diagnosis of	905	— — — — pathological conditions predisposing to (<i>Figs.</i> 568, 569)	718
— — — — simulating appendicitis	840	— — common duct in, recognition and diagnosis of	721
— — — — unusual onsets and syndromes	906	— in acute cholecystitis, when to perform	715
— duodenum, dyspepsia of (<i>Fig.</i> 132)	209	— after-treatment	713
— hypopharyngeal, dysphagia due to (<i>Fig.</i> 3)	4	— anæsthesia in	700
— intestinal obstruction due to	823, 827	— approach from cystic duct (<i>Figs.</i> 559-566)	705
— of liver, enlargement due to	624	— — — — fundal end (<i>Fig.</i> 567)	711
— nausea and vomiting due to	68	— dissection of the gall-bladder (<i>Figs.</i> 559-567)	705
— of œsophagus (<i>see</i> Esophagus)		— drainage	712
— pancreas (<i>Fig.</i> 578)	740	— essential principles	699
— — diagnosis from chronic pancreatitis	755	— incision for (<i>Figs.</i> 557, 558)	702
— — head of, diagnosis from gall-stones	686	— isolation of gall-bladder	703
		— multiple stones in common duct after	681
		— pains following	713
		— pathological investigation	704

	PAGE		PAGE
Cholecystectomy, position of patient (<i>Fig.</i> 556)	701	CO ₂ inhalations in post-operative in- testinal distension	780
— repair of wounds of common duct after (<i>Figs.</i> 572-575)	723	— — — shock	767
— reflex dyspepsia after (<i>Figs.</i> 36, 37)	78	Coccyx, removal of, in perineo-abdomi- nal resection of rectum (<i>Fig.</i> 666)	992
— through Kocher incision, chole- dochotomy after	728	Cod-liver oil instillations in preparation of a defunctioned rectum	988
Cholecystgastrostomy (<i>Figs.</i> 579)	743	— — per appendicostomy in ulcerative colitis	915
— in cancer of common duct	740	— — treatment of chronic gastric ulcer	422
— — head of pancreas	741	Codeine phosphate to depress laryngeal reflexes in gastroscopy	302
Cholecystitis, acute, appendicitis, simulating	696, 697	'Cold' pneumonia post-operatively in surgical dyspepsia	786
— — diagnosis from suppurating central hydatid of liver (<i>Fig.</i> 555)	694	Colic artery in collateral circulation of anal canal in resection of rectum (<i>Fig.</i> 682)	1006
— — due to impacted stone	665	— — partial gastrectomy for carci- noma (<i>Fig.</i> 332)	457
— — when to operate	715	Colitis, acute, appendicitis following	839
— after removal of calcified hydatid	652	— — simulating appendicitis	841
— associated with chronic pancreatic disease	736	— — mucous, in diverticulitis	919
— causation of	657	— — ulcerative, diagnosis of	897
— chronic, due to gall-stones	663	— — — from cancer of distal colon	909
— dyspepsia due to	692	— — regional ileitis simulating	888
— non-lithogenous	661	— — surgical treatment	915
Cholecystogram, negative, in reflex dyspepsia	406, 407, 408	Collapse (<i>see</i> Shock)	
Cholecystography (<i>Figs.</i> 540-542) 670-677		Colon, descending, cancer of, resection of	974
— absence of shadow	673	— distal, cancer of, diagnosis of	905
— gall-stone shadows (<i>Figs.</i> 540-542)	675	— — simulating appendicitis	840
— principles underlying	670	— — unusual onsets and syn- dromes	606
— significance of contour of shadow in — — emptying function of gall- bladder in	676	— — defunctioned, operation on (<i>Figs.</i> 631, 632)	943
— — position of shadow	675	— — — technique of (<i>Figs.</i> 646- 657)	958-975
— — technique of	671	— — — pre-operative preparation of (<i>Fig.</i> 641)	954
— value of evidence obtained by	672	— — — functioning, operations on	942
Cholecystostomy, fistula discharging pus after	727	— — — innocent conditions, of, dia- gnosis of	909
— recurrent gall-bladder symptoms after	728	— — — surgical treatment (<i>Fig.</i> 618)	914-917
Choledochoduodenal sphincter, spasm of, after cholecystectomy	714, 715	— — papilloma of, surgical treatment	914
Choledochoduodenostomy (<i>Figs.</i> 581, 582)	746	— — principles of operations on (<i>Figs.</i> 631, 632)	942-947
Choledochotomy after cholecystectomy through Kocher incision	728	— — and upper part of rectum, dia- gnosis of diseases of (<i>Fig.</i> 617)	905-913
Cholelithiasis (<i>see</i> Gall-stones)		— ileus of	59
Choleperitoneum after cholecystectomy (<i>Fig.</i> 569)	720	— obstruction of	819, 827
Cholesterol gall-stones	659	— operative approach to	389
— — cholecystitis due to	658	— proximal, cancer of, clinical picture	891
Circulatory disturbance, acute, after upper abdominal operations (<i>Figs.</i> 585, 586)	758	— — — diagnosis of	889
— failure, diagnosis between peri- pheral and cardiac failure	769	— — — ileo-transverse-colostomy in — — — operation in very ill cases (<i>Figs.</i> 615, 616)	903
— insufficiency, abdominal operability and	376	— — — pathological types of	889
— obstruction in intestinal obstruction	820	— — — principles of operation (<i>Figs.</i> 615, 616)	898-904
— origin of hepatomegaly	623	— — — standard operation in	901
Cirrhosis of liver, hæmatemesis in	295	— — — unusual onsets and syndromes	891
— — hepatomegaly in	623	— — — development of (<i>Figs.</i> 593, 594)	831
— — jaundice due to	752	— — — diagnosis of diseases of	889-897
— — portal, spleen and	604	— — — innocent conditions	894
Clamps, box, for use in rectosigmoid resection (<i>Figs.</i> 648, 662) 962, 985		— — — papilloma of	890
— for closure of duodenal stump in partial gastrectomy (<i>Figs.</i> 365- 372)	489	— — sigmoid, adenoma of, removal of	961
— splenic pedicle (<i>Fig.</i> 508)	619	— — cancer of, diagnosis from diver- ticular tumour	929
Clauden in hæmatemesis	299		

	PAGE		PAGE
Colon, sigmoid, cancer of, operation		Detrusor muscle movements, rectal	
— on defunctioned colon in	944, 945	surgery and	981
— — — operative approach to	989	Devine operating frame (<i>Figs. 222-224</i>)	325
— — — pelvic appendicitis simulating	851	— — — advantages of use of (<i>Figs. 249, 250</i>)	346
— — — penetrating gastric ulcer		— — — isolation of gall-bladder	
diagnosed as (<i>Fig. 78</i>)	139	(<i>Figs. 242-250</i>)	341
— — — simulating rectal cancer	908	— — — in perineo-abdominal resection of rectum	992 et seq.
— — cellulitis of, in diverticulitis, intestinal obstruction due to		— — — rectal surgery (<i>Fig. 660</i>)	983
(<i>Fig. 620</i>)	925	— — — upper abdominal operations	
— — improved method of closing cut end of (<i>Fig. 685</i>)	1013	(<i>Figs. 229-250</i>)	329
— — spasm of (<i>Fig. 31</i>)	64, 66	— splenic pedicle clamp (<i>Fig. 508</i>)	619
— — volvulus of	828	— syringe for evipan anaesthesia (<i>Fig. 336</i>)	466
— spasm of	64, 66	Dexterity in armamentarium of abdominal surgeon	318
— transverse, in relation to jejunal loop in gastro-entero anastomosis		Dextrose (<i>see</i> Glucose)	
(<i>Figs. 376-382</i>)	495	Diabetes, abdominal operations and	378
Colonic affections, reflex dyspepsia due to	88	Diaphragmatic hernia, strangulated	582
— exclusion operation in ulcerative colitis (<i>Fig. 618</i>)	916	— — treatment (<i>Figs. 471-475</i>)	578
— wall, cellulitis of, in diverticulitis	919	— — varieties, symptoms and signs	578
Common bile-duct (<i>see</i> Bile-ducts)		— rupture of hydatid of liver (<i>Figs. 524-526</i>)	642
Congenital diaphragmatic hernia	578	Diarrhoea in diagnosis of abdominal conditions	897
— duodenal diverticulum	173	— diverticulitis	919
Constipation in gastric carcinoma	237	Diastase examination in acute pancreatic necrosis	732
Coramine as cardiac stimulant	770	Diathermy knife in abdominal dissections	
— in post-operative shock	767	— medical, in post-operative treatment of acute appendicitis	868
Coronary artery sclerosis, operability and	373	— — — perforation	814
Corset for use after abdominal operations (<i>Fig. 441</i>)	547	— — — spleen and	595
— — in post-operative vomiting	775	Digestive system, spleen and	595
Costal incision in approach to upper abdominal organs	388	Digilamid as cardiac stimulant	377, 378
— — for partial gastrectomy for ulcer on lesser curvature		Digitalin as cardiac stimulant	770
(<i>Figs. 414, 419</i>)	524	Digitalis in pre-operative circulatory insufficiency	378
Crocodile, alimentary canal of (<i>Fig. 29</i>)	60	Dilatation of alimentary canal due to hypertrophy of sphincters and presphincteric muscle-fibres	61
Crohn's disease (<i>Fig. 614</i>)	886	— — — pathological (<i>Figs. 27-30</i>)	55
Croupous pneumonia post-operatively in surgical dyspepsia	786	— of oesophagus in cardiospasm (<i>Figs. 9-12</i>)	19
Cyclopropane anaesthesia in partial gastrectomy	465	— pyloric sphincter in reflex dyspepsia	413
Cyst, hydatid (<i>see</i> Hydatid)		Director, grooved, Kirschner's (<i>Fig. 266</i>)	357
— of liver, solitary	625	Dissecting forceps, long (<i>Fig. 262</i>)	356
— spleen	604	— scissors, abdominal (<i>Figs. 251, 252</i>)	351
Cystic disease of pancreas	737	Dissector and ligature carrier, McCormick (<i>Fig. 257</i>)	355
— duct, examination of, in reflex dyspepsia	407	— McCormick, for cholecystectomy (<i>Fig. 561B</i>)	707
— — gall-stones blocking (<i>Figs. 536, 537</i>)	663	Distal colon (<i>see</i> Colon, Distal)	
— — at junction with common duct (<i>Fig. 538</i>)	666	Distension in acute pancreatic necrosis	732
Cystitis-like syndrome in diverticulitis (<i>Fig. 621</i>)	927	— post-operative, causation	779
DECICAIN as surface analgesic in gastroscopy	303	— — prophylaxis	781
Defaecation, abdominal crisis following, in diverticulitis	923	— — refractory (<i>Fig. 588</i>)	789
— frequency of, in cancer of distal colon	908	— — in surgical dyspepsia	779
— — in ulcerative colitis	909	— — treatment	781
Deschamps' ligature needle (<i>Fig. 265</i>)	357	Diverticular tumour	918
Desmoid tumour over caecum, diagnosis of	896	— — causing lump in left iliac fossa	912
— — in scar of abdominal wound	404	— — diagnosis from cancer of sigmoid colon	929
		— — intestinal obstruction due to	924, 926
		— — pelvic appendicitis simulating	852
		Diverticulitis, carcinoma developing on	931
		— of distal colon, obstruction in	910
		— and diverticulosis, diagnosis of (<i>Figs. 619-621</i>)	918-931

	PAGE		PAGE
Diverticulitis and diverticulosis, treatment of (<i>Figs. 622-630</i>)	932-941	Duodenal ulcer, gastric ulcer co-	
— management of uncomplicated cases	933	existing with	166
— — various complications	933	— gastro-enterostomy for	426
— simulating appendicitis	841	— partial gastrectomy for, principles	457
— syndromes of	919	— penetrating pancreas (<i>Figs. 91-94</i>)	161
Diverticulosis and diverticulitis, diagnosis of (<i>Figs. 619-621</i>)	918-931	— on posterior wall, partial gastrectomy and duodenectomy in (<i>Figs. 412, 413</i>)	521
— — treatment of (<i>Figs. 622-630</i>)	932-941	— principles of surgical treatment	416
Diverticulum, duodenal, dyspepsia of (<i>Figs. 102-105</i>)	173-175	— syndrome, cholecystitis simulating	694
— — or jejunal in reflex dyspepsia	412	— uncomplicated, dyspepsia of (<i>Fig. 90</i>)	159
— jejunal, dyspepsia of (<i>Fig. 117</i>)	193	Duodenal-ulcer-like dyspepsia in gastric carcinoma	218
— Meckel's, intestinal obstruction due to	823	— reflex gall-bladder dyspepsia (<i>Figs. 33-35</i>)	78
— — simulating appendicitis	840	Duodenectomy in duodenal ulcer	419, 423
— of œsophagus, upper part of, dysphagia due to	6	— and partial gastrectomy in ulcer of posterior duodenal wall (<i>Figs. 412, 413</i>)	521
— stomach giving rise to abdominal tumour (<i>Figs. 130, 131</i>)	207	Duodenitis (<i>Figs. 50, 85-87</i>)	101, 153-155
Donati's instrument for closure of duodenal stump in partial gastrectomy (<i>Figs. 365-368</i>)	489	— acute (<i>Fig. 87</i>)	154
Drainage in appendicectomy	859	— bleeding from, operation in	294
— cholecystectomy	712	— examination for, in reflex dyspepsia	411
— of gall-bladder in cholecyst-gastrostomy	756	— secondary to penetrating ulcer	98
— in ileocelectomy	903	— symptoms (<i>Figs. 85, 86</i>)	153
— pelvic appendicectomy	874	— X-ray appearance of (<i>Fig. 56</i>)	101
— perforation of hollow organ	813	— — demonstration of deformity of duodenal cap (<i>Fig. 172</i>)	263
— rectal wounds penetrating peritoneum	1021, 1022	Duodenojejunal flexure in retrocolic method in gastro-entero-anastomosis (<i>Figs. 377-382</i>)	497
— rectosigmoid resection with sutured anastomosis	966	Duodenum, anastomosis of common duct to (<i>Figs. 573, 574</i>)	724
— — — telescopic anastomosis	968	— carcinoma of, dyspepsia of (<i>Fig. 132</i>)	209
— — retrocæcal appendicitis (<i>Fig. 611</i>)	877	— dislocation of, in cholecystectomy (<i>Figs. 564, 565</i>)	709
Dukes's tests for urine in faeces and faeces in urine	928	— division and closure of, in partial gastrectomy (<i>Figs. 358-373</i>)	485
'Dumping stomach'	428	— exploration of, in gastro-enterostomy (<i>Fig. 309</i>)	435
Duodenal bleeding, partial gastric exclusion in	560	— ileus of, in reflex dyspepsia	412
— cap, deformities of, demonstrated radiographically	171	— mobilization of, preliminary to gastric resection (<i>Figs. 327, 328</i>)	451
— disease, negative cholecystogram and	673	— in partial gastrectomy	478
— diverticulum, dyspepsia of (<i>Figs. 102-105</i>)	173-175	— spasm of	66
— — in reflex dyspepsia	412	Dynamic ileus	817
— infection, cholecystitis due to	658	Dyspepsia of acute duodenal ulcer (<i>Figs. 88, 89</i>)	156-158
— retraction in exposure of gall-bladder (<i>Figs. 244, 245</i>)	341	— — gastric ulcer (<i>Fig. 65</i>)	118-122
— stasis due to carcinoma of ampulla of Vater (<i>Fig. 576</i>)	739	— aetiological classification	72-73
— stenosis complicating ulcer (<i>Figs. 95, 96</i>)	165	— benign and other tumours of stomach (<i>Figs. 122-131</i>)	201-208
— — X-ray diagnosis (<i>Fig. 196</i>)	282	— in cancer of distal colon	907
— ulcer (<i>see also</i> Peptic Ulcer)		— — duodenum and stomach (<i>Figs. 132-156</i>)	209-241
— — acute, dyspepsia of (<i>Figs. 88, 89</i>)	156-158	— of chronic duodenal ulcer (<i>Figs. 90-101</i>)	159-172
— — — hæmatemesis in	296	— — gastric ulcer (<i>Figs. 66-73</i>)	123-131
— — chronic, dyspepsia of (<i>Figs. 90-101</i>)	159-172	— chronic gastritis as cause of (<i>Figs. 43-55</i>)	90
— — — partial gastric exclusion in	558	— circulatory disturbance after operations for (<i>Figs. 585, 586</i>)	758
— — — radiological view of surgery of	288	— clinical deductions	43
— — — radio-surgical diagnosis (<i>Figs. 170-172</i>)	261	— — diagnosis (<i>Figs. 1-156</i>)	3-241
— — — varieties of (<i>Fig. 90</i>)	159	— of complicated gastric ulcer (<i>Figs. 74-87</i>)	132-152
— — complicated (<i>Figs. 91-96</i>)	161		

	PAGE		PAGE
Dyspepsia, consultative, radiographic, and gastroscopic diagnosis (<i>Figs. 157-219</i>)	242-314	Dyspepsia, renal	86
— distinction between organic and inorganic gastric disease	241	— surgery of (<i>Figs. 220-592</i>)	315-803
— due to abdominal adhesions	198-200	— symptoms of (<i>Fig. 13</i>)	24-27
— — tuberculous mesenteric lymphadenitis (<i>Fig. 42</i>)	87	— vitality	72
— of duodenal diverticulum (<i>Figs. 102-105</i>)	173-175	— wound sepsis in	799
— dysphagic (<i>Figs. 4-12</i>)	8-23	Dysphagia due to cardiospasm (<i>Figs. 4-8</i>)	11
— erroneously attributed to post-operative adhesions	199	— — hypopharyngeal malignancy (<i>Fig. 3</i>)	4
— functional	44, 45, 72, 73, 412	— — œsophagitis	18
— — carcinomatous dyspepsia imposed on (<i>Fig. 141</i>)	224	— in lower œsophagus (<i>Figs. 4-12</i>)	8
— — radio-surgical diagnosis	252	— middle œsophagus	7
— in gall-bladder syndrome (<i>Figs. 550-554</i>)	690	— treatment of (<i>Figs. 9-12</i>)	19
— of gall-stones	662	— in upper œsophagus (<i>Figs. 1-3</i>)	3-7
— gastro-colic fistula (<i>Fig. 116</i>)	188	— with Plummer-Vinson syndrome	19
— incidence on filling or emptying of stomach (<i>Figs. 23, 24</i>)	45-51	Dysphagic carcinomatous dyspepsia (<i>Fig. 149</i>)	231
— of jejunal diverticulum and obstruction (<i>Figs. 117-121</i>)	193-197	— dyspepsia (<i>Figs. 4-12</i>)	8-23
— — ulcer (<i>Figs. 106-116</i>)	176-192	EINHORN tube for aspiration and feeding in vomiting of gastric ileus (<i>Fig. 587</i>)	777, 783
— mechanism of causation of (<i>Figs. 14-22</i>)	28-44	Emptying time after gastro-enterostomy (<i>Fig. 306</i>)	427
— medical and surgical, definitions	43	Encapsulating peritonitis, adhesions due to (<i>Figs. 292, 301</i>)	390, 402
— — forms of distinctions between	70	Endogenous daughter cysts in hydatid disease	627
— of neuromuscular disease of stomach	412	Endometrioma causing intestinal obstruction (<i>Fig. 617</i>)	911
— painful	43	— of umbilicus	405
— — with deep tender spot, radio-surgical diagnosis (<i>Figs. 165-173</i>)	254-265	Enema, abdominal crisis following, in diverticulitis	923
— — without deep tender spot, radio-surgical diagnosis (<i>Figs. 174-202</i>)	266-287	— to evacuate blood in hæmatemesis and melæna	300
— painless	43	<i>Entamoeba histolytica</i> , liver abscess due to	624
— — radio-surgical diagnosis (<i>Figs. 160-164</i>)	248	Enterectomy and partial gastrectomy in jejunal ulcer (<i>Figs. 459-461</i>)	192, 566, 189
— peritonitis following operation for	801	Enterocolic fistula	566
— post-operative complications, early period (<i>Figs. 585-587</i>)	758-788	Enterostomy in post-operative distension due to mechanical obstruction (<i>Figs. 589-592</i>)	794
— — — late period	799-802	Enterotome for reconnection of colonic segments in disconnecting anus (<i>Figs. 642-644</i>)	955
— — — middle period (<i>Figs. 588-592</i>)	789-798	Epigastric hernia	404
— — — remote	803	— hypersensitivity in dyspepsia	25
— — distension in (<i>Fig. 587</i>)	779-784	— pain in gall-bladder syndrome, diagnosis from pelvic appendicitis (<i>Fig. 547</i>)	686
— — mechanical obstruction (<i>Figs. 589-592</i>)	794	— — left, in gall-stone, diagnosis from angina	697
— — pain and vomiting in	774-778	— reflex rigidity and tenderness in dyspepsia (<i>Fig. 13</i>)	25
— — paralytic ileus in	792	— rigidity in gastric carcinoma	238
— — pulmonary complications	785-788	Epithelioma of pyriform fossa, dysphagia due to (<i>Fig. 3</i>)	5
— prolapse of viscera after operation	800	— — valleculla, dysphagia due to	5
— radio-clinical classification	246	Erethric phase of shock	761
— radiological view of surgery of (<i>Fig. 203</i>)	288-290	Eruption in dyspepsia	25
— recognition of a pattern of	44	Erythrocythæmia, spleen and (<i>Fig. 495</i>)	602
— reflex (<i>Figs. 32-42</i>)	74-89	Ether anaesthesia in cholecystectomy	701
— — appendiceal (<i>Figs. 40, 41</i>)	84	— — contra-indicated in intestinal obstruction	825
— — due to carcinoma of pancreas (<i>Fig. 39</i>)	83	— — for jejunal ulcer operations	563
— — — colonic affections	88	— — warm vapour, in partial gastrectomy	463
— — of gall-bladder (<i>Figs. 32-38</i>)	76		
— — surgical treatment of (<i>Figs. 304, 305</i>)	406-414		
— — X rays in diagnosis of (<i>Fig. 173</i>)	263		
— refractory post-operative distension in (<i>Fig. 588</i>)	789		

	PAGE		PAGE
Ethyl chloride contra-indicated in ether anaesthesia for partial gastrectomy	464	GALL-BLADDER, adhesions in neighbourhood of, dyspepsia due to	198
Eukodal in minimization of post-operative shock	762	— bed, toilet of, in cholecystectomy (<i>Fig. 566</i>)	710
Evipan anaesthesia in partial gastrectomy (<i>Fig. 336</i>)	465	— and bile-ducts, diseases of, general considerations (<i>Figs. 535-539</i>)	653-669
Evolution of animal stomach (<i>Fig. 25</i>)	52	— — physiology and anatomy	653
FÆCAL fistula after incision of peridiverticular abscess (<i>Fig. 619</i>)	920	— dilatation with jaundice, significance of	750
— lumps causing tumour in left iliac fossa	913	— disease, causes of	660
Fæces, blood in, coming from colon, diagnosis	897	— — epigastric pain of (<i>Fig. 547</i>)	686
— — in papillomata of colon and rectum	909	— — hepatic insufficiency and	375
— urine in, test for	928	— — hypochondriac pain and tenderness in (<i>Figs. 548, 549</i>)	687
Fæcoliths, search for, in appendicectomy	867	— — jaundice in	683
Fallopian tubes, inflammation of, causing lump in left iliac fossa	913	— drainage of, in cholecystgastrostomy	756
Femoral hernia, appendicitis in	856	— dyspepsia (<i>Figs. 550-554</i>)	690
Fibrosarcoma of stomach (<i>Figs. 122, 123, 126</i>)	204	— — reflex (<i>Figs. 32-38</i>)	76
— — X-ray diagnosis (<i>Figs. 199, 200</i>)	286, 287	— emptying function of, significance in cholecystography	675
Filling defects in radiographs in carcinoma of stomach	169	— examination in reflex dyspepsia	406
— — of prepyloric area (<i>Figs. 178-194</i>)	270	— fibrous contracted calculous, cholecystectomy and	721
Fistula(e) discharging pus after cholecystostomy	727	— functions of	653
— entero-colic	189	— hydatid of liver in vicinity of (<i>Figs. 522, 523</i>)	640
— faecal, following incision of peridiverticular abscess (<i>Fig. 619</i>)	920	— ileus of	60
— formation after appendicectomy	878	— infection (<i>see</i> Cholecystitis)	
— gastro-colic, dyspepsia of (<i>Fig. 116</i>)	188	— isolation of, Devine operating frame in (<i>Figs. 242-250</i>)	341
— ischio-rectal and prostatic, treatment of	1019	— lymphatic connexions of	655
— vesicosigmoid, formation in diverticulitis	928	— mucocele of (<i>Fig. 537</i>)	664
— — surgical treatment of (<i>Figs. 629, 630</i>)	940	— nerve-supply and sphincters of (<i>Fig. 535</i>)	655
Flatulence in dyspepsia	25	— obscure conditions of	668
Flatulent dyspepsia due to gall-stones	690	— operative approach to	388
— painless reflex gall-bladder dyspepsia	77	— situation of	657
Fluids, absorption of, in abdominal cavity	382	— 'strawberry' (<i>Fig. 536</i>)	661
— in conservative treatment of acute pancreatic necrosis	735	— syndromes, differential diagnosis (<i>Figs. 547-555</i>)	683-698
— replacement in appendicitis in young	881, 882	— tumour, diagnosis of	896
Forceps, Allis's (<i>Fig. 260</i>)	356	— — prepyloric filling defect due to (<i>Fig. 194</i>)	280
— intestinal (<i>Fig. 263</i>)	357	Gall-stones associated with chronic pancreatic disease	736
— Lieferstrom's (<i>Fig. 256</i>)	355	— blocking cystic duct (<i>Figs. 536, 537</i>)	663
— long dissecting (<i>Fig. 262</i>)	356	— cholecystitis due to	658
— for picking up needles (<i>Fig. 259</i>)	356	— in common bile-duct, differential diagnosis (<i>Figs. 543-546</i>)	678-682
Fossa pyriformis, epithelioma of, dysphagia due to (<i>Fig. 3</i>)	5	— diagnosis from acute pancreatic necrosis	733
Friedrich's clamp for closure of duodenal stump in partial gastrectomy (<i>Figs. 370, 371</i>)	491	— formation of	658
Fullness and discomfort in dyspepsia	24	— in gall-bladder	662
Fulminating appendicitis	844	— hydatid of liver simulating	633, 635
Functional dyspepsia	44, 45, 72, 73, 412	— of inflammatory origin	660
— — carcinomatous dyspepsia imposed on (<i>Fig. 141</i>)	224	— intestinal obstruction due to	823, 827
— — radio-surgical diagnosis	252	— intra-hepatic (<i>Fig. 539</i>)	668
		— at junction of cystic and common bile-ducts (<i>Fig. 538</i>)	666
		— of non-inflammatory origin	659
		— reflex dyspepsia in (<i>Figs. 32-37</i>)	76
		— shadows in cholecystograms (<i>Figs. 540-542</i>)	675
		Gangrene of rectal stump in conservative resection of rectum	1004
		Gangrenous appendicitis	844
		Gas and oxygen anaesthesia in cholecystectomy	701
		— — — for partial gastrectomy	464
		— — — in minimization of post-operative shock	762

	PAGE		PAGE
'Gastral systems' (<i>Figs.</i> 61, 62)	111	Gastric ulcer becoming malignant, radio-surgical diagnosis	281
Gastroectomy, partial, anaesthesia for (<i>Figs.</i> 336-345)	463-474	— — carcinomatous degeneration (<i>Figs.</i> 79-84)	145
— — in carcinoma of stomach, principles (<i>Figs.</i> 331-333)	455	— — characteristics in various sites (<i>Figs.</i> 70-73)	127
— — disposition of omentum	520	— — chronic carcinomatous, dyspepsia of (<i>Figs.</i> 142, 143)	225
— — in duodenal ulcer	419	— — — — supervening on (<i>Fig.</i> 144)	227
— — — — jejunal ulcer following (<i>Fig.</i> 108)	176, 184	— — — — X-ray diagnosis	252
— — — — principles	457	— — — — clinical features (<i>Figs.</i> 66-69)	123
— — and duodenectomy in ulcer of posterior duodenal wall (<i>Figs.</i> 412, 413)	521	— — — — dyspepsia of (<i>Figs.</i> 66-73)	123-131
— — as emergency operation in hæmatemesis	297	— — — — of fundus (<i>Fig.</i> 73)	130
— — and enterectomy in jejunal ulcer (<i>Fig.</i> 459-461)	192, 566	— — — — on lesser curvature (<i>Fig.</i> 70)	127
— — in gastric ulcer, principles	461	— — — — — — partial gastroectomy in (<i>Figs.</i> 414-426)	524
— — for jejunal ulcer, principles (<i>Fig.</i> 334)	461	— — — — — — resection and gastro-enterostomy in (<i>Figs.</i> 427-429)	532
— — making the gastro-entero-anastomosis (<i>Figs.</i> 374-411)	493-520	— — — — — — X-ray appearance (<i>Figs.</i> 160-164)	250
— — in myoma of fundus (<i>Figs.</i> 433, 434)	539	— — — — radiological view of surgery of	288
— — peptic ulcer, comments on	423	— — — — radio-surgical diagnosis (<i>Figs.</i> 165-169)	254
— — perforated peptic ulcer	813	— — — — complicated, dyspepsia of (<i>Figs.</i> 74-87)	132-152
— — steps of operation (<i>Figs.</i> 346-373)	475-492	— — — — complications of (<i>Figs.</i> 74-87)	132
— — technique (<i>Figs.</i> 336-434)	463-540	— — — — diagnosis from carcinoma	214
— — — — in different types of ulcer and in myoma of fundus (<i>Figs.</i> 331-335, 412-434)	455, 521-540	— — — — gastro-enterostomy for	426
— — in ulcer on lesser curvature (<i>Figs.</i> 414-431)	524	— — — — gastroscopic appearances (<i>Figs.</i> 217, 218)	312
— — — — posterior wall penetrating pancreas (<i>Fig.</i> 432)	538	— — — — hour-glass contraction complicating	145
— — — — ulcer-tumour of prepyloric region	539	— — — — malignant, diagnosis of	261
— — — — where gastric musculature is weak (<i>Fig.</i> 335)	462	— — — — partial gastroectomy for, principles	461
Gastric (<i>see also</i> Stomach)		— — — — penetrating (<i>Figs.</i> 74-78)	132
— — affections, cardiospasm simulating	13	— — — — duodenal ulcer coexisting	166
— — exclusion, partial, in duodenal ulcer	420	— — — — liver, technique of partial gastroectomy (<i>Figs.</i> 430, 431)	536
— — — — jejunal ulcer	576	— — — — pancreas, technique of partial gastroectomy (<i>Fig.</i> 432)	538
— — — — peptic ulcer, comments on	423	— — — — of posterior wall in X-ray diagnosis of malignancy	266
— — — — results of	561	— — — — principles underlying surgical treatment	421
— — — — with resection (<i>Figs.</i> 442-455)	548-561	— — — — radiographically unobvious, examination for, in reflex dyspepsia	411
— — — — — — basic principles	548	— — — — syphilitic complications (<i>Fig.</i> 84)	151
— — — — — — examples of use of (<i>Figs.</i> 454, 455)	557	— — — — tumour complicating	142
— — — — — — indications	549	— — — — in X-ray diagnosis of painless dyspepsia with hæmatemesis	253
— — — — — — technique (<i>Figs.</i> 442-453)	551	— — — — wall, inflammation of, dyspepsia due to	48
— — — — — — postural tone underlying	40	— — — — systemic disease causing impairment of vitality of, dyspepsia due to	42, 44
— — fundus, ileus of	56	Gastric-ulcer-like dyspepsia in cancer of stomach	212
— — hypotonus, gastro-enterostomy and ileus, vomiting due to	429, 777	— — reflex gall-bladder dyspepsia	77
— — operations, vomiting after	777	Gastritis, antral, examination for, in reflex dyspepsia	411
— — pain, mechanism of causation of (<i>Figs.</i> 14-22)	29	— — associated with gastric stasis	98
— — resection, principles of (<i>Figs.</i> 327-335)	451-462	— — atrophic, in pernicious anæmia (<i>Fig.</i> 51)	97
— — retention, postural tone underlying	38	— — bleeding from, operation in	294
— — stasis, gastritis associated with	98		
— — ulcer (<i>see also</i> Peptic Ulcer)			
— — — — acute, dyspepsia of (<i>Fig.</i> 65)	118-122		
— — — — hæmatemesis in	296		

	PAGE		PAGE
Gastritis, cause of (<i>Figs. 43-47</i>) -	92	Glucose intravenously in enterostomy	
— chronic antral, filling defect due to		for post-operative distension -	797
(<i>Fig. 186</i>) -	276	— hæmatemesis -	299
— — in causation of peptic ulcer -	108	— paralytic ileus -	784
— — as cause of surgical dyspepsia		— post-operative shock -	764, 767
(<i>Figs. 43-55</i>) -	90	— — venous congestion -	771
— — X-ray recognition of (<i>Figs.</i>		— — vomiting due to hepatic	
48-50) -	95	insufficiency -	776
— diagnosis of -	264	— — pre-operative treatment of per-	
— diffuse chronic, dyspepsia due		foration of hollow organ -	811
to -	46	— — preparation for operation for	
— and duodenitis (<i>Figs. 43-56</i>)	90-102	intestinal obstruction -	824
— following operations on stomach		— — vomiting due to gastroduodenal	
(<i>Figs. 54, 55</i>) -	100	ileus -	777
— gastroscopic appearances (<i>Figs.</i>		Glycogenolysis, liver function and -	621
214-216) -	309	'Green' jaundice in gall-bladder	
— secondary to penetrating ulcer		syndrome -	686
(<i>Figs. 52, 53</i>) -	98, 132	— — significance of -	749
— types of -	91	Gridiron incision in appendicectomy	
Gastrocolic fistula, dyspepsia of (<i>Fig.</i>		(<i>Figs. 597, 598</i>) -	858, 859
116) -	188	Gum solution in post-operative shock	
Gastroduodenal ileus, post-operative		'Guy-rope' retraction to Devine frame	
vomiting due to -	776	in intestinal anastomoses (<i>Figs.</i>	
Gastro-entero-anastomosis, making of,		250, 318) -	348, 442, 445
in partial gastrectomy (<i>Figs.</i>		Gymnastics in bed -	802
374-411) -	493-520		
— in partial exclusion (<i>Figs. 450-453</i>)	554	HÆMATEMESIS, is the cause medical	
Gastro-enterostomy, bleeding after,		or surgical? -	295
partial gastric exclusion in -	560	— factors indicating delayed operation	293
— for duodenal ulcer -	425	— — — immediate operation -	292
— — — consideration of -	416	— in gastric carcinoma -	238
— emptying time after (<i>Fig. 306</i>) -	427	— — ulcer, X-ray examination -	257
— failures of -	431	— immediate treatment in -	291
— for gastric ulcer -	426	— and mælena, consultation on a	
— in hæmatemesis -	297	case of -	291-300
— — bleeding after -	298	— nature of emergency operation -	297
— jejunal ulcer after, incidence of		— problems confronting the surgeon	291
176, 178, 184		— in sarcoma of stomach -	201
— — — can incidence be minimized?		— stopping bleeding and preparing	
(<i>Fig. 111</i>) -	182	for future operation -	299
— in peptic ulcer, comments on	422, 423	— with painless dyspepsia, X-ray	
— — perforated -	813	diagnosis -	253
— physiology of -	425	Hæmatogenous infection, cholecystitis	
— preliminary investigation of patient	424	due to -	657
— principles on which operation is		Hæmatoma formation in anastomosis	
based (<i>Fig. 306</i>) -	424-433	of gastro-enterostomy, incidence	
— for pyloric obstruction -	427	of jejunal ulcer and -	181
— regurgitation after -	430	of rectus muscle -	405
— and resection for ulcer on lesser		Hæmatopoietic system, spleen and -	594
curvature (<i>Figs. 427-429</i>) -	532	Hæmolytic icterus, spleen and (<i>Figs.</i>	
— technique of (<i>Figs. 307-326</i>)	433-450	493, 494) -	597
— — initial steps (<i>Figs. 307-312</i>) -	433	Hæmorrhage after gastro-enterostomy	
— — operation proper (<i>Figs. 313-326</i>)	439	for hæmatemesis -	298
Gastro-intestinal wounds, technique of		— from cut edges of wall of hollow	
routine suture (<i>Figs. 268-272</i>)	358	organ in abdominal operations -	370
Gastro-jejunal anastomosis in partial		— duodenum or stomach, partial	
gastrectomy, choice of type of -	454	gastric exclusion in -	560
— — undoing of, in jejunal ulcer		— in rupture of spleen -	608
(<i>Figs. 462-470</i>) -	569	Hæmorrhagic purpura, spleen and -	603
Gastroscope, Wolf-Schindler flexible		Hæmorrhoids in cancer of distal colon	907
type (<i>Figs. 204, 205</i>) -	301	Hæmostasis in abdominal operations,	
Gastroscopy, appearances (<i>Figs. 213-</i>		importance of (<i>Fig. 273</i>) -	362
219) -	309	— gastric resection, attainment of -	452
— contra-indications -	302	Hanging belly position in rectal	
— technique (<i>Figs. 206-212</i>) -	302	operations (<i>Figs. 658, 659</i>) -	981
— with flexible gastroscope (<i>Figs.</i>		Hartmann, pouch of, in cholecystec-	
204-219) -	301-314	tomy (<i>Fig. 559</i>) -	705
Gaucher's disease, splenectomy in -	611	— — stone in, post-cholecystectomy	
Gentian-violet - acriflavine - brilliant-		reflex dyspepsia due to (<i>Figs.</i>	
green solution in rectal surgery	986	36, 37) -	80
Glucose in appendicitis in young -	882		

	PAGE		PAGE
Heart (<i>see also</i> Cardiac)		Hydatid of liver, calcified (<i>Figs.</i> 531-	
— failure, incipient or chronic, hæma-		534) - - - - -	650
— — — post-operative, diagnosis from	80	— — — centrally situated (<i>Figs.</i> 515-	
— — — — peripheral vascular failure -	769	518) - - - - -	632
— — — — treatment of - - - - -	770	— — — diagnosis from acute chole-	
Heartburn in dyspepsia - - - - -	25	— — — — cystitis (<i>Fig.</i> 555) - - - - -	694
Heat in post-operative distension	781, 782	— — — — gall-bladder syndrome - -	684
— — — — pain in surgical dyspepsia -	774	— — — — general characteristics of -	629
— — — — treatment of acute appendicitis	868	— — — — left lobe (<i>Figs.</i> 519-521) - -	638
— — — — — perforation - - - - -	814	— — — — on lower surface of right lobe	
Hepatic (<i>see also</i> Liver)		(<i>Figs.</i> 510, 511) - - - - -	631
— flexure, retraction of, in exposure		— — — mistaken for gastric carcinoma	
— of gall-bladder (<i>Fig.</i> 246) - - - -	343	(<i>Fig.</i> 156) - - - - -	239
— — — insufficiency, abdominal operability		— — — near gall-bladder (<i>Figs.</i> 522, 523)	640
— — — — and - - - - -	374	— — — occupying whole right side (<i>Figs.</i>	
— — — — post-operative vomiting due to	776	512, 513) - - - - -	631
Hepatitis, hydatid of liver with (<i>Figs.</i>		— — — opening into kidney - - - - -	646
517, 518) - - - - -	636	— — — portal fissure - - - - -	641
Hepatomegaly caused by hydatid		— — — on posterior surface (<i>Fig.</i> 514)	632
disease (<i>Figs.</i> 510-527) - - - - -	627	— — — suppurating, diagnosis from	
— of medical import - - - - -	622	— — — — gall-stones (<i>Figs.</i> 548, 549) -	687
— — — surgical import - - - - -	624	— — — — upper part of right lobe, opera-	
Hernia (<i>Figs.</i> 471-490) - - - - -	578-591	— — — — — tion for (<i>Figs.</i> 528-530) -	647
— — — diaphragmatic, strangulated -	582	— — — — — upper surface - - - - -	642
— — — — treatment (<i>Figs.</i> 471-475) -	578	— — — — — pancreas - - - - -	737
— — — — — varieties, symptoms, and signs -	578	— — — — — spleen - - - - -	605
— — — — — epigastric - - - - -	404	— — — — — splenectomy in - - - - -	611
— — — — — external, causing intestinal obstruc-		Hydrochloric acid treatment of calcified	
— — — — — — tion - - - - -	821, 827	hydatid cysts (<i>Fig.</i> 532-534) -	650
— — — — — femoral, appendicitis in - - - - -	856	Hydronephrosis simulating appendi-	
— — — — — inguinal, appendicectomy through		citis in female - - - - -	841
— — — — — — internal abdominal ring during		Hydrostatic pressure dilatation in	
— — — — — — — operation for - - - - -	877	cardiospasm (<i>Fig.</i> 9) - - - - -	19
— — — — — — — herniotomy under local anæ-		Hypertrophic gastritis, gastroscopic	
— — — — — — — — sthesia (<i>Figs.</i> 476-488) -	583	appearances (<i>Figs.</i> 215, 216) -	311
— — — — — — — — internal, intestinal obstruction due		Hypertrophy of pylorus, dyspepsia	
— — — — — — — — — to - - - - -	822	due to - - - - -	413
— — — — — — — — — operations, hæmatemesis following	295	Hypochondriac pain and tenderness in	
— — — — — — — — — — sliding, operation for (<i>Figs.</i> 489,	590	gall-bladder syndrome, differ-	
490) - - - - -	590	ential diagnosis (<i>Figs.</i> 548, 549)	687
Hernie en glissade, operation for (<i>Figs.</i>		Hypogastrium, inflammatory condition	
489, 490) - - - - -	590	of, in diverticulitis - - - - -	922
Hiccup after splenectomy in ruptured		Hypopharyngeal malignancy, dys-	
spleen - - - - -	609	phagia due to (<i>Fig.</i> 3) - - - -	4
Hirschsprung's disease - - - - -	59	ICTERUS (<i>see</i> Jaundice)	
Histamine in production of shock -	761	Idiopathic ileus (<i>Figs.</i> 27-30) - - -	55
'Hochsitzung' ulcer of lesser curvature		Ileitis, regional (<i>Fig.</i> 614) - - - -	886
(<i>Fig.</i> 70) - - - - -	127	Ileocæcal junction, torsion at, simu-	
Hollow viscera, technique of opera-		— — — — — lating appendicitis - - - - -	841
tions on, general - - - - -	369-372	— — — — — lymphadenitis simulating appendi-	
Horsley's modification of Billroth I		— — — — — — citis - - - - -	841
operation (<i>Figs.</i> 404-408) - - - - -	516	— — — — — — mesenteric lymphadenitis - - -	885
Hospitals, abdominal surgery in -	320	— — — — — — tuberculosis, diagnosis of - -	895
Hour-glass contraction complicating		— — — — — — — tuberculous adenitis, diagnosis of	895
gastric ulcer - - - - -	145	— — — — — — — — tumour due to pelvic appendicitis -	852
— — — — — X-ray diagnosis (<i>Figs.</i> 166-169)	257	— — — — — — — — valve, carcinoma of, simulating	
Hunger dyspepsia in duodenal ulcer -	159	— — — — — — — — — — — appendicitis - - - - -	840
Hybrinette's method of anastomosis		Ileocolotomy in cancer of proximal	
in repair of common duct (<i>Fig.</i>		colon (<i>Figs.</i> 615, 616) - - - - -	898, 901
574) - - - - -	725	Ileo-transverse-colostomy in cancer of	
Hydatid of abdominal wall - - - - -	405	proximal colon - - - - -	903, 904
— — — — — diagnosis of - - - - -	895	Ileus of colon and bladder (<i>Fig.</i> 29) -	59
— — — — — — causing tumour in left iliac fossa -	913	— — — — — common bile-duct - - - - -	60
— — — — — — — disease, hepatomegaly due to (<i>Figs.</i>		— — — — — diagnosis from acute pancreatic	
510-527) - - - - -	627	— — — — — — — — — — — necrosis - - - - -	733
— — — — — — — hæmatemesis following operation		— — — — — — — — — — — duplex arising from pelvic appen-	
— — — — — — — — — — — for - - - - -	295	— — — — — — — — — — — — dicitis (<i>Fig.</i> 595) - - - - -	849
— — — — — — — — — — — infestation of scar of abdominal		— — — — — — — — — — — — dynamic - - - - -	817
— — — — — — — — — — — — — wound - - - - -	404	— — — — — — — — — — — — of gall-bladder - - - - -	60
— — — — — — — — — — — — — of liver, anterior surface - - - -	642		

	PAGE		PAGE
Ileus, gastro-duodenal, post-operative		Inguinal hernia, appendicectomy	
vomiting due to	776	through internal abdominal	
— idiopathic (<i>Figs. 27-30</i>)	55	ring during operation for	877
— of kidney pelvis	60	— herniotomy under local anaesthesia	
— oesophagus	55	(<i>Figs. 476-488</i>)	583
— paralytic, refractory post-operative		Instruments, high-pressure sterilization	
distension due to	790, 792	of (<i>Fig. 267</i>)	357
— — treatment of early case (<i>Fig.</i>		— tray for (<i>Fig. 255</i>)	355
587)	783	Instrumentarium for abdominal	
— of small intestine	57	surgery	321
— stomach	56	Insulin in post-operative vomiting due	
— — and duodenum (<i>Figs. 27, 28</i>)	56	to hepatic insufficiency	776
— — in reflex dyspepsia	412	Intestinal adhesions, examination for,	
— — fundus	56	in reflex dyspepsia	410
— — vomiting due to	777	— — method of dealing with, in	
— — ureters (<i>Fig. 30</i>)	61	jejunal ulcer operations (<i>Fig.</i>	
Iliac fossa, left, inflammatory symptoms		458)	564
in, in diverticulitis (<i>Fig. 619</i>)	920	— contents, aspiration of, in gastric	
— — tumour of, in cancer of distal		resection	453
colon	908	— forceps (<i>Fig. 263</i>)	357
— — — innocent conditions of		— loops, adhesions between (<i>Fig. 300</i>)	399
distal colon	911	— — gastro-enterostomy, disposition	
— — right, inflammatory symptoms		of	429, 449
in, in diverticulitis	921	— — obstruction, actual onset of	816
Illumination in dealing with abdo-		— — acute, in cancer of distal colon	907
minal adhesions (<i>Figs. 294-296</i>)	395	— — causing post-operative disten-	
— of theatre for abdominal surgery		sion (<i>Figs. 589, 592</i>) 789, 790, 794	
(<i>Fig. 220</i>)	321	— — choice of anaesthetic	825
Incision for appendicectomy (<i>Figs.</i>		— — circulatory obstruction in	820
597, 598, 606)	858, 859, 869	— — clinical picture	815
— cholecystectomy (<i>Figs. 557, 558</i>)	702	— — determining method of treatment	823
— closure of perforated abdominal		— — nature of obstruction	821
organ	812	— — in diverticular tumour	924, 926
— gastro-enterostomy (<i>Fig. 307</i>)	433	— — diverticulitis, surgical treatment	
— ileocolotomy	902	(<i>Figs. 622-628</i>)	934
— intestinal obstruction	825	— — due to external hernia	821
— jejunal ulcer operations (<i>Fig. 456</i>)	563	— — — pelvic appendicitis (<i>Fig. 595</i>)	849, 851
— making disconnecting anus (<i>Fig.</i>		— — — during post-operative course	822
631)	946	— — — functional	817
— opening old abdominal scar (<i>Figs.</i>		— — — inflammatory	817, 822
297, 298)	397	— — — method of treatment	823
— partial gastrectomy (<i>Figs. 346-348</i>)	475	— — — in innocent conditions of distal	
— — for ulcer on lesser curvature		colon	910
(<i>Figs. 414-419</i>)	524	— — is the cause mechanical?	817
— splenectomy (<i>Fig. 498</i>)	612	— — level of	819
— upper abdominal operations (<i>Fig.</i>		— — operative approach	824
229)	330	— — pelvic appendicitis simulating	852
— — — general principles <i>re</i>		— — post-operative treatment	828
(<i>Figs. 289-291</i>)	386-389	— — pre-operative management	824
Infarct pneumonia post-operatively,		— — previous history as guide to	
in surgical dyspepsia	785	diagnosis	815
Infarction theory of causation of		— — in small bowel, surgery of	827
peptic ulcer (<i>Fig. 57</i>)	105	— — strategy of surgical approach	
Infection, function of spleen in		to	815-828
immunity to	604	— — toxic pseudo-obstruction	817
— splenomegaly due to, splenectomy		— — treatment of early case (<i>Fig. 587</i>)	783
in	610	— — retraction in abdominal operations	340
Infective conditions, hepatomegaly		Intestine (<i>see also under individual</i>	
in	626	portions)	
— duodenal ulcer	418	— adhering to anterior abdominal wall	
— symptoms, jaundice with, signi-		(<i>Fig. 299</i>)	398
ficance of	749	— — posterior abdominal wall	400
Inflammation, areas of, in diverticu-		— — handling of, in cholecystectomy	699
litis	919, 920	— — small, abdominal incisions and	388
— around gastric carcinoma	237	— — as danger area in abdominal	
— of gastric wall, dyspepsia due to	48	operations	385
Inflammatory infiltration of stomach		— — ileus of	57
causing pain (<i>Figs. 15-17</i>)	32	— — protection of, in appendicec-	
— — — mechanical effects of	42	tomy (<i>Fig. 600</i>)	863
— — intestinal obstruction	817, 822	— — spasm of	66
— — — method of treatment	823		

	PAGE		PAGE
Intestine and stomach, method of handling abdominal dissection (<i>Fig.</i> 253)	352	Jejunal ulcer, gastro-colic fistula from (<i>Fig.</i> 116)	188
Intra-hepatic gall-stones (<i>Fig.</i> 539)	668	— — general considerations (<i>Figs.</i> 106-108)	176
Intravenous feeding post-operatively in acute appendicitis	868	— — incidence of	183
— glucose (<i>see</i> Glucose)		— — medical treatment	191
— saline (<i>see</i> Saline)		— — operability of patient	562
Intussusception, intestinal obstruction due to	822	— — operations for (<i>Figs.</i> 456-470)	191, 562-577
— of normal appendix (<i>Fig.</i> 612)	883	— — — anaesthesia	563
— in sigmoid cancer	908	— — — technique (<i>Figs.</i> 456-470)	563
Invasive cancer of proximal colon, operation for	901	— — — partial gastrectomy and enterectomy in (<i>Figs.</i> 459-461)	566
— — — — syndrome of	891	— — — — principles (<i>Fig.</i> 334)	461
Iodotetragrost in cholecystography	673	— — — gastric exclusion in	558
Iodotetraphenolphthalein in cholecystography	670	— — — pre-operative preparation of patient	562
Irritable bladder	65	— — — undoing gastrojejunal anastomosis in (<i>Figs.</i> 462-470)	569
— — symptoms in diverticulitis (<i>Fig.</i> 621)	927	Jejunitis	177, 185
— stomach, dyspepsia due to	47	— — bleeding from, operation in	294
Ischiorectal fistulae, surgical management of	1019	— — following operations on stomach (<i>Figs.</i> 54, 55)	100
— sepsis, surgical management of	1019	Jejunostomy in post-operative distension due to mechanical obstruction	794
JAKSCH'S (VON) anæmia, spleen and — — splenectomy in	604 611	Jejunum, anastomosis of common duct to (<i>Fig.</i> 574)	725
Jaundice, acholic, diagnosis of	748	— — choosing site of opening in, in gastro-enterostomy	441
— — — from gall-bladder syndrome	683	— — diverticula of, in reflex dyspepsia	412
— — — spleen and (<i>Figs.</i> 493, 494)	597	— — gall-bladder anastomosed to (<i>Fig.</i> 580)	745
— — — splenectomy in	609	Juxtapyloric chronic ulcer, filling defects due to (<i>Figs.</i> 183-185)	274
— — — in 'ball-valve' stone in common duct	679	KELLY atraumatic needle for peritoneal suture in cholecystectomy (<i>Fig.</i> 566)	710
— — — catarrhal	752	Kidney (<i>see also</i> Renal)	
— — — cause not discovered at operation (<i>Fig.</i> 583)	753	— — hydatid of liver opening into	646
— — — colour of, significance of	749	— — operative approach to	389
— — — conditions causing slight icterus	751	— — pelvis, ileus of	60
— — — consultation on a case of	748-752	— — tuberculous, lymph passing down ureter from, simulating appendicitis	840
— — — in gall-bladder syndrome	683	— — tumour of, diagnosis of	896
— — — hæmolytic, spleen and (<i>Figs.</i> 493, 494)	597	Kirschner's grooved director (<i>Fig.</i> 266)	357
— — — hepatomegaly with	625	— — method of high-pressure anaesthesia (<i>Fig.</i> 343)	469
— — — in hydatid disease	629, 630	— — — — in partial gastrectomy	473
— — — of non-surgical import	752	Knife, art of using, in abdominal cavity — Bard-Parker, for cholecystectomy (<i>Fig.</i> 562)	707
— — — operation table problems in (<i>Figs.</i> 583, 584)	753-757	Knot-tying in abdominal operations (<i>Figs.</i> 274-286)	319, 363
— — — painful, significance of	749	Kocher clamps in technique of making disconnecting anus (<i>Figs.</i> 635-637)	951
— — — in stone impacted in ampulla of Vater	679	— — incision, cholecystectomy through, choledochotomy after	728
— — — of surgical import	748	LAMP, flexible, for illuminating deep cavities (<i>Fig.</i> 264)	357
— — — with gall-bladder dilatation, significance of	750	Leucocytosis in acute appendicitis	838
— — — infective symptoms, significance of	749	Leukæmia, hæmatemesis in	295
Jejunal diverticulum, dyspepsia of (<i>Fig.</i> 117)	193	— — splenomedullary, spleen and — — splenectomy in	603 610
— — loop in relation to transverse colon in gastro-entero-anastomosis (<i>Figs.</i> 376-382)	495	Lieferstrom's forceps (<i>Fig.</i> 256)	355
— — obstruction, high, dyspepsia of (<i>Figs.</i> 118-121)	194		
— — ulcer, bleeding from, operation in — — carcinoma developing from	294 190		
— — — causation of (<i>Figs.</i> 109, 110)	177		
— — — diagnosis of (<i>Figs.</i> 112-115)	185		
— — — dyspepsia of (<i>Figs.</i> 106-116)	176-192		
— — — extensive partial gastric exclusion in	576		

	PAGE		PAGE
Ligation in abdominal operations, routine method (<i>Figs.</i> 274-287)	363	McBURNLEY'S incision in appendicec- tomy (<i>Figs.</i> 597, 598, 606)	858, 859, 870
Ligature carrier and McCormick dissector (<i>Fig.</i> 257) -	355	McCormick dissector for cholecystec- tomy (<i>Fig.</i> 561B) -	707
— needle, Deschamps' (<i>Fig.</i> 265) -	357	— — and ligature carrier (<i>Fig.</i> 257)	355
— and sutures for closure of abdo- minal wounds -	541	<i>Magenstrasse</i> , ulcer formation in -	113
Linitis plastica -	223	Malignancy (<i>see</i> Cancer; Sarcoma)	
— — prepyloric filling defect in -	270	Mandy's diffusion anæsthesia in partial gastrectomy (<i>Figs.</i> 344, 345) -	471
— — X-ray diagnosis (<i>Figs.</i> 160-164)	250	Manual dilation in cardiospasm (<i>Figs.</i> 10-12) -	20
Lipoma of stomach, bleeding from operation in -	294	Mask, operation (<i>Fig.</i> 221) -	323
— — dyspepsia of (<i>Fig.</i> 129) -	206	Massive collapse of lung post-opera- tively in surgical dyspepsia -	786
Liver (<i>see also</i> Hepatic)		'Mechanical hands' for Devine opera- ting frame (<i>Figs.</i> 226, 227) -	326
— adhering to abdominal wall -	398	— — in exposure of gall-bladder (<i>Figs.</i> 244-248) -	341
— cancer of, hepatomegaly in -	624	Meckel's diverticulum, intestinal obstruction due to -	823
— cirrhosis of, hæmatemesis in -	295	— — simulating appendicitis -	840
— — hepatomegaly in -	623	Medical dyspepsia, definition of -	43
— — jaundice due to -	752	Megacolon -	59
— disease, negative cholecystogram and -	673	Megacystitis -	59
— enlargement of (<i>see</i> Hepatomegaly)		Melana in cancer of distal colon -	906
— examination of, in negative chole- cystogram in reflex dyspepsia -	407	— from colon, diagnosis -	897
— exploration of, in obscure jaundice function -	755	— in duodenal ulcer -	160, 163
— — test in absence of cholecysto- graphic shadow -	674	— gastric ulcer, X-ray examination -	257
— gall-stones in ducts of (<i>Fig.</i> 539) -	668	— and hæmatemesis, consultation on a case of -	291-300
— gastric ulcer penetrating into (<i>Fig.</i> 74) -	133	— in papillomata of colon and rectum	909
— — — technique of partial gastrectomy (<i>Figs.</i> 430, 431) -	536	Mercury tube dilatation in cardiospasm	20
— handling of, in cholecystectomy -	699	Mesenteric artery, inferior, in circula- tion of anal canal in resection of rectum (<i>Fig.</i> 682) -	1002, 1005
— and hepatomegaly (<i>Figs.</i> 510-534)	621-652	— — in production of gastroduodenal ileus -	777
— hydatid of (<i>see</i> Hydatid)		— attachments to posterior wall in upper abdominal surgery (<i>Fig.</i> 288) -	381
— sepsis, hydatid simulating -	633, 635	— lymphadenitis, ileocæcal -	885
— solitary cyst of -	625	— — tuberculous, dyspepsia due to (<i>Fig.</i> 42) -	87
— tenderness from congestive heart failure, diagnosis from gall- stones -	689	Metabolic disturbances and operability	378
— tropical abscess of -	624	Meulengracht's diet in hæmatemesis -	299
— upper surface of, exposure of by Devine operating frame (<i>Fig.</i> 249)	348	Mid-colic artery, identification of, in partial gastrectomy -	480
Lobeline in post-operative shock -	767	Midline incision in approach to upper abdominal organs -	388, 389
Local anæsthesia in cholecystectomy -	701	Miles operation in cancer of rectum -	976
— — inguinal herniotomy under (<i>Figs.</i> 476-488) -	583	— — — technique (<i>Figs.</i> 686- 688) -	1015-1018
— — in minimization of post-operative shock -	762	Miller-Abbott tube in post-operative distension (<i>Fig.</i> 588) -	791
— — partial gastrectomy (<i>Figs.</i> 337- 343) -	467	Mitral stenosis, hæmatemesis in -	295
— — with 'diffusion' anæsthesia in partial gastrectomy (<i>Figs.</i> 344, 345) -	471	Mixed gall-stones -	660
Lockhart-Mummery perineal excision of rectum (<i>Fig.</i> 684) -	1012	Morphia in minimization of post- operative shock -	762
Locking mechanism in Devine opera- ting frame (<i>Fig.</i> 223) -	325	— post-operative distension -	781
Lung, massive collapse of, post- operatively, in surgical dyspepsia	786	— — pain in surgical dyspepsia -	774
Lymphadenitis, ileocæcal mesenteric -	885	— — treatment of acute appendicitis	868
— — simulating appendicitis -	841	— premedication in gas and oxygen anæsthesia in partial gastrectomy	464
— tuberculous mesenteric, dyspepsia due to (<i>Fig.</i> 42) -	87	— in pre-operative treatment of per- foration of hollow organ -	810, 811
Lymphatic connexions of gall-bladder — fields in abdomen, surgery and -	655	Motor function of stomach -	28
Lymph-glands, abdominal, examina- tion of, in reflex dyspepsia -	411	Mucocèle of gall-bladder (<i>Fig.</i> 537) -	664
		Mucoclasia to facilitate prepyloric closure in partial gastrectomy (<i>Fig.</i> 413) -	523

	PAGE		PAGE
Mucous colitis syndrome in diverticulitis	919	Norwegian knot, Devine modification (<i>Figs.</i> 274-286)	363
— membrane of hollow viscera, management of in abdominal operations	369	Novocain local anaesthesia for inguinal herniotomy (<i>Figs.</i> 477, 481)	584
— — inaccurate coaptation of in gastro-enterostomy, jejunal ulceration and	181	— — — in partial gastrectomy	469, 471
— — — sutures in Billroth II operation (<i>Figs.</i> 399, 400)	510	OCHSNER · DEBAKEY enterotome (<i>Fig.</i> 645)	957
— — — of duodenum in partial gastrectomy (<i>Figs.</i> 360, 361)	486	Oddi, sphincter of, function of	654
— — — in gastro-enterostomy (<i>Figs.</i> 321-323)	445	— — spasm or hypotonus of, causing retrojection of bile into pancreas	731
— — — Polya gastro-entero-anastomosis (<i>Figs.</i> 389, 390)	504	Œsophagitis, dysphagia due to	18
— — — of stomach after undoing gastrojejunal anastomosis (<i>Fig.</i> 465)	573	Œsophagus, carcinoma at level of tracheal bifurcation, dysphagia due to	7
Muscle spasm causing gastric pain (<i>Fig.</i> 15)	31	— — of lower end of, diagnosis from cardiospasm (<i>Figs.</i> 5-8)	14
— — round large gall-stone	663	— — — — dysphagia due to	9
Myoma of stomach, bleeding from, operation in	294	— — — — treatment	19
— — dyspepsia of (<i>Figs.</i> 127, 128)	205	— — upper part, dysphagia due to	6
— — resection of fundus (<i>Figs.</i> 433, 434)	539	— — cardiospasm (<i>Figs.</i> 4-8)	11
— — X-ray diagnosis	287	— — chronic peptic ulcer of, dysphagia due to	17
Myomatous tumours causing lump in left iliac fossa	913	— — diverticulum of upper part, dysphagia due to	6
NAPOLEON, penetrating ulcer as cause of death of	135	— — dysphagia in lower part of (<i>Figs.</i> 4-12)	8-23
Nausea in dyspepsia	24	— — — middle part of	7
— and vomiting, significance of	68-71	— — — upper part of (<i>Figs.</i> 1-3)	3-7
Nauseous dyspepsia due to gall-stones — reflex gall-bladder dyspepsia (<i>Fig.</i> 32)	76	— — ileus of	55
Needle, art of using in abdominal cavity — curved, method of using, in abdominal operations (<i>Figs.</i> 271, 272)	359	— — preliminary X-ray investigation of, in diagnosis of surgical dyspepsia (<i>Fig.</i> 159)	245
— Deschamps' ligature (<i>Fig.</i> 265)	357	— — sites of obstruction in (<i>Fig.</i> 2)	3
— Kelly atraumatic, for peritoneal suture in cholecystectomy (<i>Fig.</i> 566)	710	— — spasm of	66
— straight, method of using in abdominal operations (<i>Figs.</i> 268-270)	358	Omentum, adhesions to anterior abdominal wall	396
Neo-athrombit blood transfusion apparatus (<i>Fig.</i> 586)	771	— in anastomosis in ileocelectomy	903
Nerve control of whole alimentary canal	384	— disposal of, in suture of incision after undoing gastrojejunal anastomosis	576
Nerve-supply of abdominal viscera (<i>Fig.</i> 26)	54, 383	— disposition of, in partial gastrectomy	520
— — wall (<i>Fig.</i> 289)	386	— mobilization of, in partial gastrectomy for ulcer on lesser curvature (<i>Fig.</i> 421)	528
— — gall-bladder (<i>Fig.</i> 535)	655	— — twisted, simulating appendicitis in female	841
Neurogenic causation of shock	761	Omnopon premedication in gas and oxygen anaesthesia in partial gastrectomy	464
— shock, prevention of	762	Operating frame, Devine (<i>Figs.</i> 222-224)	325
Neuromuscular disease of stomach causing dyspepsia	412	— — — advantages of use of (<i>Figs.</i> 249, 250)	346
— disorder of stomach, intrinsic, diagnosis of	264	— — — in isolation of gall-bladder (<i>Figs.</i> 242-250)	341
Niche in radiographs of duodenal ulcer (<i>Figs.</i> 97, 101)	168	— — — use in upper abdominal operations (<i>Figs.</i> 229-250)	329
Nitroglycerin in dyskinesia of sphincter of Oddi	715	— — theatre for abdominal surgery (<i>Figs.</i> 220, 221)	321
Nitrous oxide and oxygen anaesthesia in cholecystectomy	701	Operation mask (<i>Fig.</i> 221)	323
— — — for partial gastrectomy	464	— — team in abdominal surgery	320
— — — in minimization of post-operative shock	762	Oral method of cholecystography	671
Non-lithogenous cholecystitis	661	Ovarian conditions causing lump in left iliac fossa	913
		Ovulation, painful, simulating appendicitis	840

	PAGE		PAGE
PAIN, abdominal right-sided, diagnosis of	896	Paramedian incision in approach to upper abdominal organs	388, 389
— in acute appendicitis	837	— — cholecystectomy (<i>Fig. 557</i>)	702
— — pancreatic necrosis	731	— — for gastro-enterostomy (<i>Fig. 307</i>)	433
— dyspepsia	24	— — upper abdominal operations (<i>Fig. 229</i>)	330
— epigastric, in gall-bladder syndrome, diagnosis from pelvic appendicitis (<i>Fig. 547</i>)	686	Parasympathetic nerve-supply of abdominal viscera (<i>Fig. 26</i>)	54
— — left, in gall-stone, diagnosis from angina	697	— system in control of alimentary canal	384
— erroneously attributed to post-operative abdominal adhesions	199	Paul technique in operations on functioning distal colon	942
— hypochondriac, in gall-bladder syndrome, differential diagnosis (<i>Figs. 548, 549</i>)	687	Pelvic abscess in appendicitis	873
— post-cholecystectomy	713	— — appendicitis (<i>Fig. 595</i>)	833, 847
— post-operative, in surgical dyspepsia	774	— — case histories illustrating proctean syndromes	847
— thoracic, left, in gall-stone, diagnosis from angina	697	— — causing acute intestinal obstruction (<i>Fig. 595</i>)	849
Pancreas, carcinoma of (<i>Fig. 578</i>)	740	— — — chronic intestinal obstruction	851
— — diagnosis from chronic pancreatitis	755	— — diagnosis from gall-bladder disease (<i>Fig. 547</i>)	686
— — head of, diagnosis from gall-stones	686	— — intestinal obstruction in	910, 911
— — reflex dyspepsia due to (<i>Fig. 39</i>)	83	— — operation for (<i>Figs. 606-608</i>)	869
— cystic disease of	737	— — inflammatory syndrome in diverticulitis	922
— duodenal ulcer penetrating (<i>Figs. 91-94</i>)	161	Pelvo-ureteral obstruction, dyspepsia of (<i>Figs. 304, 305</i>)	409
— examination of, in reflex dyspepsia	408	Penetrating gastric ulcer (<i>Figs. 74-78</i>)	132
— gastric ulcer penetrating into (<i>Fig. 75</i>)	134	Peptic ulcer, acidic theory of causation (<i>Figs. 58-64</i>)	108
— — — — technique of partial gastrectomy (<i>Fig. 432</i>)	538	— — aetiology of (<i>Figs. 57-64</i>)	103-117
— hydatid of	737	— — bleeding from, factors indicating delayed operation	293
— non-malignant affections of	730-737	— — cause of death in	103
— stone causing retrojection of bile into (<i>Fig. 546</i>)	681	— — chronic gastritis in causation of	108
Pancreatic duct, retrojection of bile into, causes of	730	— — comments on operations for	422
— — — — due to stone at exit to duodenum (<i>Fig. 546</i>)	681	— — distribution of	104
— necrosis, acute	730	— — gastritis as forerunner of	95
— tumour of doubtful character, operation in (<i>Fig. 584</i>)	756	— — secondary to (<i>Figs. 52, 53</i>)	98
Pancreatitis, acute	730	— — incidence of	103
— chronic, association with gall-stones and cholecystitis	736	— — infarction theory of causation (<i>Fig. 57</i>)	105
— — diagnosis from carcinoma	755	— — juxtapyloric, filling defects due to (<i>Figs. 183-185</i>)	274
— — gall-stone	685	— — medical or surgical treatment	414
— subacute	736	— — nausea and vomiting in	68
Pancreatosis	730	— — of œsophagus, chronic, dysphagia due to	17
Pantopon pre-operatively in partial gastrectomy	474	— — partial gastric exclusion in (<i>Figs. 442-445</i>)	551
Papilloma, bleeding from, operation in	294	— — perforated, diagnosis from acute pancreatic necrosis	733
— of distal colon, surgical treatment	914	— — principles underlying treatment	414-423
— — and upper rectum	909	— — theories of causation (<i>Figs. 57-64</i>)	104
— proximal colon	890	— — — the surgeon and	115
Papilloma-like carcinoma of stomach, demonstrating filling defect in (<i>Figs. 176, 177</i>)	269	Percaime 'diffusion' anaesthesia with local anaesthesia in partial gastrectomy (<i>Figs. 344, 345</i>)	471
Papillomatous cancer of proximal colon	890	— — spinal zonal anaesthesia	474
— — — — syndrome of	893	— — — in intestinal obstruction	825
Paraffin to aid evacuation of blood in melæna	300	Perforated peptic ulcer, diagnosis from acute pancreatic necrosis	733
Paralytic ileus, refractory post-operative distension due to	790, 792	Perforation in acute gastric ulcer (<i>Fig. 65</i>)	120
— — treatment of early case (<i>Fig. 587</i>)	783	— of hollow organ, choice of anaesthesia	811
Paramedian and costal incisions in partial gastrectomy for ulcer on lesser curvature (<i>Figs. 418, 419</i>)	526	— — — determining organ affected	809
		— — — — whether in upper or lower abdomen	809

	PAGE		PAGE
Perforation of hollow organ, diagnosis of	807	Pernicious abdominal adhesions	390
— — — operative technique	811	— anæmia, atrophic gastritis in (<i>Fig.</i>	
— — — post-operative treatment	814	51) - - - - -	97
— — — pre-operative treatment	810	— — spleen and - - - - -	600
— — — question of drainage	813	— — type of clinical picture in	
— — — radical operation	813	'silent' gastric carcinoma	232
— — — strategy of surgical approach		Petz clamp in Billroth II operation	
to - - - - -	807-814	(<i>Fig.</i> 394) - - - - -	507
Perforative appendicitis, acute	846	Phantom tumour of abdominal wall	
Pericarcinomatous inflammation or		(<i>Figs.</i> 302, 303) - - - - -	403
abscess of stomach	237	Pitkin's syringe for local anaesthesia	
Peridiverticulitis	918	(<i>Fig.</i> 337) - - - - -	467
Perigastric adhesions, dyspepsia due to	198	Plastic chronic appendicitis	842
inflammation, gastric ileus due to	777	Plasticity of gastric muscle	39
Perineal and abdomino-perineal resections of rectum compared	1008	Pleural cavity, rupture of hydatid of	
— operation for cancer of rectum	976, 978	liver into (<i>Fig.</i> 527) - - - - -	644
— resection of rectum, two-stage method (<i>Fig.</i> 684)	1012	— effusion after splenectomy in ruptured spleen	609
Perineo-abdominal operation in cancer of rectum	978, 989	Plummer hydrostatic dilator in cardiospasm (<i>Fig.</i> 9)	19
— — — conservative (<i>Fig.</i> 679)	1001	Plummer-Vinson syndrome, dysphagia in	19
— — — radical (<i>Fig.</i> 678)	1001	Pneumococcal peritonitis, pelvic appendicitis in child simulating	853
— — — technique (<i>Figs.</i> 665-682)	989	Pneumonia, post-operatively, in surgical dyspepsia	785, 786
Perinephric abscess due to retrocæcal appendicitis	855	— rupture of hydatid into pleural cavity simulating	645
Peripheral vascular failure, diagnosis from cardiac failure	769	Pointing test in œsophageal obstruction (<i>Fig.</i> 1)	3
— — system in post-operative shock, toning-up of	766	Polya gastro-entero-anastomosis, method of making (<i>Fig.</i> 374)	493
Perisplenitis	606	— — technique of suturing (<i>Figs.</i> 383-393)	500
Peristalsis in post-operative cardiac failure	770	Polycythæmia, hepatomegaly due to	623
Peritoneal cavity, perforation of rectum into (<i>Fig.</i> 690)	1021	Polyp of stomach, X-ray diagnosis (<i>Figs.</i> 201, 202)	287
— — rupture of hydatid into	630	Portal cirrhosis, spleen and	604
— covering, absence of in rectum as problem in surgery	983	fissure of liver, hydatid of	641
— effusion after splenectomy in ruptured spleen	609	— pyæmia, diagnosis from cholangitis	698
— exudate, removal of, in appendectomy	867	— hepatomegaly in	626
— involvement in abdominal wound sepsis	799	Post-cholecystectomy type of reflex dyspepsia (<i>Figs.</i> 36, 37)	78
— sac, lesser, making opening into, in gastro-enterostomy (<i>Fig.</i> 313)	439	Post-operative abdominal adhesions	390
— surface of anterior abdominal wall, repair of	401	— — dyspepsia due to	199
Peritoneum, avoidance of soiling of, in ileocectomy	902	Postural tone of abdominal wall (<i>Figs.</i> 290, 291)	386
— closure of, in abdominal operations (<i>Figs.</i> 435, 436)	543	— — underlying gastric expulsion (<i>Figs.</i> 21, 22)	40
— — after undoing a gastrojejunal anastomosis	575	— — — retention	38
— suture of rents of, in upper abdominal operations (<i>Fig.</i> 240)	338	Posture in abdominal operations	349
Peritonism in acute appendicitis	838	— dealing with exudate in appendectomy	867
Peritonitis after upper abdominal operations	800	— perineo-abdominal resection of rectum (<i>Fig.</i> 665)	990
— chronic localized, in diverticulitis, treatment of	933	— in post-operative cardiac failure	770
— due to perforated diverticulum	922	— pre-operative treatment of perforation of hollow organ	810
— — rupture of diverticulum in abdominal exploration	923	— for two-stage perineal operation (<i>Fig.</i> 684)	1012
— encapsulating, adhesions due to (<i>Figs.</i> 292, 301)	390, 402	Pouch of Hartmann in cholecystectomy (<i>Fig.</i> 559)	705
— general, in diverticulitis	934	— — stone in, post-cholecystectomy reflex dyspepsia due to (<i>Figs.</i> 36, 37)	80
— — fulminating appendicitis	844	Pre-cholelcytic disease	660
— — intestinal obstruction of	817	Pregnancy, tubal, simulating appendicitis	840
— pneumococcal, pelvic appendicitis in child simulating	853	Prepyloric carcinoma, dyspepsia due to (<i>Figs.</i> 133-135, 141)	215, 224

	PAGE		PAGE
Prepyloric carcinoma, filling defect in (Figs. 178-180)	270, 271	RADIANT heat in post-operative treatment of acute appendicitis	868
— carcinomatous ulcer, X rays in	271	— — — perforation	814
— disease, cholecystography and	673	Radiography (see X-ray Diagnosis)	
— filling defects (Figs. 178-194)	270	Radio-surgical diagnosis of obscure types of painless dyspepsia (Figs. 160-164)	248-253
— presphincteric filling defects (Figs. 187-190)	276	— — — in painful dyspepsia with tender spot (Figs. 165-173)	254-265
— ulcer, characteristics (Figs. 71, 72)	128	— — — — without tender spot (Figs. 174-202)	266-287
— — — treatment of	539	— — — surgical dyspepsia (Figs. 157- 159)	242-247
— — — tumour, partial gastric exclusion in	557	Rectal approach to pelvic appendiceal abscess in male	874
Presphincteric prepyloric filling defects (Figs. 187-190)	276	— tube in prevention of post-operative distension	781
Pressure, abdominal, in post-operative cardiac failure	770	— — — vomiting in surgical dyspepsia	775
— sterilization of instruments (Fig. 267)	357	Rectosigmoid carcinoma, operative approach to	989
Primary shock	761	— resection with anastomosis in cancer of rectum	977, 989
Prolapse of visceral contents after upper abdominal operation	800	— — — sutured anastomosis (Figs. 648-651, 655)	961, 970
Proliferative, appendicitis, chronic	842	— — — telescopic anastomosis (Figs. 652-657)	967
— — — diagnosis of	895, 912	Rectum, <i>abaissement</i> of (Fig. 683)	1009
— — — carcinoma of body of pancreas	741	— cancer of, Miles operation, tech- nique (Figs. 686-688)	1015-1018
— — — proximal colon, operation for (Figs. 615, 616)	808	— — — operative approach to	989
— — — — syndrome of	891, 892	— — — pathological types	976
Prostato-rectal fistula, surgical manage- ment of	1019	— — — standard operation methods	976
Protein administration in hæmatemesis	299	— — — surgery of	976-979
Proximal colon (see Colon, Proximal)		— — — defunctioned, pre-operative pre- paration of (Figs. 663, 664)	988
Pseudo-diverticulum, duodenal	173	— — — principle of operation on (Figs. 658-662)	980
Pseudo-inflammatory intestinal obstruc- tion	817	— — — technique of operation on (Figs. 663-685)	987-1014
Pseudo-obstruction, toxic	817	— 'loose area' around, as danger in surgery (Figs. 661, 662)	984
Pulmonary complications after opera- tions in surgical dyspepsia	785	— in megacystitis	60
— insufficiency, abdominal operations and	378	— penetrating injuries of (Figs. 689, 690)	1020
Pulsion diverticulum of duodenum (Fig. 103)	173	— perineal resection in two stages (Fig. 684)	1012
Purpura hæmorrhagica, spleen and	603	— perineo-abdominal resection of (Figs. 665-682)	978, 989
— thrombocytopenic, splenectomy in	610	— resection of, operation on function- ing bowel (Figs. 686-688)	1015-1018
Pus discharged through fistula after cholecystostomy	727	— surgery of, unfavourable conditions peculiar to	980
Pyelography in diagnosis of enlarged spleen (Fig. 492)	593	— upper part (see Colon, Distal)	
Pylephlebitis, hepatomegaly in	626	Rectus muscle, hæmatoma of	405
Pyloric antrum, normal gastroscopic appearance (Fig. 213)	309	— — — in incision for cholecystectomy (Fig. 558)	703
— carcinoma, dyspepsia of (Figs. 145- 148)	228	— — — and nerves of abdominal wall (Fig. 289)	386
— muscle, hypertrophy of, filling defect due to (Figs. 191-193)	278	Reflex dyspepsia (see Dyspepsia)	
— obstruction, gastro-enterostomy for	427	— dyspeptic dysphagia	18
— occlusion in gastro-enterostomy, jejunal ulceration and	179, 180	Regional ileitis (Fig. 614)	886
— stenosis complicating gastric ulcer	143	Regurgitation after gastro-enterostomy	430
— — — incomplete, dyspepsia due to (Figs. 23, 24)	49	<i>Rémision trompeuse</i> in appendicitis	837, 845
— — — intermittent, from gastric mucous-membrane polyp (Figs. 201, 202)	287	Renal (see also Kidney)	
— — — with chronic gastric ulcer, radio- surgical diagnosis	259	— dyspepsia	86
— — — X-ray diagnosis (Fig. 195)	282	— insufficiency, abdominal operability and	374
— ulcer, characteristics (Figs. 71, 72)	128	— — hæmatemesis in	295
Pylorus, hypertrophy of, dyspepsia due to	413	— — — manifestations with appendicitis	333
Pyriform fossa, epithelioma of, dys- phagia due to (Fig. 3)	5		

	PAGE		PAGE
Renal pelvo-ureteral obstruction, incomplete, dyspepsia of (<i>Figs.</i> 304, 305) -	409	Schindler's tube for anæsthetization of pharynx and hypopharynx (<i>Fig.</i> 206) -	303
Respiration, abdominal, in post-operative cardiac failure -	770	Scirrhus carcinoma of pancreas (<i>Fig.</i> 578) -	742
— centres, stimulation of, in post-operative shock -	767	— — — dyspepsia due to (<i>Fig.</i> 39) -	83
Rest, prolonged, disadvantages of -	801	Scissors dissection in abdominal cavity (<i>Figs.</i> 251, 252) -	318, 350
— in the stopping of hæmatemesis -	299	— — — cholecystectomy (<i>Fig.</i> 561A) -	707
Reticulo-endothelial system, spleen and Retraction in exposure of gall-bladder (<i>Figs.</i> 244-248) -	595	Scolices in hydatidosis -	627
— of intestines in abdominal operations -	340	Secondary shock -	761
Retractors, abdominal (<i>Fig.</i> 261) -	356	Seemen's (von) clamping apparatus for closure of duodenal stump in partial gastrectomy (<i>Fig.</i> 369) -	489
— — — insertion of (<i>Figs.</i> 233-236) -	330, 332, 340, 341	— crushing and suturing instrument (<i>Fig.</i> 685) -	1013
— for Devine operating frame (<i>Fig.</i> 225) -	326	Sensory innervation of stomach (<i>Figs.</i> 14-20) -	29
— visceral, spoon (<i>Fig.</i> 228) -	329	Sennatin intramuscularly in acute pancreatic necrosis -	735
Retrocaecal appendiceal abscess, chronic, diagnosis of -	895	Sepsis, rectal surgery and -	981
— appendicitis -	833, 854	— wound, in surgical dyspepsia -	799
— — operation for (<i>Figs.</i> 610, 611) -	875	Seromuscular suture in Billroth II operation (<i>Figs.</i> 398, 401) -	510, 512
Retrocolic gastro-entero-anastomosis in partial gastric exclusion (<i>Fig.</i> 450) -	554	— — of duodenum in partial gastrectomy (<i>Fig.</i> 362) -	487
— method in gastro-entero-anastomosis (<i>Figs.</i> 377-382) -	497	— — jejunum after undoing gastro-jejunal anastomosis (<i>Figs.</i> 468-470) -	573
Retrograde appendicectomy -	865	— — in Polya gastro-entero-anastomosis (<i>Figs.</i> 385, 386, 391) -	500, 504
Retroperitoneal appendicitis -	854	— — of stomach after undoing gastro-jejunal anastomosis (<i>Fig.</i> 466) -	573
— cellulitis due to retrocaecal appendicitis -	855	Serous sutures in Billroth II operation (<i>Fig.</i> 397) -	509
— tissue plane in upper abdominal surgery -	380	— — gastro-enterostomy (<i>Figs.</i> 319, 325) -	445
Rigidity, epigastric, in gastric carcinoma -	238	— — Polya gastro-entero-anastomosis (<i>Figs.</i> 384, 392) -	500, 504
Ringer's solution in post-operative shock -	764	Sex incidence of peptic ulcer -	103, 104
Rupture of hydatid of liver -	629, 630	Shock after upper abdominal operations in cases with crippled circulatory mechanism -	767
— — — into bronchus -	646	— — — — normal circulation (<i>Fig.</i> 585) -	759
— — — pleural cavity (<i>Fig.</i> 527) -	644	— — — — causation -	759, 760
— — — through diaphragm (<i>Figs.</i> 524-526) -	642	— chemical -	761, 762
— spleen -	608	— in pancreatic necrosis -	731
— — splenectomy in -	611	— post-operative, blood transfusion in (<i>Fig.</i> 586) -	764, 765, 771
SALINE intravenously in paralytic ileus -	784	— — prevention of -	762
— — post-operative shock -	764, 766	— — treatment (<i>Fig.</i> 585) -	764
— — vomiting in surgical dyspepsia -	776	— primary -	761
— — in preparation for ileo-transverse colostomy in cancer of proximal colon with obstruction -	904	— secondary -	761
— — — operation for intestinal obstruction -	824	Sigmoid artery in circulation of anal canal in resection of rectum -	1002
— — — vomiting due to gastroduodenal ileus -	777	— colon (<i>see</i> Colon, Sigmoid)	
Salpingitis simulating appendicitis -	840	Sigmoidectomy, partial, with sutured anastomosis (<i>Figs.</i> 646, 647) -	958
Salt and water in appendicitis in young -	881, 882	Sigmoideo-rectal resection with sutured anastomosis (<i>Figs.</i> 648-651, 655) -	961, 970
Salvarsan, jaundice due to injections of -	752	— — — telescopic anastomosis (<i>Figs.</i> 652-657) -	967
Sarcoma of stomach, bleeding from, question of operation in -	294	Sigmoidoscopic diagnosis in cancer of sigmoid and diverticular tumour -	930
— — dyspepsia of (<i>Figs.</i> 122-126) -	201	Sigmoidotomy for removal of adenomata -	961
— — X-ray diagnosis (<i>Figs.</i> 197, 198) -	285, 286	'Silent' gastric carcinoma (<i>Figs.</i> 150-153) -	232
Schicht-aufnahmen in diagnosis of surgical dyspepsia -	243		

	PAGE		PAGE
'Silent' gastric carcinoma, errors of diagnosis in	240	Spleen, wandering, splenectomy in	611
— — — hæmatemesis in	297	Splenectomy, indications for	609
— — — radio-surgical diagnosis	248	— operation of (<i>Figs.</i> 498-509)	611
Silk sutures and ligatures in closure of abdominal wounds	541	— in ruptured spleen	608, 609
Silkworm-gut sutures in abdominal surgery	541	Splenic anæmia	596
Skin, closure of, in abdominal operations (<i>Fig.</i> 440)	547	— — — bleeding from operation in	294
Skull changes in acholuric jaundice (<i>Fig.</i> 493)	598, 599	— — — hepatomegaly in	623
Solvac container for intravenous solutions (<i>Fig.</i> 585)	765	— — — splenectomy for	609
Spasm(s) of bladder	65	— flexure, cancer of, resection of	974
— choledochoduodenal sphincter after cholecystectomy	714, 715	— pedicle clamp (<i>Fig.</i> 508)	619
— colon	66	Splenomedullary leukæmia, spleen and — — — splenectomy in	603, 610
— duodenum	66	Splenomegaly (<i>see</i> Spleen, Enlarged)	
— œsophagus	66	Spoon visceral retractors (<i>Fig.</i> 228)	329
— pathological, of alimentary canal (<i>Fig.</i> 31)	64	— wooden, for use in front of X-ray screen (<i>Fig.</i> 176)	269
— in sigmoid (<i>Fig.</i> 31)	64	Spur formation in gastro-enterostomy	430
— of small intestine	66	Stereoscopic 'Binokel' for viewing radiographs (<i>Fig.</i> 158)	244
— sphincter of Oddi, retrojection of bile into pancreas due to	731	Sterilization of instruments under pressure (<i>Fig.</i> 267)	357
— stomach	66	Sthenic males, type of stomach in (<i>Fig.</i> 21)	41
Sphincter(s) of anus in conservative resection of rectum, method of dealing with (<i>Fig.</i> 679)	1003	— type, duodenal ulcer and	417
— control in rectal surgery	983	Stoma in gastro-enterostomy, choosing site (<i>Figs.</i> 314-316)	440
— of gall-bladder (<i>Fig.</i> 535)	655	— — — emptying time in relation to site and size of (<i>Fig.</i> 306)	428, 429
— hypertrophy of, pathological dilatation due to	61	Stomach (<i>see also</i> Gastric)	
— of Oddi, function of	654	— adhering to abdominal wall	398
Spinal anæsthesia in cholecystectomy	701	— adhesions in vicinity of, dyspepsia due to	198
— — — intestinal obstruction	825	— aspiration of, in partial gastrectomy (<i>Fig.</i> 350)	478
— — — minimization of post-operative shock	762	— benign tumours of, bleeding from operation in	294
— — — partial gastrectomy	472	— — — X-ray diagnosis (<i>Figs.</i> 199-202)	287
— — — rectal operations	983	— bleeding, partial gastric exclusion in	560
Spindle-celled sarcoma of stomach (<i>Figs.</i> 124, 125)	202	— carcinoma of, age and site incidence	209
Spleen, cancer of	606	— — — bleeding from, operation in	294
— cysts of	604	— — — classification of types of dyspepsia	212
— enlarged, in association with diseases due to abnormal white blood-cells	603	— — — dyspepsia of (<i>Figs.</i> 133-156)	
— — — conditions associated with (<i>Figs.</i> 493-495)	596	— — — early diagnosis of	46, 48, 210
— — — diagnosis of (<i>Figs.</i> 491, 492)	592	— — — errors of diagnosis of 'silent' type	240
— — — erythrocythæmia and (<i>Fig.</i> 495)	602	— — — diagnosis from cancer of lower œsophagus	9
— — — hæmolytic icterus and (<i>Figs.</i> 493, 494)	597	— — — gastroscopic appearances of of (<i>Fig.</i> 219)	313
— — — hæmorrhagic purpura and	603	— — — importance of early recognition	211
— — — infective conditions causing	604	— — — inoperable, partial gastric exclusion in (<i>Figs.</i> 446, 452)	553
— — — — — splenectomy in	610	— — — mechanical effects of	42
— — — pernicious anæmia and	600	— — — method of causation of symptoms	211
— — — portal cirrhosis and	604	— — — mode of onset	210
— — — splenic anæmia and	596	— — — pain due to (<i>Figs.</i> 18, 19)	36, 44
— — — in X-ray diagnosis of painless dyspepsia with hæmatemesis	253	— — — partial gastrectomy for (<i>Figs.</i> 331-333)	455
— functions of	594	— — — radiological view of operability of (<i>Fig.</i> 203)	289
— hydatid cyst of	605	— — — significance of certain symptoms and signs (<i>Fig.</i> 156)	237
— — — splenectomy in	611	— — — value of test-meal in diagnosis	239
— operative approach to	389	— deflation of, in exposure of gall-bladder (<i>Figs.</i> 242, 243)	341
— rupture of	608	— — — gastric resection (<i>Figs.</i> 329, 330)	453
— — — splenectomy in	611		
— and splenomegaly (<i>Figs.</i> 491-509)	592-620		
— wandering (<i>Figs.</i> 496, 497)	606		

	PAGE		PAGE
Team work in abdominal surgery	320	Tumour(s), appendicitic	842
Tenderness in chronic duodenal ulcer	160	— diagnosis	895, 912
— gastric ulcer	126	— carcinoid, of appendix (<i>Fig.</i> 613)	883
— differential diagnosis of duodenal ulcer and gall-stones	663	— complicating gastric ulcer	142
— dyspepsia (<i>Fig.</i> 13)	25	— desmoid, over cæcum, diagnosis of	896
— radio-surgical diagnosis in (<i>Figs.</i> 165-173)	254	— diverticular	918
— hypochondriac, in gall-bladder syndrome, differential diagnosis (<i>Figs.</i> 548, 549)	687	— causing lump in left iliac fossa	912
— localized, in acute appendicitis	838	— diagnosis from cancer of sigmoid colon	929
— in reflex gall-bladder dyspepsia, diagnosis and significance of (<i>Fig.</i> 38)	82	— intestinal obstruction due to	924, 926
Tenismus in cancer of distal colon	906	— pelvic appendicitis simulating	852
— ulcerative colitis	909	— due to diverticulum of stomach (<i>Figs.</i> 130, 131)	207
Tension impulses from stomach, path of (<i>Fig.</i> 14)	30	— jejunal obstruction (<i>Fig.</i> 120)	196
— receptors of gastric wall	29	— of gall-bladder, diagnosis of	896
— — — stimulation of (<i>Figs.</i> 15-20)	31	— prepyloric filling defect due to (<i>Fig.</i> 194)	280
Terminal ileitis (<i>Fig.</i> 614)	886	— in gastric carcinoma (<i>Figs.</i> 154, 155)	236, 238
Test(s), Dukes's, for urine in fæces and fæces in urine	928	— ileocæcal, due to pelvic appendicitis	852
— liver function, in absence of cholecystographic shadow	674	— of left iliac fossa in cancer of distal colon	908
Test-meal in diagnosis of gastric carcinoma	240	— — — innocent conditions of distal colon	911
— — penetrating gastric ulcer (<i>Fig.</i> 78)	140	— renal, diagnosis of	896
Thoracic pain, left, in gall-stone, diagnosis from angina	697	— of stomach, dyspepsia of (<i>Figs.</i> 122-131)	201-208
Thorotrast in cholangiography	754	— — unusual, X-ray diagnosis (<i>Figs.</i> 197-202)	285
Thrombocytopenic purpura, splenectomy in	610	— umbilicus	405
Thrombosis migrans with anæmia and enlarged spleen	600	Tyrodé's solution in post-operative shock	764
Tomography in diagnosis of surgical dyspepsia	243	ULCER carcinoma of stomach (<i>Figs.</i> 79-84)	145
Towels in upper abdominal operations (<i>Figs.</i> 230, 237)	330	— — dyspepsia of (<i>Fig.</i> 144)	227
Toxic nature of secondary shock	761	— carcinomatous prepyloric, radiography in	271
— pseudo-obstruction	817	— duodenal (<i>see</i> Duodenal Ulcer)	
Transient cardiospasm	17	— duodenitis	153
Transperitoneal approach in diaphragmatic hernia (<i>Figs.</i> 473-475)	578	— gastric (<i>see</i> Gastric Ulcer)	
Transpleural approach in diaphragmatic hernia	580	— jejunal (<i>see</i> Jejunal Ulcer)	
Traumatic diaphragmatic hernia	578	— of œsophagus, chronic peptic, dysphagia due to	17
Tray, instrument (<i>Fig.</i> 255)	355	— peptic (<i>see</i> Peptic Ulcer)	
Trendelenburg position in dealing with abdominal adhesions (<i>Fig.</i> 294)	395	— prepyloric, characteristics (<i>Figs.</i> 71, 72)	128
— — high reverse, in cholecystectomy (<i>Fig.</i> 556)	701	— — partial gastric exclusion in	557
— — — upper abdominal operations	349	— — radiography in	271
— — reversed, in dealing with abdominal adhesions (<i>Fig.</i> 295)	393	— — treatment	539
Tropical abscess of liver	624	Ulcerative colitis, diagnosis of	897
Tubal pregnancy simulating appendicitis	840	— — from cancer of distal colon	909
Tuberculosis, ileocæcal, diagnosis of	895	— — regional ileitis simulating	888
— Tuberculous adenitis, ileocæcal, diagnosis of	895	— — surgical treatment	915
— kidney, lymph passing down ureter from, simulating appendicitis	840	Umbilical pain with appendicitis	833
— mesenteric lymphadenitis, dyspepsia due to (<i>Fig.</i> 42)	87	Umbilicus, tumours of	405
Tumour(s) of abdominal wall (<i>Figs.</i> 302, 303)	403-405	Urea, tests for	928
		Urease test for urea	929
		Ureter(s), lymph from tuberculous kidney passing down, simulating appendicitis	840
		— idiopathic dilatation of (<i>Fig.</i> 30)	61
		Ureteric calculus simulating appendicitis	840
		Urinary changes in heart failure	769
		— symptoms in cancer of distal colon	907
		Urine, examination of diastase number, in acute pancreatic necrosis	732
		— in fæces, Dukes's test for	928

	PAGE		PAGE
Urine, fæces in, Duker's test for	928	Vomiting, post-operative, due to	
Urobilinogen in urine in heart failure	769	hepatic insufficiency	776
Uterus, examination of, in reflex dyspepsia	411	— in surgical dyspepsia	774
VACCINE therapy in ulcerative colitis	915	WANDERING spleen (<i>Figs.</i> 496, 497)	606
Vaginal drainage in rectosigmoid resection with sutured anastomosis	966	— splenectomy in	611
Vagotonia, type of stomach associated with (<i>Fig.</i> 21)	41	Water cure in jejunal ulcer	191
Vallecula, epithelioma of, dysphagia due to	5	Wertheim's vaginal clamp in technique of rectosigmoid resection (<i>Fig.</i> 650)	964
Vascular pedicles and ducts in relation to operative approach in abdomen	388	'Wire-drawn' abdominal adhesions	390
Vater, ampulla of (<i>see</i> Ampulla of Vater)		Wolf-Schindler flexible gastroscope (<i>Figs.</i> 204, 205)	301
Veils for use in conjunction with 'mechanical hands'	329	Wound(s), abdominal (<i>see</i> Abdominal)	
Venous congestion in heart failure, jaundice due to	752	— retractor, abdominal (<i>Fig.</i> 261)	356
— post-operative cardiac failure, treatment	770	— — — insertion of (<i>Figs.</i> 233-236)	330, 332, 340, 341
— pressure, increase in, in heart failure	769	— — for Devine operating frame (<i>Fig.</i> 225)	326
Ventilation of operating theatre	323	— sepsis in surgical dyspepsia	799
Veritol as cardiac stimulant	378	X-RAY diagnosis (<i>see also</i> Radio-surgical Diagnosis and under various organs and conditions)	
— in post-operative shock	766	— — in cancer of proximal colon	894
— pre-operatively in splenectomy	612	— — — sigmoid and diverticular tumours	930
Vesicosigmoid fistula formation in diverticulitis	928	— — — stomach (<i>Figs.</i> 134, 136-138)	215 et seq.
— surgical treatment of (<i>Figs.</i> 629, 630)	940	— — of cardiospasm and cancer of lower œsophagus (<i>Figs.</i> 5-8)	15
Viscera, prolapse of, after upper abdominal operation	800	— — duodenal ulcer (<i>Figs.</i> 97-101)	168
Visceral tenderness in dyspepsia	25	— — duodenitis (<i>Fig.</i> 56)	101
Vitality dyspepsia	72	— — hydatid of upper surface of liver (<i>Figs.</i> 524, 525)	643
Volvulus, intestinal obstruction due to		— — jejunal ulcer (<i>Figs.</i> 112-115)	186
— of sigmoid	822, 827	— — 'silent' carcinoma of stomach	248
Vomiting in acute pancreatic necrosis	732	— interpretation of operability in surgical dyspepsia (<i>Fig.</i> 203)	288-290
— after gastric operations, management of	777	— projection apparatus (<i>Fig.</i> 157)	244
— in dyspepsia	24	— therapy in cancer of pancreas	741, 743
— and nausea, significance of	68-71	'YELLOW' jaundice in gall-bladder syndrome	683
— in paralytic ileus (<i>Fig.</i> 587)	783	— — significance of	749